Unknown Speaker 0:00



.

.Good morning. This lecture is about the uveal tract anatomy and its major diseases

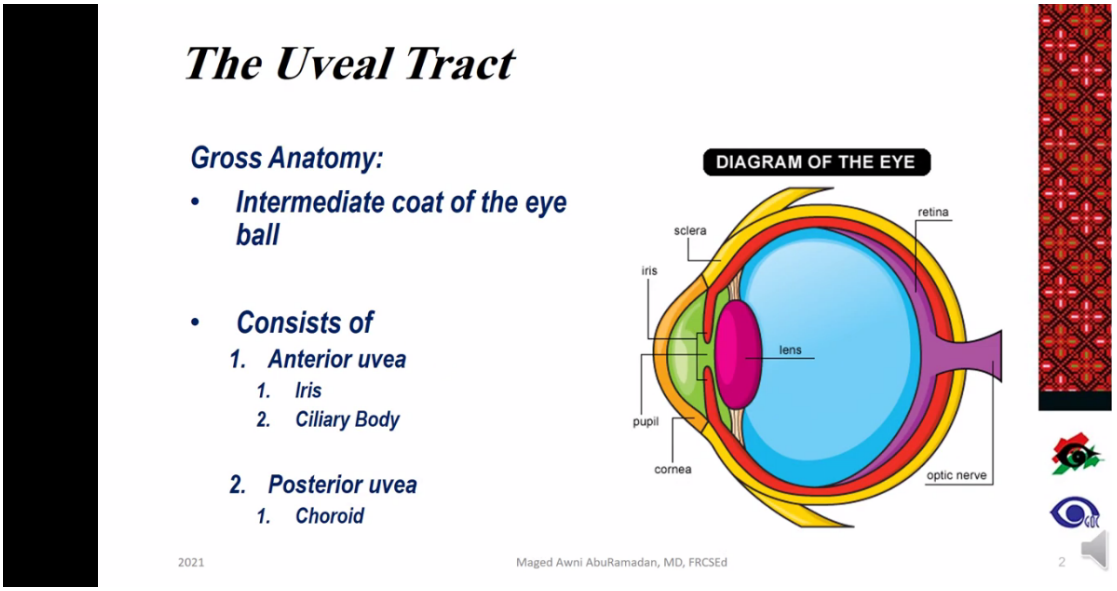

The uveal tract is the intermediate coat of the eyeball is the vascular coat formed from the iris and in front the ciliary body and in the middle and the choroid in the posterior aspect of .the globe

IRIS ANATOMY

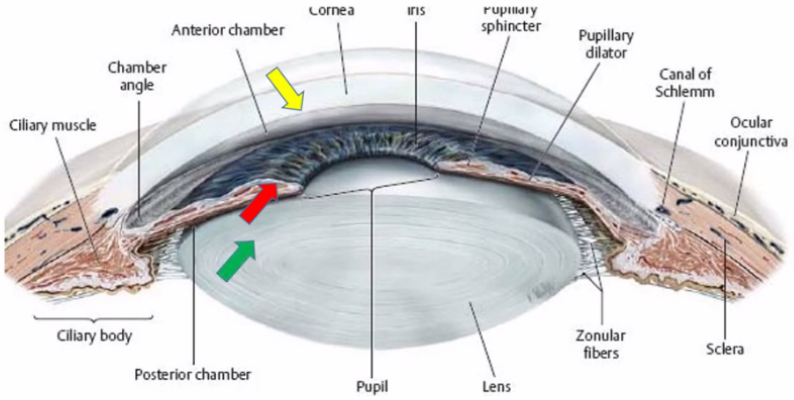

The iris is it disciform shaped with the pupil and it's middle and it is present in between the cornea and anterior chamber in front of it, the lens and the posterior chamber behind

Iris

Gross Anatomy:

- ***The anterior part of uveal tract***
- ***Pigmented circular diaphragm***
- ***Perforated in its center (pupil)***
- ***Divides the space between the cornea & the lens***
  - ***➔ Anterior Chamber***
  - ***➔ Posterior chamber***

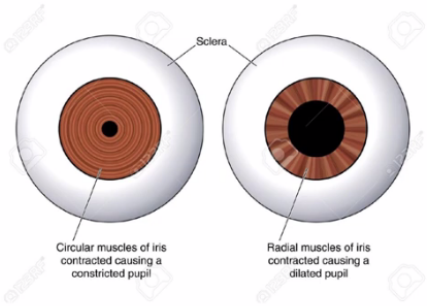

Iris is the anterior part of the uveal tract it is pigmented circular diaphragm perforated in . the center by the pupil. It divides the space between the cornea and the lens into anterior .chamber in front of it and posterior chamber

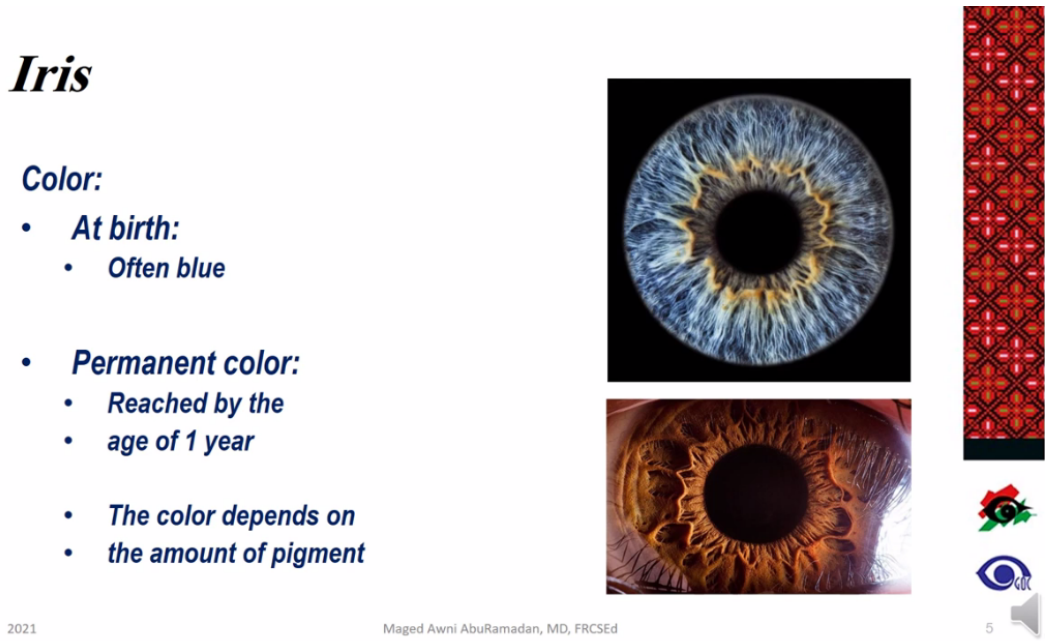

The iris color at birth is almost bluish. However, the definitive cataract the definitive color is .reach at the age of one year and it depends on the amount of pigment due to racial factors

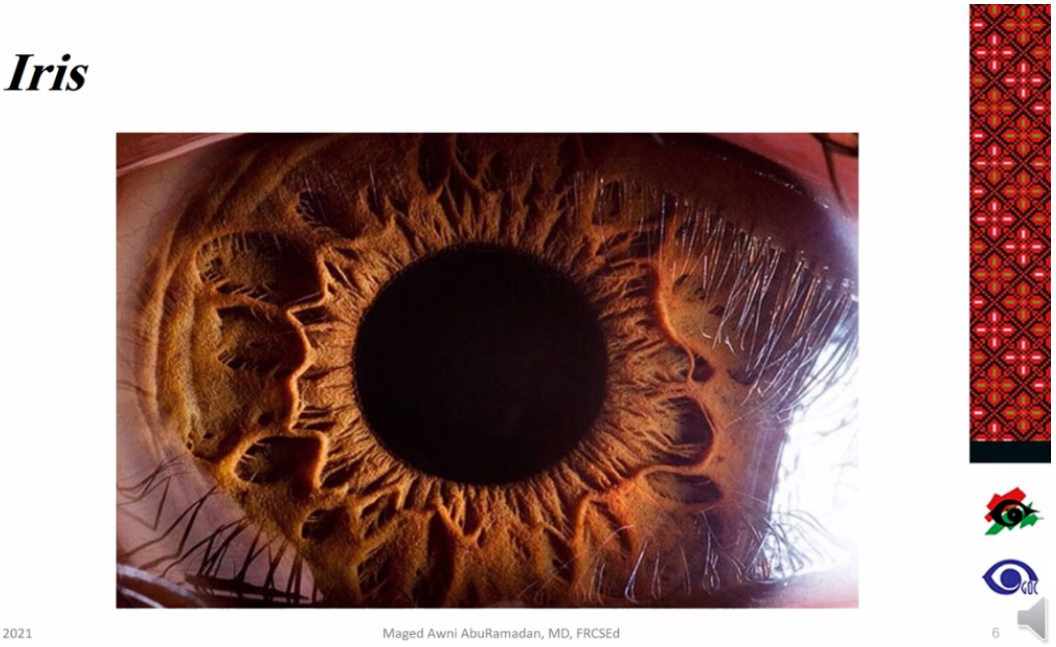

This is a detailed photograph and we can see that the iris structure is complex the pupil is in the middle and the iris there is an inner part which is much smoother than the peripheral .part of the eye

Iris

Minute Anatomy:

1. **Pigmented epithelium**
2. **Iris muscles**
   1. **Sphincter pupillae**
   2. **Dilator pupillae**
3. **Stroma**

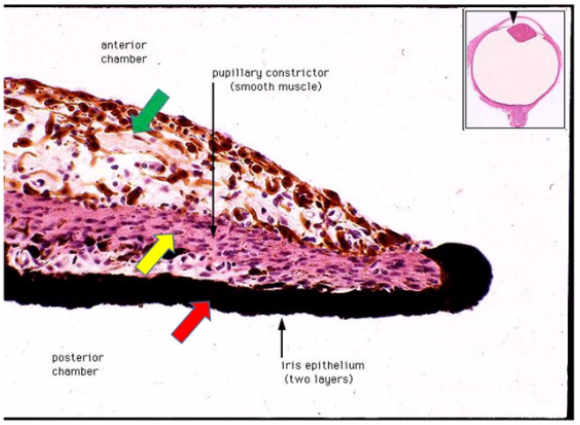

This is a histological view of the iris from back to front we have the pigmented epithelium of the iris, which is continuous with the pigmented epithelial layers of the ciliary body And the choroid behind. Then, in front of it, there is the iris muscle. We have the sphincter pupillae muscle at the edge of the pupil with dilator pupillae on the periphery and from there is a .stroma rich of blood vessels and melanocytes and pigmented cells

Iris

Minute Anatomy:

- **Iris muscles**

1. **Sphincter pupillae**
   - **A circular band**
   - **(1 mm broad)**
   - **which run around the pupil**
2. **Dilator pupillae**
   - **A radially arranged ms**
   - **which run**
   - **from ciliary border**
   - **to pupillary border**

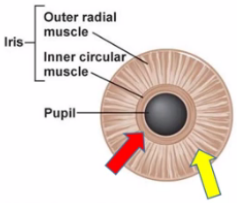

(a) Anatomy of iris and pupil

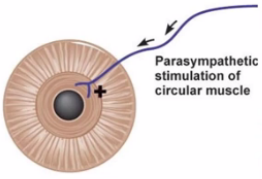

(b) Pupillary constriction

the iris muscle is the sphincter pupillaely which is a circular band one millimeter rod which runs around the pupil and then we have the dilator pupil muscle which is radially arranged .fibers running from the ciliary body to the pupillary border

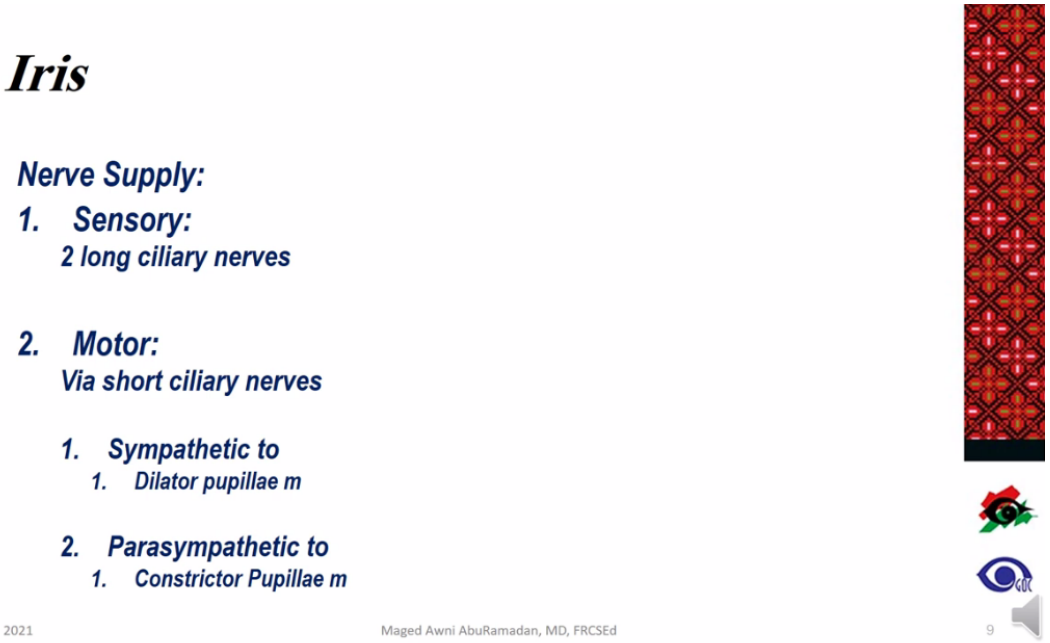

The iris have sensory and motor nerve supply the sensor is via two long ciliary nerves, the motor is via the short ciliary nerves sympathetic innervation to the dilator piccalilli and ..parasympathetic to the constructor pupil muscle



Iris have two functions first the pupil is regulation of the light entering the eye when it constricts when the light is bright and dilates in them situation. Also the iris Crypts in the anterior part of the stroma edge in the the non conventional aqueous drainage pathway .accounting to 20% of aqueous drainage

.

Ciliary Body

Gross Anatomy:

- Intermediate part of
- The uveal tract

- Extends
  - Form the iris
  - To the choroid

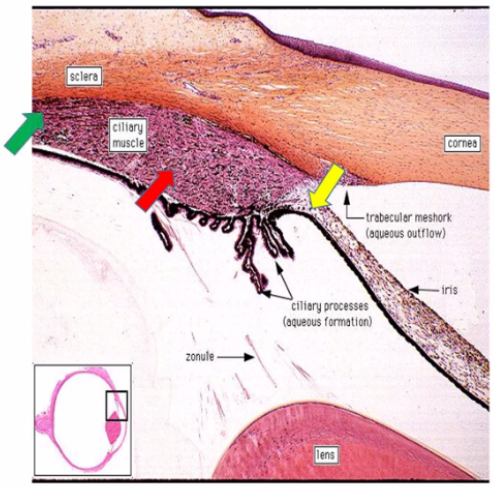

The ciliary body is the intermediate part of the uveal tract extending from the iris route to .the choroid in the back

CB

Minute Anatomy:

1. Ciliary epithelium:
   1. Continuous with iris epith
2. Ciliary processes:
   1. 75 plications
   2. Each process is formed of
      - Wide capillary
      - Covered by cil. Ep.
3. Ciliary muscles:
   1. 3 parts

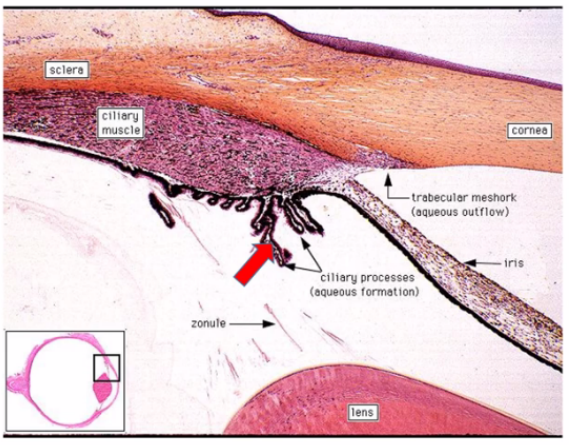

histologically the ciliary body is formed from the ciliary epithelium which is continuous with the iris epithelium and then folds in that epithelium gives the ciliary processes 75 plications almost, each process is formed by white capillary covered by the ciliary epithelium and this is the secretory part of the ciliary body. And then we have the ciliary muscle, which further .divided into three parts

CB

Function:

1. **Ciliary processes**
   1. **Aqueous Formation**
2. **Ciliary muscle:**
   1. **Circular fibers:**
      1. **Accommodation**
   2. **Longitudinal f.:**
      1. **Aqueous Drainage**
      2. **Opens Schlemm Canal**

The function of the ciliary body is that it produces and excretes the aqueous humor into the posterior chamber through the ciliary processes via active metabolic process and ultra .filtration

Ciliary Muscle

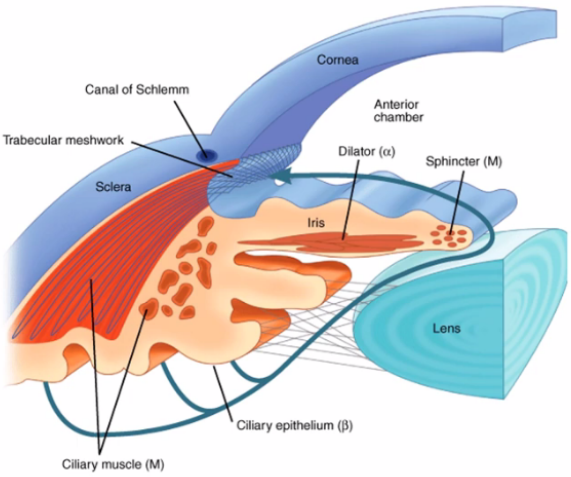

The ciliary muscle circular part is responsible for accommodation to near reflex why the longitudinal fibers helps in aqueous drainage because it pulls on the Scleral spur and opens schlemm canal. This is how the aqueous humor is produced by the ciliary epithelium into the posterior chamber passing through the pupil into the anterior chamber and finally drain .through the trabecular meshwork

Choroid

Gross Anatomy:

- The posterior part of
- The uveal tract

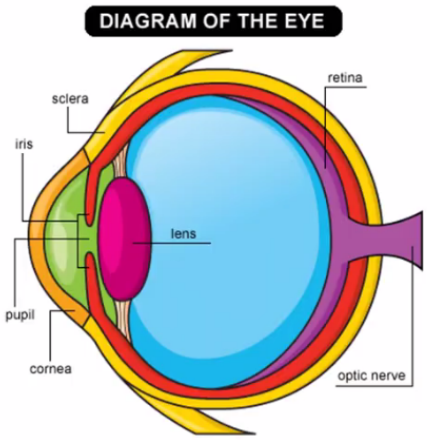

.The choroid is the posterior part of the uveal tract

Choroid

Minute Anatomy:

Stroma of

1. BV
   1. Large
   2. Medium
   3. Choriocapillaris
2. Melanocytes

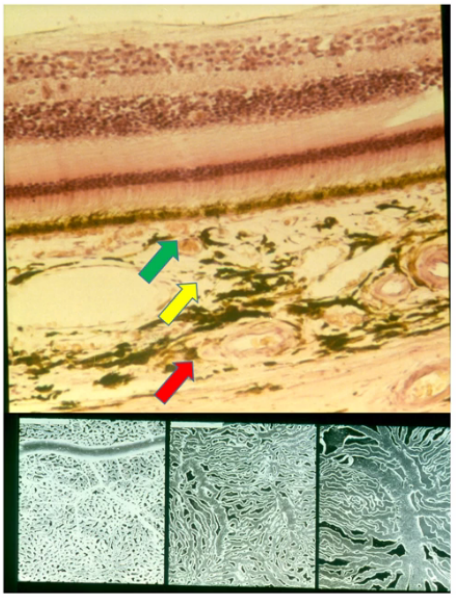

The choroid is mainly formed by large stroma containing multiple blood vessels which are larger in the periphery, medium in the middle, and then the choriocapillaris in the inner part next to the retinal pigment epithelium. There is also a lot of melanocytes giving it its color. The bottom photograph shows large micrographs of the different types of choroidal blood .vessels

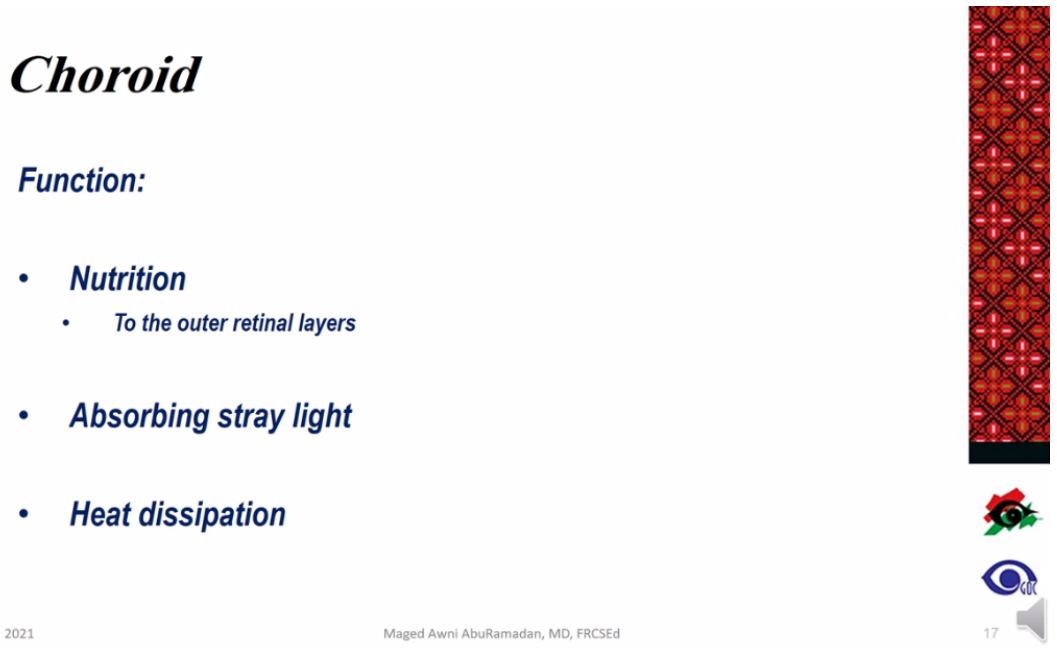

The choroid is responsible for nutrition of the outer retinal layers also as absorbing the stray light inside the eye, as well as helping in dissipating heat transmitted through light rays, with .a lot of other metabolic functions as well



uveitis means inflammation of the uveal tract. The uveitis can be classified according to the anatomical site of the part involved as anterior uveitis involving the iris and the ciliary body, posterior uveitis including the Choroid, panuveitis including both the iris Ciliary body as well .as the Choroid

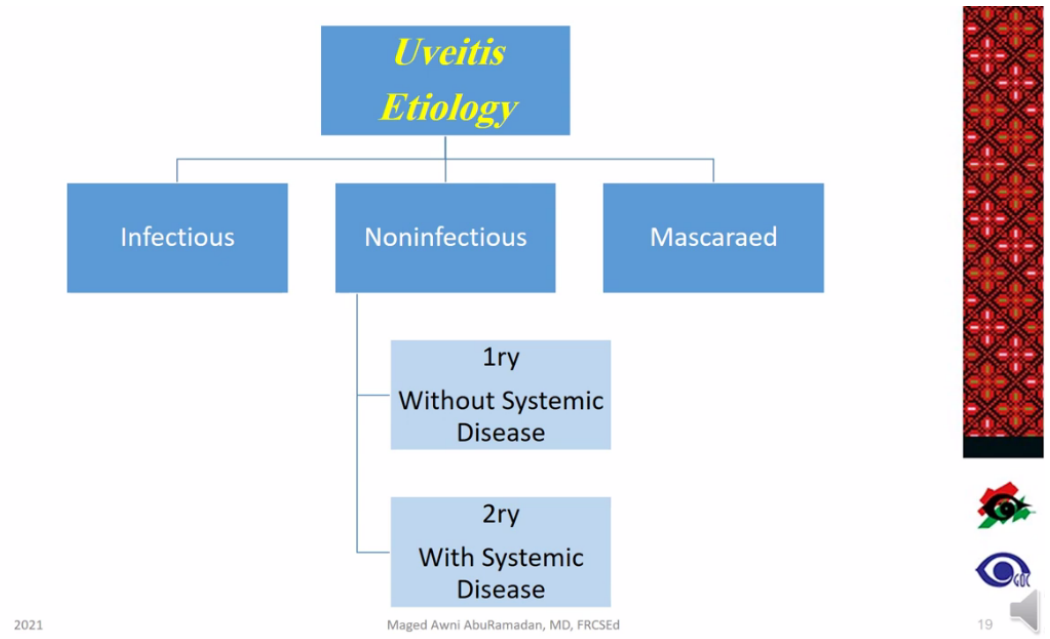

Etiologically, uveitis this can be infectious, non infectious or Mascaraed syndrome. The non infectious part can be primary without systemic disease, or can be secondary to a systemic .disease

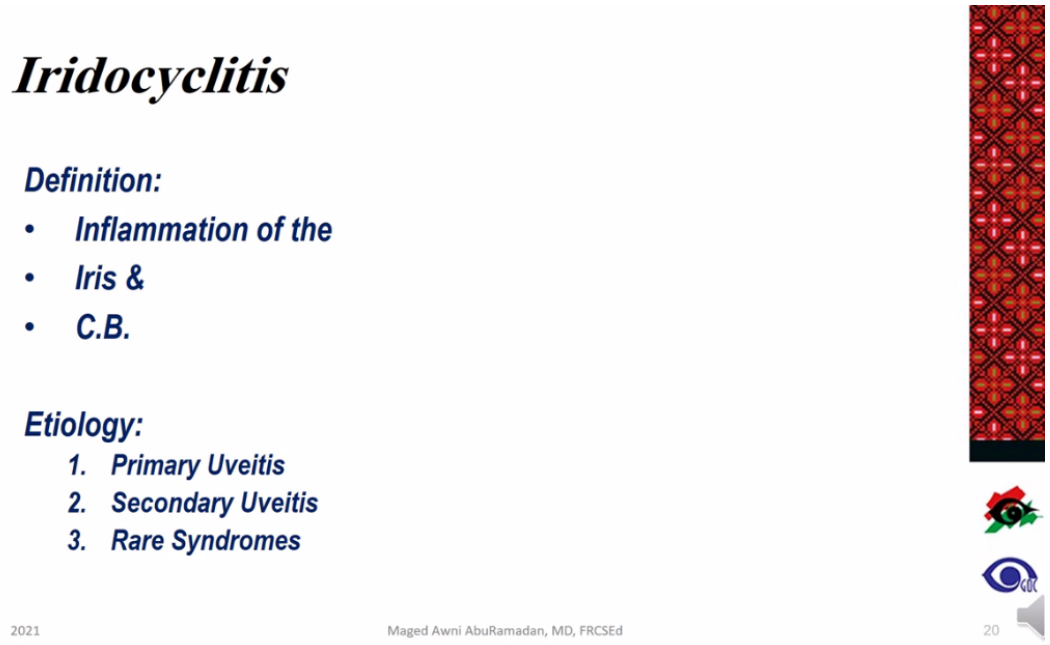

Iridoscyclitis is an inflammation of the iris and the ciliary body usually they are involved together with maybe one part involved more than the other. etiologically This can be primary ..uveitis, secondary uveitis and also within rare syndrome

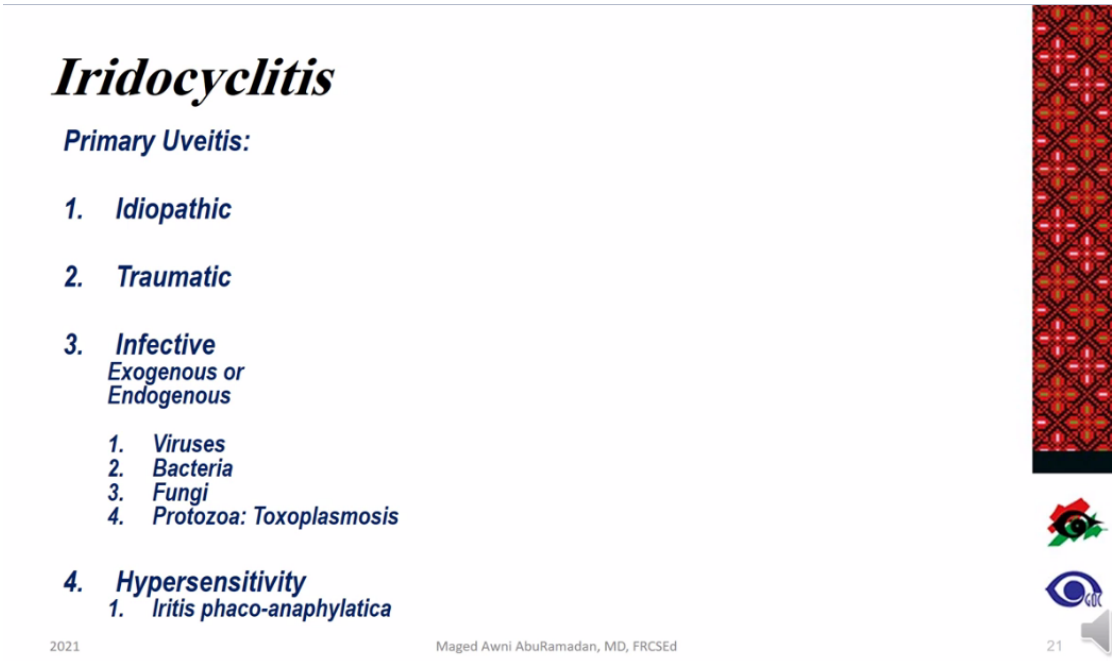

Primary uveitis this can be idiopathic, traumatic and infective whether exogenous or endogenous, by viruses, bacteria, fungi or protozoa and also can be hypersensitivity reaction .For example Iritis phacoanaphylactic

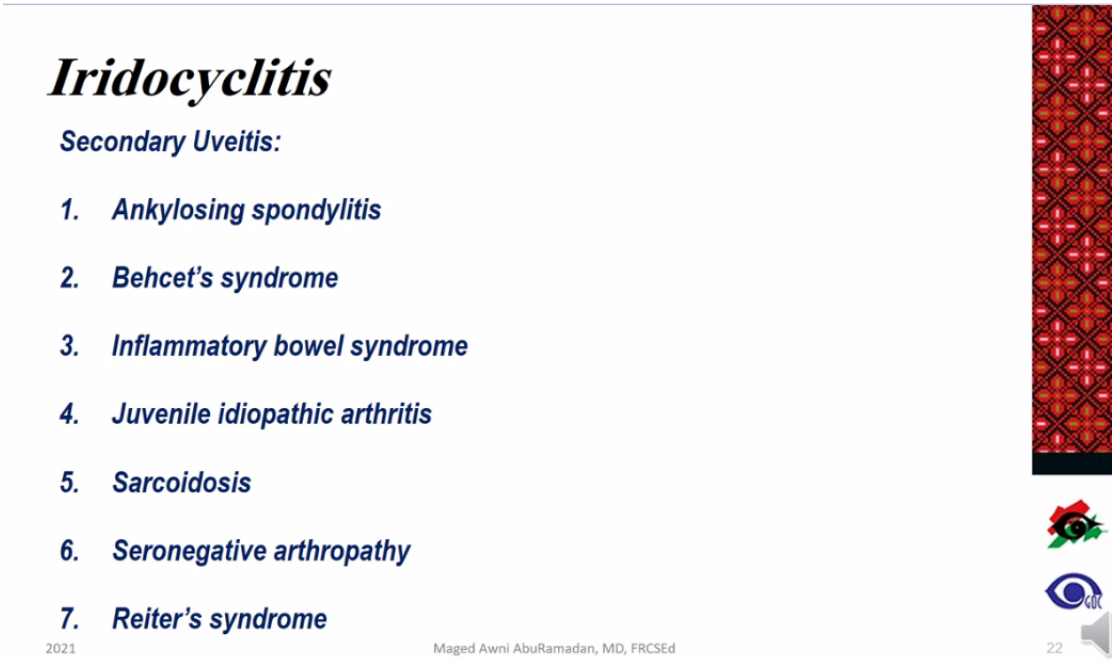

Secondary uveitis this was syndromes, the most important ones are ancylosing spondylitis, behcet's disease, inflammatory bowel syndrome, juvenile idiopathic arthritis, sarcoidosis, seronegative arthropathy and Reiter

Iridocyclitis

Rare syndromes:

1. ***Behcet's Syndrome***
2. ***Vogt-Koyanagi syndrome***
3. ***Funch's heterochromic Iridocyclitis***

other rare syndromes as we said behcet's disease,vogt-koyanagi syndrome and fuchs'. .heterochromic iridocyclitis

Iridocyclitis

Behcet Syndrome:

1. ***Bilateral***
2. ***Recurrent***
3. ***Iridocyclitis***
4. ***Posterior uveitis***
5. ***Oro-genital ulcers***
6. ***Vasculitis***



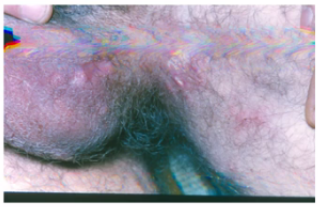

behcet's syndrome it is bilateral and it is recurrent. It is Iridocyclitis however, it can affect the posterior uvea as well. There is association of Orogenital ulcers as well as vasculitis in the .lower limp and other site

Iridocyclitis

Vogt-Koyanagi syndrome:

1. Bilateral
2. Iridocyclitis
3. Deafness
4. Vitiligo
5. Poliosis



vogt-koyanagi syndrome is bilateral Iridocyclitis associated with deafness locally we can see .Vitiligo on the skin and poliosis which means whitening of the eye lashes

Iridocyclitis

Funch's heterochromic Iridocyclitis:

1. Unilateral
2. Recurrent
3. Iridocyclitis
4. Young female
5. Heterochromia

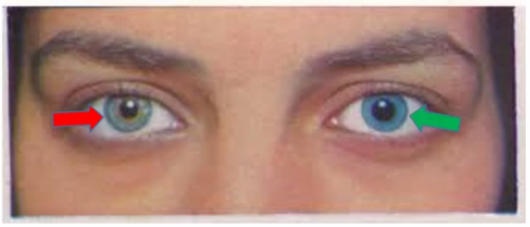

funchs' heterochromic iridocyclitis is usually unilateral however recurrent it is an iridocyclitis happening mostly in young females and there is heterochromia with the eye one is different .from the other eye

Iridocyclitis

Clinical Picture:
Symptoms:

1. ***Pain***
2. ***Photophobia***
3. ***Blepharospasm***
4. ***Decreased vision***

clinically a patient with iridocyclitis will complain from pain which is dull ache, photophobia and blepharospasm. There is also decreased vision especially in the late and complicated .case

Iridocyclitis

Signs:

- ***Lid***
  - ***Edema***
- ***Conjunctiva***
  - ***Ciliary injection***

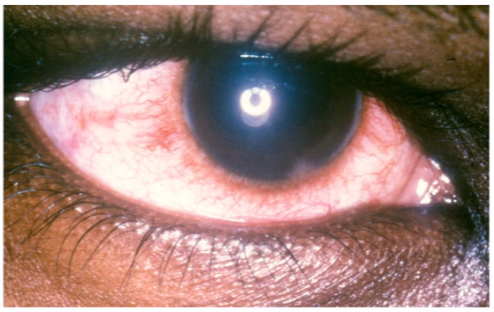

On examination we might find little LiD edema however, the conjunctiva have a particular .Ciliary injection which means redness around the Limbus

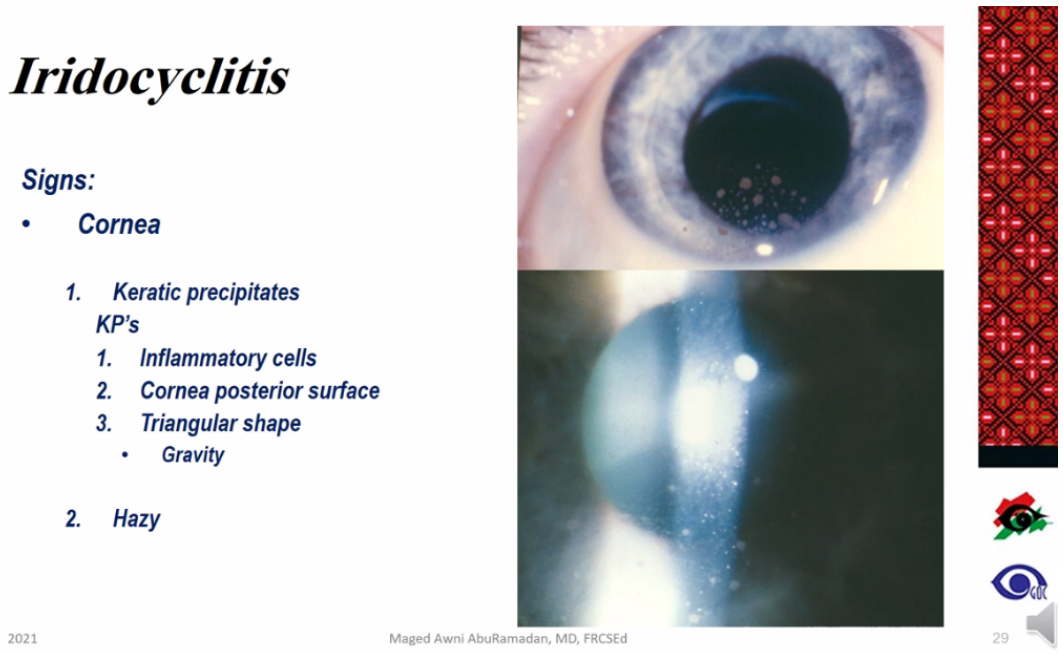

the cornea the main sign is keratic precipitates which are inflammatory cells at the posterior Corneal Surface the endothelial usually these make like a triangle and that's because of the gravity effect. The cornea is hazy and you can see the stucked with a lot of small and medium sized KPS

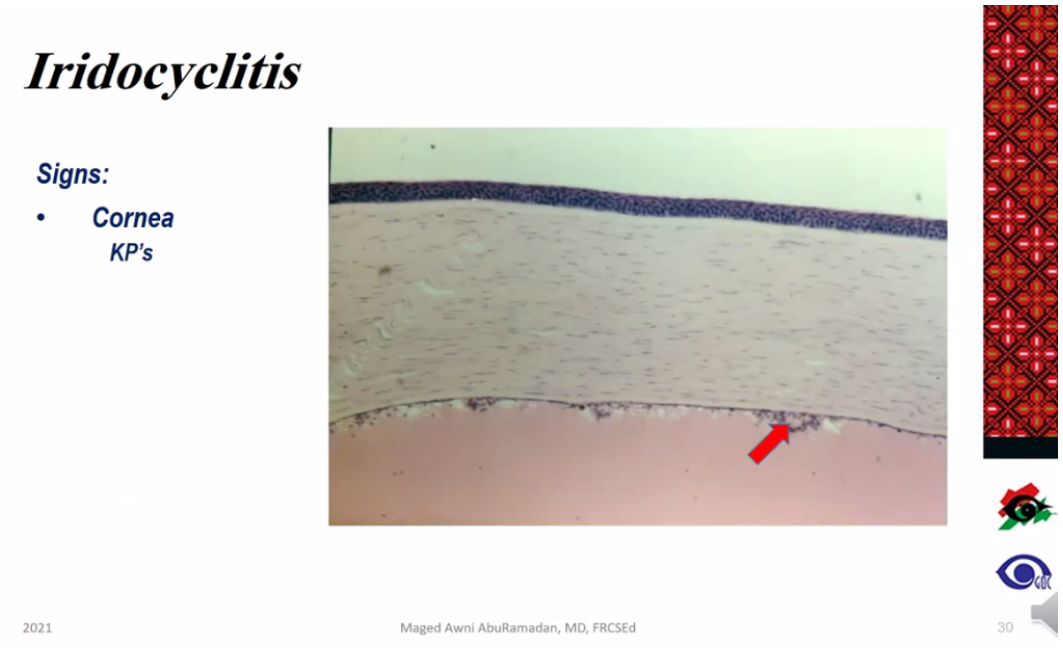

.

This is to show that the KPS are aggregations of inflammatory cells at the back of the endothelial of the cornea

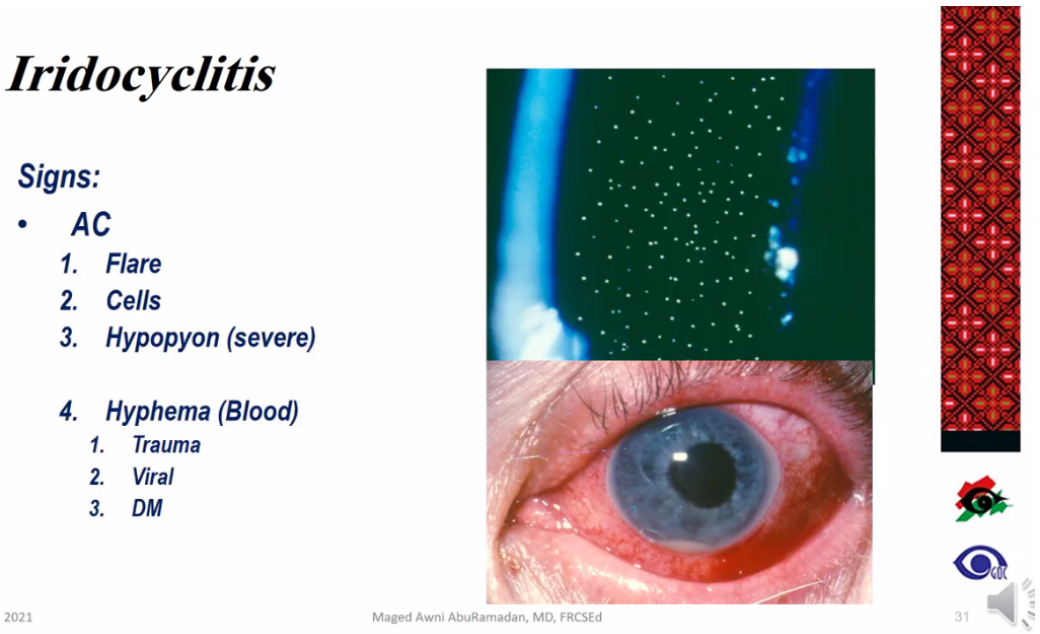

Other signs include flare and cells in the anterior chamber and when the inflammation is much severe, these cells will gravitate downward and make an hypopyon which means pus in .the lower part of the anterior chamber

In case of traumatic origin, viral origin or associated with diabetes mellitus. We can also find blood or Hyphema in the lower part of the anterior chamber

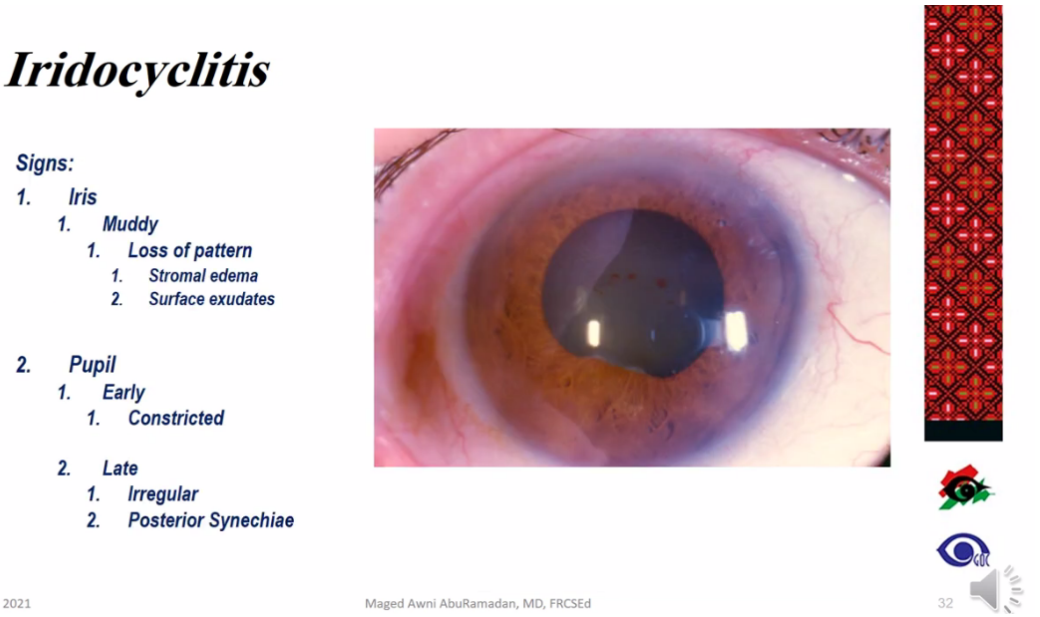

The iris is muddy in shape The details of the trabeculae is muffled, there is loss of pattern due to stromal edema and exudates on the surface, the pupil early will be constricted ,however late it will be irregular, it's not rounded and there is a posterior synechiae that sticks the posterior surface of the iris to the anterior surface of the lens and when we use mydriatic, some of these posterior synechiae will lyse and that will lead a little pigment on the anterior surface of the lens capsule

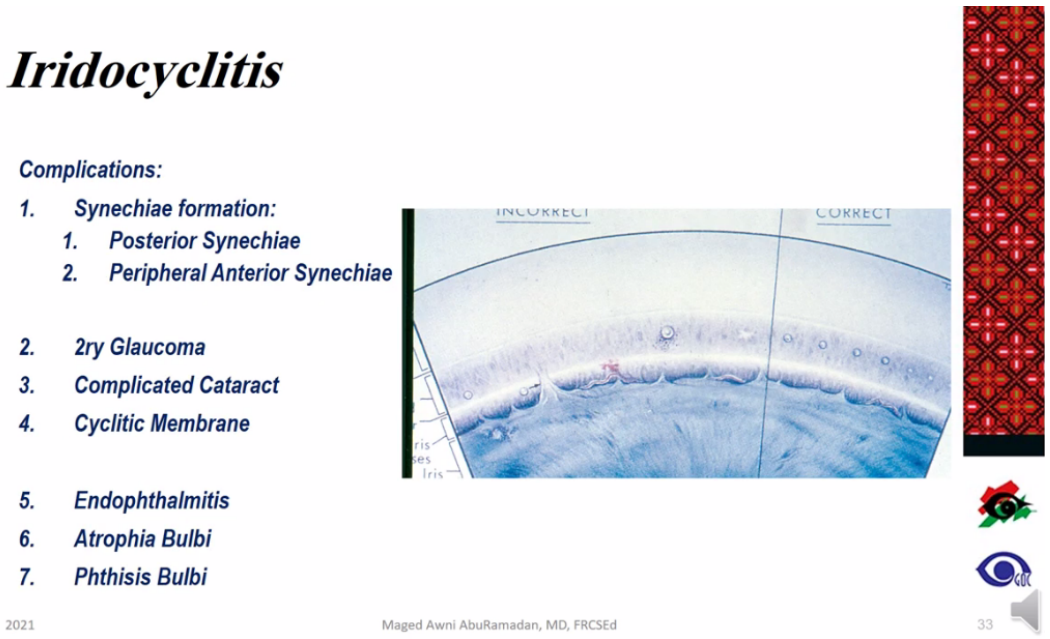

iridocyclitis have a lot of complications mainly due to synechiae formation which can be posterior synechiae as we said earlier, between the pupillary margin and the anterior surface of the lens capsule or it can be peripheral anterior synechiae where the root of the iris is stuck to the structures at the AC angle closing the angle causing secondary angle closure glaucoma. Chronic iridocyclitis due to toxins can lead to complicated cataract and in severe cases there will be a cyclitic membrane which can close the pupil totally, in very much severe and untreated and recurrent cases, severe endophthalmitis may start leading to atrophy of the globe and leading to phthisis bulbi

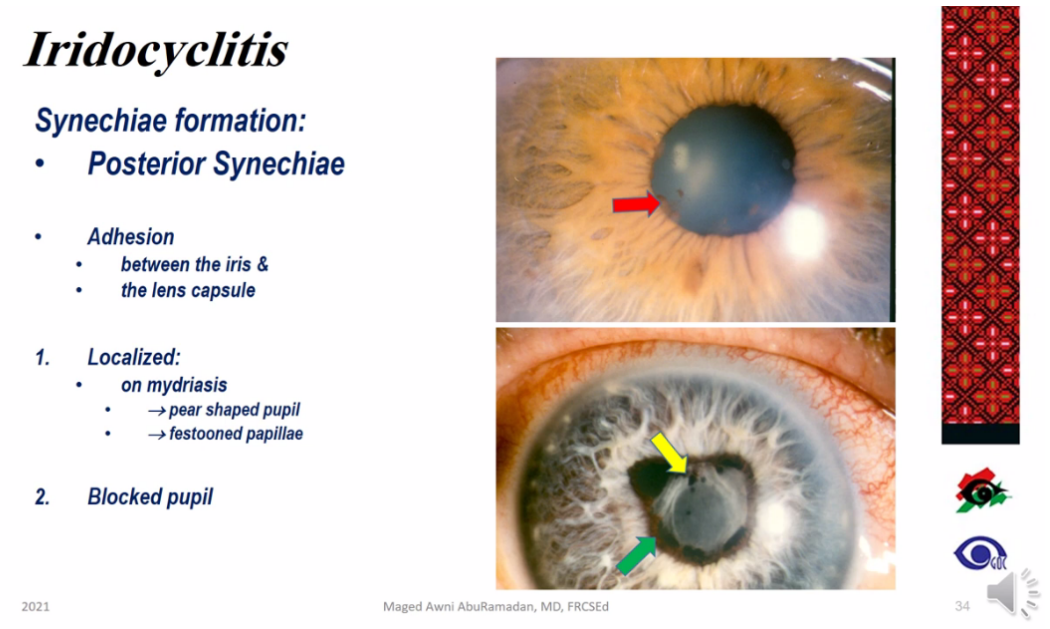

Here is a posterior synechiae which is adhesion between the iris and the lens capsule on . mydriasis the pupil will have an irregular shape, it's not rounded anymore, it's more festooned and the pupil might also be blocked by the inflammatory

Iridocyclitis

Peripheral Anterior Synechiae (PAS):

- Adhesion between
  - Peripheral Iris
  - Anterior surface &
  - Back of the cornea
- → occlusion of the
  - AC angle

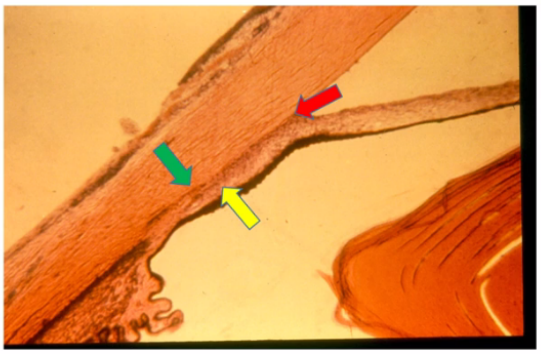

2021 Maged Awni AbuRamadan, MD, FRCSEd 35

the peripheral anterior synechiae is adhesion in between the peripheral iris and the . anterior surface of the iris in the back of the cornea, this will eventually lead to occlusion of the AC angle

Iridocyclitis

2ry Glaucoma:

1. Acute iritis:
   - Due to
     1. Plasmoid aqueous
     2. Hypopyon
2. Chromic iritis:
   - Due to
     1. Synechiae formation (PAS)
     2. Iris bombe

2021 Maged Awni AbuRamadan, MD, FRCSEd 36

So one of the important long term complications of iridocyclitis is secondary glaucoma, ... acute ririts the plasmoid thick aqueous and hypopyon will directly block the trabecular meshwork leading to rise of the intraocular pressure. However in chronic ririts, the synechiae formation especially the peripheral anterior ones will close the angle on the posterior synechiae lead to the production of Iris Bombay and once again angle closure

Iridocyclitis

Complicated Cataract:

- *Due to:*
  1. *Diffusion of toxins &*
  2. *Interference with lens nutrition*

Complicated cataract is due to diffusion of toxins and this interferes with the lens nutrition

Iridocyclitis

In long-standing Iridocyclitis

- *→ Band shaped keratopathy*
- *→ Rubeosis iridis*
- *→ NVG*

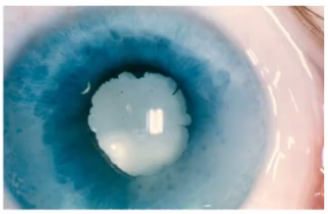

In long standing,iridocyclitis there may be a banned keratopayht which is due to prolong toxicity to corneal structure, especially the epithelium and Bowman's membrane where calcification starts to ensure them. in severe cases rubeosis iridis, which means new vessels in the iris leading to neovascular glaucoma as a severe sequelae

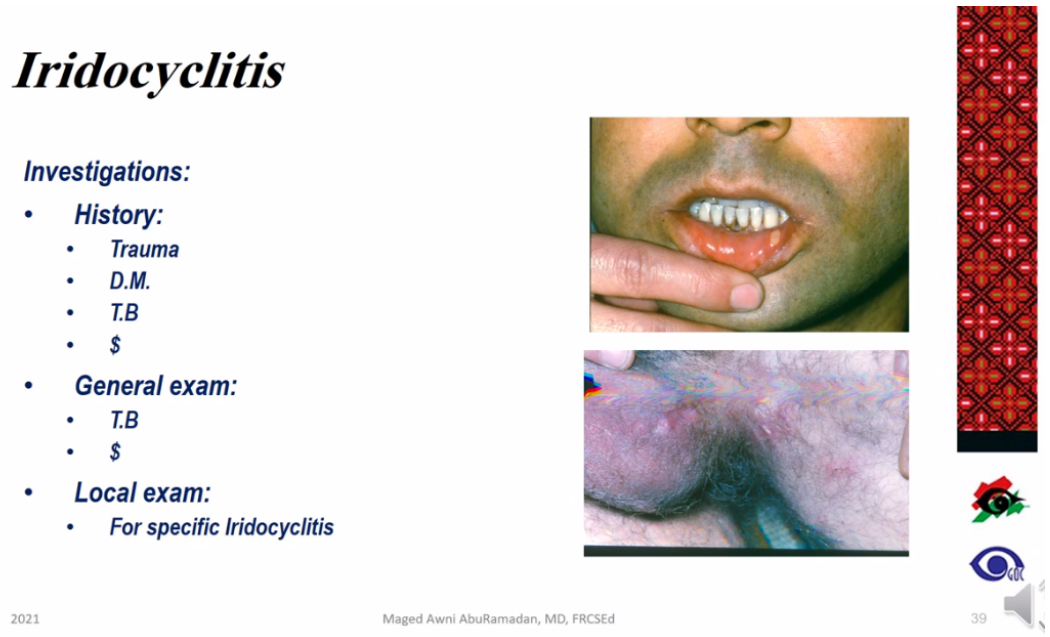

nvestigations of iridocyclitis are multiple and they are not usually indicated in the first attack. However, if the patient have several recurrent attack, or even if it's bilateral, bilateral affection from the start, then we need to do some lab testing. However, the history is very important to know whether there is a trauma diabetes, TB, syphilis. And we look for the signs of specific iridocyclitis

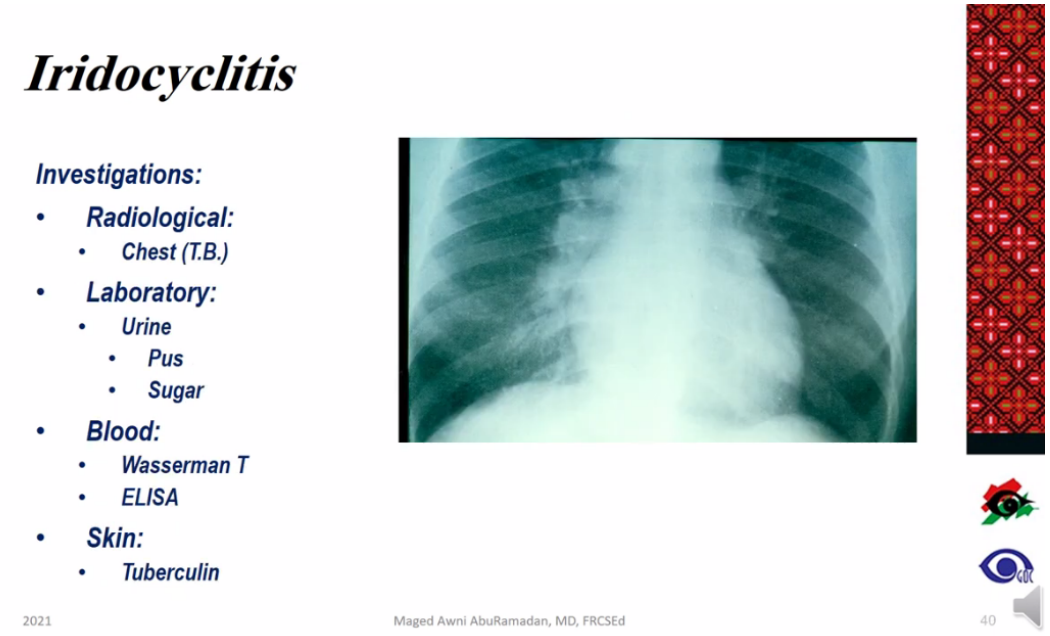

among the common investigation is a chest radiograph looking for TB or sarcoidosis. Also examining the urine examining the blood and the tuberculin test

Lab Tests for Etiologies of Uveitis	
Systemic Disease	**Recommended Testing**
Seronegative spondylarthopathies	HLA-B27, RF Spine and sacroiliac X-ray
Juvenile idiopathic arthritis	RF ANA
Sarcoidosis	ACE, lysozyme Chest X-ray
Systemic lupus erythematosus	ANA, anti-SM, anti-dsDNA, anti-SSa/anti-SSb, anti-RNP, anticardiolipin
Behcet's disease	HLA-B51 Skin pathergy test
Herpes simplex	HSV IgG/IgM
Syphilis	VDRL FTA ABS RPR
Tuberculosis	PPD, chest X-ray
Lyme disease	ELISA Western blot
Toxoplasmosis	Toxoplasma IgG/IgM
Histoplasmosis	Chest X-ray Histoplasma serology

Also examining the urine examining the blood and the tuberculin test. Here is a lot of tests . that you can check, especially when you suspect a systemic disease

Table 2: HLA Associations and Ocular Inflammatory Disease		
Disease	**HLA Association**	**Specific Relative Risk**
Acute anterior uveitis	HLA-B27	RR = 8
Reiter syndrome	HLA-B27	RR = 60
Juvenile idiopathic arthritis	HLA-DR4, -Dw2	Acute systemic disease
Behcet syndrome	HLA-B51	RR=4-6, Japanese and Middle Eastern descent
Birdshot retinochoroiditis	HLA-A29, -A29.2	RR=6
Intermediate uveitis	HLA-B8, -B51, -DR2, -DR15	RR=6
Sympathetic ophthalmia	HLA-DR4	
VKH syndrome	HLA-DR4	Japanese and North Americans
Sarcoidosis	HLA-B8; -B13	Acute systemic disease; chronic systemic non-ocular disease
Multiple sclerosis	HLA-B7, -DR2	
Ocular histoplasmosis syndrome	HLA-B7, -DR2	RR=12
Retinal vasculitis	HLA-B44	Britons

From: Intraocular Inflammation and Uveitis, Basic and Clinical Science Course, 2003-2004, American Academy of Ophthalmology, 2003, p 92.

.

And this table shows the HLA types associated with different diseases causing associated secondary uveitis

Iridocyclitis DD (Symptoms)

	Conjunctivitis	Corneal Ulcer	Iridocyclitis	Congestive Glaucoma
Pain	Discomfort	Stitching	Dull aching	Bursting
Vision	Normal	Decreased	Decreased	Marked vv
Discharge	Mucopurulent Purulent	Watery lacrimation	Watery	Watery
General	Absent	Little	Syndromes	Marked

in differential diagnosis uveitis Due to the redness of the eye and some pain and other signs have to be differentiated from conjunctivitis from corneal ulcer and from congestive glaucoma. Symptom wise we see that iridocyclitis produce dull, aching pain in contrast with the bursting pain of congestive glaucoma. Vision is decreased a little bit. However, once again, congestive glaucoma there is decreased loss of vision while the conjunctivitis is normal. The discharge in iridocyclitis is watery if any. However, the mucopurulent or purulent discharge present with conjunctivitis and corneal ulcer is a differentiating factor. Generally, iridocyclitis is associated with syndromes, while the other three categories are very little affected, or linked to systemic conditions

Iridocyclitis DD (Signs)

	Conjunctivitis	Corneal Ulcer	Iridocyclitis	Congestive Glaucoma
Redness	Fornices	Local	Peri Limbal	Diffuse
Discharge	Mucopurulent Purulent watery	Purulent	Watery	Marked Tearing
Special signs	Crusts	Fluorescein staining	KPs Cells Flare PS	^^^ IOP
General	Absent	Little	Syndromes	Headache Nausea Vomiting

.

From signs point of view, we find the redness in iridocyclitis is peri limbus around the Limbus. While it is most in the fornices in conjunctivitis, and localized to the part of the corneal ulcer, while congestive glaucoma It is diffuse. As we said earlier, the discharge is important to distinguish between conjunctivitis and iridocyclitis ,special signs we find KP cells flare in the posterior synechiae differentiates iritis from the crusts in conjunctivitis, the fluorescein staining of a corneal ulcer and they extremely increased intraocular pressure in congestive glaucoma. Generally, iridocyclitis you might show the signs of syndromes in secondary type. However, there are little or absent General signs and conjunctivitis in corneal ulcer, while congestive glaucoma might lead to headache, nausea, vomiting and mimic acute abdomen

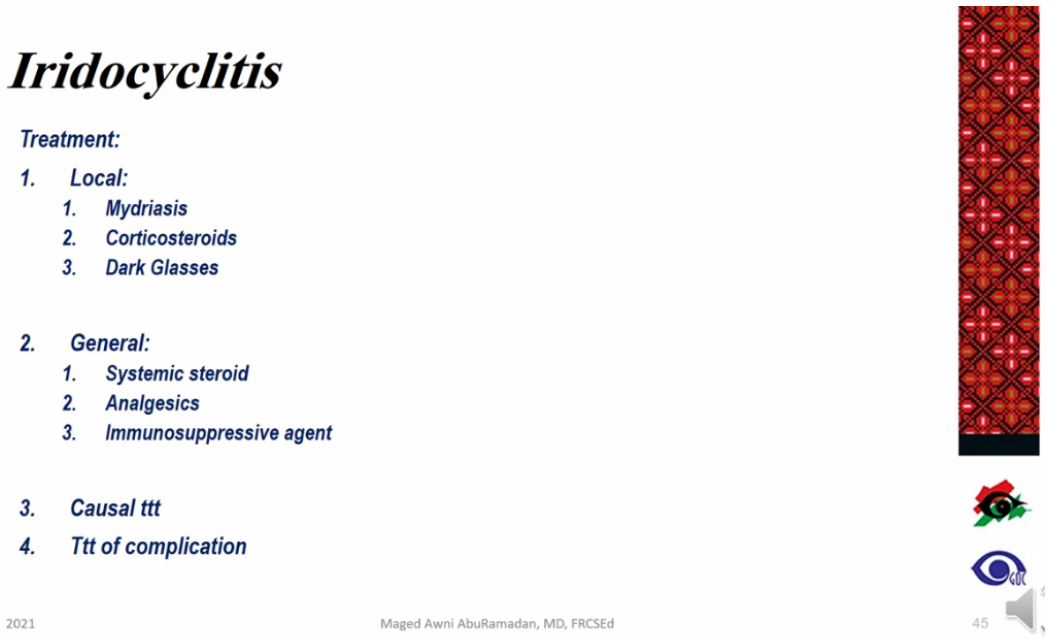

Treatment of iridocyclitis is local or general or both plus treating the cause and the complication locally we give midrics eyedrops to keep the iris moving and dilating to prevent the development of posterior synechiae. corticosteroids is the main treatment and it is needed for suppressing of the inflammatory process. dark glasses for photophobia. Generally, we can give systemic steroid if the case is severe or if there's posterior involvement. analgesic may be needed if the pain is significant, immunosuppressive agents are used as mainly steroid sparing drugs



choroiditis, inflammation of the back of the uveal tract can be exudative, granulomatous or suppurative

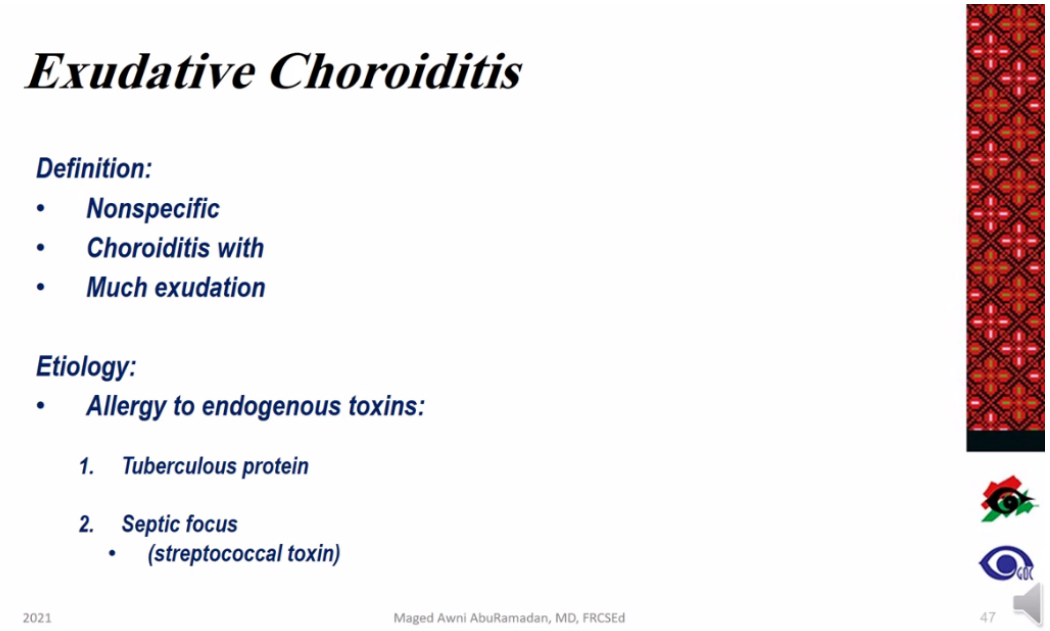

exudative choroiditis can be or is a nonspecific choroiditis With much exudation, the ... etiology, It's related to endogenous toxins like tuberculous protein or streptococcal toxin from septic foci in tonsils for example

Exudative Choroiditis

Symptoms:

1. **Due to distortion of photoreceptor**
   1. **Metamorphopsia**
   2. **Micropsia**
   3. **Macropsia**
2. **No pain**
3. **Photopsia**
   - **due to irritation of photoreceptors**
4. **Decrease of vision**

2021 Maged Awni AbuRamadan, MD, FRCSEd 48

exudative choroiditis can be or is a nonspecific choroiditis With much exudation, the . etiology, It's related to endogenous toxins like tuberculous protein or streptococcal toxin from septic foci in tonsils for example. symptoms are due to distortion of the photoreceptors in the retina, it can cause metamorphopsia or the objects have changed shape, smaller shape in micropsia or larger than normal in macropsia. Usually pain is not present in exudative choroiditis, However, photopsia or flashes of light maybe seen you to irritation of the photo receptor. visual loss is related to the site of the exudate and its extent, if it is involving the macula, it will be severe and if it is the periphery it will be more or just the visual field defect

Infective Choroiditis

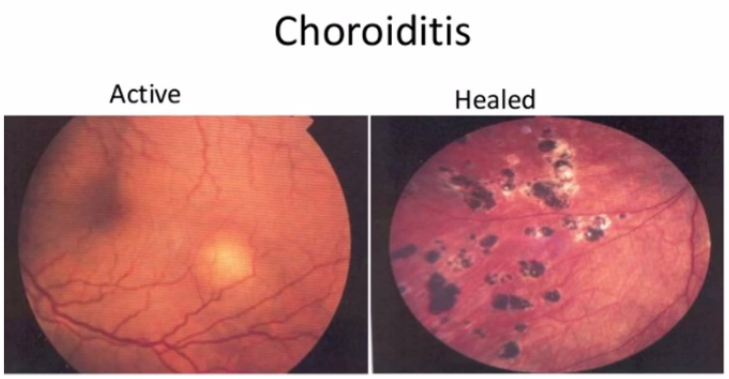

2021 Maged Awni AbuRamadan, MD, FRCSEd 49

here and this photo on the left we can see is a case of toxoplasmosis, infective choroiditis .. as a focus of or focal area of retinochoroiditis showing yellowish whitening and swelling. later on after healing of the infection Due to immune mechanism of the body there is a change in the pigment content you can see both deep pigmented and hyper pigmented areas

denoting the scarring in the retinal pigment epithelium, overlying retina and underlying choroid

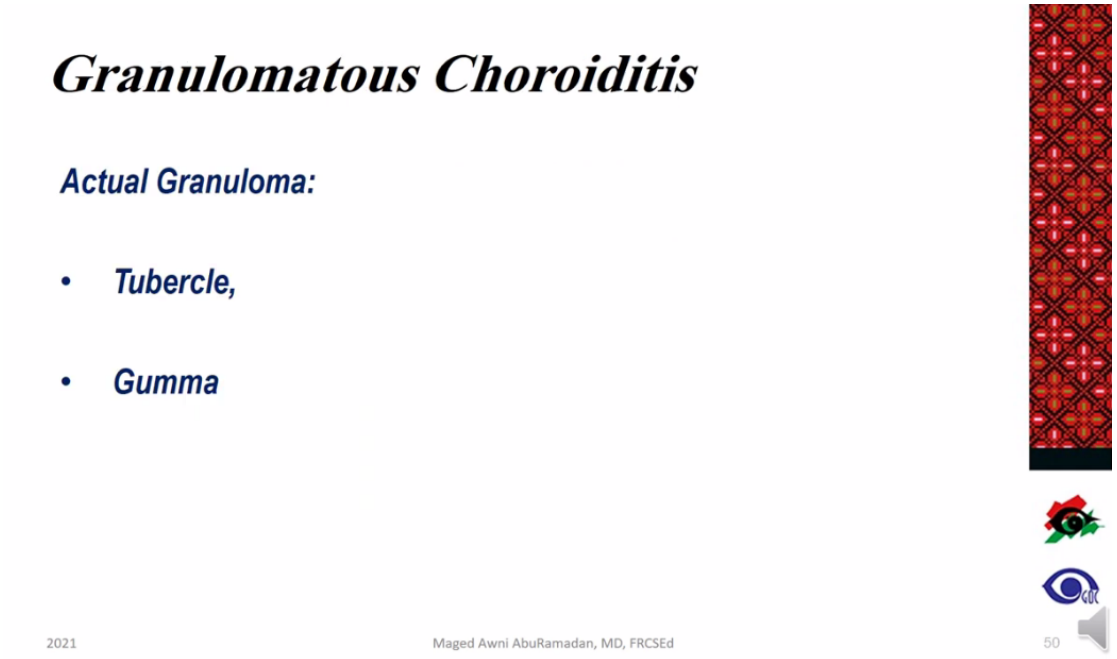

granulomatous choroiditis can be seen as an actual granuloma in both of TB tubercle or . syphilitic Gumma

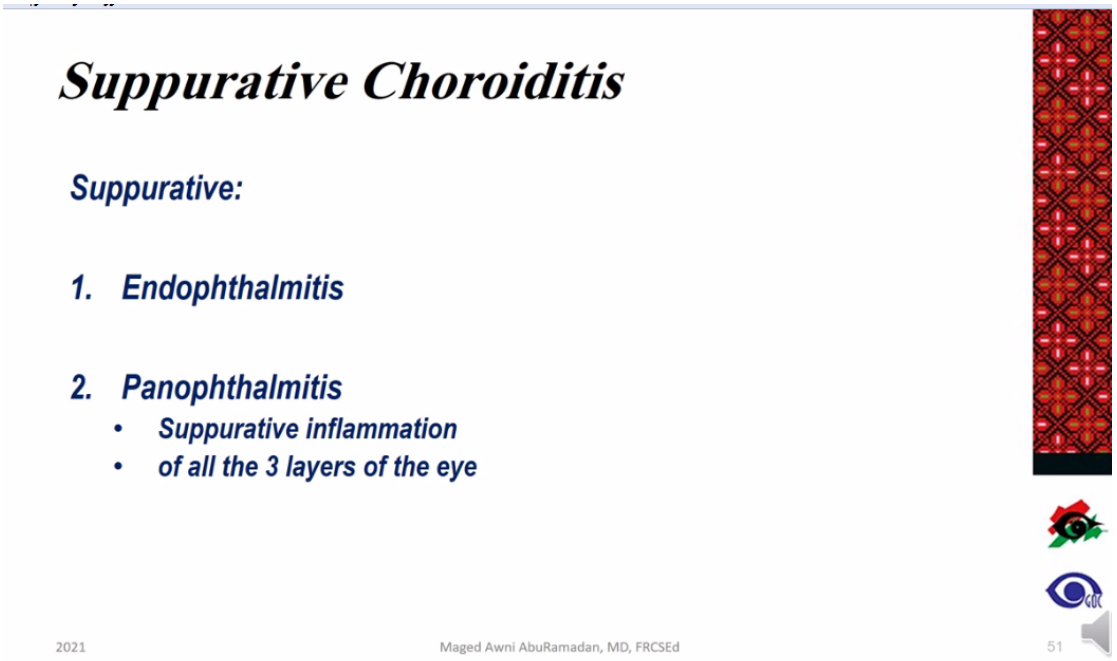

..

suppurative choroiditis is due to very severe or virulent organism it can be endophthalmitis. involving the posterior part of the eye or panophthalmitis, which means all three layers, the .anterior segment and the posterior segment are involved in the suppurative process

Thank you