Anatomy of the oral cavity

DR. NOUR ALMADHOUN

Oral cavity

- Mouth
- Teeth
- Tongue
- Palate
- Salivary glands

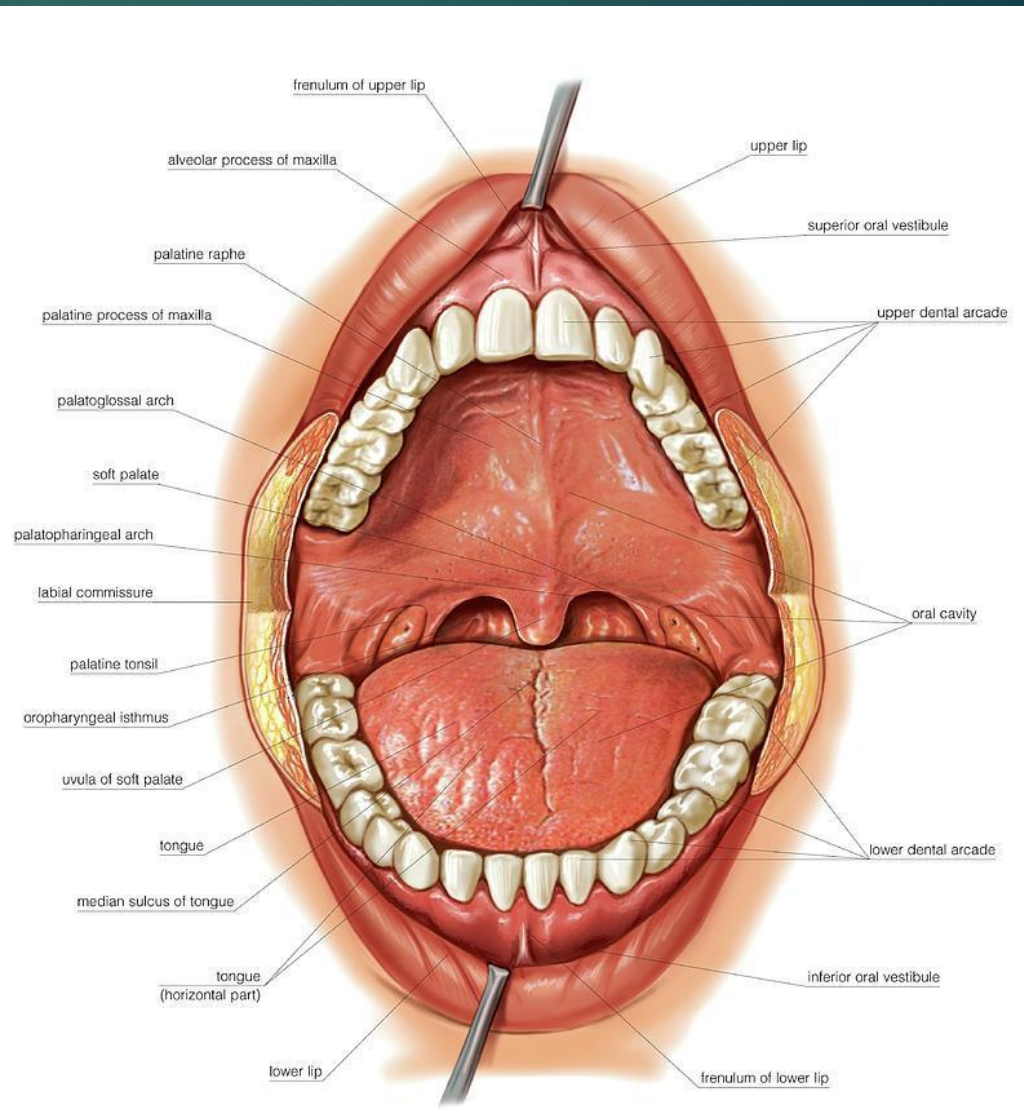

The Lips

- The lips are two fleshy folds that surround the oral orifice.
- They are covered on the outside by skin and are lined on the inside by mucous membrane.
- The substance of the lips is made up by the **orbicularis oris muscle** and the muscles that radiate from the lips into the face.
- Also included are the labial blood vessels and nerves, connective tissue, and many small salivary glands.
- The philtrum is the shallow vertical groove seen in the midline on the outer surface of the upper lip.
- Median folds of mucous membrane _the **labial frenulae**_ connect the inner surface of the lips to the gums.

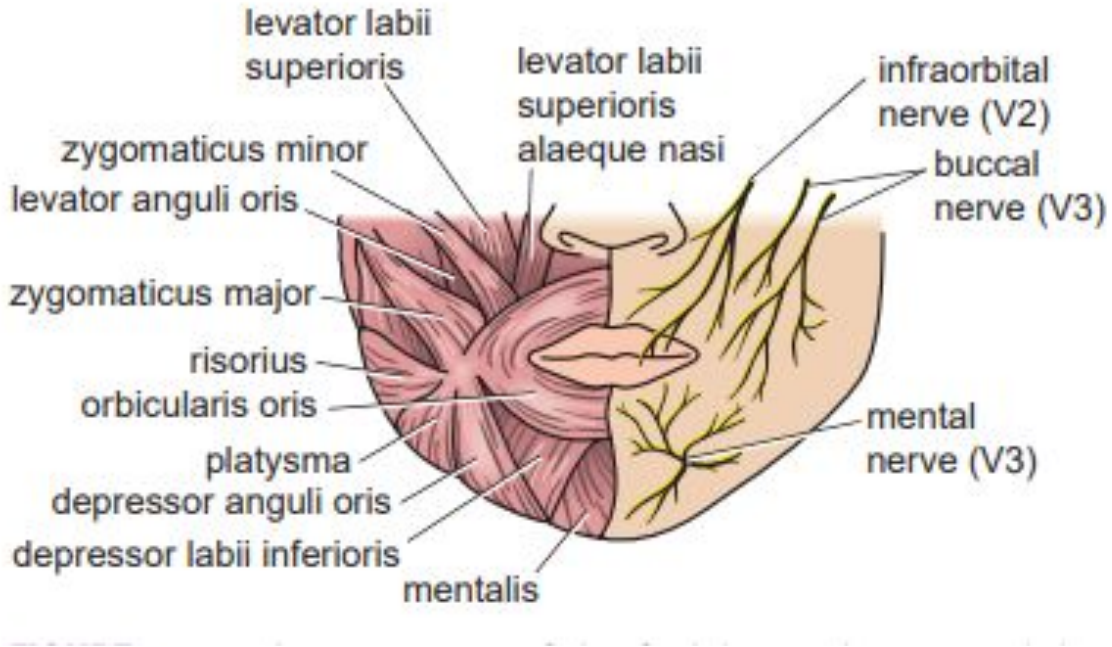

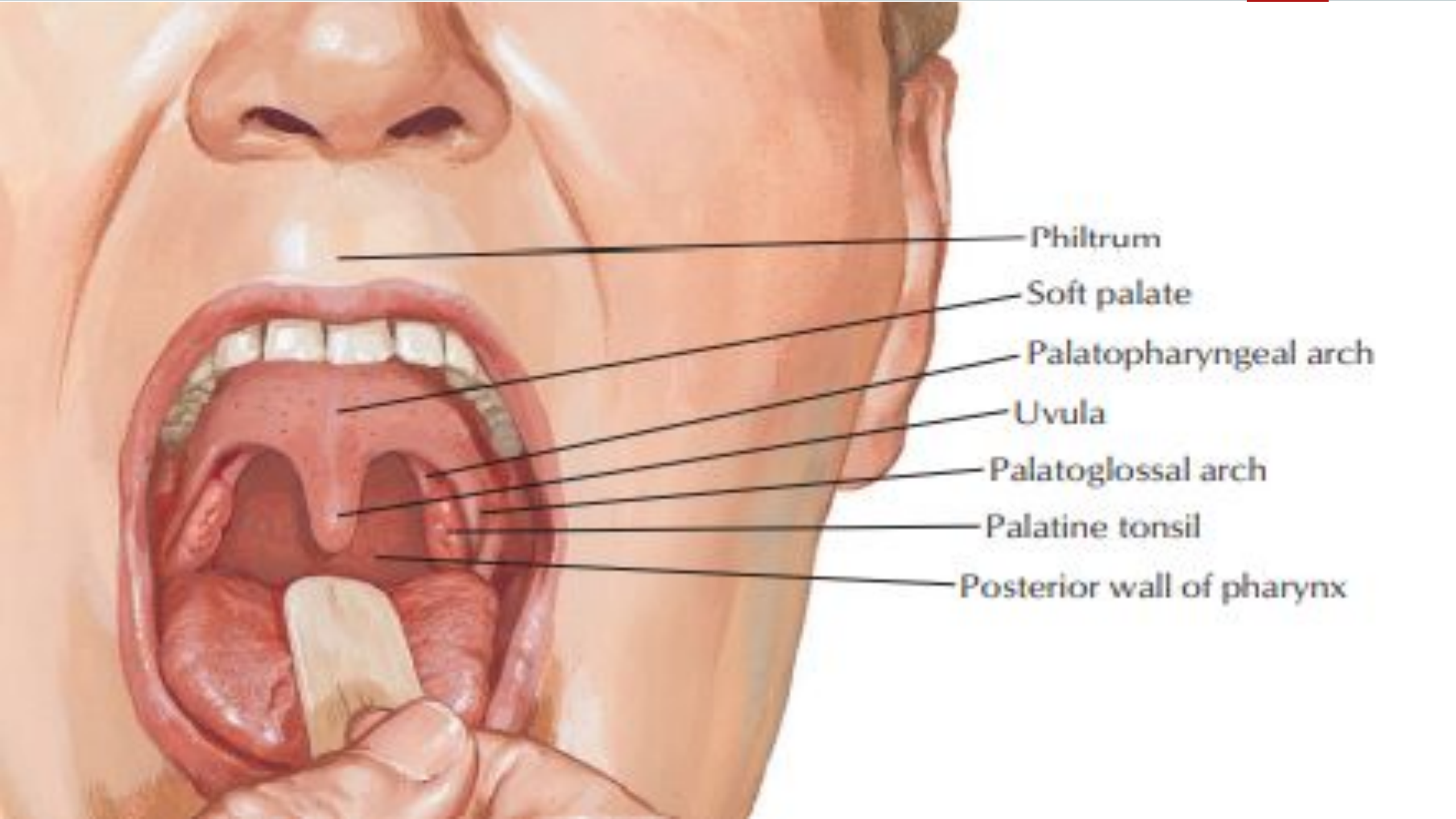
Philtrum
Soft palate
Palatopharyngeal arch
Uvula
Palatoglossal arch
Palatine tonsil
Posterior wall of pharynx

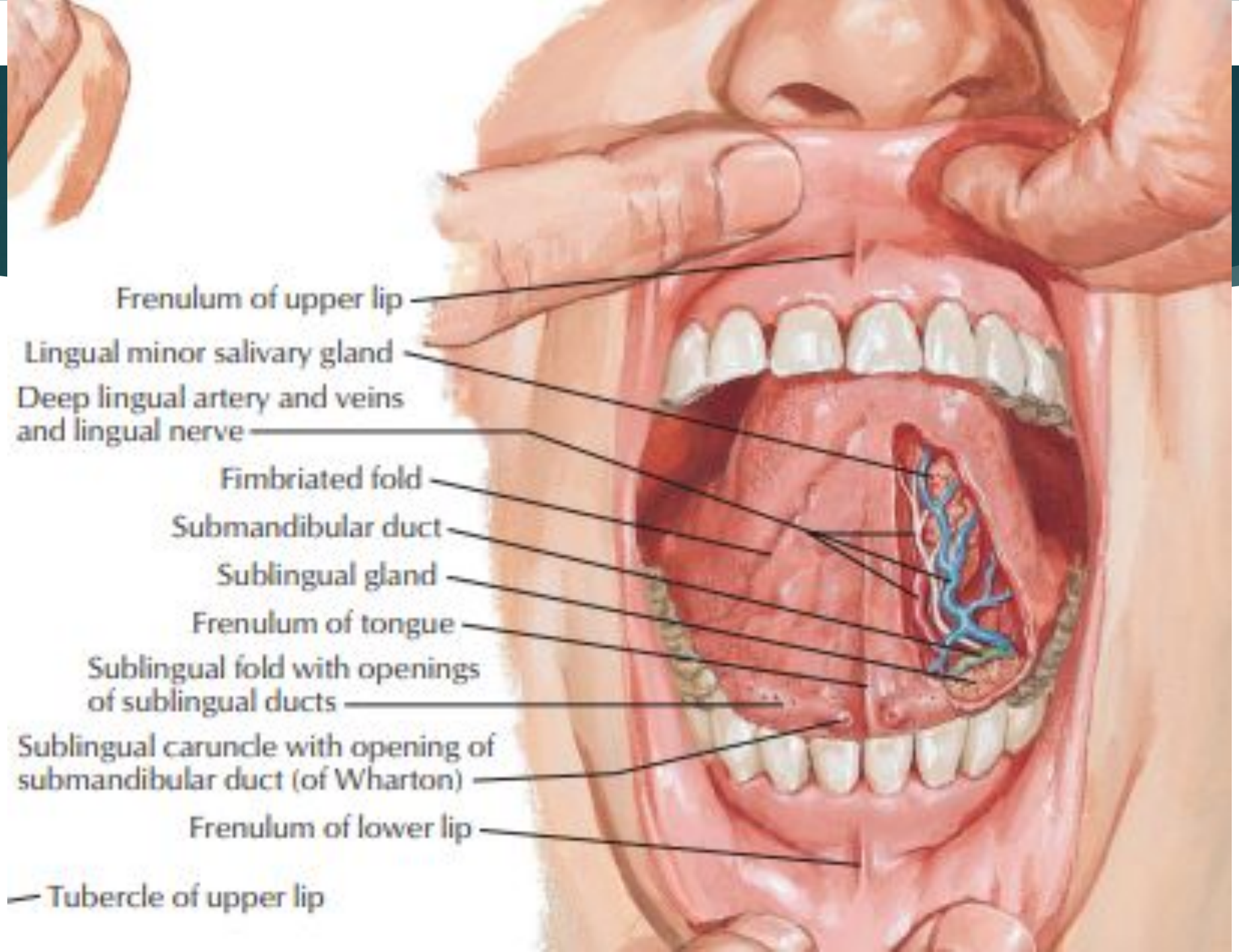
Frenulum of upper lip
Lingual minor salivary gland
Deep lingual artery and veins and lingual nerve
Fimbriated fold
Submandibular duct
Sublingual gland
Frenulum of tongue
Sublingual fold with openings of sublingual ducts
Sublingual caruncle with opening of submandibular duct (of Wharton)
Frenulum of lower lip
Tubercle of upper lip

The mouth cavity

- The mouth extends from the lips to the pharynx.
- The entrance into the pharynx _the oropharyngeal isthmus_ is formed on each side by the **palatoglossal fold**.
- The mouth is divided into the **vestibule** and the **mouth cavity proper**.

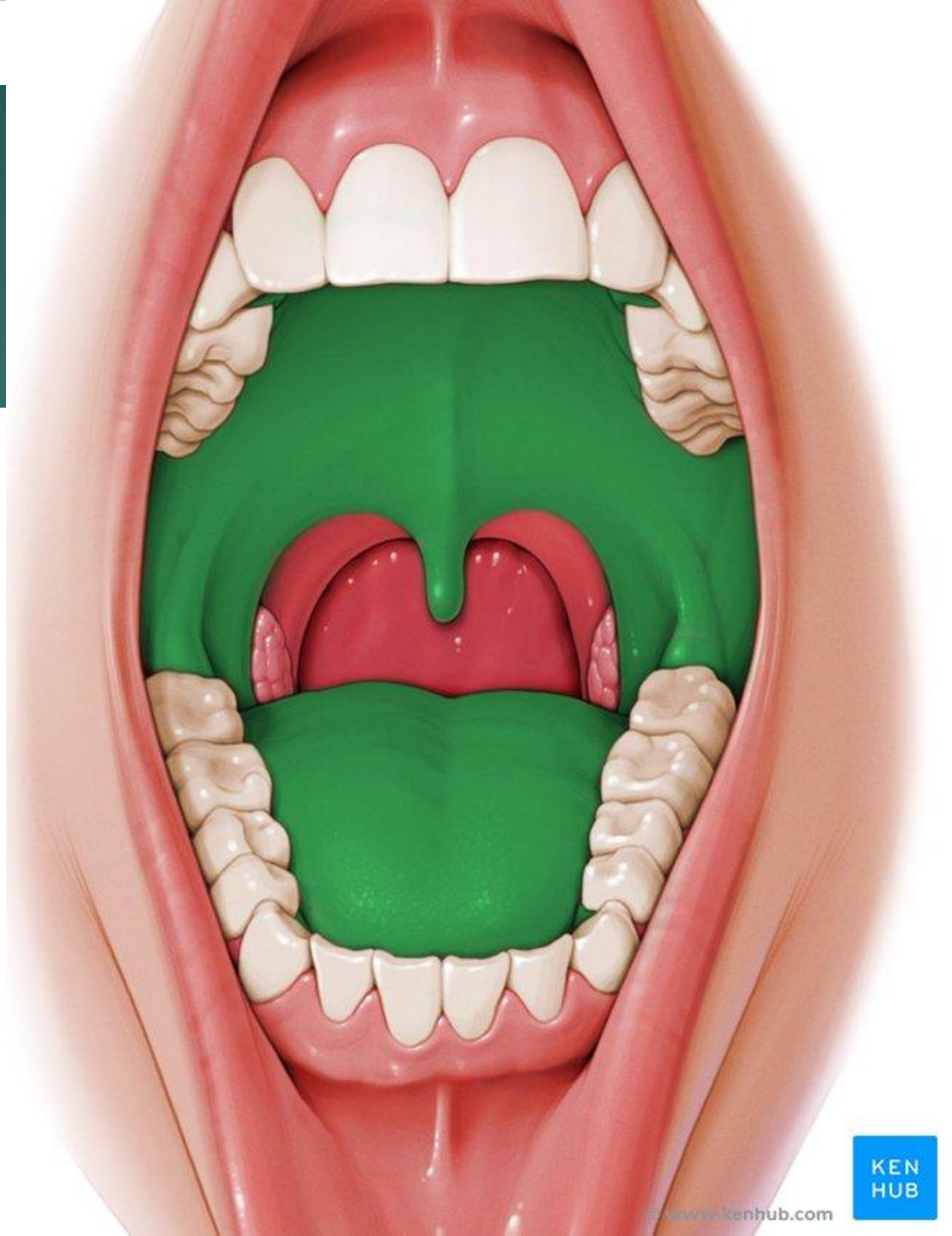

Vestibule

- The vestibule lies between the lips and the cheeks externally and the gums and the teeth internally.
- The lateral wall of the vestibule is formed by the cheek, which is made up by the **buccinator muscle** and is lined with mucous membrane.
- The **duct of the parotid salivary gland (Stensen duct)**, penetrates the buccinator muscle and opens on a small papilla into the vestibule opposite the upper second molar tooth.

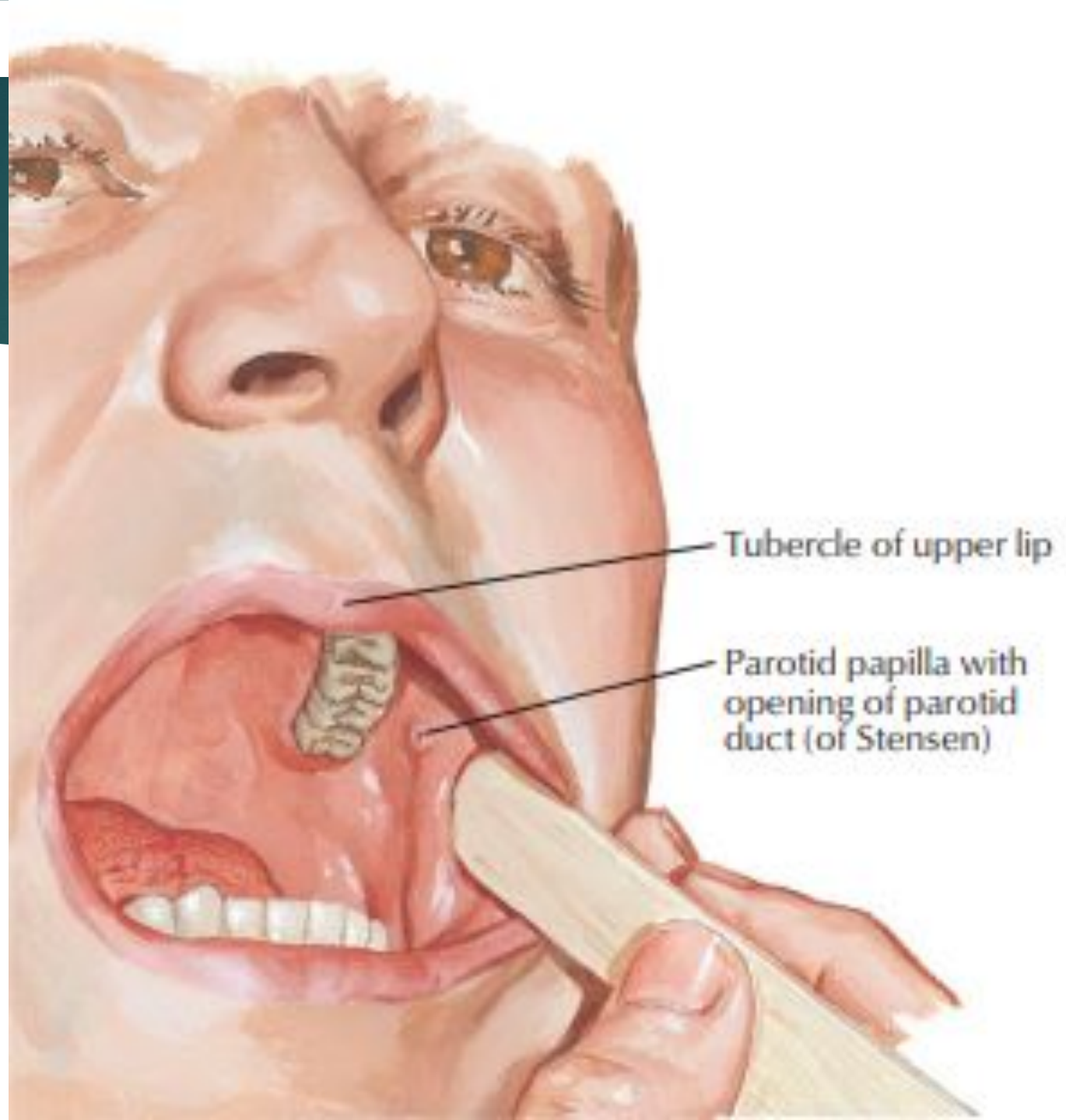
Tubercle of upper lip
Parotid papilla with opening of parotid duct (of Stensen)

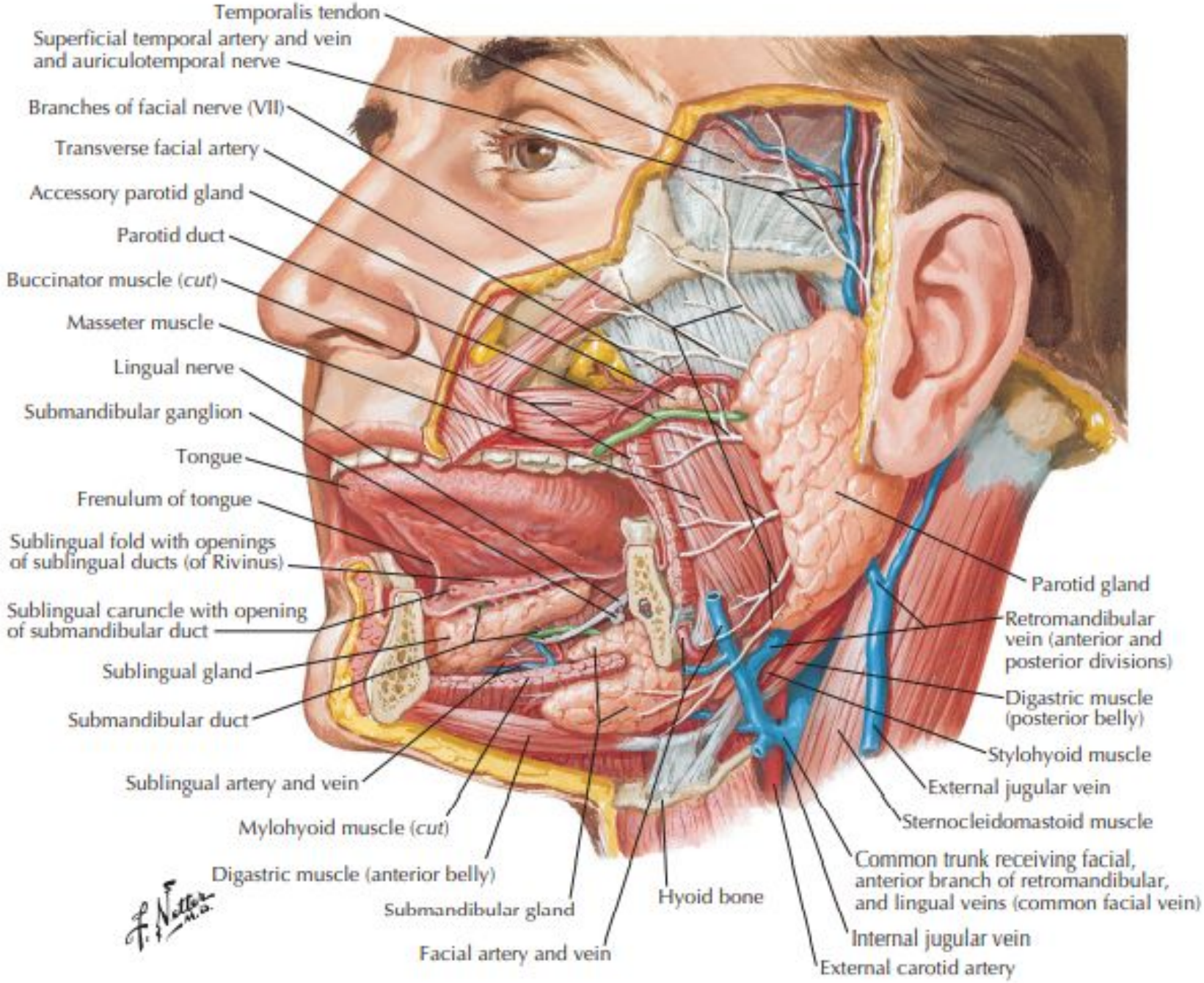
Temporalis tendon
Superficial temporal artery and vein and auriculotemporal nerve
Branches of facial nerve (VII)
Transverse facial artery
Accessory parotid gland
Parotid duct
Buccinator muscle (*cut*)
Masseter muscle
Lingual nerve
Submandibular ganglion
Tongue
Frenulum of tongue
Sublingual fold with openings of sublingual ducts (of Rivinus)
Sublingual caruncle with opening of submandibular duct
Sublingual gland
Submandibular duct
Sublingual artery and vein
Mylohyoid muscle (*cut*)
Digastric muscle (anterior belly)
Submandibular gland
Facial artery and vein
Hyoid bone
Parotid gland
Retromandibular vein (anterior and posterior divisions)
Digastric muscle (posterior belly)
Stylohyoid muscle
External jugular vein
Sternocleidomastoid muscle
Common trunk receiving facial, anterior branch of retromandibular, and lingual veins (common facial vein)
Internal jugular vein
External carotid artery

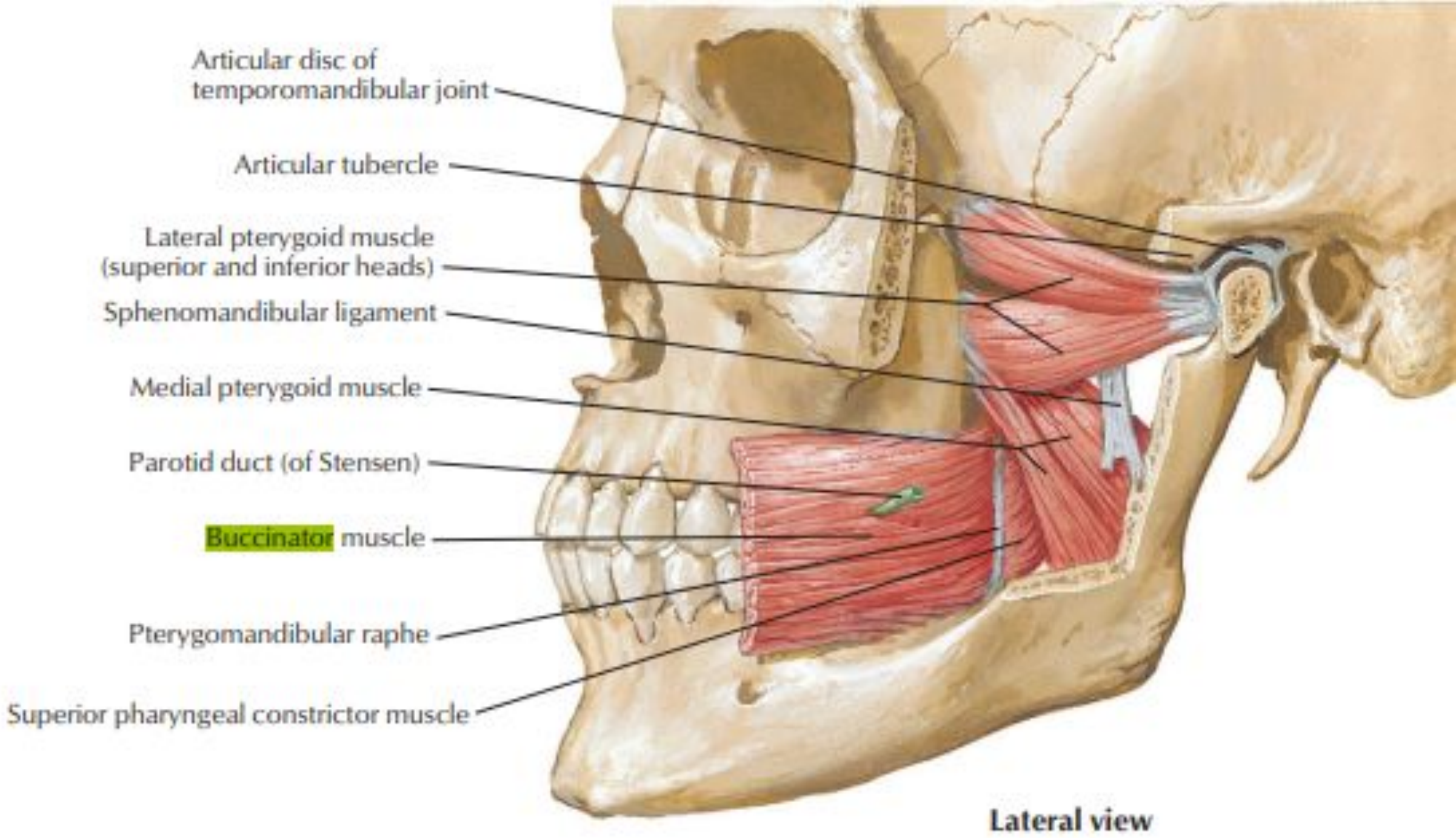
Articular disc of temporomandibular joint
Articular tubercle
Lateral pterygoid muscle (superior and inferior heads)
Sphenomandibular ligament
Medial pterygoid muscle
Parotid duct (of Stensen)
Buccinator muscle
Pterygomandibular raphe
Superior pharyngeal constrictor muscle
Lateral view

Mouth Proper

- The mouth proper has a **roof** and a **floor**
- The roof of the mouth is formed by the hard palate in front and the soft palate behind.
- The floor is formed largely by the tongue
- A fold of mucous membrane called the **frenulum of the tongue** connects the undersurface of the tongue in the midline to the floor of the mouth.
- On the lateral side of the frenulum, the **deep lingual vein** can be seen through the mucous membrane.
- Lateral to the frenulum, the mucous membrane forms a fringed fold, the **plica fimbriata.**

Mouth Proper

- The submandibular duct of the submandibular gland opens onto the floor of the mouth on the summit of a small papilla on either side of the frenulum of the tongue.
- The close relation of the submandibular duct to the floor of the mouth may enable one to palpate a calculus in cases of periodic swelling of the submandibular salivary gland.
- The sublingual gland projects up into the mouth, producing a low fold of mucous membrane, the sublingual fold. Numerous ducts of the gland open on the summit of the fold.

Sensory Innervation of the Mouth

- Roof:

The **greater palatine** and **nasopalatine nerves** from the maxillary division of the trigeminal nerve.

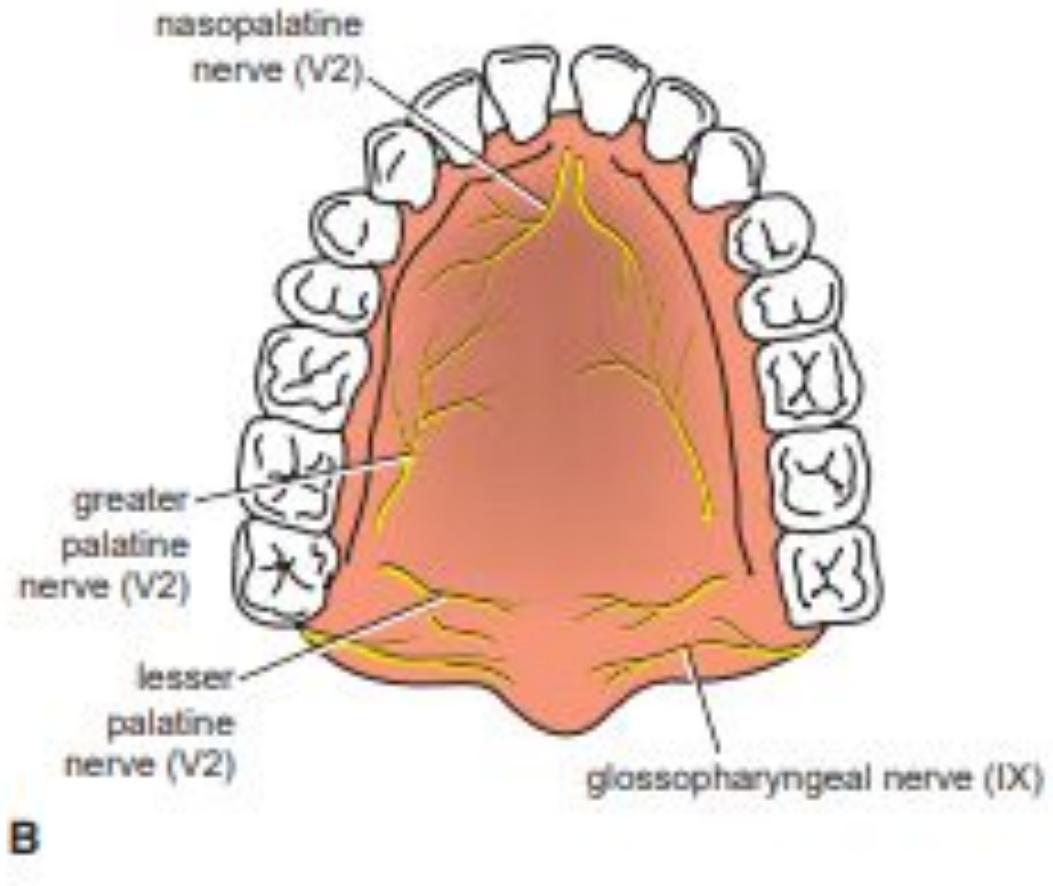

Sensory Innervation of the Mouth

- Floor:
- Taste to the anterior two-thirds of the tongue is achieved through innervation from **the chorda tympani nerve, a branch of the facial nerve**
- General sensation to the anterior two-thirds of the tongue is by innervation from **the lingual nerve, a branch of the mandibular branch of the trigeminal nerve (CN V3)**
- On the other hand, taste to the posterior one-third of the tongue is accomplished through innervation from the **glossopharyngeal nerve**, which also provides general sensation to the posterior one-third of the tongue.

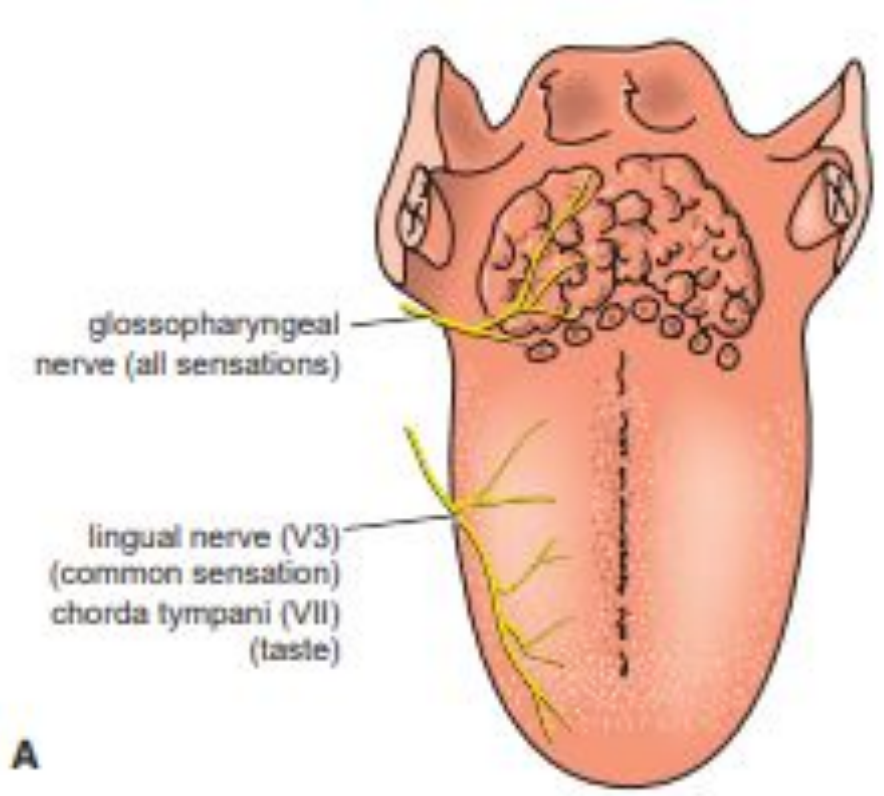

Sensory Innervation of the Mouth

- Cheek: The **buccal nerve**, a branch of the mandibular division of the trigeminal nerve
- The buccinator muscle is innervated by the **buccal branch of the facial nerve**

CRANIAL NERVES

Functional group of cranial nerves:

I. Olfactory nerve: **Sensory**
II. Optic nerve: **Sensory**
III. Occulomotor nerve: **Motor**
IV. Trochlear nerve: **Motor**
V. Trigeminal nerve:**Mixed** (Sensory+Motor)
VI. Abducent nerve: **Motor**
VII. Facial nerve: **Mixed**
VIII. Vestibulocochlear nerve: **Sensory**
IX. Glossopharyngeal nerve: **Mixed**
X. Vagus nerve: **Mixed**
XI. Accessory nerve: **Motor**
XII. Hypoglossal nerve: **Motor**

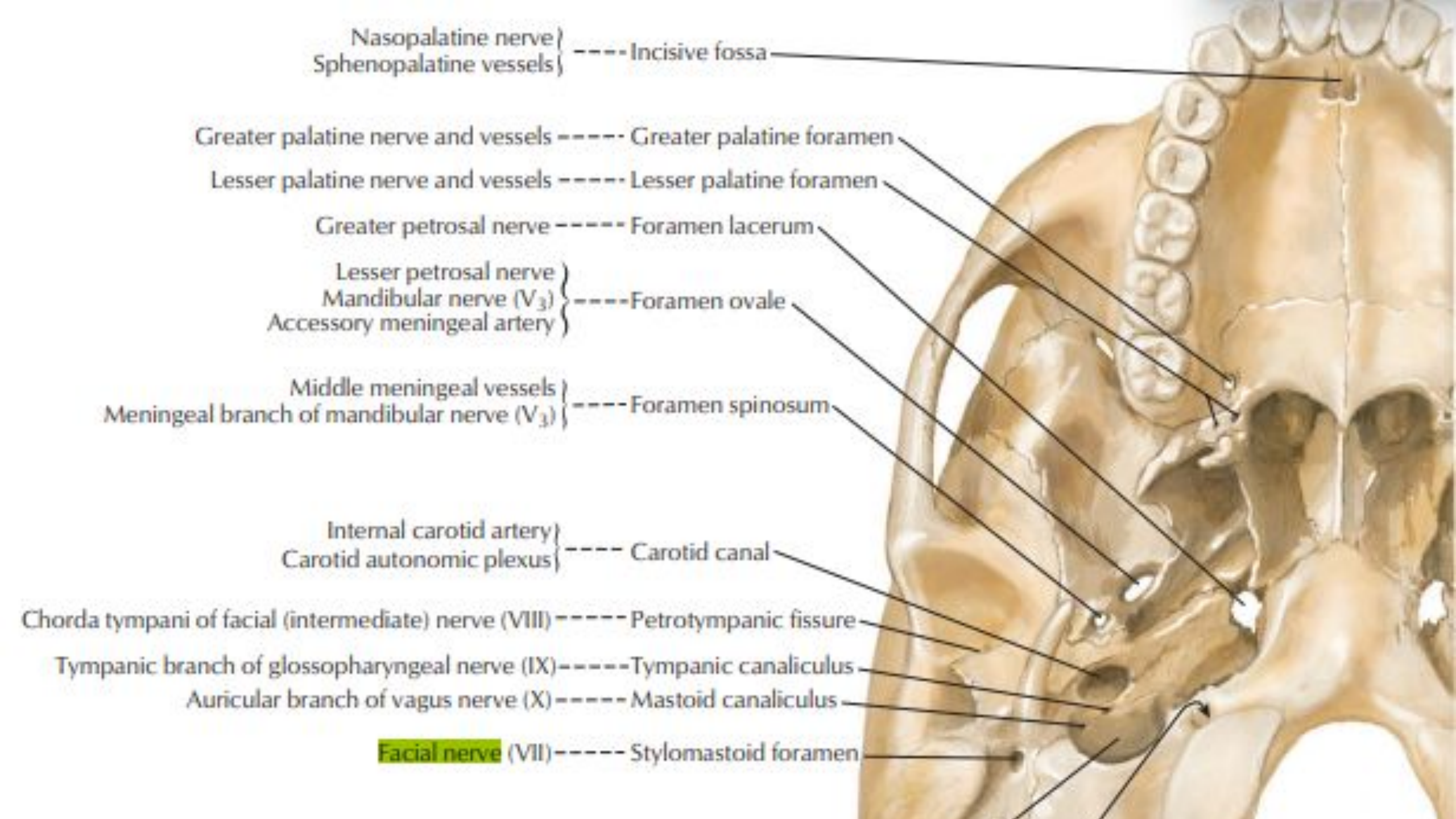
Nasopalatine nerve
Sphenopalatine vessels
Incisive fossa
Greater palatine nerve and vessels
Greater palatine foramen
Lesser palatine nerve and vessels
Lesser palatine foramen
Greater petrosal nerve
Foramen lacerum
Lesser petrosal nerve
Mandibular nerve (V3)
Accessory meningeal artery
Foramen ovale
Middle meningeal vessels
Meningeal branch of mandibular nerve (V3)
Foramen spinosum
Internal carotid artery
Carotid autonomic plexus
Carotid canal
Chorda tympani of facial (intermediate) nerve (VIII)
Petrotympanic fissure
Tympanic branch of glossopharyngeal nerve (IX)
Tympanic canaliculus
Auricular branch of vagus nerve (X)
Mastoid canaliculus
Facial nerve (VII)
Stylomastoid foramen

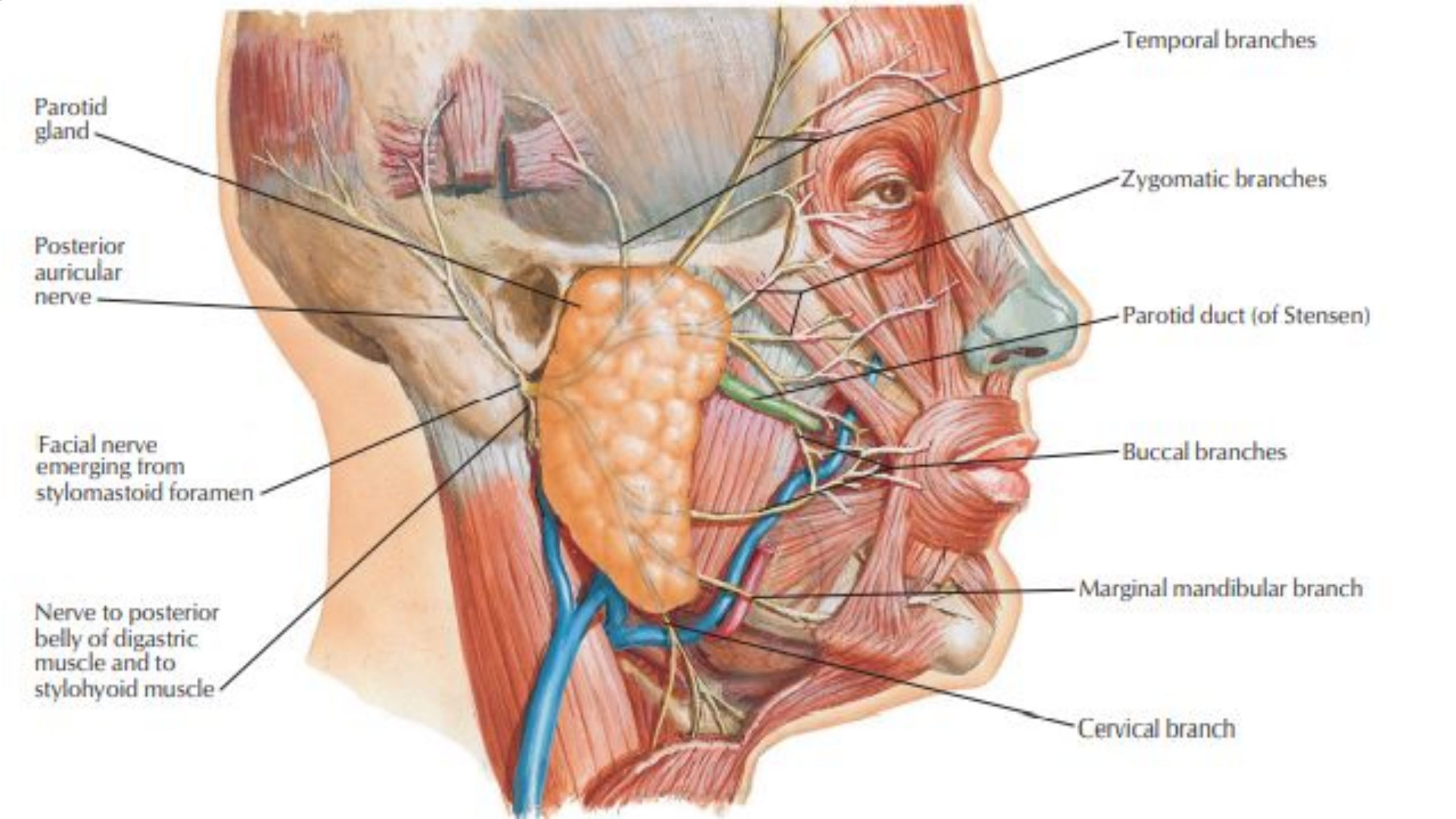
Temporal branches
Parotid gland
Zygomatic branches
Posterior auricular nerve
Parotid duct (of Stensen)
Facial nerve emerging from stylomastoid foramen
Buccal branches
Marginal mandibular branch
Nerve to posterior belly of digastric muscle and to stylohyoid muscle
Cervical branch

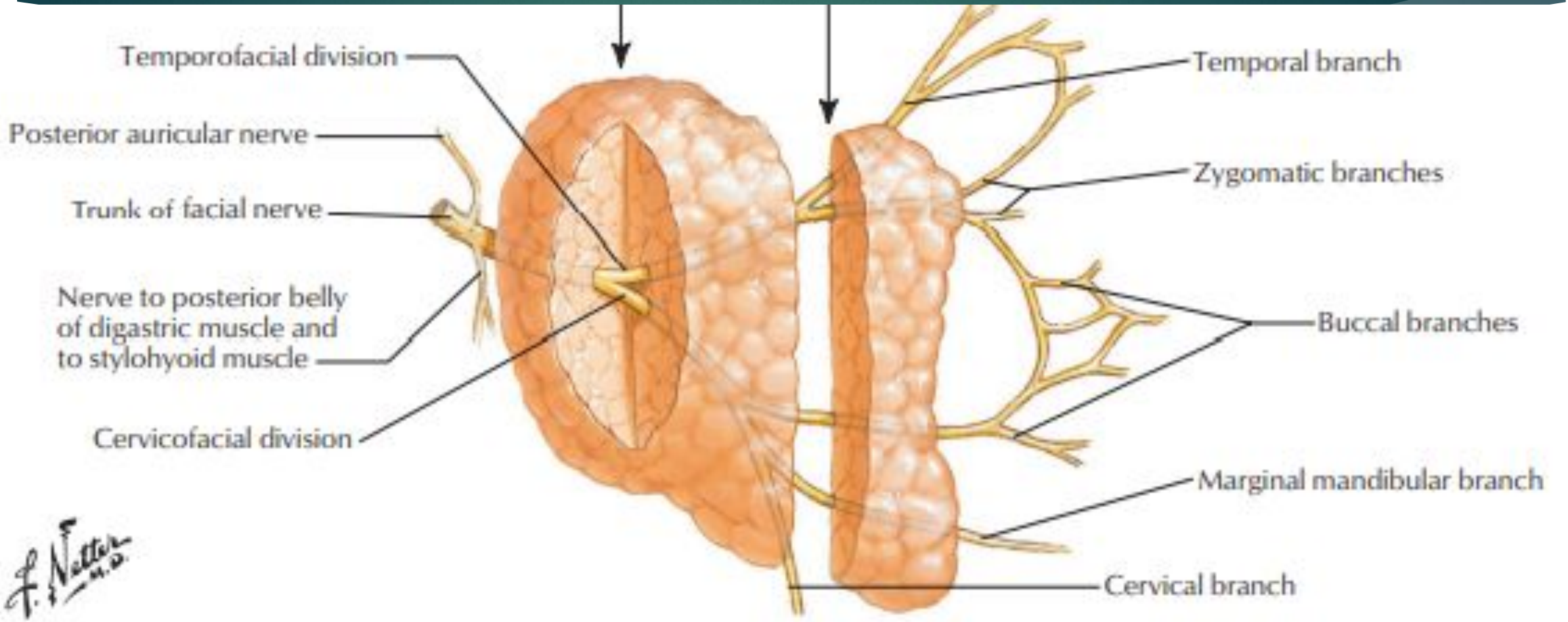
Temporofacial division
Posterior auricular nerve
Trunk of facial nerve
Nerve to posterior belly of digastric muscle and to stylohyoid muscle
Cervicofacial division
Temporal branch
Zygomatic branches
Buccal branches
Marginal mandibular branch
Cervical branch

The Teeth

- **Deciduous Teeth** There are 20 deciduous teeth: four incisors, two canines, and four molars in each jaw.
- They begin to erupt about 6 months after birth and have all erupted by the end of 2 years.
- The teeth of the lower jaw usually appear before those of the upper jaw.

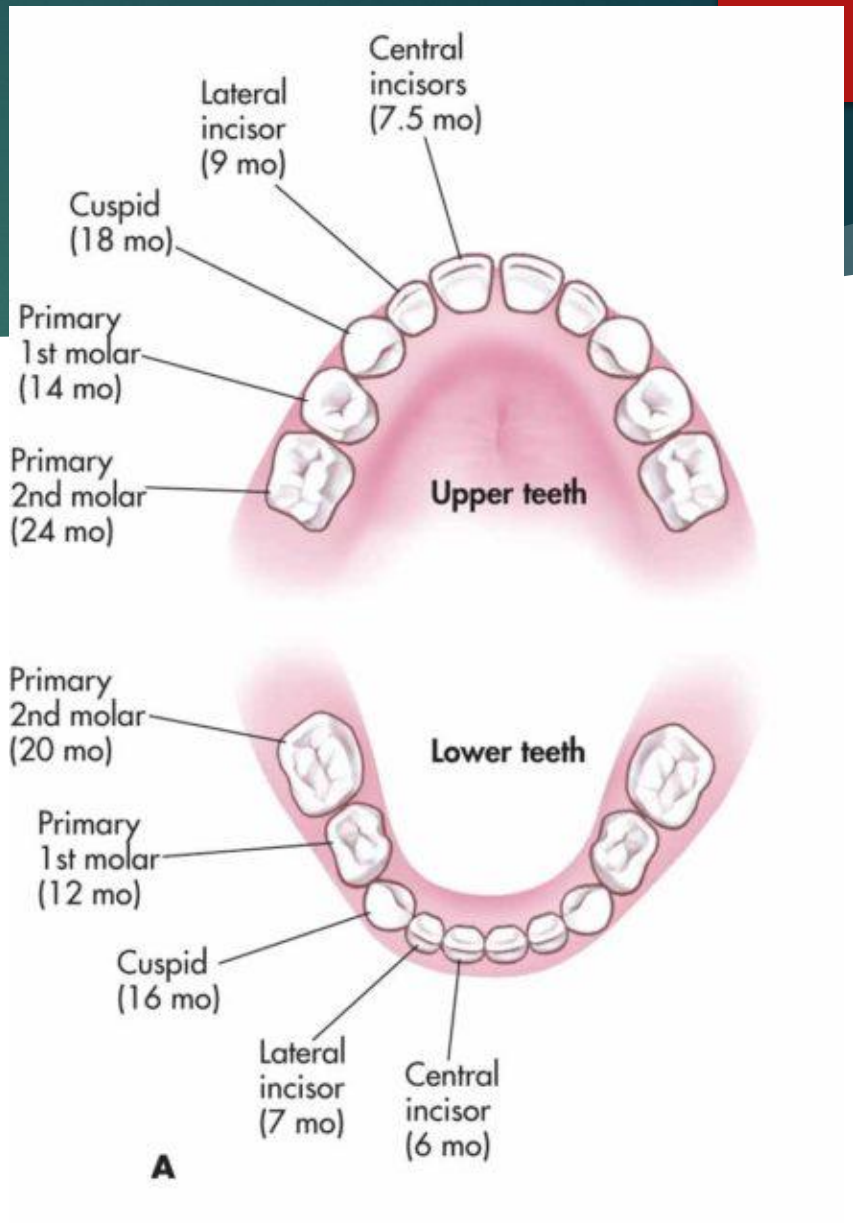

The Teeth

- **Permanent Teeth** There are 32 permanent teeth: 4 incisors, 2 canines, 4 premolars, and 6 molars in each jaw.
- They begin to erupt at 6 years of age. The last tooth to erupt is the third molar, which may happen between the ages of 17 and 30.
- The teeth of the lower jaw appear before those of the upper jaw

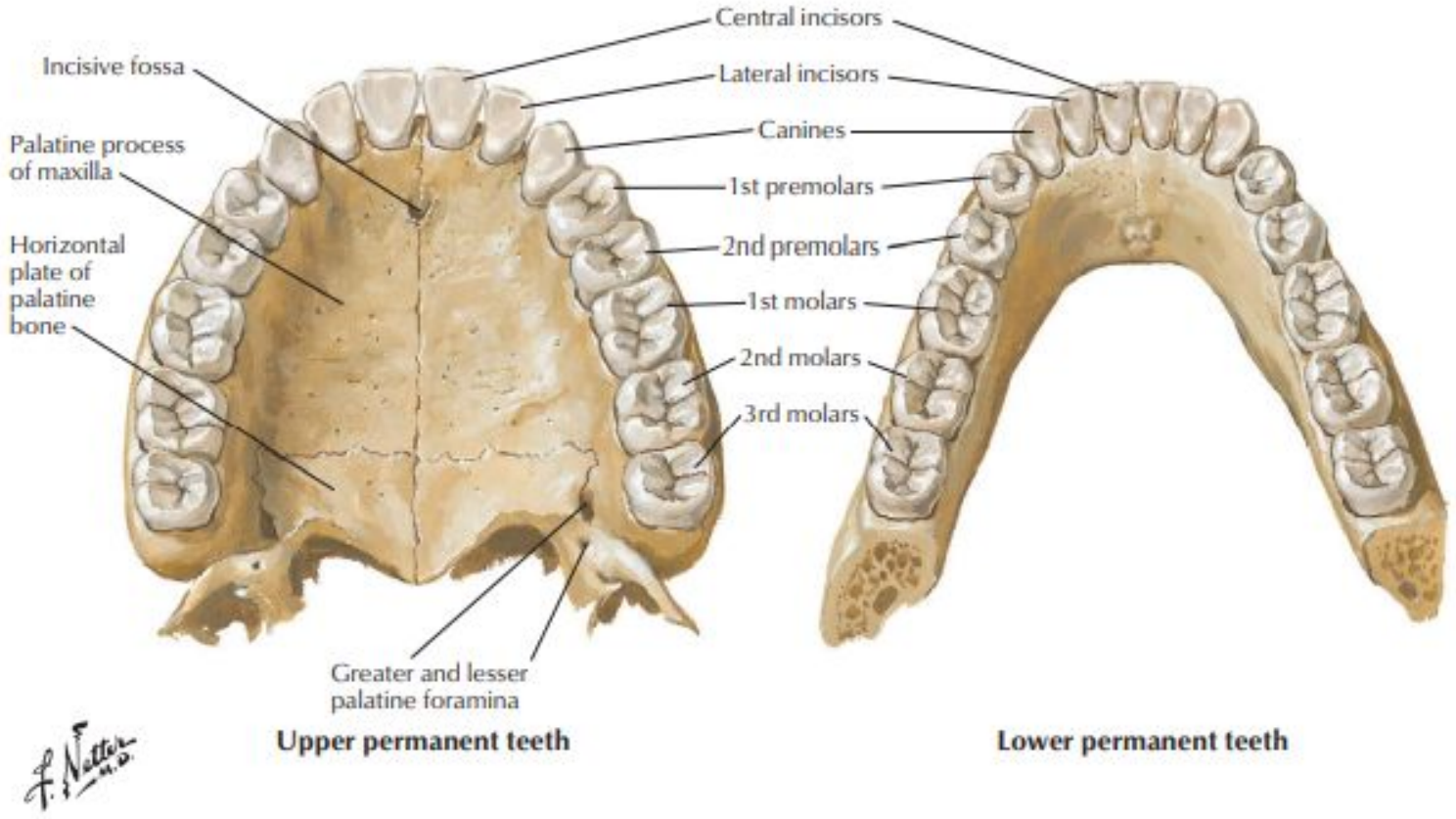

The Tongue

- The tongue is a mass of striated muscle covered with mucous membrane.
- The muscles attach the tongue to the styloid process and the soft palate above and to the mandible and the hyoid bone below.
- The tongue is divided into right and left halves by a **median fibrous septum**

Mucous Membrane of the Tongue

- The mucous membrane of the upper surface of the tongue can be divided into anterior and posterior parts by a V-shaped sulcus, the **sulcus terminalis**.
- The sulcus serves to divide the tongue into the anterior two thirds, or **oral part**, and the posterior third, or **pharyngeal part**.
- The apex of the sulcus projects backward and is marked by a small pit, the **foramen cecum.**
- The foramen cecum is an embryologic remnant and marks the site of the upper end of the **thyroglossal duct**.

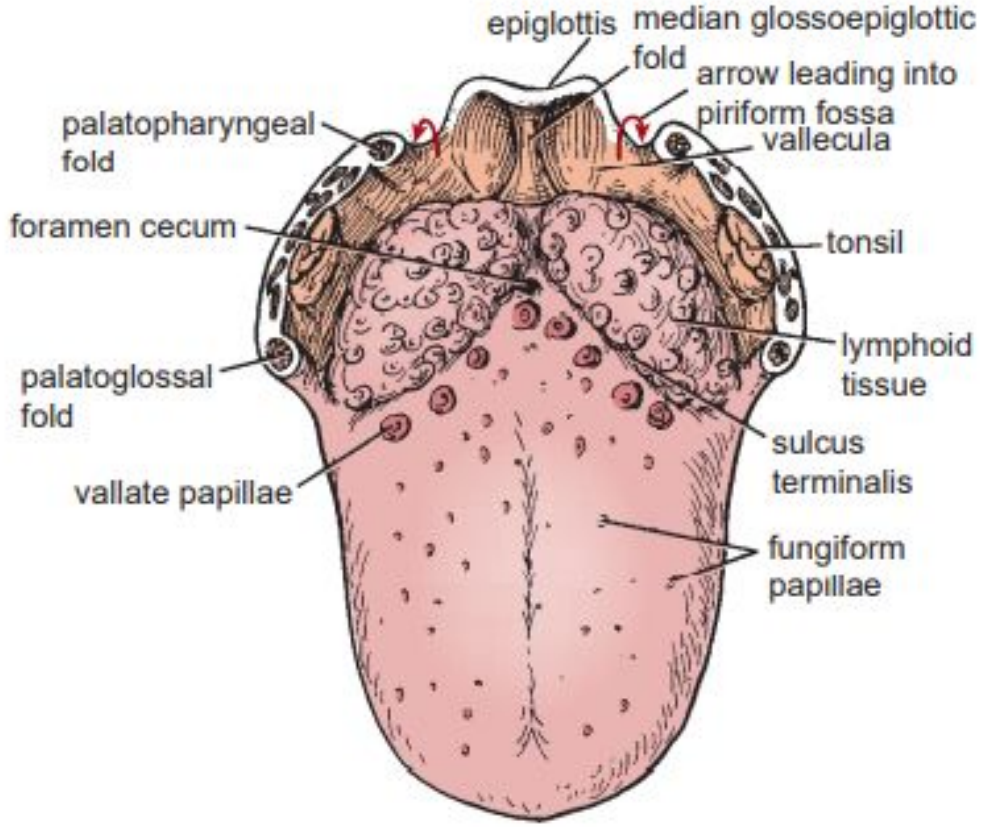

Mucous Membrane of the Tongue

- Three types of papillae are present on the upper surface of the anterior two thirds of the tongue: the **filiform papillae**, the **fungiform papillae**, and the **vallate papillae**.
- The mucous membrane covering the posterior third of the tongue is **devoid of papillae** but has an irregular surface (Fig. 11.77), caused by the presence of underlying lymph nodules, the **lingual tonsil**.

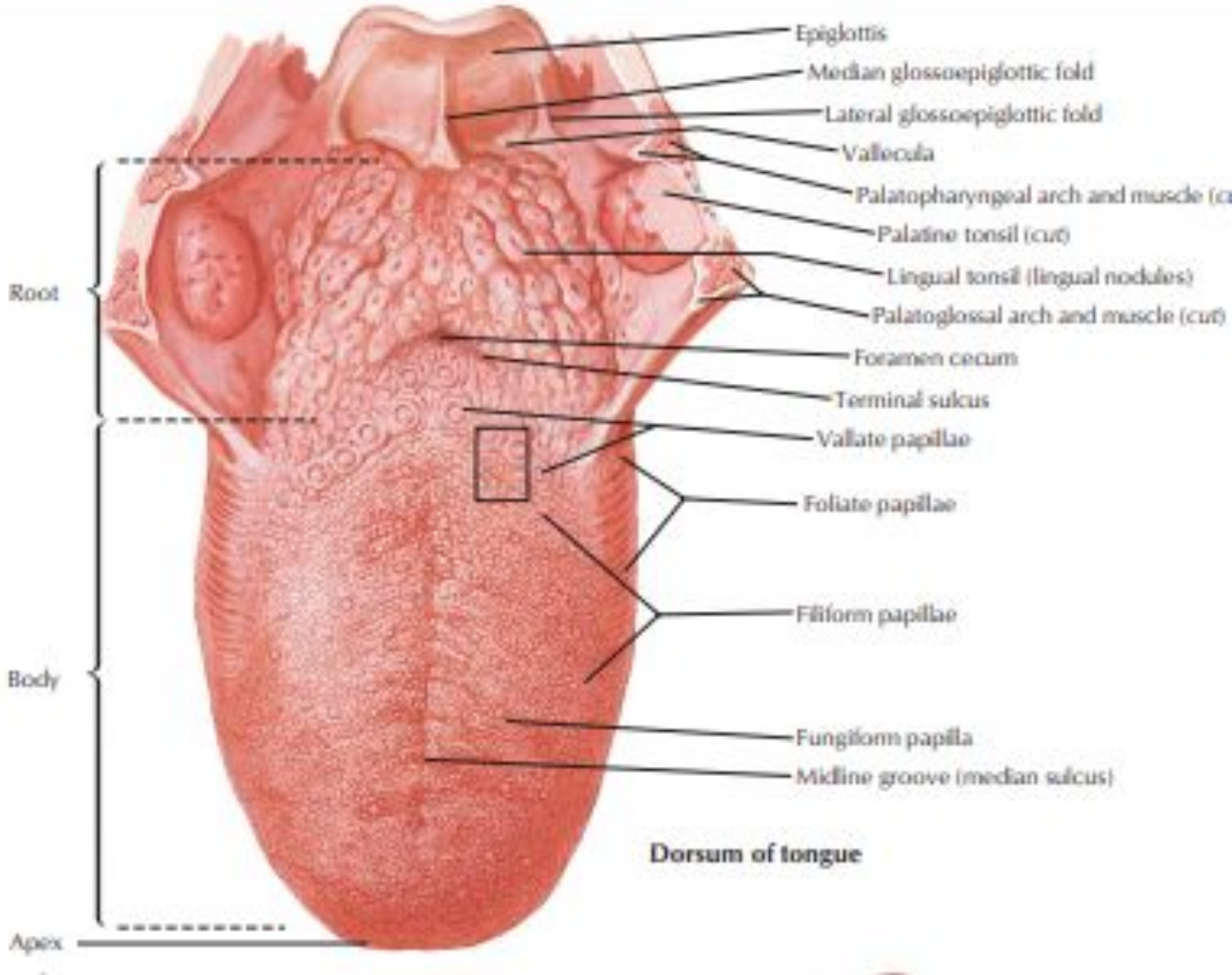

Mucous Membrane of the Tongue

- The following papillae cover the tongue and are used for taste perception:

1. **Vallate papillae** are arranged in a V-shape anterior to the sulcus terminalis and studded with numerous taste buds. Innervation is by the glossopharyngeal nerve (CN IX).
2. **Fungiform papillae** are mushroom-shaped papillae with erythematous domes located on the lateral aspects and at the apex of the tongue.
3. **Filiform papillae** are slim, cone-shaped projections organized in rows parallel to the sulcus terminalis.
4. **Foliate papillae** are rarely found in humans (vestigial).

Mucous Membrane of the Tongue

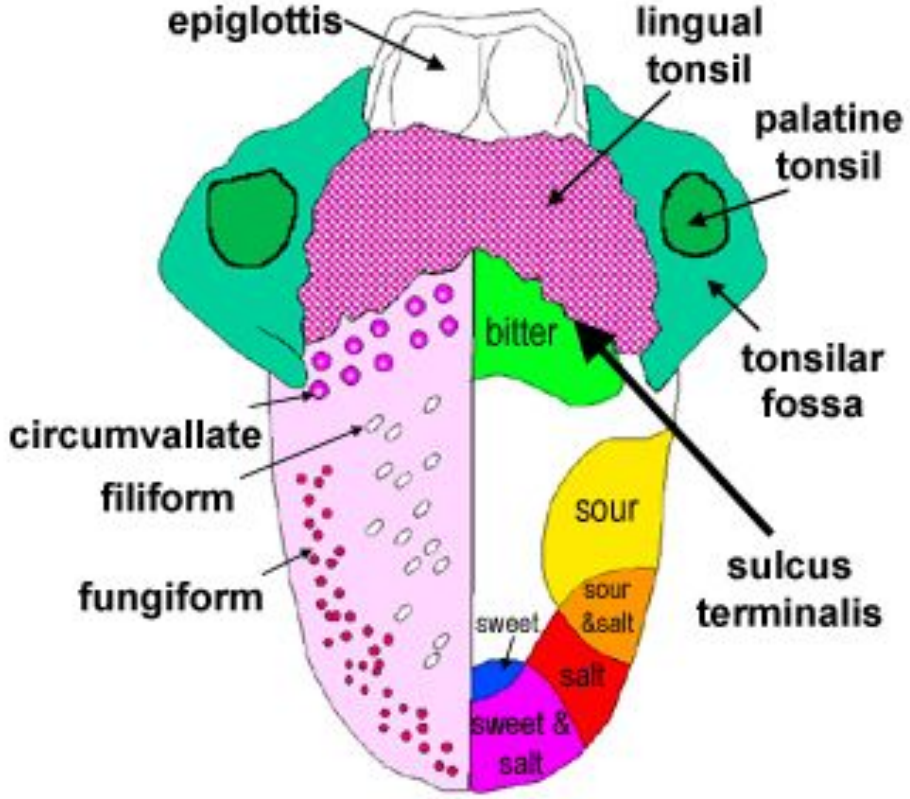

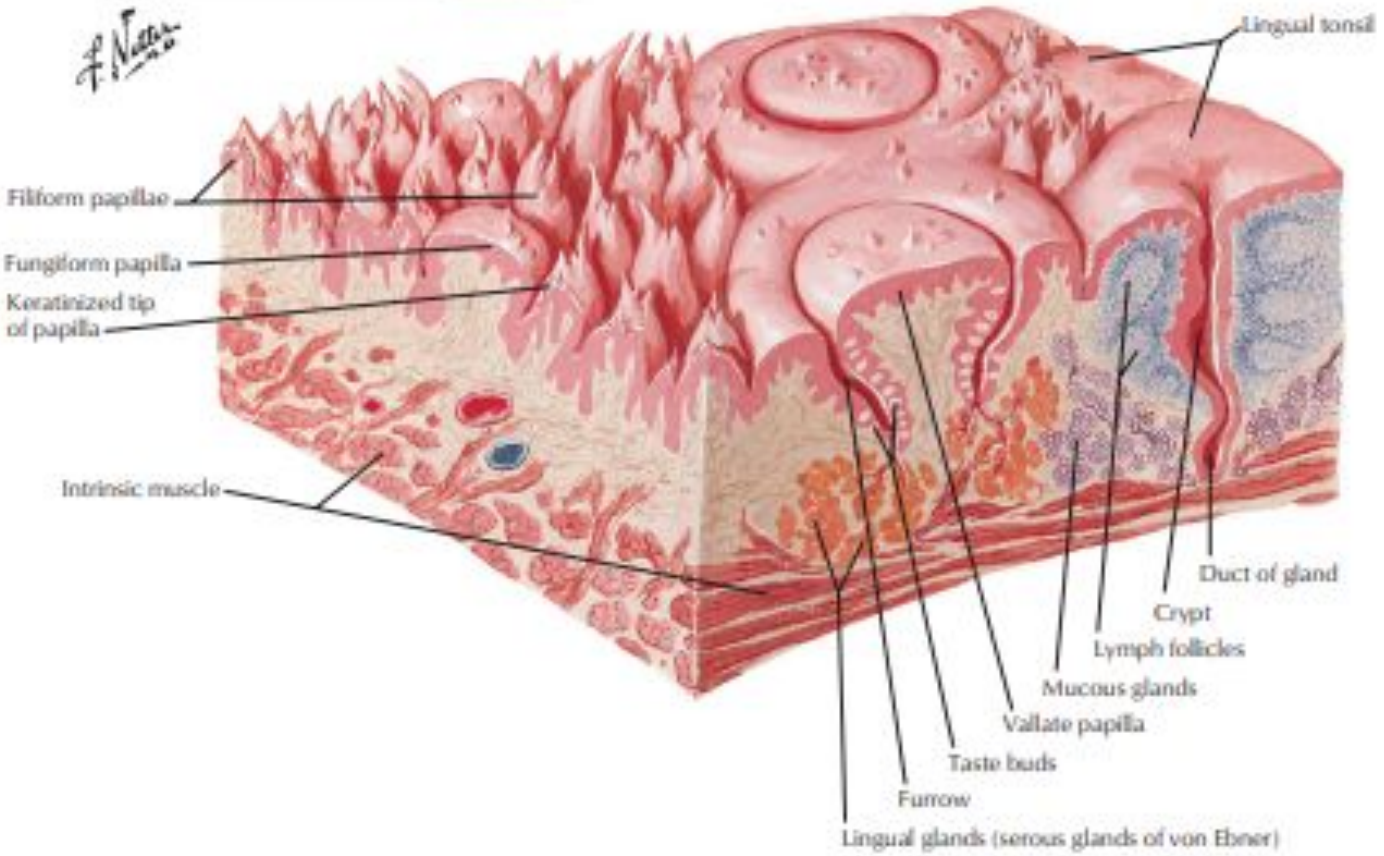

Muscles of the Tongue

- The muscles of the tongue are divided into two types: **intrinsic** and **extrinsic**.
- Intrinsic Muscles These muscles are confined to the tongue and are not attached to bone.
- They consist of **longitudinal, transverse,**

and vertical fibers.

- Nerve supply: **Hypoglossal nerve**
- Action: Alter the shape of the tongue

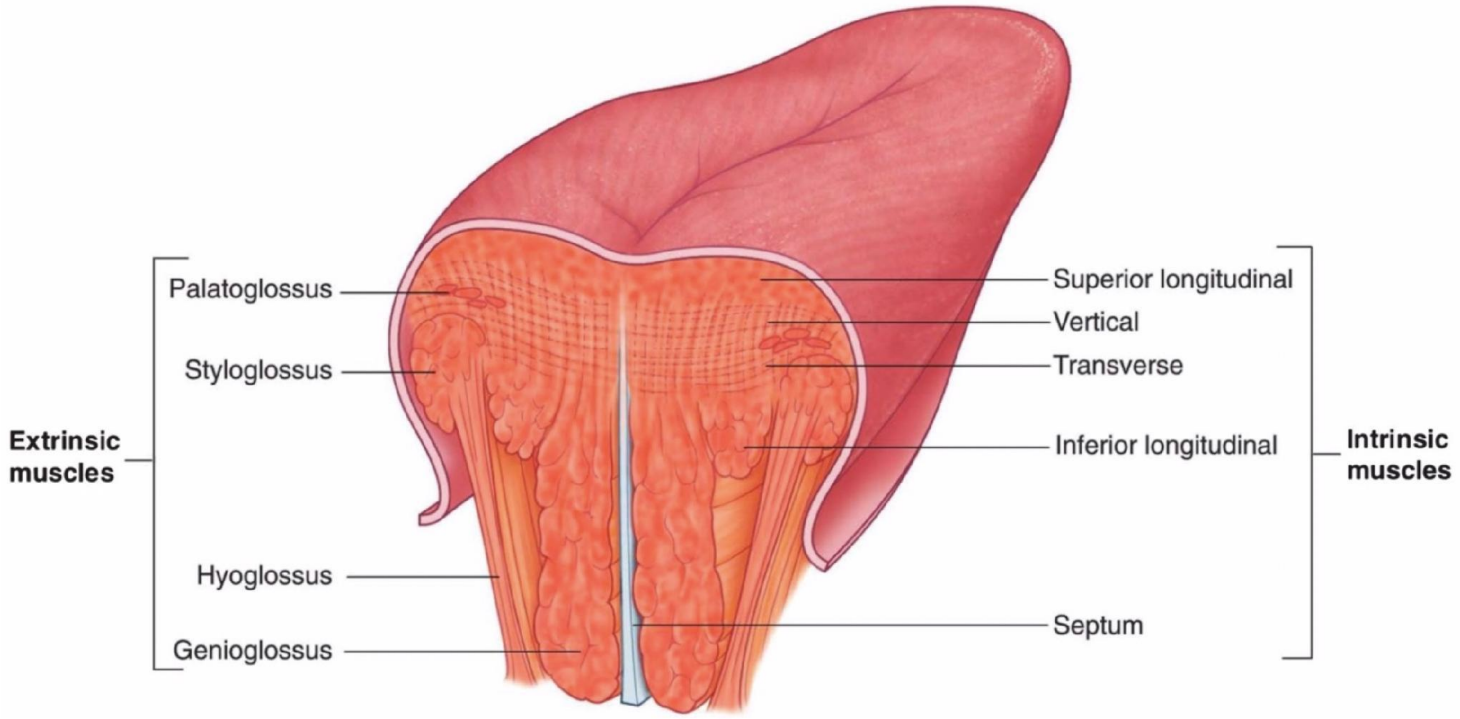

Muscles of the Tongue

- Extrinsic Muscles:

These muscles are attached to bones and the soft palate.

They are the **genioglossus**, the **hyoglossus**, the **styloglossus**, and the **palatoglossus**.

Nerve supply: **Hypoglossal nerve, except for palatoglossus muscle** which innervated by **vagus nerve (via branches of pharyngeal plexus)**

TABLE 11.8 Muscles of Tongue

Muscle	Origin	Insertion	Nerve Supply	Action
Intrinsic Muscles				
Longitudinal	Median septum and submucosa	Mucous membrane	Hypoglossal nerve	Alters shape of tongue
Transverse				
Vertical				
Extrinsic Muscles				
Genioglossus	Superior genial spine of mandible	Blends with other muscles of tongue	Hypoglossal nerve	Protrudes apex of tongue through mouth
Hyoglossus	Body and greater cornu of hyoid bone	Blends with other muscles of tongue	Hypoglossal nerve	Depresses tongue
Styloglossus	Styloid process of temporal bone	Blends with other muscles of tongue	Hypoglossal nerve	Draws tongue upward and backward
Palatoglossus	Palatine aponeurosis	Side of tongue	Pharyngeal plexus	Pulls roots of tongue upward and backward, narrows oropharyngeal isthmus

Damage of hypoglossal nerve

- Injury produces paralysis of the **ipsilateral side of the tongue**, with wasting and fasciculation; the tongue **deviates towards the affected side**.

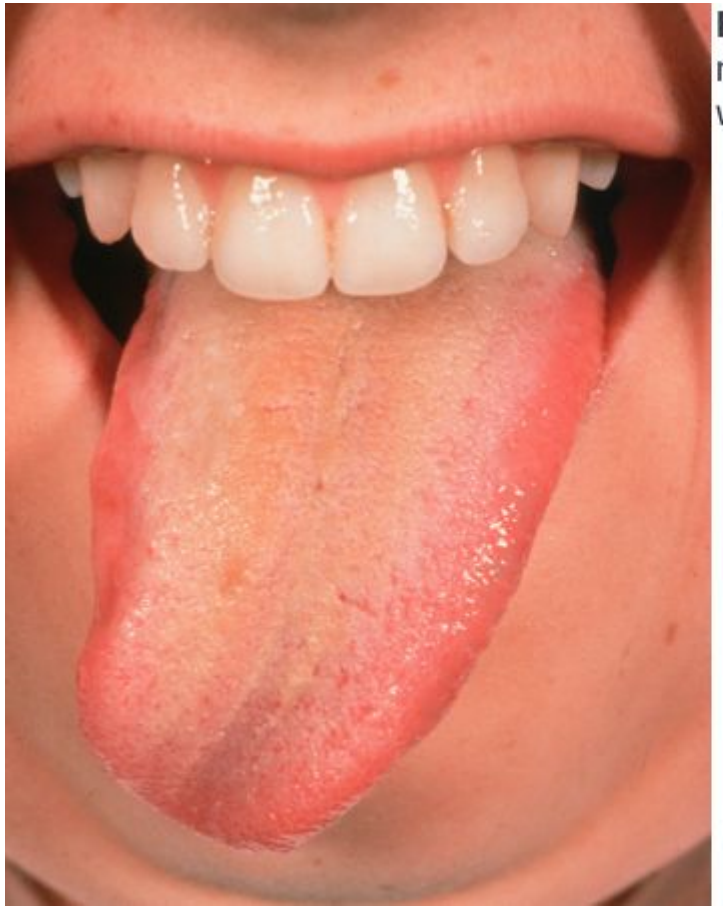

Figure 45 Right sided twelfth nerve palsy; note deviation to right and right muscle wasting.

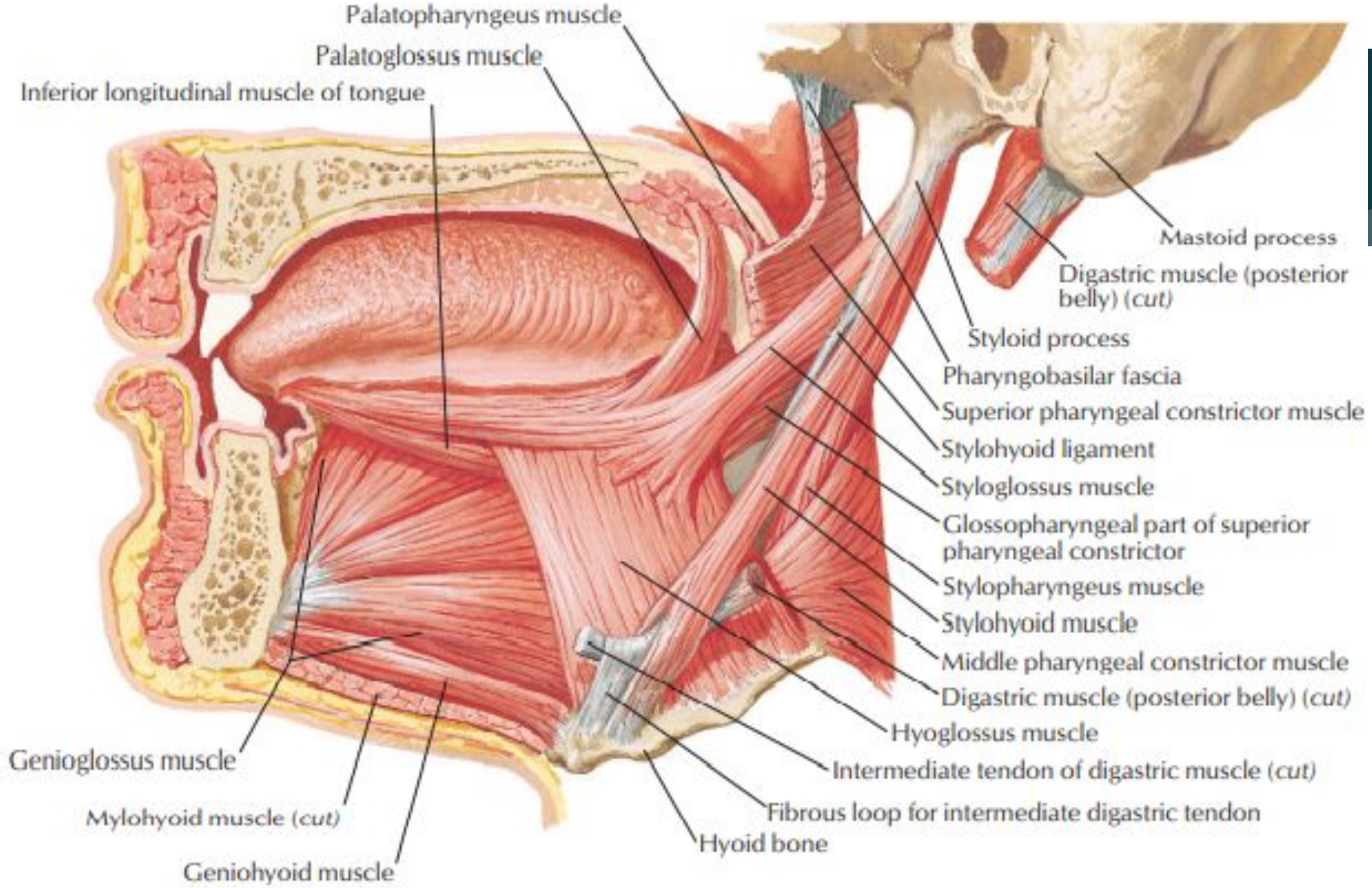
Palatopharyngeus muscle
Palatoglossus muscle
Inferior longitudinal muscle of tongue
Mastoid process
Digastric muscle (posterior belly) (cut)
Styloid process
Pharyngobasilar fascia
Superior pharyngeal constrictor muscle
Stylohyoid ligament
Styloglossus muscle
Glossopharyngeal part of superior pharyngeal constrictor
Stylopharyngeus muscle
Stylohyoid muscle
Middle pharyngeal constrictor muscle
Digastric muscle (posterior belly) (cut)
Hyoglossus muscle
Intermediate tendon of digastric muscle (cut)
Fibrous loop for intermediate digastric tendon
Hyoid bone
Genioglossus muscle
Mylohyoid muscle (cut)
Geniohyoid muscle

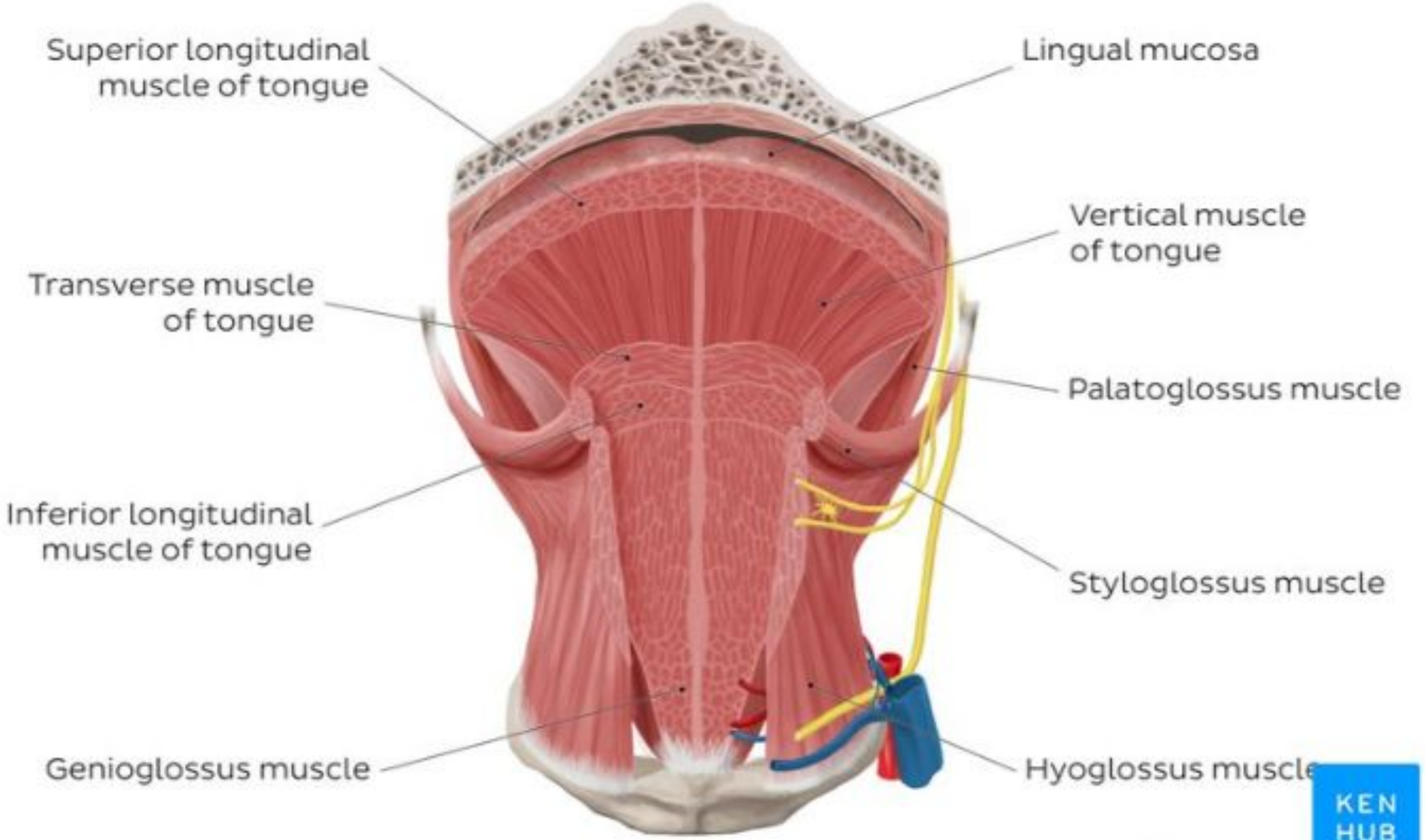
Superior longitudinal muscle of tongue
Lingual mucosa
Vertical muscle of tongue
Transverse muscle of tongue
Palatoglossus muscle
Inferior longitudinal muscle of tongue
Styloglossus muscle
Genioglossus muscle
Hyoglossus muscle
KEN HUB
© www.kenhub.com

Blood Supply of the tongue

- The **lingual artery**, the tonsillar branch of the facial artery, and the ascending pharyngeal artery supply the tongue.
- The veins drain into the internal jugular vein.

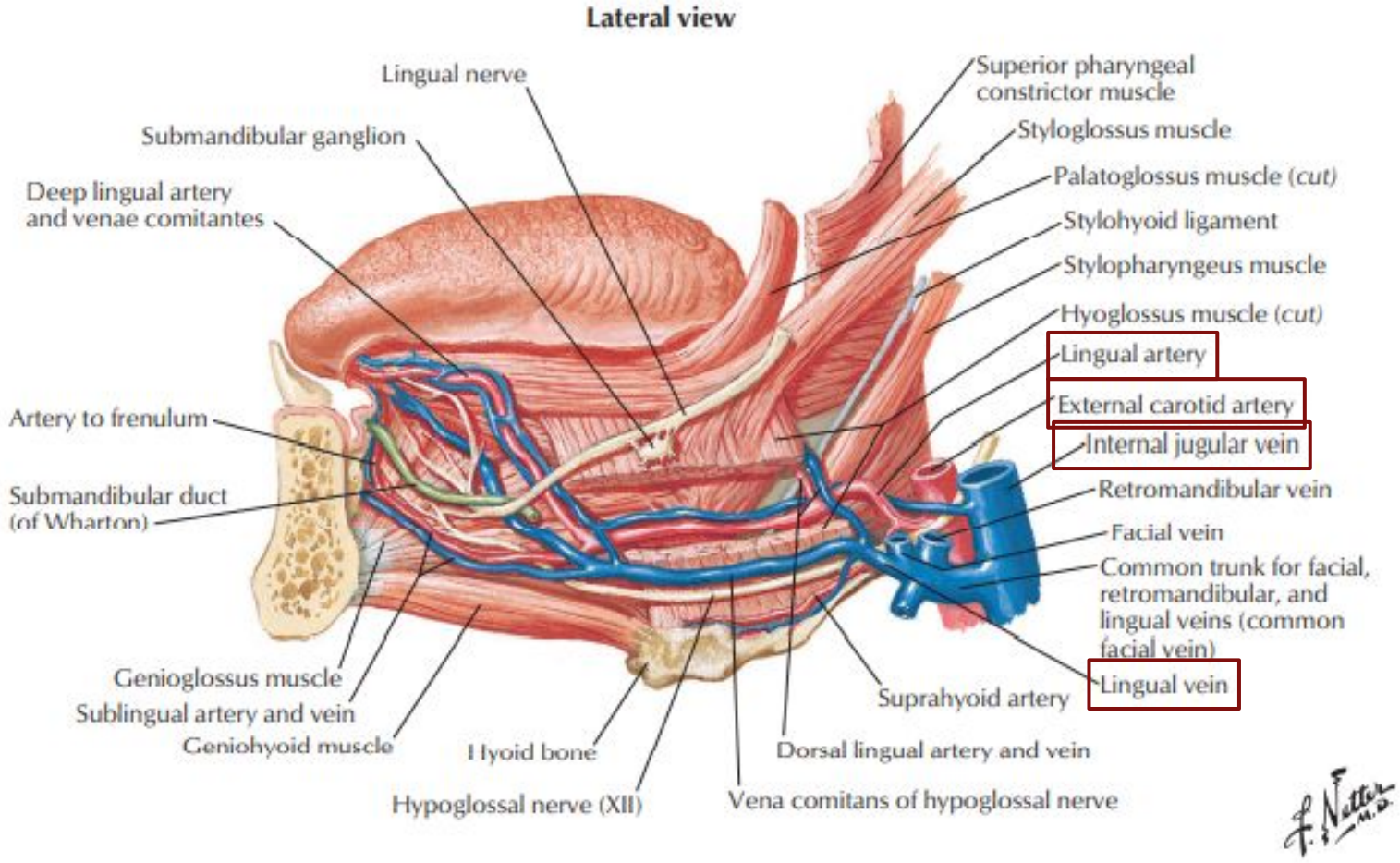

Sensory Innervation

- **Anterior two thirds**: Lingual nerve branch of mandibular division of trigeminal nerve (general sensation) and chorda tympani branch of the facial nerve (taste)
- **Posterior third**: Glossopharyngeal nerve (general sensation and taste)

The Palate

- The palate forms the roof of the mouth and the floor of the nasal cavity.
- It is divided into two parts: the hard palate in front and the soft palate behind.
- Hard Palate:

The hard palate is formed by the **palatine processes of the maxillae** and the **horizontal plates of the palatine bones.**

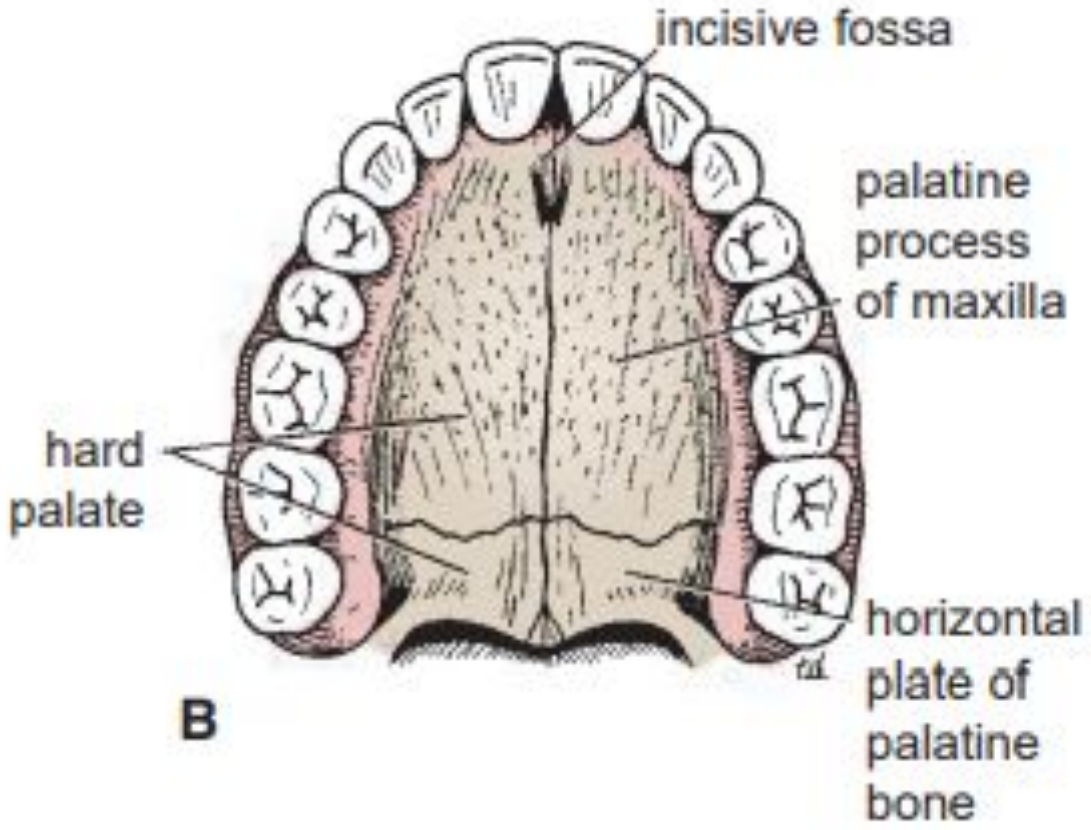

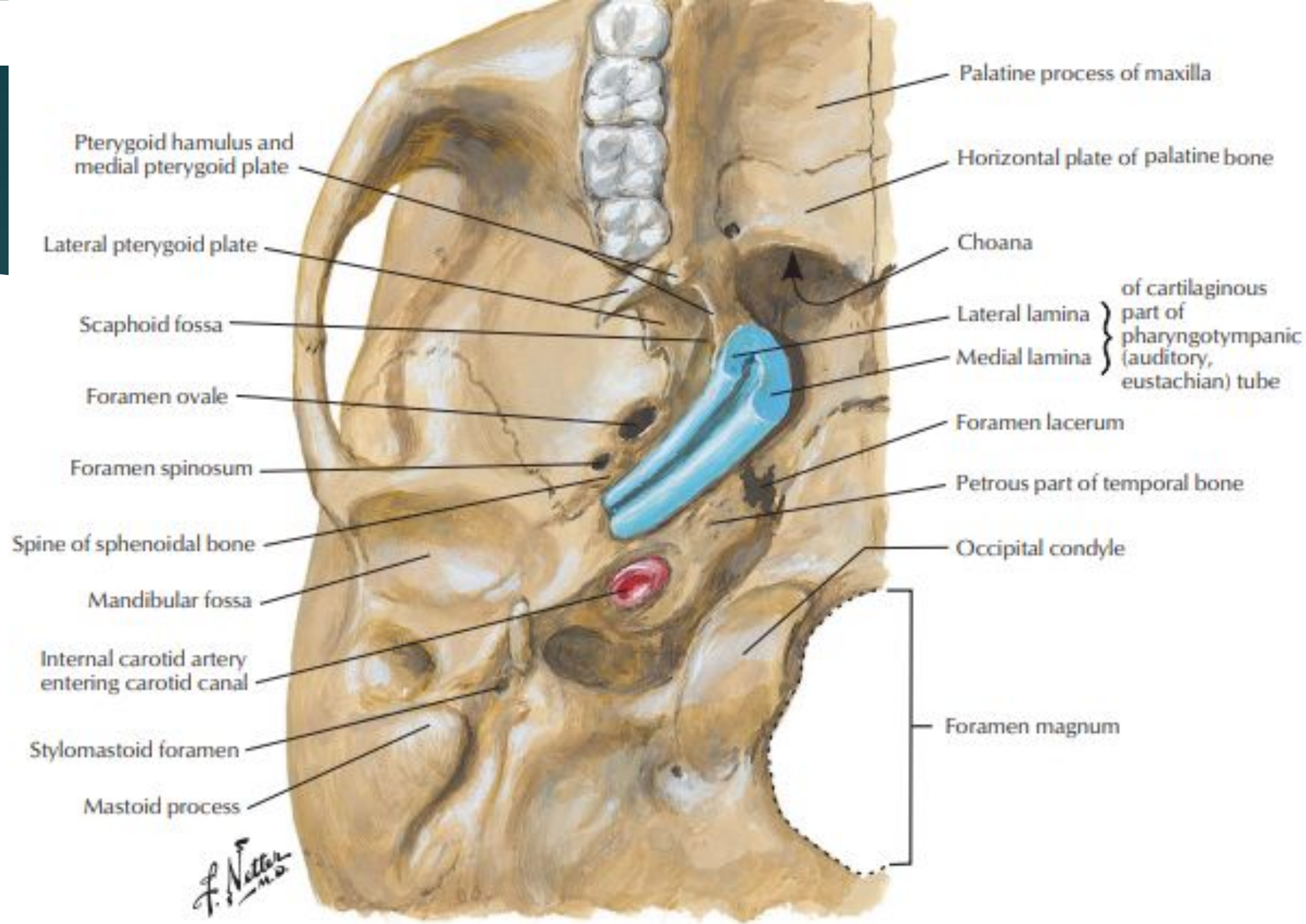
Palatine process of maxilla
Pterygoid hamulus and medial pterygoid plate
Horizontal plate of palatine bone
Lateral pterygoid plate
Choana
Scaphoid fossa
Lateral lamina
Medial lamina
of cartilaginous part of pharyngotympanic (auditory, eustachian) tube
Foramen ovale
Foramen lacerum
Foramen spinosum
Petrous part of temporal bone
Spine of sphenoidal bone
Occipital condyle
Mandibular fossa
Internal carotid artery entering carotid canal
Foramen magnum
Stylomastoid foramen
Mastoid process
F. Netter M.D.

The Palate

- Soft Palate:

The soft palate is a mobile fold attached to the posterior border of the hard palate.

Its free posterior border presents in the midline a conical projection called the **uvula**.

The soft palate is continuous at the sides with the lateral wall of the pharynx.

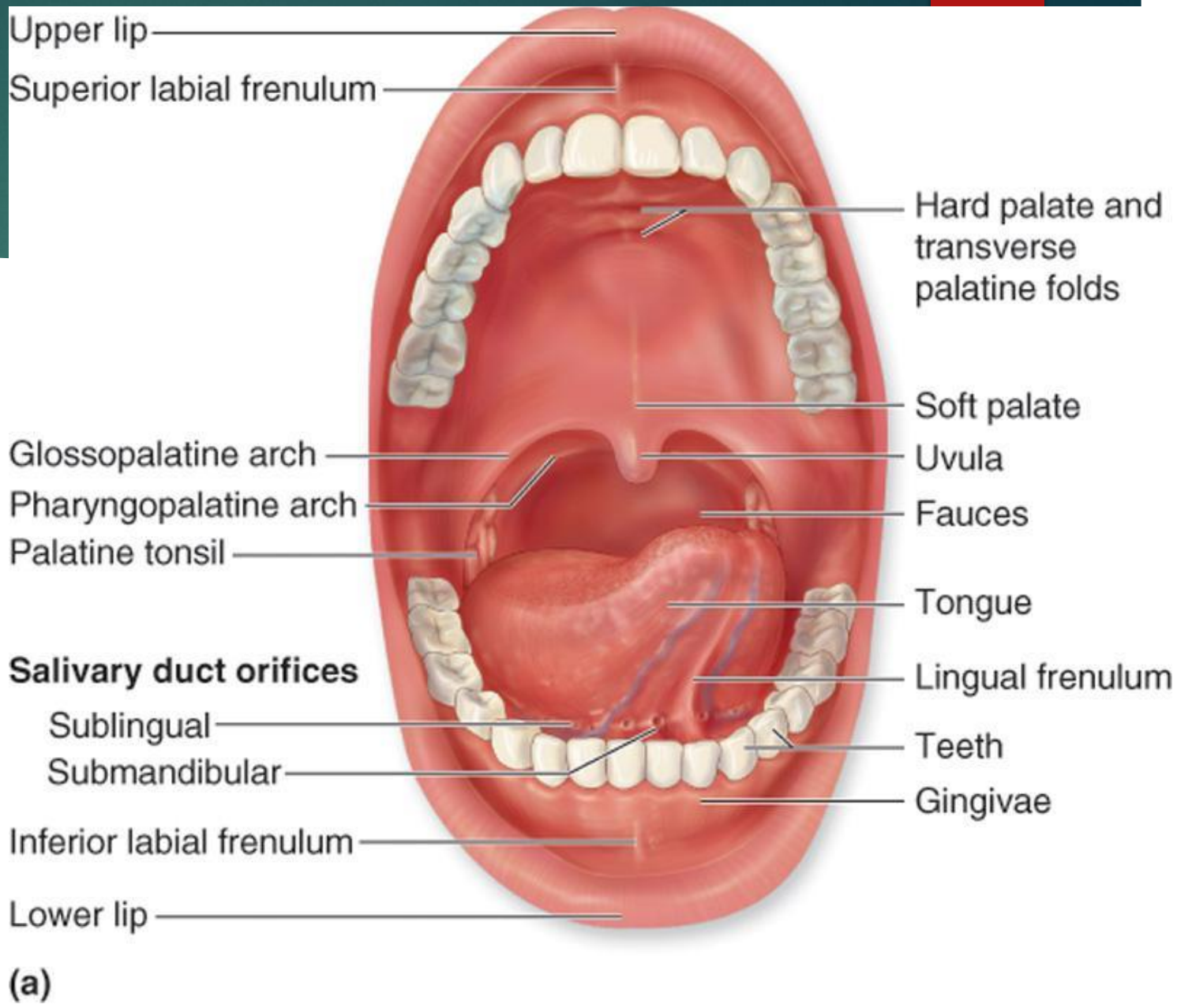

The Salivary Glands

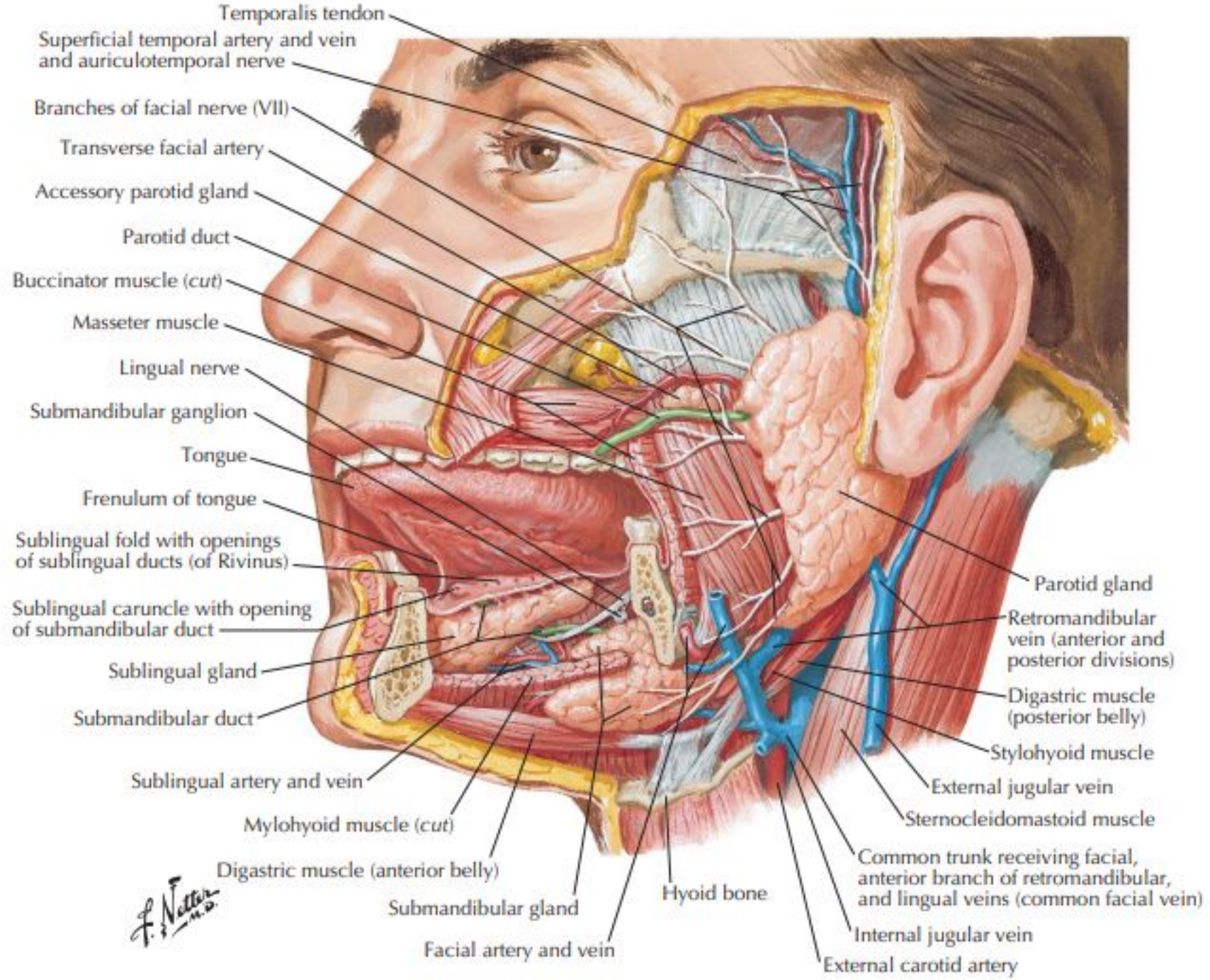

Parotid gland

- The parotid gland is the **largest** salivary gland and is composed mostly of serous acini. It lies in a deep hollow below the external auditory meatus, behind the ramus of the mandible, and in front of the sternocleidomastoid muscle.
- The **facial nerve** divides the gland into **superficial** and **deep** lobes.
- The parotid duct emerges from the anterior border of the gland and passes forward over the lateral surface of the masseter. It enters the vestibule of the mouth upon a small papilla opposite the **upper second molar tooth.**
- Parasympathetic secretomotor supply arises from the **glossopharyngeal nerve.**

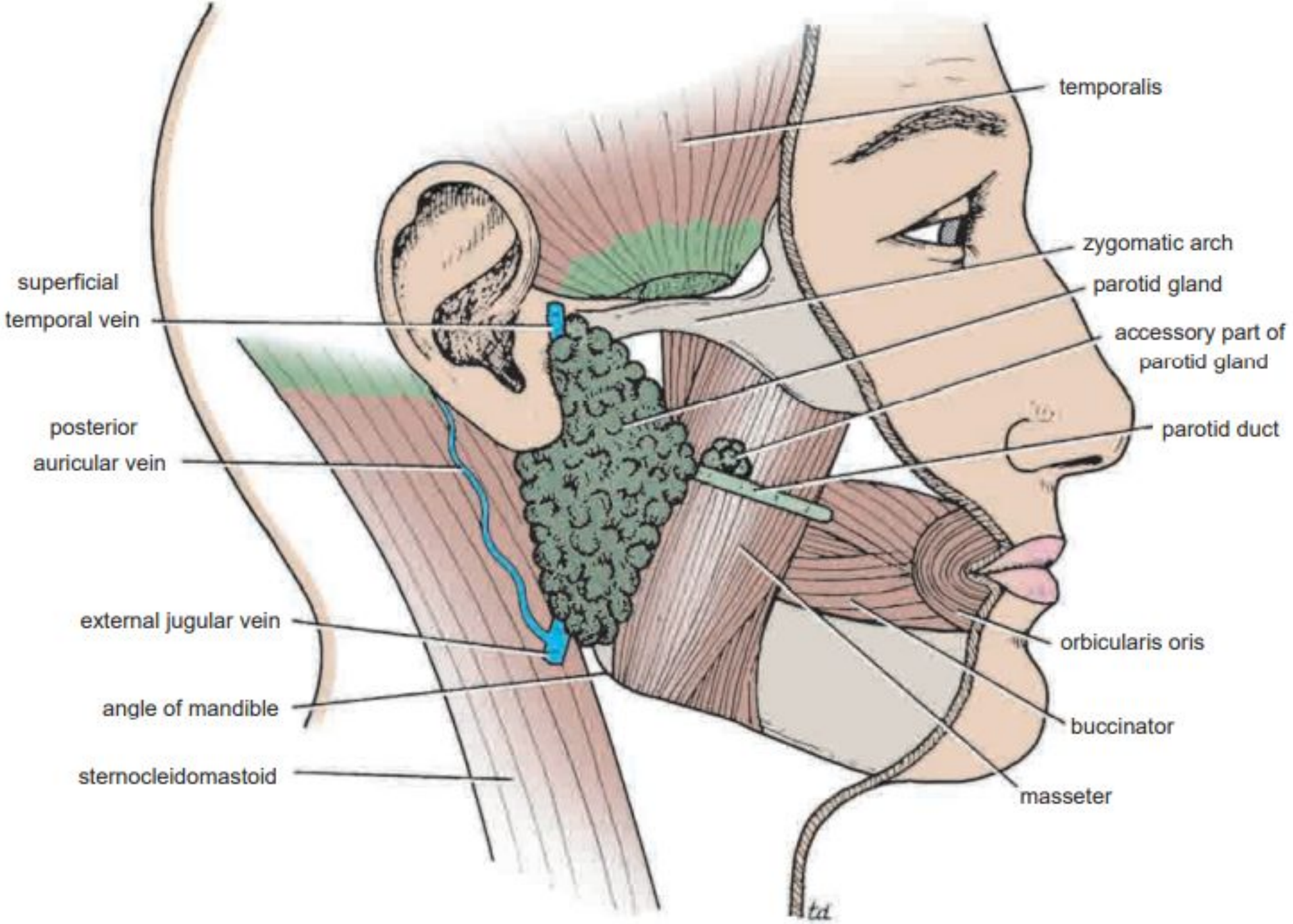
temporalis
zygomatic arch
parotid gland
accessory part of
parotid gland
parotid duct
superficial
temporal vein
posterior
auricular vein
external jugular vein
angle of mandible
sternocleidomastoid
orbicularis oris
buccinator
masseter

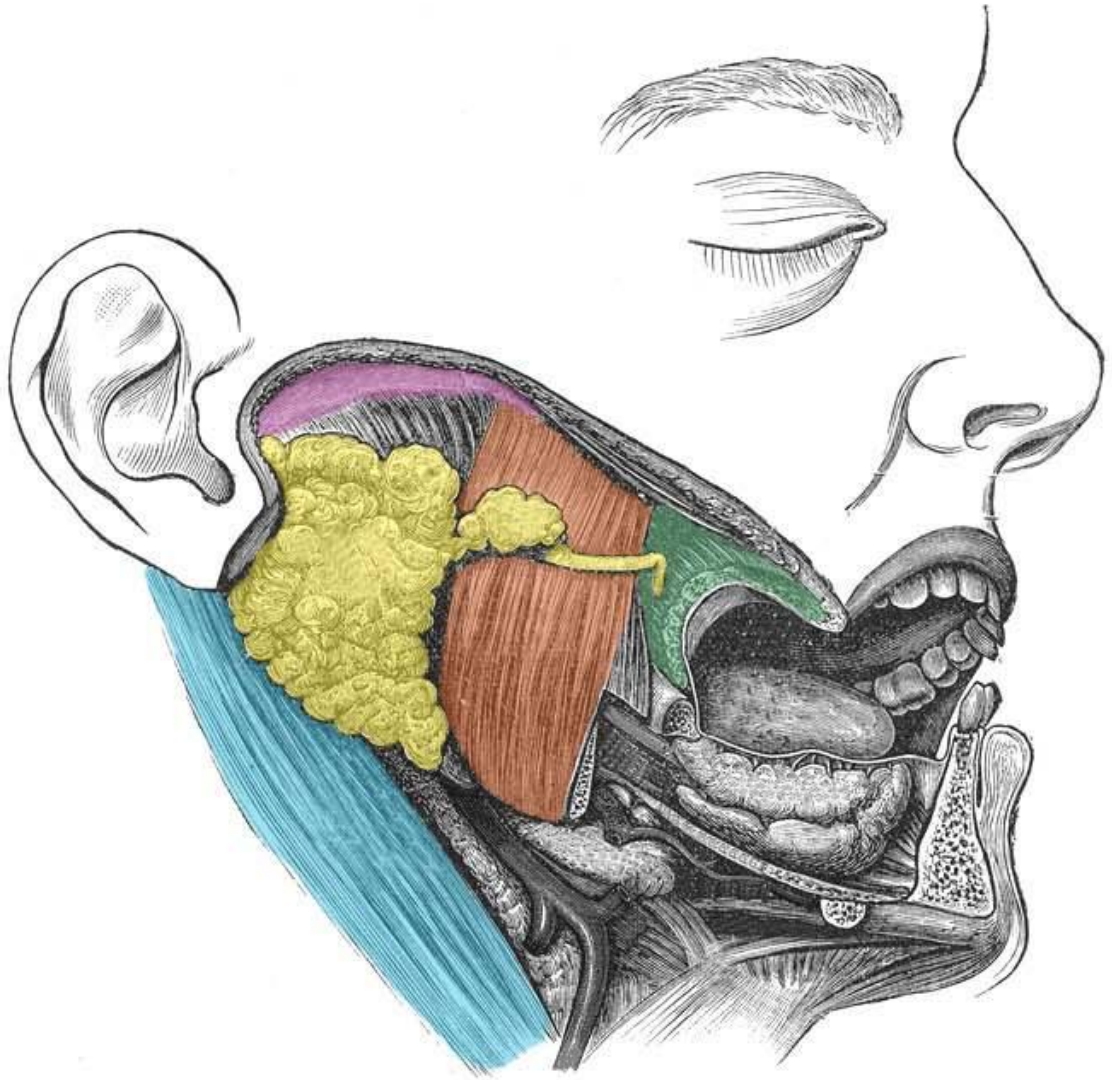

Parotid gland and duct

Zygomatic arch (superior border)

Sternocleidomastoid (posterior border)

Masseter (anterior border)

Buccinator

© teachmeanatomy
The #1 Applied Human Anatomy Site on the Web.

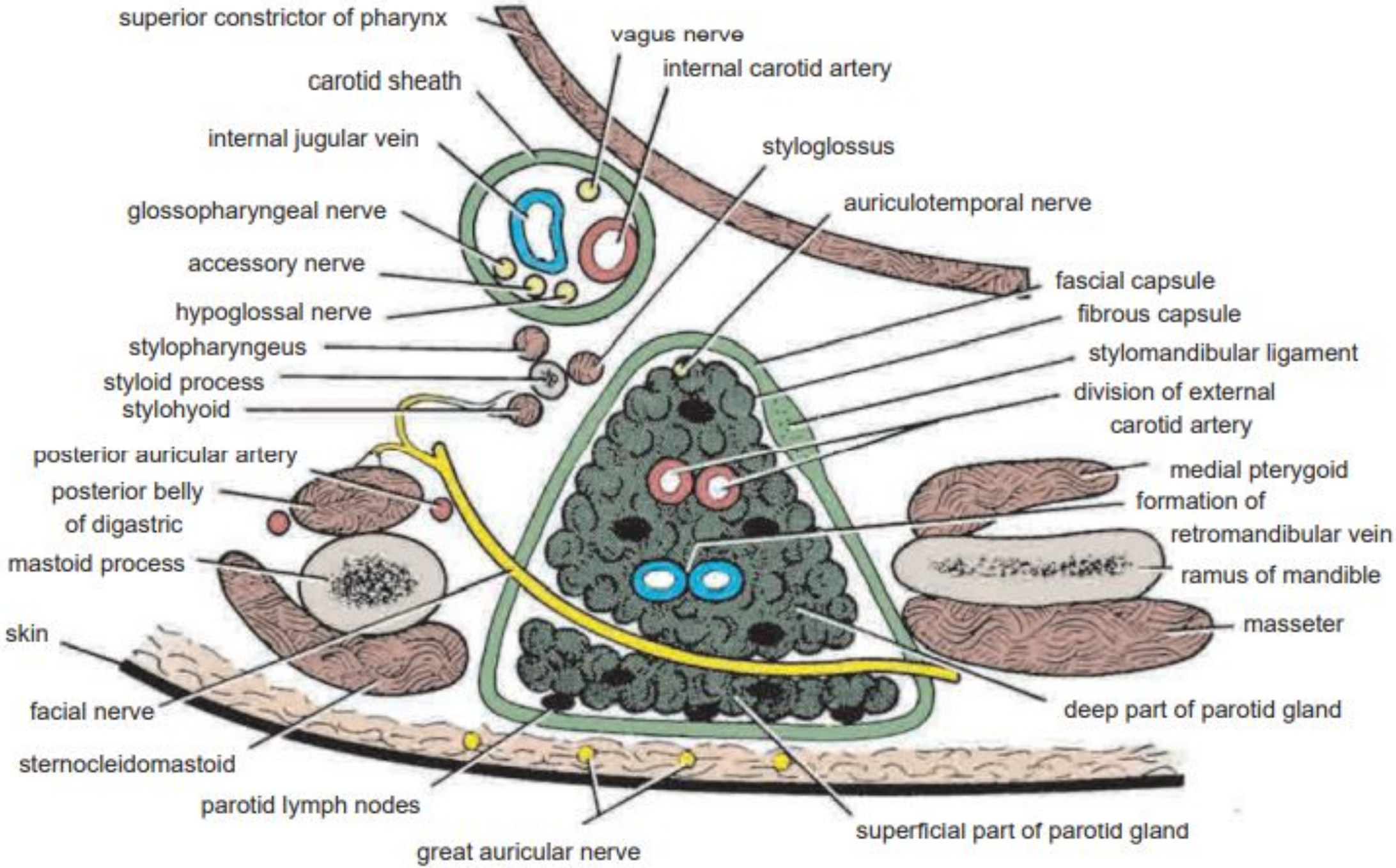
superior constrictor of pharynx
vagus nerve
internal carotid artery
carotid sheath
internal jugular vein
styloglossus
glossopharyngeal nerve
auriculotemporal nerve
accessory nerve
fascial capsule
hypoglossal nerve
fibrous capsule
stylopharyngeus
stylomandibular ligament
styloid process
division of external
stylohyoid
carotid artery
posterior auricular artery
medial pterygoid
posterior belly
of digastric
formation of
retromandibular vein
mastoid process
ramus of mandible
skin
masseter
facial nerve
deep part of parotid gland
sternocleidomastoid
parotid lymph nodes
superficial part of parotid gland
great auricular nerve

B

Submandibular Gland

- The submandibular gland consists of a mixture of serous and mucous acini.
- It lies beneath the lower border of the body of the mandible
- It is divided into superficial and deep parts by the **mylohyoid muscle.**
- The submandibular duct emerges from the anterior end of the deep part of the gland and runs forward beneath the mucous membrane of the mouth. It opens into the mouth on a small papilla, which is situated at the side of the frenulum of the tongue.
- Parasympathetic secretomotor supply is from the **facial nerve via the chorda tympani**, and the submandibular ganglion.

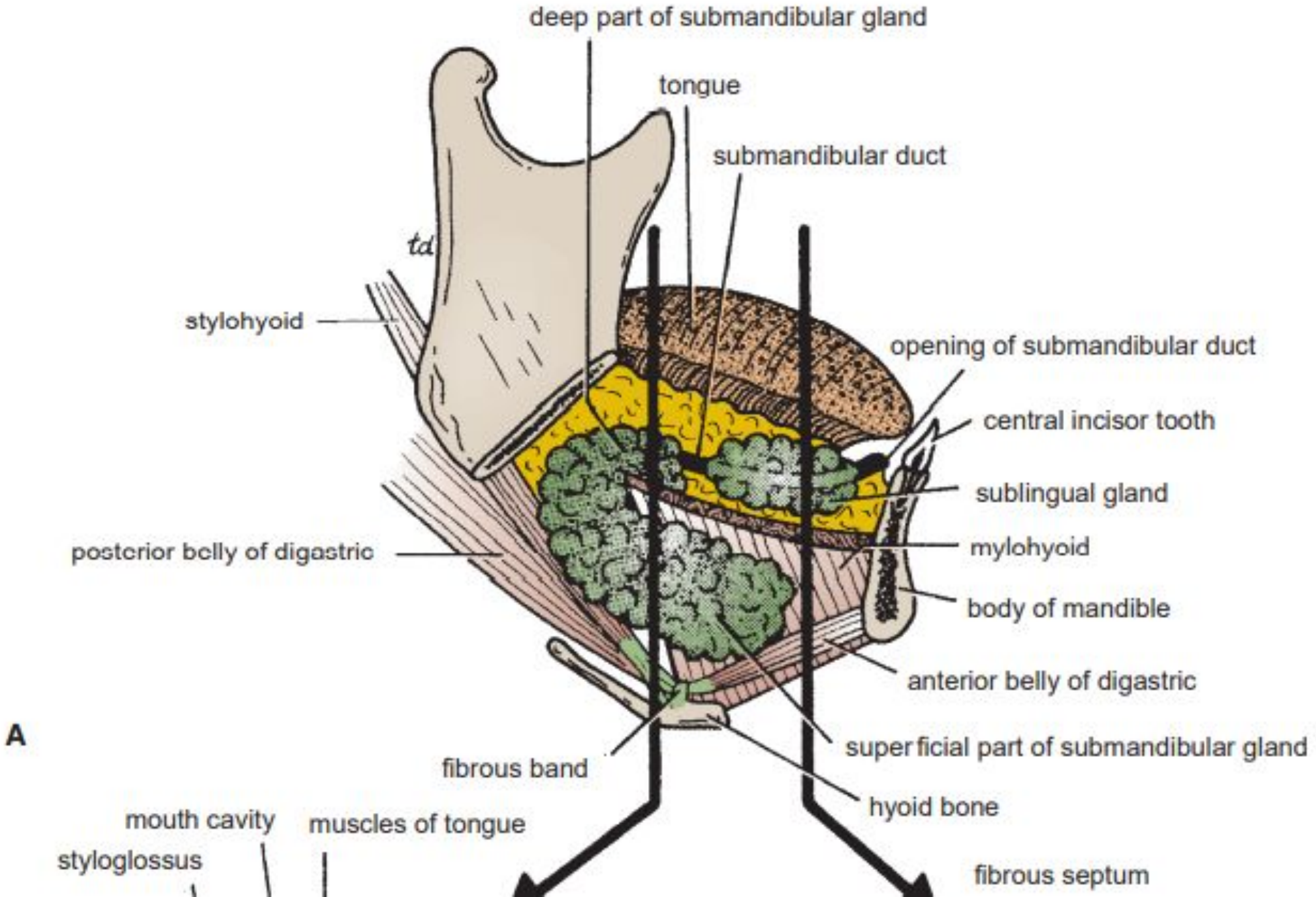
deep part of submandibular gland
tongue
submandibular duct
td
stylohyoid
opening of submandibular duct
central incisor tooth
sublingual gland
posterior belly of digastric
mylohyoid
body of mandible
anterior belly of digastric
A
fibrous band
superficial part of submandibular gland
hyoid bone
mouth cavity
muscles of tongue
styloglossus
fibrous septum

Sublingual Gland

- The sublingual gland lies beneath the mucous membrane of the floor of the mouth, close to the frenulum of the tongue.
- It has both serous and mucous acini, with the latter predominating.
- The sublingual ducts (8 to 20 in number) open into the mouth on the summit of the sublingual fold.
- Parasympathetic secretomotor supply is from the **facial nerve via the chorda tympani, and the submandibular ganglion**.

Thank you