Liver, biliary tree & pancreas

Dr. Oday Hamad; MD
Teaching assistant

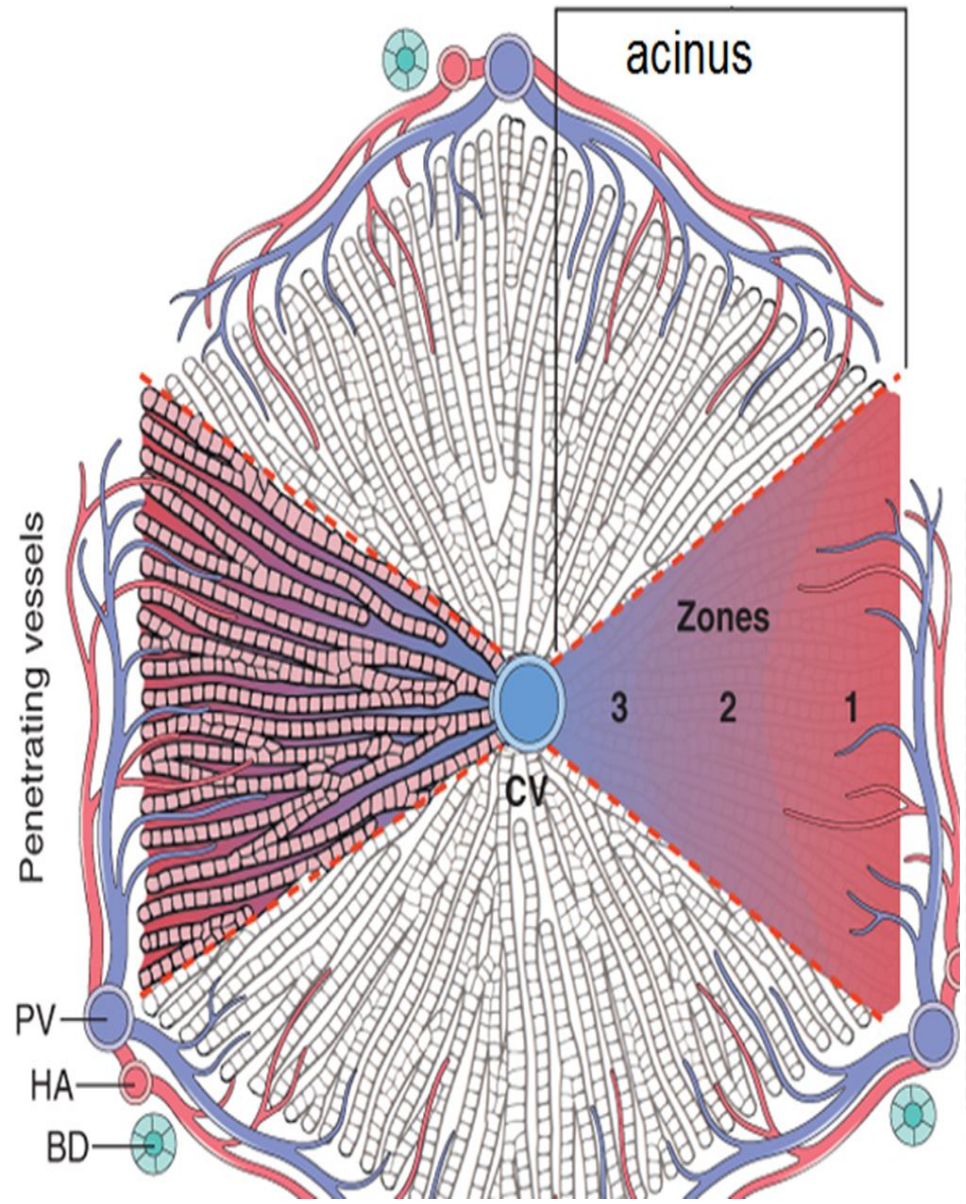
acinus
Zones
3
2
1
CV
Penetrating vessels
PV
HA
BD

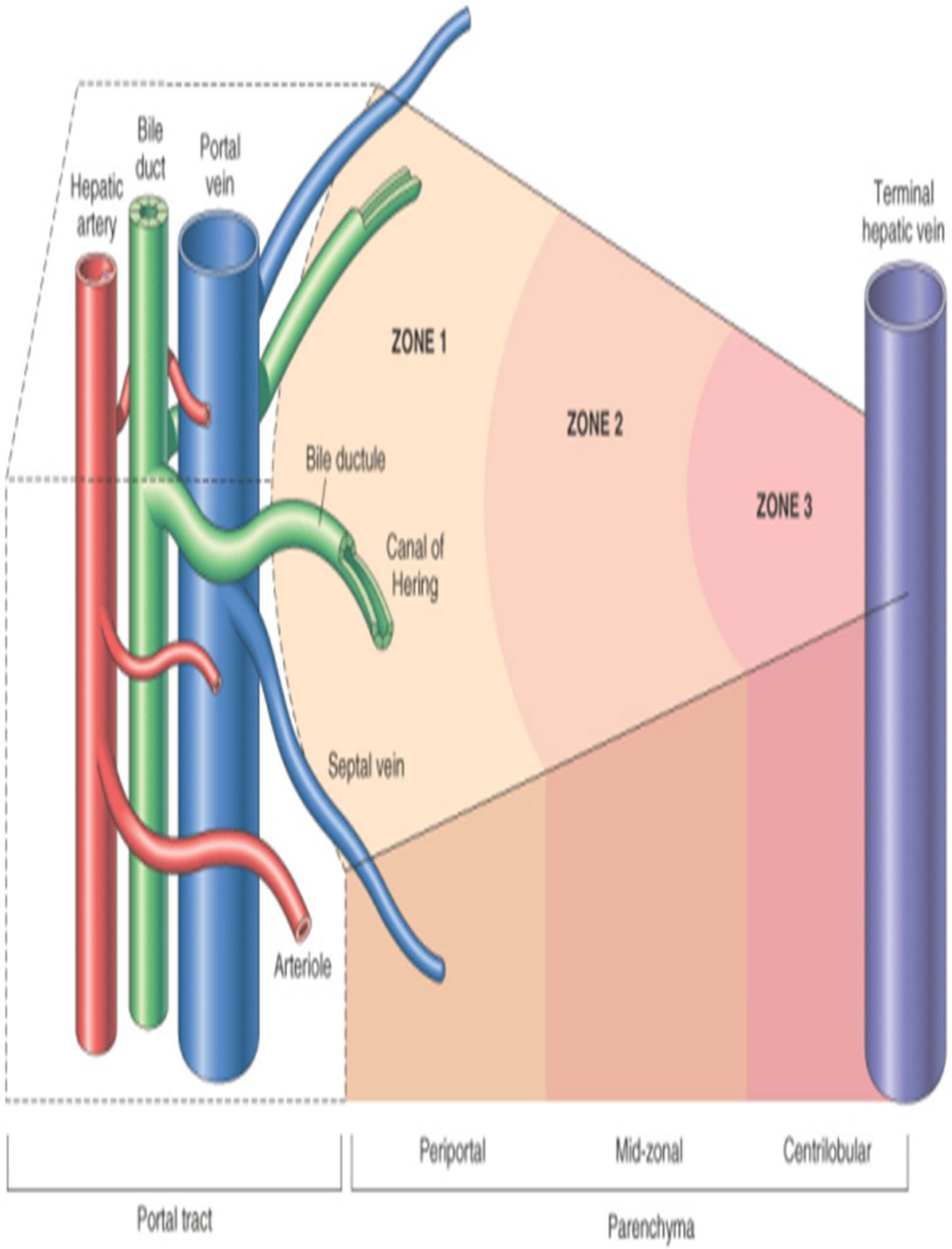
Hepatic artery
Bile duct
Portal vein
Terminal hepatic vein
ZONE 1
ZONE 2
ZONE 3
Bile ductule
Canal of Hering
Septal vein
Arteriole
Periportal
Mid-zonal
Centrilobular
Portal tract
Parenchyma

•Catabolism of hormones

•and other serum proteins

•Glucose homeostasis;

•glycogenolysis & gluconeogenesis

Chronic Liver Disease

•Synthesis:

- Albumin
- Coagulation factors

•Storage:

- Glycogen
- Iron
- Cu, Iron, vitamins

•Bile excretion

Liver diseases

- Acute hepatitis
- Chronic hepatitis
- Fatty liver disease
  - Steatosis & steatohepatitis
- Metabolic liver disease
- Diseases of intrahepatic biliary tracts
- Circulatory disorders
- Tumors and hepatic nodules

Clinical syndromes

The major clinical syndromes of liver disease:

- Hepatic failure
- Cirrhosis
- Portal hypertension
- Cholestasis

Hepatic Failure

- 80% to 90% of hepatic function must be lost before hepatic failure ensues.

- **Precipitating factors:**
- Systemic infections
- Electrolyte disturbances
- Stress (major surgery, heart failure)
- Gastrointestinal bleeding.

Acute liver failure & massive hepatic necrosis

- An uncommon but life-threatening condition that often requires liver transplantation
- **Causes:**
- Drugs: Acetaminophen, halothane, anti tuberculosis drugs
- Fulminant viral hepatitis: HAV & HBV infection
- Acute liver failure: progresses from onset of symptoms to hepatic encephalopathy within 2 to 3 wks
- Subacute failure: a course extending as long as 3Ms
- The histologic correlate is **massive hepatic necrosis**

- **Chronic liver disease:**
- The most common route to hepatic failure
- The end stage of chronic liver damage ending in cirrhosis.

- **Hepatic dysfunction without overt necrosis:**
- Hepatocytes may be viable but unable to perform normal metabolic function:
- Acute fatty liver of pregnancy
- Tetracycline toxicity
- Reye syndrome

Clinical Features of hepatic failure

- Jaundice
- Hypoalbuminemia & peripheral edema
- Hyperammonemia
- Fetor hepaticus “musty” or “sweat & sour”
  - Formation of mercaptans by action of GI bacteria on sulfur containing aa methionine
- Hyperestrogenemia in chronic liver disease:
  - Palmar erythema (local vasodilatation)
  - Spider angiomas of the skin
  - In the male, hypogonadism and gynecomastia

Palmar erythema






Complications of hepatic failure

- Ascites
- Portal hypertension
- Multiple organ failure
- Coagulopathy
  - Impaired hepatic synthesis of clotting factors
  - Bleeding tendency & GI hemorrhage
- Hepatic encephalopathy
- Hepatorenal syndrome

Hepatic Encephalopathy

- A complication of acute & chronic liver failure.
- Mechanism ?

- A spectrum of disturbances in brain function:
- Fluctuating neurologic signs:
  - Rigidity, hyper-reflexia, nonspecific EEG changes
  - Asterixis (flapping tremor) is characteristic
  - Rarely seizures
- Behavioral abnormalities
- Confusion and stupor
- Deep coma and death

Hepatorenal syndrome

- Oliguria
- Rising BUN & creatinine values.
- The ability to concentrate urine is retained:
- Hyperosmolar urine devoid of proteins & abnormal sediment with low sodium.

- Renal failure may lead to death
- Borderline renal insufficiency may persist for weeks to months.

1. Cirrhosis with ascites;
2. Serum creatinine > 133 μmol/L (1.5 mg/dl);
3. No sustained improvement of serum creatinine (decrease to a level of 133 μmol/L or less) after at least 2 days of diuretic withdrawal and volume expansion with albumin.The recommended dose of albumin is 1 g/kg of bodyweight per day to a maximum of 100 g/day;
4. Absence of shock;
5. No current or recent treatment with nephrotoxic drugs;
6. Absence of parenchymal disease as indicated by proteinuria >500 mg/day, microhematuria (>50 red blood cells per high power field) and/or abnormal renal ultrasononography.

Classification of the hepatorenal syndrome

- Type 1: cirrhosis with rapidly progressive acute renal failure
- Type 2: cirrhosis with subacute renal failure
- Type 3: cirrhosis with types 1 or 2 HRS superimposed on chronic kidney disease or acute renal injury
- Type 4: fulminant liver failure with HRS

Munoz S. Medical Clinics of North America July 2008

Type 1 vs Type 2 HRS

Definition of hepatorenal syndrome type I and type 2
Type I Hepatorenal Syndrome
Doubling of serum creatinine >2.5 mg/dl (220 µmol/l) or a 50% reduction in 24-hr creatinine clearance to <20 ml/min <2 wk
Frequently follows a precipitating event such as infection
Survival without treatment in the order of weeks
Type 2 Hepatorenal Syndrome
Less rapid renal functional deterioration than type I
Mainly presents with refractory ascites
Survival without treatment in order of months

Elsevier items and derived items © 2007 by Mosby, Inc., an affiliate of Elsevier Inc.

Hepatorenal Syndrome

- The development of renal failure without primary abnormalities of the kidneys themselves.

- **Pathogenesis:**
- Splanchnic VD and systemic VC, leading to severe reduction of renal blood flow

- Kidney function improves if hepatic failure is reversed.

Liver Cirrhosis

- Irreversible chronic injury of the hepatic parenchyma
- Extensive fibrosis - Distortion of the hepatic architecture
- Formation of regenerative nodules

Three main characteristics

- **Bridging fibrous septa**
- Delicate bands or broad scars around multiple adjacent lobules.
- **Parenchymal nodules** encircled by fibrotic bands,
- Micronodular cirrhosis, Small nodules < 3 mm
- Macronodular cirrhosis, nodules > 3mm
- The nodules mostly contain proliferating (regenerating) hepatocytes
- **Disruption of the architecture** of the entire liver.

Classification of cirrhosis

- **Micronodular cirrhosis**
  - Alcoholic liver disease
  - Hemochromatosis

- **Macronodular cirrhosis**
  - Cirrhosis due to viral hepatitis

- **Mixed micro- & macronodular**
  - Most cases

Micronodular Cirrhosis





*Restricted use. Source: PEIR: University of Alabama at Birmingham, Department of Pathology

Micronodular cirrhosis

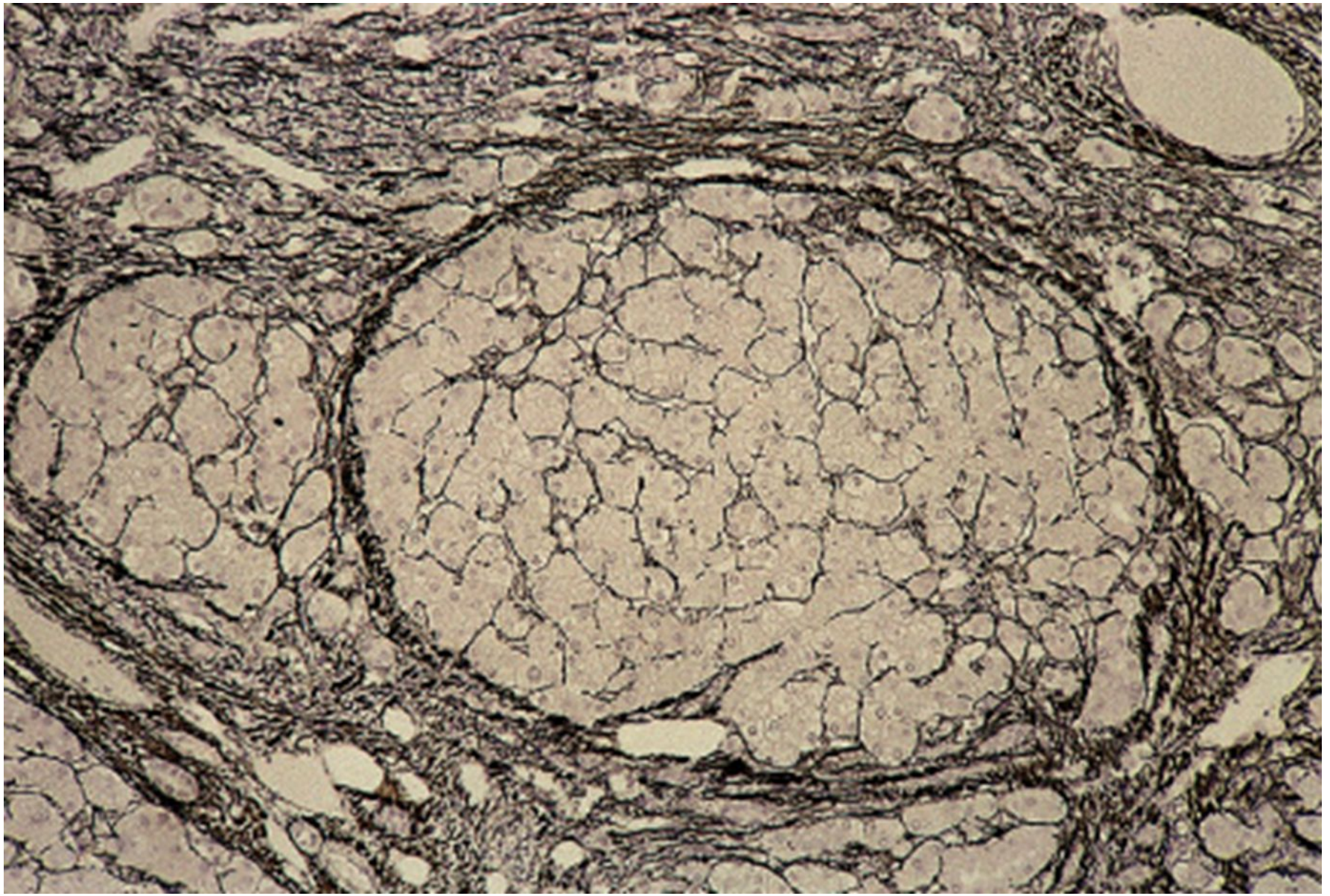

Macronodular Cirrhosis



*Restricted use. Source: PEIR: University of Alabama at Birmingham, Department of Pathology

Classification by etiology

Causes of cirrhosis	
Viral hepatitis HBV, HCV, HDV	60–70%
Alcoholic liver disease	10%
Biliary diseases	5–10%
Autoimmune hepatitis	5%
Hemochromatosis	5%
Wilson disease	Rare
Alpha1 antitrypsin deficiency	
Galactosemia, tyrosinemia	
Drug induced (α methyldopa)	
Cryptogenic cirrhosis	10–15%
Cryptogenic cirrhosis is a "wastebasket" category due to difficulty in establishing an etiologic diagnosis once cirrhosis is well established	

Clinical Features

- May be clinically silent.
- Nonspecific manifestations: anorexia, weight loss & weakness

- **Complications of cirrhosis:**
- Hepatic failure
- Portal hypertension
- Hepatocellular carcinoma

Portal Hypertension

- Increased resistance to portal blood flow, portal vein pressure > 12 mmHg (N 5-10).

Causes of portal hypertension	
Prehepatic	
Portal or splenic vein thrombosis	
Intrahepatic	
Sinusoidal	Cirrhosis, the most common cause
	Presinusoidal Schistosomiasis
	Sarcoidosis, TB, PBC, nodular regenerative hyperplasia
	Postsinusoidal Veno-Occlusive disease
Posthepatic	
Severe right-sided heart failure	
Constrictive pericarditis	
Hepatic vein or IVC outflow obstruction (Budd-Chiari $)	

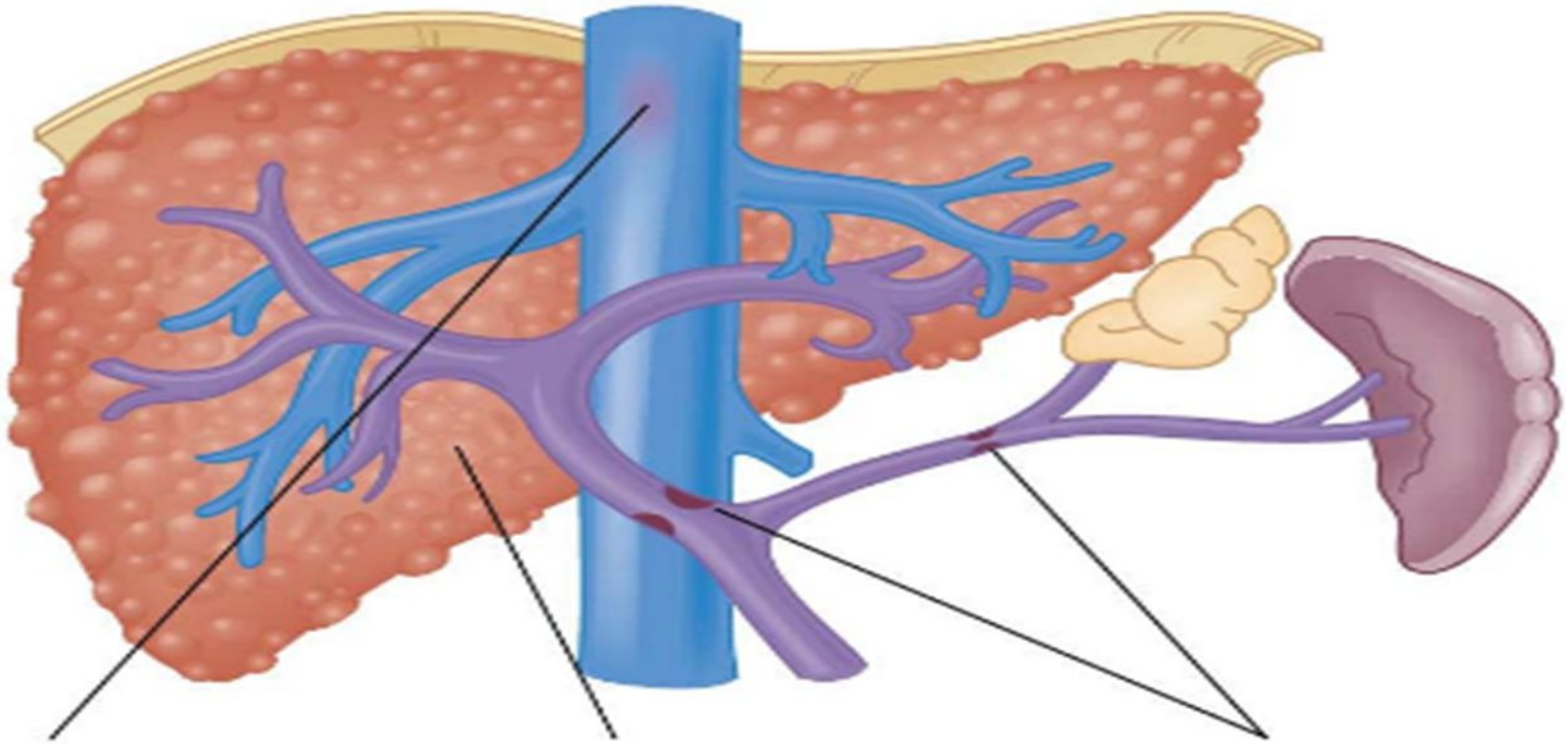

Posthepatic
Budd-Chiari syndrome
Constrictive pericarditis
Inferior vena caval obstruction
Right-sided heart failure
Severe tricuspid regurgitation

Intrahepatic
Presinusoidal
- Idiopathic portal hypertension
- Primary biliary cirrhosis
- Sarcoidosis
- Schistosomiasis

Sinusoidal
- Alcoholic cirrhosis
- Alcoholic hepatitis
- Cryptogenic cirrhosis
- Postnecrotic cirrhosis

Postsinusoidal
- Sinusoidal obstruction syndrome

Prehepatic
Portal vein thrombosis
Splenic vein thrombosis

Mechanism of portal HTN in cirrhosis

- Increased resistance to portal flow at the level of the sinusoids.
- Compression of central veins by perivenular fibrosis and expanded parenchymal nodules
- Porto-systemic anastomoses in the fibrous bands impose arterial pressure on the normally low-pressure portal venous system

Clinical consequences of portal HTN

- Ascites
- Portosystemic venous shunts
- Congestive splenomegaly
  - Hypersplenism
- Hepatic encephalopathy

Ascites

- **Definition:**
- Collection of excess fluid in the peritoneal cavity.
- Clinically detectable when at least 500 mL
- Many liters may collect and cause massive abdominal distention.
- Long-standing ascites may lead to seepage of fluid through transdiaphragmatic lymphatics to produce hydrothorax, more often on the Rt side.

Pathogenesis of ascitis

- **Sinusoidal hypertension &↑** hydrostatic pressure drives fluid into the space of Disse to be removed by hepatic lymphatics.
- Promoted by hypoalbuminemia & ↓ oncotic pressure.

Leakage of hepatic lymph into the peritoneal cavity:

- With cirrhosis, hepatic lymphatic flow may approach 20 L/day, exceeding thoracic duct capacity (800 to 1000 mL/day).

Intestinal fluid leakage

- Portal HTN ↑perfusion pressure in intestinal capillaries
- The osmotic action of the protein rich ascitec fluid promotes movement of fluid out of intestinal capillaries into the abdomen

- Renal retention of sodium and water due to secondary hyperaldosteronism

Portosystemic Shunt

- The rise in portal venous pressure leads to bypasses between the systemic and portal circulations at site of anastomosis

- Sites:
- Hemorrhoids
- Esophagogastric varices
- The retroperitoneum
- Periumbilical and abdominal wall collaterals

Portosystemic Shunt

- **Esophagogastric varices:**
- 65% of those with advanced cirrhosis
- Cause massive hematemesis and death in about half

- **Abdominal wall collaterals:**
- Dilated subcutaneous veins extending outward from the umbilicus *(caput medusae)*

Endoscopic Treatment

- Endoscopist experience and expertise
- Grade of varices
  - Grade 1 – Small, straight varices
  - Grade 2 – tortuous varices occupying <1/3rd of lumen
  - Grade 3 – Large, coil-shaped varices occupying > 1/3rd of lumen

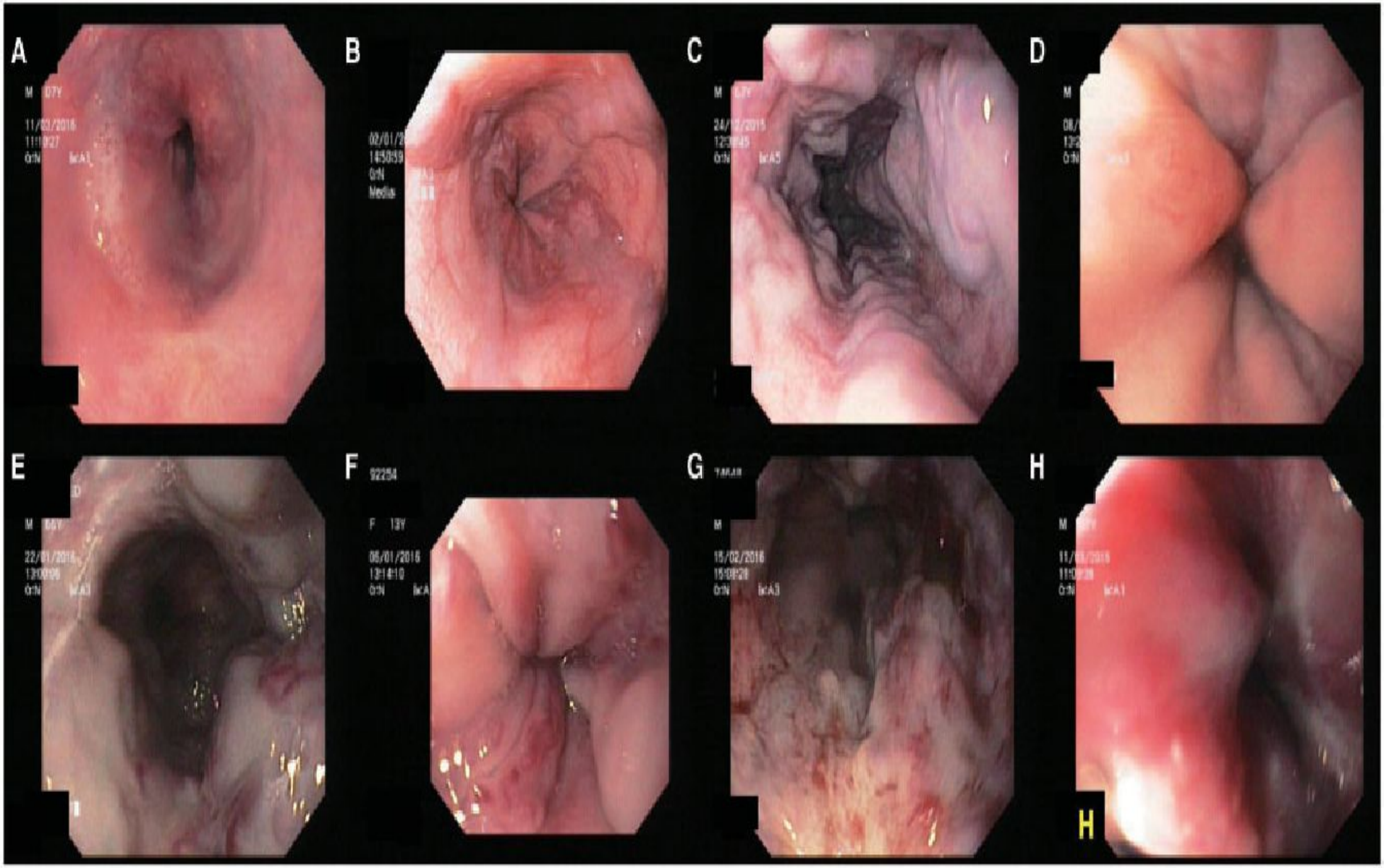

Figure 1 - A) Small esophageal varices (grade 1, form F1); B) Small and beady esophageal varices (grade 2, form F0); C) Large esophageal varices (grade 2, form F2); D)

Jaundice and Cholestasis

- **Jaundice (icterus):**
- A common manifestation of liver disease.
- A yellow discoloration of skin and sclerae due to elevated bilirubin serum levels > 2.6 mg/dL (N 0.3-1.2 mg/dL)

- **Cholestasis:**
- Systemic retention of bilirubin & other solutes eliminated in bile (bile salts and cholesterol).

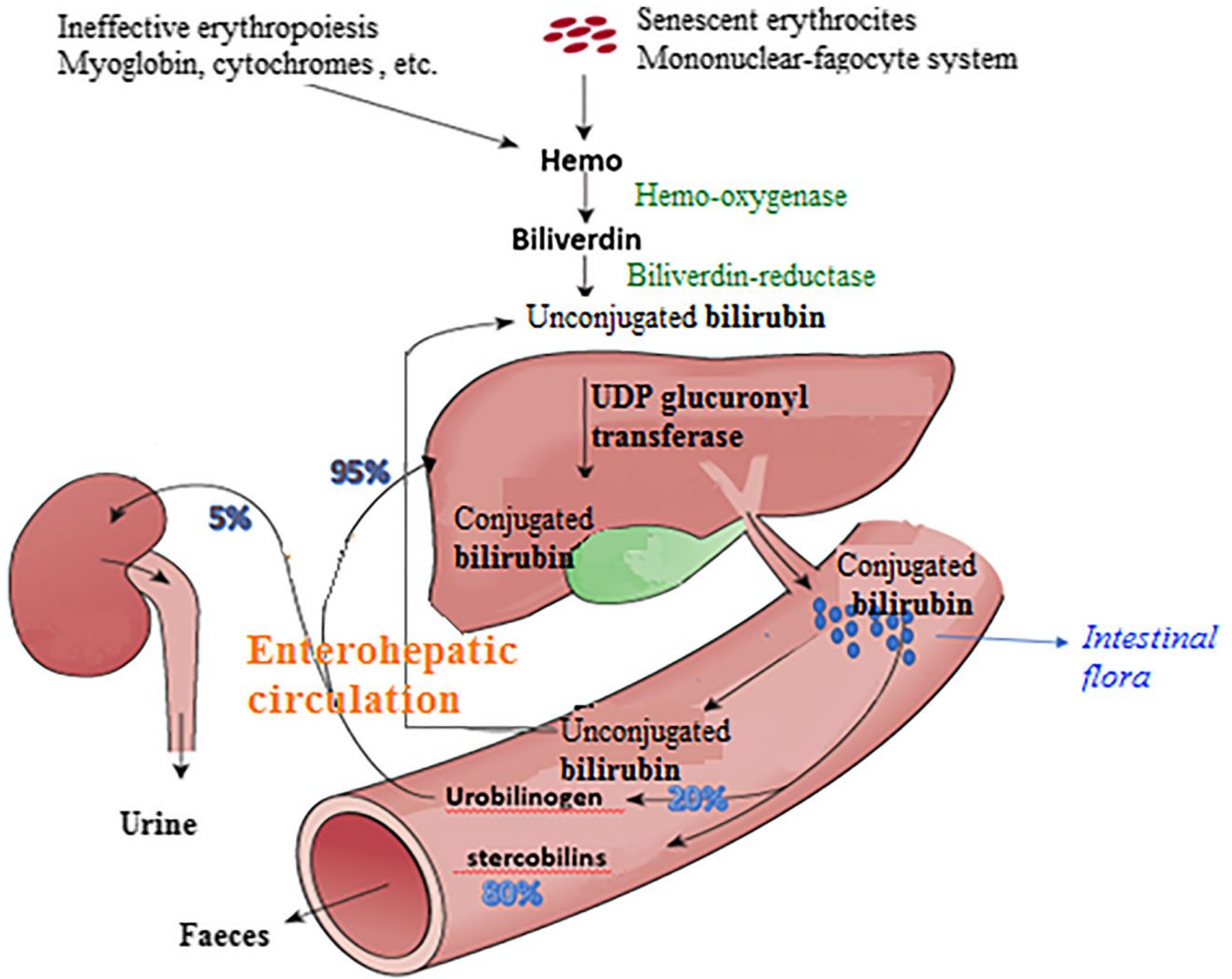
Ineffective erythropoiesis
Myoglobin, cytochromes , etc.
Senescent erythrocites
Mononuclear-fagocyte system
Hemo
Hemo-oxygenase
Biliverdin
Biliverdin-reductase
Unconjugated bilirubin
UDP glucuronyl transferase
95%
5%
Conjugated bilirubin
Conjugated bilirubin
Intestinal flora
Enterohepatic circulation
Unconjugated bilirubin
Urobilinogen
20%
Urine
stercobilins
80%
Faeces

Pathogenesis

- Jaundice occurs when the equilibrium between bilirubin production and clearance is disturbed:

- Unconjugated hyperbilirubinemia
- Excessive production of bilirubin,
- Reduced hepatic uptake,
- Impaired conjugation,
- Conjugated hyperbilirubinemia
- Decreased hepatocellular excretion,
- Impaired bile flow (Intrahepatic & extrahepatic).

Main causes of jaundice

Predominantly Unconjugated Hyperbilirubinemia

Excess production of bilirubin

- Hemolytic anemias
- Resorption of blood from internal hemorrhage
- Ineffective erythropoiesis (e.g., pernicious anemia, thalassemia)

Reduced hepatic uptake

- Drug interference with membrane carrier systems
- Some cases of Gilbert syndrome

Impaired bilirubin conjugation

- Physiologic jaundice of the newborn (reduced bilirubin UDP-glucouronyltransferase (UGT1A1) activity & decreased excretion)
- Breast milk jaundice (B-glucouronidase in milk)
- Crigler-Najar syndrome
- Gilbert syndrome
- Diffuse hepatocellular disease (e.g., viral or drug-induced hepatitis, cirrhosis)

Main Causes of Jaundice

Predominantly Conjugated Hyperbilirubinemia

Decreased hepatocellular excretion

- Deficiency in canalicular membrane transporters
  - Dubin-Johnson syndrome
  - Rotor syndrome
- Drug-induced canalicular membrane dysfunction
  - OCPs, cycloporine
- Hepatocellular damage or toxicity
  - Viral or drug-induced hepatitis
  - Total parenteral nutrition
  - Systemic infection

Impaired intra- or extra-hepatic bile flow (cholestasis)

- Inflammatory destruction of intrahepatic bile ducts
  - Primary biliary cirrhosis
  - Primary sclerosing cholangitis
  - Graft-versus-host disease
  - Liver transplantation

Hereditary jaundice

- Jaundice results from inborn errors of metabolisms:
- Unconjugated hyperbilirubinemia:
  - Crigler Najar syndrome
  - Gilbert syndrome
- Conjugated hyperbilirubinemia:
  - Dubin-Johnson syndrome
  - Rotor syndrome

Unconjugated hyperbilirubinemia

Inheritance	Defects in bilirubin metabolism	Liver pathology	Clinical course
Crigler Najar syndrome			
Type I AR	Absent UGT1A1 activity	Normal	Fatal in neonatal period due to kernicterus
Type II AD	Decreased UGT1A1 activity	Normal	Severe hyperbilirubinemia Occasional kernicterus
Gilbert syndrome, Common, 7% of population			
Heterogenous ?? AD Polymorphism	Decreased uptake Decreased UGT1A1 activity	Normal	Mild transient hyperbiluribinemia in periods of stress

Conjugated hyperbilirubinemia

	Defects in bilirubin metabolism	Liver pathology	Clinical course
Dubin –Johnson syndrome			
AR	Deficiency in canalicular membrane transporters Impaired hepatocellular excretion of bilirubin glucouronides	A darkly pigmented liver (polymerized epinephrine metabolites, not bilirubin in lysosomes)	Chronic or recurrent jaundice
Rotor syndrome			
AR	Deficiency in canalicular membrane transporters Impaired hepatocellular excretion of bilirubin glucouronides	Normal	Chronic or recurrent jaundice

Laboratory Evaluation of Liver Disease

Hepatocyte integrity

Cytosolic hepatocellular enzymes

- Serum aspartate aminotransferase (AST)
- Serum alanine aminotransferase (ALT)
- Serum lactate dehydrogenase (LDH)

Elevated in liver disease as hepatitis

Hepatocyte function

Proteins secreted into the blood

- Serum albumin
  - Decreasesd in liver disease
- Prothrombin time (factors V, VII, X, prothrombin, fibrinogen)
  - Elevated in liver disease

Hepatocyte metabolism

- Serum ammonia
  - Elevated in liver disease

Lab evaluation of liver disease

Biliary excretory function

Substances secreted in bile
- Serum bilirubin
  - Total: unconjugated plus conjugated
  - Direct: conjugated only
  - Delta: covalently linked to albumin
- Urine bilirubin
- Serum bile acids

Plasma membrane enzymes (from damage to bile canaliculus)
- Serum alkaline phosphatase
- Serum γ-glutamyl transpeptidase
- Serum 5'-nucleotidase

Table 11.1: Causes of Jaundice

DISEASE	ETIOLOGY	LABORATORY FINDINGS	CLINICAL FEATURES
Extravascular hemolysis or Ineffective erythropoiesis	High levels of UCB overwhelm the conjugating ability of the liver.	↑ UCB	Dark urine due to ↑ urine urobilinogen (UCB is not water soluble and, thus, is absent from urine) Increased risk for pigmented bilirubin gallstones
Physiologic jaundice of the newborn	Newborn liver has transiently low UGT activity.	↑ UCB	UCB is fat soluble and can deposit in the basal ganglia (kernicterus) leading to neurological deficits and death. Treatment is phototherapy (makes UCB water soluble).
Gilbert syndrome	Mildly low UGT activity; autosomal recessive	↑ UCB	Jaundice during stress (e.g., severe infection); otherwise, not clinically significant
Crigler-Najjar syndrome	Absence of UGT	↑ UCB	Kernicterus; usually fatal
Dubin-Johnson syndrome	Deficiency of bilirubin canalicular transport protein; autosomal recessive	↑ CB	Liver is dark; otherwise, not clinically significant Rotor syndrome is similar to Dubin-Johnson syndrome, but lacks liver discoloration.
Biliary tract obstruction (obstructive jaundice)	Associated with gallstones, pancreatic carcinoma, cholangiocarcinoma, parasites, and liver fluke (*Clonorchis sinensis*)	↑ CB, ↓ urine urobilinogen, and ↑ alkaline phosphatase	Dark urine (due to bilirubinuria) and pale stool Pruritus due to ↑ plasma bile acids Hypercholesterolemia with xanthomas Steatorrhea with malabsorption of fat-soluble vitamins
Viral hepatitis	Inflammation disrupts hepatocytes and small bile ductules.	↑ in both CB and UCB	Dark urine due to ↑ urine bilirubin; urine urobilinogen is normal or decreased.

Table 11.2: Important Features of Hepatitis Viruses

Inflammatory disorders of liver

- **Hepatitis**

"Injury to hepatocytes associated with an influx of acute or chronic inflammatory cells"

  - Viral hepatitis, the most common
  - Autoimmune hepatitis
  - Drug-induced hepatitis
  - Alcoholism
  - Wilson disease, alpha 1 antitrypsin deficiency

- **Infections**
- Liver abscess

Viral hepatitis

- A term reserved for infection of the liver by hepatotropic viruses (a small group of viruses having a particular affinity for the liver).

- Hepatitis A virus (HAV)
- Hepatitis B virus (HBV)
- Hepatitis C virus (HCV)
- Hepatitis D virus (HDV)
- Hepatitis E virus (HEV)
- Hepatitis G virus (HGV), not pathogenic

Other hepatic viral infections

- Systemic viral infections can involve the liver:
- Infectious mononucleosis (Epstein-Barr virus) Mild hepatitis during the acute phase
- Cytomegalovirus or herpesvirus infections,
- in newborns or immunosuppressed
- Yellow fever, in tropical countries
- Infrequently, rubella, adenovirus, or enterovirus in children and the immunosuppressed.

Table 11.2: Important Features of Hepatitis Viruses

VIRUS	TRANSMISSION	COMMENTS
Hepatitis A (HAV) and Hepatitis E (HEV)	Fecal-oral transmission HAV is commonly acquired by travelers. HEV is commonly acquired from contaminated water or undercooked seafood.	Acute hepatitis; no chronic state. Anti-virus IgM marks active infection. Anti-virus IgG is protective, and its presence indicates prior infection or immunization (immunization is available for HAV only). HEV infection in pregnant women is associated with fulminant hepatitis (liver failure with massive liver necrosis).
Hepatitis B (HBV)	Parenteral transmission (e.g., childbirth, unprotected intercourse, and intravenous drug abuse [IVDA])	Results in acute hepatitis; chronic disease occurs in 20% of cases (Table 11.3).
Hepatitis C (HCV)	Parenteral transmission (e.g., IVDA, unprotected intercourse, needle stick); risk from transfusion is almost nonexistent due to screening of the blood supply.	Results in acute hepatitis; chronic disease occurs in most cases. HCV-RNA test confirms infection; decreased RNA levels indicate recovery; persistence indicates chronic disease.
Hepatitis D (HDV)		Dependent on HBV for infection; superinfection upon existing HBV is more severe than coinfection (infection with HBV and HDV at the same time)

Hepatitis A Virus (HAV)
" "infectious hepatitis

- Incubation period: (2-4 weeks)
- Type of virus: non-enveloped ssRNA
- Mode of transmission ?
- **Feco-oral**
- Contaminated water and foods (raw or steamed shellfish)
- It is shed in the stool for 2 to 3 weeks before and 1 week after the onset of jaundice.

- HAV is <u>NOT</u> shed in any significant quantities in saliva, urine, or semen.
- HAV viremia is transient.

Clinical disease

- **Acute hepatitis**
  - Mild or asymptomatic (in children)
  - Rare in adults, may cause greater morbidity

- NO chronic hepatitis or a carrier state
- Fulminant hepatitis is rare
- Mortality rate 0.1%

Serologic markers

- Anti-HAV IgM antibody
- Appear in blood at the onset of symptoms.
- Detection of anti-HAV IgM antibody is the best diagnostic marker for the disease

- Anti-HAV IgG antibody:
- Persists beyond convalescence
- The primary defense against reinfection
- No routinely available tests for IgG anti-HAV

HAV

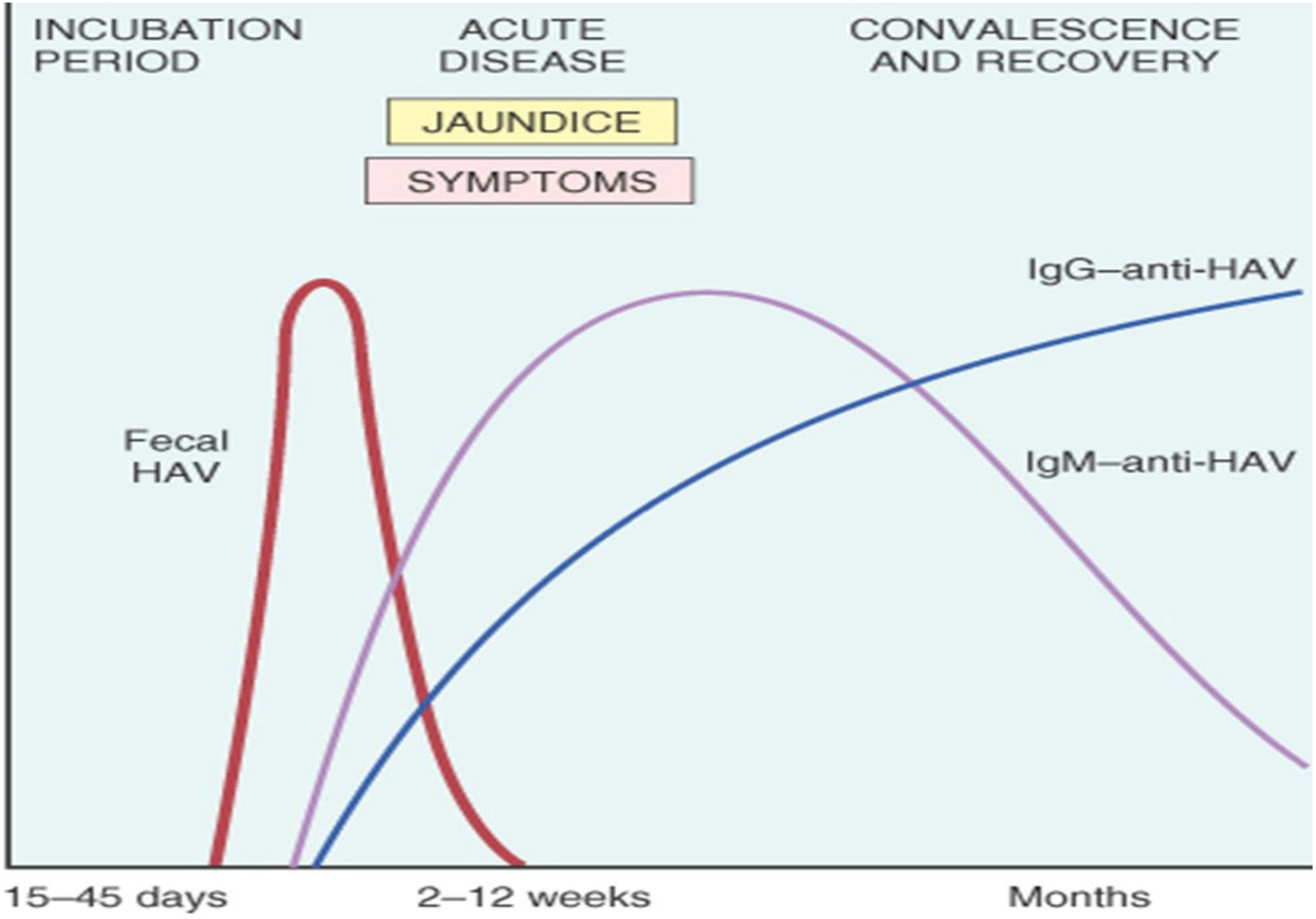
INCUBATION PERIOD
ACUTE DISEASE
CONVALESCENCE AND RECOVERY
JAUNDICE
SYMPTOMS
IgG–anti-HAV
IgM–anti-HAV
Fecal HAV
15–45 days
2–12 weeks
Months

Hepatitis B Virus (HBV)

- Type of virus: enveloped dsDNA
- Incubation period: (4-26 weeks)

- In areas of low prevalence -parentral
  - Contact with blood or body fluids
  - Transfusion, blood products, dialysis
  - Needle-stick accidents among health workers
  - Intravenous drug abuse
  - Sexual transmission
- In endemic regions
  - Vertical transmission from mother to child during birth is the main mode of transmission.

Table 4. Risk of infection and required post-exposure prophylaxis for the three most commonly transmitted pathogens

Pathogen	Infection risk after needlestick*	Post-exposure prophylaxis (PEP)	
		What to do?	When to act?
Human immunodeficiency virus (HIV)	0.3%	A four-week course of a combination of either two or three antiretroviral drugs determined on a case-by-case basis	As quickly as possible, preferably within hours
Hepatitis B virus (HBV)	Approximately 0% with PEP; 6% to 30% without PEP	HBIG† alone or in combination with vaccine (if not previously vaccinated)	Preferably within 24 hours, no later than seven days
Hepatitis C virus (HCV)	1.8%	No recommendation	N/A

*After needlestick injury from a known positive patient source

†HBIG=Hepatitis B immune globulin

Source: Adapted from Exposure to blood: What healthcare personnel need to know. *Centers for Disease Control and Prevention website. Available at: www.cdc.gov/ncidod/dhqp/pdf/bbp/Exp_to_Blood.pdf.*

Clinical disease

- Acute hepatitis with recovery
- Non-progressive chronic hepatitis
- Progressive chronic disease ending in cirrhosis
- Fulminant hepatitis with massive liver necrosis in <1%
- An asymptomatic carrier state
  - 1-10% in adults
  - 90-95% in children with vertical transmission
- Hepatocellular carcinoma

HBV

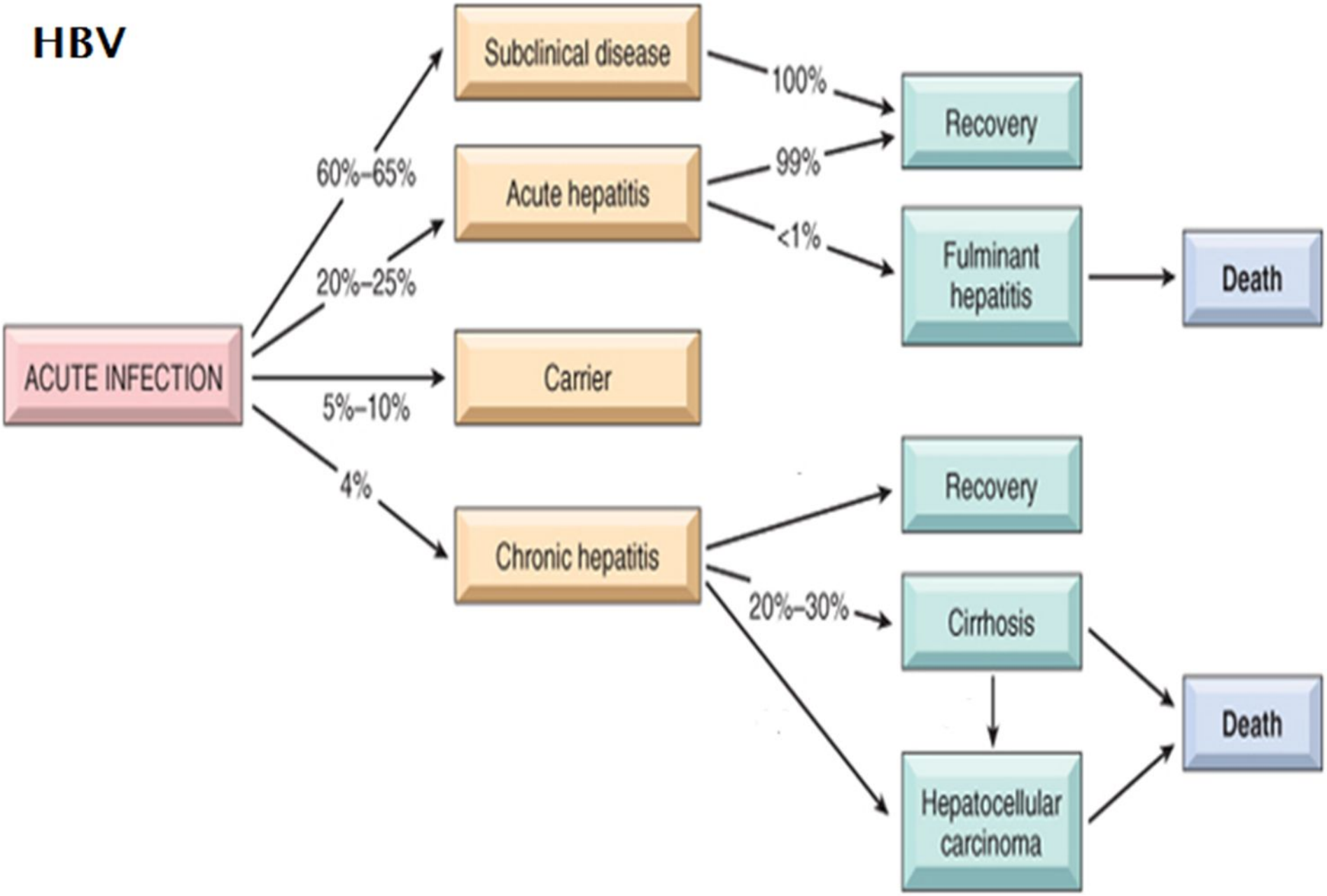
ACUTE INFECTION
60%–65%
20%–25%
5%–10%
4%
Subclinical disease
Acute hepatitis
Carrier
Chronic hepatitis
100%
99%
<1%
Recovery
Fulminant hepatitis
Death
Recovery
20%–30%
Cirrhosis
Hepatocellular carcinoma
Death

Table 11.3: Serologic Markers of Hepatitis B Virus

STAGE	HBsAG	HBeAG AND HBV DNA	HBcAB	HBsAB
Acute	+ (first serologic marker to rise)	+	IgM	–
Window	–	–	IgM	–
Resolved	–	–	IgG	IgG (protective)
Chronic	+ (presence > 6 months defines chronic state)	+/–: presence of HBeAg or HBV DNA indicates infectivity.	IgG	–
Immunization	–	–	–	IgG (protective)

Serum markers- Acute hepatitis B

- **HBsAg**
- Appears before the onset of symptoms, peaks during overt disease, and declines to undetectable levels in 3 to 6 months

- **HBeAg, HBV-DNA, and DNA polymerase**
- Appear in serum soon after HBsAg
- Signify active viral replication

IgM anti-HBc

- Becomes detectable in serum shortly before the onset of symptoms, with onset of serum elevation of serum aminotrasferases (hepatocyte destruction)

- Over months, it is replaced by IgG anti-HBc
- No direct assay for IgG anti-HBc

Anti HBe antibody

- Detected shortly after disappearance of HBeAg
- It implies that the acute infection has peaked & the disease is on the wane

- **Anti-HBc & Anti-HBe** are used to diagnose HBV during the Window gap (disappearance of HBsAg & appearance of anti HBs)

IgG anti-HBs antibody

- Does not rise until the acute disease is over
- Is usually not detectable for a few weeks or months after the disappearance of HBsAg.

- Anti-HBs may persist for life, conferring protection (the basis for current vaccination)

HBV

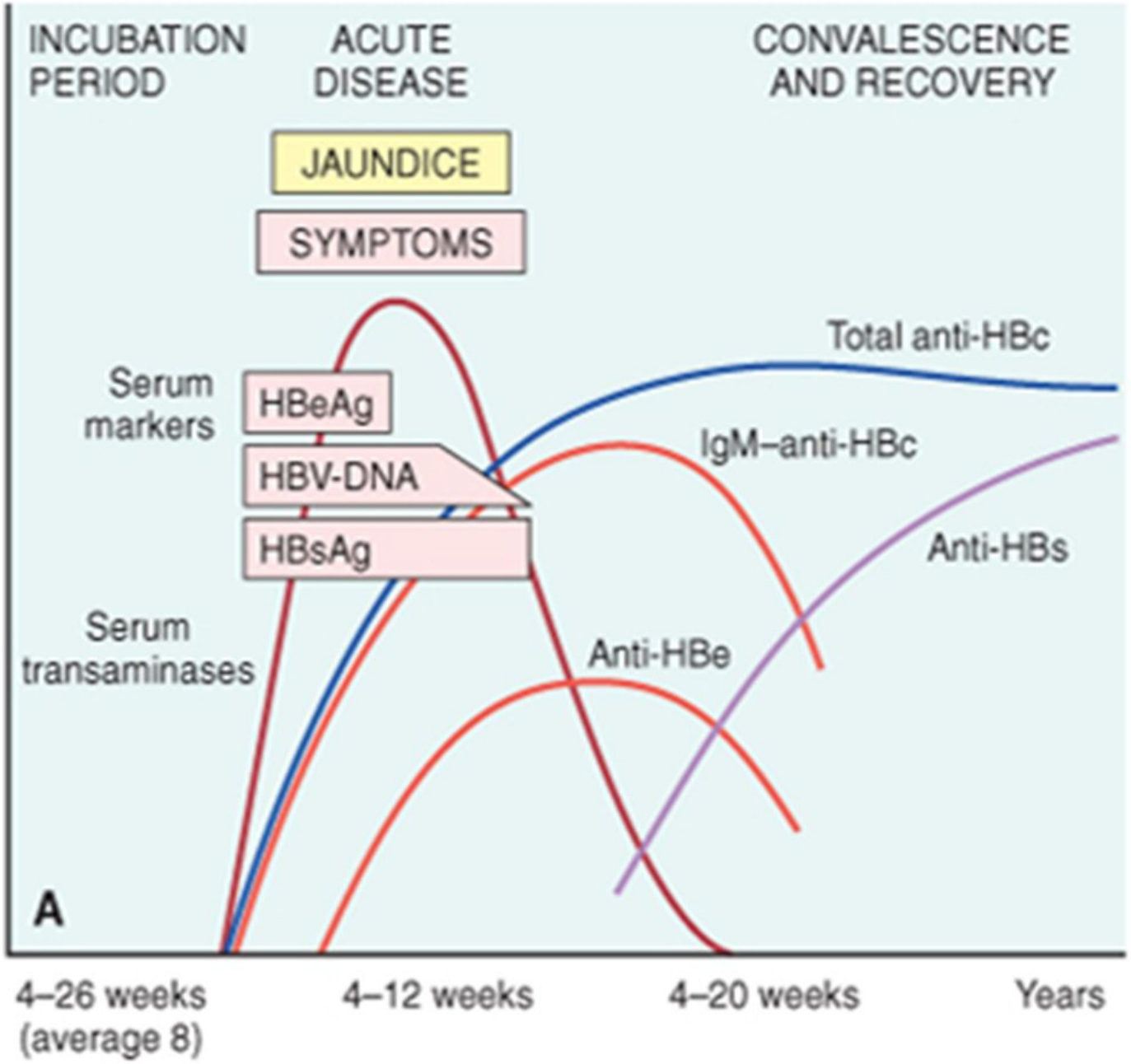
INCUBATION PERIOD
ACUTE DISEASE
CONVALESCENCE AND RECOVERY
JAUNDICE
SYMPTOMS
Total anti-HBc
Serum markers
HBeAg
IgM–anti-HBc
HBV-DNA
HBsAg
Anti-HBs
Serum transaminases
Anti-HBe
A
4–26 weeks (average 8)
4–12 weeks
4–20 weeks
Years

Serum markers

- **The chronic carrier state**
- Defined by the presence of HBsAg in serum for 6 months or longer after initial detection
- HBeAg negative
- Serum HBV DNA $<10^5$ copies/mL

- **Chronic hepatitis:**
- Circulating HBsAg, HBeAg & HBV DNA
- Usually with anti-HBc antibody

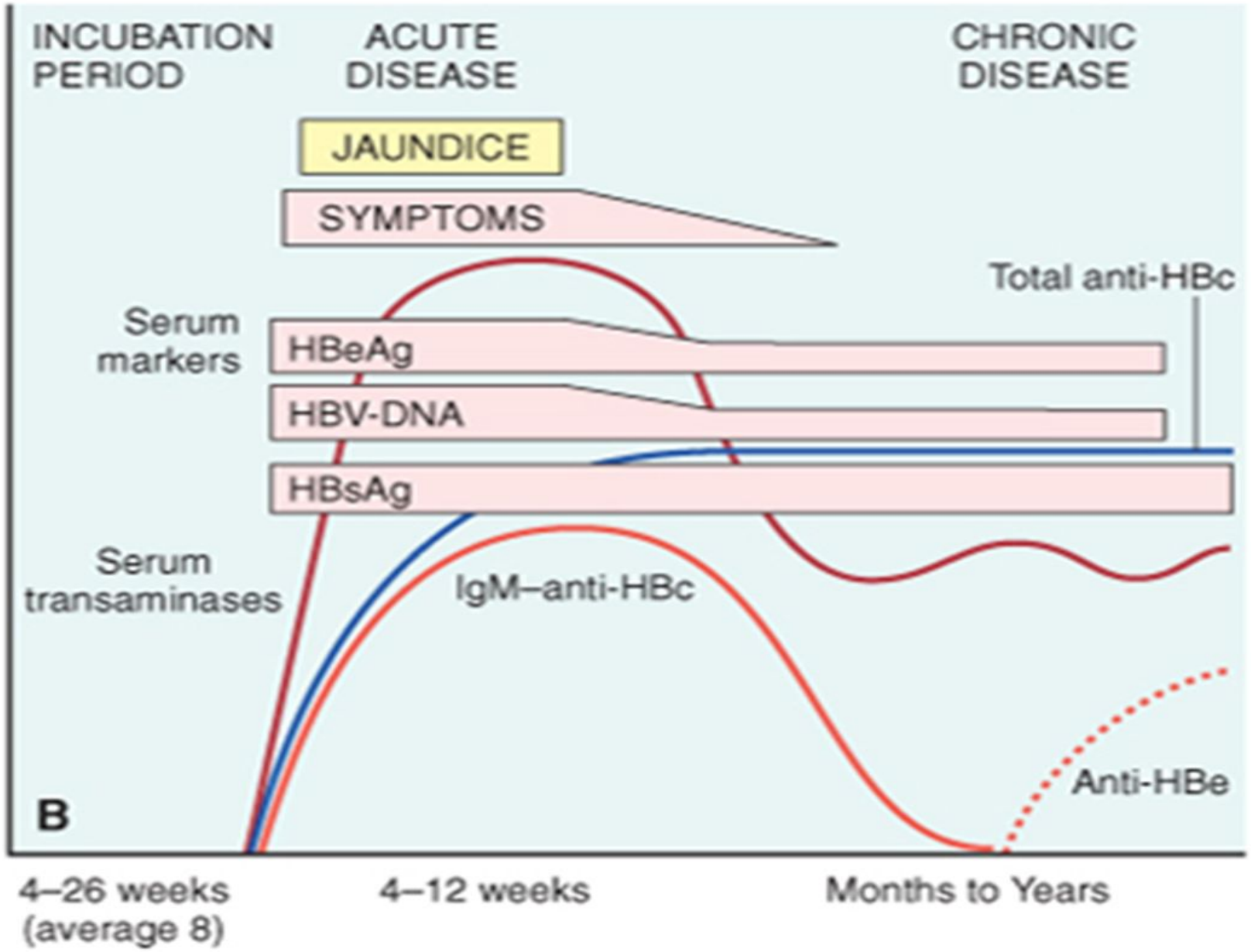
INCUBATION PERIOD
ACUTE DISEASE
CHRONIC DISEASE
JAUNDICE
SYMPTOMS
Total anti-HBc
Serum markers
HBeAg
HBV-DNA
HBsAg
Serum transaminases
IgM–anti-HBc
Anti-HBe
B
4–26 weeks (average 8)
4–12 weeks
Months to Years

Hepatitis C Virus (HCV)

- Type of virus: Enveloped ssRNA
- Incubation period: (2 to 26 weeks)

Mode of transmission

- The major route is blood inoculation:
- IV drug use in > 40% of cases
- Transmission via blood products in 4%
- Occupational exposure among health care workers in 4%.

Clinical disease

- Acute hepatitis
- The clinical course of acute hepatitis C is asymptomatic in 75%

- HCV infection has a much higher rate than HBV of progression to chronic disease (80-85%)
- Cirrhosis in 20% of cases of chronic infections
- Hepatocellular carcinoma

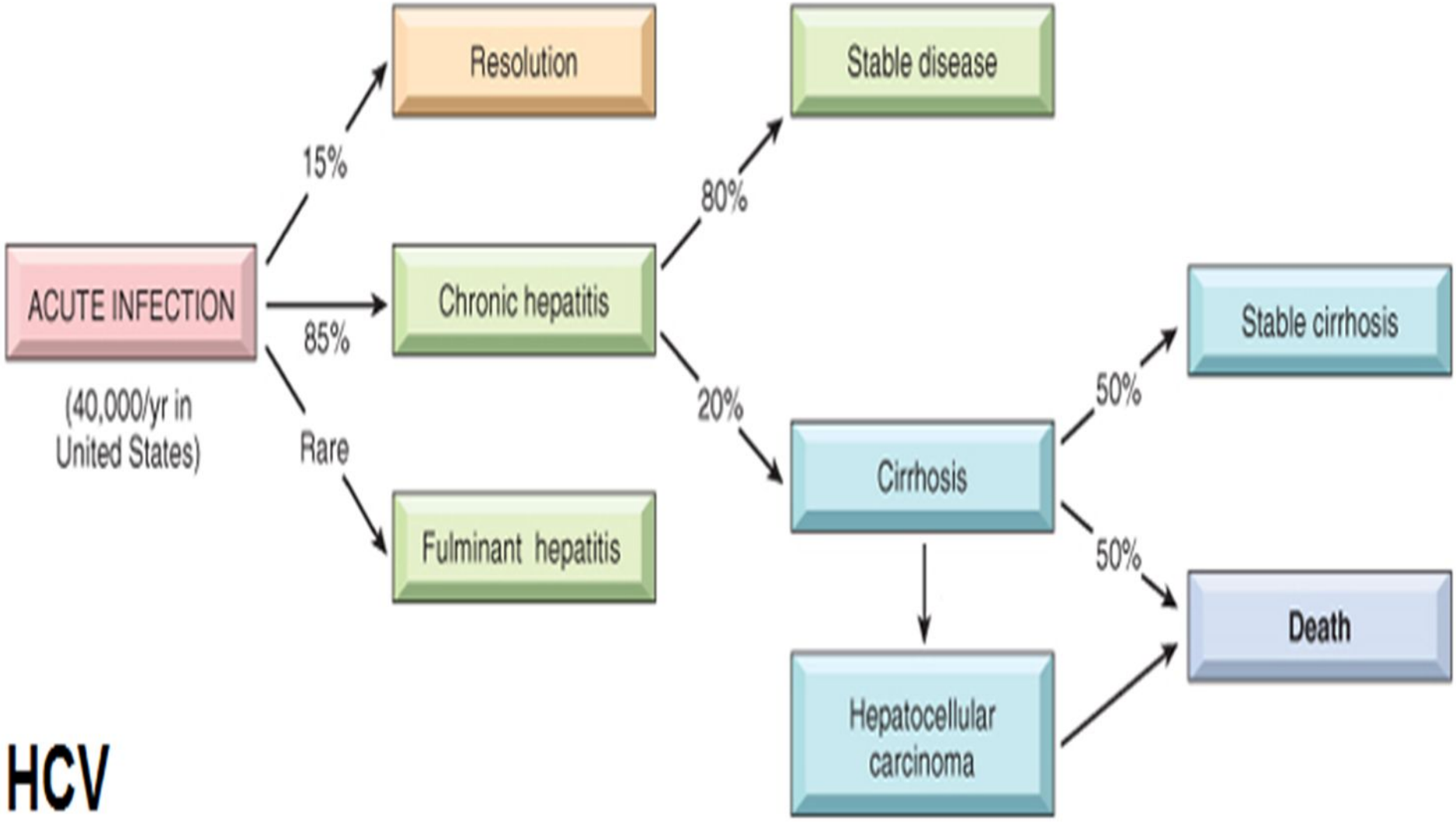
ACUTE INFECTION
(40,000/yr in United States)
15%
85%
Rare
Resolution
Chronic hepatitis
Fulminant hepatitis
80%
20%
Stable disease
Cirrhosis
Hepatocellular carcinoma
50%
50%
Stable cirrhosis
Death

HCV

Serum markers

- **Acute phase**
- HCV RNA is detected in blood for 1 to 3 weeks.
- This is accompanied by elevations in serum aminotransferase.

- Anti-HCV antibodies:
- Develop within weeks to a few months
- They do not confer effective immunity .

HCV

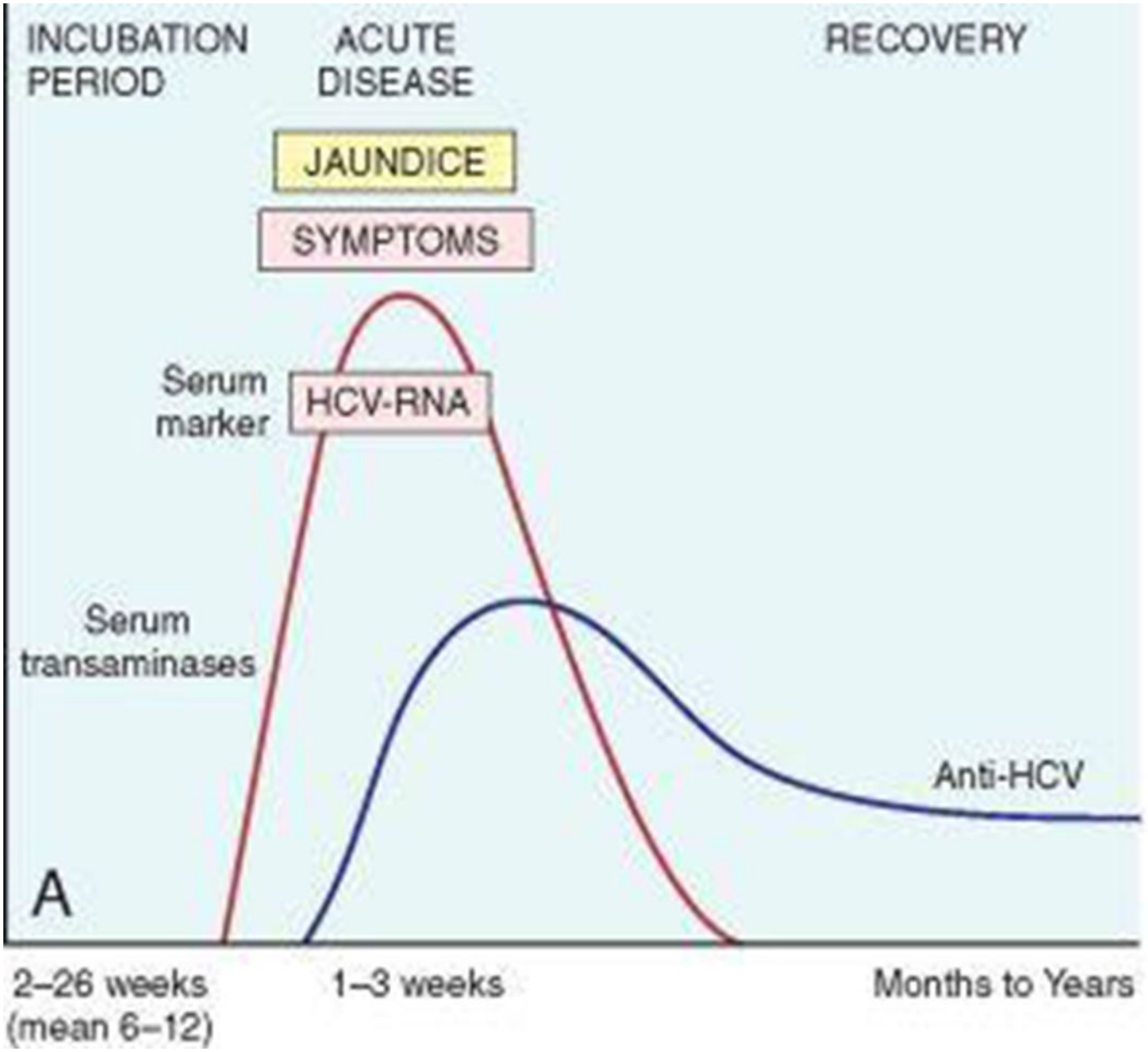
INCUBATION PERIOD
ACUTE DISEASE
RECOVERY
JAUNDICE
SYMPTOMS
Serum marker
HCV-RNA
Serum transaminases
Anti-HCV
A
2–26 weeks (mean 6–12)
1–3 weeks
Months to Years

Serum markers

- **Chronic (persistent) infection:**

- Circulating HCV-RNA is detectable
- Aminotransferases show fluctuating levels (reflecting bouts of hepatocytes necrosis)

Hepatitis D Virus

- Hepatitis delta virus (HDV)
- Type of virus:
  - Circular ssRNA with defective replication
  - Needs to be encapsulated by HBsAg.
- Virus family: Deltaviridae family
- Incubation period: Same as HBV
- Mode of transmission:
  - Parentral (drug addicts & blood transfusion)

Clinical disease

Acute coinfection	Superinfection
Exposure to serum containing both HDV and HBV	Infection of a chronic carrier of HBV with a new inoculum of HDV
Most individuals can clear the viruses and recover completely	Most individuals shows an acceleration of hepatitis: ❑More severe hepatitis ❑More progression to chronic hepatitis & cirrhosis
Detection of IgM against both HDV Ag and HBcAg (denoting new infection with HBV).	HBsAg is present in serum Anti-HDV antibodies (IgM and IgG) persist in low titer for months

Hepatitis E Virus (HEV)

- HEV is endemic in India
- Epidemic & sporadic cases have been reported in other sites

- Type of virus: non-enveloped ssRNA
- Virus family: Calicivirus
- Incubation period: 2-8 weeks
- Mode of transmission: feco-oral (waterborne infection)

Clinical disease

- In most cases, the disease is self-limited
- NO chronic liver disease or persistent viremia.
- A characteristic feature is the high mortality rate among pregnant women ~ 20%.

- HEV Ag can be identified in the hepatocytes.
- Virus can be detected in stools.
- Anti-HEV IgM and IgG antibodies are detectable in serum.

Clinical Features

- **Clinical syndromes of hepatitis viruses:**
  - Asymptomatic acute infection
  - Acute hepatitis: anicteric or icteric
  - Chronic hepatitis ± progression to cirrhosis
  - Chronic carrier state
  - Fulminant hepatitis

  - Serologic studies are critical for the diagnosis of viral hepatitis & identification of virus types.

Asymptomatic Infection

- Incidentally discovered
- Minimally elevated serum aminotransferases
- Serological evidence of the disease (the presence of antiviral antibodies).

Acute Viral Hepatitis

- Any one of the hepatotropic viruses
- Acute HCV can be easily missed
- Divided into four phases:
- (1) an incubation period,
- (2) a symptomatic preicteric phase,
- (3) a symptomatic icteric phase (with jaundice and scleral icterus), and
- (4) convalescence.
- Elevated serum aminotransferase levels

Chronic Hepatitis

- Symptomatic, biochemical, or serologic evidence of continuing or relapsing hepatic disease for more than 6 months
- With histologically documented inflammation and necrosis.
- Fluctuating levels of serum aminotransferases
- May or may not progress to cirrhosis

The Carrier State

- A "carrier" is an individual without manifest symptoms who harbors and can transmit an organism.

- In HBV, HDV, HCV
- Symptoms free
- Persistently normal ALT & AST
- Absence of significant inflammation and necrosis on liver biopsy.

Fulminant Hepatitis

- In very small proportion of patients with acute hepatitis A, B, or E
-
- Acute liver failure, resulting from submassive or massive hepatic necrosis.

Autoimmune hepatitis

- Clinical presentation:
- Mainly as a syndrome of chronic hepatitis
- May present as acute or fulminant hepatitis

- The histologic features:
- Indistinguishable from chronic viral hepatitis;
- Usually severe hepatitis
- Prominent hepatitic rosettes
- Plasma cells in the infiltrate

Autoimmune hepatitis

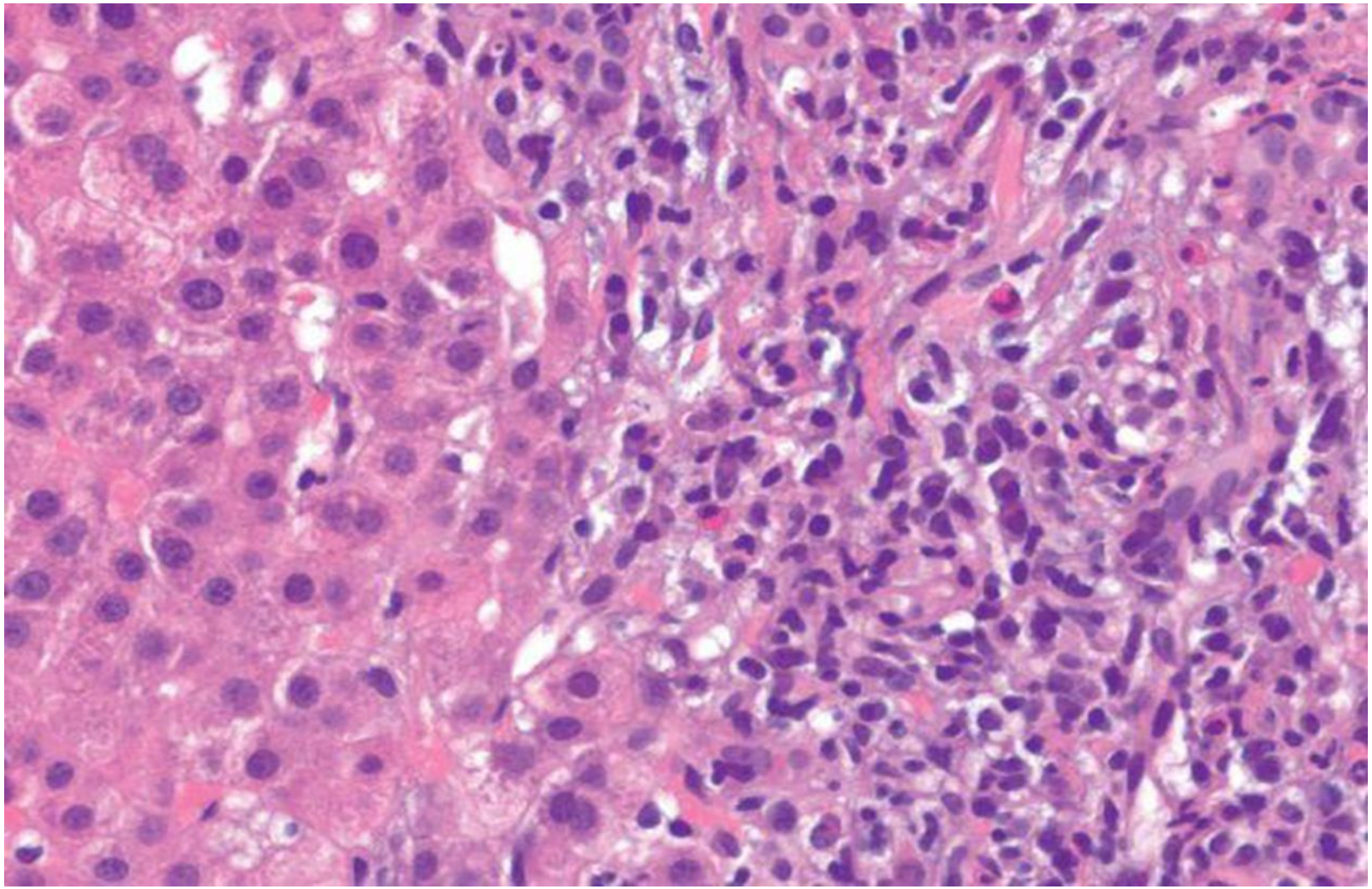

General features

- Female predominance (70%)
- Absence of serologic markers of a viral infection
- Elevated serum IgG (>2.5 g/dL)
- High titers of autoantibodies in 80% of cases.
- The presence of other forms of autoimmune diseases in 60% of patients, including rheumatoid arthritis, thyroiditis, Sjögren syndrome, and ulcerative colitis.

Clinical subtypes

- **Type 1:**

Anti-smooth muscle antibody (ASMA) & antinuclear antibody (ANA) positive
Teenager girls or ages 45-70 years
10% have other autoimmune disorders

- **Type 2:**

Anti-liver-kidney-microsomal antibody (LKMA) positive
More common in children
Often presents with acute or fulminant hepatitis
17% have other autoimmune disorders

- **Type 3:**

25% have only anti-soluble liver antigen antibody (anti-SLA)
Negative for ANA and anti-(LKM) antibody
75% have ASMA
Usually women, mean age 37 years
Usually no systemic autoimmune manifestations

Steatosis

- Definition:

"Accumulation of fat droplets within hepatocytes"

Microvesicular steatosis	Macrovesicular steatosis
Multiple tiny droplets that do not displace the nucleus	A single large droplet that displaces the nucleus
❑Alcoholic liver disease ❑Reye syndrome ❑Acute fatty liver of pregnancy ❑Drugs: tetracycline, ethanol, amiodarone, salicylate, valproate	Alcoholic liver disease❑ Non-alcoholic fatty liver ❑ disease (NAFLD) Drugs: methotrexate, CCL4, ethanol, TPN Corticosteroids

Macrovesicular steatosis

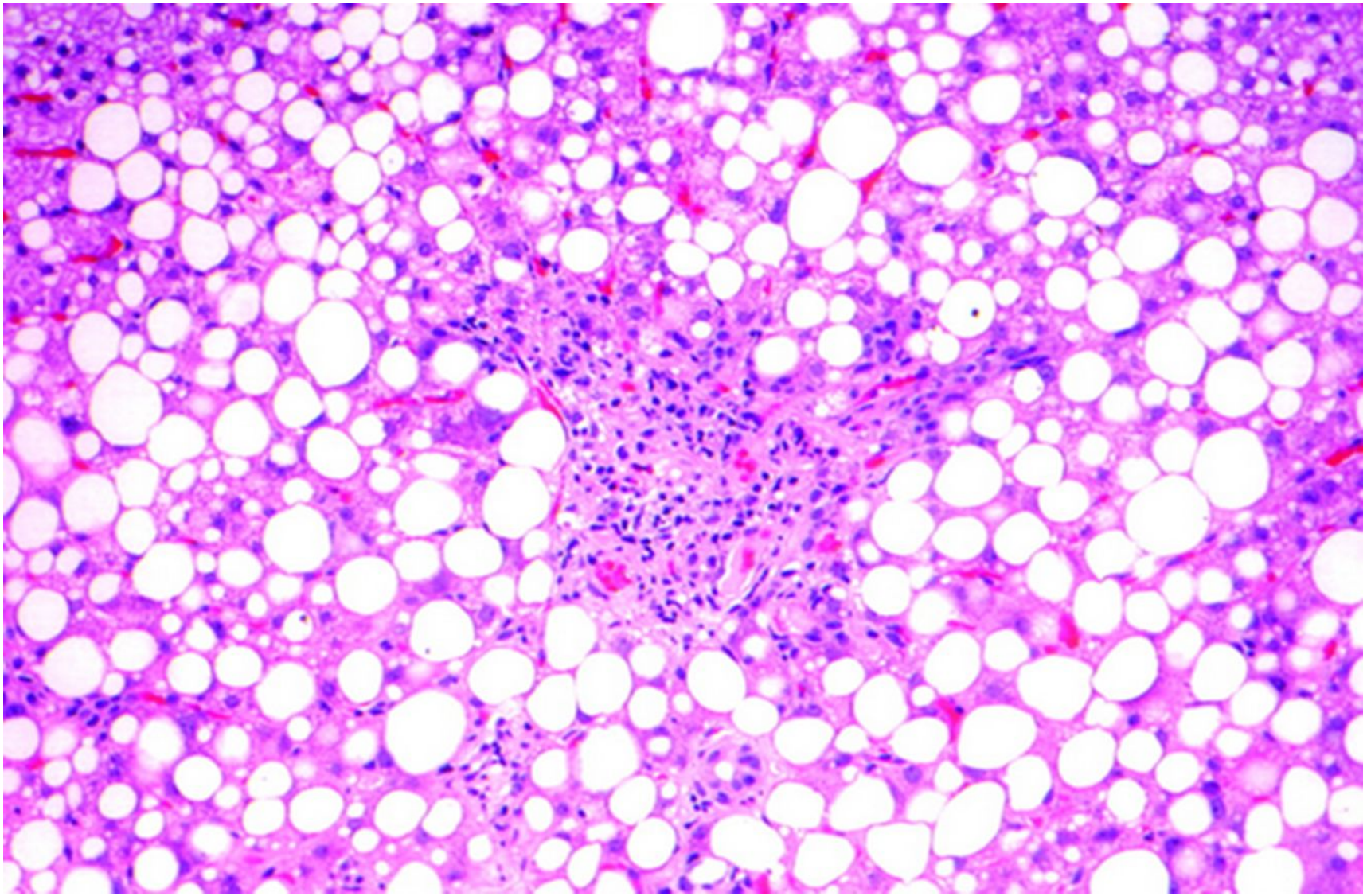

Microvesicular steatosis

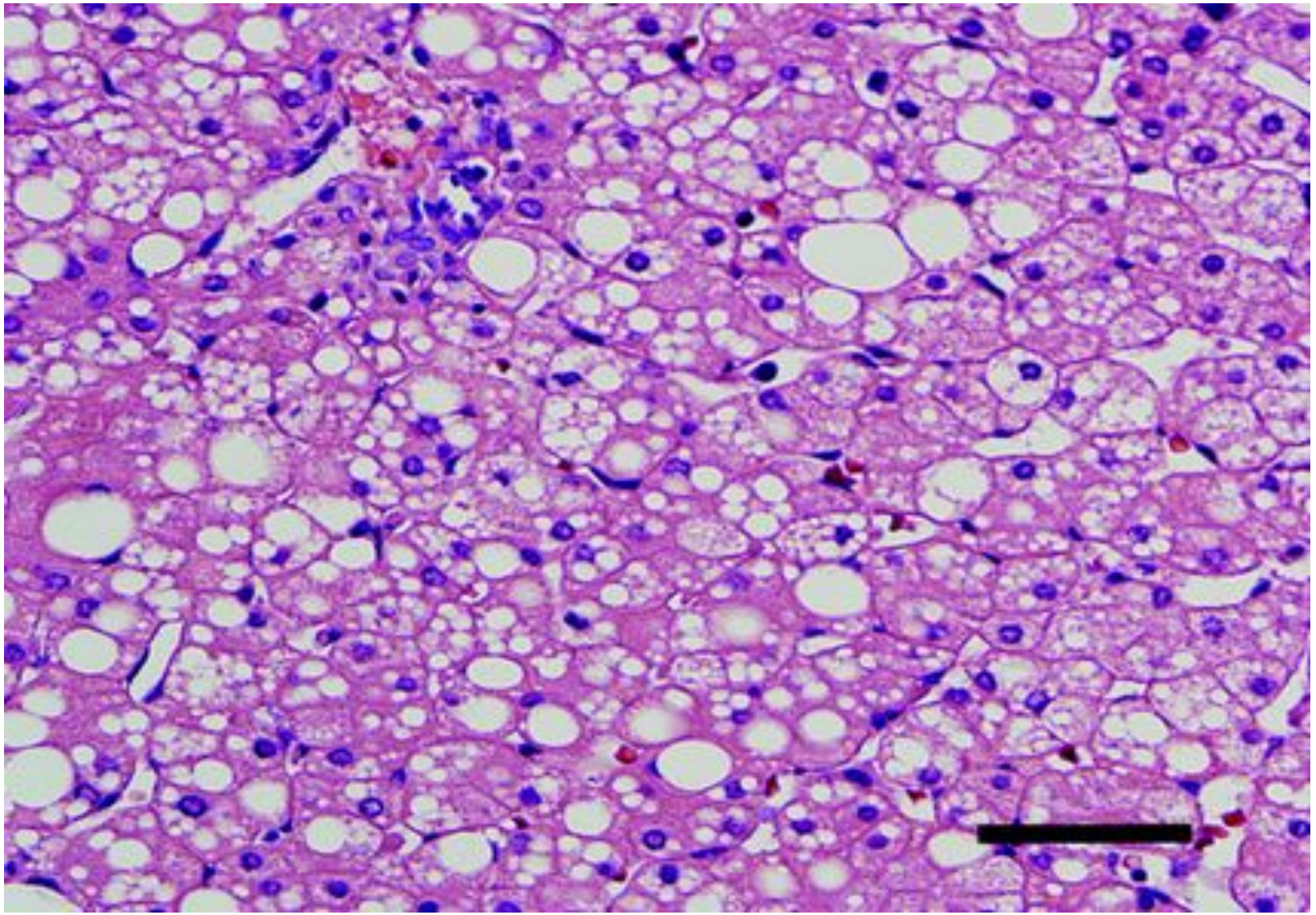

Alcoholic Liver Disease

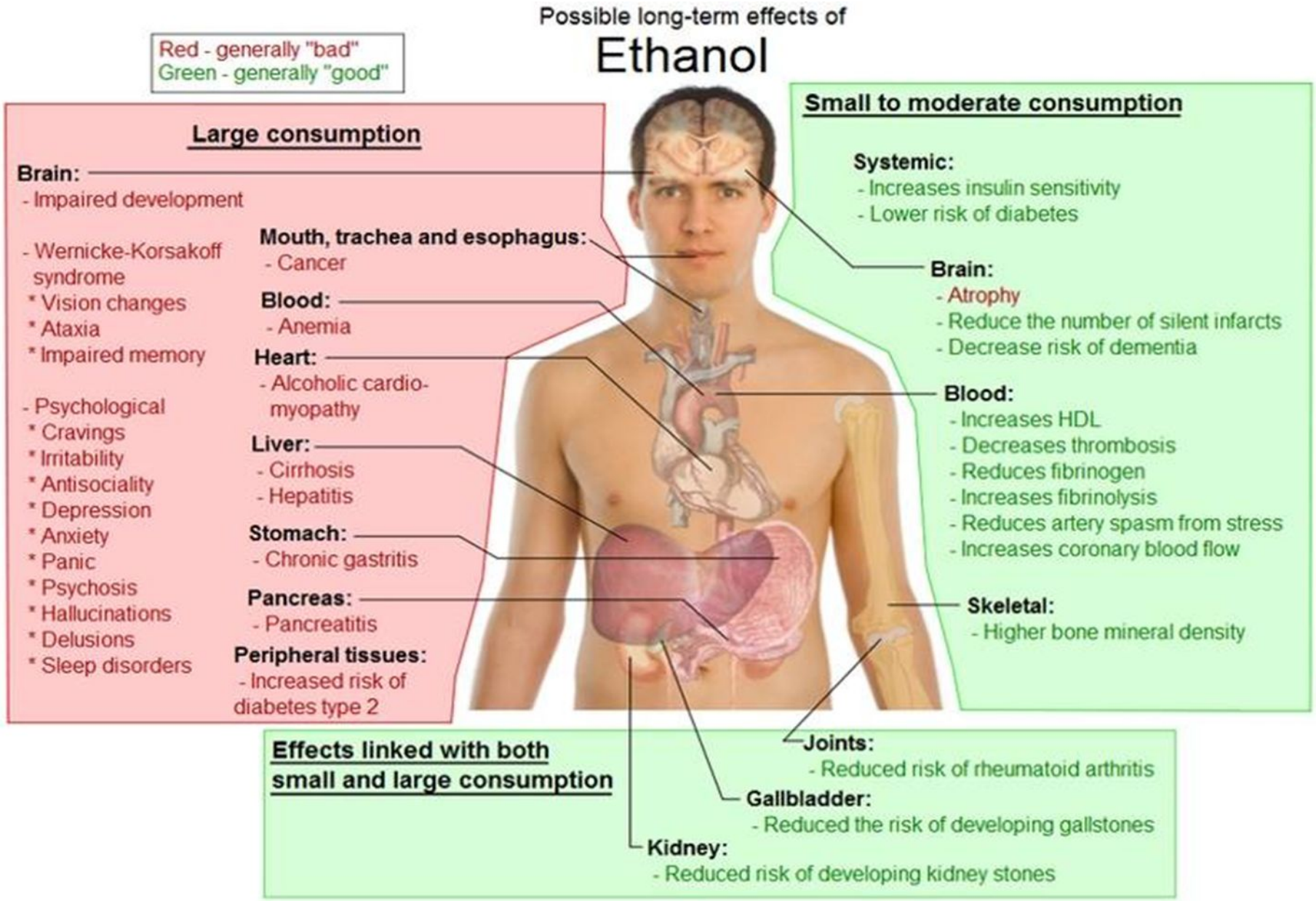

Alcoholic Liver Disease

- More than 60% of chronic liver disease in most Western countries and 40% to 50% of deaths due to cirrhosis.

Alcoholic liver disease
Hepatic steatosis (fatty liver) Alcoholic hepatitis Cirrhosis

Hepatic Steatosis (Fatty Liver)

- Gross appearance:
- Large (≤4-6 kg), soft, yellow, and greasy
- Steatosis:
  - Mainly microvesicular steatosis
  - With chronic intake of alcohol, large clear macrovesicular globules appear
- Initially centrilobular, but in severe cases it may involve the entire lobule
- Completely reversible if there is abstention

Fatty liver (steatosis)



Alcoholic steatohepatitis (ASH)

- **Neutrophil Infiltration**
- Neutrophils accumulate around degenerating hepatocytes, particularly those with Mallory bodies

- **Fibrosis**
- Perisinusoidal (chichen wire) & perivenular fibrosis
- Occasionally periportal fibrosis

- ± Cholestasis and mild deposition of hemosiderin in hepatocytes and Kupffer cells.

Alcoholic Cirrhosis

- The final irreversible form of alcoholic liver disease
- Usually develop insidiously & slowly
- May develop more rapidly in the setting of alcoholic hepatitis, within 1 to 2 years

- Mainly micronodular cirrhosis with scattered large nodules (hobnail appearance)

Alcoholic cirrhosis

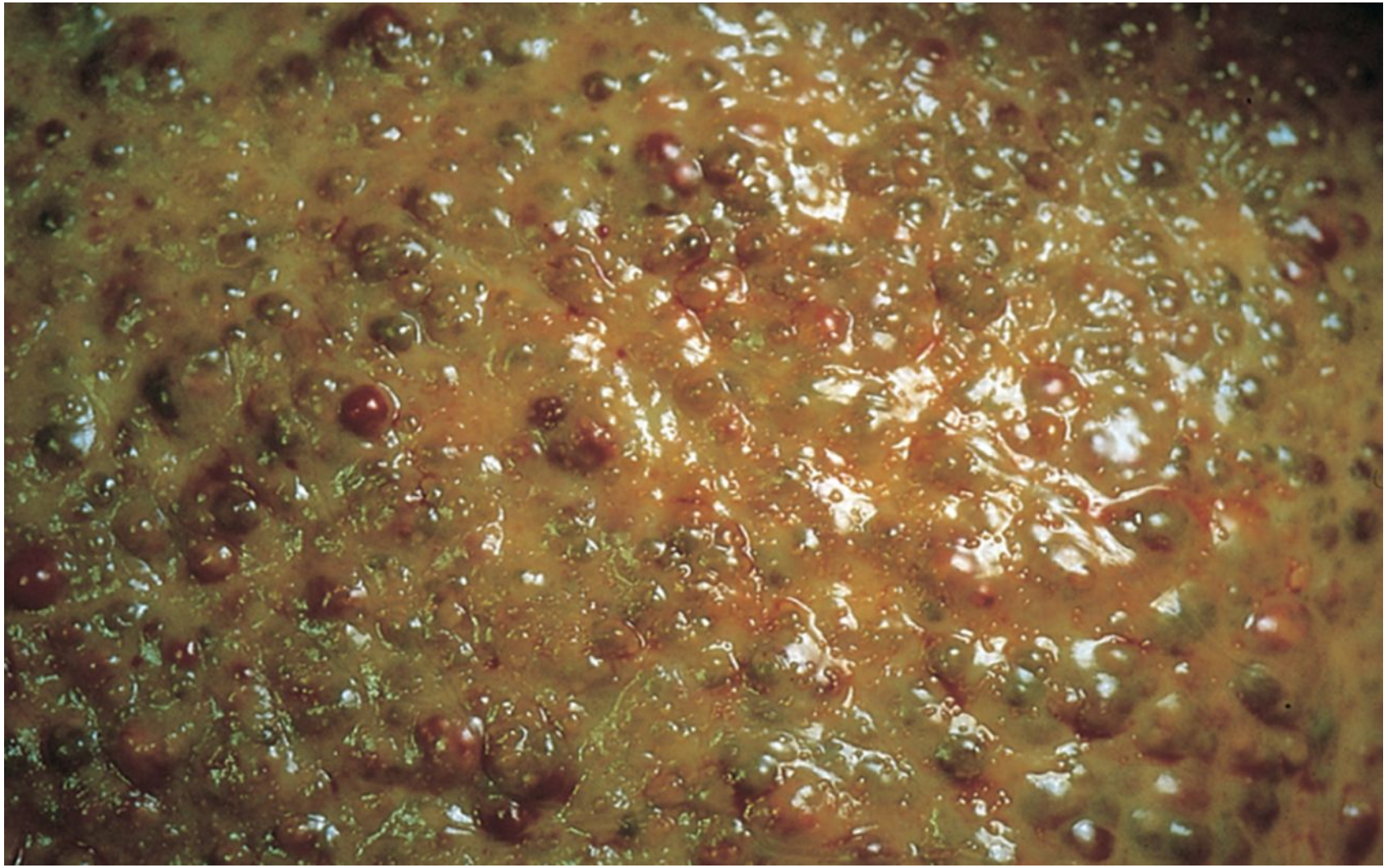

Causes of death

- Hepatic failure
- A massive gastrointestinal hemorrhage
- An intercurrent infection
- Hepatorenal syndrome after a bout of alcoholic hepatitis
- Hepatocellular carcinoma in 3% - 6% of cases.

Nonalcoholic fatty liver disease (NAFLD)

- The most common metabolic liver disease

A condition in which fatty liver and liver disease develop in individuals who do not drink alcohol.

NAFLD
Steatosis (fatty liver) Nonalcoholic steatohepatitis (NASH) Cirrhosis: NAFLD is a significant contributor to cryptogenic cirrhosis

Pathogenesis

- Most consistently associated with *insulin resistance.*

- **Other key associated variables are:**
- Type 2 diabetes (or family history)
- Obesity
- Dyslipidemia
  - Hypertriglyceridemia, low HDL cholesterol, high LDL cholesterol
- Metabolic syndrome
  - insulin resistance, HTN, obesity
- Sudden weight loss as in jejunoileal bypass surgery

NASH

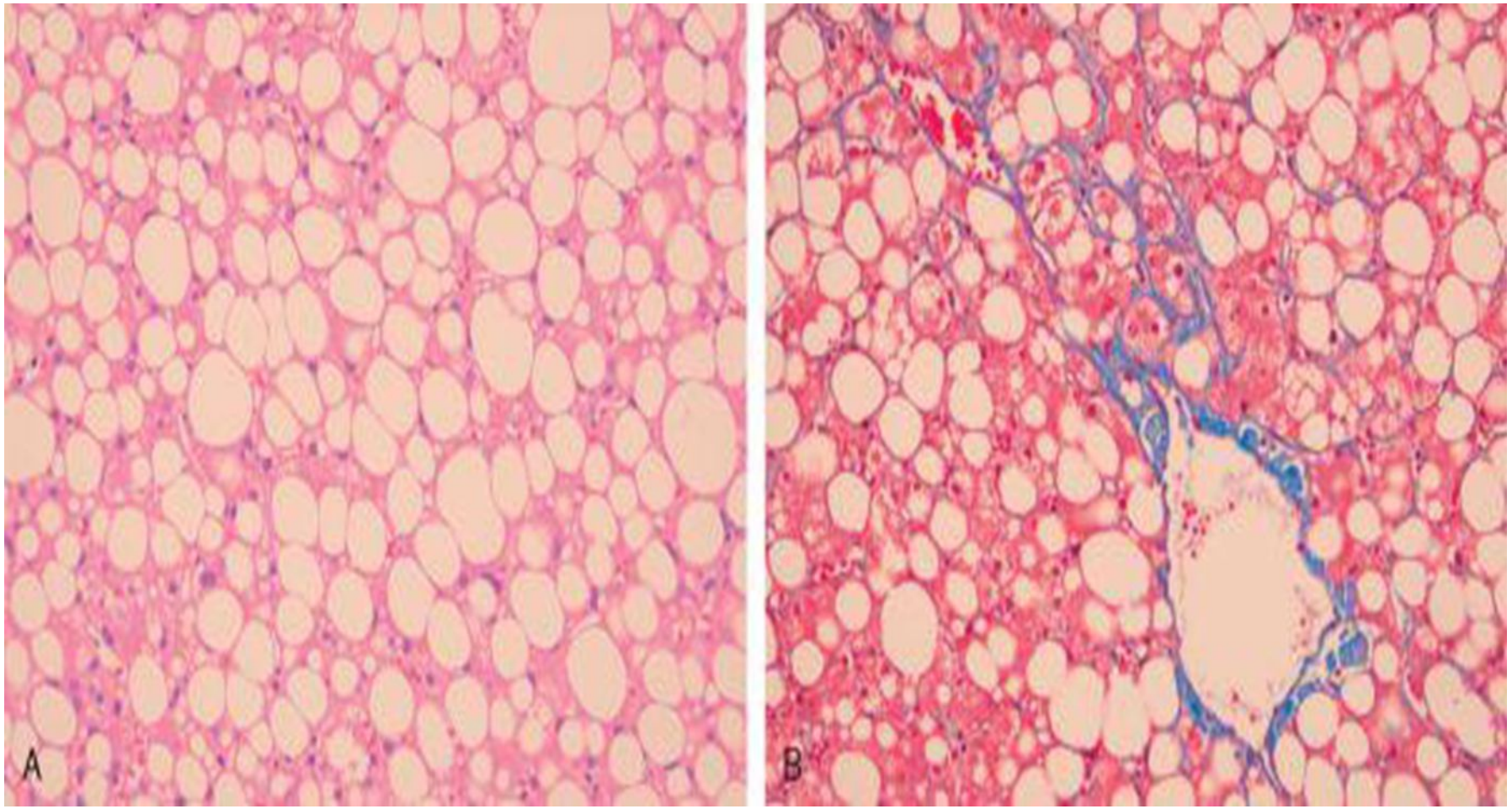

A, Liver tissue with macro & microvesicular steatosis (H&E stain).
B, NASH, showing perivenular fibrosis and perisinusoidal fibrosis

Inherited Metabolic Diseases

- Inborn errors of metabolism:
- Hereditary hemochromatosis
- Wilson disease
- α_1-antitrypsin deficiency

Hereditary hemochromatosis

- Genetic disorders characterized by the excessive accumulation of body iron, most of which is deposited in the parenchymal organs

- Fully developed cases show

(1) Cirrhosis (all patients),

(2) Diabetes mellitus (75% to 80% of patients)

(3) Skin pigmentation (75% to 80%)

Genetics

At least four genetic variants

- The most common form is an AR disease of adult onset due to mutations in the *HFE* gene
- *HFE* gene is located on chromosome 6p
- The most common mutation is a tyrosine substitution for cysteine at aa 282 (C282Y)

Pathogenesis

- HFE gene regulate the levels of *hepcidin*
- When hepcidin levels are reduced there is increased intestinal iron absorption
- Net iron accumulation is 0.5 to 1.0 gm/year

- Hereditary hemochromatosis manifests typically after 20 gm of storage iron has accumulated.

Morphology

- The morphologic changes in hereditary hemochromatosis are characterized by:

- (1) The **deposition of hemosiderin** in the following organs: liver, pancreas, myocardium, pituitary, adrenal, thyroid and parathyroid glands, joints & skin
- (2) **Cirrhosis**
- (3) **Pancreatic fibrosis**

Cirrhosis

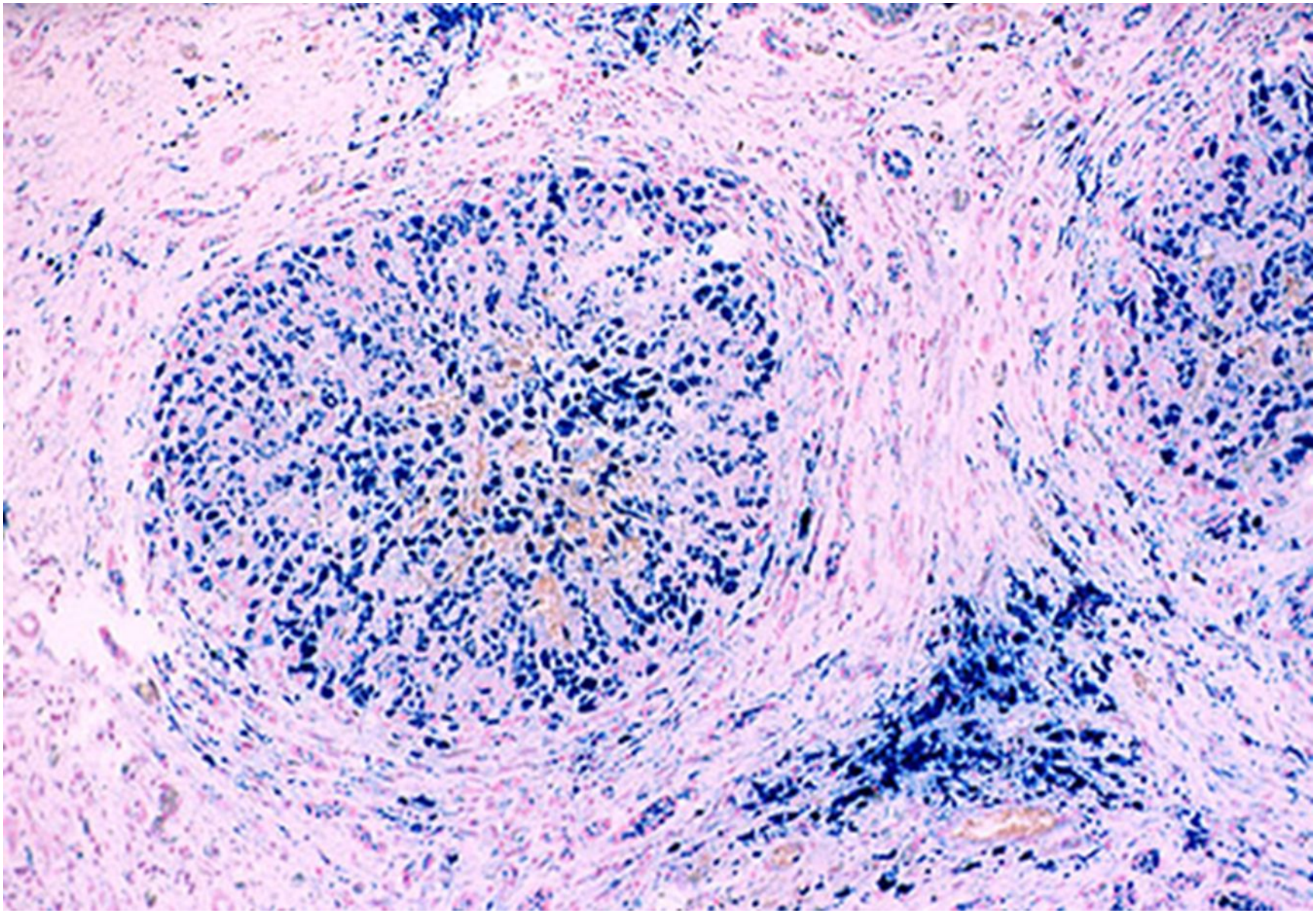

Morphology

- **The pancreas:**

Intensely pigmented, Hemosiderin in the acinar and the islet cells

Diffuse interstitial fibrosis & some parenchymal atrophy.

- **The heart:**

Enlarged & brown

Hemosiderin granules within the myocardial fibers.

A delicate interstitial fibrosis

- The **testes**:

Small and atrophic but are usually not discolored.

- Skin pigmentation (slate-gray):

Mostly due to increased epidermal melanin production

Hemosiderin deposition in dermal macrophages and fibroblasts

- Joints:

Hemosiderin deposition in the synovial linings

Acute synovitis may develop

Excessive deposition of calcium pyrophosphate (pseudogout), damages the articular cartilage.

Clinical course

- Males to females ratio is 5 to 7 : 1), with slightly earlier clinical presentation in males
- **Symptoms & signs:**
- First appear in the 5th to 6th decades of life.
- Hepatomegaly, abdominal pain
- Skin pigmentation
- Impaired glucose homeostasis or frank DM.
- Arrhythmias, cardiomyopathy
- Atypical arthritis.

Clinical course

- The classic clinical triad of cirrhosis with hepatomegaly, skin pigmentation, and diabetes mellitus may not develop until late
- **Hepatocellular carcinoma (HCC)**
- 200-fold higher than in normal populations Treatment of iron overload does not remove the risk for development of HCC
- Causes of death:
- Cirrhosis, HCC, or cardiac disease.

Screening

A 25-year-old man presents with lethargy and increased skin pigmentation. Blood test reveal deranged liver function tests and impaired glucose tolerance. *Given the likely diagnosis of hemochromatosis, what is the most appropriate initial investigation strategy?*

A - Transferrin saturation + ferritin

B - Hematocrit + ferritin

C - Liver biopsy with Perl's stain

D - Serum iron + ferritin

E - Serum iron + hematocrit

Hemosiderosis

Acquired (secondary iron overload)
Parentral iron overload Multiple transfusions Ineffective erythropoiesis β-thalassemia Sideroblastic anemia Increased iron intake Bantu siderosis Chronic liver disease Chronic alcoholic liver disease
Morphology Iron accumulation starts in kupffer cells

- Screening for haemochromatosis
- general population: transferrin saturation > ferritin
- family members: HFE genetic testing
- **Typical iron study profile in patient with haemochromatosis**

1. transferrin saturation > 55% in men or > 50% in women
2. raised ferritin (e.g. > 500 ug/l) and iron
3. low TIBC

Questions have previously been asked regarding which features are reversible with treatment:

Reversible complications	Irreversible complications
• Cardiomyopathy • Skin pigmentation	• Liver cirrhosis** • Diabetes mellitus • Hypogonadotrophic hypogonadism • Arthropathy

Wilson Disease
Hepatolenticular degeneration

- An AR disorder of copper metabolism
- Characterized by the accumulation of toxic levels of copper in many tissues and organs, principally the liver, brain, and eye.

- The genetic defect:
- Mutation in *ATP7B* gene on 13q
- It encodes an ATPase metal ion transporter that localizes to the Golgi region of hepatocytes

Pathogenesis

- Defective function of ATP7B leads to:
- Absorbed copper fails to enter the circulation in the form of ceruloplasmin
- Failure to excrete copper into bile, the primary route for copper elimination

- Copper accumulation in the liver causing toxic liver injury mainly by free radicals

Pathogenesis

- Usually by 5 years of age, free Copper spills over into the circulation leading to:

- Hemolysis
- Pathologic changes at other sites as brain, cornea, kidneys, bones, joints, & parathyroids

Liver morphology

- **Mild to moderate fatty change**
- An **acute hepatitis** mimic acute viral hepatitis.
- A **chronic hepatitis**
  - Mimic chronic viral hepatitis of viral
  - Clues: fatty change, vacuolated (glycogenated) nuclei, and Mallory bodies
  - May progress to **cirrhosis**
- **Massive liver necrosis** is rare

Morphology

- **The brain:**
- Toxic injury of the basal ganglia, particularly the putamen lead to atrophy and cavitation.

- **Eye lesions (Kayser-Fleischer rings):**
- Green to brown deposits of copper in the limbus of the cornea.

Kayser-Fleischer ring

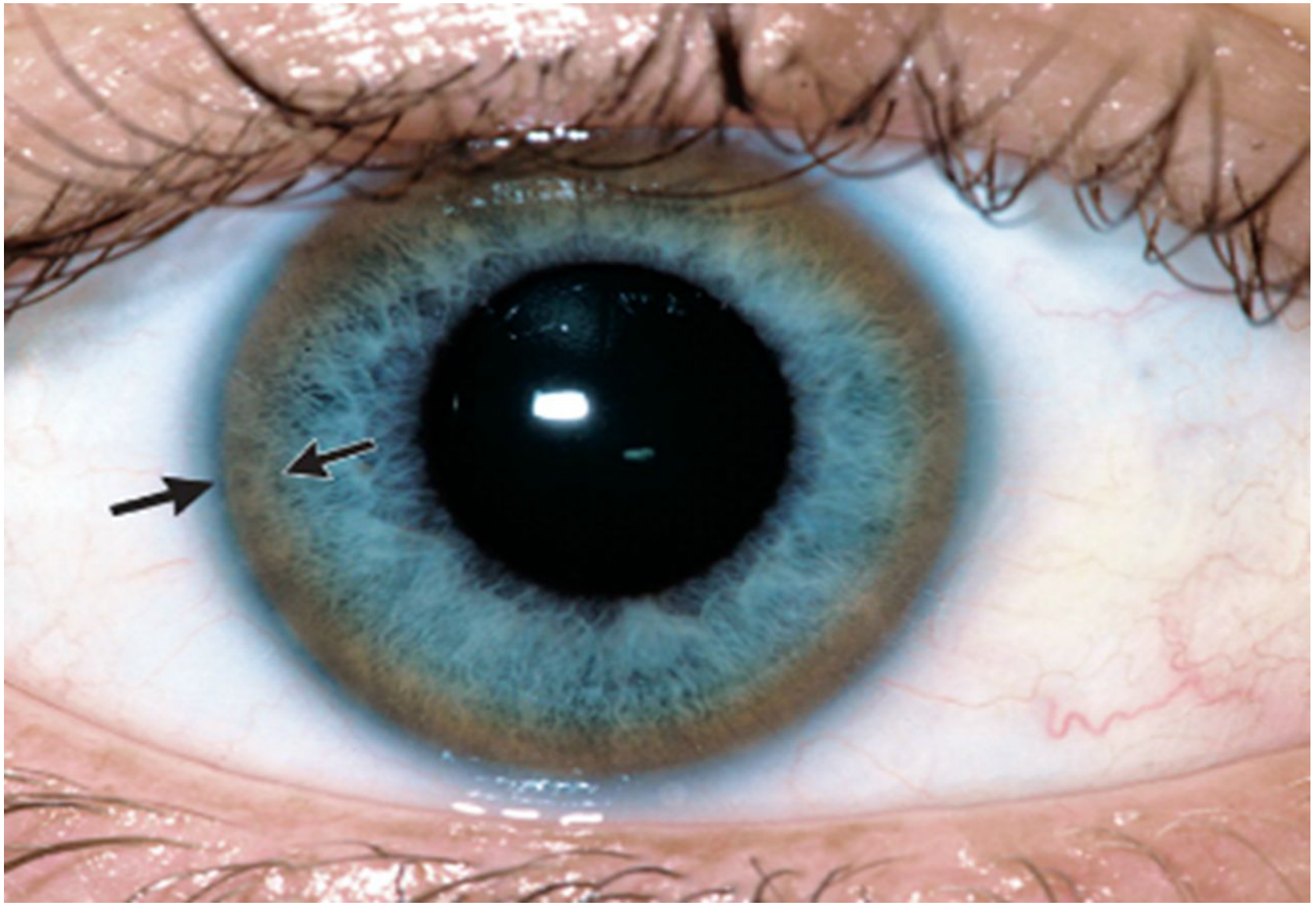

Clinical Features

- The age at onset and the clinical presentation are extremely variable
- The disorder rarely manifests before 6 years
- The most common presentation is acute or chronic liver disease.
- Neuropsychiatric manifestations:
- Mild behavioral changes, psychosis, or a Parkinson disease-like syndrome

Diagnosis

- Demonstration of Kayser-Fleischer rings

- Biochemical diagnosis:

Low serum ceruloplasmin
Increase in hepatic copper content
Increase in urinary excretion of copper

- Treatment:

Copper chelation therapy (D-penicillamine)
Trienteine
Zinc

α_1-Antitrypsin (AAT) Deficiency

- An autosomal recessive disorder marked by abnormally low serum levels of α_1-Antitrypsin
- AAT is a protease inhibitor, it inhibits particularly neutrophil elastase

- AAT deficiency leads to pulmonary emphysema.
- All individuals with the *PiZZ* genotype accumulate AAT in the endoplasmic reticulum of liver
- Only 8% to 20% develop significant liver damage

Morphology

- Hepatocytes contain round to oval cytoplasmic **globular inclusions** of AAT
- Strongly positive for PAS stain
- By E/M, they lie within smooth and sometimes rough endoplasmic reticulum.

α_1-Antitrypsin deficiency

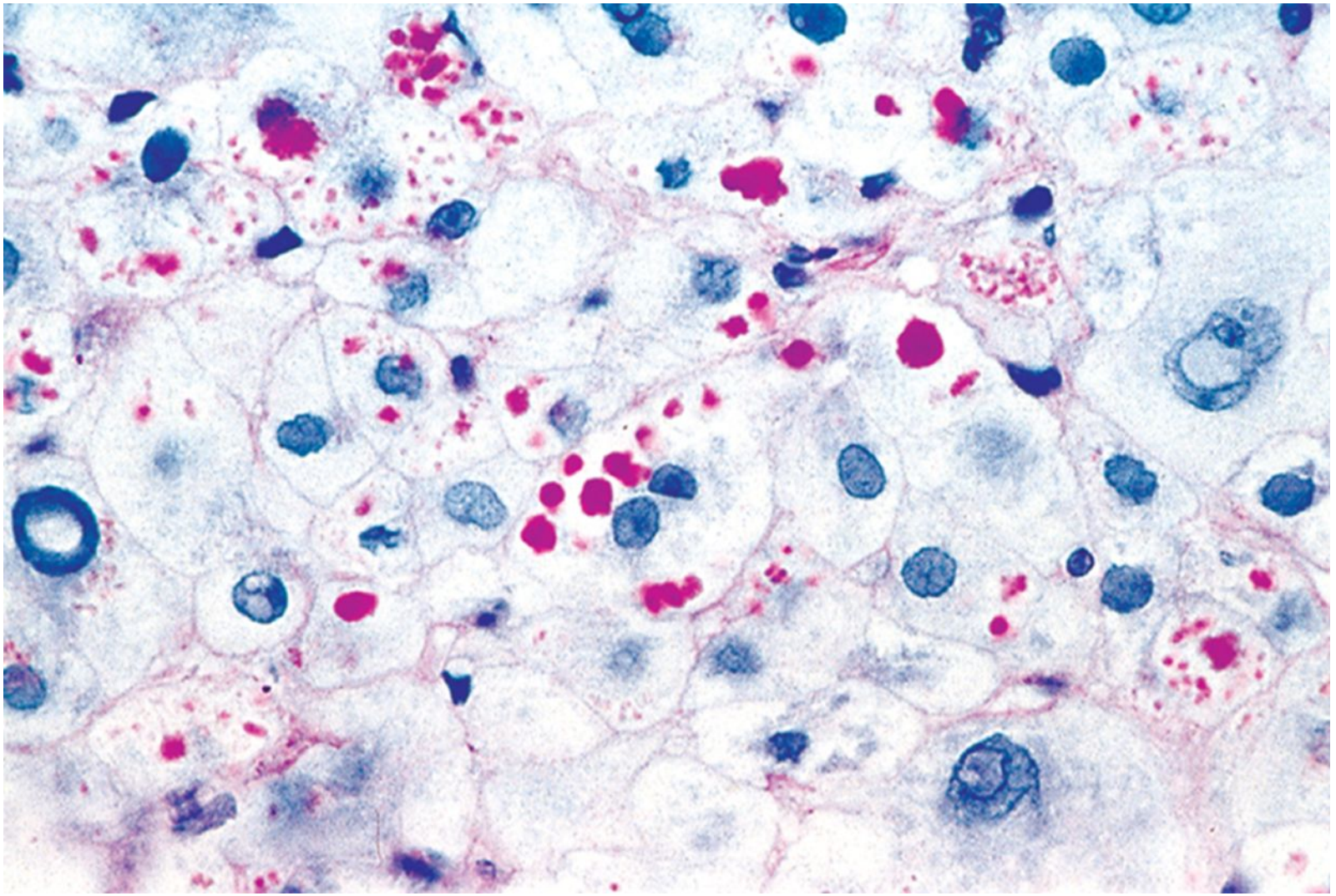

Morphology

- Range of hepatic injury:
- Neonatal cholestasis; c**holestasis** with **hepatocyte necrosis** in newborns
- C**hildhood cirrhosis**
- Chronic hepatitis or cirrhosis late in life.
- HCC develops in 2% to 3% of *PiZZ* adults, usually, but not always, in the setting of cirrhosis

Neonatal Cholestasis

- Prolonged conjugated hyperbilirubinemia in the newborn.

- **Clinical presentation:**
- Jaundice, dark urine & light stools
- Hepatomegaly.
- Variable degrees of hepatic dysfunction

- It is important to differentiate extrahepatic biliary atresia from other causes

Major causes of neonatal hepatitis	
Bile duct obstruction	**Extrahepatic biliary atresia (EHBA) (20%)**
	Neonatal infection Cytomegalovirus Bacterial sepsis Urinary tract infection Syphilis
Neonatal hepatitis •Not a specific entity •The disorders are not necessarily inflammatory	**Toxic** Drugs Parenteral nutrition
	Metabolic disease Tyrosinemia Galactosemia α_1-Antitrypsin deficiency Cystic fibrosis
	Miscellaneous Shock/hypoperfusion Indian childhood cirrhosis Alagille syndrome (paucity of bile ducts)
	Idiopathic neonatal hepatitis (50%)

Diseases of the intrahepatic biliary tract

- Primary biliary cirrhosis (PBC)
- Destruction of intrahepatic bile ducts

- Primary sclerosing cholangitis (PSC)
- Involves extrahepatic and large intrahepatic bile ducts

Primary Biliary Cirrhosis

- A chronic progressive cholestatic liver disease
- Characterized by nonsuppurative destruction of small and medium-sized intrahepatic bile ducts, portal inflammation and scarring, and eventually cirrhosis late in the course.

Primary biliary cirrhosis

- Middle-aged women, peak incidence (40 – 50 y)
- > 90% have high titers of antimitochondrial antibodies (AMA) directed to specific domains of mitochondrial acid dehydrogenase enzymes
- Associated extrahepatic conditions include: Sjögren syndrome, scleroderma, thyroiditis, RA, Raynaud phenomenon, membranous glomerulonephritis, & celiac disease

Clinical picture

- Insidious onset, usually presenting as pruritus
- Jaundice develops late
- Hepatic failure over two or more decades

- LAB tests:
  - ⇑ Serum alkaline phosphatase
  - ⇑ cholesterol levels
  - Hyperbilirubinemia develops late

Primary Sclerosing Cholangitis

- A chronic cholestatic disorder
- Characterized by progressive fibrosis and destruction of extrahepatic and large intrahepatic bile ducts

Primary sclerosing cholangitis

- Common in association with IBD, particularly UC; UC present in 70% of patients with PSC, while PSC present in 4% of patients with UC

- P-ANCA is present in 80% of cases
- Age: 3rd to 5th decades
- Males to females ratio is 2 : 1.

Clinical picture

- Insidious onset
- Progressive fatigue, pruritus, and jaundice.
- Chronic liver disease late in the course
- PSC has a protracted course over years.
- Cholangiocarcinoma may develop in 10-15% of individuals, with a median time of 5 years from diagnosis.

Retrograde cholangiography

- The changes are patchy
- Retrograde cholangiography shows a characteristic "beaded appearance".



An ERCP image showing intra- and extrahepatic bile-duct strictures (thin arrow) and dilations (thick arrow)

Morphology of PBC

- **Early lesions:**
- Dense mononuclear inflammatory cell infiltrate in the portal tract
- Granulomatous inflammation
- **Florid duct lesion:** intraepithelial infiltration of lymphocytes and granuloma with destruction of intralobular ducts
- Ductular reaction; bile ductular proliferation

PBC

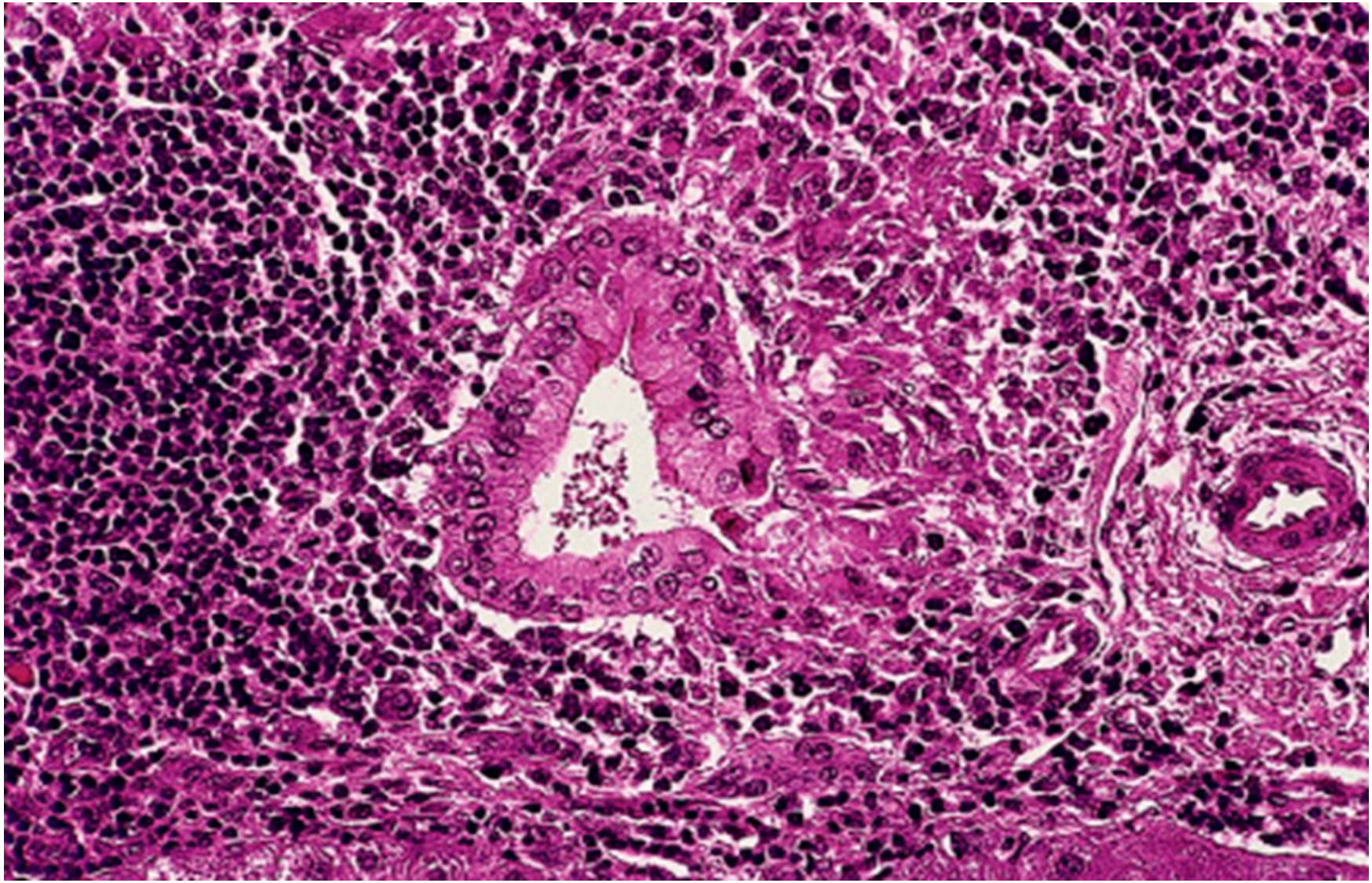

Morphology of PSC

- **Fibrosing cholangitis of bile ducts**:
  - The characteristic feature of **PSC**
  - Affected portal tracts show concentric periductal **onion-skin fibrosis** and lymphocytic infiltrate
- Progressive atrophy of the bile duct epithelium leads to obliteration of the lumen.
- In between, bile ducts are ectatic & inflamed
- Cholestasis & biliary cirrhosis

Primary sclerosing cholangitis

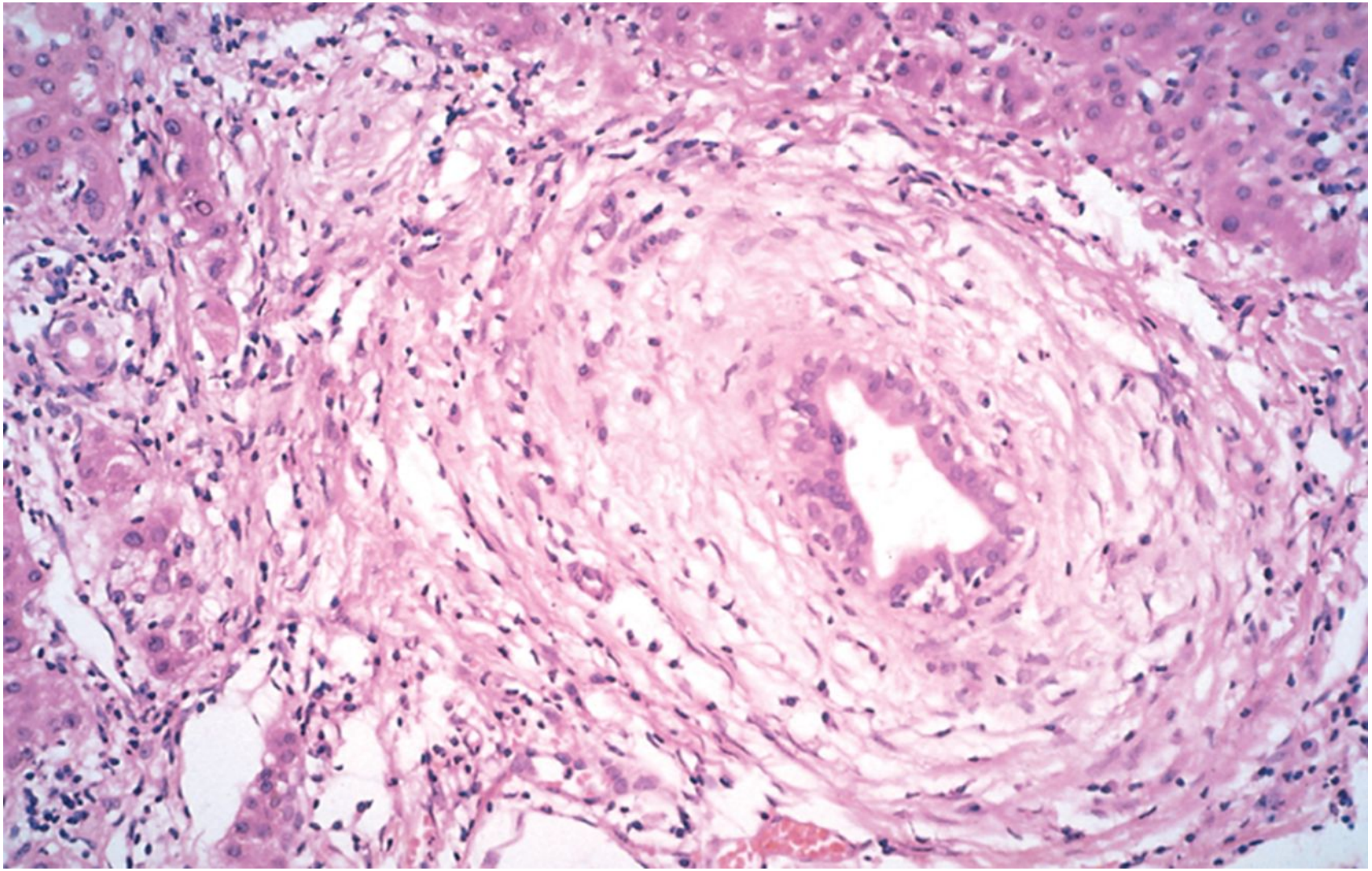

Main Features of Primary Biliary Cirrhosis and Primary Sclerosing Cholangitis

Parameter	Primary Biliary Cirrhosis	Primary Sclerosing Cholangitis
Age	Median age 50 years (30-70)	Median age 30 years
Gender	90% female	70% male
Clinical course	Progressive	Unpredictable but progressive
Associated conditions	Sjögren syndrome (70%)	Inflammatory bowel disease (70%)
	Scleroderma (5%)	Pancreatitis (≤25%)
	Thyroid disease (20%)	Idiopathic fibrosing diseases (retroperitoneal fibrosis)
Serology	95% AMA positive	0% to 5% AMA positive (low titer)
	20% ANA positive	6% ANA positive
	60% ANCA positive	82% ANCA positive
Radiology	Normal	Strictures and beading of large bile ducts; pruning of smaller ducts
Duct lesion	Florid duct lesion; loss of small ducts	Concentric periductal fibrosis; loss of small ducts

CIRCULATORY DISORDERS

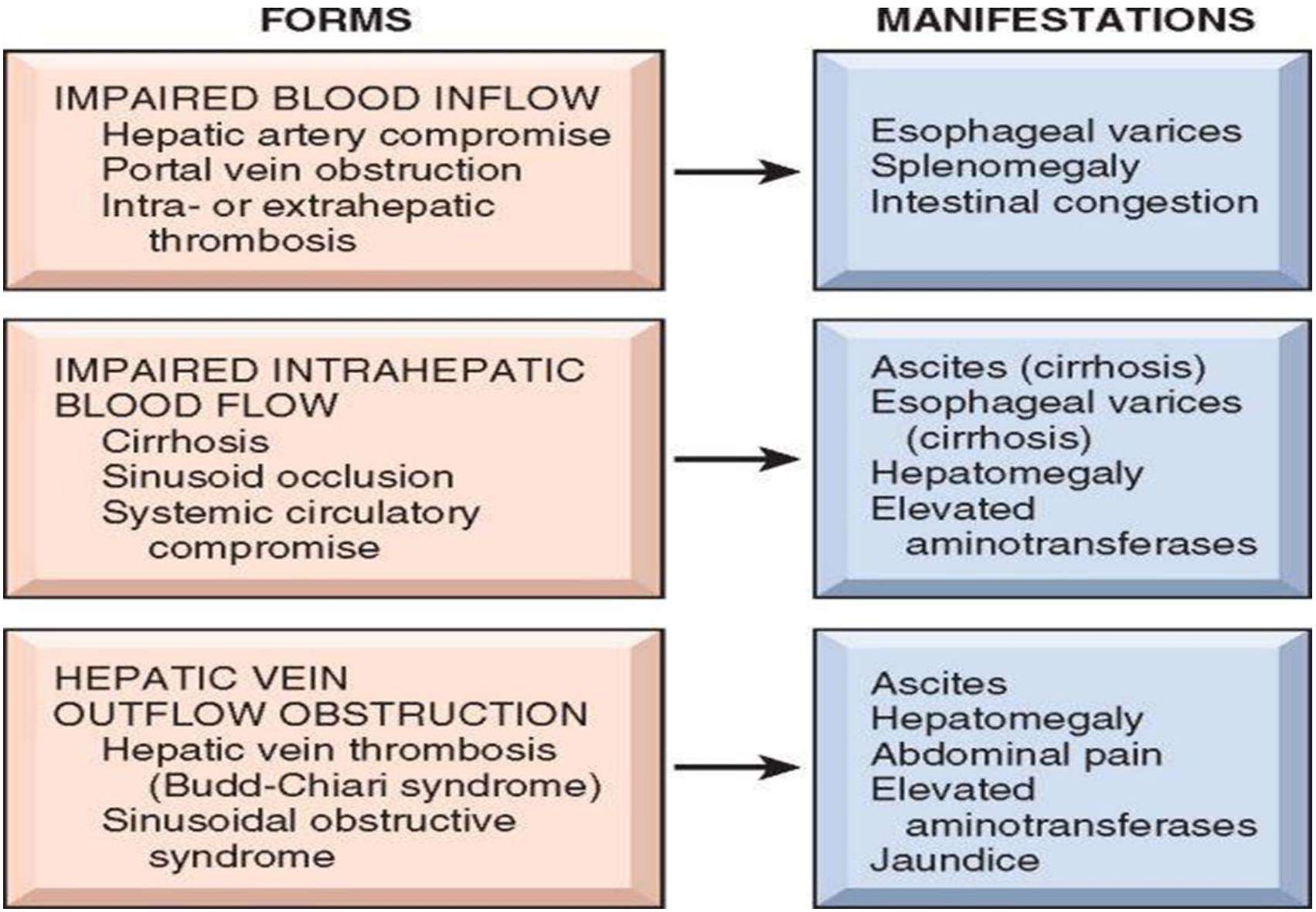

Budd-Chiari Syndrome

- Results from the thrombosis of two or more major hepatic veins

Causes	
Thrombotic states	Myeloproliferative disorders including PV Pregnancy & postpartum states The use of oral contraceptives Paroxysmal nocturnal hemoglobinuria Intra-abdominal cancers
Mechanical obstruction to blood outflow	Intrahepatic abscess Parasitic cyst
Obstruction of the IVC at the level of the hepatic veins by thrombus or tumor	
	Idiopathic (10%)

Morphology

- **Acute cases:**

- Grossly the liver is swollen, is red-purple, and has a tense capsule
- Microscopic appearance:
- Severe **centrilobular congestion and necrosis**
- **Chronic cases: Centrilobular fibrosis** develops
- The major veins may contain totally occlusive fresh thrombi, subtotal occlusion, or, in chronic cases organized adherent thrombi.

A 25-year-old woman develops deranged liver function tests following the introduction of a new drug. Alb 40, Bilirubin 46, ALT 576, ALP 95, yGT 150. Which of the following drugs is the most likely cause?

A - Oral contraceptive pill

B - Sodium valproate

C - Flucloxacillin

D - Chlorpromazine

E - Tetracycline

Answer & Comments

Answer: B - Sodium valproate The liver function tests suggest a hepatitis rather than cholestasis. Sodium valproate may be associated with such a picture

Drug-induced liver disease

Drug-induced liver disease is generally divided into hepatocellular, cholestatic or mixed. There is however considerable overlap, with some drugs causing a range of changes to the liver

The following drugs tend to cause a hepatocellular picture:

- paracetamol
- sodium valproate, phenytoin
- MAOIs
- halothane
- anti-tuberculosis: isoniazid, rifampicin, pyrazinamide
- statins
- alcohol
- amiodarone
- methyldopa

The following drugs tend to cause cholestasis (+/- hepatitis):

- oral contraceptive pill
- antibiotics: flucloxacillin, co-amoxiclav, erythromycin*, nitrofurantoin
- anabolic steroids, testosterones
- phenothiazines: chlorpromazine, prochlorperazine
- sulphonylureas
- fibrates
- rare reported causes: nifedipine

Liver cirrhosis

- methotrexate
- methyldopa
- amiodarone

Tumors and tumor like lesions of liver

Hepatic nodules
Nodular regenerative hyperplasia
Focal nodular hyperplasia
Macroregenerative nodules

Epithelial neoplasms
Benign
- Liver cell adenoma

Malignant
- Liver cell carcinoma
- Cholangiocarcinoma
- Tumors of mixed cell types
- Hepatoblastoma

Epithelial abnormalities
Liver cell dysplasia (≤1mm)
- Large cell type
- Small cell type

Dysplastic nodules (> 1mm)
- Low-grade
- High-grade

Non-epithelial neoplasms
Benign
- Hemangioma

Malignant
- Angiosarcoma

The most common hepatic neoplasms are **metastatic carcinomas**
Colon, lung, and breast are the most common

Focal nodular hyperplasia

- Usually single (20% multiple) nodules in noncirrhotic livers
- A nodular regeneration in response to local vascular injury
- It is usually an incidental finding
- Most common in women of reproductive age
- Does NOT carry a risk for malignancy.

Morphology

- Localized, well-demarcated & un-encapsulated
- It consists of hyperplastic hepatocyte nodules with a central fibrous scar.
- The central scar contain large BVs, lymphocytic infiltrate & bile duct proliferation

FNH



cavernous hemangioma

- The most common benign tumors of the liver

They are well-circumscribed lesions

- Discrete red-blue, soft nodules, usually < 2 cm, often directly beneath the capsule
- They consist of endothelial cell-lined vascular channels and intervening stroma.

- Blind percutaneous needle biopsy may cause severe intra-abdominal bleeding.

Hepatic Adenoma

- A benign primary neoplasm of hepatocytes.
- Usually occurs in women of childbearing age who have used OCPs
- It may regress on discontinuance use.

- Gross appearance:
- 70% solitary lesions
- Well-demarcated nodules often beneath the capsule, may reach 30 cm in diameter
- Pale, yellow-tan, bile-stained or hemorrhagic
- Central scar is absent

Liver cell adenoma

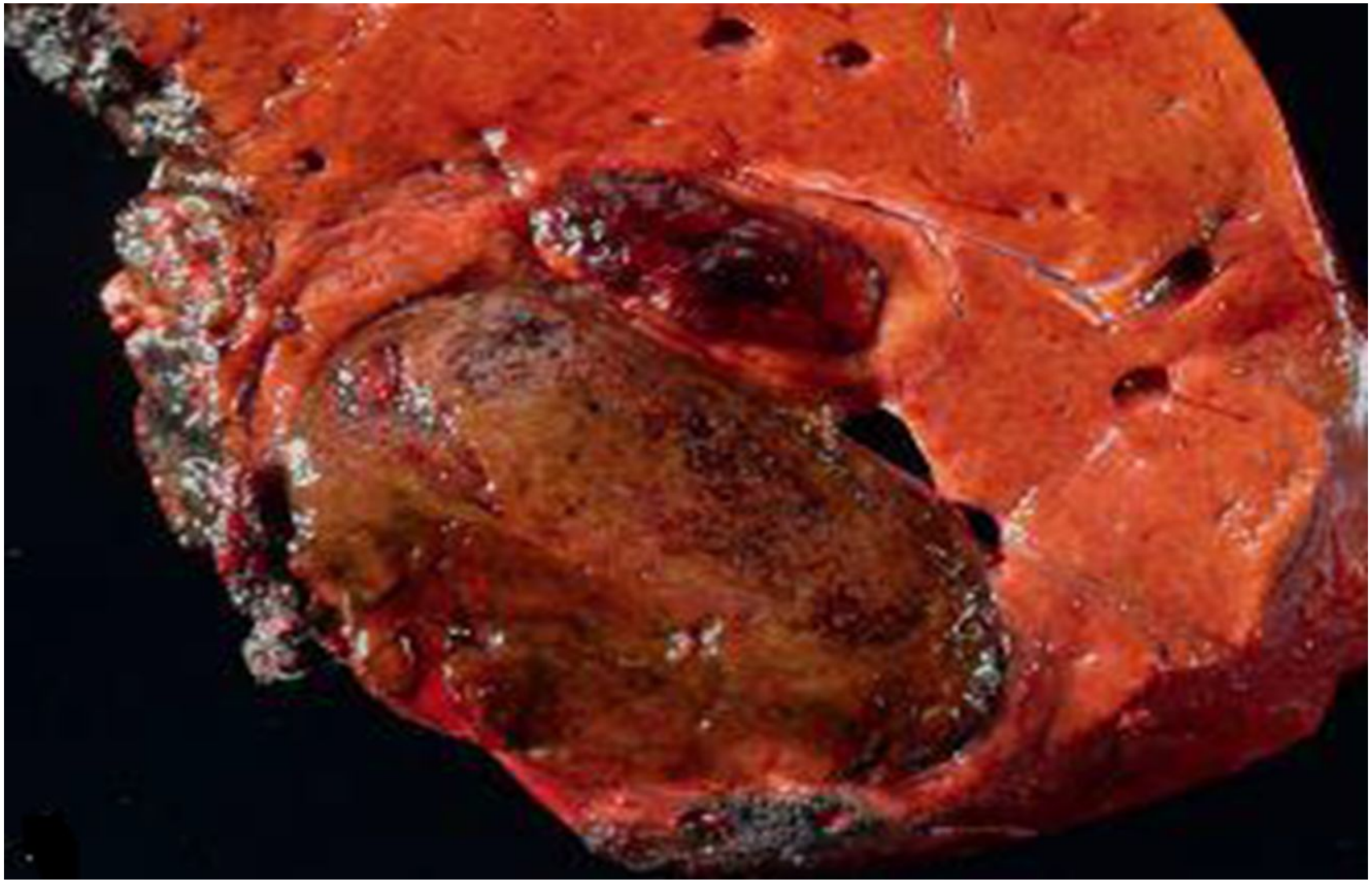

?Why is liver cell adenoma significant

- When they present as an intrahepatic mass, they may be mistaken for HCC
- Subcapsular adenomas are at risk for rupture, particularly during pregnancy causing life-threatening intra-abdominal hemorrhage
- Adenomas carrying β-catenin mutations carry a risk of developing into cancers.

Hepatocellular Carcinomas (HCC)

Epidemiology

- Worldwide, HCC constitutes 5.4% of all cancers

- > 85% in Asian and African countries:

- Chronic HBV infection
- Aflatoxin increases the risk
- In 50% of cases, HCC occur without cirrhosis
- The peak incidence is between 20 & 40 years
- Male to female ration is 8:1

Epidemiology

- In the western countries:
- HCC incidence is rapidly increasing.
- Mainly due to HCV & chronic alcoholism
- HCC is rarely present before age 60
- In 90% of cases tumors develop in persons with cirrhosis
- Male to female ration is 3:1

Pathogenesis

- **Major etiologic associations:**
- Infection with HBV or HCV
- Chronic alcoholism
- Aflatoxin (derived from *Aspergillus flavus) can cause mutation in p53*
- Hemochromatosis
- Tyrosinemia

- **Cirrhosis:**
- An important contributor but not a requisite
- HCC in HCV occurs almost exclusively in the setting of cirrhosis

Pathogenesis

- **Precancerous lesions**
- Small-cell and high-grade dysplastic nodules in cirrhotic livers.
  - Distinguishing from early HCC is difficult
  - An important criterion is nodule vascularization visualized by imaging, which is almost always a clear indication of malignancy.
- **Cell of origin in HCC:**
- The tumors may arise from both mature hepatocytes and progenitor cells (oval cells)

Morphology

- **Gross appearance:**

(1) A **unifocal,** usually massive tumor

(2) A **multifocal tumor** made of nodules of variable size

(3) A **diffusely infiltrative** cancer, sometimes involving the entire liver

Morphology

- Tumors are yellow-white, punctuated by bile staining and areas of hemorrhage or necrosis

- **All patterns of HCC have a strong propensity for invasion of vascular channels:**
- Extensive intrahepatic metastases
- Occasionally snakelike masses of tumor invade the portal vein or IVC extending into the right side of the heart.

HCC



Microscopic picture

- HCCs shows a range of differentiation
- **Well-differentiated:**
- Hepatocytes arranged in thick cords, trabeculae or glandular patterns
- **Moderately differentiated**
- **Poorly differentiated:**
- Composed of large anaplastic multinucleate tumor giant cells

Microscopic picture

- **Other features:**
- Loss of reticulin stain is an important sign
- Bile pigment may be found within the cells and in canaliculi between cells.
- Acidophilic hyaline inclusions resembling MB.
- Scant stroma
- Sinusoides lined by tumor cells
- Invasion of BVs

Well differentiated HCC

