Anatomy lab- Liver, Gallbladder, pancreas & spleen

Liver

- Largest gland in the body
  - Weight: ~ 1.2–1.5 kg in adults
- Wedge-shaped : base directed to the right and tapered end directed to the left.
- Site : It occupies mainly the right hypochondrium and epigastrium, extending to left hypochondrium.
- Surfaces :

- Convex supero-anterior (Diaphragmatic surface)
- Flat infero-posterior (Visceral surface)



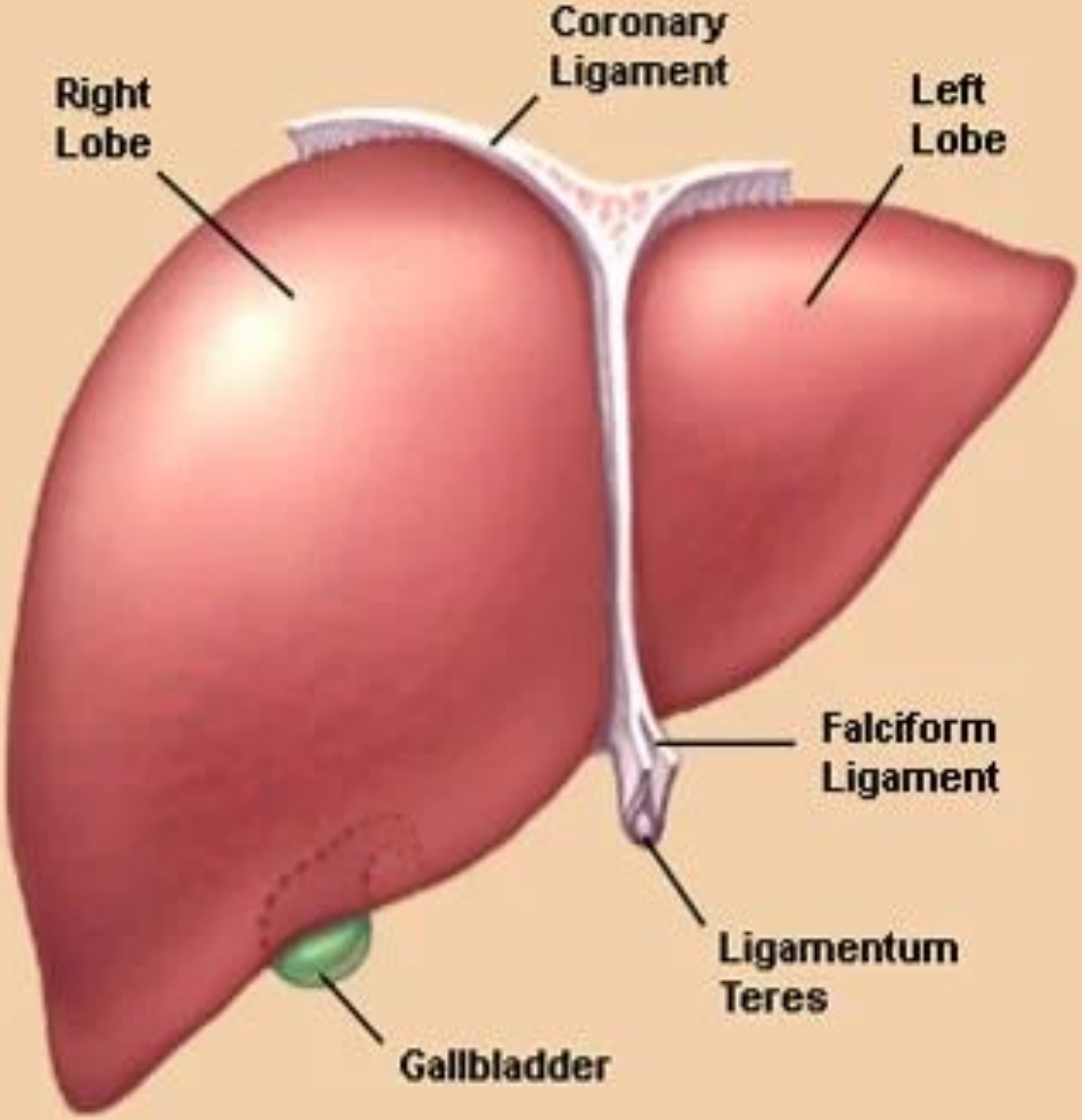

©2008 WebMD, LLC.

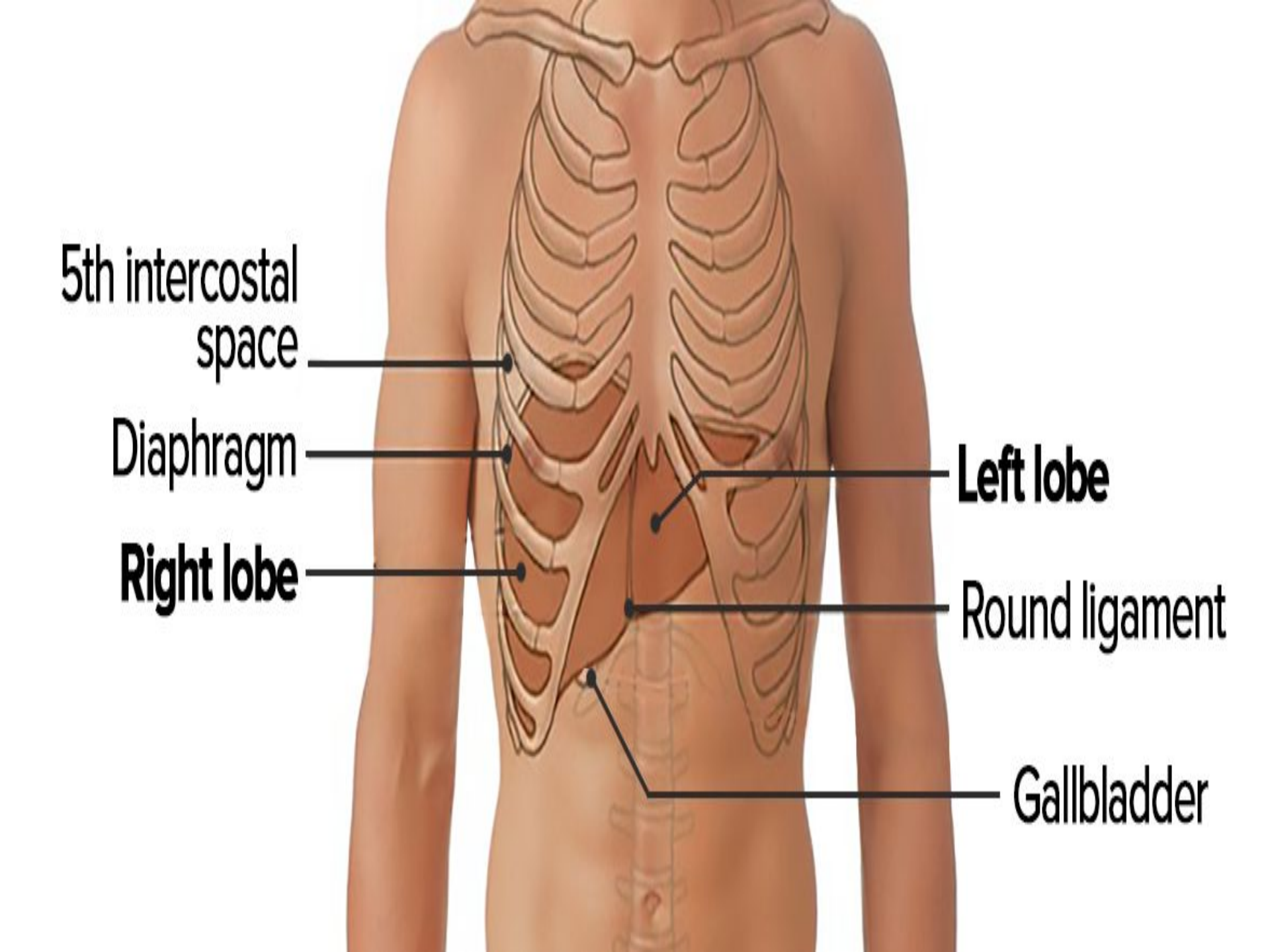
5th intercostal space
Diaphragm
Right lobe
Left lobe
Round ligament
Gallbladder

Diaphragmatic Surface

The convex upper, anterior and right lateral surface is smooth and molded to the undersurface of the domes of the diaphragm.

The diaphragm separates the liver from pleurae, base of both lungs, pericardium, and heart.

It is covered with visceral peritoneum, **except** posteriorly in the bare area of the liver, where it lies in direct contact with the diaphragm.

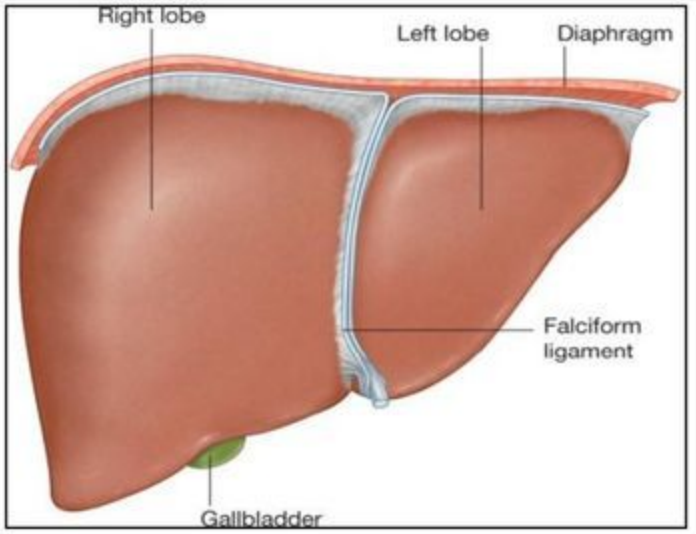

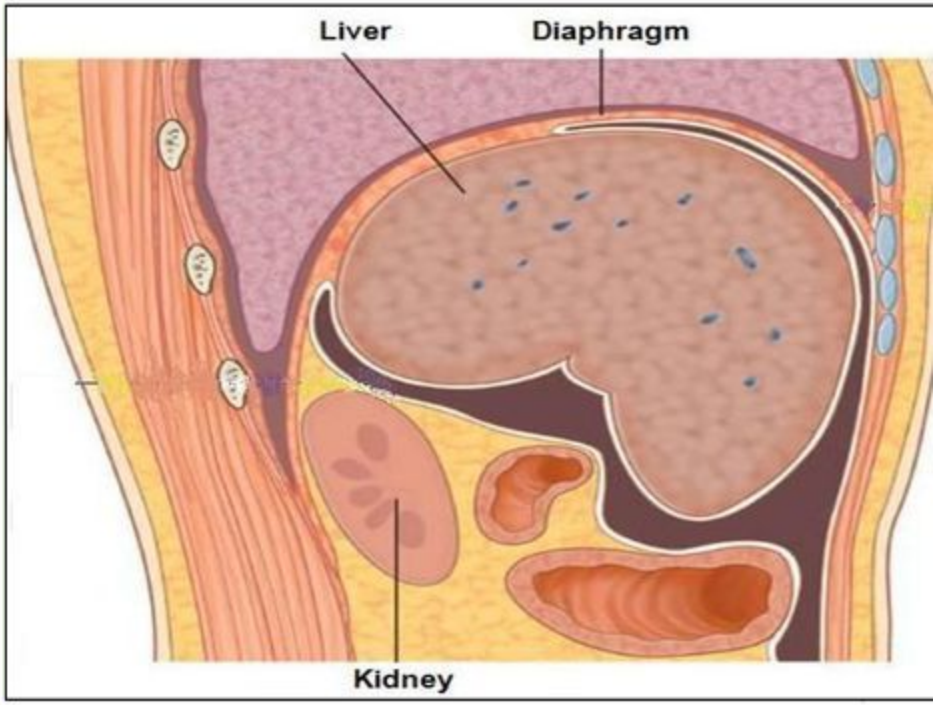

➢ The liver is related to diaphragm in all directions (except inferiorly):

- **Right surface:** is separated by the diaphragm from right lung, pleura, and 7th-11th ribs.
- **Anterior surface:** is related to anterior abdominal wall. It is separated by the diaphragm from both lungs and pleurae.
- **Superior surface:** is separated by the diaphragm from both lungs and pleurae (on either sides), and from pericardium and heart (in the middle).
- **Posterior surface:** is attached to diaphragm by loose connective tissue and represents the bare area of the liver (see later).

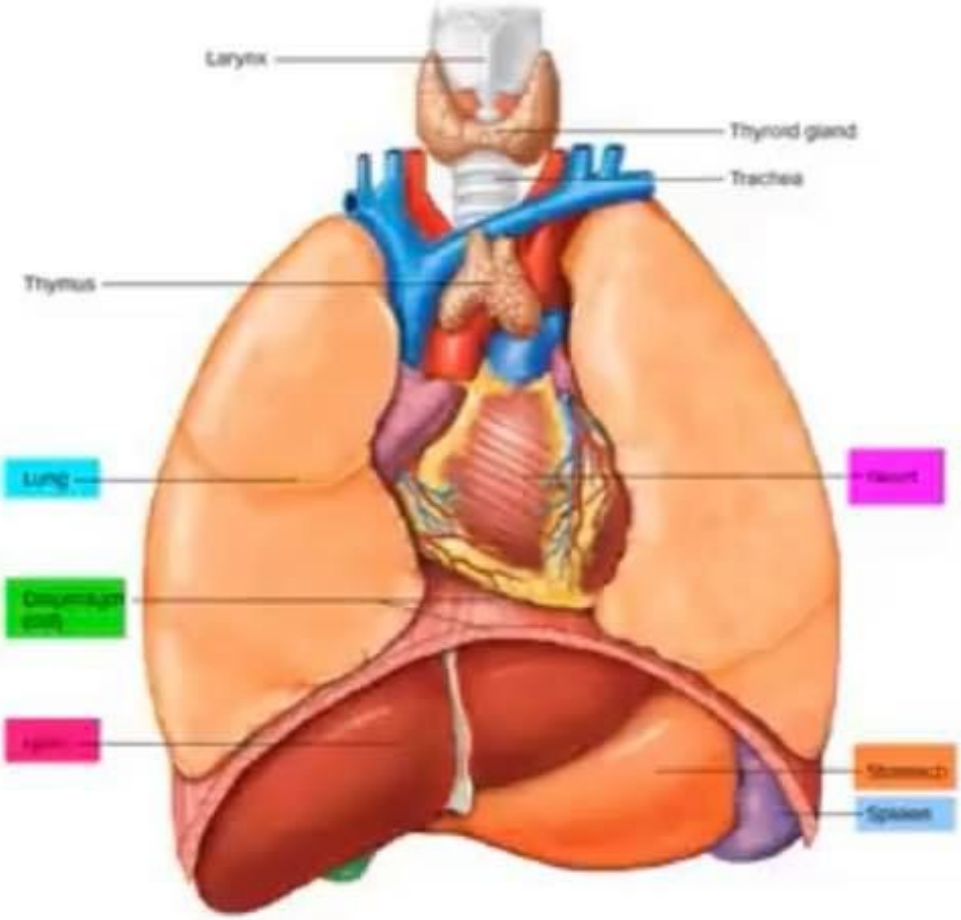

Notice the peritoneal recesses associated with the diaphragmatic portion of the liver

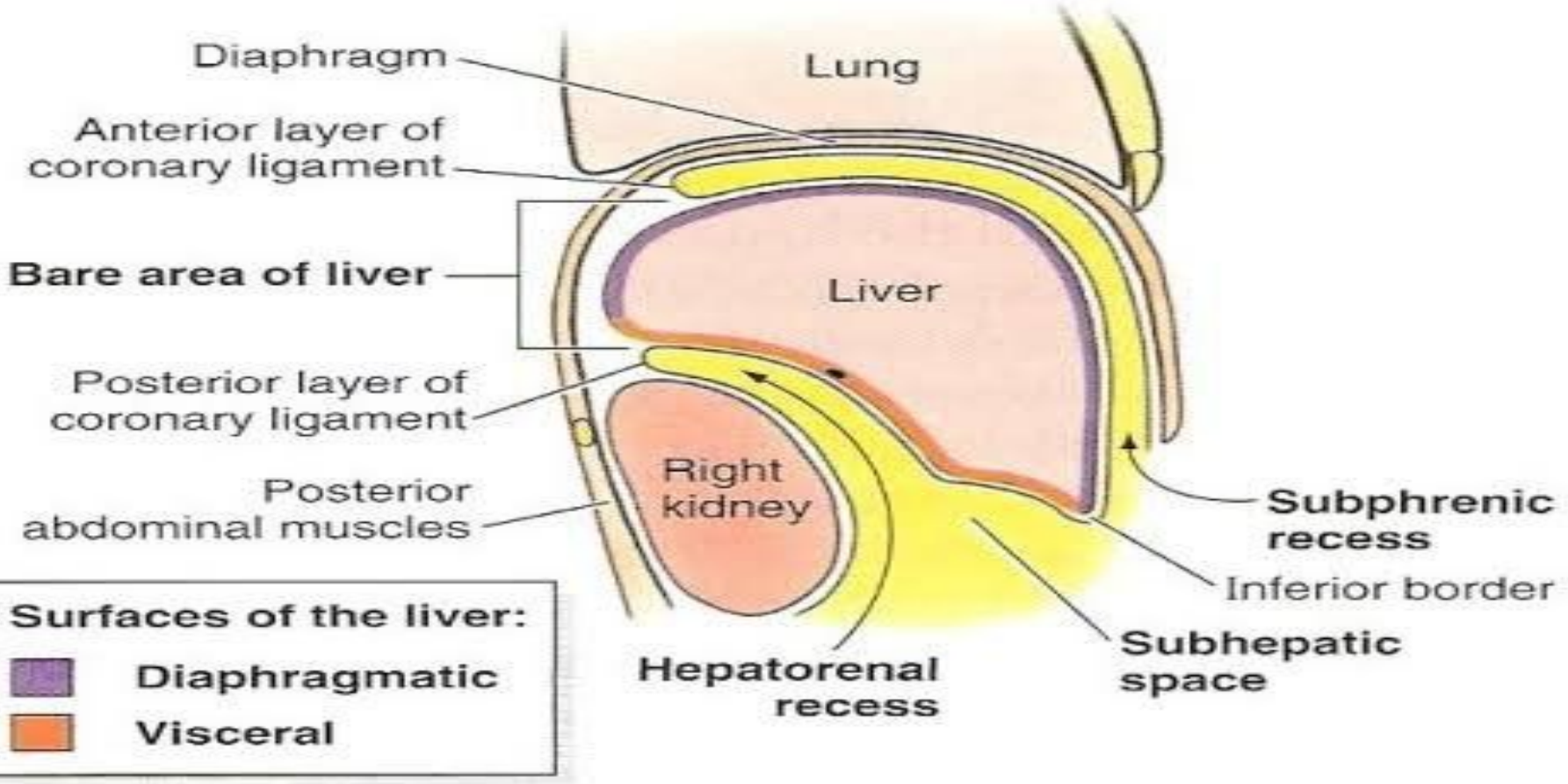

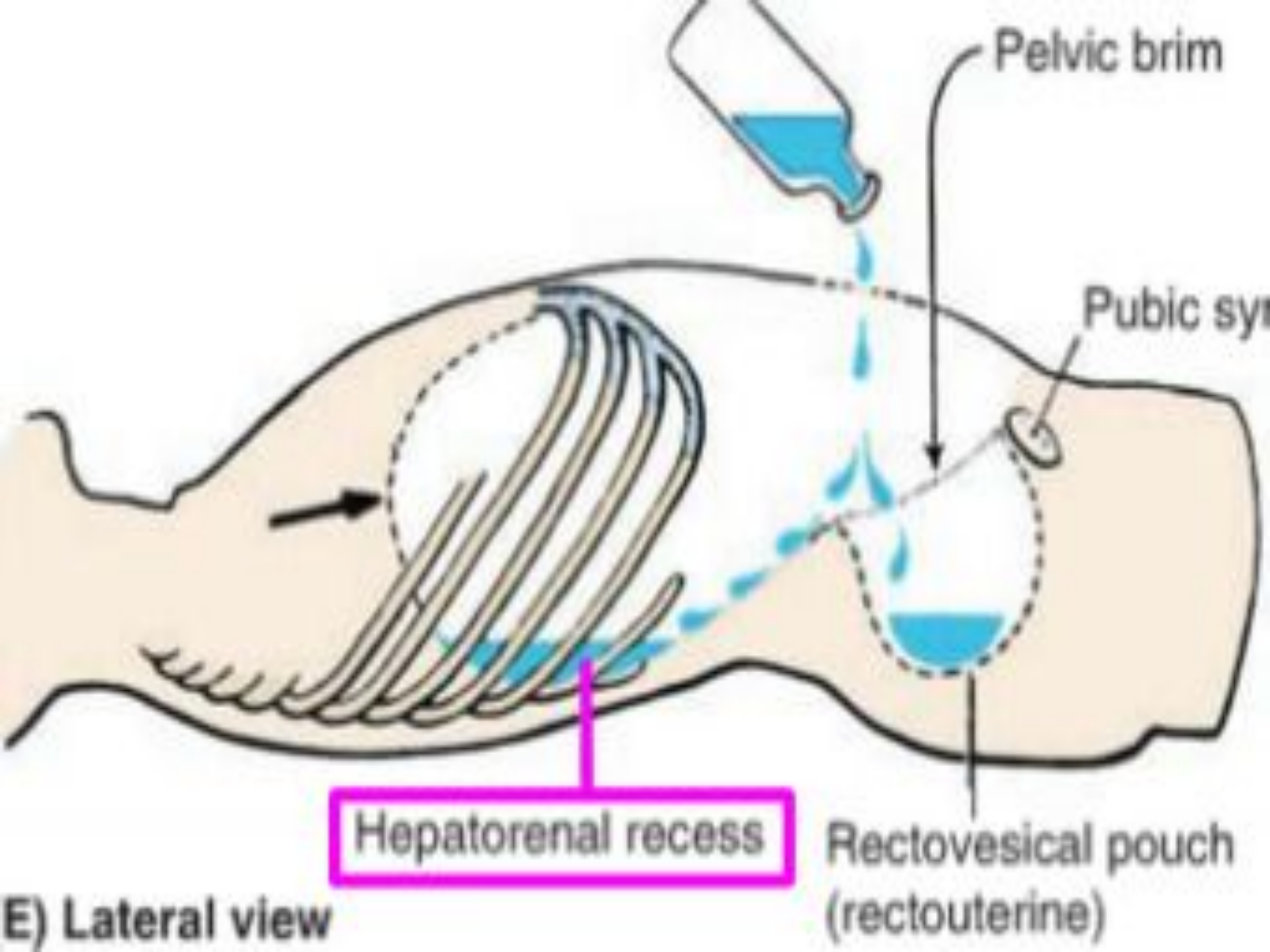

E) Lateral view

Hepatorenal recess (Morrison pouch)

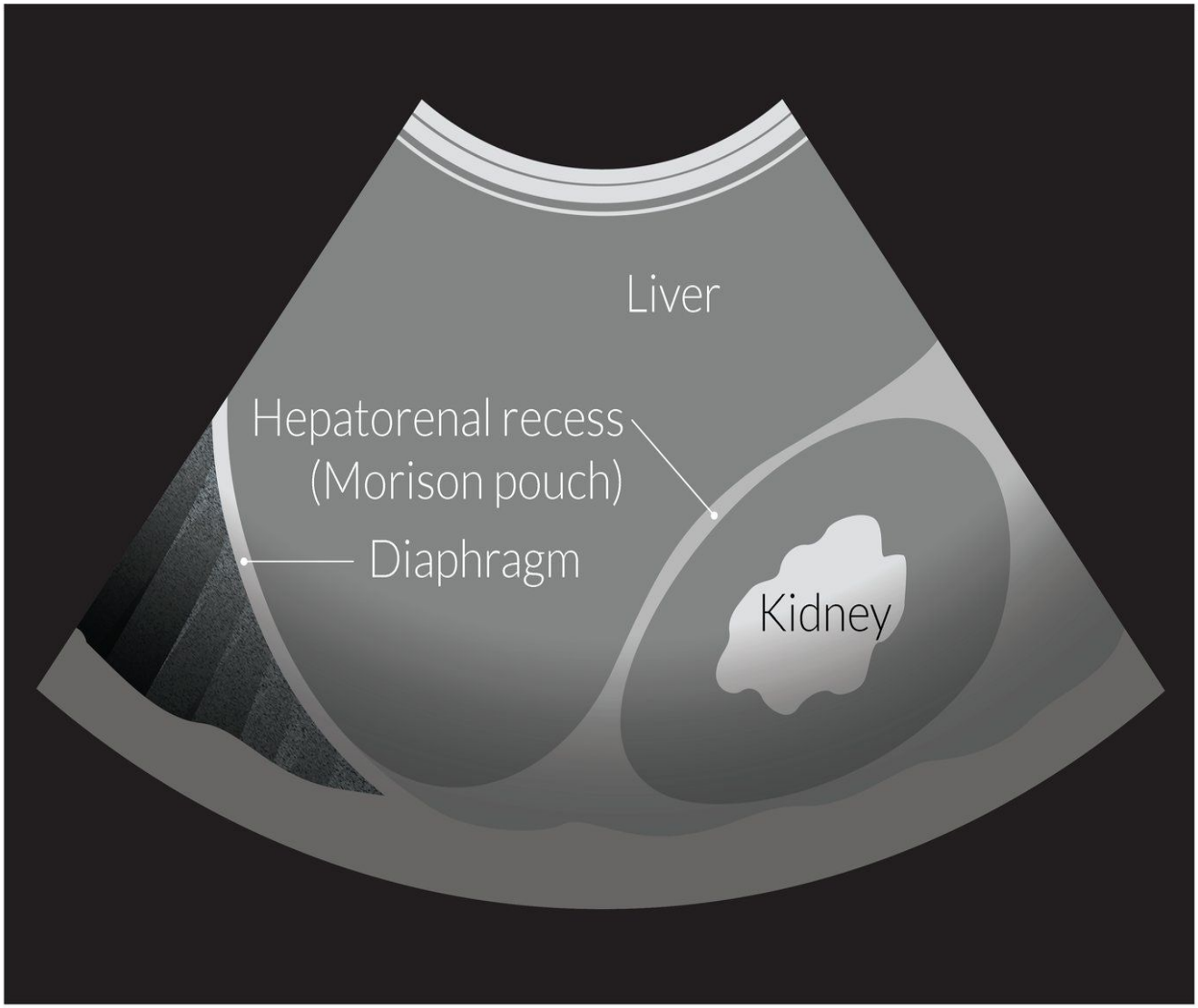

Subphrenic space

- Paired spaces (left and right) between the diaphragm and the liver
- Separated by the falciform ligament
- Site of subphrenic abscess (most commonly occurring as a complication of intraabdominal surgery)



Subphrenic spaces

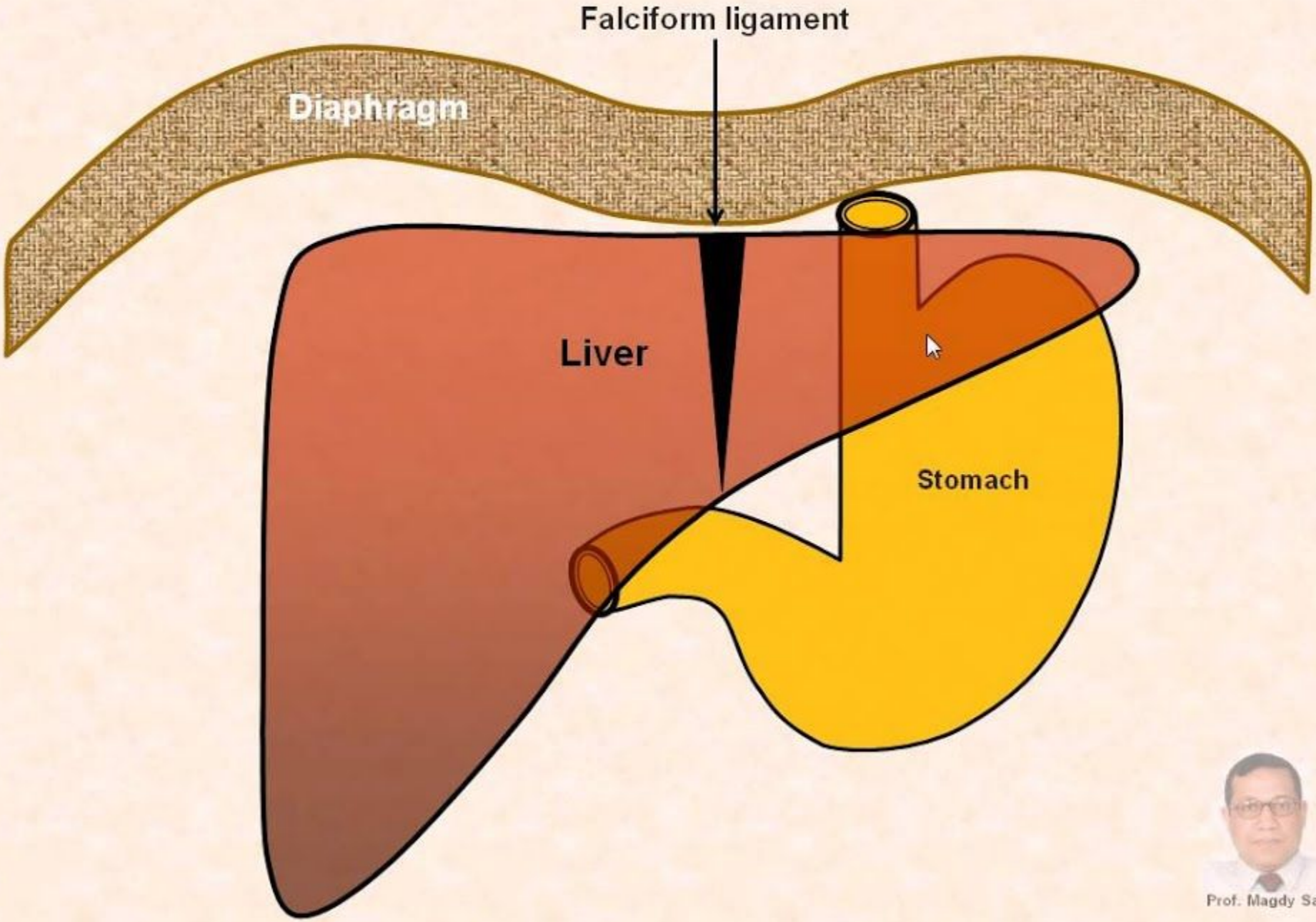

Visceral Surface of Liver

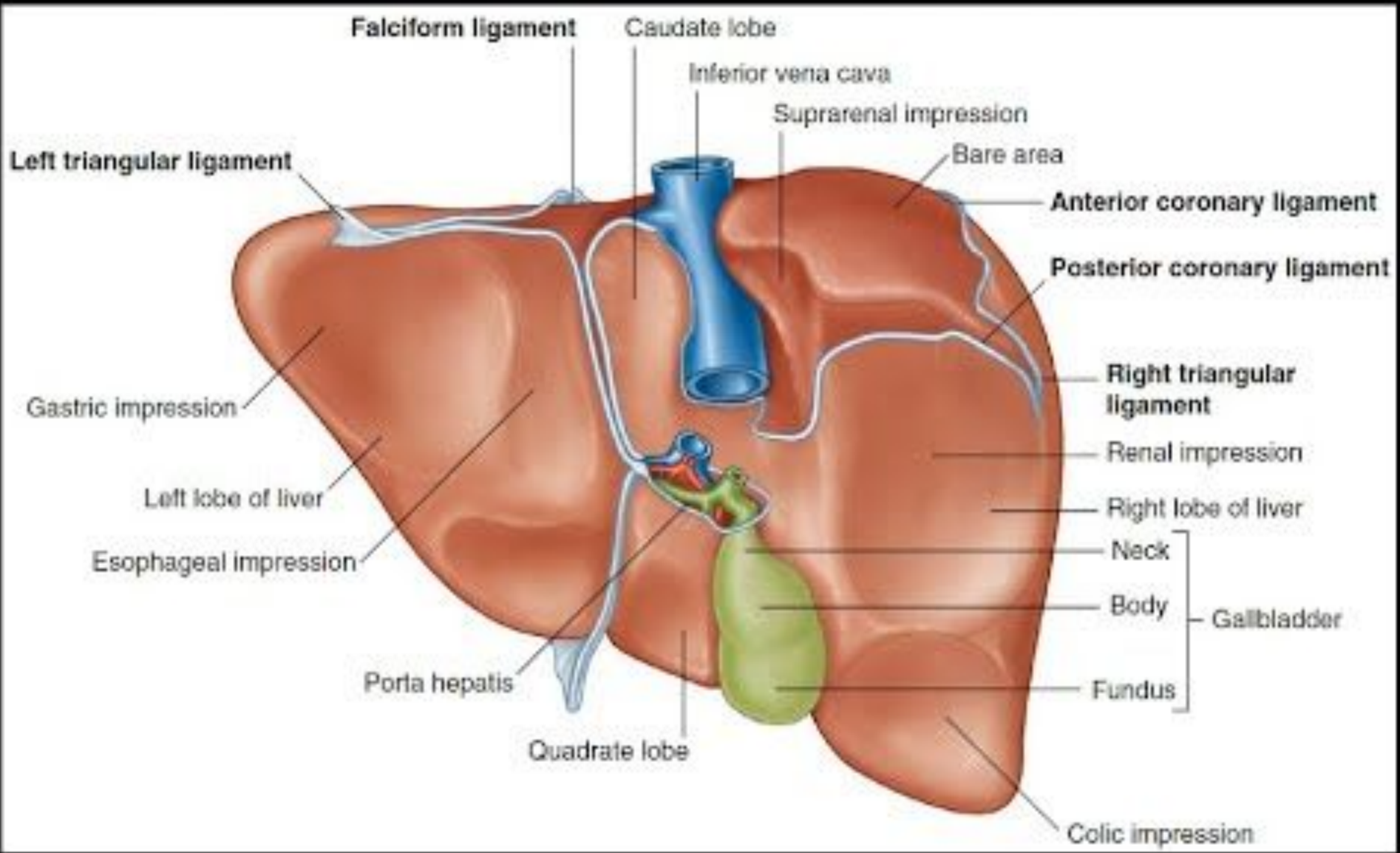

Relations of Visceral Surface of the Liver

The visceral surface is related to:

1. Stomach.
2. Esophagus.
3. Lesser omentum.
4. Gallbladder.
5. Right colic flexure
6. Right kidney.
7. Right suprarenal gland.

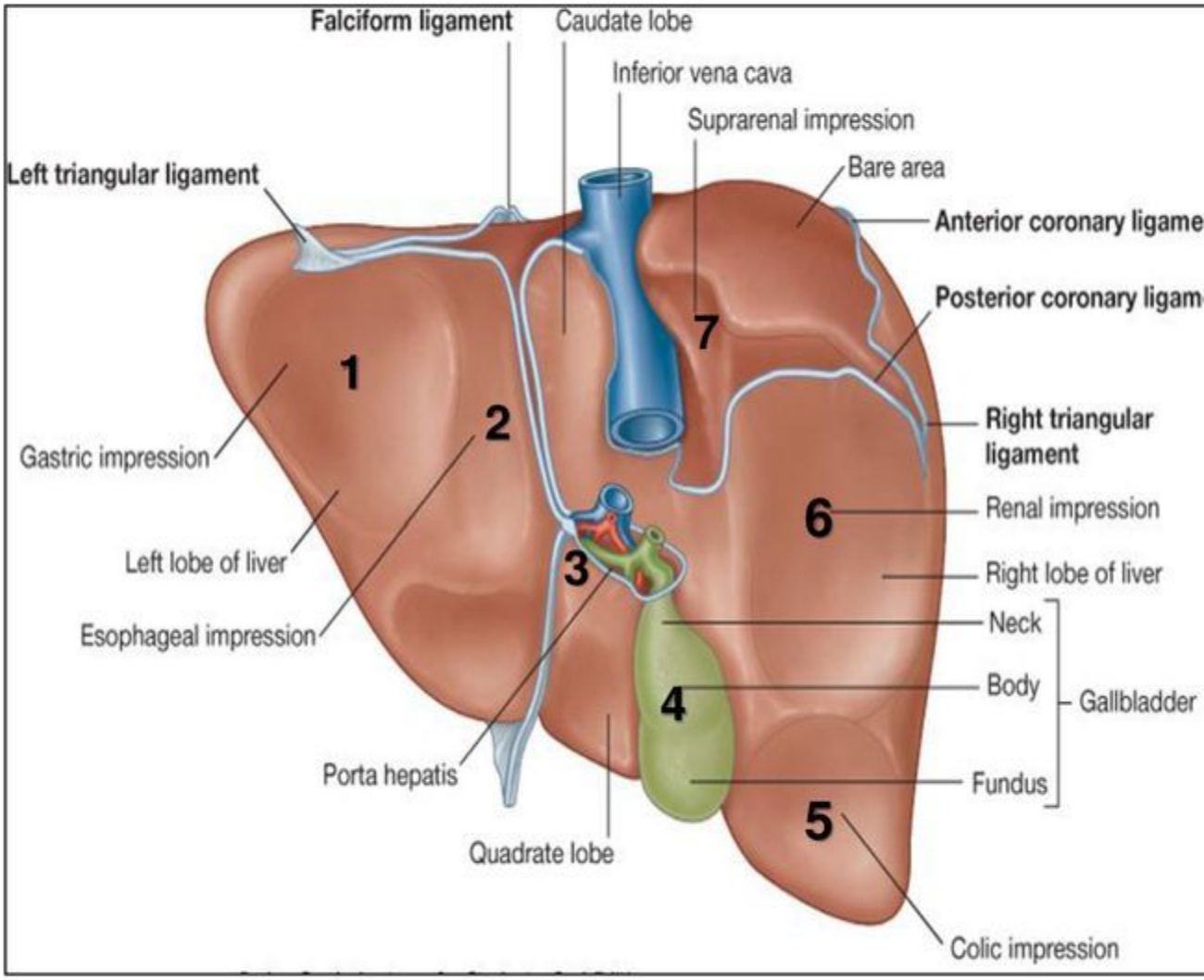

Peritoneum of liver : (Liver ligaments)

- **Liver ligaments** are double-layered folds of peritoneum that attach the liver to surrounding organs, or to the abdominal wall. The majority of ligaments associated with the liver are remnants of embryological blood vessels that regressed as the fetus developed.

- Coronary ligament
- Triangular ligaments
- Falciform ligament

Connects liver to abdominal wall

Divides liver into right (larger) and left (smaller) lobes

Contains round ligament of liver

- Ligamentum teres (Round ligament , remnant of umbilical vein)
- Ligamentum venosum (fibrosed remnant of ductus venosus)
- Lesser omentum: Hepatogastric and hepatoduodenal ligaments

- **Hepatoduodenal ligament**
  - Connects liver to duodenum
  - Contains portal triad (proper hepatic artery, portal vein, common bile duct)
    - Clinical correlate: in cases of liver hemorrhage, temporary clamping of the hepatoduodenal ligament (Pringle maneuver) can help to achieve hemostasis
- **Gastrohepatic ligament**
  - Connects liver to lesser curvature of the stomach
  - Contains gastric arteries



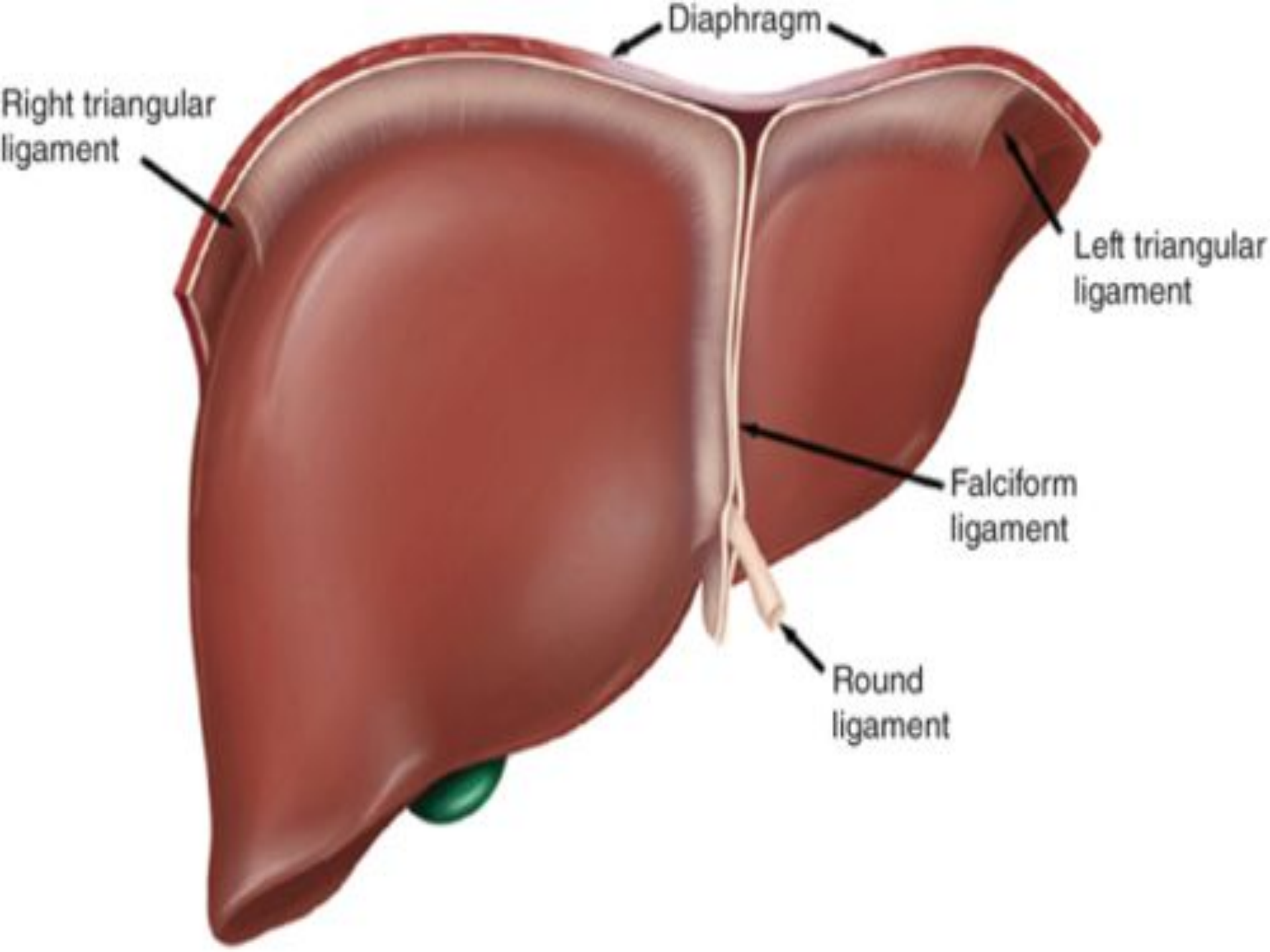
Diaphragm
Right triangular ligament
Left triangular ligament
Falciform ligament
Round ligament

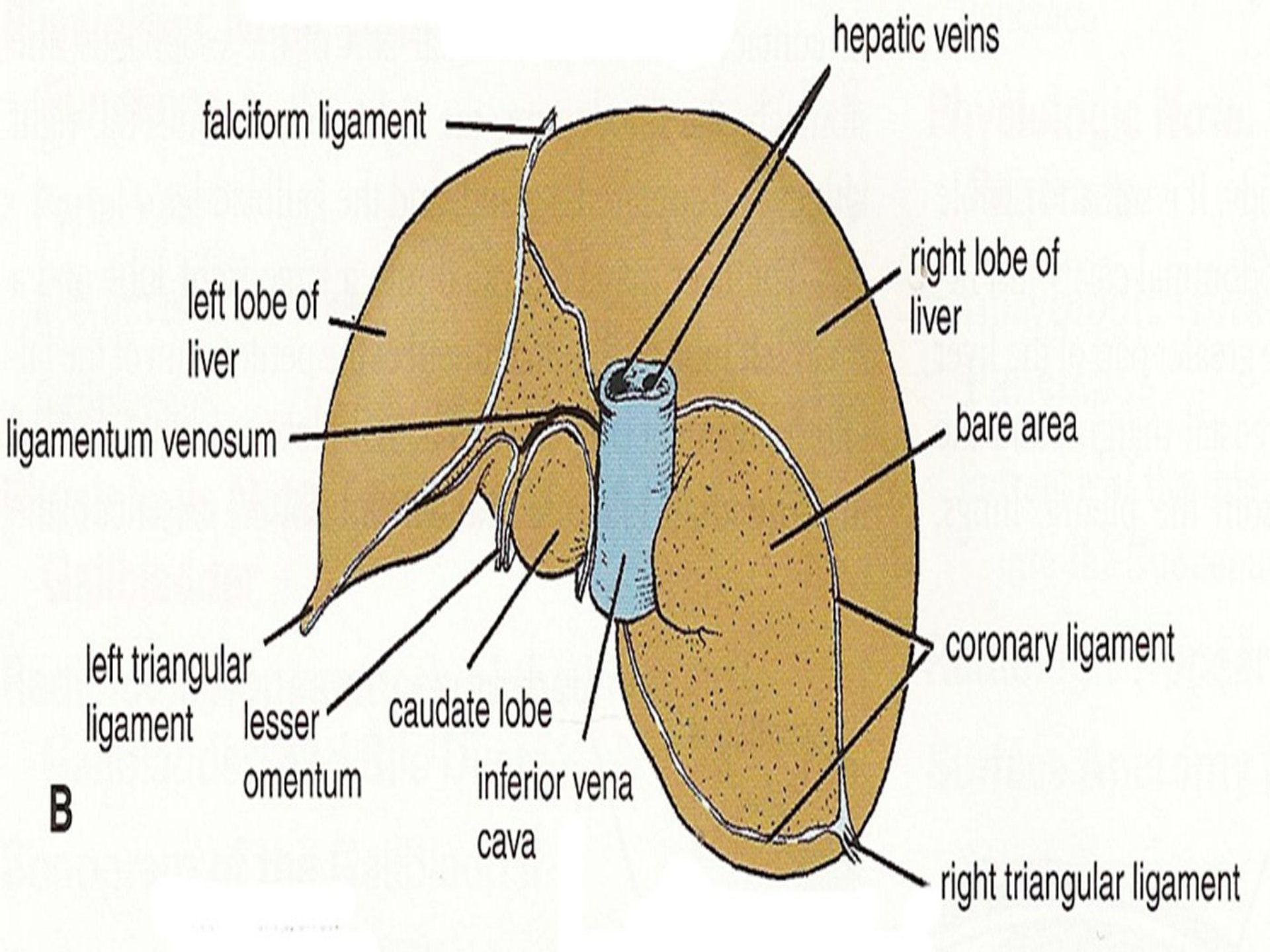
hepatic veins
falciform ligament
right lobe of liver
left lobe of liver
ligamentum venosum
bare area
coronary ligament
left triangular ligament
lesser omentum
caudate lobe
inferior vena cava
right triangular ligament
B

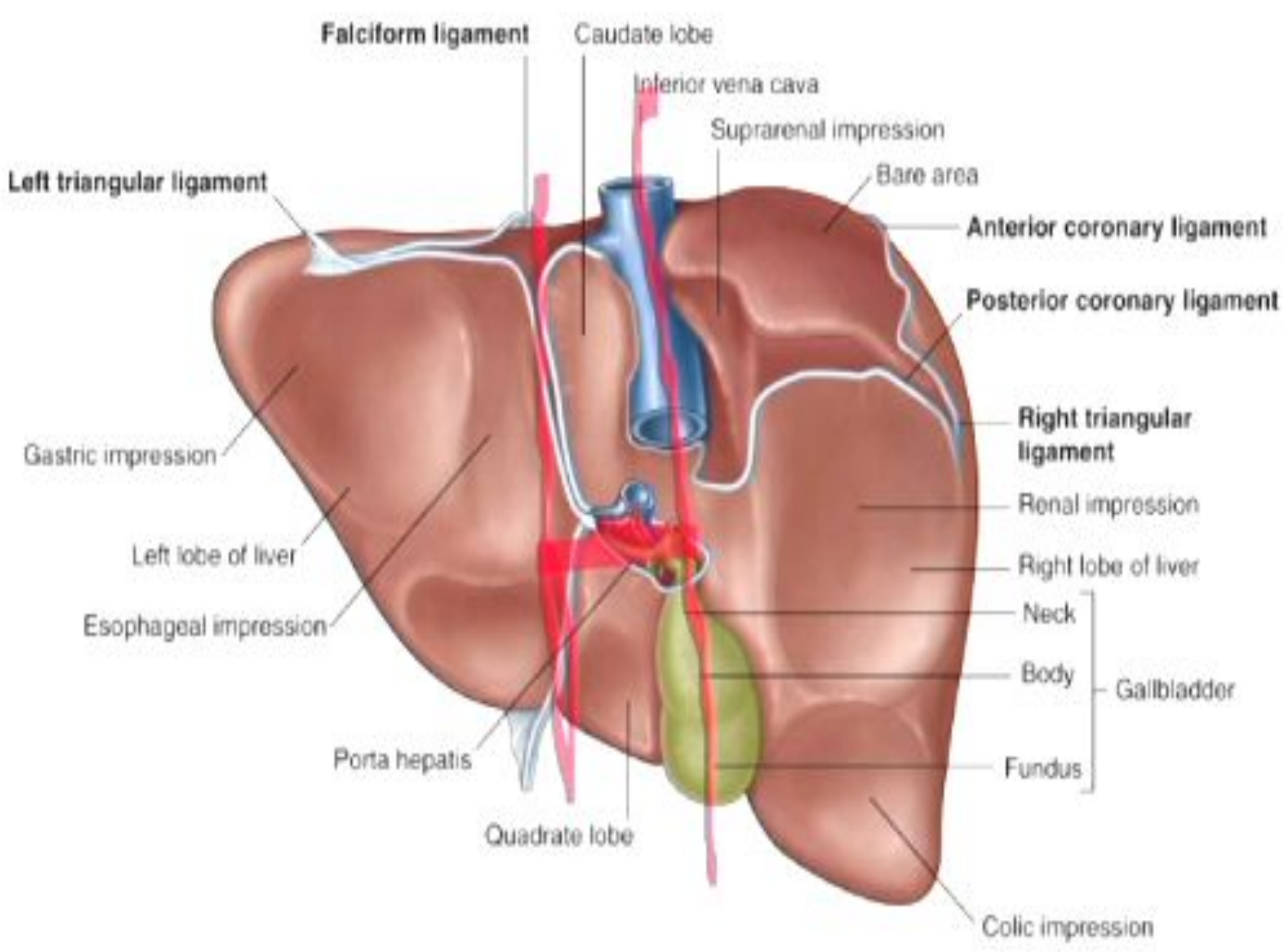
Falciform ligament
Caudate lobe
Inferior vena cava
Suprarenal impression
Bare area
Left triangular ligament
Anterior coronary ligament
Posterior coronary ligament
Right triangular ligament
Gastric impression
Renal impression
Left lobe of liver
Right lobe of liver
Esophageal impression
Neck
Body
Gallbladder
Porta hepatis
Fundus
Quadrate lobe
Colic impression

The following areas are devoid of peritoneum

- Main bare area.
- Groove for IVC.
- Fossa for Gallbladder.
- Porta hepatis.
- Fissure for ligamntum veosum.
- Fissure for ligamentum teres.



Main Bare area of Liver

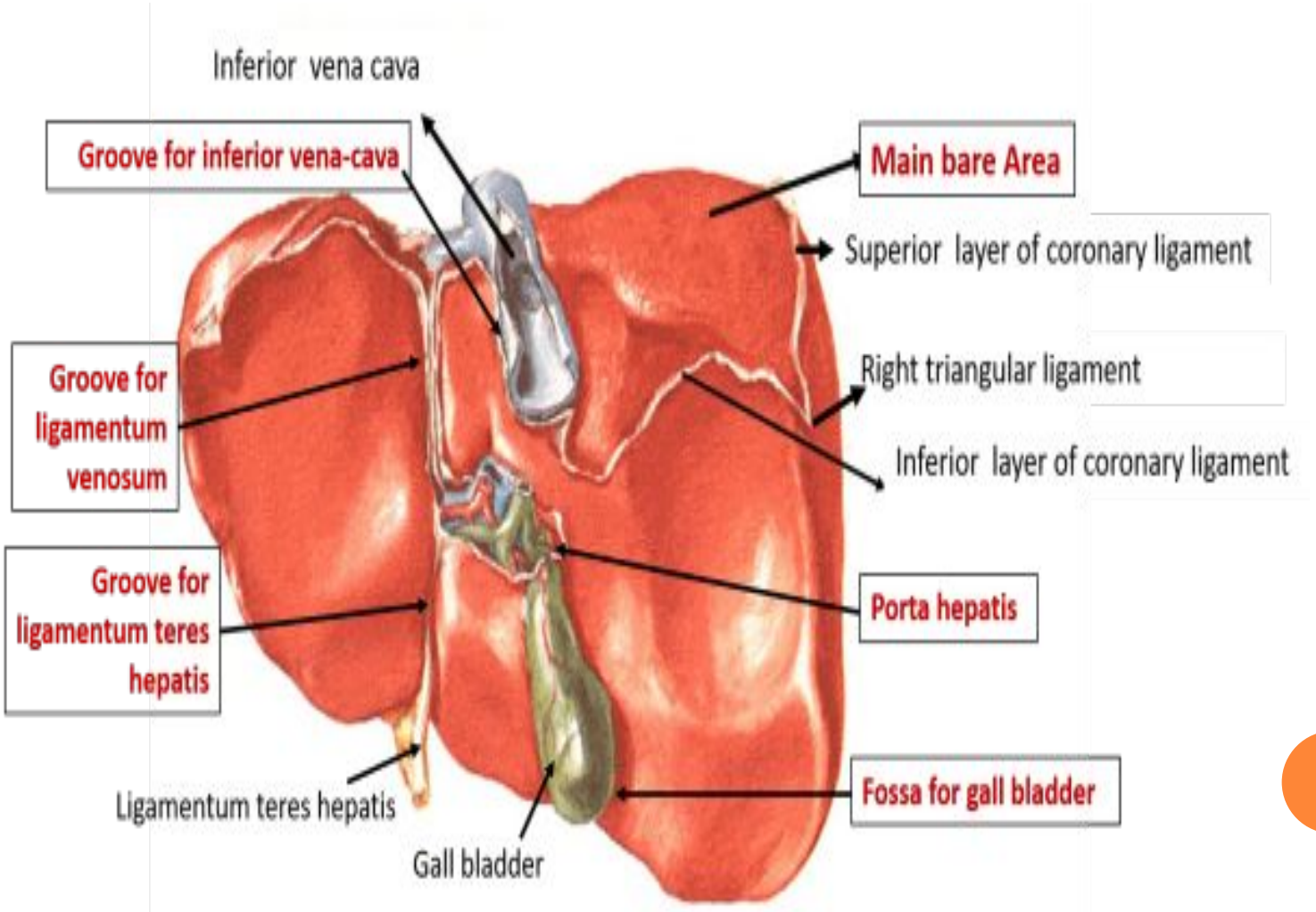

PORTA HEPAIS (HILUM)

- Fissure between the caudate and quadrate lobes that contains several veins, arteries, and nerves
- Porta hepatis structures
  - Common hepatic duct (leaving)
  - Hepatic artery proper (entering)
  - Hepatic portal vein (entering)
  - Hepatic nerve plexus and lymphatic vessels



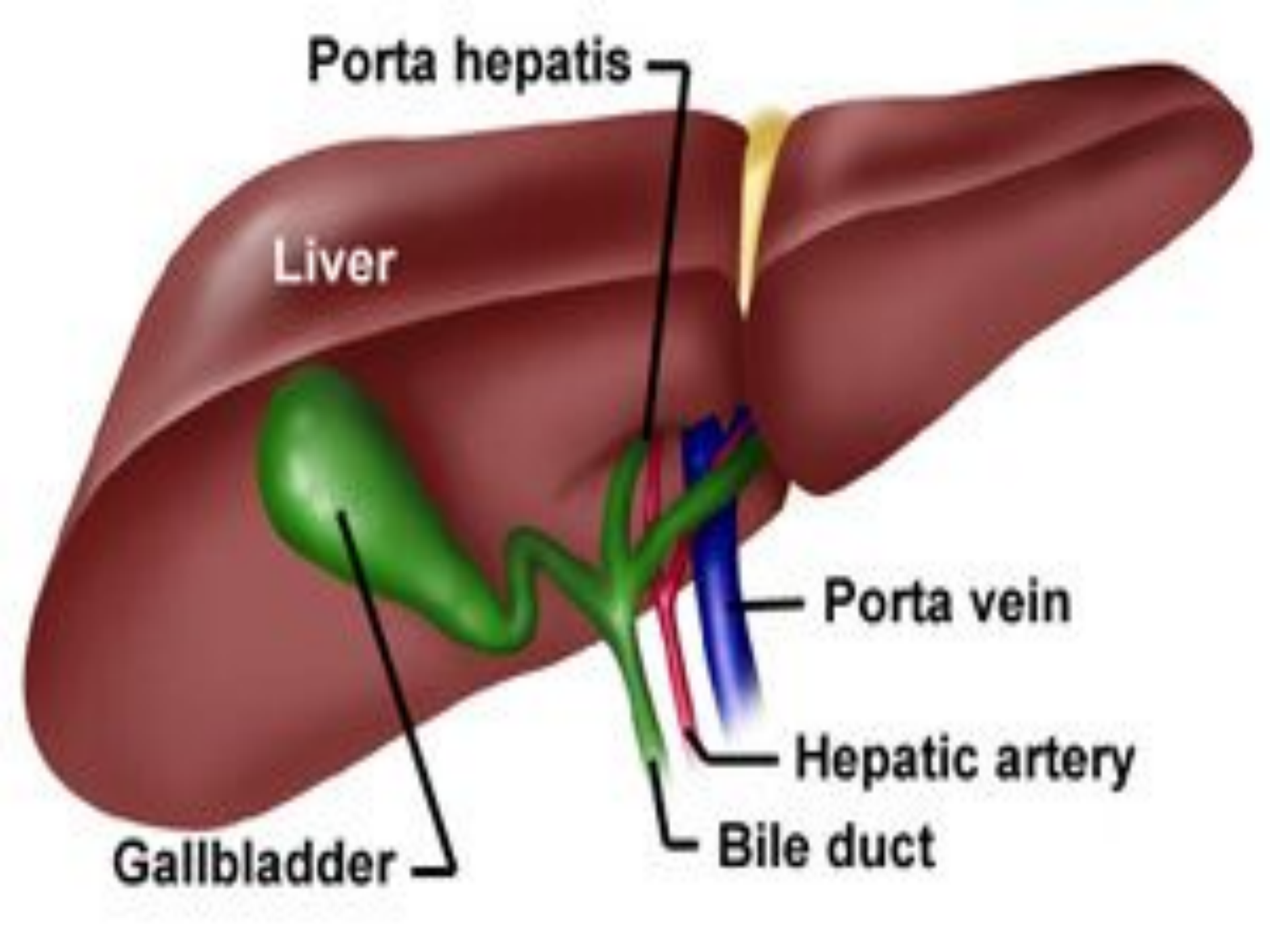
Porta hepatis
Liver
Porta vein
Hepatic artery
Bile duct
Gallbladder

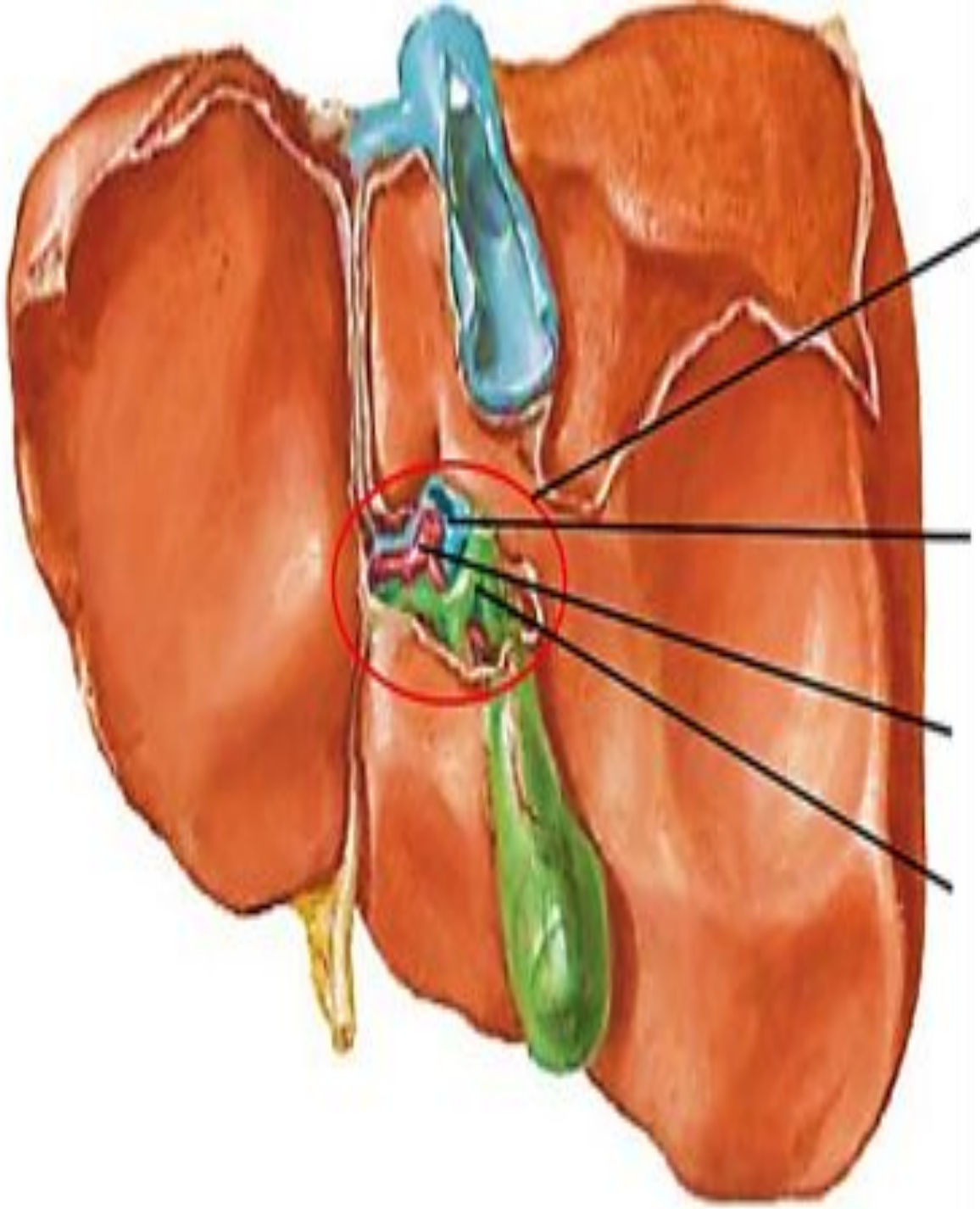

Porta Hepatis

From posterior to anterior

- Portal vein
- Hepatic artery
- Hepatic duct

Lobes of liver

Anatomical division

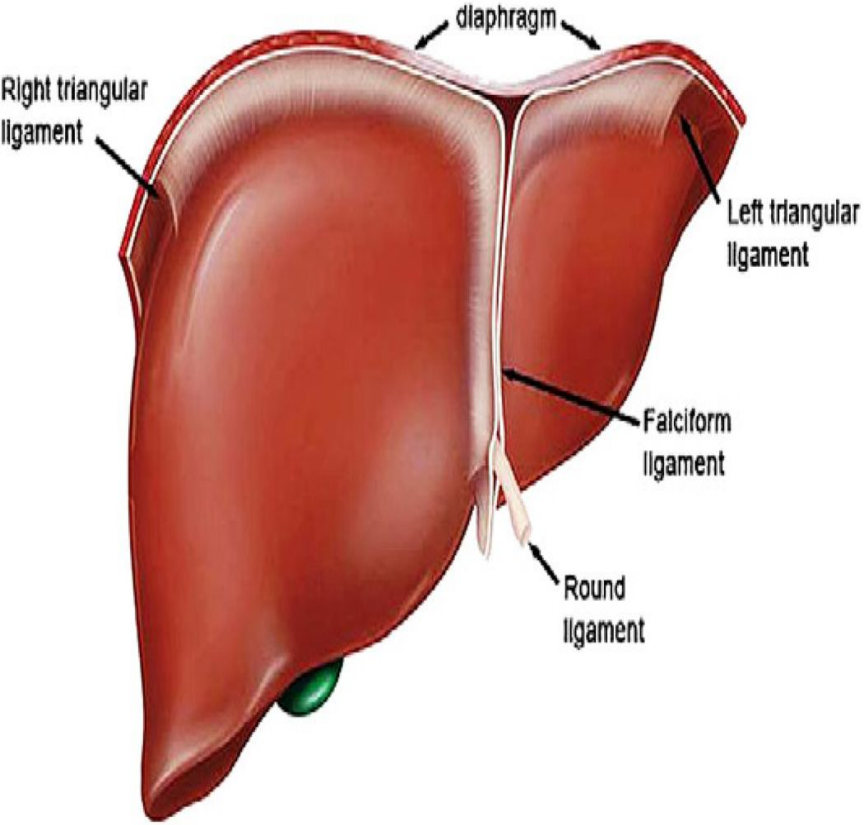

Functional division

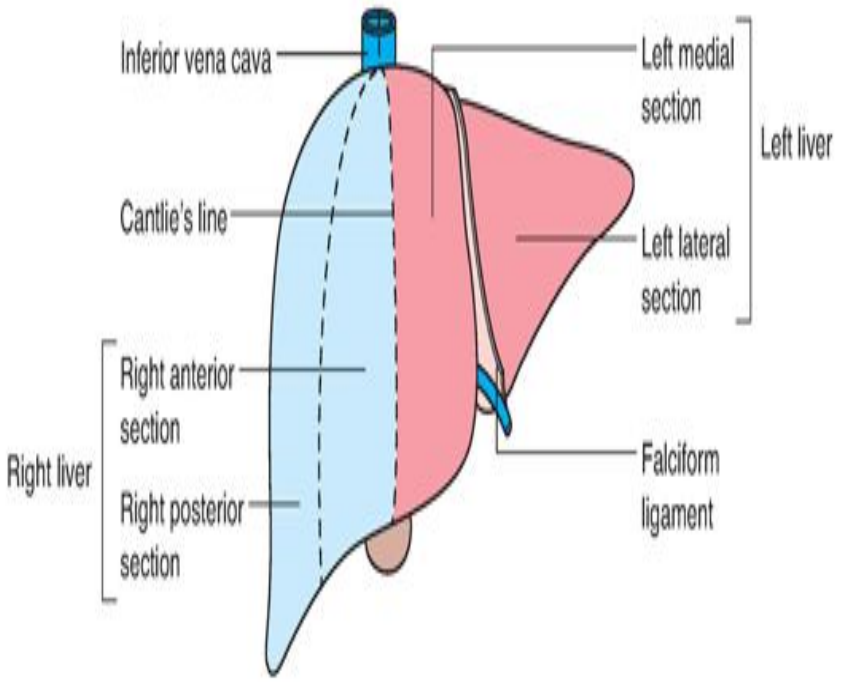

Anatomic division of the liver into right and left halves by a line extending from the gallbladder fossa posteriorly to the inferior vena cava.

Anatomical division

- By means of falciform lig, fissure for ligamentum venosum, and fissure for ligamentum teres into

LARGE RIGHT LOBE having caudate and quadrate lobes

SMALL LEFT LOBE

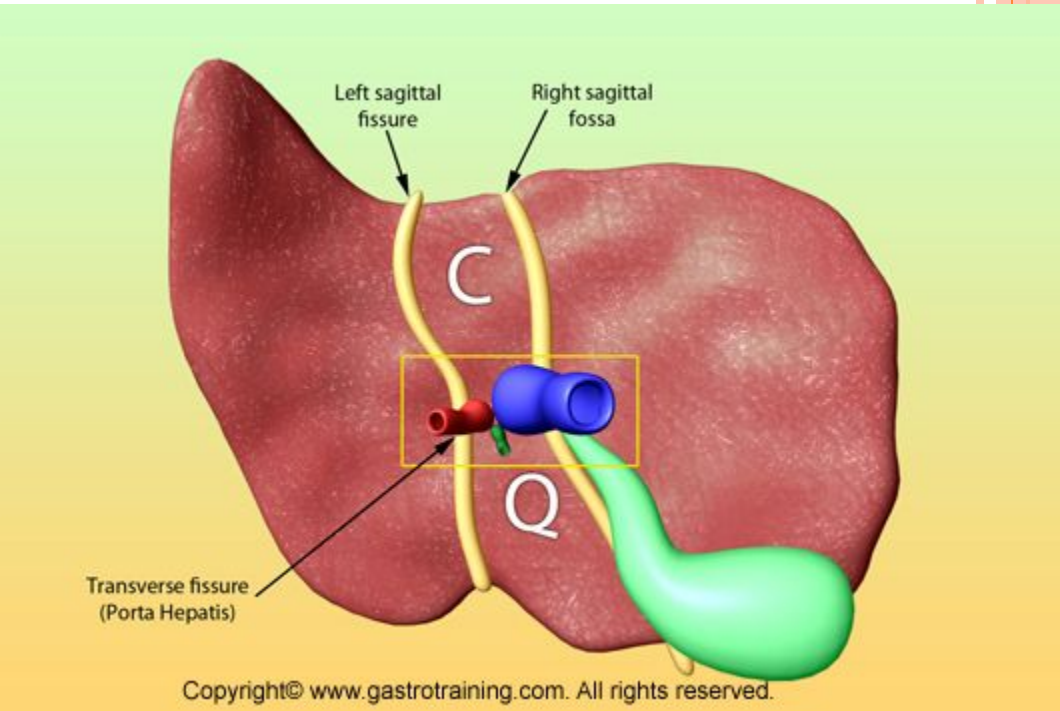

Functional Division

- By cantlie line which is an imaginary line passing through groove for IVC and fossa for GB giving :

RIGHT FUNCTIONAL LOBE & LEFT FUNCTIONAL LOBE supplied by rt and lt hepatic and portal veins , and bile is drained by rt and lt hepatic ducts.

So, caudate and quadrate lobes are parts of left functional lobe.



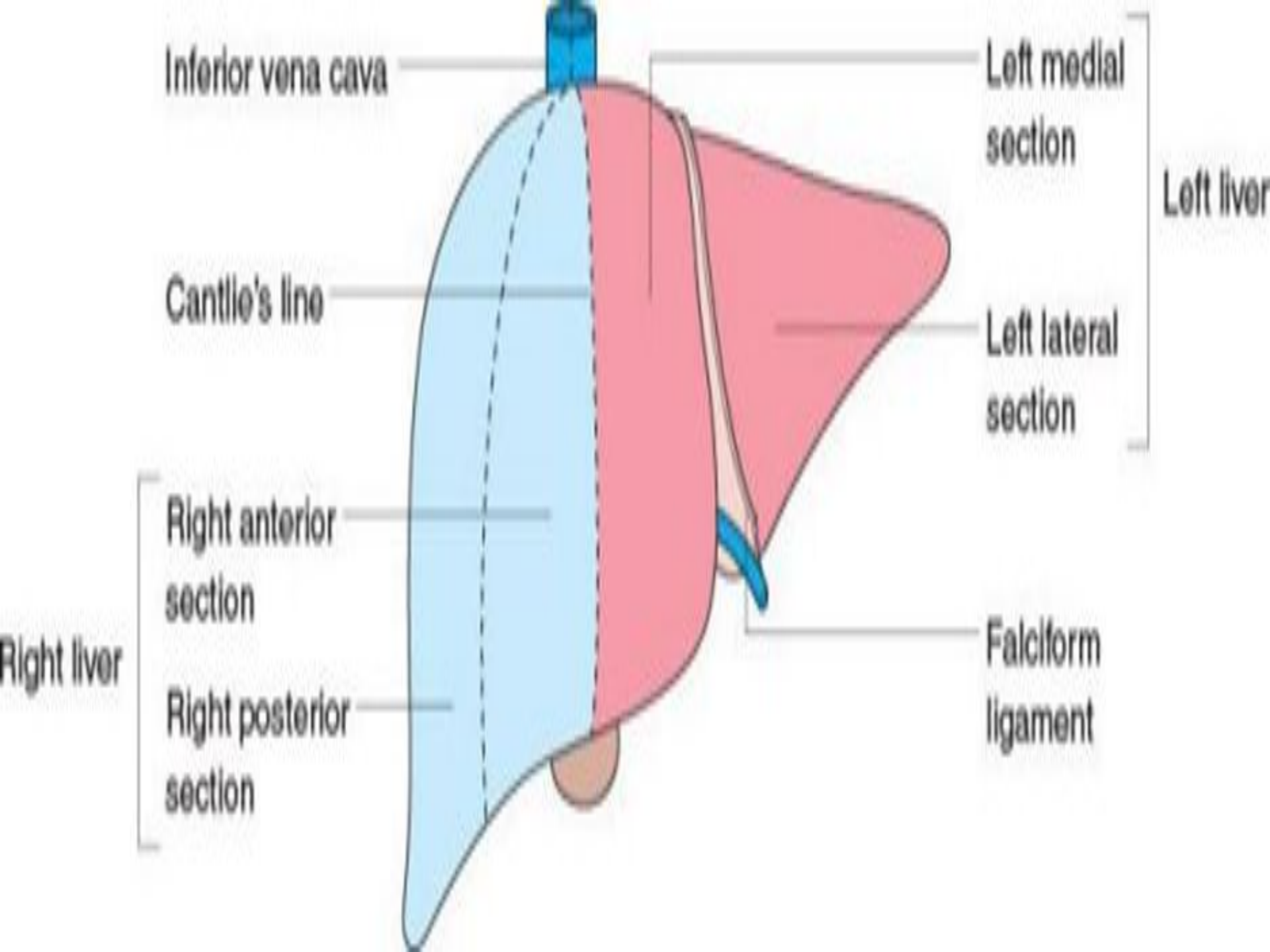
Inferior vena cava
Left medial section
Left liver
Cantlie's line
Left lateral section
Right anterior section
Right liver
Falciform ligament
Right posterior section

Surface anatomy of liver

- **Location**
- Location: under the diaphragm in the right upper abdomen.
  - Extends from the fifth intercostal space to the right costal margin in the midclavicular line
  - Percussed at the fifth intercostal space



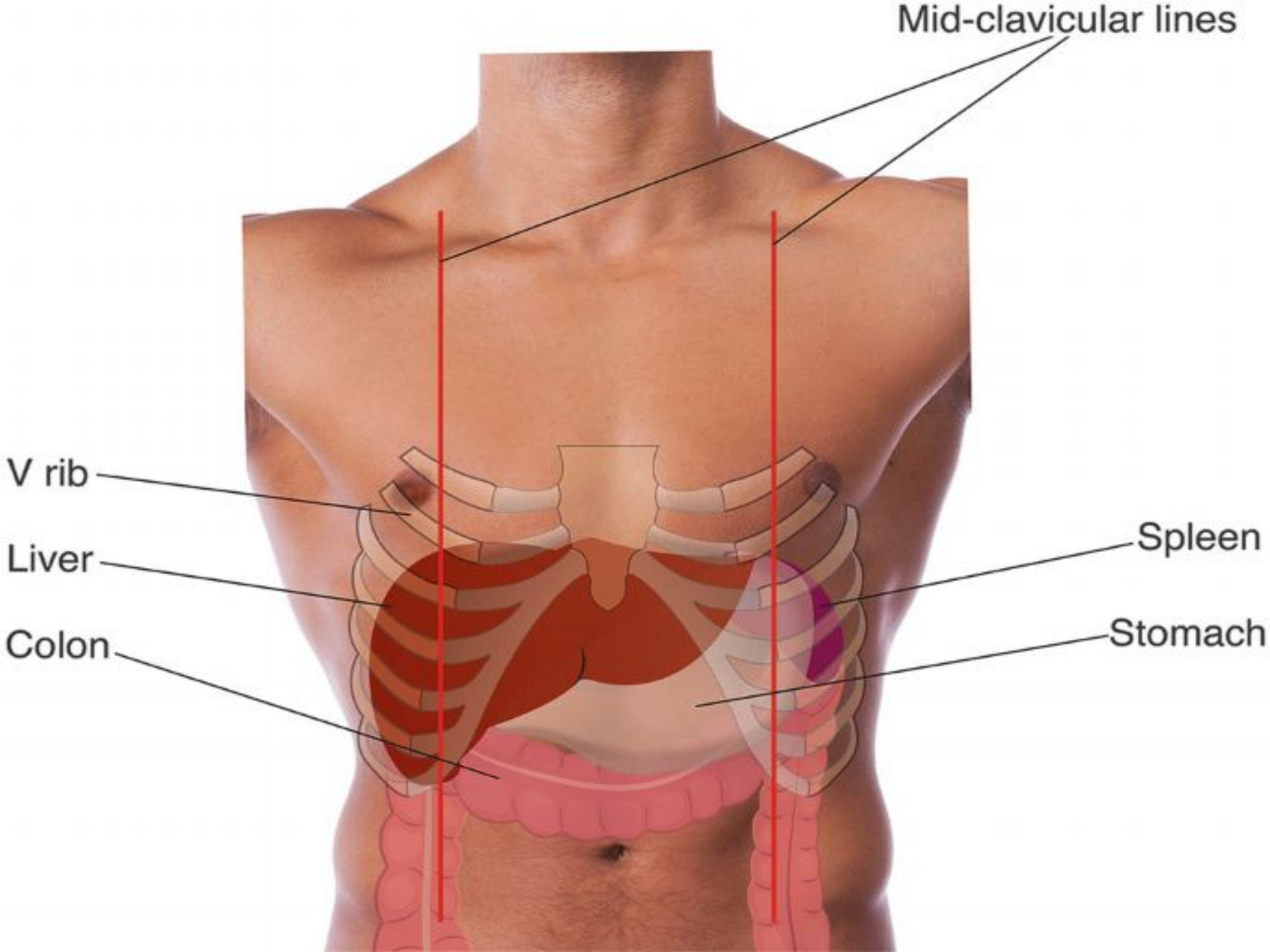
Mid-clavicular lines
V rib
Liver
Colon
Spleen
Stomach

Vasculature of the liver	
Type of vessel	**Vessels**
Arteries	•**Dual blood supply** • **Hepatic artery proper** (supplies 20–40% of blood): a branch of the common hepatic artery, which branches off the celiac trunk of the abdominal aorta • **Portal vein** (supplies 60–80% of blood) • Forms from the superior mesenteric vein (SMV) and splenic vein • Collects blood from gastrointestinal tract, spleen, and pancreas • Despite being deoxygenated, it still supplies the liver with about half its oxygen demands. • Delivers nutrients and other metabolites
Veins	•Hepatic veins, which drain into the inferior vena cava
Lymphatics	•Celiac lymph node cluster

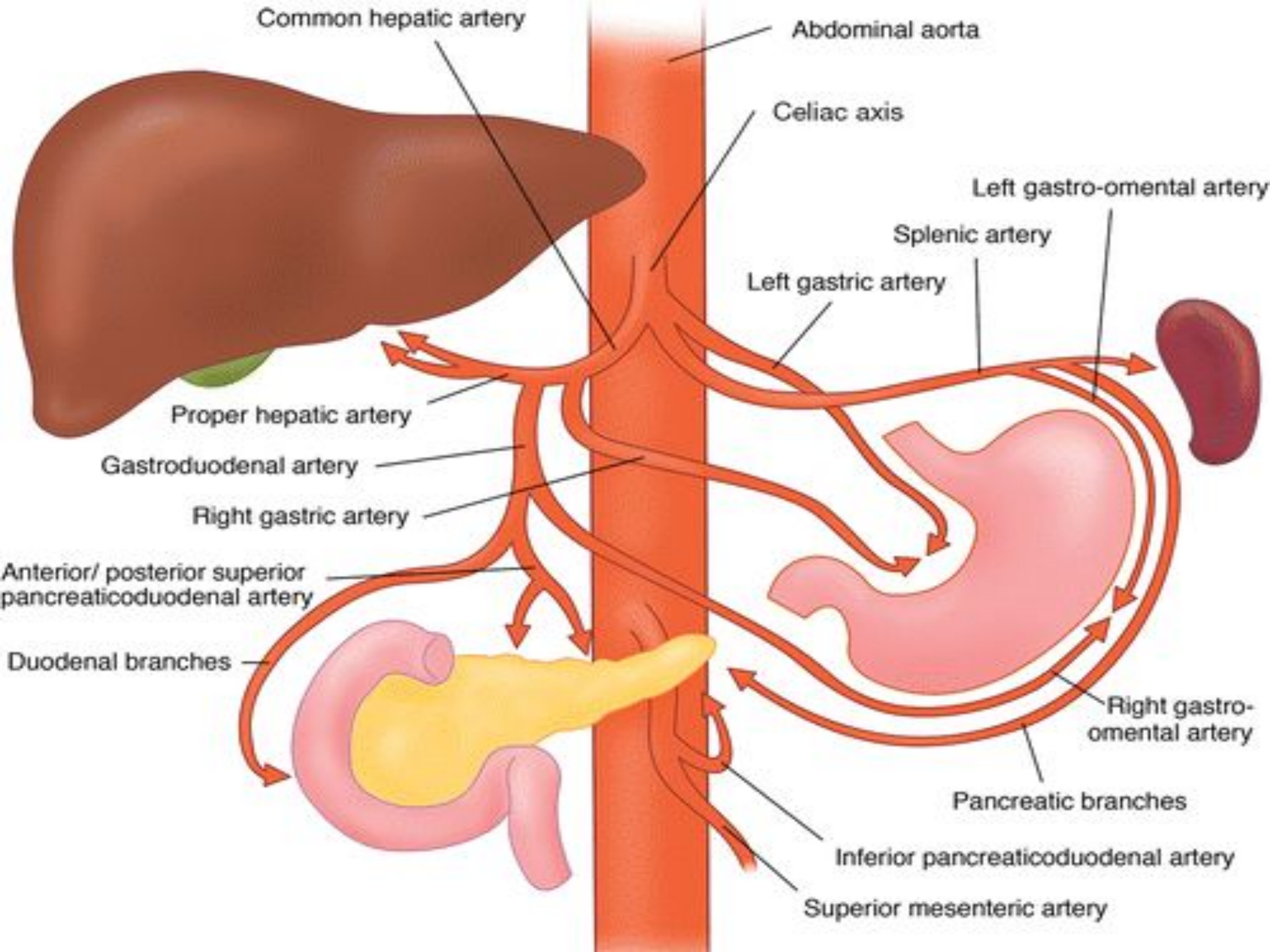
Common hepatic artery
Abdominal aorta
Celiac axis
Left gastro-omental artery
Splenic artery
Left gastric artery
Proper hepatic artery
Gastroduodenal artery
Right gastric artery
Anterior/ posterior superior pancreaticoduodenal artery
Duodenal branches
Right gastro-omental artery
Pancreatic branches
Inferior pancreaticoduodenal artery
Superior mesenteric artery

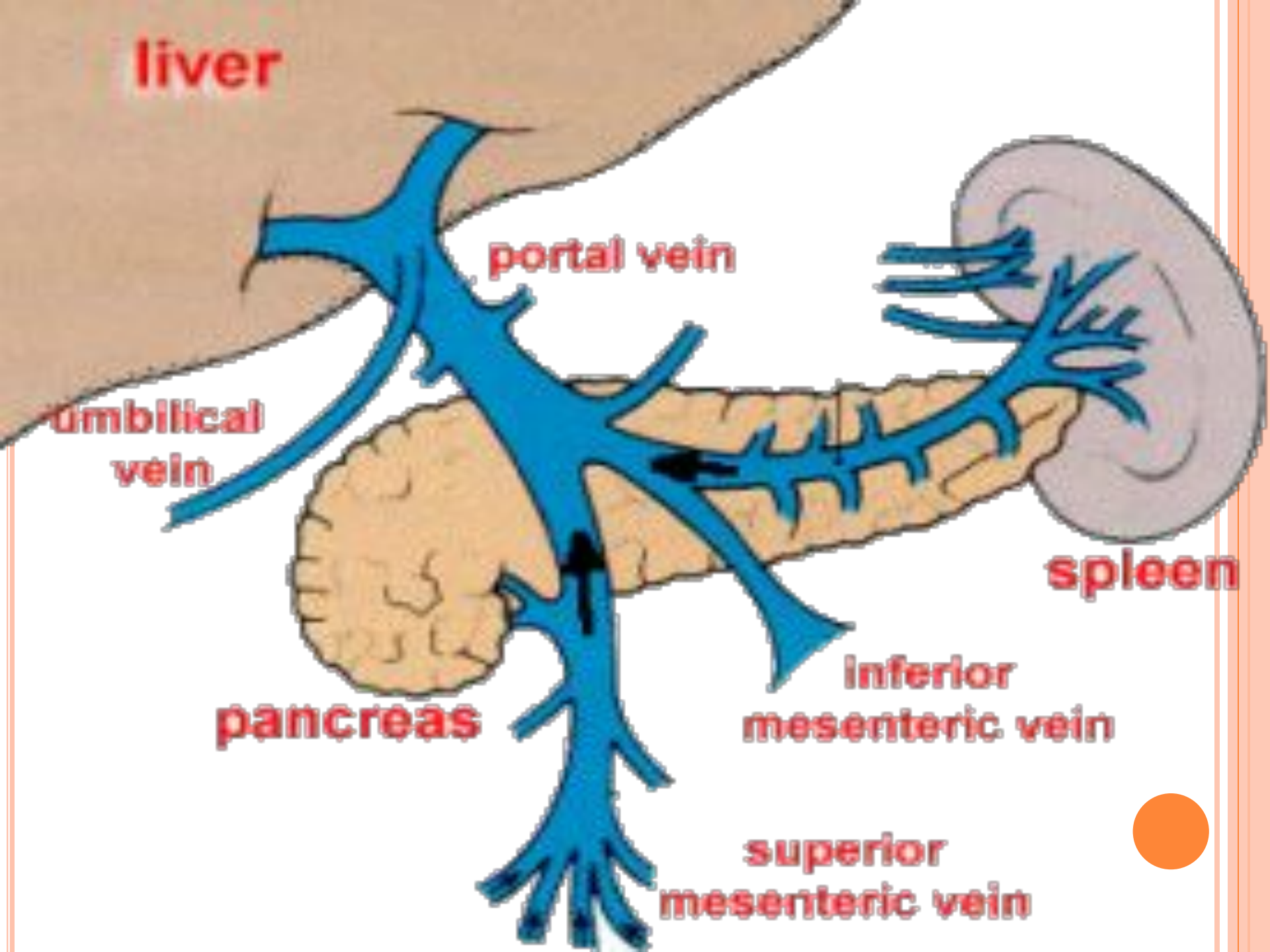
liver
portal vein
umbilical vein
spleen
pancreas
inferior mesenteric vein
superior mesenteric vein

Vascular segments of the liver

- There are 8 vascular segments of the liver.
- Each functional segment is divided into 4 vascular segments
- Each segment
- Is supplied by branches of hepatic artery and portal vein
- Is drained by a radicle to hepatic duct



ANATOMIC LIVER SEGMENTS

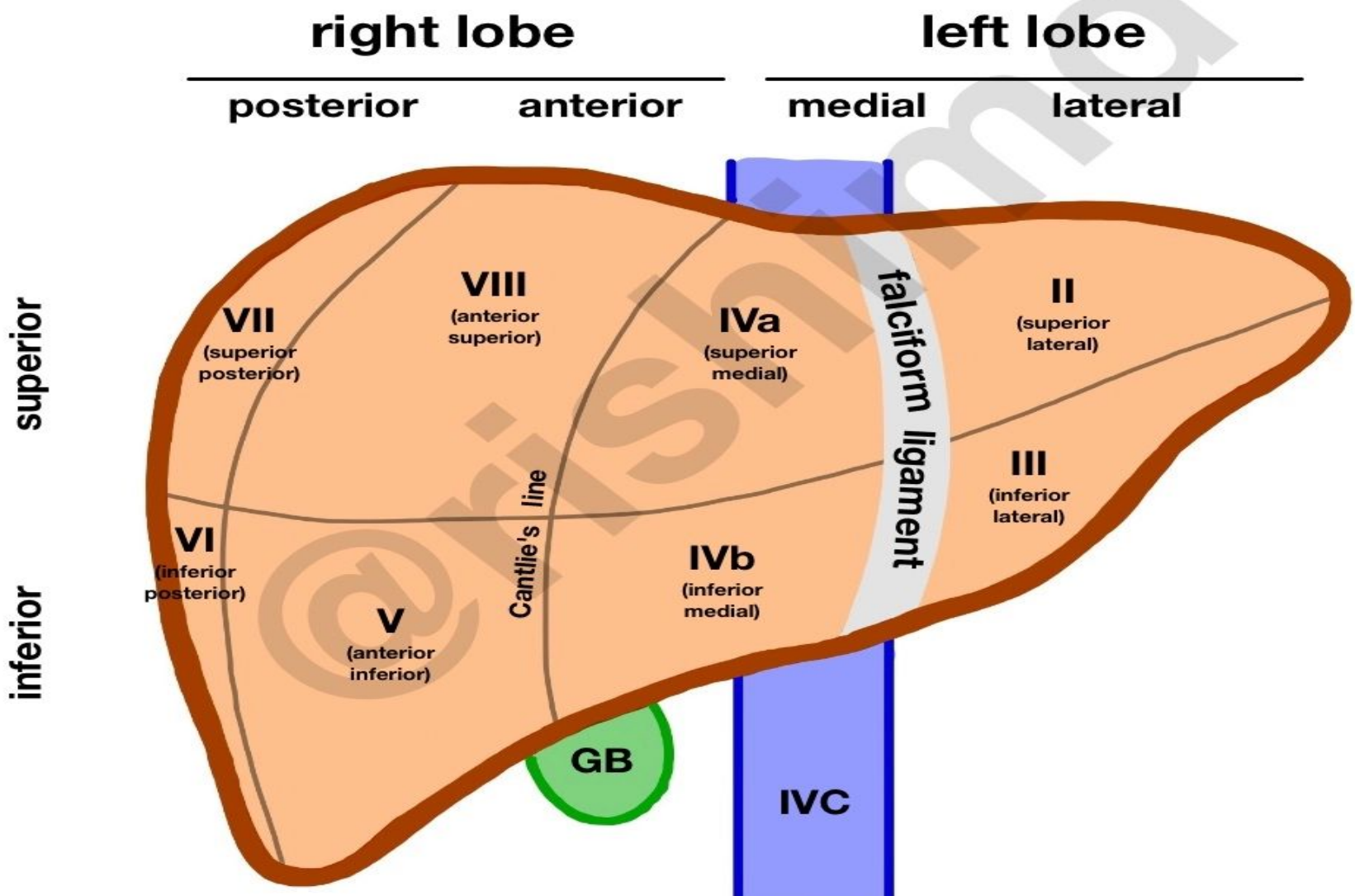

@rishmd

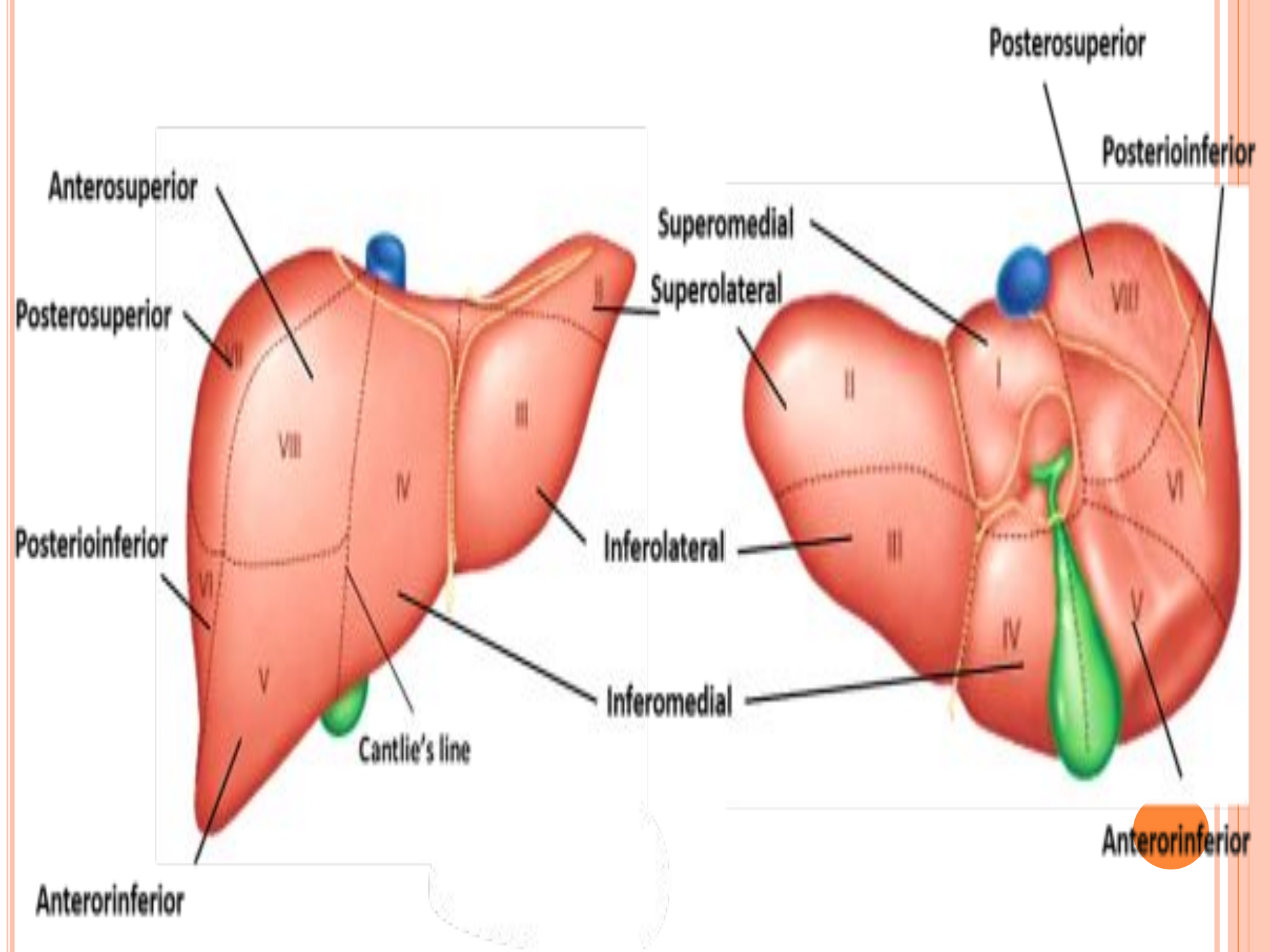
Anterosuperior
Posterosuperior
Posterioinferior
Anterorinferior
Cantlie's line
Superomedial
Superolateral
Inferolateral
Inferomedial
Posterosuperior
Posterioinferior
Anterorinferior

Epiploic foramen (foramen of Winslow)

- Peritoneal passage connecting greater sac and lesser sac
- Anterior: hepatoduodenal ligament
- Posterior: IVC
- Superior: caudate lobe of the liver
- Inferior: first part of the duodenum
- The anterior edge of the epiploic foramen is clamped during the Pringle maneuver.
- Site of internal hernia (rare)



Omental (Epiploic) Foramen

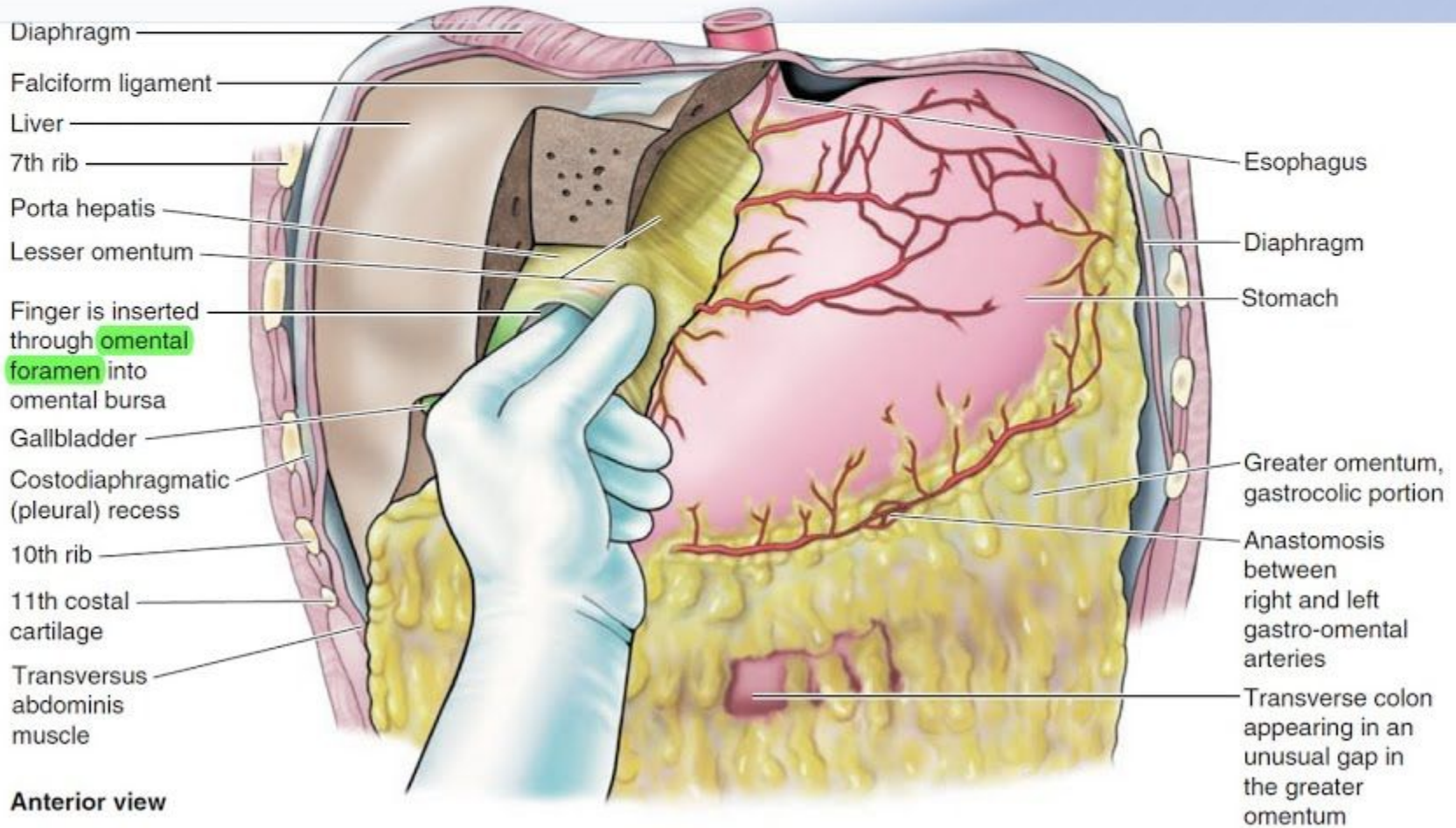

Anterior view

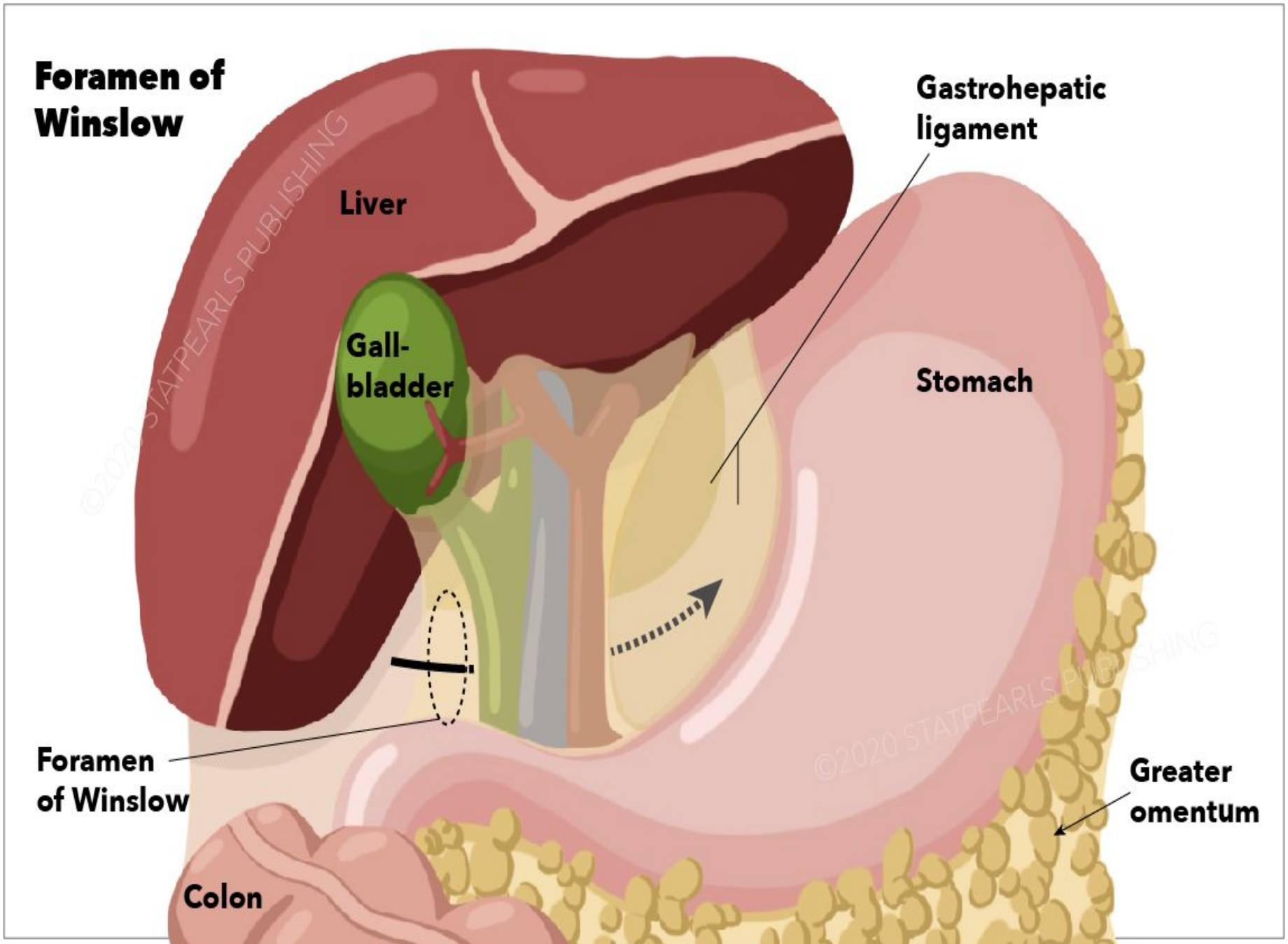
Foramen of Winslow
Gastrohepatic ligament
Liver
Gall-bladder
Stomach
Foramen of Winslow
Greater omentum
Colon
©2020 STATPEARLS PUBLISHING

GallBladder

- **Location**: intraperitoneal organ
- **Size and volume**
  - Length: 7–10 cm
  - Width: 2.5 cm (at its widest point)
  - Volume
    - 30–35 mL under normal conditions
    - Can hold up to 300 mL if the cystic duct is obstructed



Composition/structure

- Fundus
- Body
- Neck: connects to the cystic duct → common hepatic duct → common bile duct

- Body of GB is related to

T colon

Junction of D1-D2

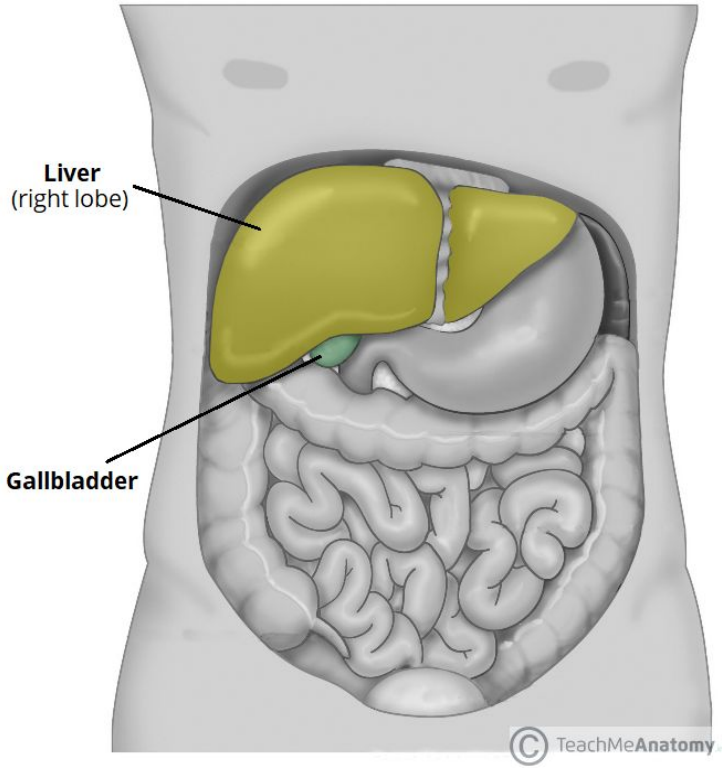

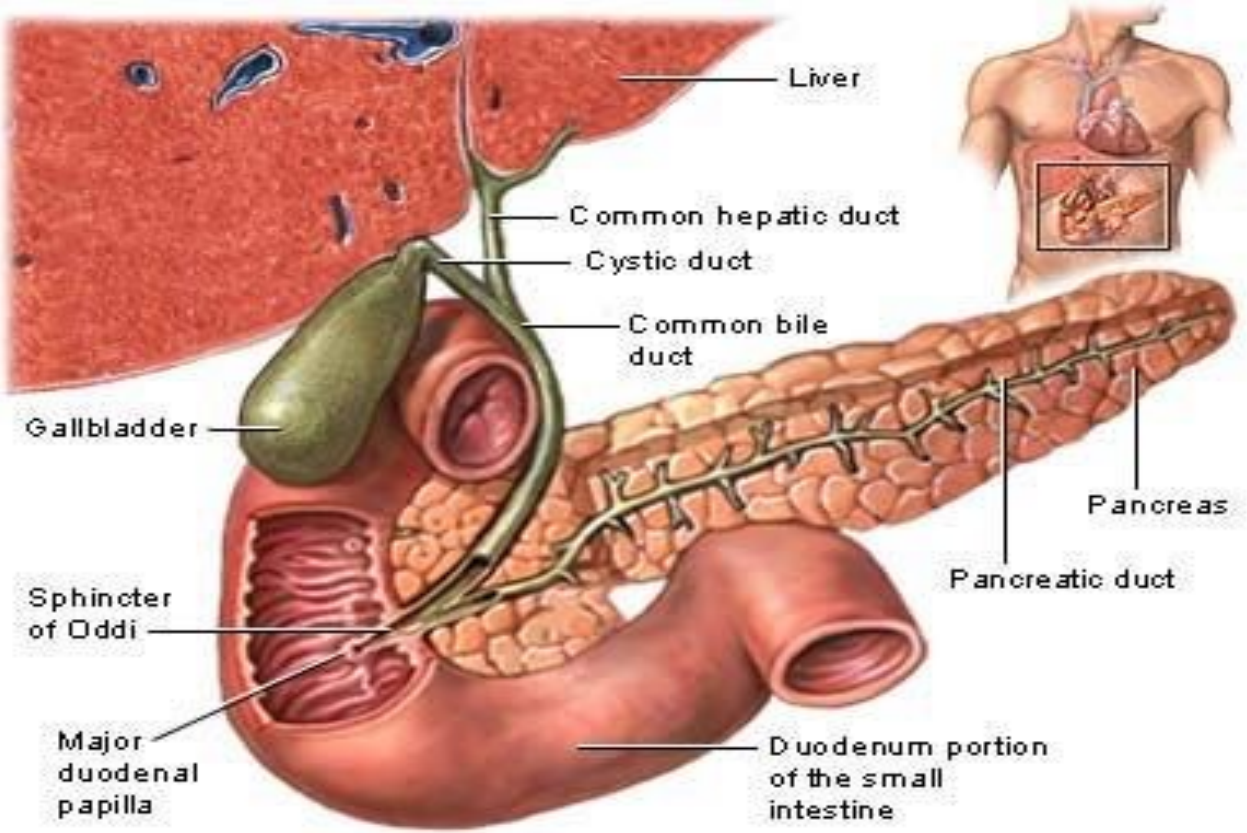
Liver
Common hepatic duct
Cystic duct
Common bile duct
Gallbladder
Pancreas
Pancreatic duct
Sphincter of Oddi
Major duodenal papilla
Duodenum portion of the small intestine

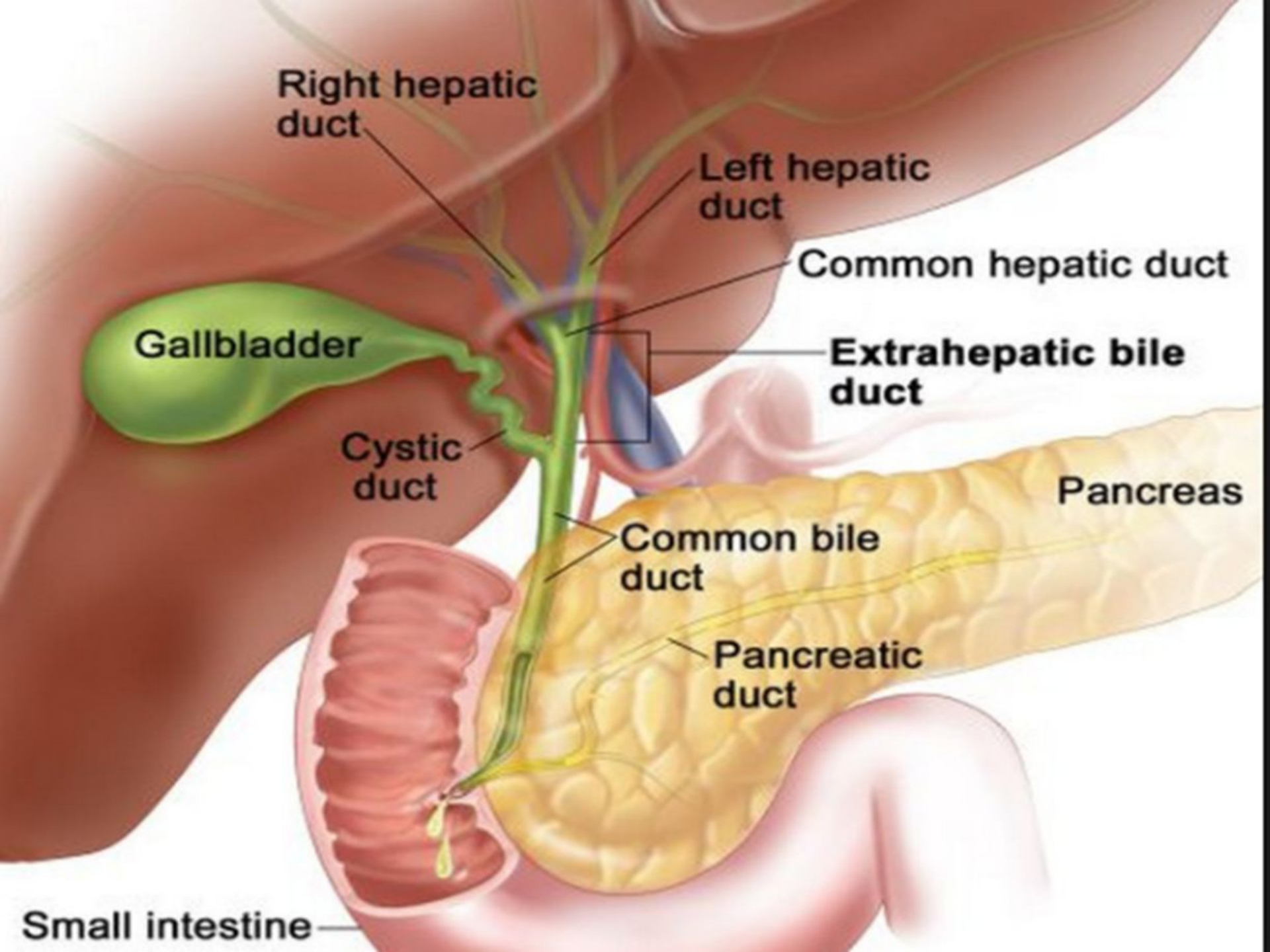
Right hepatic duct
Left hepatic duct
Common hepatic duct
Gallbladder
Extrahepatic bile duct
Cystic duct
Pancreas
Common bile duct
Pancreatic duct
Small intestine

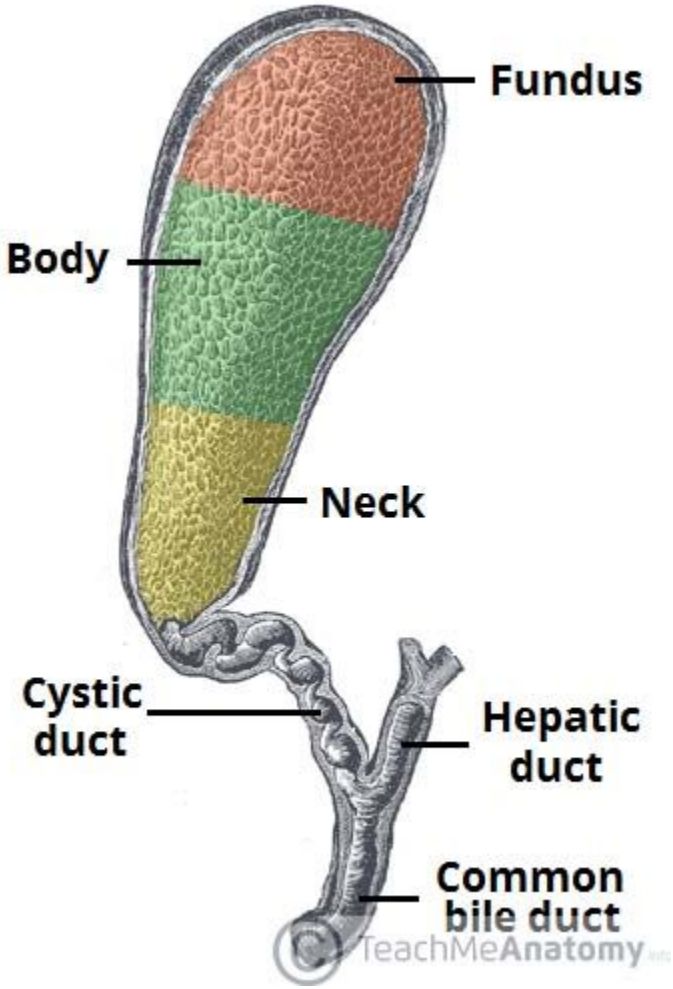
Fundus
Body
Neck
Cystic duct
Hepatic duct
Common bile duct
TeachMeAnatomy

Schematic view of interior of gallbladder and extrahepatic biliary tract

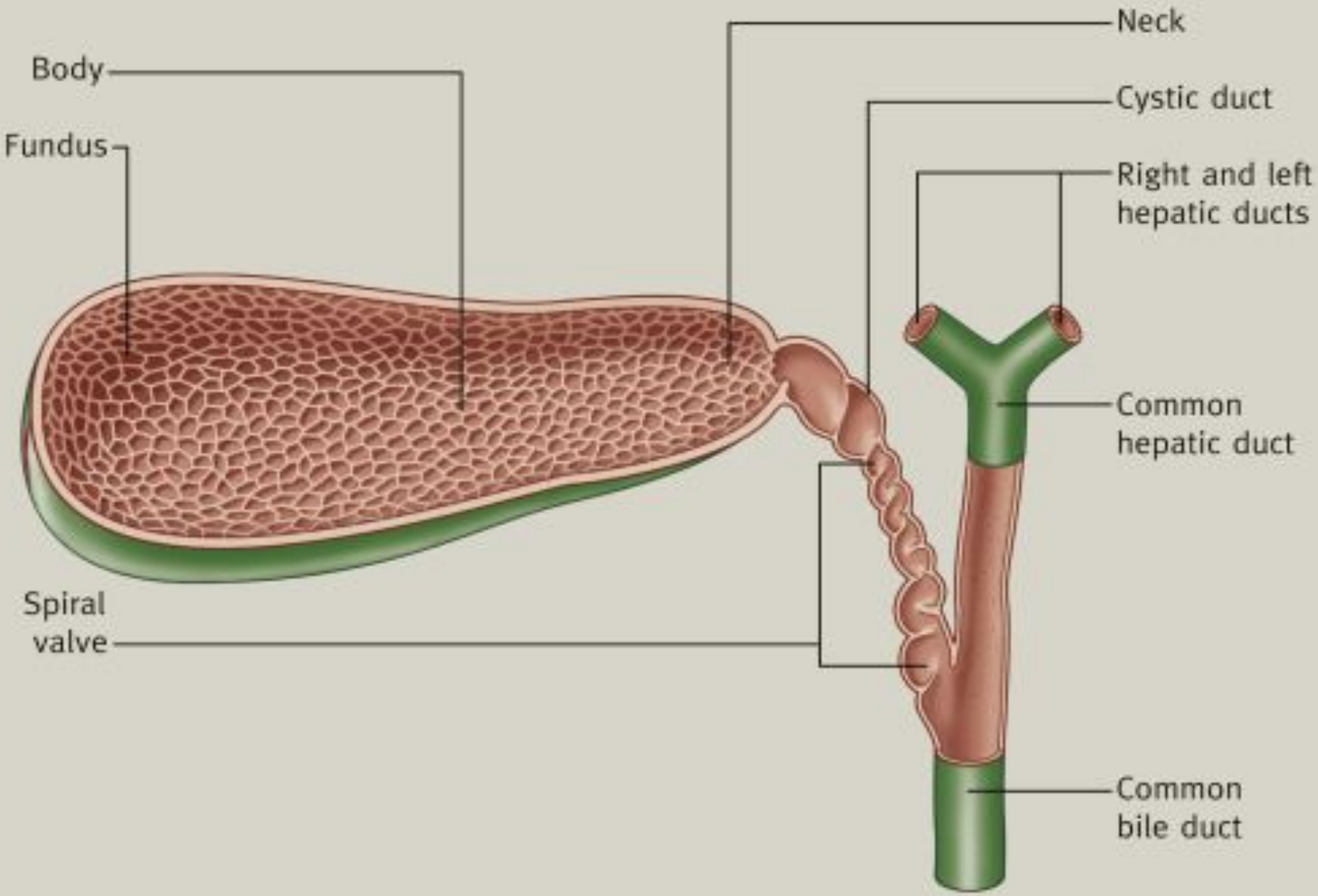

Vasculature

- **Arterial blood supply**: cystic artery (branch of the right hepatic artery)
- **Venous drainage**
  - Neck: cystic veins → portal vein
  - Body and fundus: hepatic sinusoids

Innervation

- **Sympathetic**: via the celiac plexus
- **Parasympathetic**: hepatic branch of the vagus nerve
- **Sensory**: fibers from the phrenic nerve → referred pain to the right shoulder area (via C3 nerve fibers)
- Cholecystitis causes referred pain to the right shoulder region because the phrenic nerve originates from spinal nerves C3–C5, which also provide somatic sensation to the shoulder area.

Surface anatomy of GB fundus

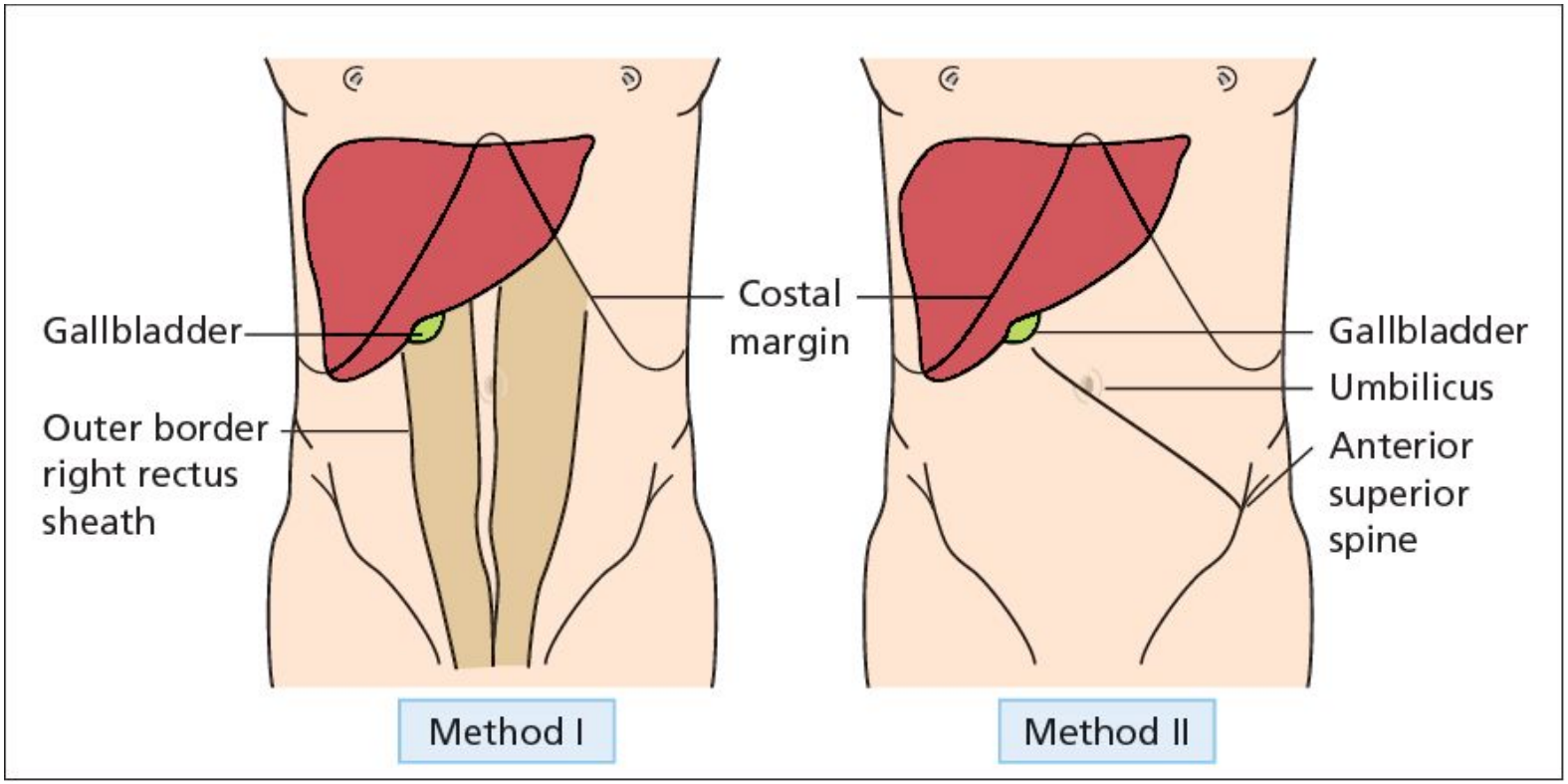

Surface anatomy of GB fundus

- The gallbladder area can be palpated **around the tip of the right ninth rib**. The normal gallbladder is impalpable; it only becomes palpable when distended with stones or bile, and the area will become very tender if there is inflammation present.



Common bile duct

- Formed by union of : CHD+ Cystic Duct- 3 Inches long.
- Descends down behind 1st part of D1.
- Joins the main pancreatic duct
- Opens in 2nd part of duodenum
- Through: Ampulla of Vater >>>Into major duodenal papilla

- Bile duct has 4 parts
- *In and just below porta hepatis*
- *In free margin of lesser* omentum: lie on Rt side of Hepatic artery
- *Behind D1 :*lie on Rt side of gastro duod a, infront of portal v
- *Behind head of pancreas;* Lie in front of IVC

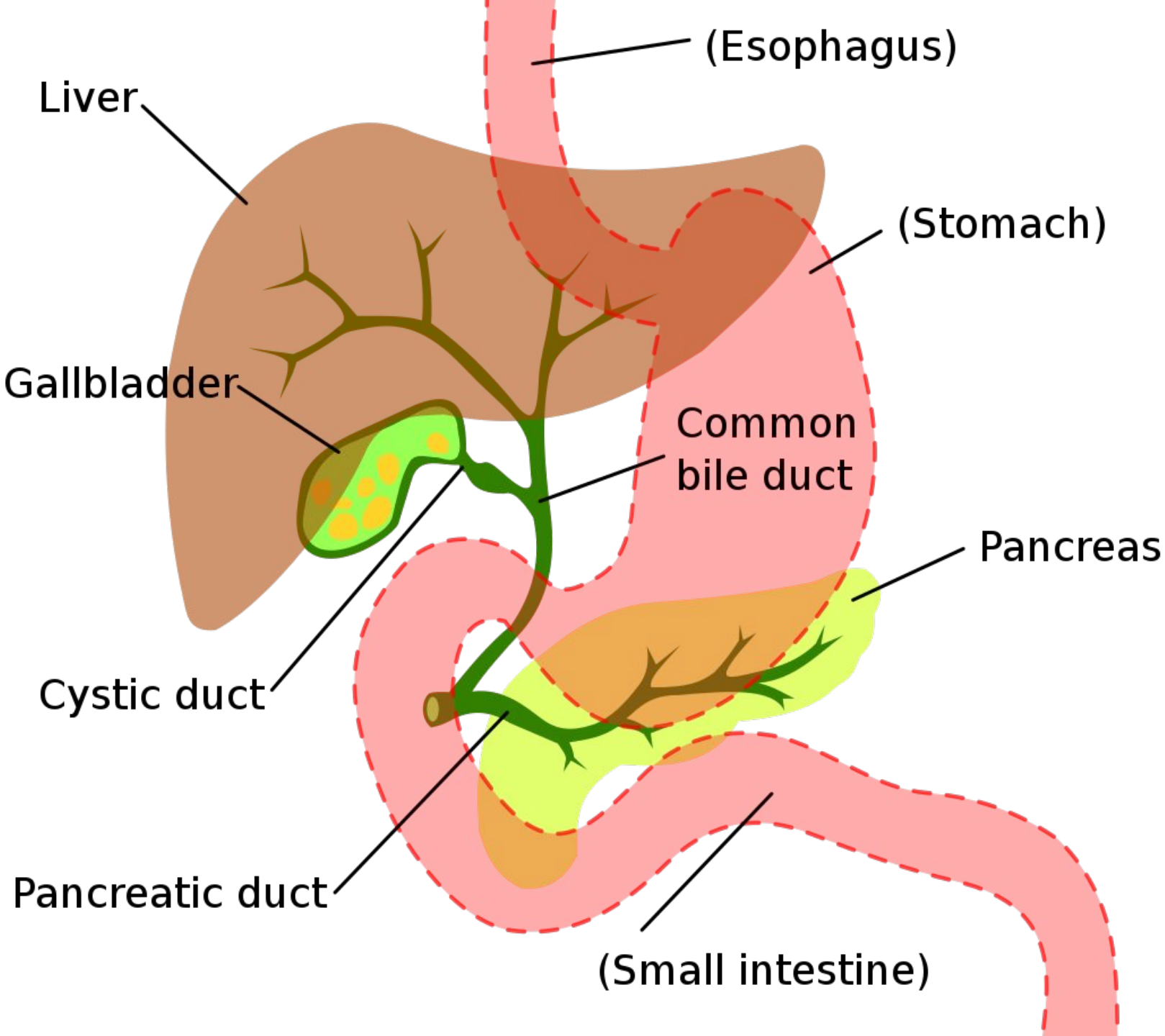
(Esophagus)
Liver
(Stomach)
Gallbladder
Common
bile duct
Pancreas
Cystic duct
Pancreatic duct
(Small intestine)

Ampulla of vater & major duodenl papilla

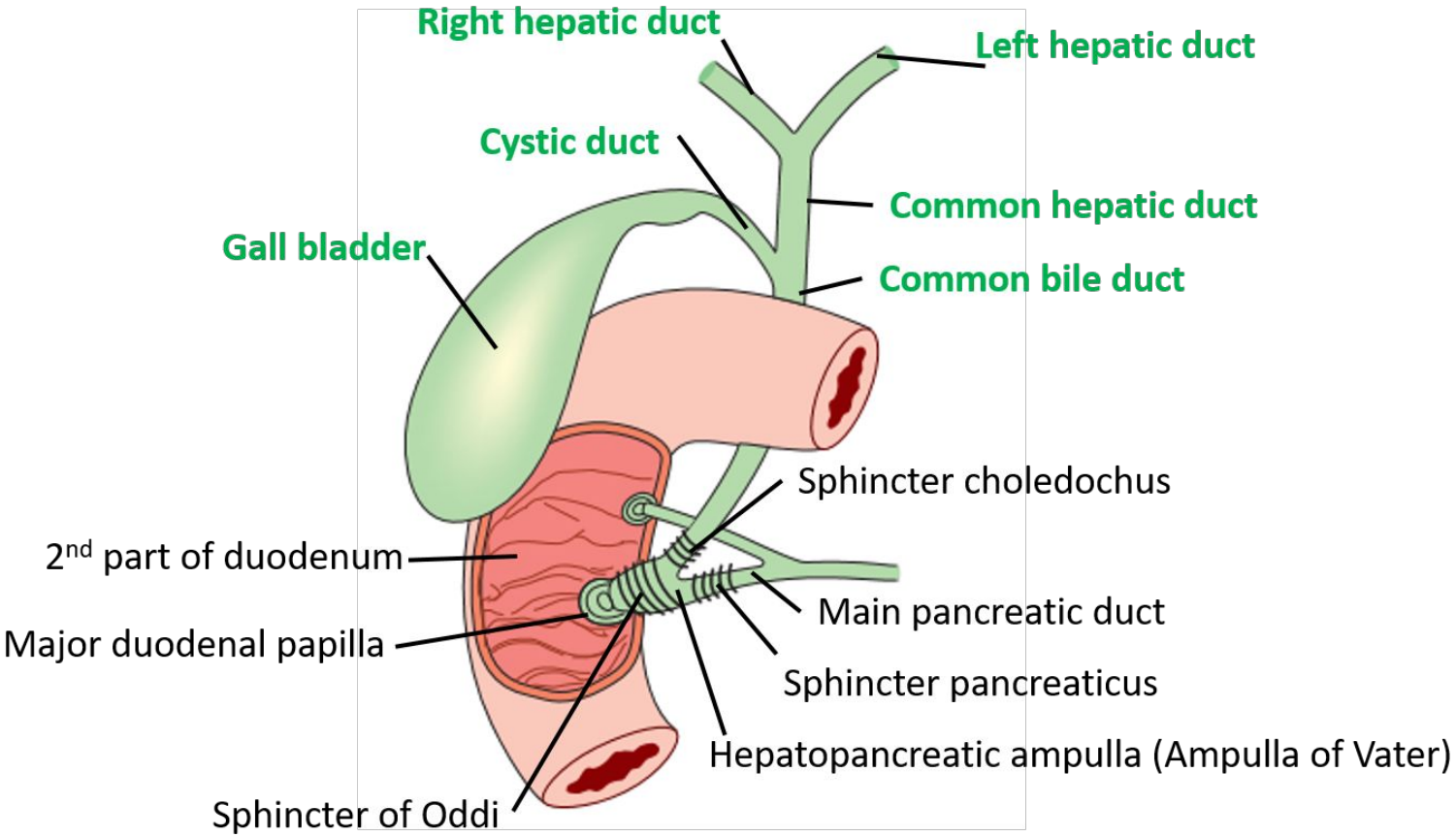

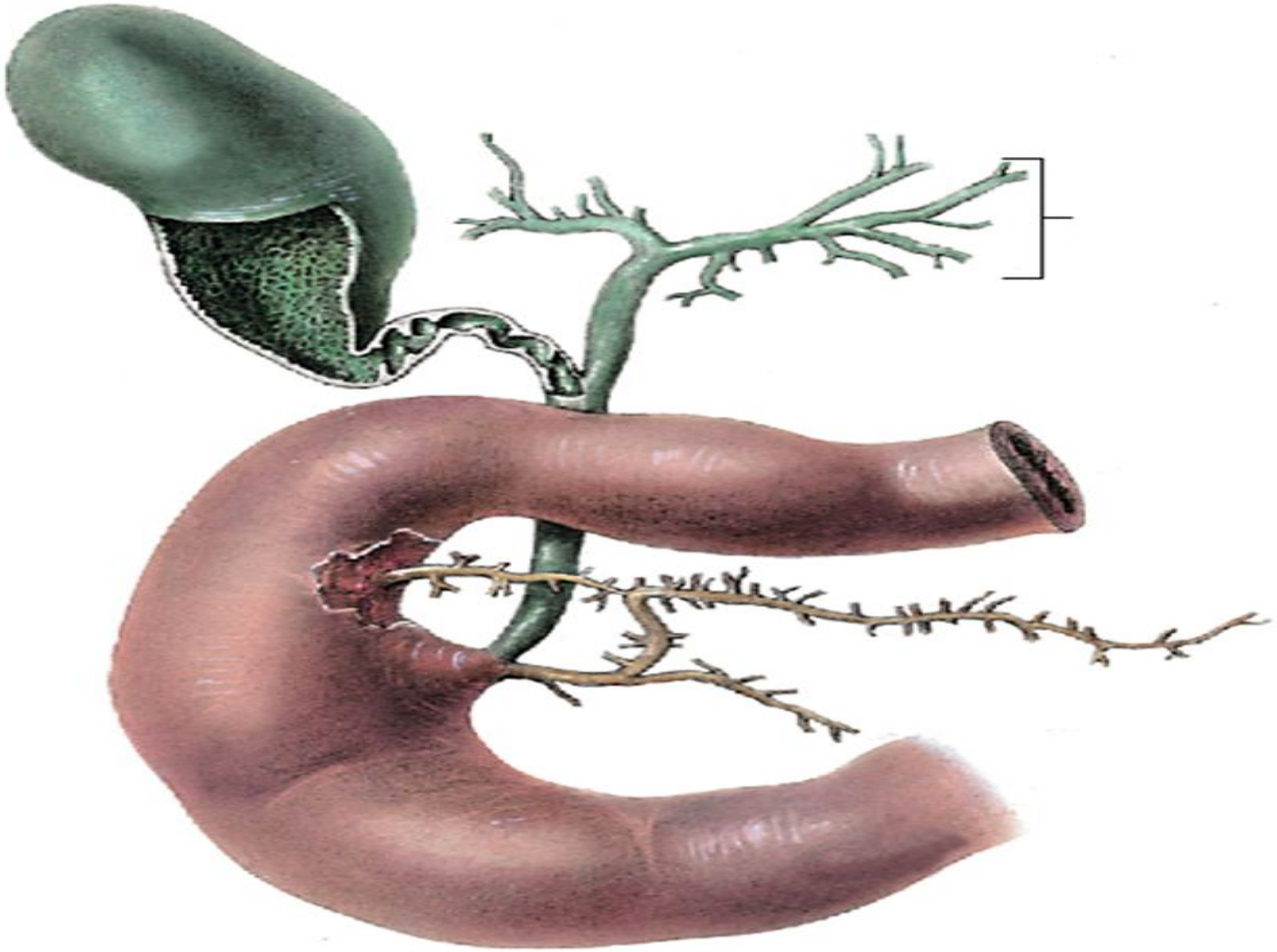

Calot's triangle

- an anatomical space formed by the common hepatic duct, the cystic duct, and the inf border of liver.
- Contents: cystic artery , rt hepatic artery and Cystic lymph nodes.

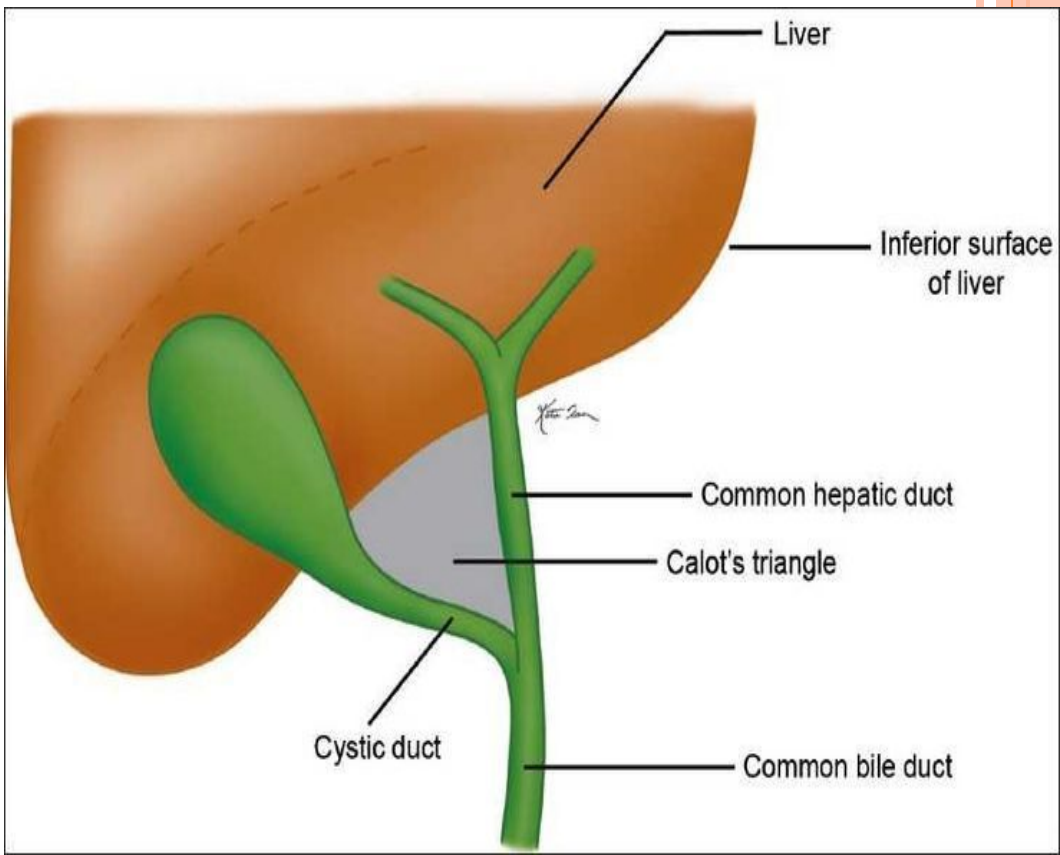

PANCREAS

- **Characteristics**
  - Glandular organ
  - Length: 12–15 cm
  - Weight: approx. 80 g
- **Location**

- In the abdominal cavity, between the duodenal curvature and the splenic hilum
- **retroperitoneal** organ except tail
- At vertebral level L1/L2

Anatomical subdivisions of the pancreas

- **Head**
  - Located within the C-shaped duodenal curvature
  - Contains the pancreatic duct and distal common bile duct
  - Uncinate process of pancreas: an extension of the pancreatic head that is located **posterior** to the superior mesenteric vessels (the remainder of the pancreas is not)
- **Neck**: lies anterior to the portal vein
- **Body**: lies anterior to the aorta and extends to the left kidney
- **Tail**
  - Lies in the splenorenal ligament and extends to the splenic hilum
  - The distal segment is **intraperitoneal**.

- The uncinate process is posterior to the superior mesenteric vessels. The head, body, and tail of the pancreas lie anterior to the superior mesenteric vessels.

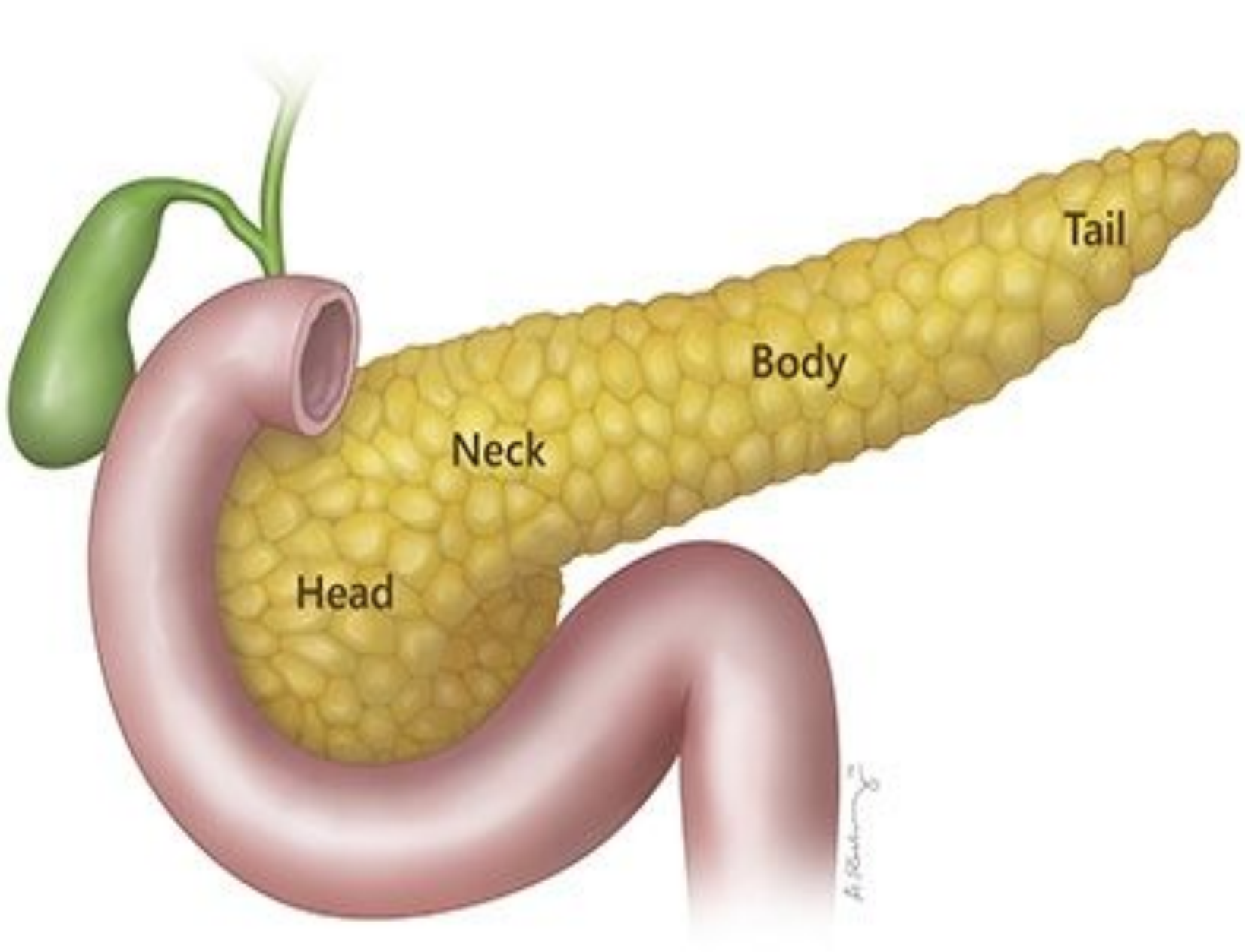

© 2016 Columbia University. All Rights Reserved.

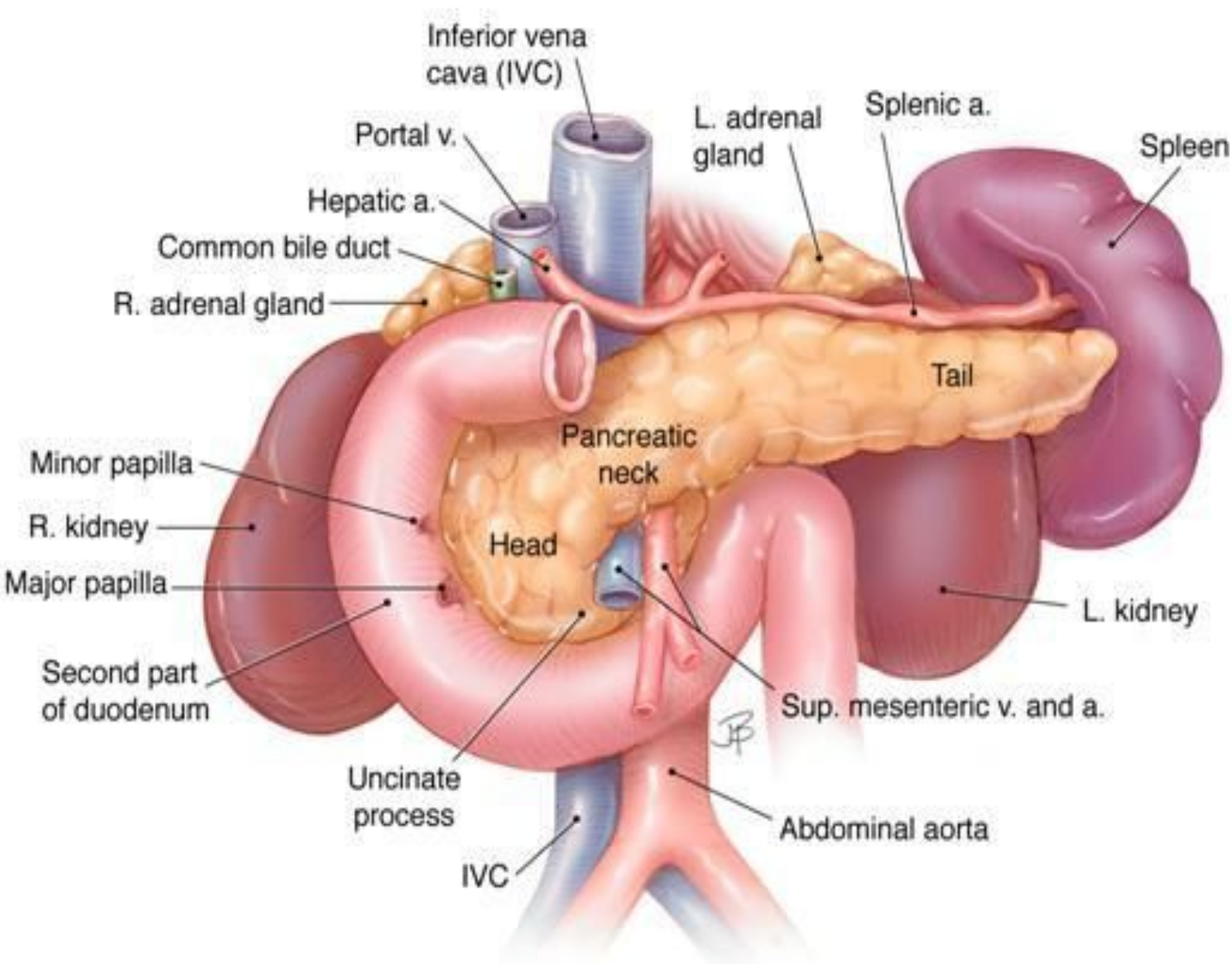
Inferior vena cava (IVC)
Portal v.
Hepatic a.
Common bile duct
R. adrenal gland
L. adrenal gland
Splenic a.
Spleen
Tail
Pancreatic neck
Head
Minor papilla
R. kidney
Major papilla
Second part of duodenum
Uncinate process
IVC
Sup. mesenteric v. and a.
Abdominal aorta
L. kidney

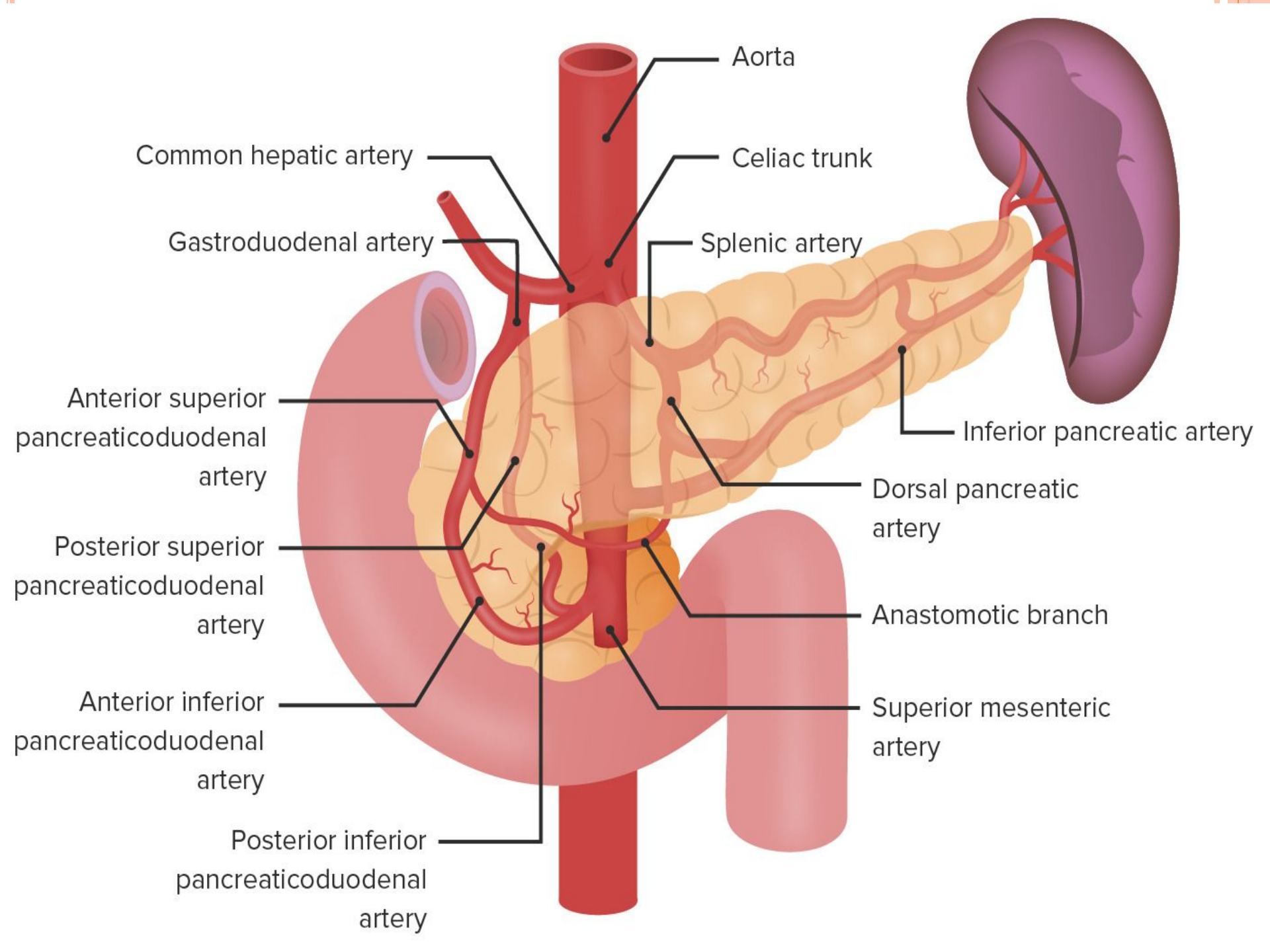
Aorta
Common hepatic artery
Celiac trunk
Gastroduodenal artery
Splenic artery
Anterior superior pancreaticoduodenal artery
Inferior pancreatic artery
Dorsal pancreatic artery
Posterior superior pancreaticoduodenal artery
Anastomotic branch
Anterior inferior pancreaticoduodenal artery
Superior mesenteric artery
Posterior inferior pancreaticoduodenal artery

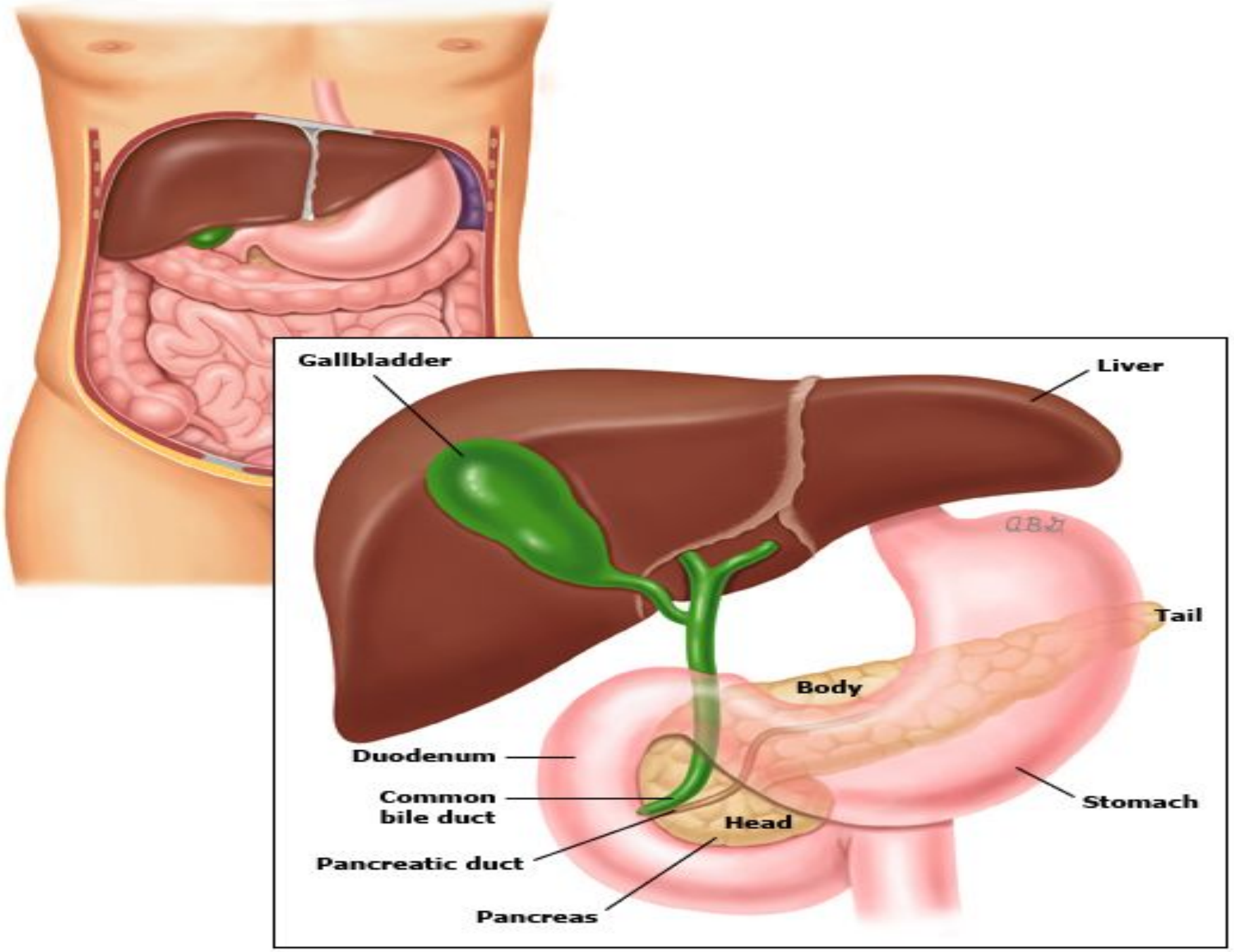
Gallbladder
Liver
Tail
Body
Duodenum
Common bile duct
Stomach
Head
Pancreatic duct
Pancreas

Pancreatic ducts

- Pancreatic duct (duct of Wirsung): extends from the tail to the head of the pancreas
  - Ventral pancreatic duct: drains the ventral bud of the developing pancreas; merges with the dorsal pancreatic duct to form the main pancreatic duct
  - Dorsal pancreatic duct: drains the dorsal bud of the developing pancreas; merges with the ventral pancreatic duct to form the main pancreatic duct
  - Joins with the common bile duct → together they form the hepatopancreatic ampulla (ampulla of Vater) → empties into the major duodenal papilla
  - Hepatopancreatic sphincter (sphincter of Oddi): controls the secretion of bile and pancreatic fluid into the duodenum
- Accessory pancreatic duct (duct of Santorini): begins in the head and drains the pancreatic head and body → empties at the minor duodenal papilla

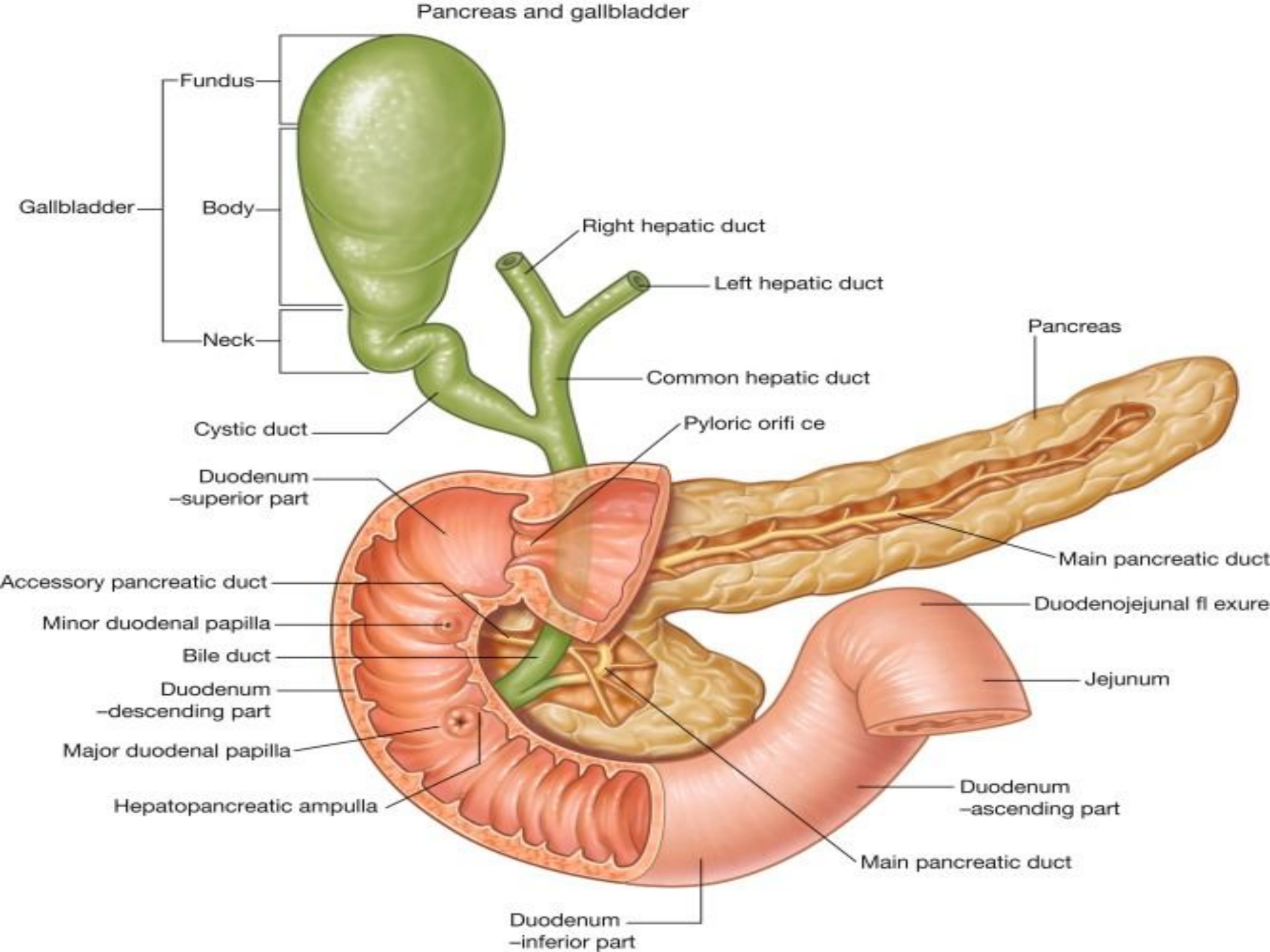
Pancreas and gallbladder
Fundus
Gallbladder
Body
Neck
Right hepatic duct
Left hepatic duct
Pancreas
Common hepatic duct
Cystic duct
Pyloric orifi ce
Duodenum
–superior part
Main pancreatic duct
Accessory pancreatic duct
Duodenojejunal fl exure
Minor duodenal papilla
Bile duct
Jejunum
Duodenum
–descending part
Major duodenal papilla
Hepatopancreatic ampulla
Duodenum
–ascending part
Main pancreatic duct
Duodenum
–inferior part

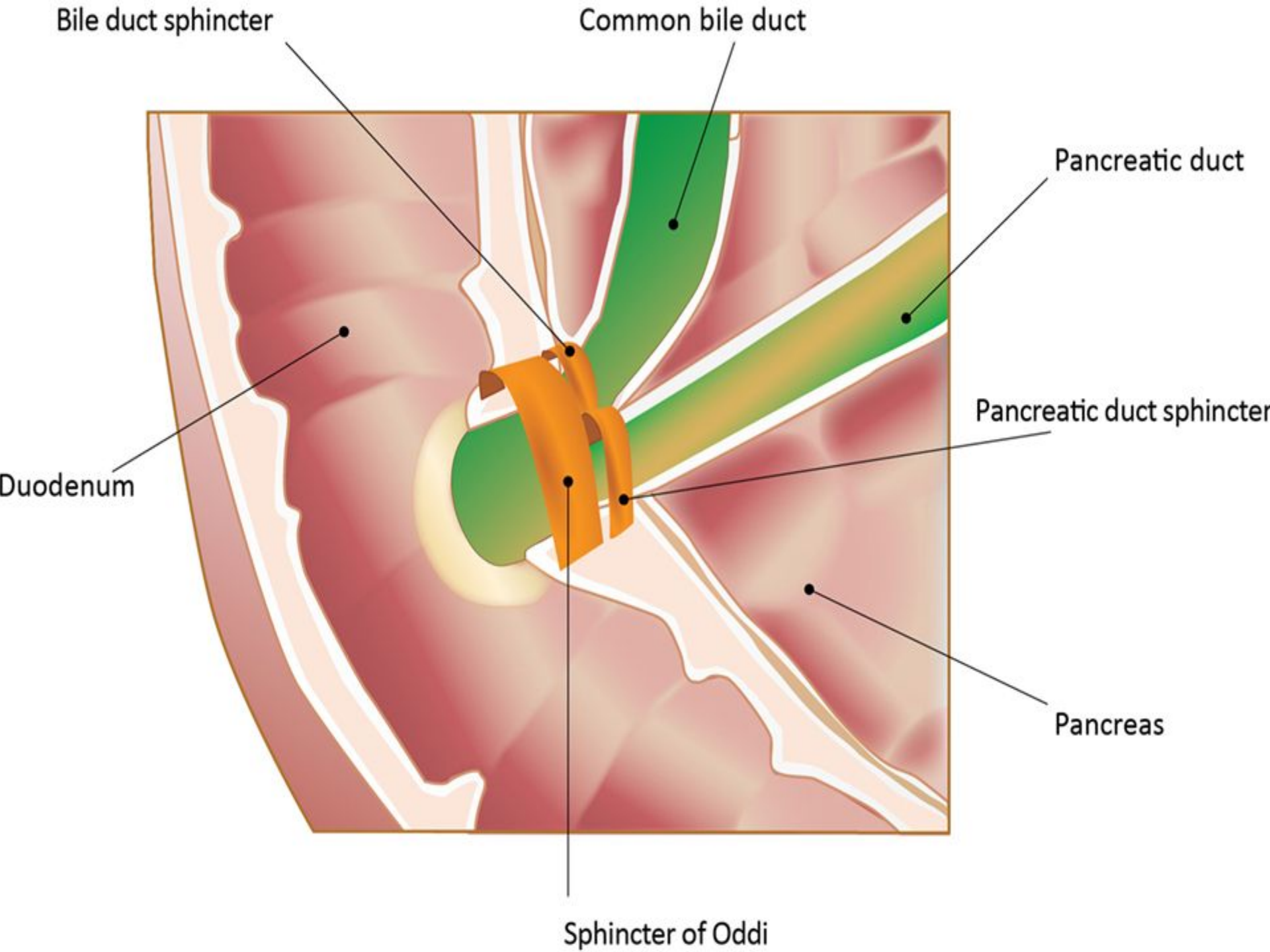
Bile duct sphincter
Common bile duct
Pancreatic duct
Duodenum
Pancreatic duct sphincter
Pancreas
Sphincter of Oddi

Tumors in the pancreatic head often cause bile duct obstruction and can manifest with painless jaundice

Gallstones that block the ampulla of Vater can result in both pancreatitis and cholangitis

Vasculature, lymphatics, and innervation of the pancreas

- **Arteries**
  - Head and neck
    - Superior pancreaticoduodenal branches (from the gastroduodenal artery)
    - Inferior pancreaticoduodenal branches (from the superior mesenteric artery)
  - Body and tail: branches of the splenic artery (itself a branch of the celiac trunk)
- **Veins**
  - Head and neck: pancreatic veins → superior mesenteric vein → portal vein
  - Body and tail: pancreatic veins → splenic vein → portal vein

- **Lymphatics**: celiac, superior mesenteric, and splenic lymph nodes → paraaortic lymph nodes
- **Innervation**: celiac ganglia
  - Sympathetic fibers from T6–12
  - Parasympathetic fibers from the vagus nerve

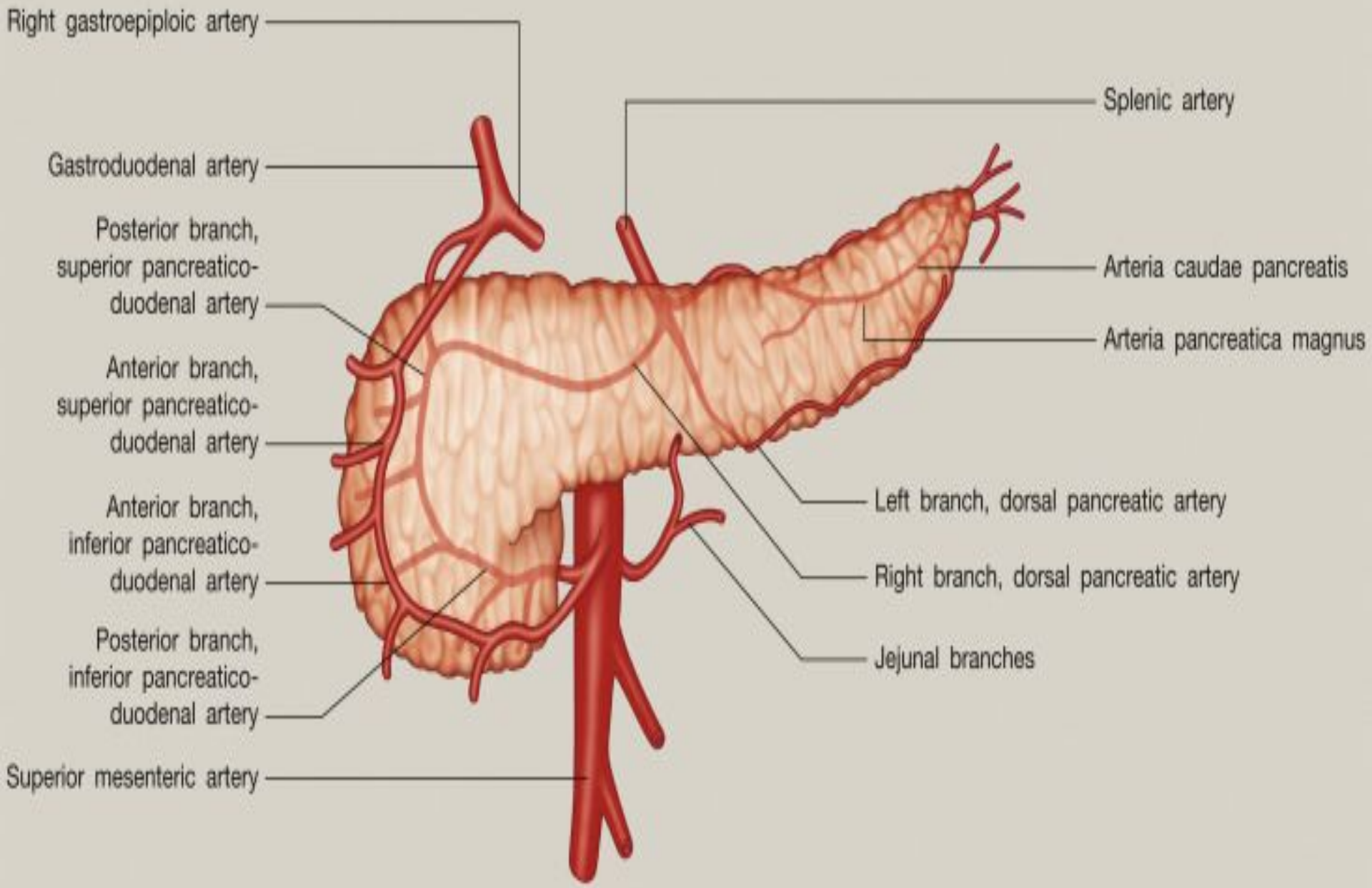
Right gastroepiploic artery
Splenic artery
Gastroduodenal artery
Posterior branch, superior pancreatico-duodenal artery
Arteria caudae pancreatis
Arteria pancreatica magnus
Anterior branch, superior pancreatico-duodenal artery
Left branch, dorsal pancreatic artery
Anterior branch, inferior pancreatico-duodenal artery
Right branch, dorsal pancreatic artery
Posterior branch, inferior pancreatico-duodenal artery
Jejunal branches
Superior mesenteric artery

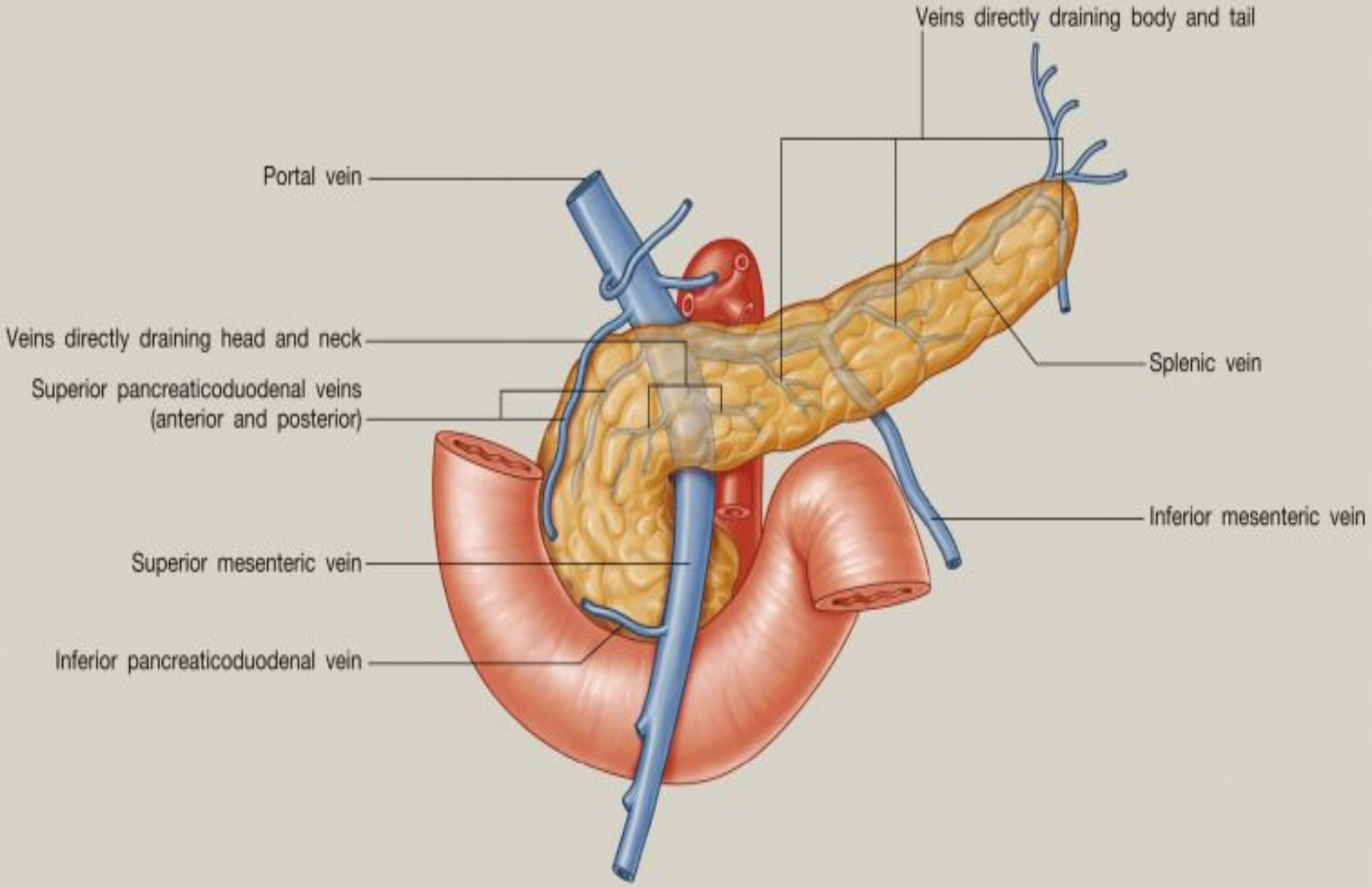
Veins directly draining body and tail
Portal vein
Veins directly draining head and neck
Superior pancreaticoduodenal veins
(anterior and posterior)
Splenic vein
Inferior mesenteric vein
Superior mesenteric vein
Inferior pancreaticoduodenal vein

Intraperitoneal vs. Retroperitoneal

- Stomach
- Part 1 of duodenum
- Jejunum, Ileum
- Cecum, Appendix
- Transverse colon
- Sigmoid colon
- Liver, Gallbladder
- Tail of pancreas
- Spleen

- Parts 2,3,4 duodenum
- Ascending, Descending colon
- Rectum
- Head, neck, body of pancreas
- Kidneys, ureters
- Suprarenal gland
- Abdominal Aorta
- Inferior vena cava

***__Rule of Thumb__:

If it has a mesentery or mesogastrium component => __Intraperitoneal__

SPLEEN

- Coffee bean-shaped, intraperitoneal organ
- The spleen has two poles (superior and inferior) and two surfaces (diaphragmatic and visceral).
- Usually not palpable as it lies deep in the rib cage, but may be felt in individuals of slender build or those with splenomegaly.
- Fist size, 5 inches long 3 inches wide one inch thick, protected by rib cage.
- 150 Gm in weight

Location

- Left upper quadrant (LUQ) of the abdomen
- Protected by the left 9th to 11th ribs
- Neighboring structures of the spleen :
- Diaphragm (posterior and superior)
- Stomach (anterior and medial)
- Left kidney (inferior, medial, and posterior)
- Left colic flexure (inferior)
- Tail of the pancreas (at the hilum of the spleen)

Vasculature and innervation of the spleen

- Blood supply by splenic a
- It runs anterior to the left kidney and suprarenal gland, and posterior to the stomach, through the peritoneal splenorenal ligament and along the tail of the pancreas. Its tortuous course allows the spleen and stomach to distend without compromising their blood flow.



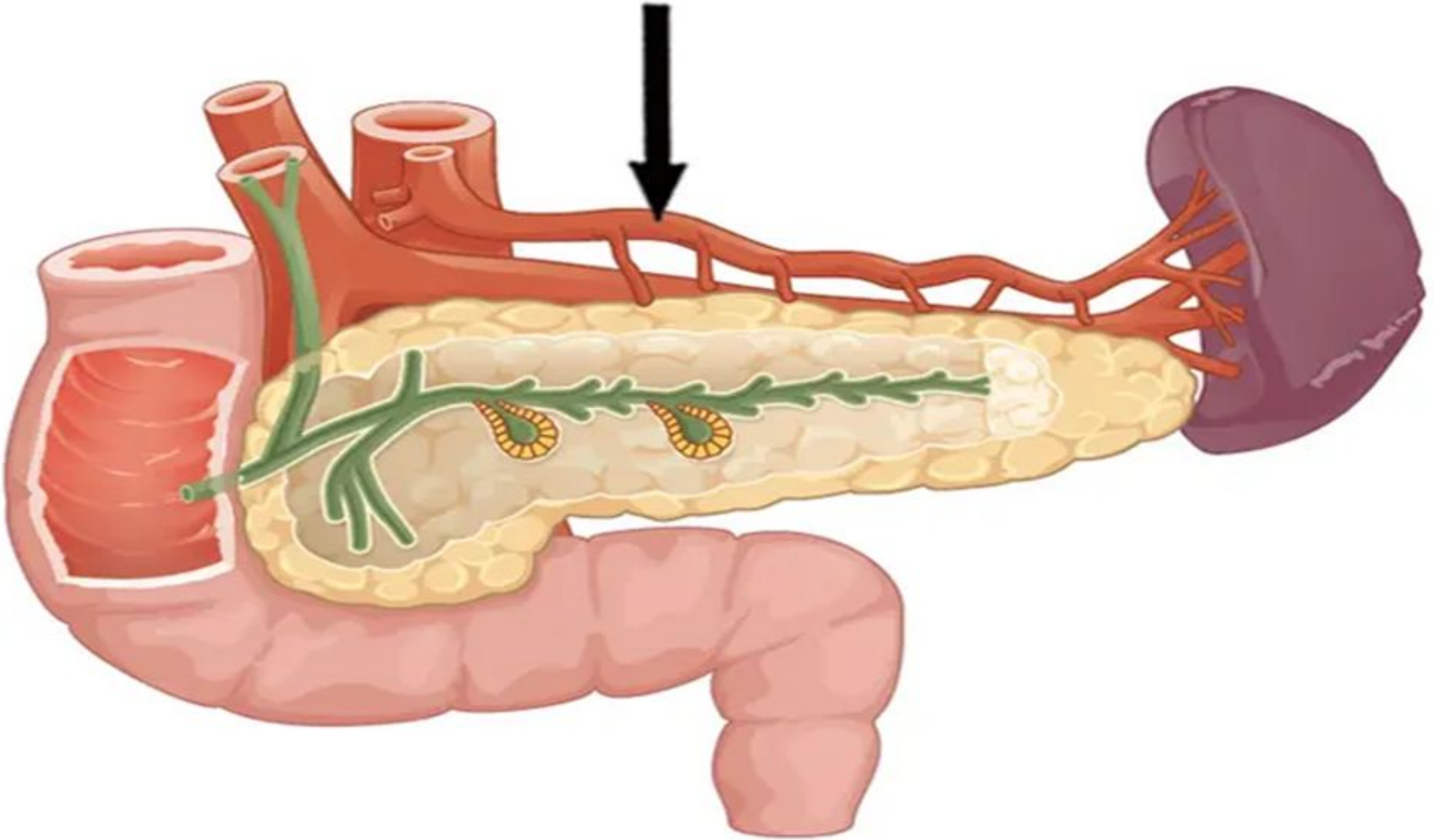

openstax™ COLLEGE

ANATOMYZONE

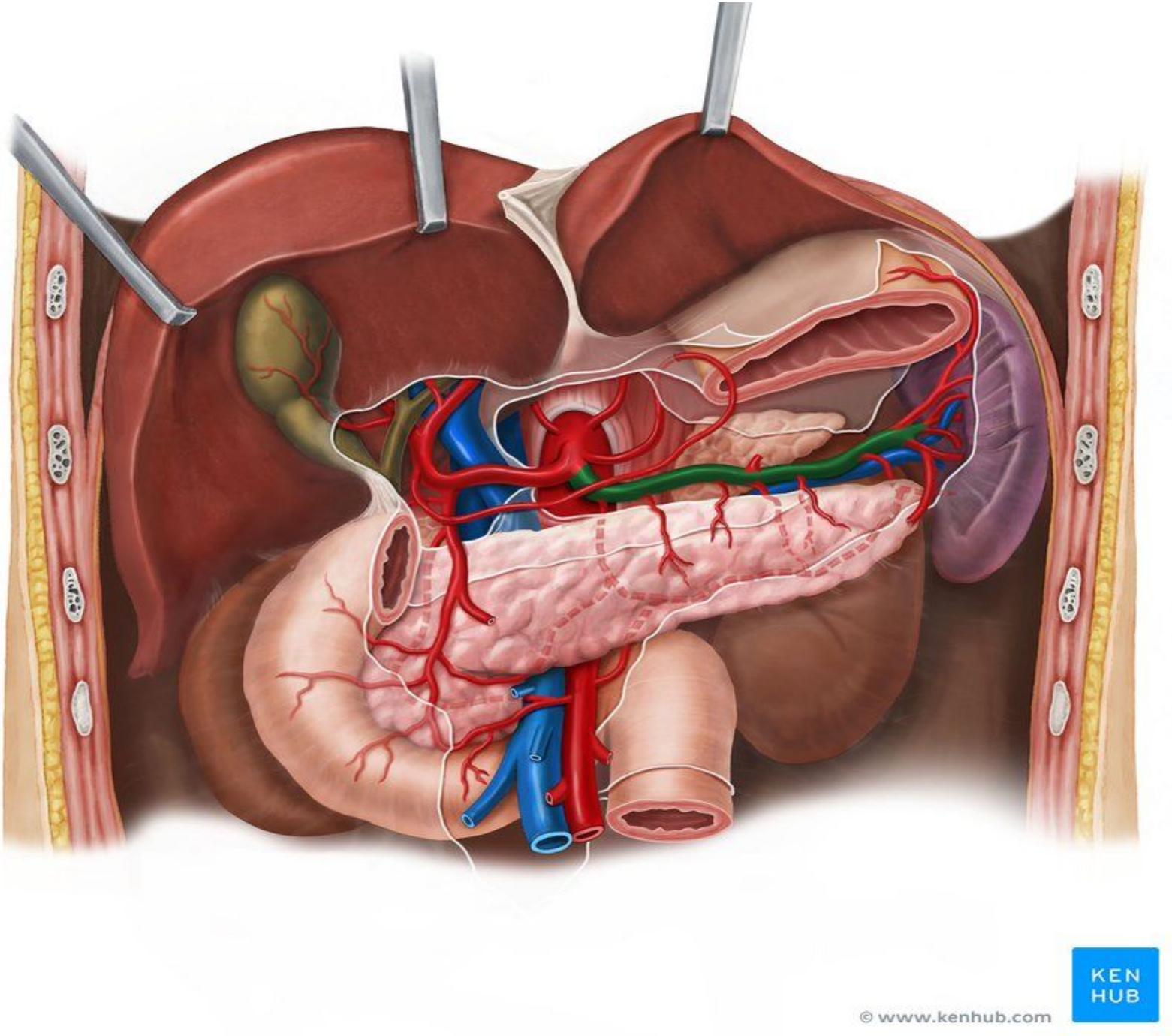
© www.kenhub.com
KEN
HUB

- Venous drainage by splenic vein
- Lymphatics>>Celiac nodes

-Follow course of splenic artery

- Innervation>>>Celiac plexus ,Vagus nerve

-Follow course of splenic artery

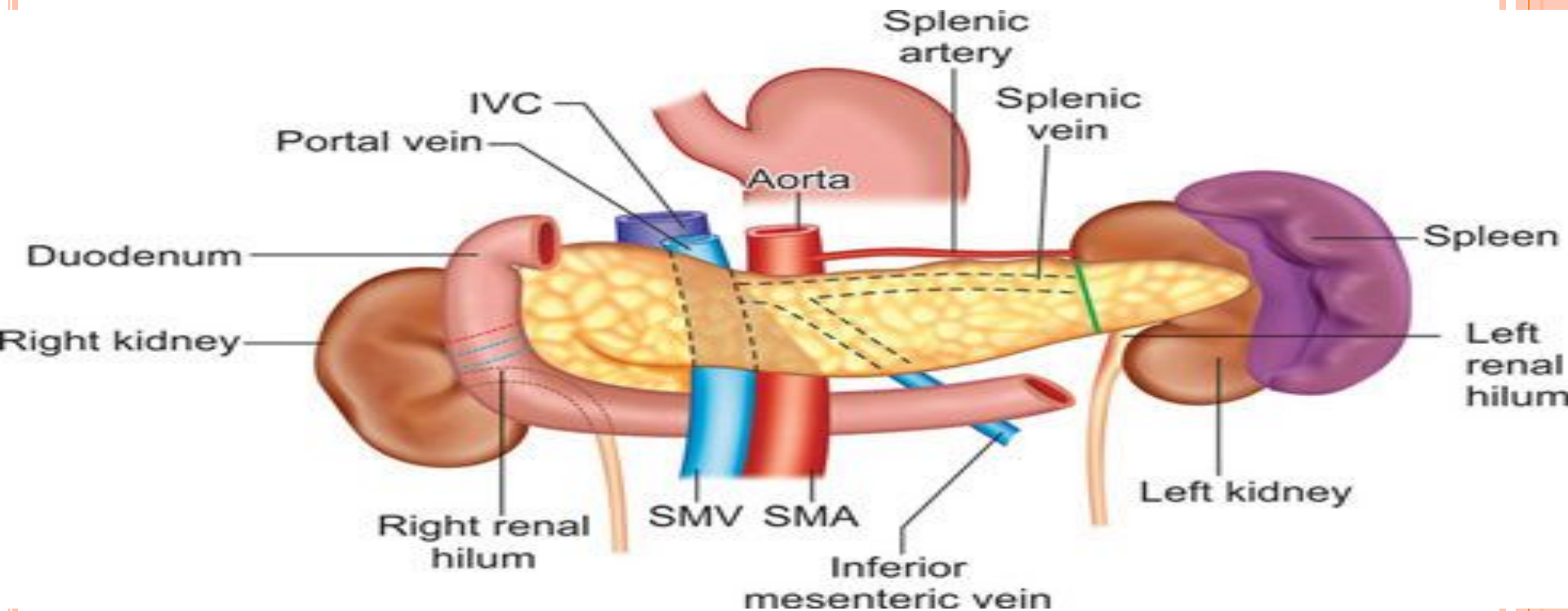

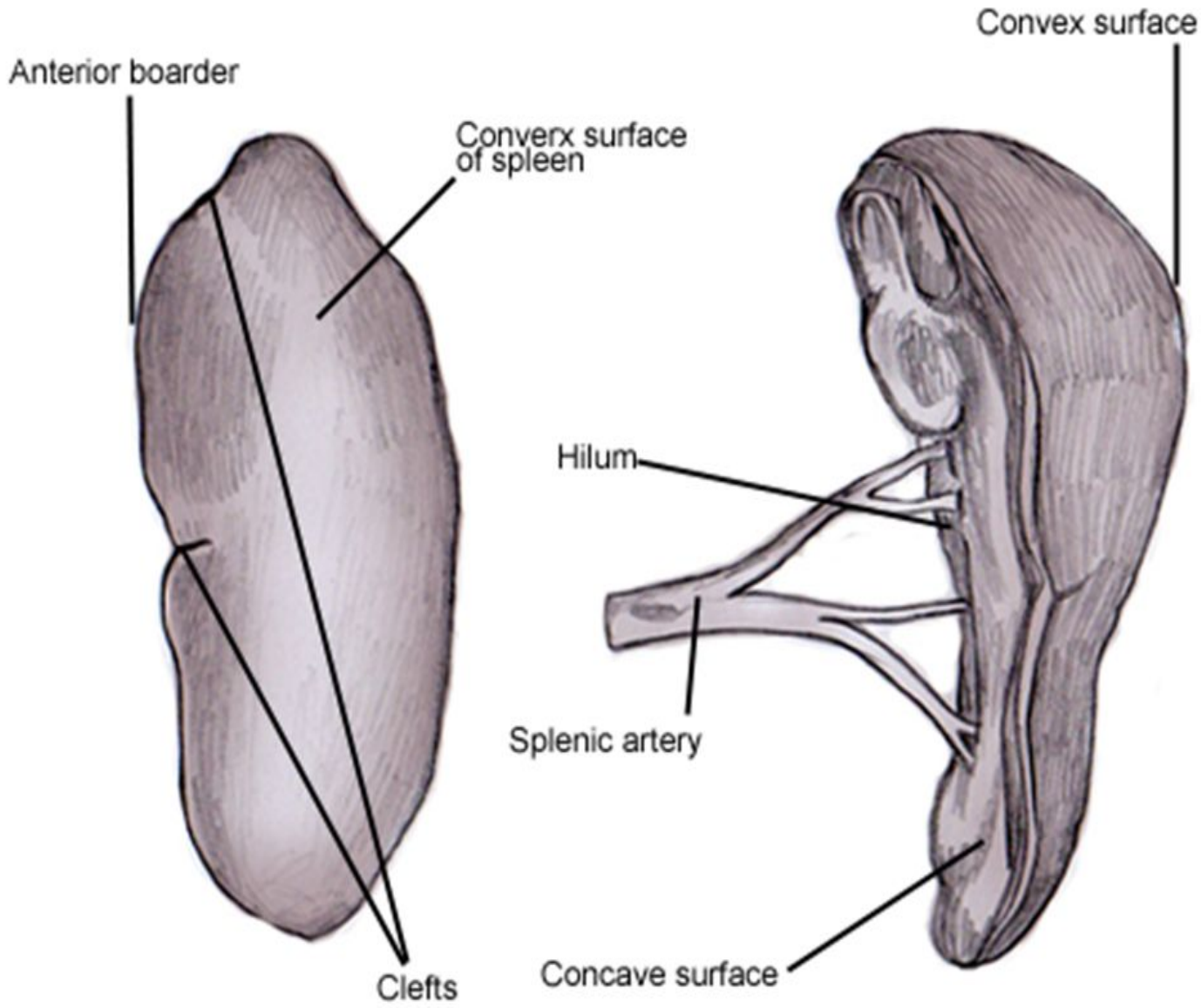
Anterior boarder
Converx surface
of spleen
Clefts
Convex surface
Hilum
Splenic artery
Concave surface

Relation of spleen

- Gastric impression : for fundus of stomach above hilum.
- Renal impression : for left kidney below hilum.
- Colic impression : for splenic flexure of colon.
- Pancreatic impression : for the tail of pancreas between hilum and colic impression.
- Hilum is found in inferior medial part of gastric impression.
- Hilum transmit splenic vessels and provide attachments for ligaments



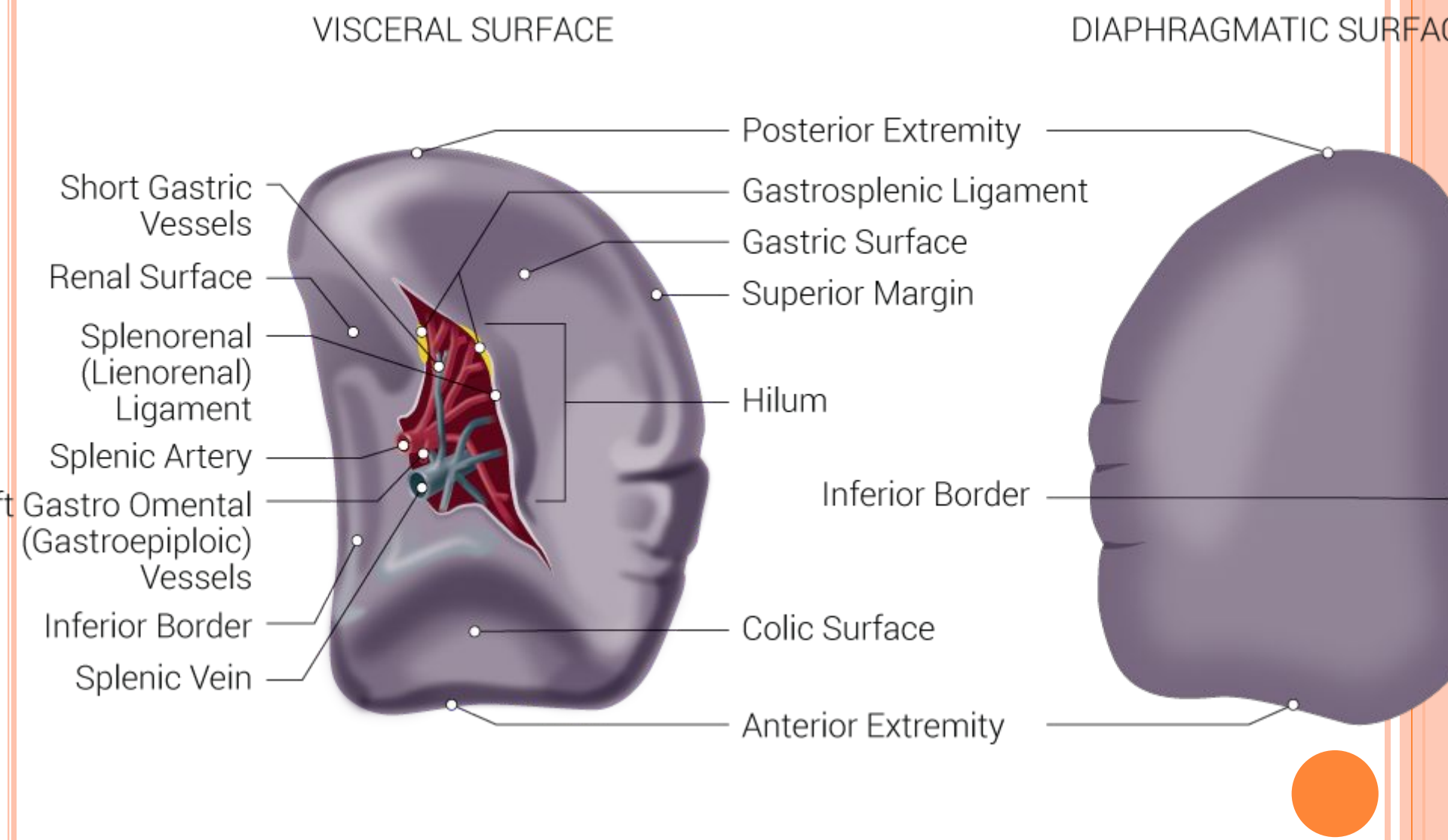
VISCERAL SURFACE
DIAPHRAGMATIC SURFAC
Posterior Extremity
Short Gastric Vessels
Gastrosplenic Ligament
Renal Surface
Gastric Surface
Superior Margin
Splenorenal (Lienorenal) Ligament
Hilum
Splenic Artery
Inferior Border
t Gastro Omental (Gastroepiploic) Vessels
Inferior Border
Colic Surface
Splenic Vein
Anterior Extremity

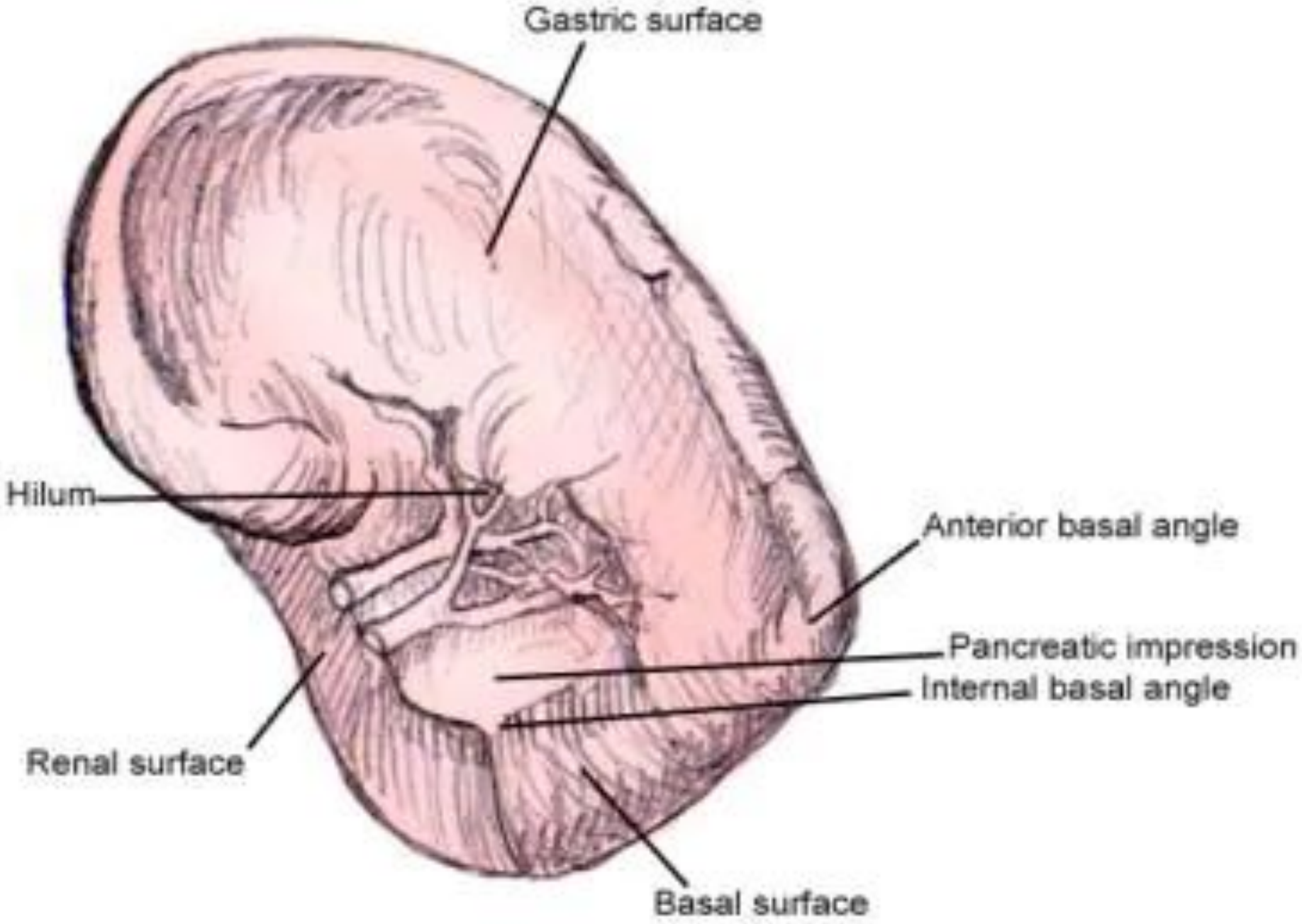
Gastric surface
Hilum
Anterior basal angle
Pancreatic impression
Internal basal angle
Renal surface
Basal surface

Splenic ligaments		
	Gastrosplenic ligament	**Splenorenal ligament**
Connected structure	•Greater curvature of the stomach	•Left kidney
Ligament contents	•Short gastric vessels •Left gastroepiploic vessels	•Splenic artery •Splenic vein •Tail of pancreas (the only intraperitoneal part of that organ)

Thank you