Genital system module (ASM 2019 team)

(PREVIOUS YEARS ANSWERED ESSAY QUESTIONS)

ASM 2019 team

1- microbiology

1) Discuss the lab diagnosis of a case of syphilis in the primary stage.

Specimen: Exudate from a chancre, any suspected penile or female genital syphilitic lesion (chancre) should be squeezed gently to obtain a serous exudate.

Bleeding should be avoided because RBCs may mask the spirochetes as they are of almost the same size.

Detection of treponema

- A drop of exudate is placed on a slide and covered by a coverslip then is examined under **dark ground microscopy** to demonstrate typical motile treponema pallidum.
- Exudate is spread on a slide, air dried, fixed and stained with fluorescein-labeled anti-treponemal serum then examined by means of **immunofluorescence microscopy** for typical fluorescent spirochetes.
- **Nucleic acid probe and PCR techniques** could be also used for detection and identification of treponema pallidum in exudate

Serology

- Cardiolipin antibodies (regain) may be negative in early primary syphilis because they can only be detected after appearance of the chancre by about 10-14 days.
- Fluorescent treponemal (FTA) test may be positive earlier because it can detect IgM anti-treponemal antibodies.

-

2) Give an account on: Urogenital mycoplasma.

- Urogenital mycoplasma mainly includes M.Hominis and ureaplasma urealyticum
- Ureaplasma urealyticum > Has urea splitting activity and **requires the presence of 10% urea in the media where it grows**
- In a large number of adults, the lower urogenital tracts are asymptomatically colonized with both species
- They become pathogenic under certain circumstances and cause diseases that are transmitted by sexual contact

Mycoplasma hominis

In females: They are associated with pyelonephritis, cystitis, salpingitis and tubo-ovarian abscesses, post-abortal or post-partum fever and may cause abortion

In males: They do not appear to cause diseases in males

Ureaplasma urealyticum

In males: They are associated with non gonocaccal urethritis (about 10% of cases)

In females: They have been associated with lung disease in premature low birth weight infants. The evidence associating them to infertility is still minimal.

(If it's the only micro Question in the exam, take ur cautions and mention the laboratory diagnosis, written in the answer in Q7 below)

3) Enumerate the five sexually transmitted bacterial diseases, the causative organism of each and discuss the lab diagnosis of a case with chronic gonorrhea.

Gonorrhea > Neisseria gonorrhoeae

Chancroid (Soft chancre) > Haemophilus ducreyi

Syphilis > Treponema pallidum

Non gonococcal urethritis > Chlamydia trachomatis (D to K)

Non gonococcal urethritis > ureaplasma urealyticum

Lymphogranuloma venereum (LGV) > Chlamydia trachomatis (L_1,L_2 and L_3)

Lab diagnosis of a case with chronic gonorrhea

Specimen:

- Morning urethral drop or prostatic secretion in male
- Swab from cervix uteri in female

Culture: Better inoculated on selective medium, the **Thayer and martin medium**, which contains the antibiotics **Vancomycin**, **colistin**, and **nystatin** (Chocolate agar+ VCN)

The plate are inoculated at 37 c in CO2 enriched atmosphere for 48 hours, then the colonies are identified by:

- Oxidase test (positive)
- Gram stained film (Gram negative diplococcic)
- Production of acid from glucose
- Coagglutination test using monoclonal antibodies has become available, may be used for identification of an isolate

4) As regard Spirochetes, give an account on the different methods for treponema pallidum demonstration.

- Weakly Refractile > Therefore examined under dark ground illumination for its typical morphology and motility

- It's very thin and has **no affinity to aniline dyes**, So can't be stained by ordinary stain
- Can be visualized by the immuno-flourescent stainig technique
- Exudate is spread on a slide, air dried, fixed and stained with fluorescein-labeled anti-treponemal serum then examined by means of **immunofluorescence microscopy** for typical fluorescent spirochetes.

5) How would you diagnose in a lab a suspected case of chancroid.

Films are made by scraping the ulcer base and stained by gram's method will show **gram negative rods**, intracellularly in pus cells and extracellularly together with secondary invaders. Culture is done on chocolate agar plus iso-vitalex plus vancomycin incubated in air plus **CO2**.
The organism **requires X factor** but not V.
The organism is haemophilius ducreyi .

6) Enumerate the members of the Herpes viruses. Mention the common properties of this group.

Subfamily herpes virinae	Human herpes virus (Common name)
Alpha	- Herpes simplex virus type 1 (HSV-1) - Herpes simplex virus type 2 (HSV-2) - Varicella-Zoster virus (VZV)
Beta	- Cytomegalovirus (CMV) - Human herpes virus-6 - Human herpes virus-7

Gamma	- Epstein-barr virus (EBV) - Kaposi's sarcoma associated - Herpes virus (KSHV)

Common properties:

- **Morphology:** large double stranded DNA viruses, icosahedral in symmetry
- **Culture:** with the exception of EBV, members of the group could be isolated easily in cell cultures and all produce giant cells and intra-nuclear inclusions in infected cultures
- Herpes viruses are considered as **very successful parasite** in that they cause a high ratio of subclinical to clinical infections
- **Herpes viruses:** are noted for their ability to cause latent infections in which the virus persists in a non-replicating form with intermittent periods of viral reactivation and shedding

6) A 25-year-old male has several enlarged lymph nodes and a *macula-papular rash*. 2 months ago he had a painless penile ulcer that resolves spontaneously. Secondary syphilis was suspected.

1- What are the microscopic examinations needed to reach a diagnosis?

- The organism is Weakly Refractile > Therefore examined under dark ground illumination for its typical morphology and motility
- It's very thin and has **no affinity to aniline dyes**, So can't be stained by ordinary stain
- Can be visualized by the immuno-flourescent stainig technique by means of **immunofluorescence microscopy** for typical fluorescent spirochetes.

2- Name the cardiolipin antibody tests. Why is it necessary to confirm a positive test by a treponemal antibody test?

- Venereal Disease Research laboratory test (VDRL)
- Rapid plasma Reagin (RPR)

Confirmation should be done because of biological false positive results that occur in malaria, measles, infectious mononucleosis, leprosy, collagen vascular diseases (SLE), recent immunization with certain vaccines and drug addiction

3- Write briefly about: Treponema pallidum particle agglutination test.

Treponema pallidum particle agglutination test (TP-PA)

Gelatin particles are sensitized with T.Pallidum antigens. The test is performed in a microdilution plate with diluted patient's serum. Antibodies against T.Pallidum react with sensitized gelatin particles.

A mat of agglutinated particles indicate a positive result. This test is similar to the FTA-Abs test in specificity and sensitivity.

7) Name 2 bacteria that cause non-gonococcal urethritis. Discuss briefly the lab diagnosis of a case caused by one of them.

Non gonococcal urethritis > Chlamydia trachomatis (D to K)

Non gonococcal urethritis > ureaplasma urealyticum

Laboratory diagnosis of ureaplasma urealyticum

Specimen: Only upper genitourinary specimens are of value because both species frequently colonize the lower genitourinary tract of both sexes.

- Urethral swabs or urine after prostatic massage in males.
- Fetal membrane swabs and semen as part of investigating infertility.

Specimens are put in stuart's transport medium and sent to the laboratory.

Isolation:

- Swabs are spread on plates of standard media for mycoplasma, but in a moist atmosphere plus 5-10% at 37 c, incubated for 7 days and inspected for the characteristic fried-egg appearance (By a magnification of 40 times)
- Ureaplasma require 10% urea in their media.
- They demonstrate their urease activity in liquid media containing **urea** and **phenol red** they grow and result in production of **ammonia** that alters the PH and changes the color of the medium
- Colonies on agar are tiny 15-30 µm in diameter but also show fried egg appearance
- Growth inhibition with specific antisera can be used for differentiation of genital mycoplasmas

Serodiagnosis: is rarely used

8) Differentiate between HSV-1 and HSV-2 as regards: their properties and the disease they produce.

Properties:

1. **Antigenicity:** although the two viruses cross react serologically but some unique proteins exists for each type
2. **DNA genome:** they can be distinguished by restriction enzyme analysis
3. **Mode of transmission:** **HSV-1** spreads by contact usually involving infected saliva whereas **HSV-2** is transmitted sexually or from maternal genital infections to a newborn
4. **Clinical features:** Most HSV-1 lesions occur above the waist i.e. HSV-1 is responsible for around 90% of oral and ocular lesions. While HSV-2 is responsible for 90% of genital lesions.
   However, HSV-1 infection of genitalia and HSV-2 lesions in oral cavity and eyes can occur in about 10% of cases.

Diseases caused by HSV-1

1. **Acute gingivostomatitis:** occurs primarily in children, characterized by irritability, fever, vesicular lesions in the mouth
2. **Herpes labialis (Fever blisters or cold sores):** characterized by crops of vesicles
3. **Keratoconjunctivitis:** characterized by corneal ulcers and lesions of the conjunctival epithelium
4. **Encephalitis :** usually involve temporal lobe. It's fatal and cause seve neurological sequelae in those who survive
5. **Herpes whitlow :** herpetic lesion of the skin of the finger or hand, often occurs in medical personnel.
6. **Disseminated infections:** such as oesophagitis and pneumonia, occur in immunocompromised patients with depressed T cell function

Diseases caused by HSV-2

1. **Genital herps:** characterized by painful vesicular lesions of the male and female genitl and anal area
2. **Neonatal herps:** originates chiefly by contact with vesicular lesions within the birth canal. The clinical picture varies from generalized disease or encephalitis to a milder local lesion or even asymptomatic infection
3. **Aseptic meningitis:** mild, self-limited disease.

9) Outline the lab diagnosis of Chlamydia trachomatis.

1. Cytologic examination of cell scrapings with Gimsa stain for the presence of **chlamydial inclusion bodies** (Valuable in ocular infection)

2. Isolation of C.trachomatis in cell culture, the most sensitive and specific method for diagnosis of C.trachomatis. Cycloheximide treated McCoy cells are used commonly
3. Direct immunofluorescence staining employs **fluorescein isothicyanate** conjugated **monoclonal antibodies** to C.trachomatis for the detection of elementary bodies in smears from clinical samples.
4. Chlamydial antigens also can be detected in clinical specimens by enzyme linked immunoassay (**ELIZA**)
5. **Nucleic acid probes** and **polymerase chain reaction (PCR)** for detection of C.trachomatis in any clinical sample
6. **Serology**

- Antibodies to genus specific antigen can be detected in serum and other secretions by complement fixation
- Type specific antibodies can be detected by micro-immunofluorescence assay.
- Serological tests have a limited value in diagnosis of chlamydial infections in adults because the test cannot differentiate between current or past infection.
- The presence of high titer IgM or rising antibody level suggests a recent infection.
- Detection of IgM to C.trachomatis is useful in the diagnosis of neonatal infection.
- A single titer of more than 64 is a good evidence of active neonatal infection.

2- histology

1) Enumerate the histological features of prostate.

- type :
  exocrine tubuloalveolar merocrine gland
- lobulation :
  divided into 3 lobes by the 2 ejaculatory ducts
- coverings :
  thin fibroelastic connective tissue capsule containing smooth muscle fibers
- trabeculae :
  thick septa (trabeculae) made up of connective tissue fibers , elastic fibers , & smooth muscle fibers . they divide the gland into compartments
- secretory units (acini) :
  they are irregular in outline and arranged in 3 groups

1- mucosal :
   - central in position
   - small in size
   - lined by pseudostratified columnar epithelium

2- submucosal
   - medium sized
   - lined by pseudostratified columnar epithelium

3- outer
   - peripheral (subcapsular)
   - large and numerous
   - lined by simple columnar epithelium

- the acini are embedded in fibro-elastic C.T with smooth muscle fibers
- the gland is traversed in the midsection by the prostatic urethra which lined by transitional epithelium.

2) Give a brief account of Sertoli cells.

- Definition : They are non-spermatogenic non proliferative cells of single type
- Site :

  In between spermatogenic cells , extending from the basement membrane to the lumen of seminefrous tubules
- Size and shape:

  These cells are tall , irregular pyramidal resting by their broad base on the basement membrane of seminefrous tubules and reach the lumen by their thinner apex where spermatozoa and spermatids are attached
- Nucleus

  Lies in the broad basal part of the cell

  Large , irregular , pale with a tripartite nucleolar apparatus
- Cytoplasm

  - L.M: Pale due to excessive lipids

  - E.M: shows :

  sER

  Well developed golgi

  Elongated mitochondria

  Primary & secondary lysosomes

  Microtubules and microfilaments
- Lateral boundries:
  - Are not resolved as they show extensive cytoplasmic ramifications to support spermatogenic cells
  - Show tight junctions between adjacent sertoli cells to form blood testicular barrier .
- Function :

  1- supportive

  2- nutritive

3- phagocytic
4- hormonal
5- formation of blood testis barrier

3) Enumerate the male genital ducts and their lining epithelium.

- **Intertesticular ducts**
  1- Tubuli recti
  - Initial part lined by **Sertoli like** cells
  - Main segment is lined by **cuboidal** epithelium

  2- Rete testis
  Lined by **cuboidal** cells

  3- Vasa efferentia
  Low **non ciliated and tall ciliated columnar** epithelium
- **Extratesticular ducts**
  4- Epididymis
  lined by **pseudostratified columnar** epithelium with principle tall cells and short basal cells .

  5- vas deferens
  mucosa lined by **pseudostratified columnar** epithelium

  6- ejaculatory duct
  lined by **columnar** epithelium and it's end by **transitional** epithelium .

4) Enumerate the different types of spermatogenic cells and draw the EM picture of a mature spermatozoon.

1- spermatogonia
2- primary spermatocyte
3- secondary spermatocyte
4- spermatids
5- spermatozoa

3- Anatomy

1) Give an account on the coverings, blood supply and lymphatic drainage of the testes.

*Coverings of the testes (from outside):

1-Skin

2-Dartos muscle

3-Colle's fascia

4-External Spermatic fascia

5-Cremasteric muscle and fascia

6-Internal Spermatic fascia

7-Tunica Vaginalis

8-Tunica Albuginea

*Blood Supply of testes:

A)Arterial Supply>>testicular artery from abdominal aorta at level of L2

B)Venous drainage >> by testicular vein to:

Left testis >> left renal vein

Right testis >> IVC

*Lymphatic drainage of testes:

Para-aortic LNs at level of L2

2) Where do the testicular veins end?

The left ends in left renal vein and the right ends in the IVC

3) Name and give the origin of the coverings of the spermatic cord.

1-External Spermatic fascia : derived from the aponeurosis of the external oblique muscle

2-Cremasteric muscle and fascia: derived from the internal oblique muscle

3-Internal Spermatic fascia: derived from the fascia transversalis

4)Give two branches of the posterior division of the internal iliac artery.

1-Iliolumbar artery.

2- Two lateral sacral arteries.

3- Superior gluteal.

5-Name two ligaments related to the uterus.

1-Uterosacral ligament.

2-pubocervical ligament.

3-transverse cervical ligament.

4-Ligament of the ovary.

5-Round ligament of the uterus.

6-Broad ligament.

6) Give the origin of the internal iliac artery and name 3 branches of its anterior division

-Origin:

It's the smaller branch of the 2 terminal branches of the common iliac artery.

-Branches of anterior devision:

A)Parietal branches:

1-Obturator artery.

2-Inferiorgluteal.

3-Internal pudendal artery.

B)Visceral branches:

1-Umbilical artery & it's superior vesical branches.

2-Inferior vesical artery in male / Vaginal artery in female.

3-Uterine artery in female.

4-Middle rectal artery.

7) Name the pouch that separates the uterus from the rectum. Which part of the vagina is related to it?

-Recto-uterine pouch (Douglas pouch).

-The upper 1/4 of posterior wall of the vagina is related to the peritoneum of Douglas pouch.

-The middle 2/4 of posterior wall of the vagina are related to the rectum.

8) Where do the ejaculatory ducts open?

The Ejaculatory duct penetrates the base of the prostate and pases anteroinferiorly to open in the prostatic urethra.

9) Name the structures related to the lateral fornix of the vagina.

Lateral fornix is closely related to the ureter which is crossed by the uterine artery.

11) In which perineal pouch are the following structures found?

-Membranous urethra >> found in the deep perineal pouch.

- bulb of penis >> superficial perineal pouch

12) Give the origin of:

- Levator ani
- Pudendal nerve

-The origin of levator ani muscle:

A line extending from the pelvic surface of the body of pubis ,
White line of obturator fascia (tendinous arch) &
Inner surface of ischial spine.

-The origin of pudendal nerve:

It's a ventral branch from the root of the sacral plexus (S2,3,4)

14) Give the vertebral level of the ovarian artery.

L2

16) Name the contents of the superficial perineal pouch.

-In female:	-In male:
1-Root of clitoris(2 bulbs of vestibule & 2 crura cavernosum) 2-Superficial perineal muscles : 3 pairs *Superficial transverse perineal *Ishiocavernosus :covers crura cavernosum. *Bulbospongiosus : covers the bulb of vestibule.	1-Root of penis (1 bulb of penis & 2 crura cavernosum) 2- Superficial perineal muscles : 3 pairs *Superficial transverse perineal *Ishiocavernosus :covers crura cavernosum.

3-Arteries: 3 branches of internal pudendal artery; Its 2 terminal branches & labial artery. 4-Nerves: *Dorsal nerve of clitoris . *Labial nerves. 5-One vein: Deep dorsal vein of clitoris 6-Greater vestibular gland: 1 on each side . - It lies deep to the posterior part of the bulb of the vestibule. -Its duct opens in the vaginal vestibule lateral to the vaginal orifice.	*Bulbospongiosus : covers the bulb of penis 3-Arteries: 3 branches of internal pudendal artery; Its 2 terminal branches & scrotal artery. 4-Nerves: *Dorsal nerve of penis . *Scrotal nerves. 5-One vein: Deep dorsal vein of penis . It joins the prostatic venous plexus of veins.

17) Give four differences between male and female pelvis.

18) Draw a diagram showing the parts of the uterus. Mention its normal anatomical
Position

19) Write short notes on:

- Pudendal nerve (root value, branches and muscles supplied).
- Contents of the broad ligament.
- Uterus (parts and relations).
- Course of pelvic part of ureter.
- Muscles forming the pelvic floor.
- Position, relations and blood supply of:

1) Ovary.
2) Prostate.

*Position of prostate: in the pelvic cavity between lower border of symphysis pubis anteriorly and ampulla of rectum posteriorly

*Relations of Prostate:

Base >> related to neck of urinary bladder and is penetrated by urethra

Apex>> Superior fascia of urogenital diaphragm

Posterior surface>> Ampulla of rectum

Anterior surface>> connected to pubic bone by puboprostatic ligament , also the urethra emerges from this surface.

Inferolateral surfaces : related to the 2 free borders of levator ani muscle (the most anterior fibers “levatore prostate”)

Also the structures inside the prostate include:

1-prostatic urethra

2-ejaculatory ducts

3-prostatic utricle

*Blood Supply of prostate:

-Arterial Supply:

Inferior vesical and middle rectal arteries.

-Venous drainage:

Prostatic venous plexus which drains into the internal iliac vein

---

20) Enumerate the contents of the deep perineal pouch.

-In female:	-In male:
1-Urethra	1-Membranous urethra
2-Muscles:	2-Muscles:
Sphincter urethrae & deep transverse perinei.	Sphincter urethrae & deep transverse perinei.
3-Dorsal nerve of clitoris.	3-Dorsal nerve of penis.
4-Internal pudendal artery.	4-Internal pudendal artery.
	5-Bulbourethral glands (Cowper's)

21) Name the fascial layers enclosing the superficial perineal pouch.

-Roofed by perineal membrane (inferior fascia of urogenital diaphragm)

-Floor : membranous layer of superficial fascia (Colle's fascia)

-Posterior & on each side : the roof & the floor fuse together.

-Anterior :the pouch is open & continuous with the space deep to membranous layer of superficial fascia of the lower part of anterior

22) Name two ligaments of the cervix uteri.

1-Uterosacral ligament:

which extends from the cerix, passes around the sides of the rectum to the front of sacrum.

2-Pubocervical ligament:

from the junction of cevix and vagina ,passes around the urethra to the back of pubic body.

3-Transverse cervical ligament (cardinal,lateral cervical):

Extends from the cervix and lateral fornix of vagina to the lateral wall of the pelvis.

23) Draw a diagram showing peritoneal reflections in female pelvis.

24) Describe the normal position and the ligamentous support of the uterus.

The normal position of the uterus is anteflexuion & anteversion (AVF position)

Anteflexed: the forward angle between long axis of body of uterus & that of the cervix = 170 degree

Anteverted: the forward angle between long axis of vagina & that of the cervix=90 degree.

*Ligamentous support:

1-Uterosacral ligament:

which extends from the cerix, passes around the sides of the rectum to the front of sacrum.

2-Pubocervical ligament:

from the junction of cevix and vagina ,passes around the urethra to the back of pubic body.

3-Transverse cervical ligament (cardinal,lateral cervical):

Extends from the cervix and lateral fornix of vagina to the lateral wall of the pelvis.

4-Ligament of the ovary:

Extends from the uterine end of the ovary to the conua of uterus.

5-Round ligament of uterus:

Extends from cornua of uterus ,runs through broad ligament ,then enters the inguinal canal to insert into the libia majora.

6-Broad ligament:

A double lavered fold of the peritoneum , extended from the lateral margin of the uterus to the side wall of the pelvis .

It has :

-A free superior border containing the uterine tube

-An attached lower border (root) ' attached to floor of the pelvis

-Ovary is attached to it by ashort peritoneal fold called mesovarium.

*Parts of the broad ligament:

I-Mesometrium:

Between pelvic floor , ovarian ligament & uterine body.

II- Mesosalpinx:

Between uterine tube,mesovarium & ovarian ligament.

III- Suspensory ligament of ovary:

Connects the infundibulum of uterine tube & upper end of ovary to the pelvic wall , transmitting ovarian vessels & nerves.

25) Name the branches of the sacral plexus

A)From the root of the plexus:	B)From the plexus itself:

*Ventral branches: 1-Pudendal nerve (S2,3,4). 2-Pelvic splanchnic nerve (S2,3,4) Gives parasympathetic supply to pelvic organs. 3-Perineal branch of S4 (supply external anal sphincter).	*Ventral branches : 1-Nerve to quadrates femoris (L4,5,S1) 2-Nerve to obturator internus (L5,S1,2) 3-Tibial part of sciatic nerve(L4,5,S1,2,3)
*Dorsal branches: 4-Nerves to piriformis (S1,2) 5-Posterior cutaneous nerve of thigh. 6-Perforating cutaneous nerve (S2,3)	*Dorsal branches: 4-Superior gluteal nerve (L4,5,S1) 5-Inferior gluteal nerve (L5,S1,2) 6-Common peroneal part of sciatic nerve (L4,5,S1,2)

27) What is the origin of the internal pudendal artery? Name 2 terminal branches.

Origin:

Anterior division of internal iliac artery .

Terminal branches:

1-Deep artery of clitoris (penis).

2-Dorsal artery of clitoris(penis).

29) Mention the arterial supply of the ovary.

Ovarian arteries which run through the suspensory ligament then through the mesovarium to reach the ovary.

31) Name the lobes of the prostate. Which of the commonly enlarges?

The lobes of prostate:

1-median lobe

2-right and left lateral lobes

3-anterior lobe (isthmus)

4-posterior lobe

-the median lobe commonly enlarges in benign enlargement of prostate in men older than 50 years

---

34) Name the parts of the levator ani muscle and give its nerve supply.

1-Pubococcygeus:

Inserted into perineal body & tip of coccyx

Fibers of this part pass across the side of prostate in male (levator prostate) & across the vagina in female (sphincter vaginalis)

2-Iliococcygeus:

Inserted into the sides of the last 2 pieces of coccyx & anococcygeal raph which extends from the apex of the coccyx to anorectal junction.

3-Puborectalis:

Passes backwards at anorectal junction ,fibers of both sides form a U shaped sling which helps the deep part of external anal sphincter.

Nerve supply:

Ventral rami of S3,4 sacral nerves & inferior rectal nerve.

36) Give the anatomy of the vagina.

It's a cylindrical musculo-fibrous tube from 7 to 10 cm in length.

Site:

It descends antero-inferiorly from the cervix of uterus to the vistibule of the vagina (cleft between the 2 libia majora).

Shape:

A tube with 2 walls (anterior 3 inches & posterior 4inches)

Relations:

Anterior:

Intimately related to the cervix of the uterus,urethra &urinary bladder.

Posteriorly:

Posterior wall is in contact with extrnal os.

1)Upper 1/4th covered by peritoneum of douglas pouch ,

2)Middle 2/4th are related to the rectum,

3)Lower 1/4th separated from anal canal by the perineal body.

Laterally:

1)Upper third :the lateral fornix is closely related to the ureter which is crossed by the uterine artery.

2)Middle third: levator ani (pubovaginalis part) & pelvic fascia.

3)Lower third: traverse the deep perineal pouch and related to the greater vestibular gland .

Superiorly: it communicates with the cervical canal.

Inferiorly : it opens into vaginal vestibule.

Vaginal fornices :

They are 4 in number.

-Two lateral fornices: one on each side & closely related to the ureter &uterine artery.

-Anterior fornix: is shallow.

-Posterior fornix : is the deepest one ,known as the seminal pool.

37) Give short account on: pudendal canal and its contents.

Formed by splitting of obturator fascia 1.5 inches above ischeal tuberosity.

Contents :

1-Pudendal nerve .

2-Internal pudendal vessels (artery +vein).

38) Write short notes on: mammary gland (position, blood supply and lymphatic drainage.

Position:

*Located in the fatty later of the superficial fascia of the pectoral region.

The base: rests upon the deep fascia covering (pectoralis major,serratus anterior & external oblique muscles)

The base extends from the 2nd to the 6th rib

& from the lateral margin of the sternum to the mid axillary line.

Axillary tail : a small part of the gland exyends up and laterally ,pierces the deep fascia at the lower border of pectoralis major to enter the axilla.

Blood supply:

I-Arterial supply:

1-Perforating branches of the internal thoracic artery and anterior intercostals arteries .

2-Branches from the lateral thoracic and thoraco-acromial branches of the axillary artery.

II-Venous drainage:

Through veins accompanying the supplying arteries.

لما يسأل عن الblood supply محدش ينسي ال ☺ venous drainage

Lymphatic drainage:

I-Suprficial lymphatics:

To subareolar & circumareolar lymphatic plexus.

II-Deep lymphatics:

-Upper lateral & central parts of the breast :apical group of axillary lymph nodes.

-Lower lateral: to pectoral group of axillary lymph nodes.

-Upper medial:to parastrnal (internal mammary) lymph nodes.

-Lower medial:to anterior abdominal wall LNs (rectus sheath & sub-peritoneal plexus).

-Tail of the axilla:to the posterior (subcapsular) group of axillary lymph nodes.

4- Physiology

Male;

1. Mention the functions of Sertoli Cells.

1) **Supportive Function :** provide a **special environment** where the **germinal cells** develop.
2) **Nutritive Function :** secrete a **fluid** to provide appropriate **nutrients** for the newly formed **sperms**.

3) **Phagocytic Functions :** play a special role in …
   a. Phagocytosis of **Dead Sperms**.
   b. **Spermiation** : converting **Spermatid → Spermatozoa.**
   c. Secrete **digestive enzymes** to remove most of **Spermatid cytoplasm.**
   d. Play a role in **Shaping** the head & tail of the sperm.

4) **Hormonal Functions :** secrete …
   a. **Muellerian Inhibitory Factor (MIF) :** secreted during **fetal development** to **inhibit** the formation of **Fallopian tubes** form **Muellerian ducts** in the male fetus.
   b. **Estradiol (Estrogen) :** the principal feminizing sex hormone.
   required as one of the **stimulatory** factors in **Spermatogenesis.**
   c. **Inhibin :** has an **inhibitory feedback** on the **Ant. Pituitary** gland to prevent **over**secretion of **FSH**.
   d. **Andorogen-binding protein (ABP) :** maintains a high & stable **supply** of **Androgen** in **tubular fluid**.
   Testosterone is accumulated inside Sertoli cells through its binding with an ABP ; for completion of Spermiogenesis process.

5) **Formation of Blood-testis barrier :** which …
   a. **Prevents protein & large Mol**. from passing from Interstitial tissue .
   b. **Allows Steriods** to pass.

c. **Prevents** passing of Blood-borne **Noxious agents ;** to protect the germ cells from harmful substances.

d. **Prevents Autoimmune diseases ,** by …

- Prevent dead sperms & antigenic products of germ cell division from entering the circulation.
- Prevent Abs passing from BVs in tunica vascolusa.

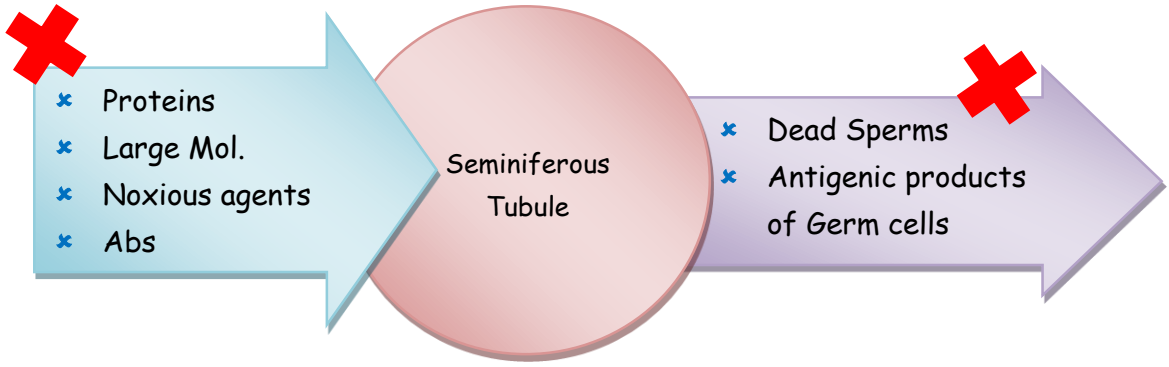

---

2. Explain Hormonal Regulation of Male Reproductive Function.

1) **Hypothalamic Regulation :** Near the age of puberty , it begins to secrete LHRL , which has strong effect on inducing LH & FSH secretion from the Ant. Pituitary gland.
2) **Ant. Pituitary Gland :** Secrets 2 major GnTH : FSH & LH , which are glycoprotein hormones playing major role in control both male & female sexual functions.

During Pregnancy, the **placenta** secretes Human Chorionic Gonadotropin in large quantities (has the same properties as LH) , this hormone stimulate the Formation of Leyding Cells in the fetus testis & causes Testosterone secretion.

In Adult ,

- LH stimulates Hyperplasia of Leyding Cells & Testosterone Production.
- FSH stimulates Spermatogenesis.

3) Feedback control of Testosterone secretion :

If Testosterone **increases** , it sends a **–ve feedback** to the **Hypothalamus** inhibiting LHRL production ; to limit the Testosterone production rate.& vice versa.

4) Feedback control of Spermatogenesis :

Steroli cells secrets Inhibin which has a direct inhibitory effect mainly on Ant. Pituitary to inhibit FSH secretion .

---

3. Mention functions of Testosterone .

1) During Fetal Development :

- Development of **male sex organs** ; Formation of Penis , Scrotum , Prostate , Seminal Vesicles & Male genital ducts.
- **Descent of the Testis** into the scrotum during **the last 2 months** of pregnancy.
- **Suppression** of **Female** genital organ formation.

2) Development of Adult 1ry & 2ry Sexual Characteristics :

- **Initiation** & **maintenance** if body changes associated with puberty.
- **External Genitalia :**
  After puberty, Enlargement of Penis , Scrotum & Testes.
- **Internal Genitalia :**
  Enlargement of Seminal Vesicles , Prostate & Bulbourethral glands.
- **2ry Sexual Characteristics :**
  - Development of Beard & Moustache.
  - Growth of hair over the pubis , chest & less on other regions.
  - Decrease hair on the top of the head.
  - **Hypertrophy** of Laryngeal mucosa , Enlargement of Larynx and Increase Vocal cords thickness & length → **Deeper Vocie.**
  - Increase Skin thickness & SC tissue ruggedness.
  - Increase Secretion of Sebaceous glands → Acne**.**

3) Bones :

- Increase total quantity of Bone matrix & Ca deposition .
- Lengthening of Pelvis.
- Narrowing of Pelvic Outlet.
- Strengthening of the entire pelvis → Load-bearing.

4) Anabolic Effect :

- After Puberty**;** increases **Musculature & protein** in different body parts.
- Deposition of **Protein** in the **Skin** → Skin changes.
- Increase **Basal Metabolic Rate** 15 %.
- Increase No of **RBCs** \ cubic mm of blood.
- Increase **Na Reabsorption** in the distal tubules of Kidney.

5) Lipid Metabolism :

- Increase LDL , Decrease HDL in circulating blood .

و دا بعكس الـ Estrogen ، عشان كدا الـ Males أكتر عرضة للـ Atherosclerosis لو تفتكروا !

- Accumulation of Fat → Upper Abdomen & Viscera .

Female ;

1. Give an account on the Ovarian cycle.

1) Follicular stage :

- At birth , the female child's ovaries contain only primordial follicles (Ova surrounded by single layer of flattened granulosa cells).
- After puberty, FSH & LH are secreted in large quantity from the Ant. Pituitary gland → so the Entire Ovary + the Follicles grow.
- FSH accelerates growth of 20 Primordial Follicles each month.
- Rapid proliferation of Granulosa and Theca Cells (Originated from Ovarian Stroma & Secrete Estrogen).
- Antrum is formed.

- The rate of secretion increases & Growing Follicle is now called “Vesicular Follicle”.
- One follicle starts to grow & the other undergo atresia.

2) Ovulation :

- It occurs 14 days after the onset of menstruation.
- LH increases greatly 2 days before ovulation , it causes rapid swelling of the follicle.
- The protruding outer wall of the follicle swells.
- Fluid oozes from the follicle, so it ruptures producing viscous fluid carrying the Ovum (surrounded by Corona radiata)
- The ovum is picked up by the fallopian tube.

3) Luteal Phase :

- After Explusion, the remaining granulosa cells change into “Lutein Cells” depending on LH effect.
- They are now called “Corpus Lutem” which secretes Estrogen , Progesterone & Inhibin.
- They have strong inhibitory effect on LH & FSH secreted by Pituitary gland.
- Their low blood level causes Degeneration of Corpus Lutem & replaced by CT & becomes “Corpus Albicans”.

When FSH & LH are secreted again , another cycle begins.

---

2. Give Short account on the cyclic changes of the Endometrium.

1) Proliferative Phase:

- **Estrogen** controls this phase
- It enhances growth of Epithelial cells & Stroma cells to proliferat rapidly.

- The Endometrium increases greatly in thickness owing to increase No. of Stroma, Endometrial gland & BVs.

2) Secretory Phase :

- **Progesterone & Estrogen** control this phase.
- **Estrogen :** Causes slightly additional cellular proliferation in the Endimetrium.
- **Progesterone :** Causes marked Swelling & Secretory development of the Endometrium.
- The glands become tortuous accumulating secretory substances.
- Lipid & Glycogen deposits increase in the Stromal cells .
- BVs become tortuous so Blood supply to Endometrium increases too.
- At the end of this phase , the endometrium becomes ready for Implantation of a fertilized ovum as it is rich in stored nutrients.

3) Menstrual Phase :

- It occurs if Fertilization if the ovum doesn't happen.
- At about 24 days of this cycle , the Corpus luteum starts to regress & its hormonal secretion decreases.
- At about 26 days , **there's (Loss of Hormonal Support to the Endometrium)** & **(Spasm of the BVs by locally produced Prostaglandins)** which causes necrosis & hemorrhagic areas which unite together to form the Menstrual flow .
- The desquamated tissues & blood initiate Uterine Contractions that expel the uterine contents.

---

3. Which hormones mainly controls Proliferative phase of Uterine cycle ? OR Mention Estrogen action in non-pregnant female.

Estrogen controls the Proliferative Phase of Uterine cycle
It enhances growth of Epithelial cells & Stroma cells to proliferat rapidly.

The Endometrium increases greatly in thickness owing to increase No. of Stroma, Endometrial gland & BVs

4. Mention the Placental Hormones & actions of 2 of them.

1) Human Chorionic Gonadotropin
2) Esterogen
3) Progesterone
4) Human Chrionic Somatomammotropin
5) Relaxin

HCG :

Has very much the same molecular St. & function of LH

1> Prevention of Normal involution of Corpus lutem,

2> & causes it to secrete large amount of "Progesterone & Estrogen" which cause the endometrium to continue growing & storing large amount of nutrients.

3> It exerts an Interstitial cell stimulating effects on the testis (of the fetus ☺) , thus resulting in "Testosterone Production".

Relaxin :

Secreted by Corpus lutem & Decidual cells to …

- relaxes the pelvic bones & ligaments .
- inhibits myometrial contractions.
- Softens the cervix.

نراجع الـ Human Chrionic Somatomammotropin بالمرة ☺

HCS :

1> Causes partial development of the breasts.

2> Has Lactogenic activity like "Prolactin".

3> Has weak action similar to those of GH , causing deposition of protein in the tissue.

4> Causes Na , K & Ca retention

5> Causes decreased utilization of Glu by the mother , thereby making large quantities of Glu available to the fetus.

6> Promotes release of FFA from the fat stores of the mother, thus providing an alternative source of energy for her metabolism.

---

5. Mention the Action of Progesterone in Pregnant & Non-pregnant female.

الدكتور قالت هنا لازم أكتب الحالتين ، حتى لو الكلام متكرر .

Pregnant	Non-pregnant
• Causes **Decidual cells** to develop in the uterine endometrium for the nutrition of the early embryo. • Decreases the **contractility** of the gravid uterus, thus preventing uterine contractions from causing spontaneous abortion. • Helps in the development of the **Zygote** prior to implantation. • Increases **the Secretion of the Fallopian tubes & uterus** to provide appropriate nutritive matter for the developing embryo. • Prepares the **Breast** for lactation.	• **Causes marked Swelling & Secretory development of the Endometrium.** • **The glands become tortuous accumulating secretory substances.** • **Lipid & Glycogen deposits increase in the Stromal cells .** • **BVs become tortuous so Blood supply to Endometrium increases too.** • **At the end of this phase , the endometrium becomes ready for Implantation of a fertilized ovum as it is rich in stored nutrients.**

---

6. Explain Hormonal Regulation of Mammary gland development & lactation.

➢ Development of Mammary Gland

1. Estrogen :

It causes proliferation of the ducts, deposition of Fat, growth of Stroma & development of nipples.

2. **Progesterone :**

It causes growth of the Lobules & Alveoli .

& Development of Secretory Characteristics in the cells of alveoli.

At puberty ; other hormones have only **a permissive effect** on the development of breasts , such as :

- ✓ **Thyroid H.**
- ✓ **Adrenal Corticosteroids**
- ✓ **Insulin**

- **Milk Formation** is stimulated by :
  1. **Prolactin**
  2. **Human Chrionic Somatomammotropin**

- **Milk Ejection** caused by :
  Oxytocin

---

7. Mention the role of Corpus Luteum in Pregnant & Non-pregnant female.

- Pregnant :
  it secretes **Relaxin hormone** which important to
  1- Relax pelvic bones and ligaments
  2- Inhibit myometrial contractions and softens the cervix
- Non-pregnant :
  During **luteal phase** of the ovarian cycle :
  It secrets **estrogen , progesterone and inhibin** , they have a strong feedback effect on the anterior pituitary gland to decrease secretion of both FSH and LH , so corpus luteum degenerates completely and replaced by corpus albicans to terminate the ovarian cycle and allow another cycle to strart .

5- Pathology

1. Give an account on cervical carcinoma. (2002)

Age incidence: 50 years

Clinical Picture:

- Asymptomatic
- Abnormal uterine bleeding
- Vaginal discharge

Risk factors: *Same as those of CIN*

a. Infection with HPV types 16 & 18
b. Sexual activity at an early age
c. Multiple high risk sexual partners
d. Multiparity
e. Cigarette smoking
f. Immunosupression
g. CIN: ALL cervical squamous cell carcinomas arise from the precursor CIN

FOCUS! No hormonal risk factors. All related to trauma & inflammation.

Gross picture: May be present in 3 forms

- Ulcerative
- Exophytic fungating mass
- Endophytic invasive lesion (barrel shaped cervix)

Microscopic picture:

- From epithelium: squamous cell carcinoma (most common!)
- From endocervical glands: adenocarcinoma
- Mixed: adenosquamous carcinoma
- Small cell carcinoma and undifferentiated carcinoma

Spread:

1. Local spread (to uterus, vagina, ureters, rectum and urinary bladder)
2. Lymphatic spread (involves chains of lymph nodes in pelvis: aortic, common iliac, internal and external iliac)
3. Blood spread (to lungs, liver, bone)

2. Give an account on the pathological differences between non-proliferative and proliferative fibrocystic disease of the breast. (1998, 2002, 04, 05)

Non-proliferative	**Proliferative**
3 microscopic findings found: fibrosis, adenosis, cyst formation	Fibrosis, adenosis, cyst formation + epithelial hyperplasia OR sclerosing adenosis
Fibrosis: stroma around the cysts is compressed and infiltrated by lymphocytes **Adenosis**: increased no. of acini per lobule **Cyst formation**: variable cysts in size and shape Small → cuboidal to columnar lining Large → flattened or atrophic lining Apocrine metaplasia is seen in most cysts [cuboial or columnar epithelium transform into large polygonal cells with abundant granular eosinophilic cytoplasm] *(PS even though there is metaplasia, there is no ↑ in risk of cancer)*	**Epithelial hyperplasia**: more than 2 layers of cells in the ductal epithelium. Classified into mild, moderate and florid hyperplasia according to the no. of layers Sometimes hyperplasia leads to formation of false papillae → ductal papillomatosis And sometimes nuclear atypia is seen → atypical epithelial hyperplasia **Sclerosing adenosis:** Proliferation of small ductules and acini + Marked stromal fibrosis which may compress the lumina of the ducts and acini so they appear as solid cords of cells simulating

	carcinoma *(← differential diagnosis with breast carcinoma)*
Gross picture: Usually multifocal and bilateral Firm irregular whitish mass that contains cysts of variable sizes containing serous turbid fluid Unopened cysts are called blue dome cysts because they show a blue-brown colour	**Gross picture:** In case of epithelial hyperplasia: like non-proliferative FCD + serous or serosanguinous nipple discharge In case of sclerosing adenosis: the lesion is hard simulating cancer *(← differential diagnosis with breast carcinoma)*

3. Give a short account on seminomas. (2002, 04, 05)

- Most common germ cell tumour in adults (30%, peak incidence= 4th decade)
- Counterpart of dysgerminoma in females

- **Gross picture:**
  - Large, well demarcated, homogenous grey-white tumour
  - Soft, bulges from the cut surface
  - Large tumours contain foci of coagulative necrosis
  - Usually confined to testis by an intact tunica albuginea

- **Microscopic picture**: (3 variants)
  - Classic seminoma (85%)
    - Large cells with distinct borders
    - Cytoplasm: clear, glycogen rich
    - Nucleus: rounded with prominent nucleolus
    - Cells arranged in small lobules separated by fibrous septae

- Fibrous septae infiltrated with lymphocytes
- [sometimes] Granulomatous reaction with giant cells are seen

- Anaplastic seminoma (15%)
- Spermatocytic seminoma (5%)

4. Enumerate causes of uterine bleeding at reproductive period of life. (2002)

A. Complications of pregnancy:
   - Abortion
   - Trophoblastic disease
   - Ectopic pregnancy
B. Organic lesions:
   - Leiomyoma
   - Adenomyosis
   - Endometrial polyp
   - Endometrial hyperplasia
   - Endometrial carcinoma
C. Anovulatory cycle
D. Inadequate luteal phase

Refer to dysfunctional uterine bleeding (pg 52)

Very important question!

5. Give an account on endometrial hyperplasia. (2001, 05, 06, 08)

Definition: increase in number of glands relative to endometrial stroma
Causes: Prolonged unopposed estrogen stimulation

Prolonged Unopposed Estrogen Stimulation

Increased estrogen

1. Exogenous estrogen: hormone replacement therapy
2. Estrogen producing ovarian tumours
3. Polycystic ovary syndrome
4. Obesity *(peripheral estrogen secretion in adipose tissue)*

Decreased progesterone

1. Anovulatory cycles *(no corpus luteum >> no progesterone)*
2. Nulliparity *(no pregnancy >> progesterone levels are elevated in pregnancy)*

TYPES AND MORPHOLOGY

Simple	Complex	Complex with Atypia
• **Gross**: endometrium thickened and granular • **Microscopically**: inc. no . of endometrial glands; some of which are cystically dilated with intervening cellular stroma (swiss cheese appearance)	• **Gross**: endometrium thickened and polypoidal • **Microscopically**: glands crowded and branching with scanty stroma (back to back appearance)	• **Gross**: endometrium thickened and polypoidal • **Microscopically**: glands crowded and branching with scanty stroma + nuclear atypia

Clinical picture: Menorrhagia and irregular uterine bleeding
Risk of malignancy: 5% of cases of complex hyperplasia and 25% of cases of atypical complex hyperplasia progress to endometrial carcinoma

6. Discuss teratoma of the ovary. (2008)

- Represents 20% of ovarian tumours
- Has 4 types:
    - Mature (benign) cystic teratoma
    - Teratomas with a malignant transformation
    - Immature (malignant) solid teratoma
    - Monodermal (highly specialized) teratoma [benign]

Mature cystic	Immature solid	Monodermal
-most common teratoma -occurs in young women during their reproductive years -usually unilateral: more on the right side	-rare -occurs in prepubertal adolescents and young women [mean age 18]	Eg: -Struma ovarii (mature thyroid tissue) → hyperthyroidism -Ovarian carcinoid (from intestinal epithelium) → may produce carcinoid syndrome

Gross: - unilocular cyst - 10 cm in diameter - thin wall - lined by wrinkled epidermis - lumen filled with sebaceous secretion admixed with hair shafts - sometimes solid instead of cystic, formed of benign structures of the 3 germ lines	- bulky, solid - with areas of necrosis and hemorrhage - hair , cartilage, bone or calcification may be present	- small, solid, unilateral
Microscopically: Ectoderm: cyst wall composed of stratified squamous epithelium with hair shafts and sebaceous glands. Mesoderm: teeth, bone, cartilage Endoderm: thyroid tissue, bronchial epithelium, GIT epithelium	Varying amounts of immature tissue differentiation : towards cartilage, bone, muscle, nerve, glands Grading of immature teratoma depends on proportion of tissue containing IMMATURE NEUROEPITHELIUM	
Prognosis & complications: May undergo - torsion → acute abdomen - malignant changes (1%)	Grows rapidly → penetrates the capsule → spreads or metastasizes Best prognosis: low grade + confined to capsule	

7. Discuss risk factors for breast carcinoma. (2005, 08)

1) Increasing age (rarely before 25 except in familial cases)
2) Family history: affection of a 1st degree relative increases the risk
3) Prolonged exposure to endogenous estrogen
   - Early menarche and late menopause
   - Late pregnancy
   - Nulliparity
   - Estrogen producing tumours (eg. Granulosa cell tumour)
   - Obesity

➢ *PS: prolonged breast feeding (↓ estrogen) decreases the risk of developing breast cancer*

4) Prolonged exposure to exogenous estrogen: estrogen replacement therapy > 5 years increases the risk
5) Proliferative fibrocystic changes especially atypical hyperplasia
6) Carcinoma of the other breast or endometrial carcinoma
7) Ionizing radiation
8) Environmental toxins

8. Tabulate the difference between seminomatous and non-seminomatous tumours of the testis. (2008)

Seminoma	Non-seminoma
Remain confined to testis reaching a considerable size before diagnosis	Have wide spread metastases at the time of diagnosis in the absence of a palpable testicular mass
Metastasise by lymphatic route to para aortic and iliac lymph nodes	Metastasise early by lymphatics
Hematogenous spread is unusual	Hematogenous spread to liver and lung
Radiosensitive	Radioresistant
Better prognosis	More aggressive , poorer prognosis

Hematogenous spread is characteristic of sarcomas and some carcinomas.
1. Renal cell carcinoma (often invades renal vein)
2. Hepatocellular carcinoma (often invades hepatic vein)
3. Follicular carcinoma of the thyroid
4. Choriocarcinoma

9. Give an account on grading and staging system of prostatic carcinoma. (2000)

What's unique about grading of prostatic carcinoma? / Why is this actually an important question? Most grading systems take nuclear features and atypia into consideration. This doesn't. It's all about the architecture! GLANDULAR FORMATION

Grading:

Gleason system

Stratified into five grades on the basis of glandular patterns of differentiation

Grade 1: most well differentiated tumours; neoplastic glands are uniform and round in appearance, and packed into well-circumscribed nodules.

Grade 5: no glandular differentiation; tumour cells infiltrate the stroma in the form of cords, sheets and nests.

Staging:

T1: incidentally found cancer

T2: organ confined cancer

T3: extra-prostatic extension

T4: direct invasion of contiguous organs

In most cases, histological grading correlates with anatomic stage of carcinoma and its prognosis

10. List the prognostic factors of breast carcinoma. (2001, 06)

(stage-grade-histology-receptors-angiogenesis-proliferative index)

1) **Stage**: most important prognostic factor [TNM]
    a. Tumour size: <1cm diameter have excellent prognosis (in absence of lymph node metastasis)
    b. Lymph node involvement: no axillary LN involvement → 5 year survival rate is 90 %
    c. Distant metastasis: hematogenous spread → rarely curable
2) Tumour **grade**
3) **Histologic** type: they are classified into 3 categories

a. Non-metastasizing: in situ ductal carcinoma, in situ lobular carcinoma
b. Uncommonly metastasizing: colloid, medullary and tubular carcinoma *(the 3 IDCs with the good prognoses; NOS and inflammatory have poorer prognoses)*
c. Moderately to aggressively metastasizing: all other types

4) **Receptor** status of the tumor

Good prognosis →
a. Estrogen receptors
b. Progesterone receptors

- Respond better to chemotherapy
- Can be supplemented with estrogen receptor blocker (tamoxifen)

Bad prognosis →
c. HER2/neu: in some cases of breast cancer the gene coding this growth factor is amplified → abundant HER2 on rsurface of malignant cells → cells grow more rapidly

5) **Angiogenesis**: increases chances of metastases
6) Chromosomal **aneuploidy** and **proliferative index**

11. Discuss the role of tumour markers in the diagnosis of malignant tumours of the male genital system. (2005)

Tumour markers are important for

- Diagnosis of prostatic carcinoma
- Evaluation of testicular masses
- Staging of germ cell tumours and prostatic carcinoma
- Monitoring response to therapy
- Diagnosis of recurrence during follow-up

- Alpha-feto protein (AFP) → embryonal carcinoma, endodermal sinus tumor, mixed germ cell tumours containing yolk sac elements
- Human chorionic gonadotropin (HCG) → embryonal carcinoma, choriocarcinoma, mixed germ cell tumours containing syncytiotrophoblast elements
- Serum acid phosphatase & prostatic specific antigen → prostatic carcinoma

12. Enumerate the epithelial ovarian tumours and discuss pathology of the commonest one. (1998)

Epithelial ovarian tumours:

- Serous (most common)
- Mucinous
- Endometroid
- Brenner's

Serous tumours:

- Most common ovarian neoplasms (20 – 50 years)
- 60% benign (cystadenoma) , 25% frankly malignant (cystadenocarcinoma) , 15% of low malignant potential (borderline serous tumous)
- Bilaterality: 20% in benign, 30% in borderline, 66% in malignant
- **Gross picture:**
  - Mostly large
  - Serosal covering: smooth and glistening in benign; showing irregularities in malignant
  - Unilocular or multilocular
  - Papillae project from internal surface
  - Malignant tumours show solid areas
- **Microscopic picture:**

Benign serous cystadenoma	Borderline	Serous cystadenocarcinoma
Lined by a single layer of columnar ciliated epithelium	Stratification of epithelial cells	Stratification of epithelial cells
Papillae have delicate fibrous cores covered by a single layer of columnar cells	Complex papillae	Complex papillae

	Moderate atypia and moderate mitotic activity of their nuclei	Marked anaplasia of the lining epithelium
	No invasion of stroma	Invasion of the underlying stroma
		Presence of psammmoma bodies

Tumours with psammoma bodies: (just in case they attack us in the oral exam :D)

- Papillary carcinoma of the thyroid
- Papillary renal cell carcinoma
- Prolactinoma
- Serous cystadenocarcinoma of the ovary
- Meningioma
- Mesothelioma

13. Give an account on the morphology and complications of senile prostatic hyperplasia. (1998, 99, 2005)

It is the hyperplasia of both prostatic glands and its fibromuscular stroma

Gross morphology:

- Usually affects the periurethral glands → urethra is compressed
- The prostate is enlarged
- CS shows multiple well circumscribed nodules (solid or cystic)
- Sometimes the hypertrophied gland bulge in the urinary bladder lumen as a pedunculated mass → ball-valve urethral obstruction

Microscopic morphology:

- Hyperplastic nodules
- Varying proportions of proliferating glands and fibromucscular stroma
- Glands lined by (1) inner tall columnar cells and (2) flattened basal cells
- Some glands show intraluminal papillae
- Some are cystically dilated
- Some contain corpora amylacia (lamellated proteinaceous material) in their lumina
- Glands are separated from each other by proliferated fibromuscular stroma
- In hugely enlarged cases, there are areas of infarcts and squamous metaplasia od some glands

Clinical manifestations:

a. Frequency, urgency and nocturia
b. Difficulty in starting and stopping the urinary system
c. Painful distention of the urinary bladder

Complications:

a. Infection (cystitis and/or pyelonephritis) due to residual urine in the bladder and chronic obstruction
b. Stone formation: due to stasis + infection
c. Hypertrophy, dilatation, and urinary bladder diverticulae
d. Bilateral hydronephrosis: leading to chronic renal failure

14. Describe the gross pathologic features characteristic of the different types of infiltrating breast carcinoma and the possible skin changes. (2007)

Invasive ductal carcinoma of no special type (NOS)	Stellate shaped indurated grayish white mass with gritty sensation on cut. CS shows areas of necrosis, hemorrhage and calcification. Peau d'orange, nipple retraction and fixation to the chest wall are seen
IDC: Medullary carcinoma	Tends to be large (up to 10 cm), soft and fleshy (brainlike)
IDC: Colloid carcinoma	Extremely soft, bulky, gelatinous and grey blue masses
IDC: Inflammatory carcinoma	Erthymatous breast with peau d'orange appearance. Usually without a palpable mass
Paget's disease of the breast	Unilateral erythematous eruption with a scaly crust in the nipple. May be associated with retroareolar palpable mass.
Invasive lobular	Poorly circumscribed mass, rubbery in consistency

carcinoma (ILC)	

15. Discuss prostatic carcinoma as regards pathogenesis, modes of spread and role of tumour markers. (2007)

- Most common visceral cancer in males
- 2nd most common cause of cancer related deaths in men older than 50 years, after the carcinoma of the lung
- Peak incidence: 65-75 years
- Occult cancers of the prostate are more common than those that are clinically apparent
- **Pathogenesis**: UNKNOWN (the following are scientific suggestions)
  - Hormonal factors:
    - No prostatic carcinoma in males castrated before puberty
    - Its growth is inhibited by orchiectomy and by administration of estrogen
  - Genetic factors:
    - Increased incidence of prostatic cancer in 1st degree relatives of patients with cancer of prostate
  - Environmental factors:
    - Occurs in certain industrial settings
    - Significant geographic difference in incidence of the disease
- **Spread**:
  a. Direct: to seminal vesicles, wall of urinary bladder. Rarely to rectum.
  b. Lymphatic: early, to regional lymph nodes
  c. Blood: especially to bones

- Use of **tumour markers**: PSA prostatic specific antigen and Serum acid phosphatase
  - Diagnosis
  - Monitoring the presence of metastases

Occult carcinoma: very small at its primary site and presents first with metastasis. Examples? Prostatic carcinoma, malignant melanoma, papillary carcinoma of the thyroid

- Monitoring the progress of the disease
- Monitoring the response to therapy

16. Compare between carcinoma of the cervix uteri and the carcinoma of the body of the uterus. (2000, 04)

Cervical Carcinoma	Endometrial Carcinoma
Risk factors 1. Infection with HPV types 16 & 18 2. Sexual activity at an early age 3. Multiple high risk sexual partners 4. Multiparity 5. Cigarette smoking 6. Immunosupression 7. CIN: ALL cervical squamous cell carcinomas arise from the precursor CIN	**Risk factors** 1. Endometrial hyperplasia 2. Prolonged unopposed estrogen stimulation (anovulatory cycles, polycystic ovary syndrome, early menarche, late menopause, estrogen replacement therapy, estrogen producing ovarian tumours, infertility, nulliparity, obesity) *<Check answer no. 5>* 3. Corpus cancer syndrome (DM, HTN and Obesity)
Precursor CIN cervical intraepithelial neoplasia	**Precursor** Endometrial hyperplasia (complex and atypical complex)
Gross May be present in 3 forms • Ulcerative • Exophytic fungating mass • Endophytic invasive lesion (barrel shaped cervix)	**Gross: 2 pictures** 1. Exophytic polypoidal mass projecting into the uterine cavity 2. Infiltrative lesion into the myometrium
Microscopic • From epithelium: squamous cell carcinoma (most common!)	**Microscopic: 2 types** Type 1: Estrogen dependant Picture: Endometrioid adenocarcinoma

• From endocervical glands: adenocarcinoma • Mixed: adenosquamous carcinoma • Small cell carcinoma and undifferentiated carcinoma	Most common – post menopausal occurrence – related to prolonged estrogen exposure – better prognosis Type 2: Non-estrogen dependant Pictures: papillary serous carcinoma, clear cell carcinoma, malignant mixed mullerian tumour Less common – occurs in older age – not related to estrogen exposure – worse prognosis
Spread: 1. Local spread (to uterus, vagina, ureters, rectum and urinary bladder) 2. Lymphatic spread (involves chains of lymph nodes in pelvis: aortic, common iliac, internal and external iliac) 3. Blood spread (to lungs, liver, bone)	**Spread** 1. Local: • To fallopian tubes → peritoneal spread • Penetrate uterus → parametrium • To cervix & vagina 2. Lymphatic: para-aortic, internal iliac lymph nodes 3. Hematogenous: bones, liver, lung
Staging: 0: carcinoma in situ = CIN III I: confined to cervix uteri II: cervix + adjacent body of uterus + upper 2/3 of vagina (not invading the pelvic wall) III: invades the pelvic wall, involves the lower 1/3 of vagina IV: outside the true pelvis OR involve the mucosa of rectum or bladder	**Staging:** I: confined to corpus uteri II: Cervix + corpus uteri III: Outside the uterus, inside the true pelvis IV: Outside the true pelvis OR involve the mucosa of rectum or bladder

17.Discuss benign tumours of the breast. (2000)

Fibroadenoma	**Intraductal papilloma**
Most common benign tumour of female breast Usually in young females before 30 yo	In women at or shortly before menopause
Arises from intralobular stroma The neoplastic component is the stromal element The epithelial growth is secondary to growth factors secreted from the neoplastic stromal element Absolute or relative increase in estrogen is thought to have a role → slight increase in size during late menstrual cycle → regression after menopause	Neoplastic papillary growth develops within a principle lactiferous duct near the nipple
Clinical picture: Solitary, discrete movable mass (breast mouse)	1. Serous or bloody nipple discharge 2. Small subareolar mass few mm in diameter 3. Rarely nipple retraction
Gross picture: -Usually solitary -Encapsulated - 1-10cm in diameter -firm in consistency -CS is grayish white	Large duct papillomas: solitary consisting of delicate branching growths within a dilated duct attached to the wall of the duct by a fibrovascular stalk. Small duct papillomas: multiple, deeply found within the ductal system
Microscopic picture: -elongated and tubular ducts	

-lined by low cuboidal to flattened epithelial cells -surrounded by loose fibrous stroma	-multiple papillae having a CT core covered by 2 layers of cells: cuboidal and myoepithelial cells *(Side-note: Myoepithelial cells are absent in papillary carcinoma. That's how we differentiate between them)*
PS: no increased risk for carcinoma!!	Solitary papillomas are usually benign Small multiple papillomas increase the risk the risk of subsequent malignancy → ductal carcinoma

18.Give an account on testicular atrophy. (2000)

It may occur as a primary developmental abnormality in patients with Kleinfelter's syndrome (XXY). It may be secondary to

- Cryptorchidism (undescended testis)
- Obstruction of semen outflow
- Vascular disease
- Inflammatory disease
- Malnutrition
- Hypopituitarism
- Elevated level of female sex hormones
- Persistently high FSH
- Radiation
- Chemotherapy

19.Determine sites, morphology and complications of endometriosis (2005,08)

Definition: presence of functional endometrial tissue (BOTH GLANDS AND STROMA) outside the uterus

Sites:

1. Ovary
2. Ovarian and uterine ligaments

} Most common

3. Douglas pouch
4. Serosa of bowel and urinary bladd
5. Peritoneal cavity

} All 3 related to peritoneum somehow

6. Laparotomy scars *(surgical incision in abdomen)*
7. Rare sites: vagina, vulva, appendix, umbilicus, lung, lymph nodes, heart, bone

Morphology: **Gross**:

- Red brown nodules → due to cycling hemorrhage in the functional endometrial tissue
- May form chocolate cysts (especially in ovaries)

Microscopic: 2 out of 3 findings should be found

- Endometrial glands
- Endometrial stroma
- Hemosiderin pigmentation

Clinical picture and complications:

a. Severe dysmenorrhea → intra-pelvic bleeding & peri-uterine adhesions
b. Dysparunia
c. Dyscasia → involvement of rectal wall
d. Dysuria → involvement of urinary bladder
e. Infertility → fibrosis → sealing of fallopian tubes
f. Acute abdomen → rupture of chocolate cysts

(Informally: Infertility & Pain: painful urination, defecation, intercourse, menstrual period.

Complication → rupture → acute abdominal pain)

20.Give an account on the fibroadenoma of the breast. (2005)

Check answer 17 (or try answering it yourself ☺)

21.Give an account on the teratoma of the testis. (2005)

Definition: a group of neoplasms that show evidence of simultaneous differentiation along the 3 germ lines.

Incidence age: at any age

Gross picture: variegated appearance, firm in consistency, CS shows cysts and cartilaginous areas.

Microscopic picture:

Mature	Immature	With malignant transformation
• Contain fully differentiated tissues from the 3 germ lines in haphazard arrangement. • More common in infants and children. • Considered malignant in adults.	• Contain elements of the 3 germ lines but in incomplete stages of differentiation. • Malignant, especially in adults	• Frank malignancy in a mature teratoma [adenocarcinoma, squamous cell carcinoma] • Occurs in adults.

22.Discuss the pathology of endometrial carcinoma. (1999)

Risk factors:

1. Endometrial hyperplasia
2. Prolonged unopposed estrogen stimulation (anovulatory cycles, polycystic ovary syndrome, early menarche, late menopause, estrogen replacement therapy, estrogen producing ovarian tumours, infertility, nulliparity, obesity) *<Check answer no. 5>*
3. Corpus cancer syndrome (DM, HTN and Obesity)

Precursor: Endometrial hyperplasia (complex and atypical complex)

Gross: 2 pictures

1. Exophytic polypoidal mass projecting into the uterine cavity
2. Infiltrative lesion into the myometrium

Microscopic: 2 types

Type 1: Estrogen dependant

- Picture: Endometrioid adenocarcinoma
- Most common – post menopausal occurrence – related to prolonged estrogen exposure – better prognosis

Type 2: Non-estrogen dependant

- Pictures: papillary serous carcinoma, clear cell carcinoma, malignant mixed mullerian tumour
- Less common – occurs in older age – not related to estrogen exposure – worse prognosis

Spread

1. Local:
   A. To fallopian tubes → peritoneal spread
   B. Penetrate uterus → parametrium
   C. To cervix & vagina
2. Lymphatic: para-aortic, internal iliac lymph nodes
3. Hematogenous: bones, liver, lung

Staging:

- I: confined to corpus uteri
- II: Cervix + corpus uteri
- III: Outside the uterus, inside the true pelvis
- IV: Outside the true pelvis OR involve the mucosa of rectum or bladder

---

6- pharmacology

1. Mention 2 pharmacological actions, therapeutic uses & side effects of Anabolic Steroids. (Give an Example)

- **Pharmacological Actions :**
  1) Increase protein anabolism by increasing incorporation of AA to proteins & stimulation of RNA polymerase.
  2) Antagonize the Catabolic Effect of Glucocorticoids.
- **Therapeutic Uses :**
  1) Short Stature
  2) Hypoproteinemia of Nephrosis
  3) Debilitated Postoperative patients , burns & premature babies
- **Side Effects :**
  1) In female ; Virilization
  2) In children ; Precocious puberty
  3) In male ; Azospermia & 2ry Hypogonadism
  4) Fuild retention
  5) Cholestatic Jaundice
- **Ex ; Nandrolone Phenopropionate**

---

2. Estrogen must be taken with Progesterone in Contraceptive pills.

- Estrogen mainly suppresses FSH release which is not enough for conception.
- Progesterone causes down-regulation of Estrogen receptors , so the Unwanted Side Effects of Estrogen decreases .

Such as ; Thromboembolisms , Carcinogenic effect, … etc

---

3. Mention pharmacological actions of Combined Oral Pills.

1) Inhibition of **Ovulation** :

Estrogen à (-) FSH

Progesterone à (-) LH

2) Inhibition of **Implantation** à Endometrial Changes that don't fit the Fertiliz ed Ovum
3) Inhibition of **Fertilization** : Progesterone increases the Viscosity of Cervical mucus secretion

---

4. List 6 Side Effects of Combined Contraceptive pills

عندك حبة بتوع الـ Estrogen
+ 3 ليهم علاقة بالـ GIT ...
(GIT disturbance, Gall bladder disease, Metabolic disorders)
+ 2 ليهم علاقة بالـ CNS (Mental depression + Optic neuritis)

1) Edema (Na & Water Retention)
2) Thromboembolism
3) Gall bladder diseases
4) GIT Disturbance
5) Metabolic disorders
6) Mental Depression
7) Optic Neuritis

---

5. Mention generic name for virilizing androgen & another for anabolic androg en. (2014)

Virilizing androgen à Testosterone
Anabolic androgen à Nandrolone Phenopropionate , Meth-andro-steno-lone

---

6. Mention a name of Oral Vasodilator drug for Erectile dysfunction & explain i ts mechanism of action. (2013)

Oral Vasodilator à Sildenafil , Tadalafil (Selective PDE5 Inhibitors)

Mechanism :

- Selectively inhibits Phosphodiesterase isoenzyme type 5 .

- So, It increases cGMP level which maintain VD & erection .

7. Mention 3 clinical indications for Oxytocin. (2014)

1) Induction of Labor
2) Incomplete Abortion
3) Promotes Milk ejection

---

8. Mention 2 regimens used to conduct male conception. (Only drug NAMES) (2014)

1) Testosrerone alone (High Dose)
2) Testtosterone + Progestin

"الحمد لله الذي هدانا لهذا وما كنّا لنهتدي لولا أن هدانا الله , و آخر دعوانا أن الحمد لله رب العالمين "

ASM 2019 team ☺