Histology Lab –Liver, Gallbladder, Pancreas & spleen

Liver

Liver

Function
Central metabolic organ: energy metabolism, nutrient storage, synthetic functions (e.g., gluconeogenesis, plasma protein synthesis, bile acid synthesis), detoxification

Size
Approx. 20 × 15 × 10 cm, wedge-shaped

Weight
Approx. 1.2–1.5 kg in adults

Location
Right upper abdomen; intraperitoneal (except bare area)

Arterial supply
Celiac trunk → common hepatic artery → hepatic artery proper → right hepatic artery/left hepatic artery

Venous drainage
Right/left/middle/minor hepatic veins → inferior vena cava

Notable features
Portal venous system:
The hepatic portal vein supplies nutrient-rich blood from the digestive organs for processing to the liver.

Associated symptoms
Jaundice, edema, ascites

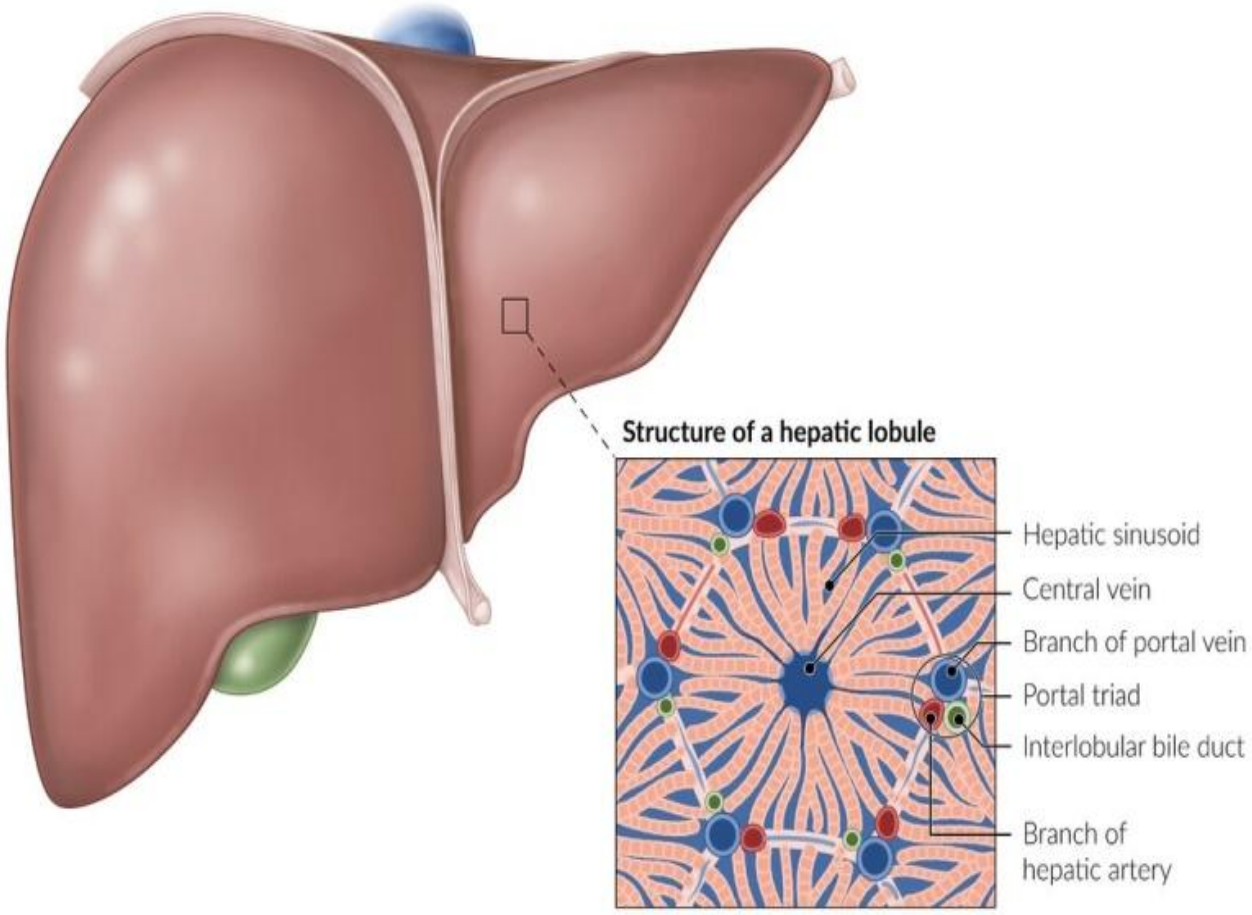

- Microscopically, the liver is divided into lobules, each with a central vein and a portal triad.
- Each portal triad consists of an artery, vein, and bile ductule, and is accompanied by lymphatic vessels and a branch of the vagus nerve.
- Liver parenchyma consists of hepatocytes and hepatic sinusoids.
- Hepatic sinusoids drain into the central vein of each lobule.



- **Hepatic lobules**: Sheets of connective tissue divide the liver into small hexagonal units called lobules. These consist of:
- A central vein in the middle
- Portal triads at the vertices

❖ A portal triad consists of:

✔ Branch of hepatic artery proper

✔ Branch of portal vein

✔ Bile ductule

❖ Each portal triad is accompanied by the following structures:

- Lymphatic vessels
- branch of the vagus nerve

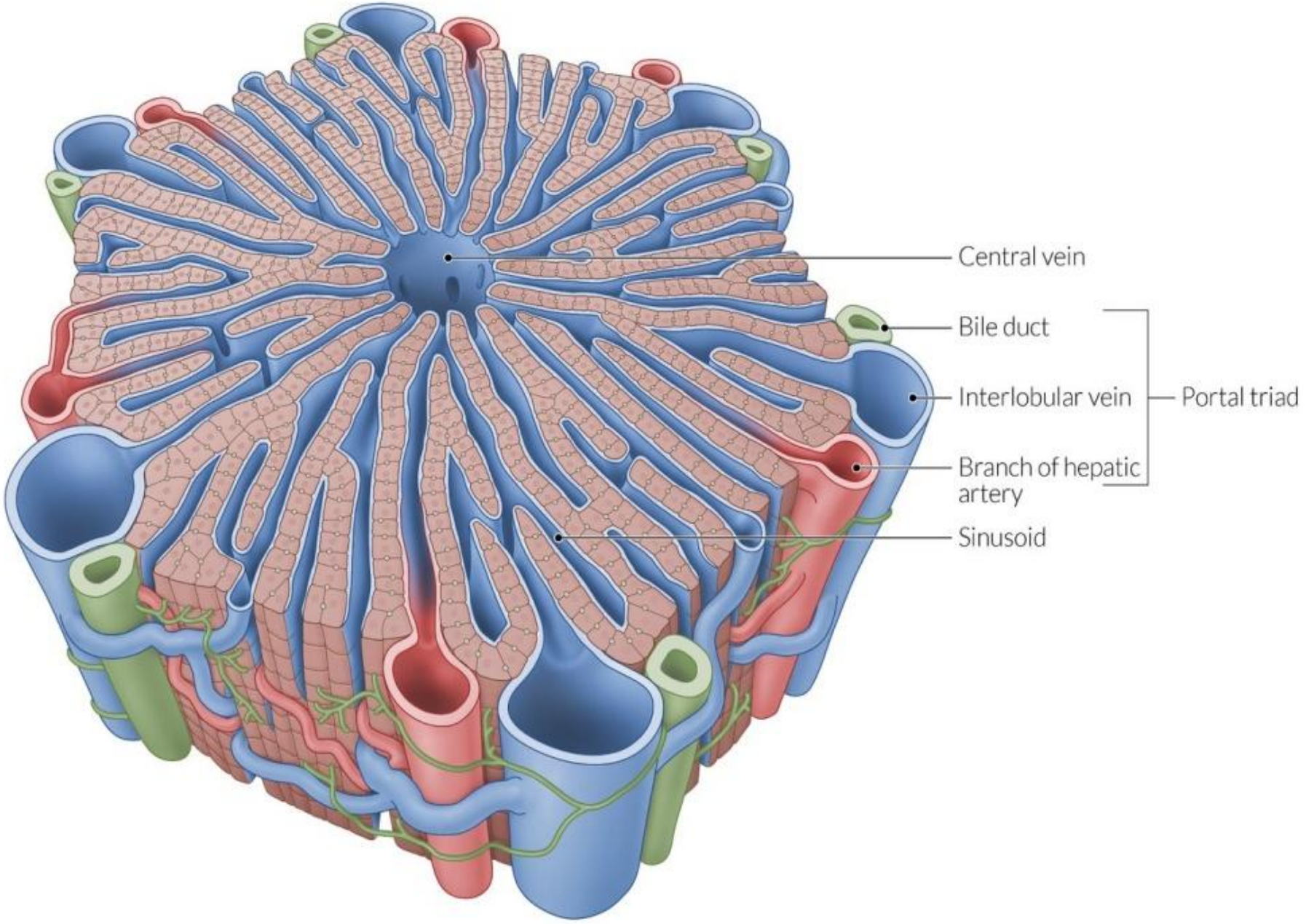
Central vein
Bile duct
Interlobular vein
Portal triad
Branch of hepatic artery
Sinusoid

- Parenchyma
- Mostly consists of hepatocytes
- Contain large amounts of smooth endoplasmic reticulum, which is involved in detoxification
- The basolateral surface of hepatocytes faces the sinusoids. .
- The apical surface of hepatocytes faces the lumen of the bile canaliculi.
- Hepatocytes secrete bile into the canaliculi → secretions flow parallel to the sinusoids, but in the opposite direction of blood → bile canaliculi form the intrahepatic bile ducts → common bile duct (delivers bile into the duodenum)
- Hepatic sinusoids are large capillaries lined with highly fenestrated endothelial cells: Blood flows through the sinusoids and empties into the central vein of each lobule.

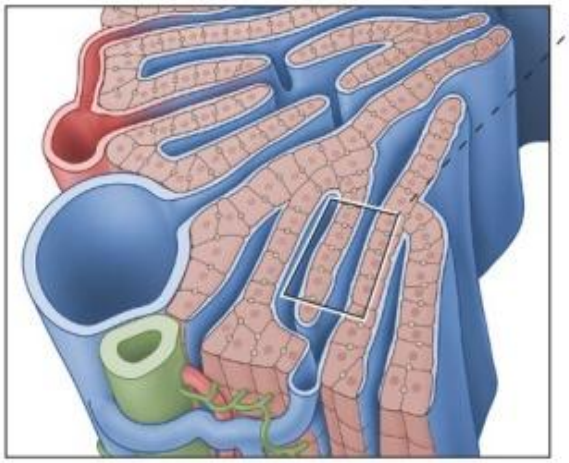

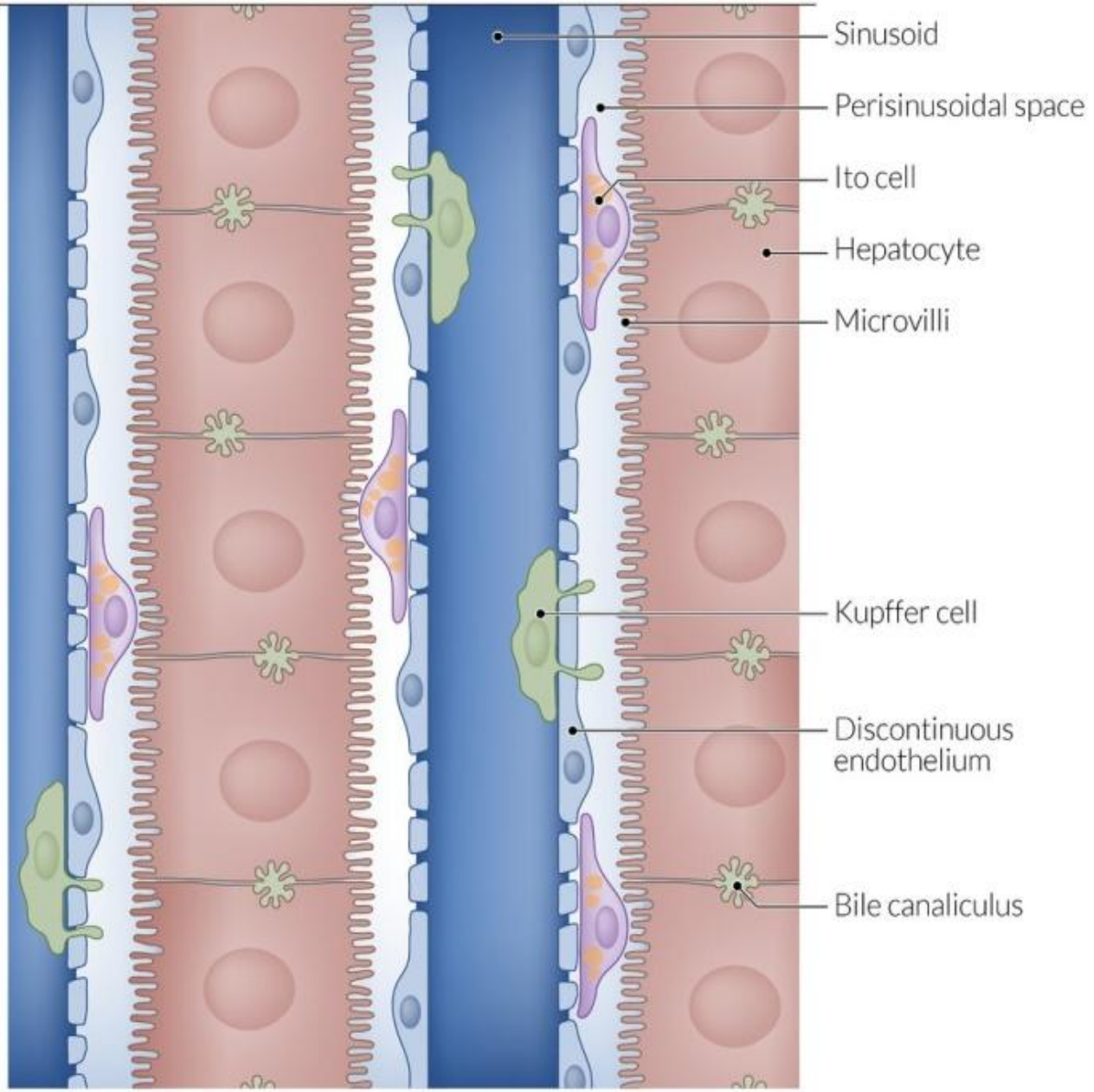
Sinusoid
Perisinusoidal space
Ito cell
Hepatocyte
Microvilli
Kupffer cell
Discontinuous endothelium
Bile canaliculus

- **Functions**
- Absorption of nutrients from blood and secretion of products synthesized by special carriers into the blood
- **Kupffer cells** (a type of macrophage) are housed in the sinusoids. These cells phagocytize foreign particles, bacteria, and damaged, old blood cells.
- The plasma-filled space between the sinusoids and hepatocytes is called the **perisinusoidal space (of Disse)**: contains hepatic **stellate cells (Ito cells),** which store vitamin A and are the main source of extracellular matrix production in liver injury (formation of scar tissue → fibrosis)

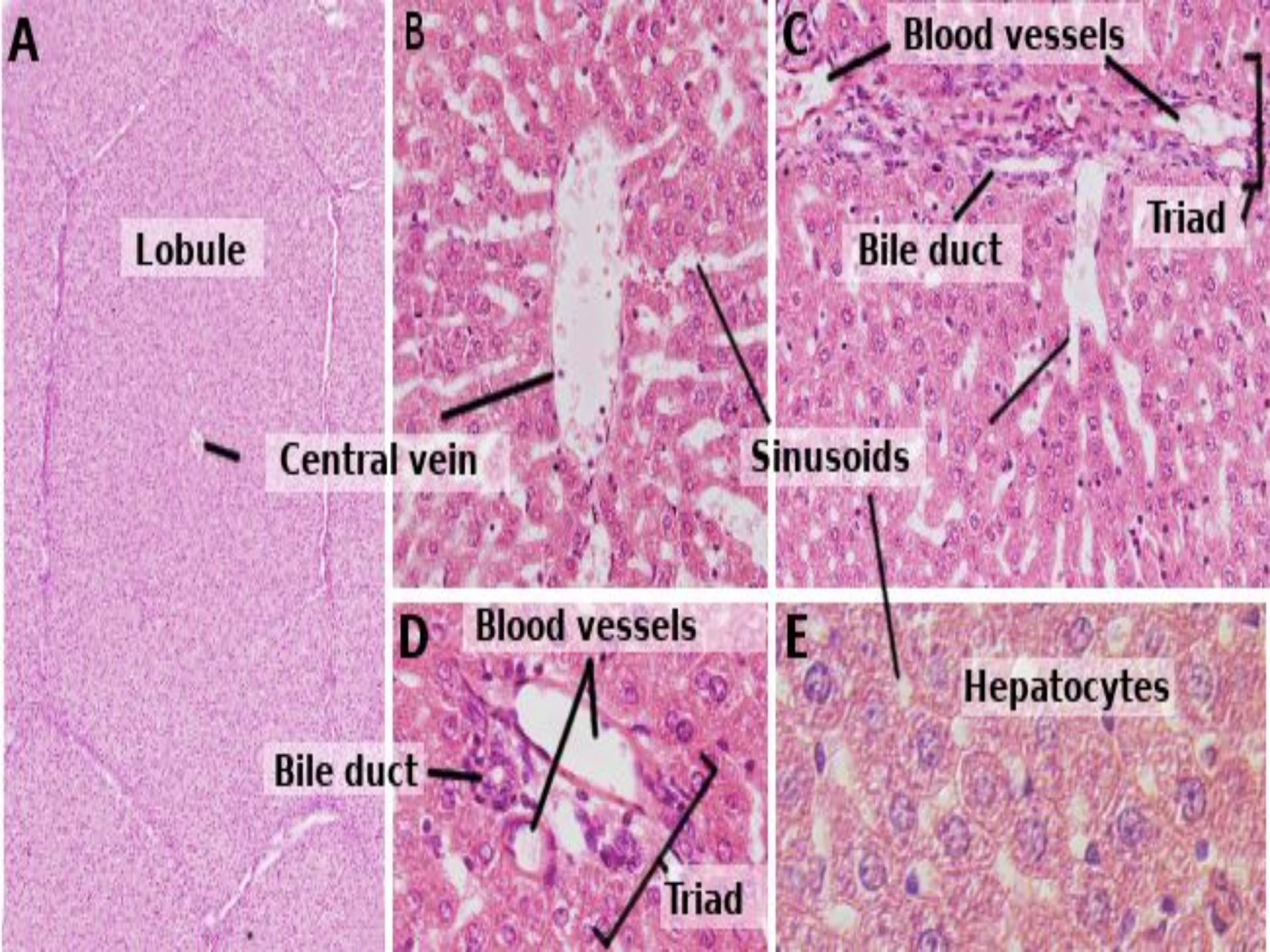
A
Lobule
Central vein
B
Sinusoids
C
Blood vessels
Bile duct
Triad
D
Blood vessels
Bile duct
Triad
E
Hepatocytes

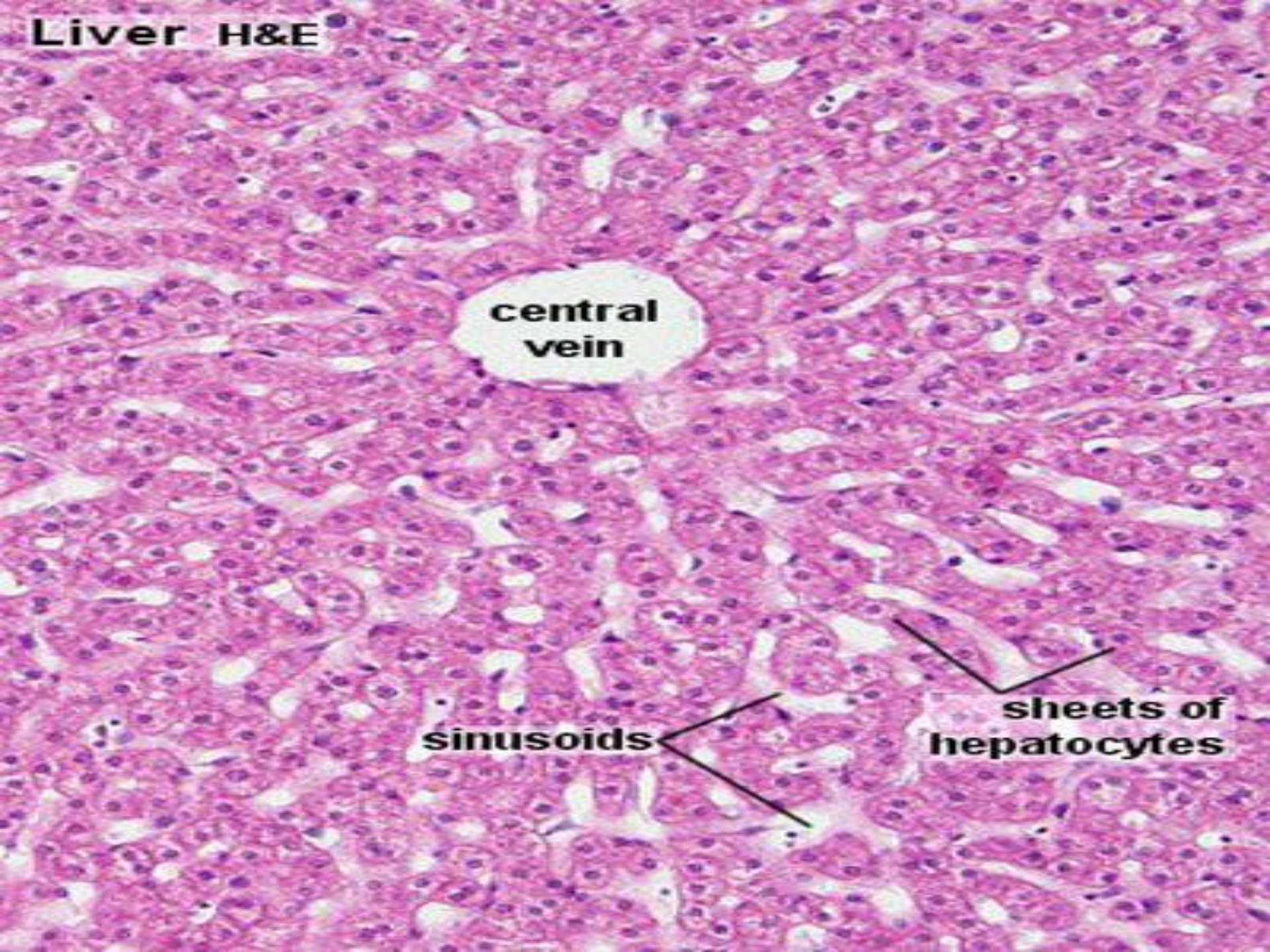
Liver H&E
central vein
sinusoids
sheets of hepatocytes

GALLBLDDER

- Layers of the gallbladder wall
- Serosa (on the inferior peritoneal surface) and adventitia (on the superior hepatic surface)
- Muscularis externa
- Lamina propria
- Mucosa

-Simple columnar epithelium with microvilli

-Secretes mucin

- The gallbladder has no submucosa or muscularis mucosae.

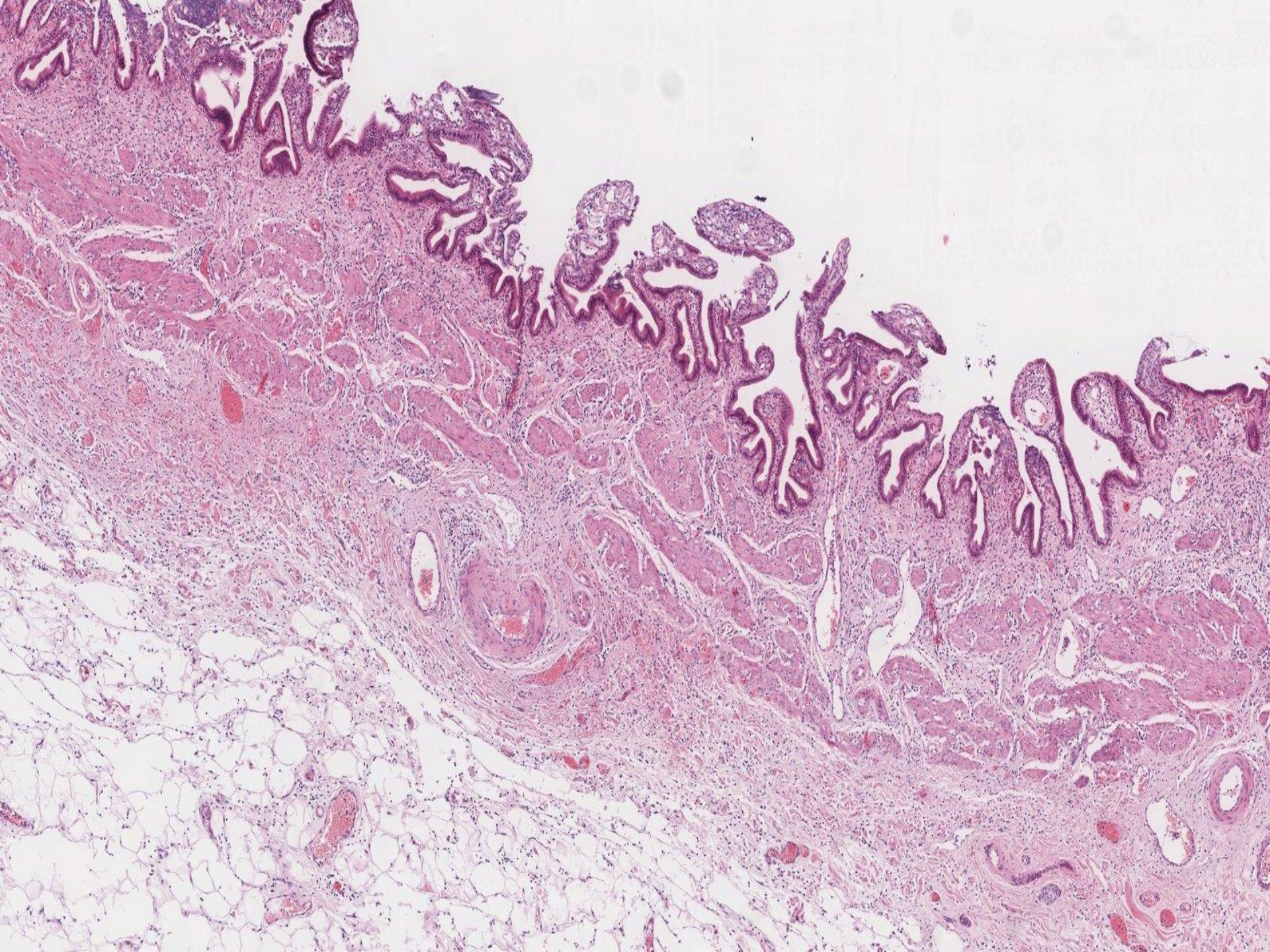

Gallbladder: normal histology

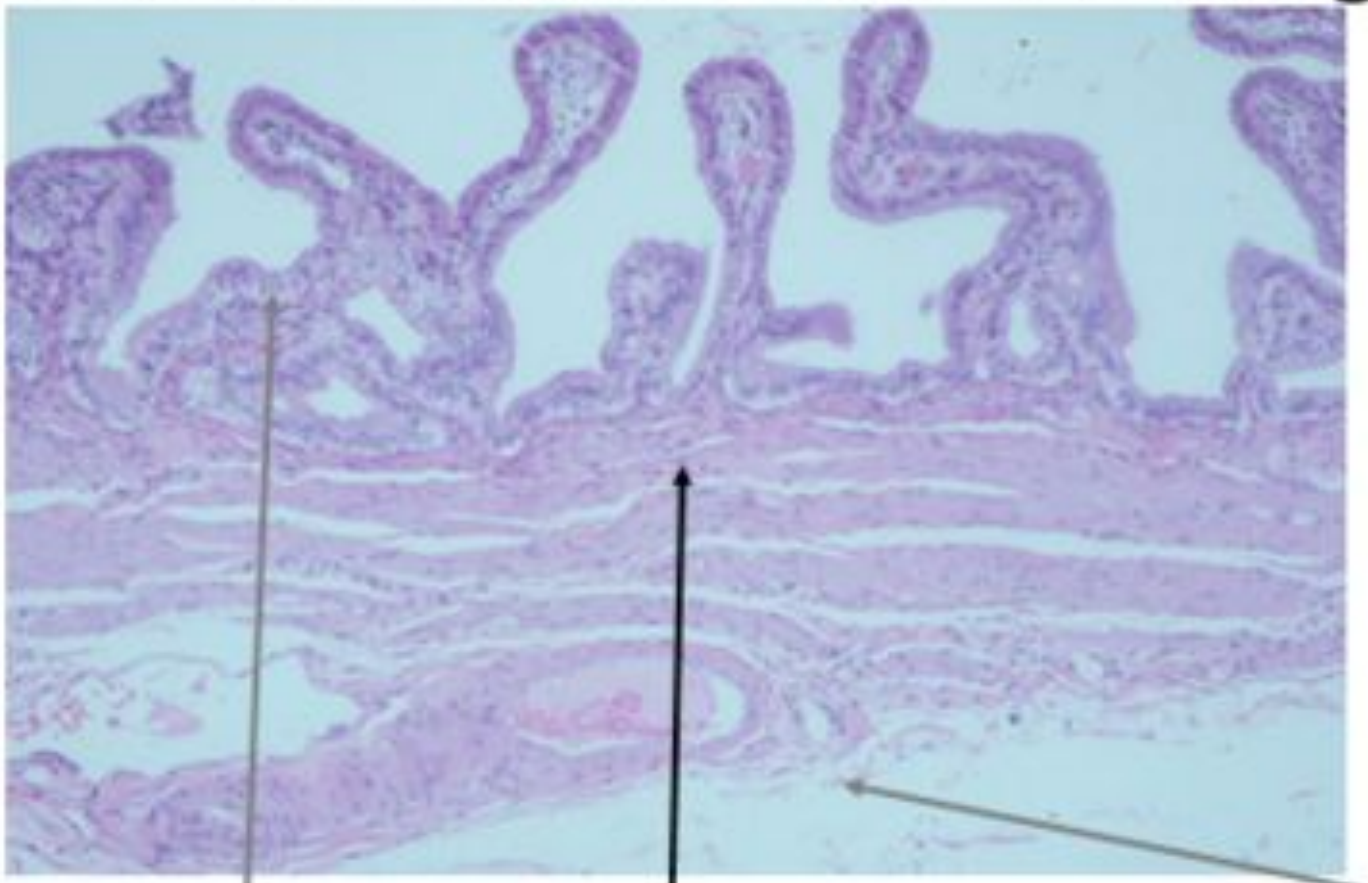

Note:
part of GB
is embedded
in liver:
Opportunity
for direct
spread to
liver of
infection or
malignancy

Mucosa: single layer
Of columnar cells

Single Fibromuscular layer
(not muscularis mucosae
and muscularis propria)

Serosal fat layer with
arteries, veins, nerves
and ganglia

PANCREAS

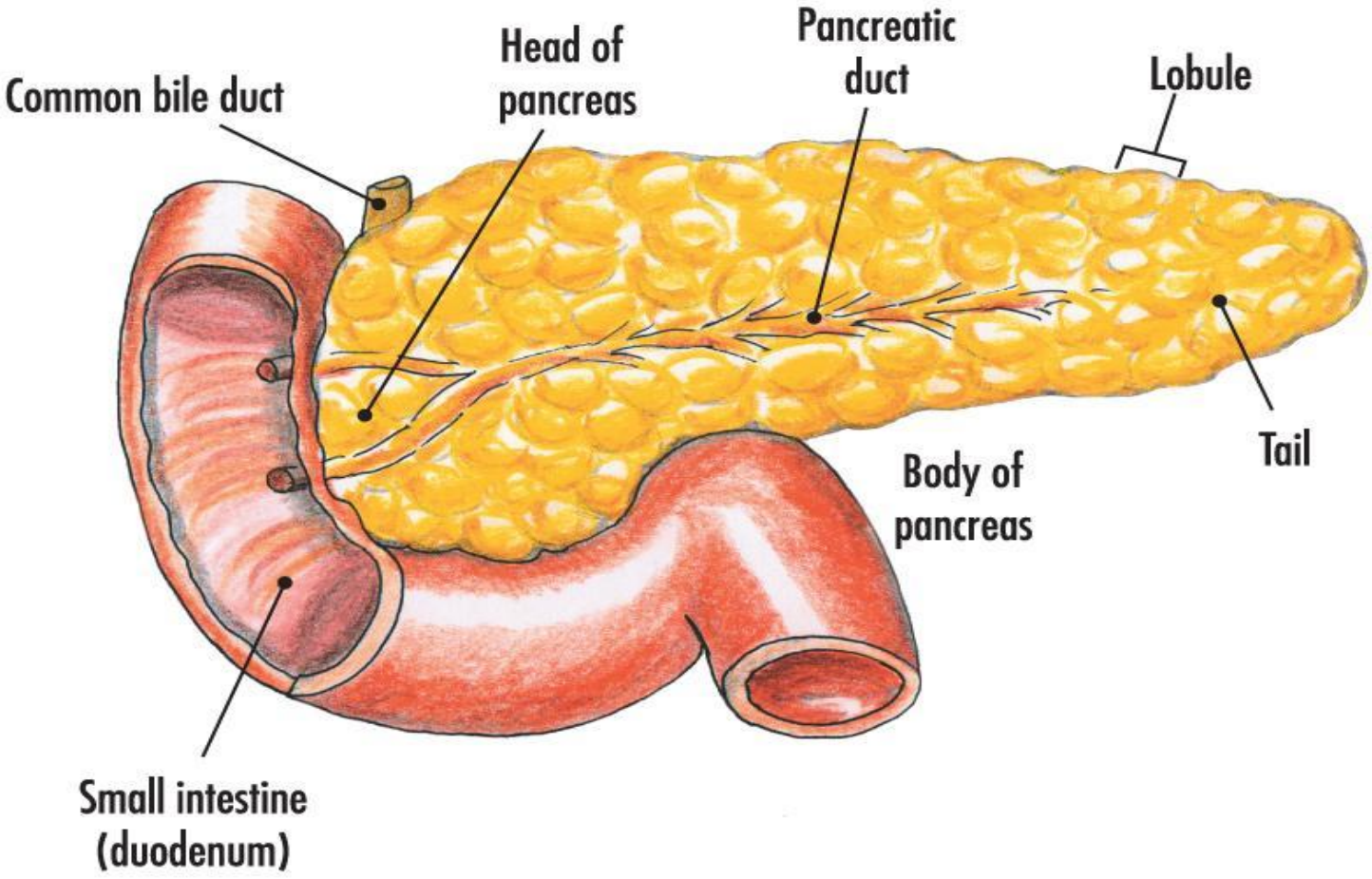
Common bile duct
Head of pancreas
Pancreatic duct
Lobule
Tail
Body of pancreas
Small intestine (duodenum)

- Exocrine pancreas
- > 90% of the pancreas
- Produces digestive enzymes that are secreted into the gastrointestinal tract
- Composed of serous glandular tissue that is separated into lobules by collagenous septae
- Pancreatic acini
  - Units of secretory acinar cells surrounding a small lumen
  - Secrete proenzymes (e.g., trypsinogen, chymotrypsinogen) into intercalated ducts → ducts eventually merge to form the pancreatic duct → duct carries the enzymes out of the pancreas and to the duodenum
  - Centroacinar cells: pale cells in the center of the acini, which secrete bicarbonate ions into the pancreatic fluid

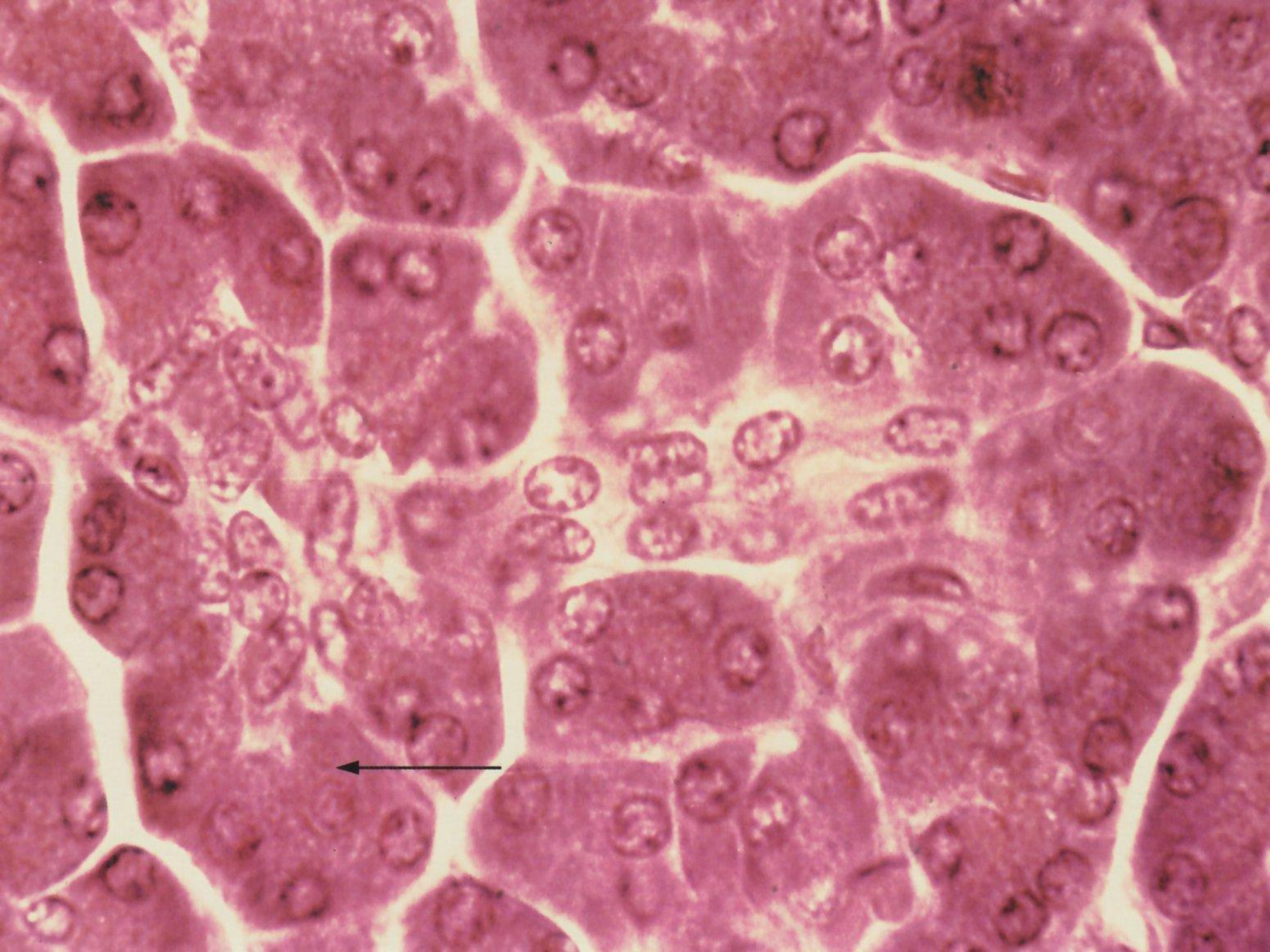

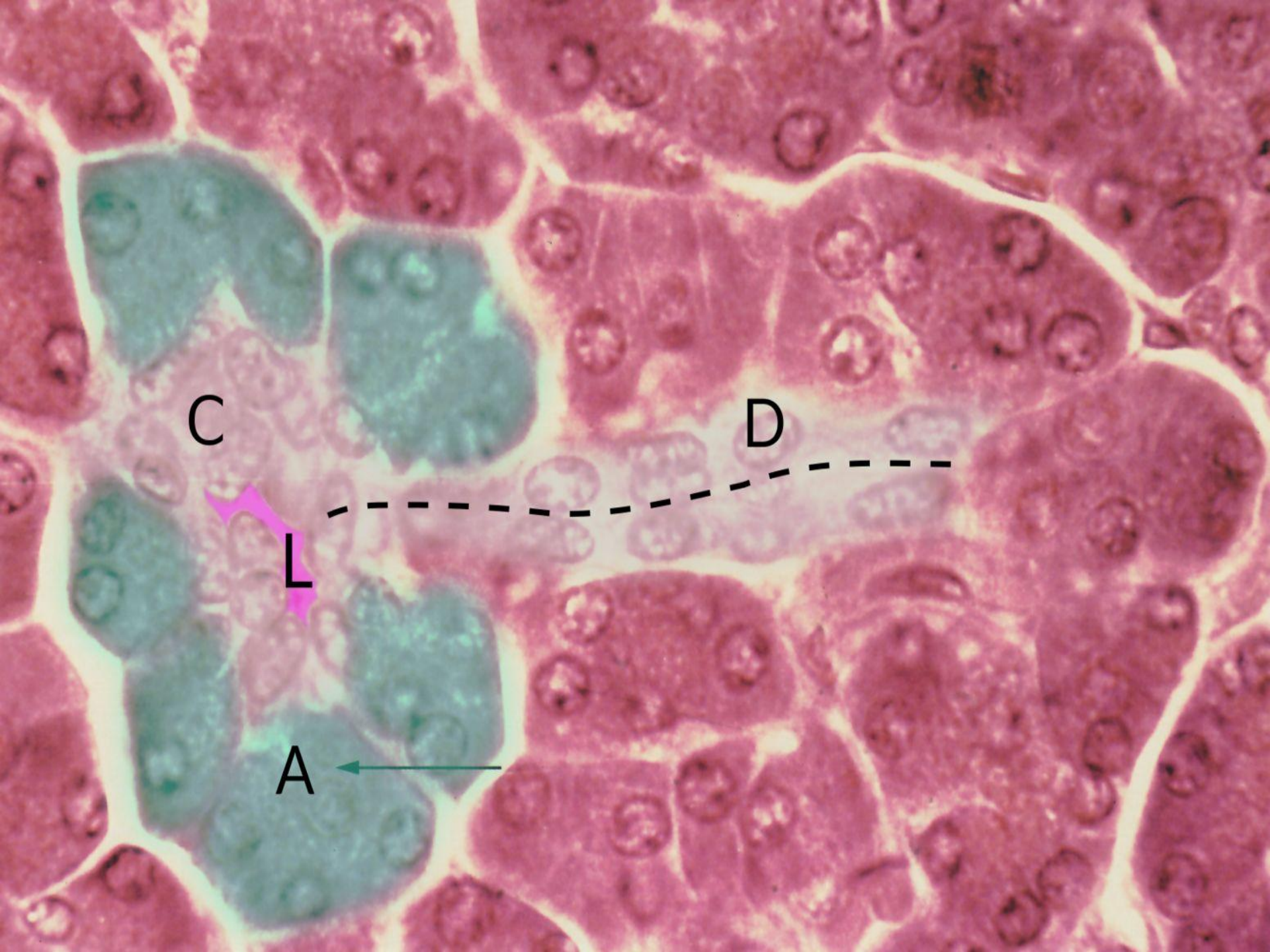
C
D
L
A

- Endocrine pancreas
- Produces different hormones that are primarily involved in the regulation of blood glucose levels
- Composed of islets of Langerhans embedded within the exocrine pancreas
- Islet cell types are dispersed throughout the pancreas.
- Alpha cells produce glucagon.
- Beta cells produce insulin.
- Delta cells produce somatostatin.
- Pancreatic polypeptide cells (formerly gamma cells) produce pancreatic polypeptide (PP).



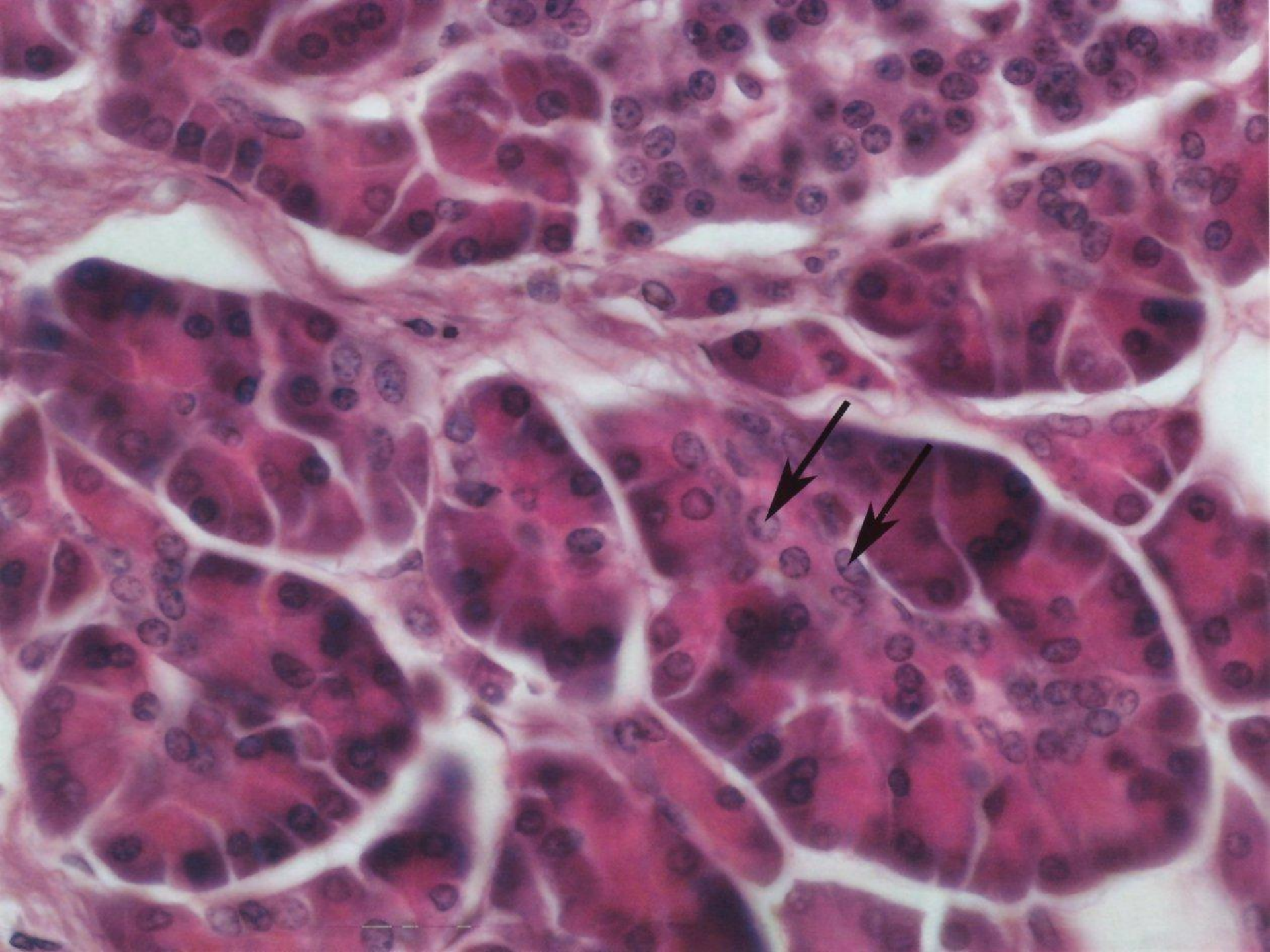

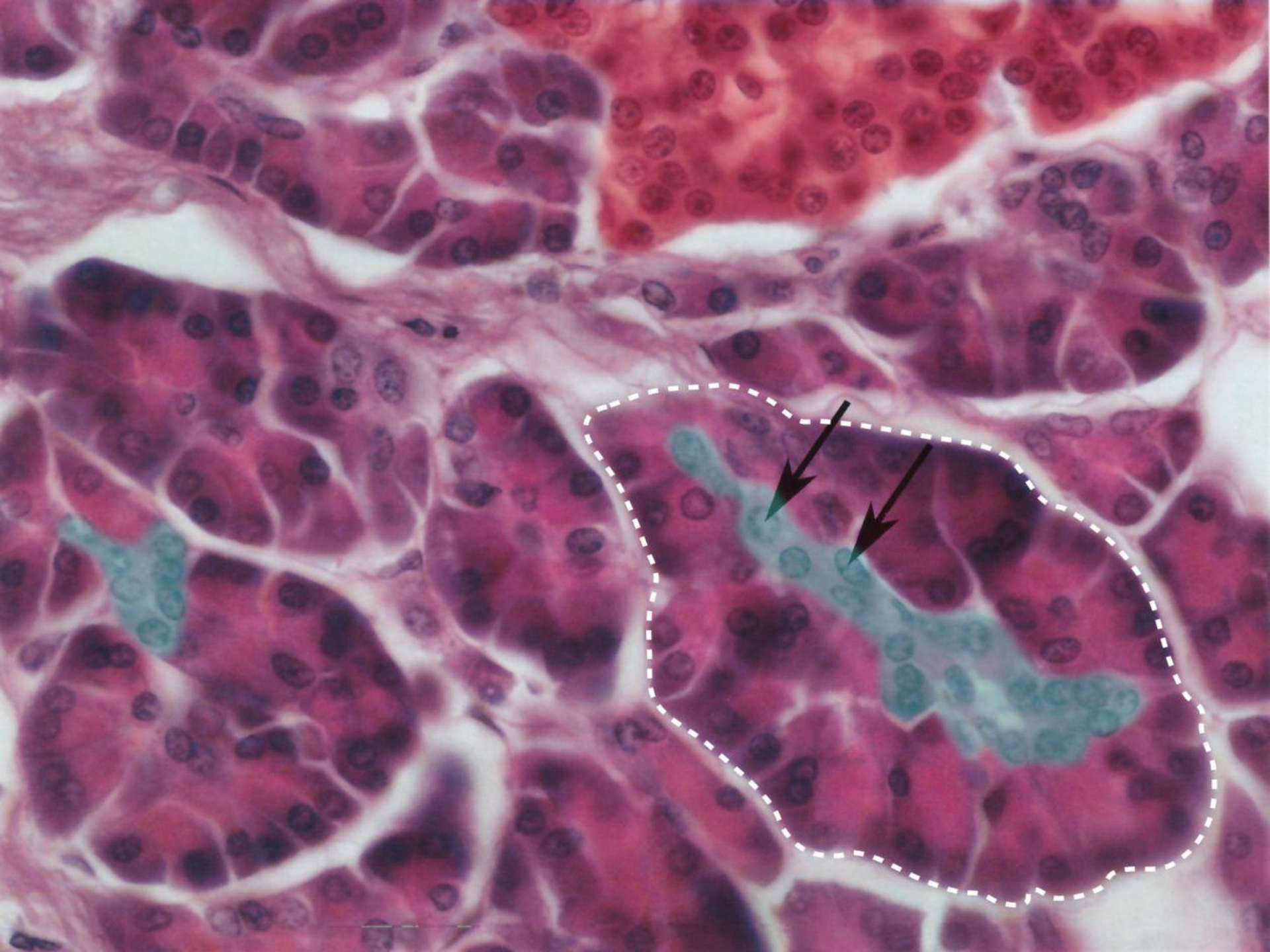

- Pancreatic ducts
- Smaller ducts have cuboidal epithelium.
- Larger interlobular ducts have columnar epithelium.
- Most pancreatic malignancies are adenocarcinomas that originate in the ductal epithelium.



- Histologically, the exocrine pancreas closely resembles the salivary glands. However, unlike the salivary glands, the pancreatic exocrine glands lack myoepithelial cells in the acini and do not possess striated ducts. Additionally, centroacinar cells are unique to the pancreas.

SPLEEN

- The spleen is made of red pulp and white pulp, separated by the marginal zone

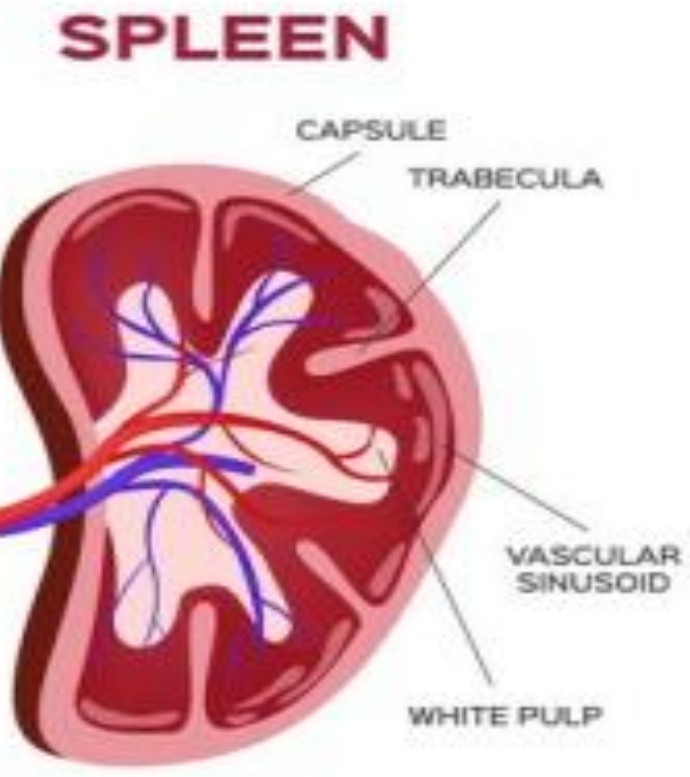

RED PULP

- Red pulp
- Red pulp is composed of splenic cords and sinuses (sinusoids).
- **Splenic cords:** a reticular meshwork filled with blood (open circulation system) that filters the blood from damaged erythrocytes
- **Spleen sinusoids**: long vessels with a fenestrated ring-like ("barrel hoop") basement membrane that prevent old or malformed RBCs/platelets from reentering venous circulation
- Open circulation: Blood empties from sheathed capillaries into the splenic cords and then enters the sinusoids through slits in the vessel wall.
- Closed circulation: Blood empties from sheathed capillaries of the red pulp directly into the sinusoids.
- **Macrophages:** found in the cords and around the sinusoids
- Phagocytosis of damaged RBCs/platelets that do not reenter circulation
- Capture of viruses and opsonized pathogens that enter the red pulp
- Blood flow: splenic artery → arterioles → red pulp (cords → sinusoids) → venules → splenic vein → portal circulation

WHITE PULP

- Periarteriolar lymphatic sheath (PALS)
- Surrounds the arterioles
- Dense lymphoid tissue containing T lymphocytes
- Splenic follicles
- Main component of white pulp
- Close to PALS
- Contain B lymphocytes
- Splenic marginal zone
- Located between the red pulp and white pulp
- Contains antigen-presenting cells (APCs): macrophages and specialized B cells (marginal zone B cells)

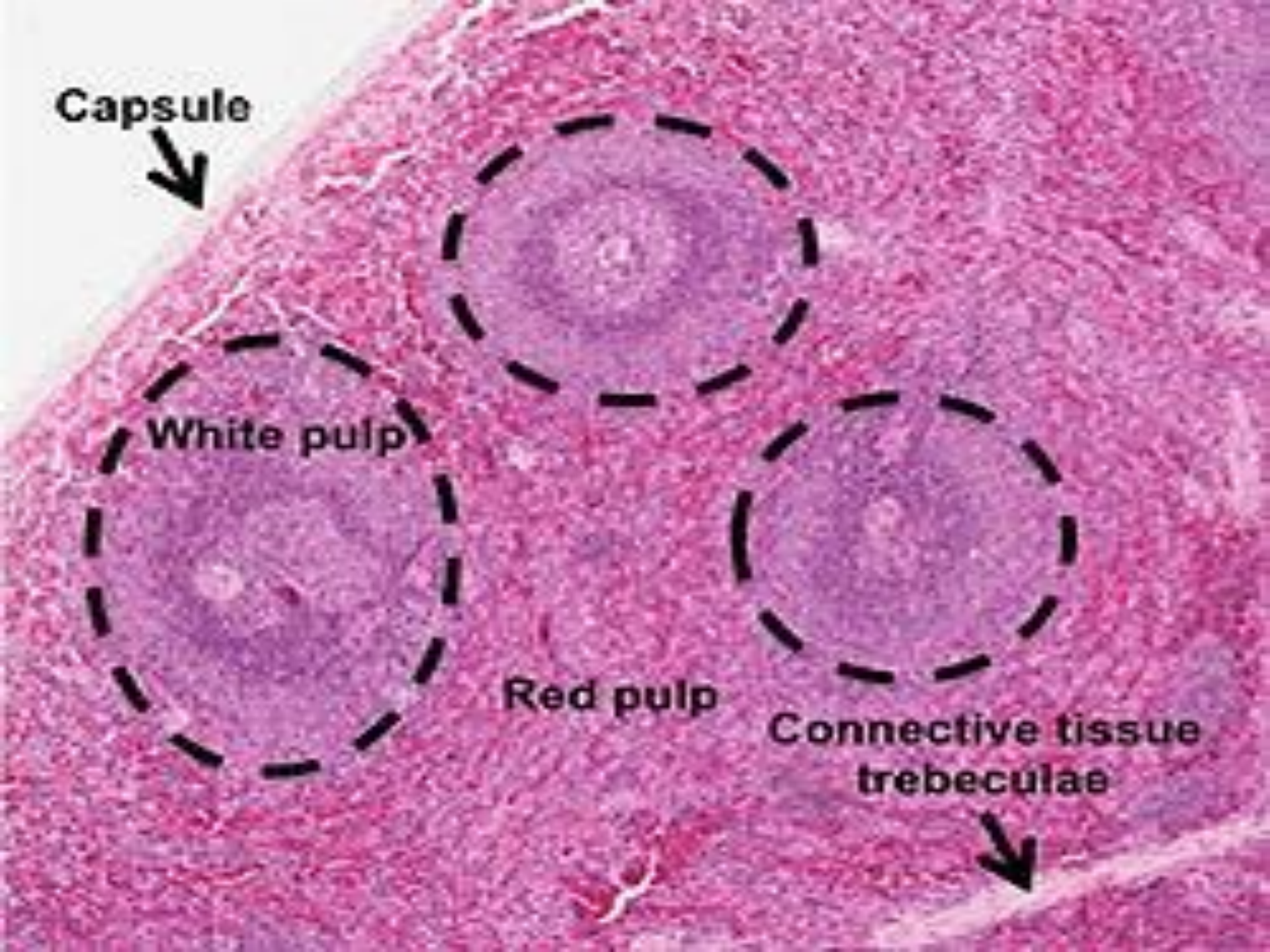
Capsule
White pulp
Red pulp
Connective tissue trebeculae

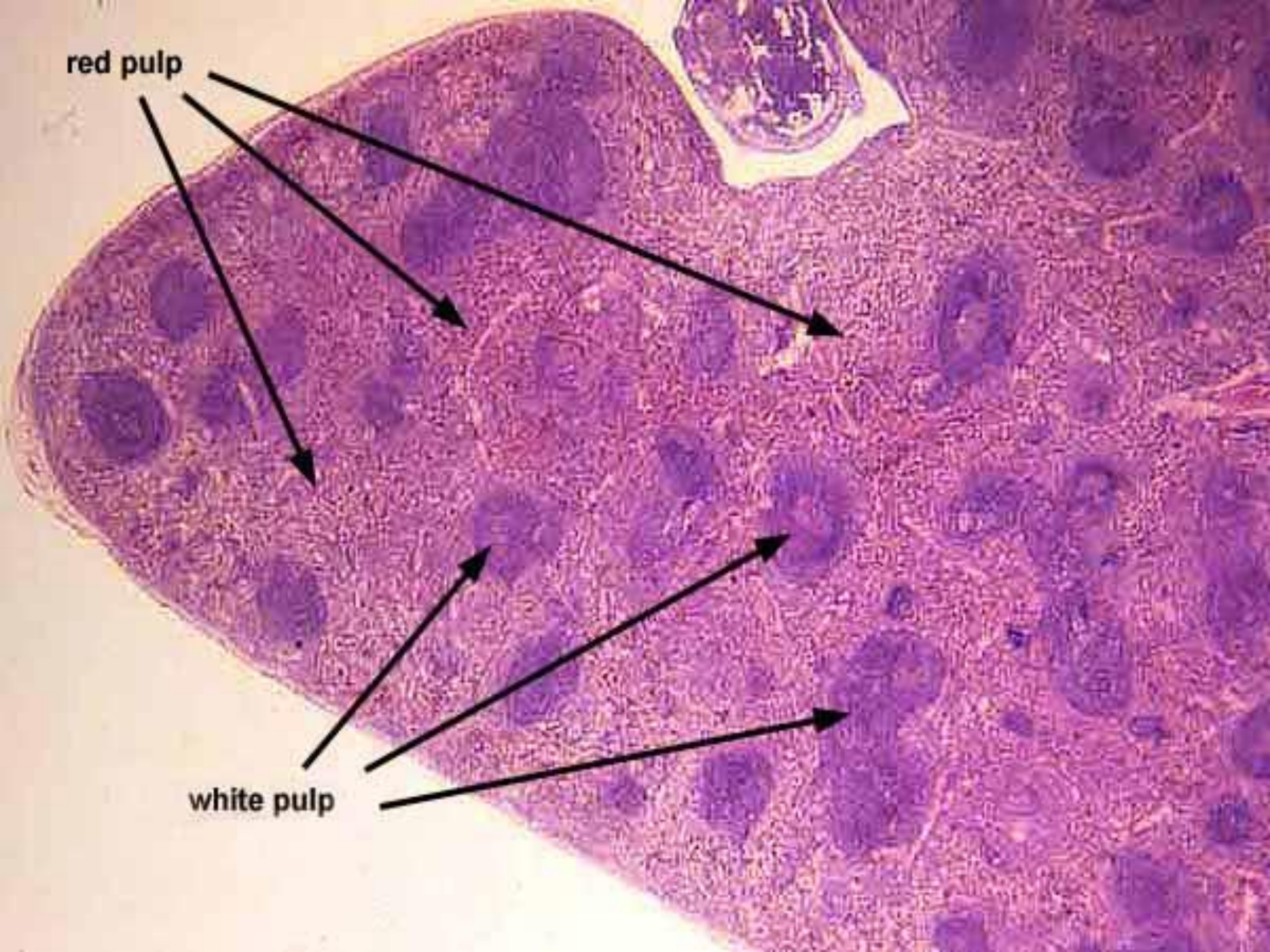
red pulp
white pulp

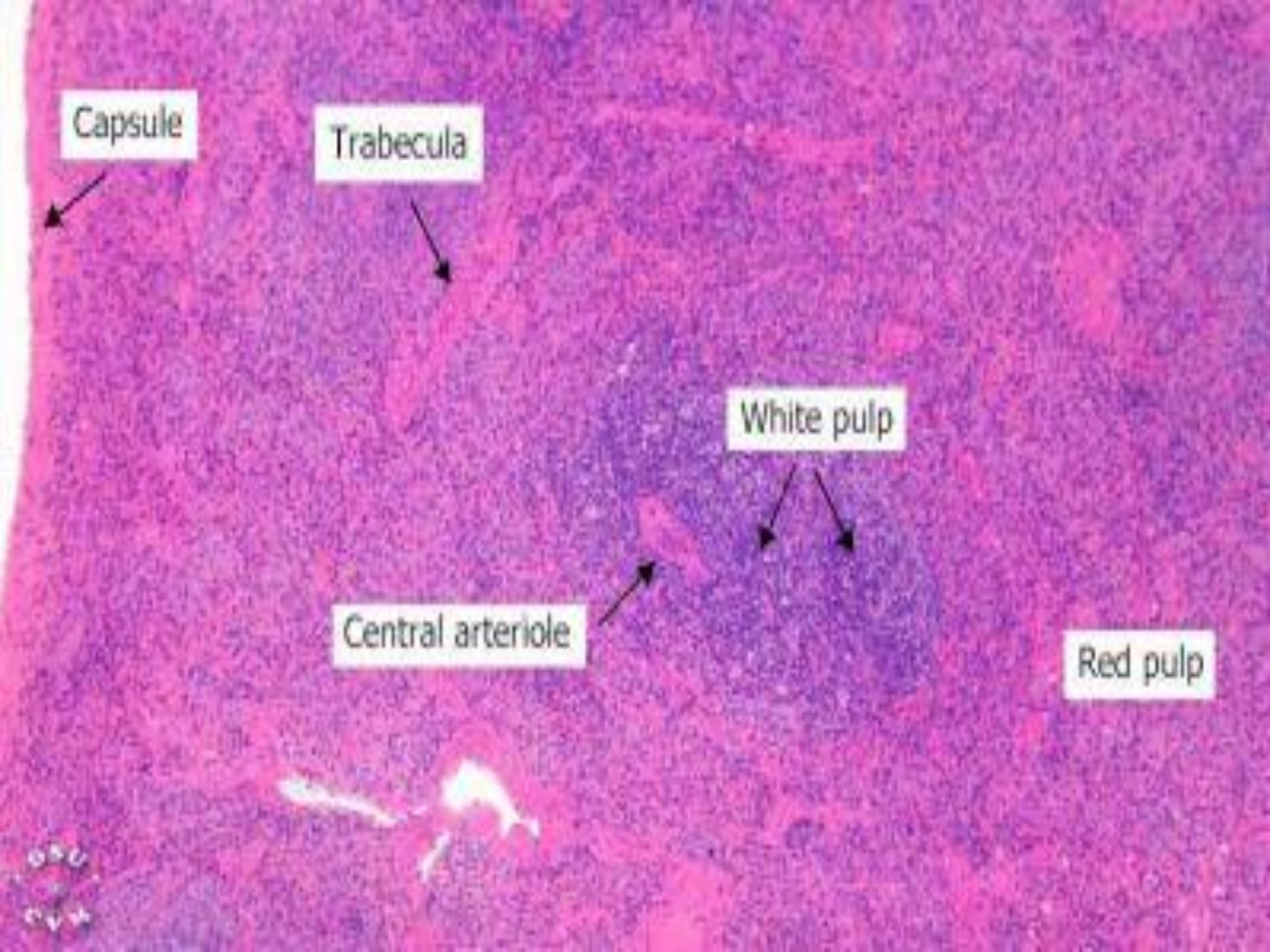
Capsule
Trabecula
White pulp
Central arteriole
Red pulp

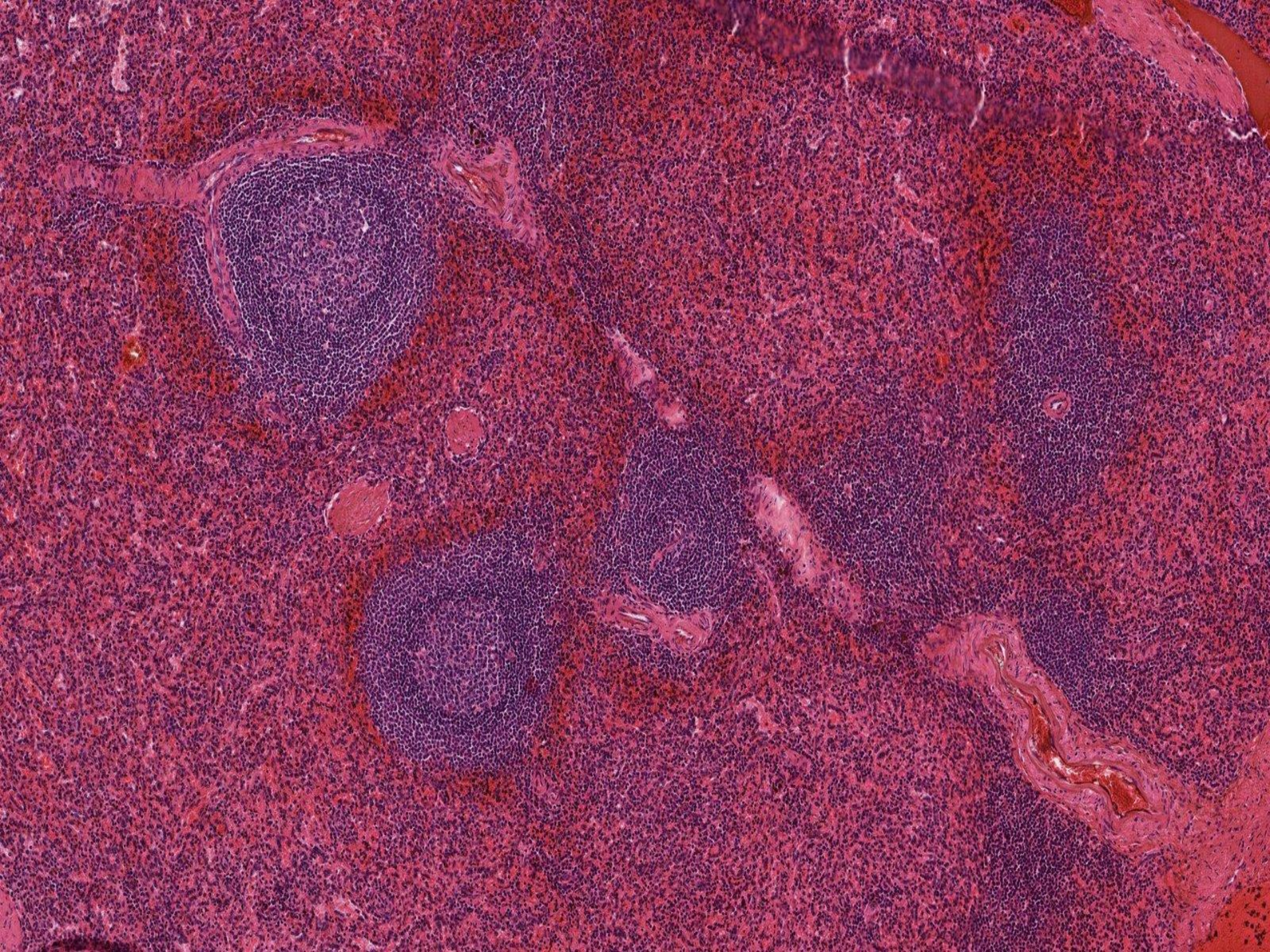

THANK YOU