Anatomy of male reproductive system

Dr. Khalil Mazen Abu Nada

Male reproductive system

- The male reproductive system consists of a number of sex organs that play a role in the process of human reproduction and make up a man's reproductive and urinary system.
- These organs are located on the outside of the body and within the pelvis
- The male reproductive system contains the external genitals (the penis, and the scrotum) and internal parts (testis, vas deferens, epididymis and accessory glands).

Organs of male reproductive system

- External organs:

  Scrotum

  Penis

- Internal organs:

  Testis

  Epididymis

  Vas deferens

  Accessory glands (prostate gland, seminal vesicles, and bulbourethral glands)

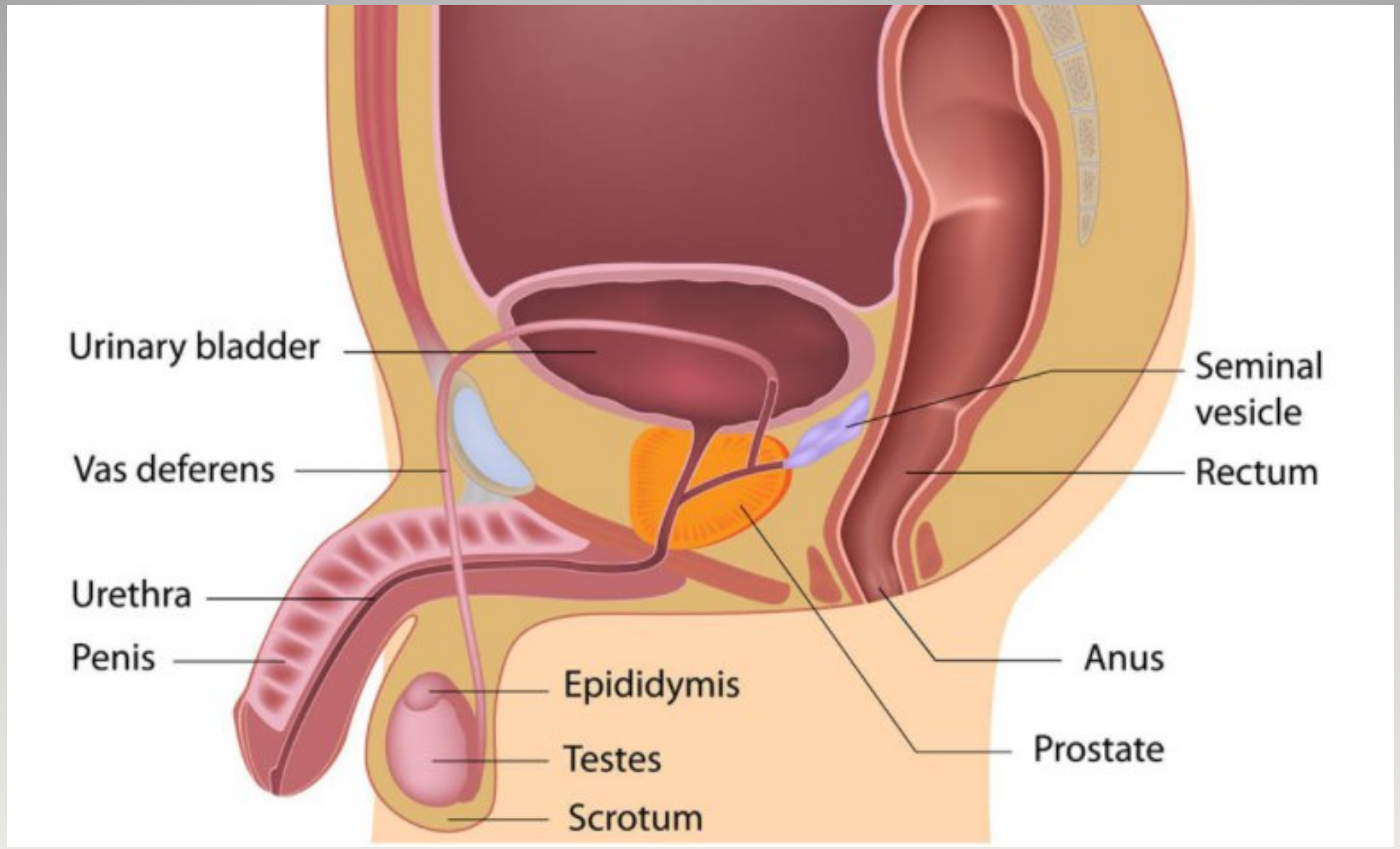
Urinary bladder
Vas deferens
Urethra
Penis
Epididymis
Testes
Scrotum
Seminal vesicle
Rectum
Anus
Prostate

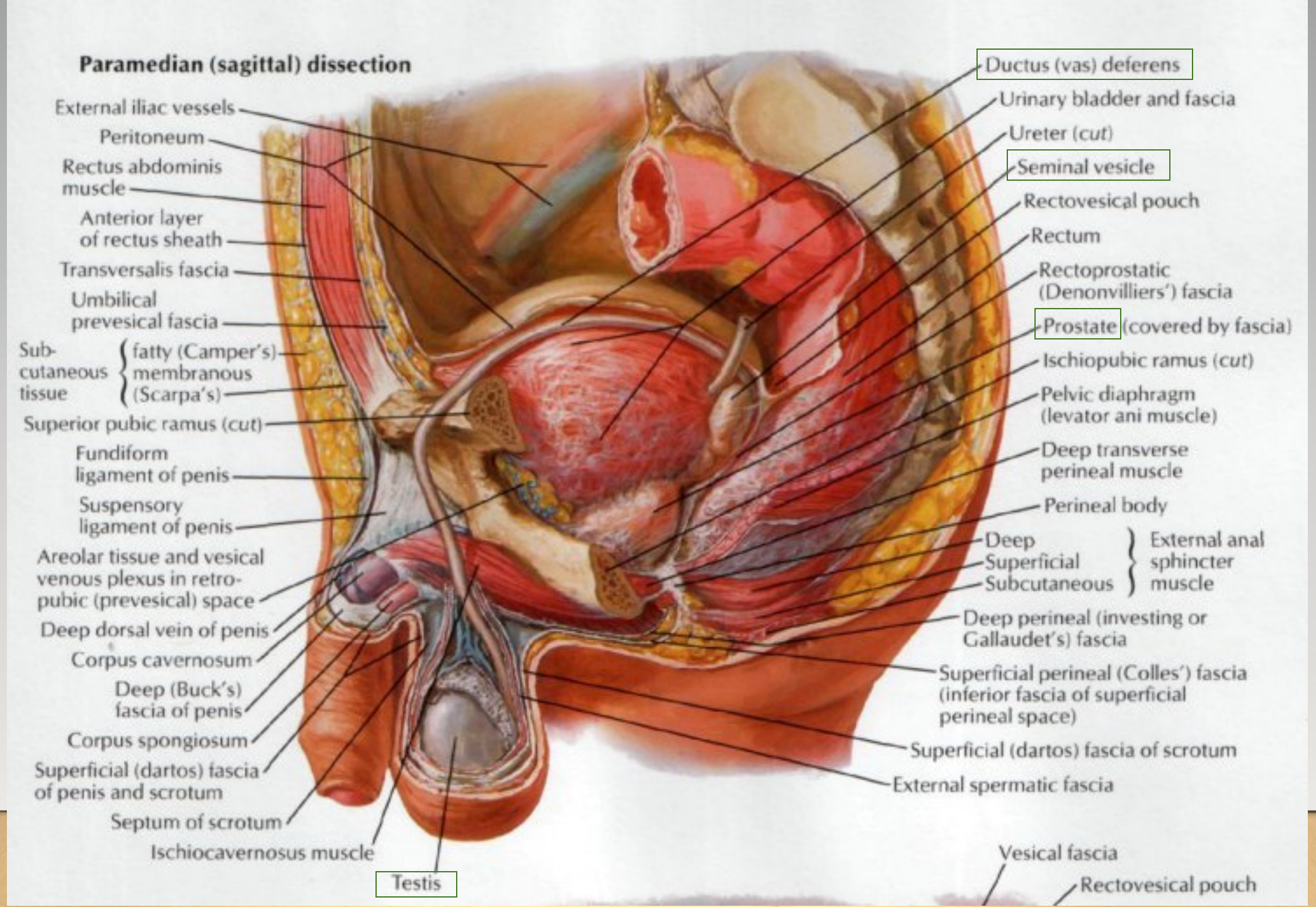
Paramedian (sagittal) dissection
External iliac vessels
Peritoneum
Rectus abdominis muscle
Anterior layer of rectus sheath
Transversalis fascia
Umbilical prevesical fascia
Sub-cutaneous tissue
fatty (Camper's)
membranous (Scarpa's)
Superior pubic ramus (cut)
Fundiform ligament of penis
Suspensory ligament of penis
Areolar tissue and vesical venous plexus in retro-pubic (prevesical) space
Deep dorsal vein of penis
Corpus cavernosum
Deep (Buck's) fascia of penis
Corpus spongiosum
Superficial (dartos) fascia of penis and scrotum
Septum of scrotum
Ischiocavernosus muscle
Testis
Ductus (vas) deferens
Urinary bladder and fascia
Ureter (cut)
Seminal vesicle
Rectovesical pouch
Rectum
Rectoprostatic (Denonvilliers') fascia
Prostate (covered by fascia)
Ischiopubic ramus (cut)
Pelvic diaphragm (levator ani muscle)
Deep transverse perineal muscle
Perineal body
Deep
Superficial
Subcutaneous
External anal sphincter muscle
Deep perineal (investing or Gallaudet's) fascia
Superficial perineal (Colles') fascia (inferior fascia of superficial perineal space)
Superficial (dartos) fascia of scrotum
External spermatic fascia
Vesical fascia
Rectovesical pouch

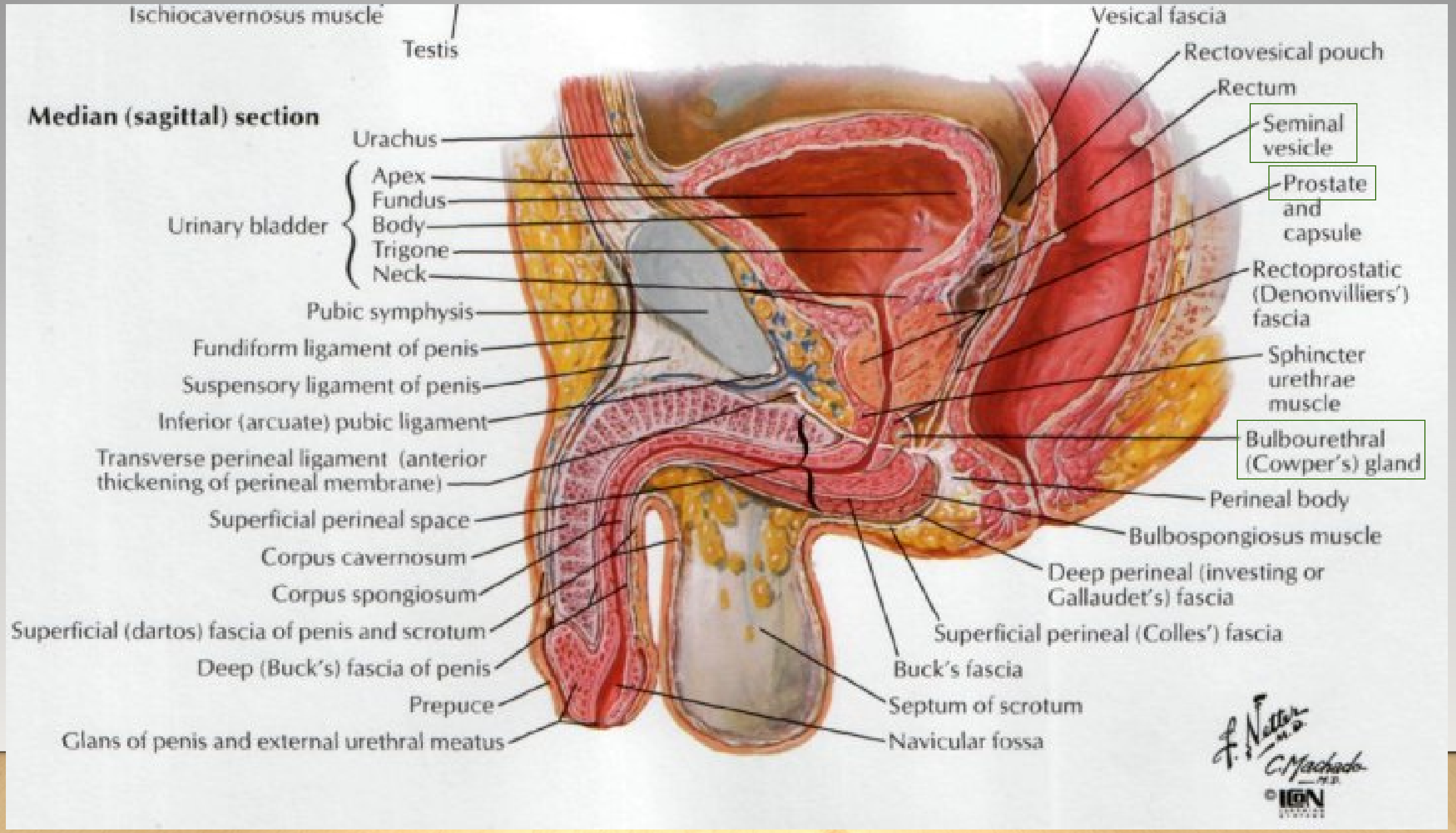
Ischiocavernosus muscle
Testis
Median (sagittal) section
Urachus
Urinary bladder
Apex
Fundus
Body
Trigone
Neck
Pubic symphysis
Fundiform ligament of penis
Suspensory ligament of penis
Inferior (arcuate) pubic ligament
Transverse perineal ligament (anterior thickening of perineal membrane)
Superficial perineal space
Corpus cavernosum
Corpus spongiosum
Superficial (dartos) fascia of penis and scrotum
Deep (Buck's) fascia of penis
Prepuce
Glans of penis and external urethral meatus
Vesical fascia
Rectovesical pouch
Rectum
Seminal vesicle
Prostate and capsule
Rectoprostatic (Denonvilliers') fascia
Sphincter urethrae muscle
Bulbourethral (Cowper's) gland
Perineal body
Bulbospongiosus muscle
Deep perineal (investing or Gallaudet's) fascia
Superficial perineal (Colles') fascia
Buck's fascia
Septum of scrotum
Navicular fossa
F. Netter M.D.
C. Machado M.D.
©IBN

Scrotum

- The scrotum is an outpouching of the lower part of the anterior abdominal wall. It contains the testes, the epididymides, and the lower ends of the spermatic cords.
- The wall of the scrotum has the following layers:

  Skin

  Superficial fascia

  Spermatic fasciae

  Tunica vaginalis

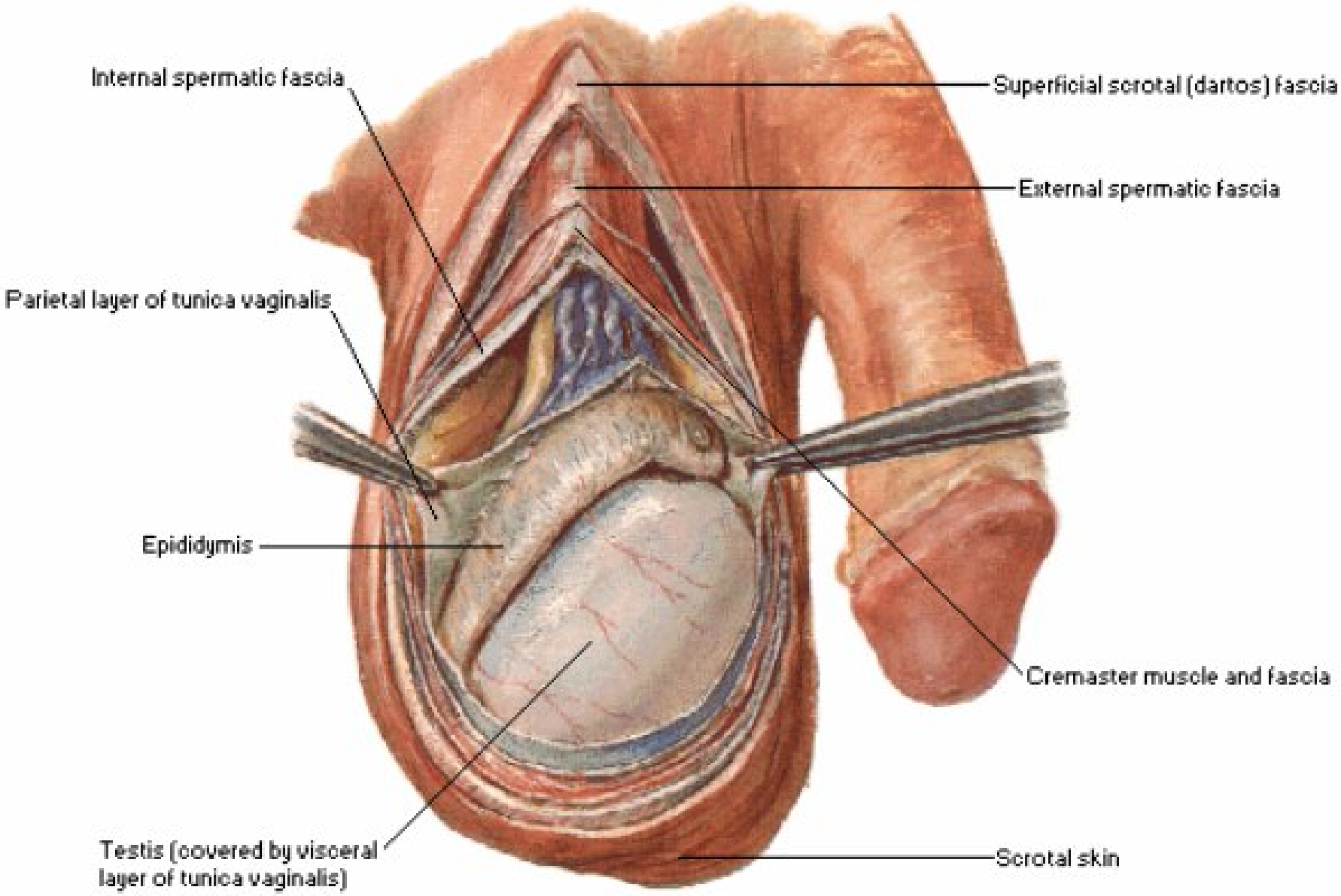
Internal spermatic fascia
Superficial scrotal (dartos) fascia
External spermatic fascia
Parietal layer of tunica vaginalis
Epididymis
Cremaster muscle and fascia
Testis (covered by visceral layer of tunica vaginalis)
Scrotal skin

Layers of the wall of the scrotum

- 1. skin:

The skin of the scrotum is thin, wrinkled, and pigmented and forms a single pouch. A slightly raised ridge in the midline indicates the line of fusion of the two lateral labioscrotal swellings

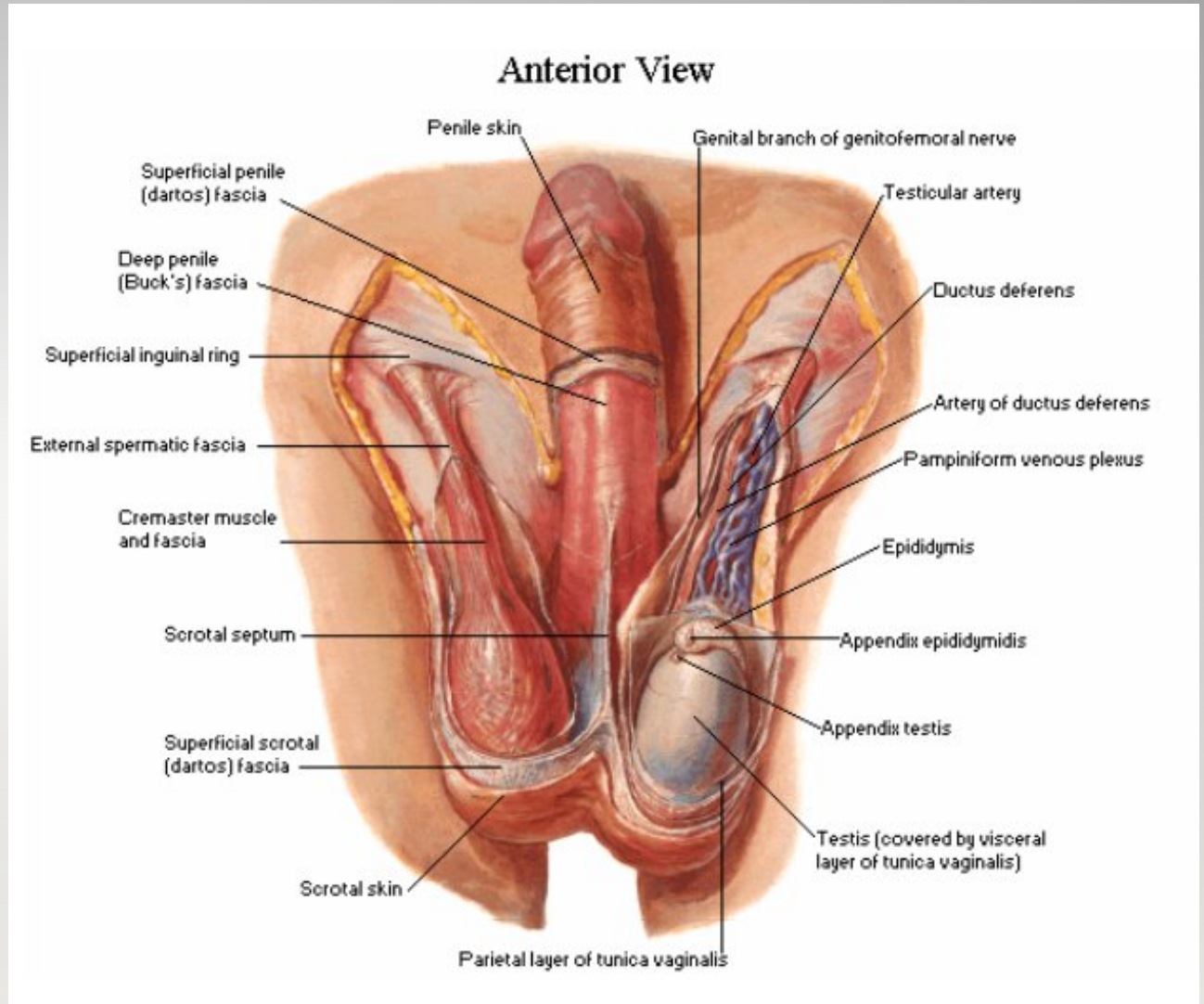

Layers of the wall of the scrotum

- 2. Superficial fascia:

This is continuous with the fatty and membranous layers of the anterior abdominal wall; the fat is, however, replaced by smooth muscle called the dartos muscle. This is innervated by sympathetic nerve fibers and is responsible for the wrinkling of the overlying skin.

Layers of the wall of the scrotum

- 3. Spermatic fasciae: three layers lie beneath the superficial fascia and are derived from the three layers of the anterior abdominal wall on each side.

  The external spermatic fascia is derived from the aponeurosis of the external oblique muscle

  The cremasteric fascia is derived from the internal oblique muscle

  The internal spermatic fascia is derived from the fascia transversalis.

The cremaster muscle is supplied by the genital branch of the genitofemoral nerve.

The cremaster muscle can be made to contract by stroking the skin on the medial aspect of the thigh. This is called the cremasteric reflex.

The afferent fibers of this reflex arc travel in the femoral branch of the genitofemoral nerve (L1 and 2), and the efferent motor nerve fibers travel in the genital branch the genitofemoral nerve.

The function of the cremaster muscle is to raise the testis and the scrotum upward for warmth and for protection against injury.

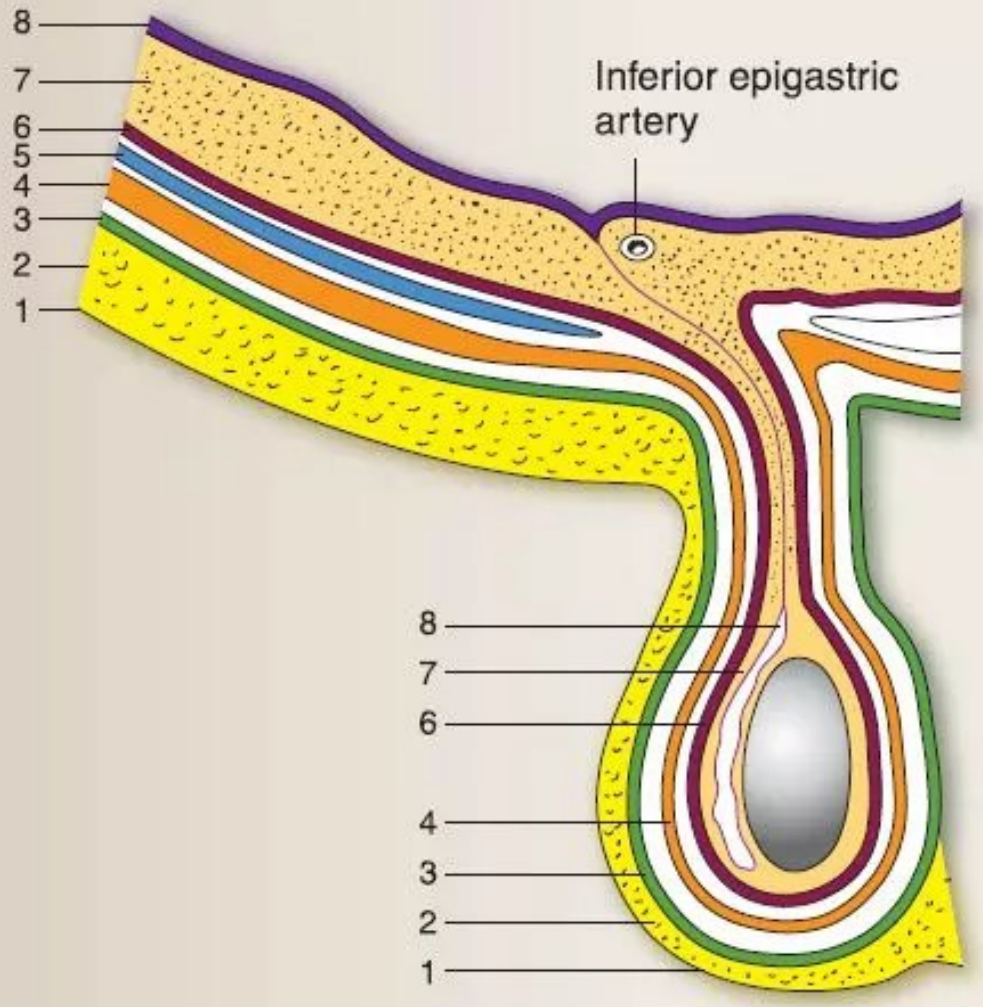

Layers of Abdominal Wall		Coverings of Testes and Spermatic Cord
1. Skin	→	Skin
2. Superficial fascia (Camper and Scarpa)	→	Colles fascia and dartos muscle
		Scrotum
Superficial perineal space (extravasated urine)		
3. External oblique muscle	→	External spermatic fascia
4. Internal oblique muscle	→	Cremasteric fascia and muscle
5. Transverse abdominus muscle		Does not continue into scrotal area
6. Transversalis fascia	→	Internal spermatic fascia
7. Extraperitoneal fat	→	Extraperitoneal fat
8. Parietal peritoneum	→	Tunica vaginalis

Cremasteric reflex pulls the testis superiorly in the scrotum and is mediated by the genitofemoral nerve. This reflex is more apparent in young males.

Layers of the wall of the scrotum

- 4. Tunica vaginalis:

This lies within the spermatic fasciae and covers the anterior, medial, and lateral surfaces of each testis. It is the lower expanded part of the processus vaginalis; normally, just before birth, it becomes shut off from the upper part of the processus and the peritoneal cavity. The tunica vaginalis is thus a closed sac, invaginated from behind by the testis.

Tunica vaginalis consist of 2 layers: parietal and visceral

Processus vaginalis

- The processus vaginalis is a blind-ended evagination of the abdominal wall that develops during fetal life and typically undergoes obliteration in early life. Persistence of the processus vaginalis leads to communication between the peritoneum and scrotum and it is associated with a number of pathologies including congenital indirect inguinal hernias, communicating hydroceles, funicular and encysted hydroceles, and acquired undescended testis.

Figure

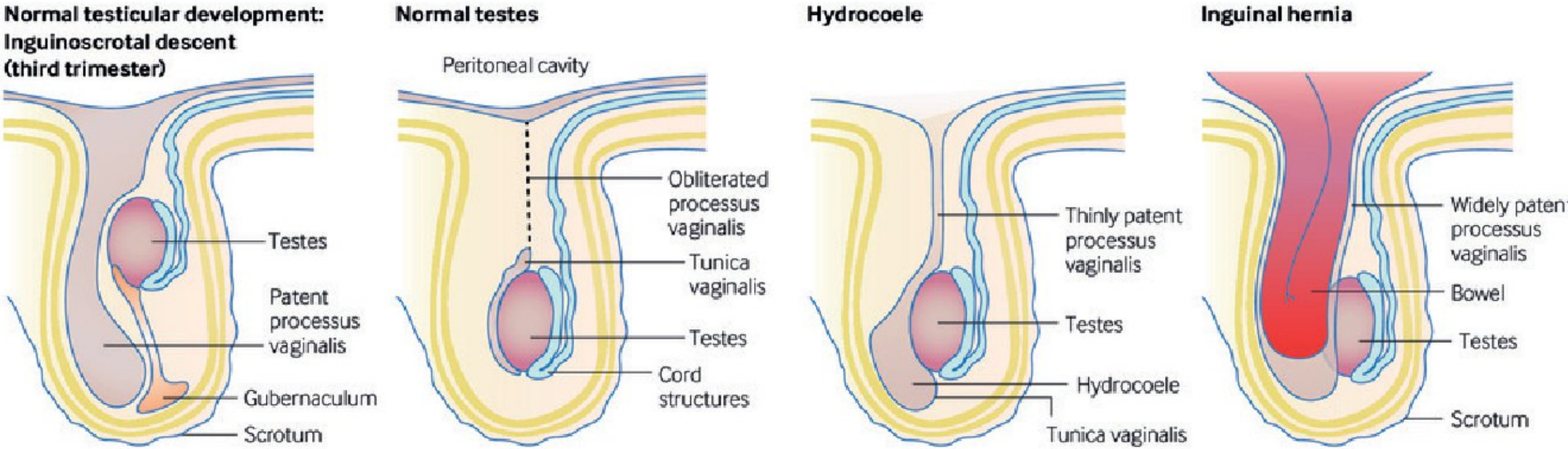

Fig 1 Paediatric inguinal hernia

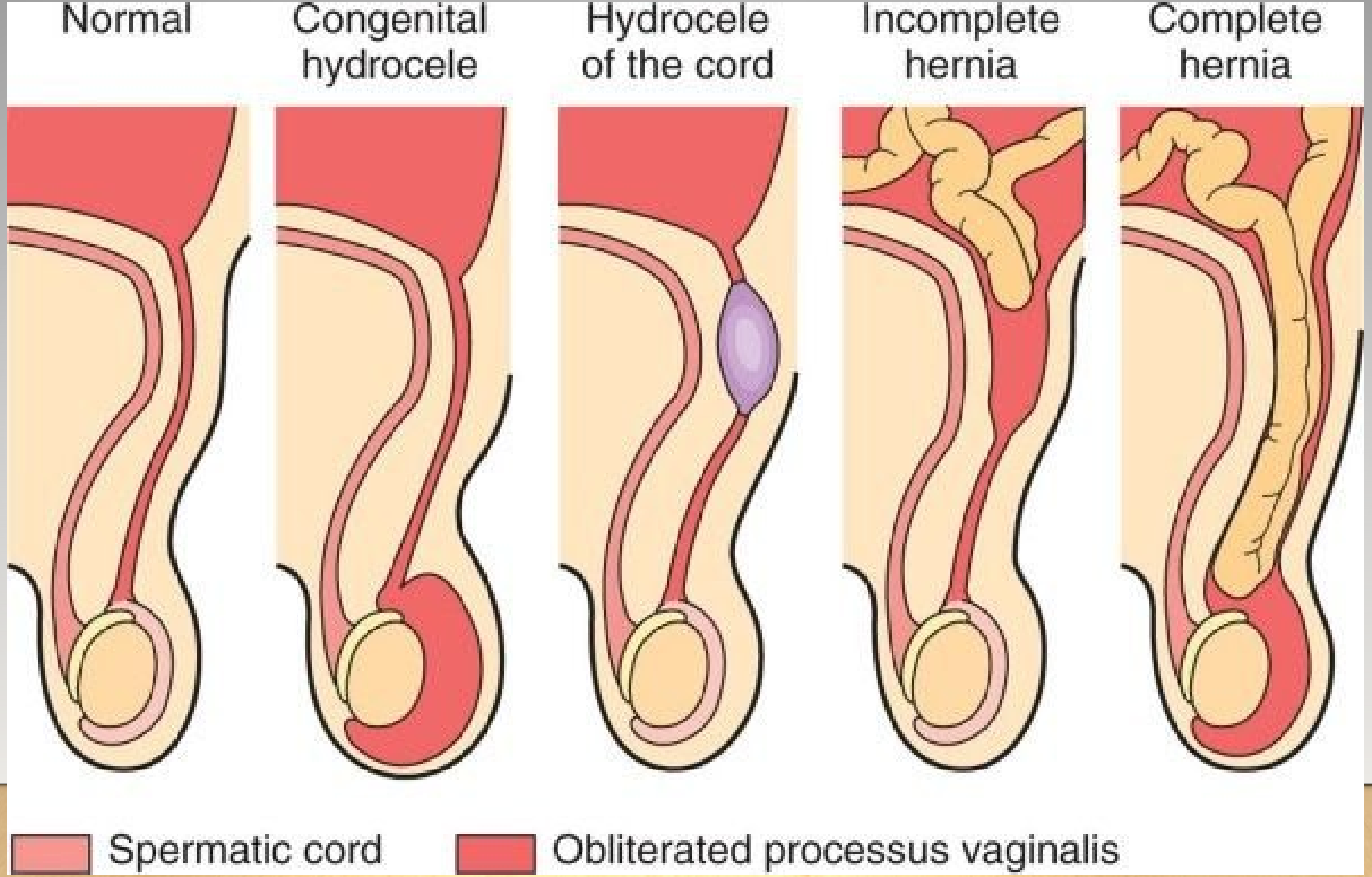
Normal
Congenital hydrocele
Hydrocele of the cord
Incomplete hernia
Complete hernia
Spermatic cord
Obliterated processus vaginalis

Penis

- The penis consists of a root, a body, and a glans
- The root of the penis consists of three masses of erectile tissue called the bulb of the penis and the right and left crura of the penis.
- The bulb is covered on its outer surface by the bulbospongiosus muscles.
- Each crus is covered on its outer surface by the ischiocavernosus muscle.
- The bulb is continued forward into the body of the penis and forms the corpus spongiosum.
- The two crura converge anteriorly and come to lie side by side in the dorsal part of the body of the penis, forming the corpora cavernosa

Penis

- The body of the penis is the free portion of the penis, which is suspended from the symphysis pubis.
- The body of the penis is composed of three cylinders of erectile tissue enclosed in a tubular sheath of fascia (Buck’s fascia)
- The glans penis forms the extremity of the body of the penis.
- the corpus spongiosum expands to form the glans penis, which covers the distal ends of the corpora cavernosa. On the tip of the glans penis is the slitlike orifice of the urethra, called the external urethral meatus.
- The corpora cavernosa are supplied by the deep arteries of the penis, the corpus spongiosum is supplied by the artery of the bulb. In addition, there is the dorsal artery of the penis. All the above arteries are branches of the internal pudendal artery which is a branch of internal iliac artery

bulbospongiosus muscles

ischiocavernosus muscle

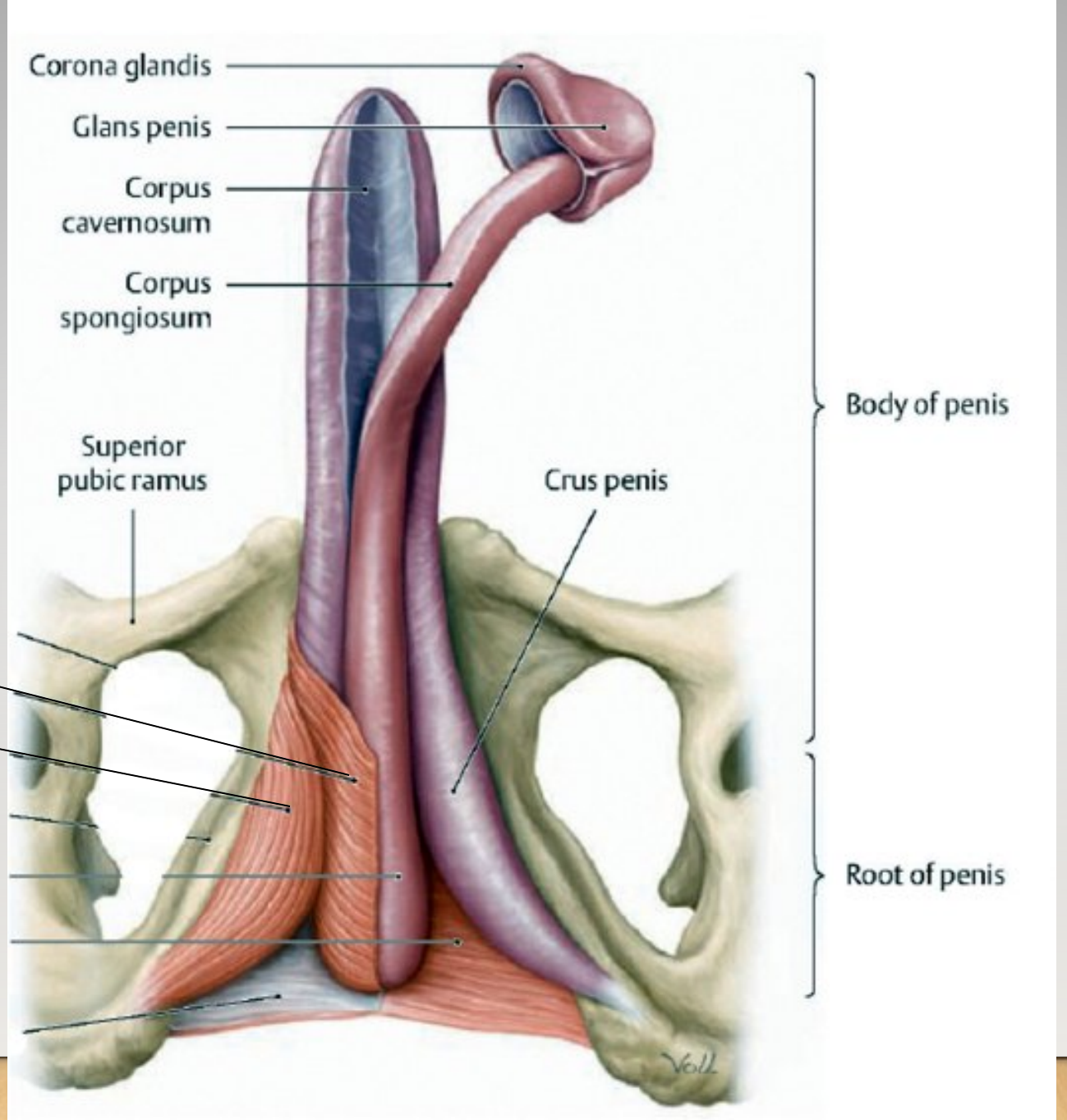

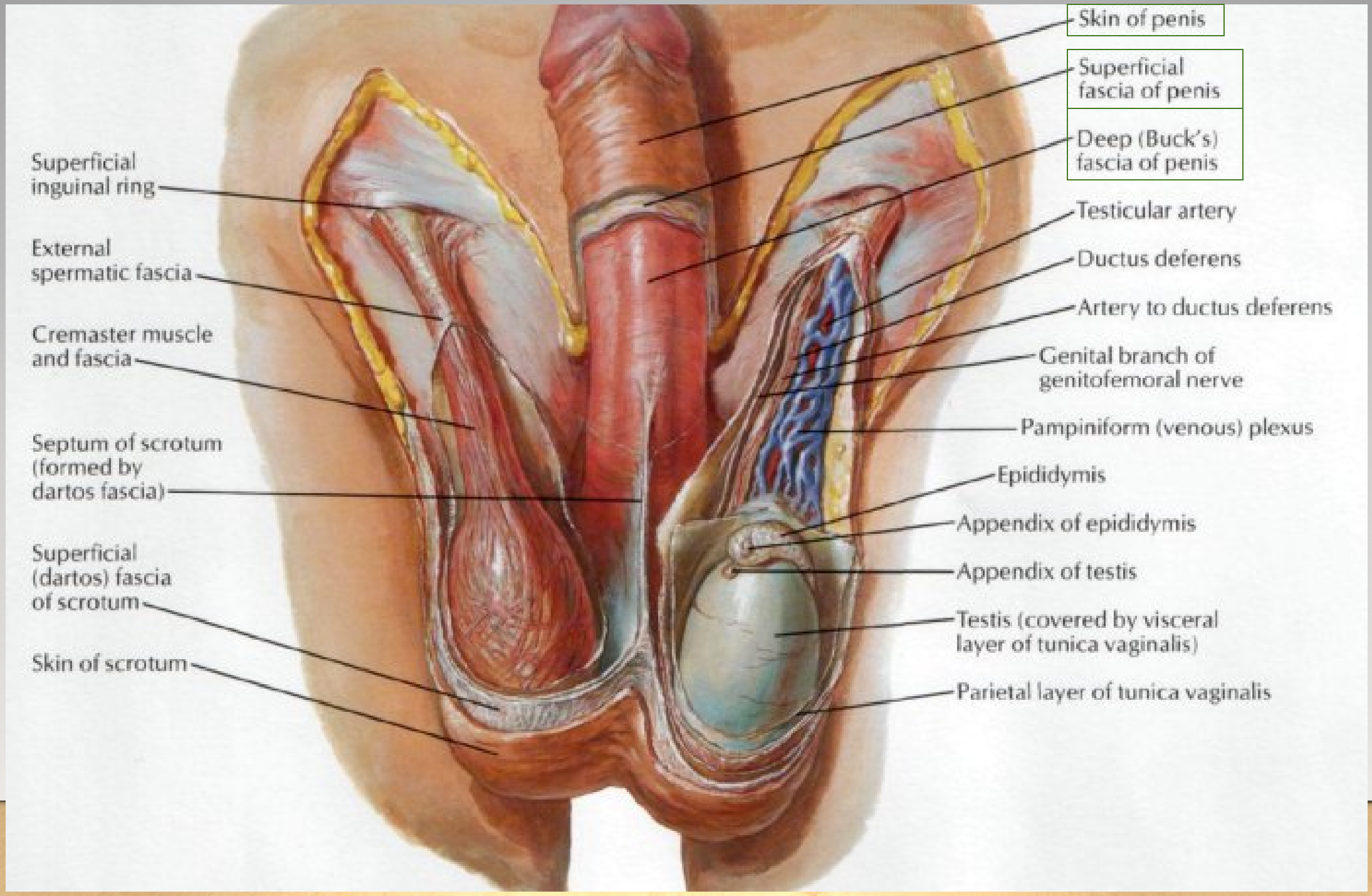
Skin of penis
Superficial fascia of penis
Deep (Buck's) fascia of penis
Testicular artery
Ductus deferens
Artery to ductus deferens
Genital branch of genitofemoral nerve
Pampiniform (venous) plexus
Epididymis
Appendix of epididymis
Appendix of testis
Testis (covered by visceral layer of tunica vaginalis)
Parietal layer of tunica vaginalis
Superficial inguinal ring
External spermatic fascia
Cremaster muscle and fascia
Septum of scrotum (formed by dartos fascia)
Superficial (dartos) fascia of scrotum
Skin of scrotum

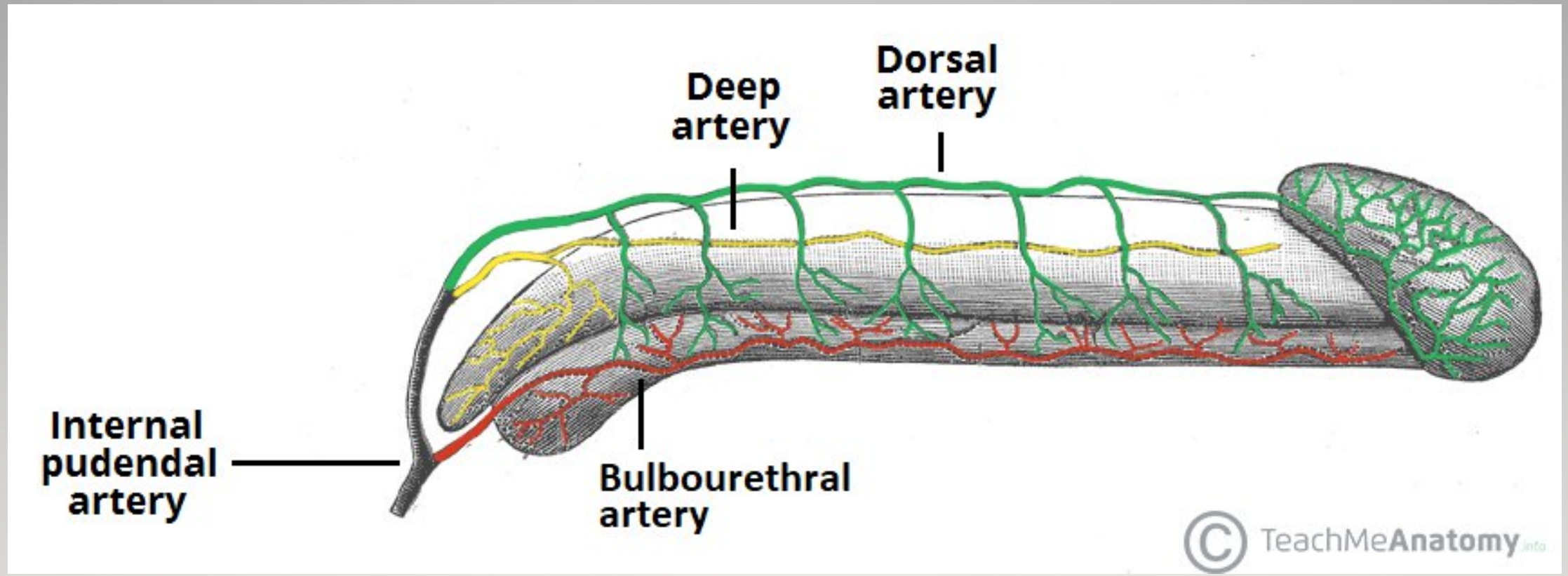
Deep artery
Dorsal artery
Internal pudendal artery
Bulbourethral artery
© TeachMeAnatomy.info

Testis

- The testis is a firm, mobile organ lying within the scrotum.
- The left testis usually lies at a lower level than the right.
- Each testis is surrounded by a tough fibrous capsule, the tunica albuginea.
- Extending from the inner surface of the capsule is a series of fibrous septa that divide the interior of the organ into lobules. Lying within each lobule are one to three coiled seminiferous tubules. The tubules open into a network of channels called the rete testis. Small efferent ductules connect the rete testis to the upper end of the epididymis

Testis

- Normal spermatogenesis can occur only if the testes are at a temperature lower than that of the abdominal cavity. When they are located in the scrotum, they are at a temperature about 3°C lower than the abdominal temperature.
- The control of testicular temperature in the scrotum is not fully understood, but the surface area of the scrotal skin can be changed reflexly by the contraction of the dartos and cremaster muscles. It is now recognized that the testicular veins in the spermatic cord that form the pampiniform plexus—together with the branches of the testicular arteries, which lie close to the veins—probably assist in stabilizing the temperature of the testes by a countercurrent heat exchange mechanism. By this means, the hot blood arriving in the artery from the abdomen loses heat to the blood ascending to the abdomen within the veins.

Cross Section

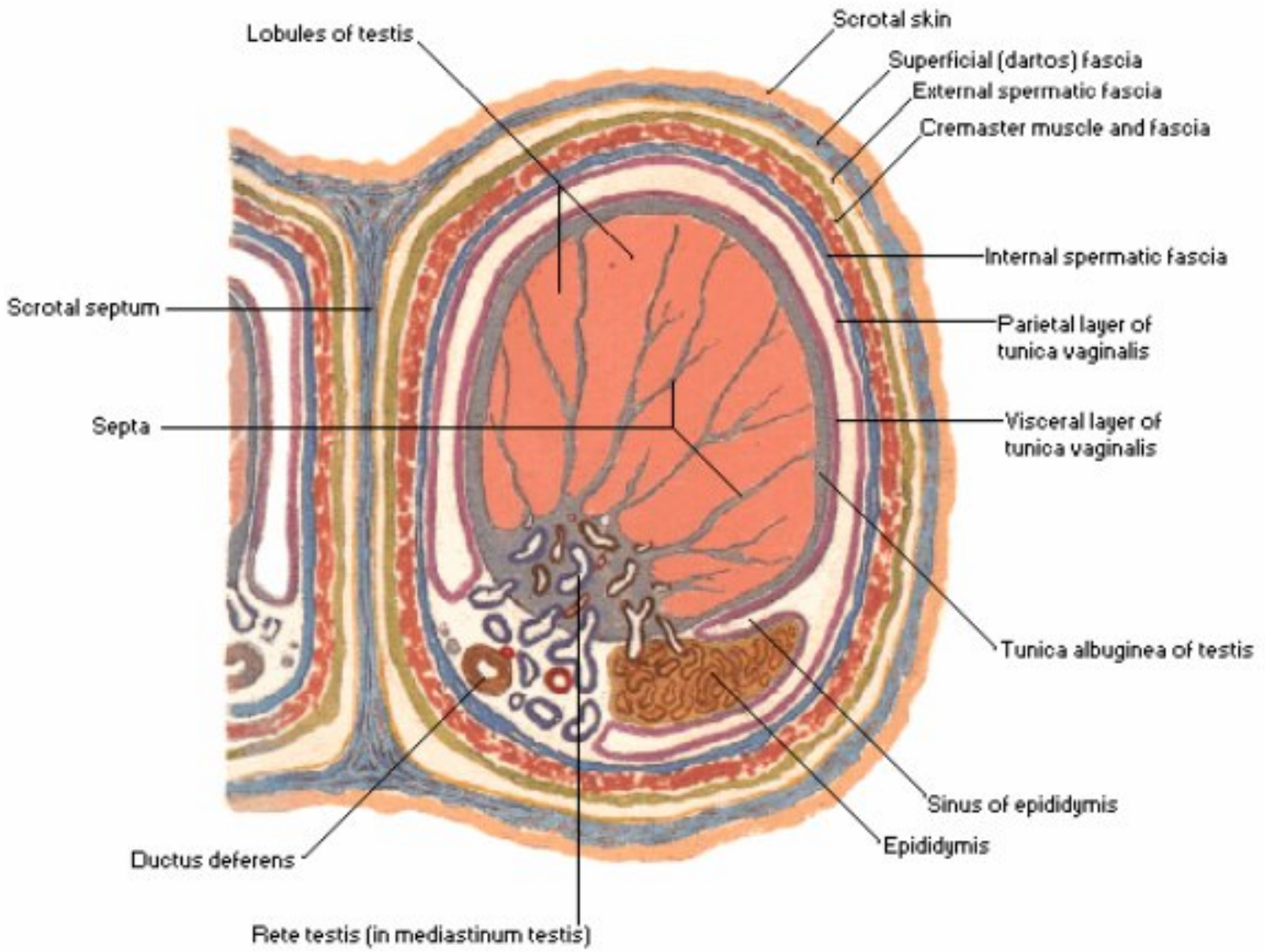

Schema

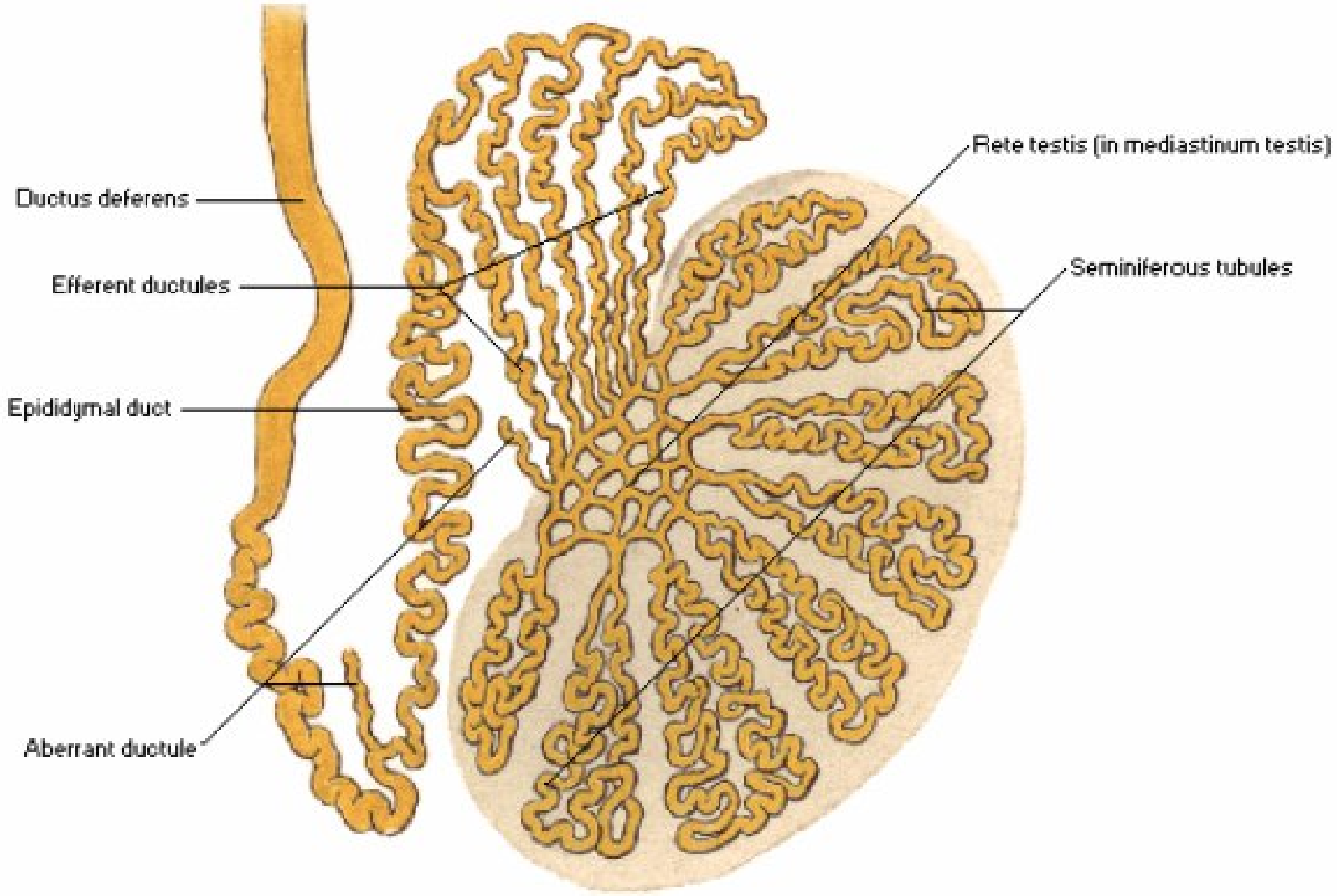
Ductus deferens
Efferent ductules
Epididymal duct
Aberrant ductule
Rete testis (in mediastinum testis)
Seminiferous tubules

Epididymis

- The epididymis is a firm structure lying posterior to the testis, with the vas deferens lying on its medial side. It has an expanded upper end, the head, a body, and a pointed tail inferiorly
- The epididymis is a much coiled tube nearly 6 m long, embedded in connective tissue. The tube emerges from the tail of the epididymis as the vas deferens, which enters the spermatic cord. The length of the duct of the epididymis provides storage space for the spermatozoa and allows them to mature.

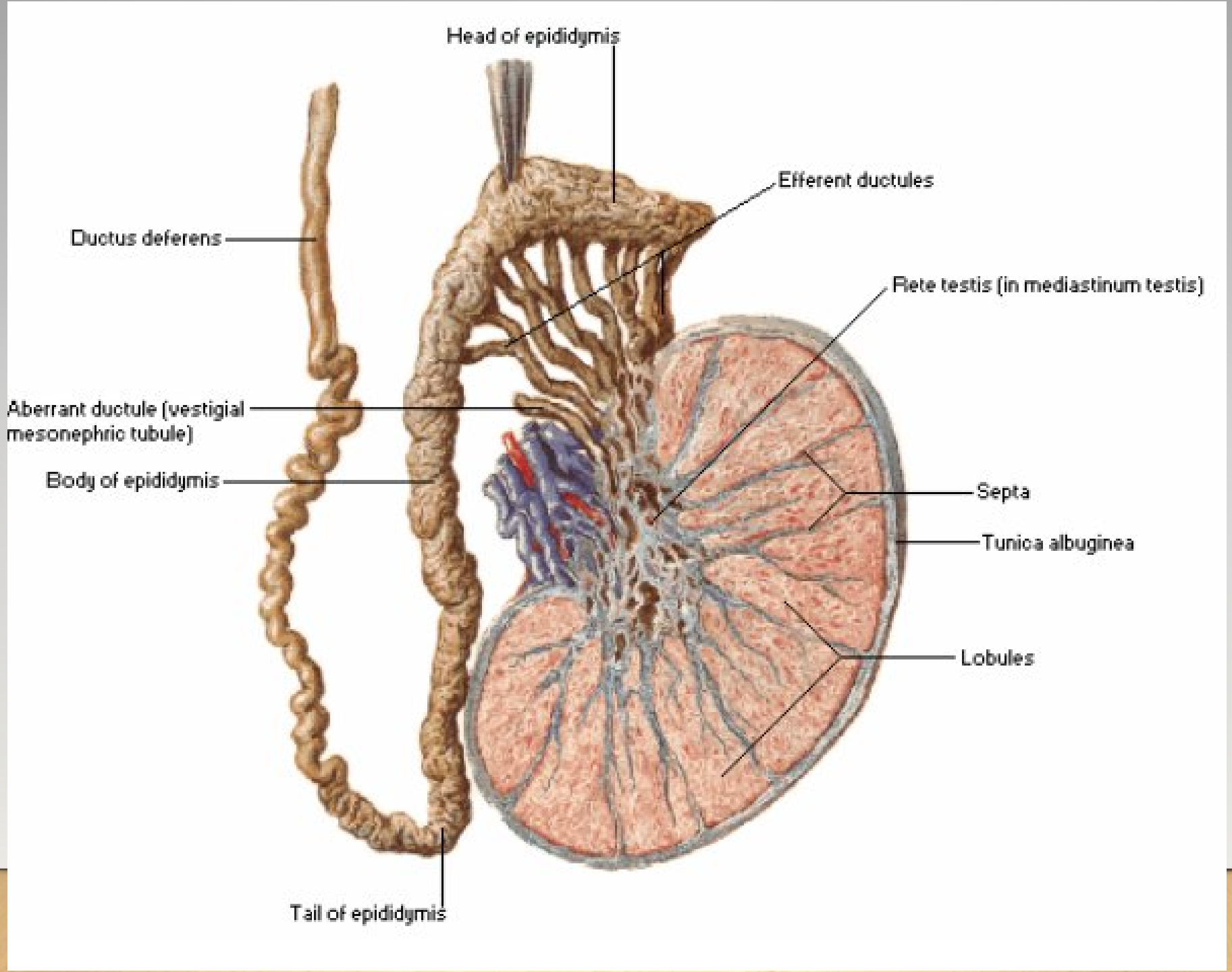
Head of epididymis
Efferent ductules
Ductus deferens
Rete testis (in mediastinum testis)
Aberrant ductule (vestigial mesonephric tubule)
Body of epididymis
Septa
Tunica albuginea
Lobules
Tail of epididymis

Blood Supply of the Testis and Epididymis

- The testicular artery is a branch of the abdominal aorta. The testicular veins emerge from the testis and the epididymis as a venous network, the pampiniform plexus. This becomes reduced to a single vein as it ascends through the inguinal canal. The right testicular vein drains into the inferior vena cava, and the left vein joins the left renal vein.
- Lymph Drainage of the Testis and Epididymis: lumbar or para-aortic lymph nodes at the level of the 1st lumbar vertebra.
- Lymph Drainage of the Scrotum Lymph from the skin and fascia, including the tunica vaginalis, drains into the superficial inguinal lymph nodes

Vas deferens

- The vas deferens is a thick-walled tube about 45 cm long that conveys mature sperm from the epididymis to the ejaculatory duct and the urethra.
- It arises from the lower end or tail of the epididymis and passes through the inguinal canal.
- It emerges from the deep inguinal ring and passes around the lateral margin of the inferior epigastric artery
- It then passes downward and backward on the lateral wall of the pelvis and crosses the ureter in the region of the ischial spine.
- The vas deferens then runs medially and downward on the posterior surface of the bladder.
- The terminal part of the vas deferens is dilated to form the ampulla of the vas deferens.
- The inferior end of the ampulla narrows down and joins the duct of the seminal vesicle to form the ejaculatory duct.

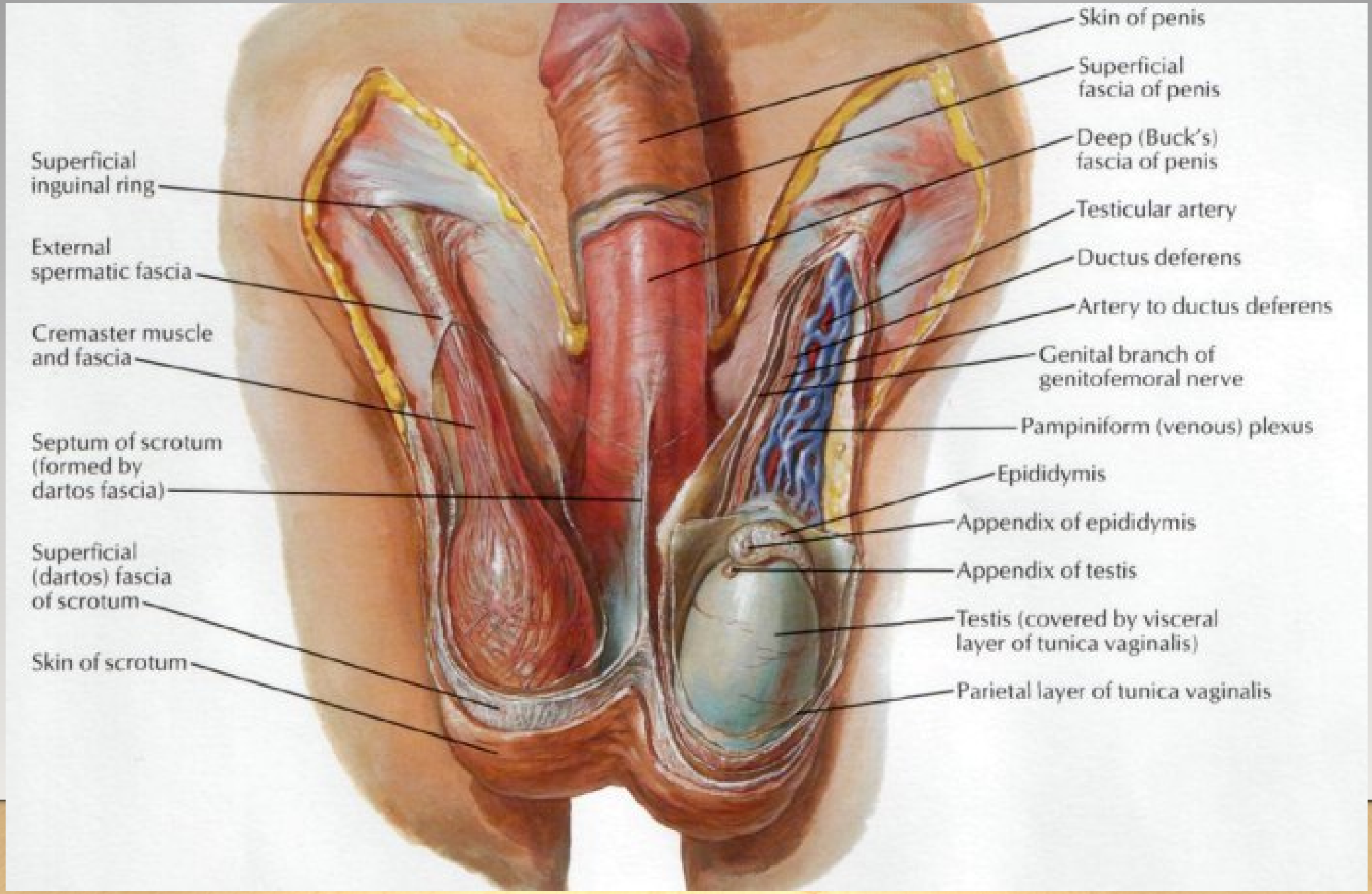
Skin of penis
Superficial fascia of penis
Deep (Buck's) fascia of penis
Testicular artery
Ductus deferens
Artery to ductus deferens
Genital branch of genitofemoral nerve
Pampiniform (venous) plexus
Epididymis
Appendix of epididymis
Appendix of testis
Testis (covered by visceral layer of tunica vaginalis)
Parietal layer of tunica vaginalis
Superficial inguinal ring
External spermatic fascia
Cremaster muscle and fascia
Septum of scrotum (formed by dartos fascia)
Superficial (dartos) fascia of scrotum
Skin of scrotum

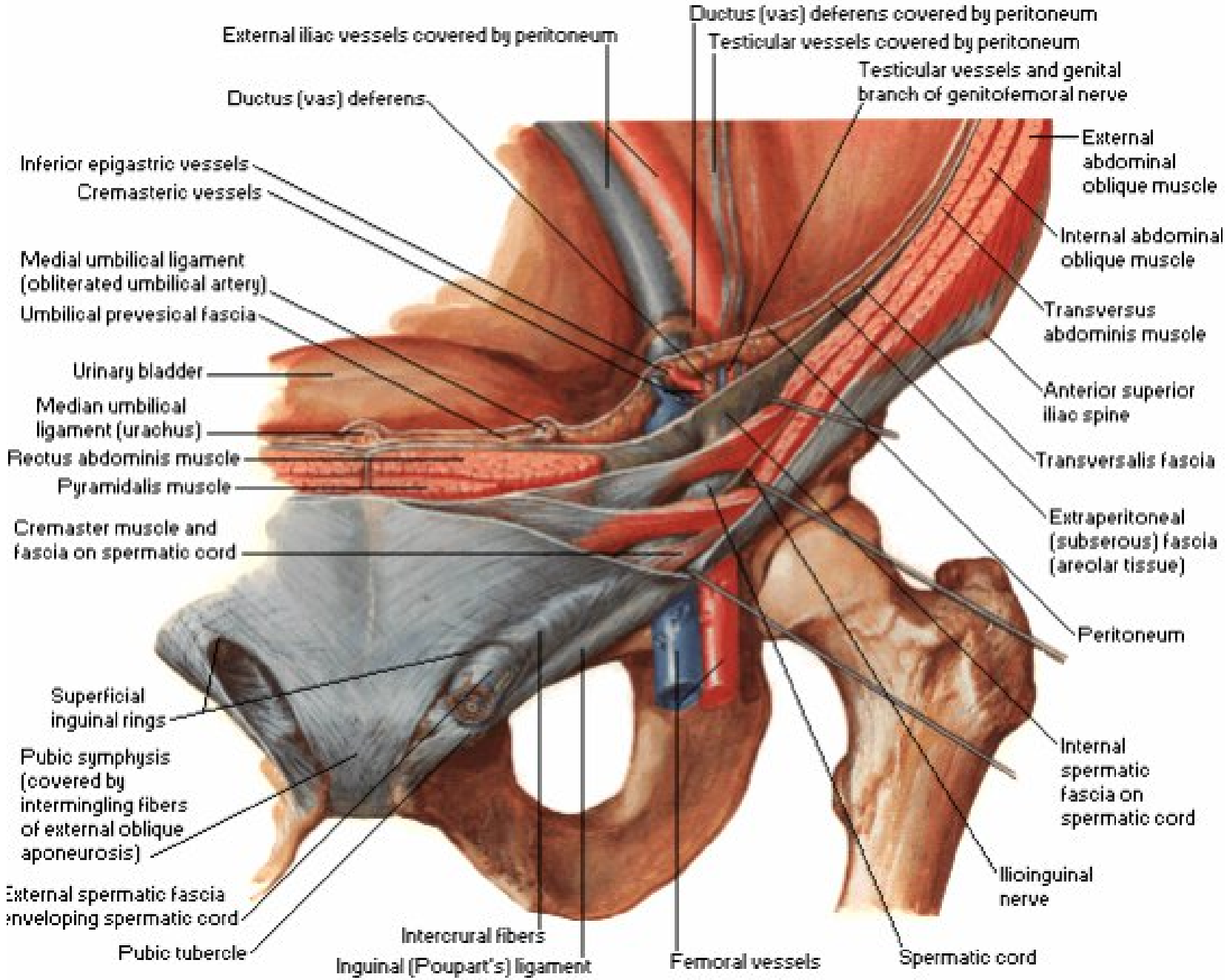
External iliac vessels covered by peritoneum
Ductus (vas) deferens covered by peritoneum
Testicular vessels covered by peritoneum
Testicular vessels and genital branch of genitofemoral nerve
Ductus (vas) deferens
Inferior epigastric vessels
Cremasteric vessels
External abdominal oblique muscle
Internal abdominal oblique muscle
Medial umbilical ligament (obliterated umbilical artery)
Umbilical prevesical fascia
Transversus abdominis muscle
Urinary bladder
Anterior superior iliac spine
Median umbilical ligament (urachus)
Rectus abdominis muscle
Transversalis fascia
Pyramidalis muscle
Extraperitoneal (subserous) fascia (areolar tissue)
Cremaster muscle and fascia on spermatic cord
Peritoneum
Superficial inguinal rings
Internal spermatic fascia on spermatic cord
Pubic symphysis (covered by intermingling fibers of external oblique aponeurosis)
Ilioinguinal nerve
External spermatic fascia enveloping spermatic cord
Intercrural fibers
Pubic tubercle
Inguinal (Poupart's) ligament
Femoral vessels
Spermatic cord

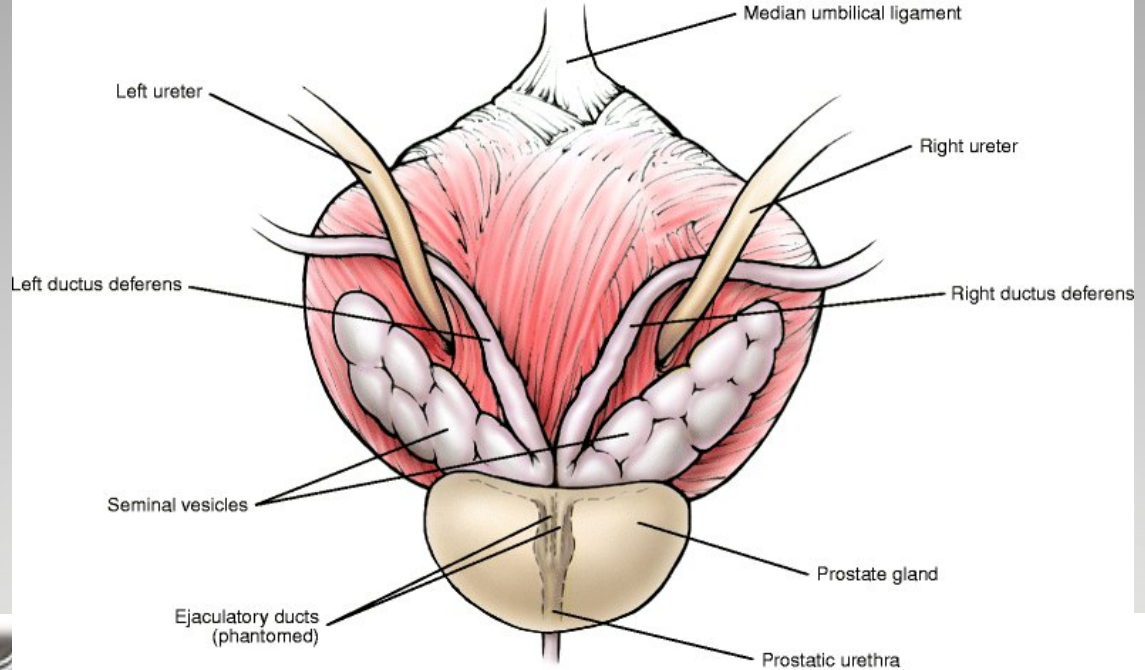
Median umbilical ligament
Left ureter
Right ureter
Left ductus deferens
Right ductus deferens
Seminal vesicles
Prostate gland
Ejaculatory ducts
(phantomed)
Prostatic urethra

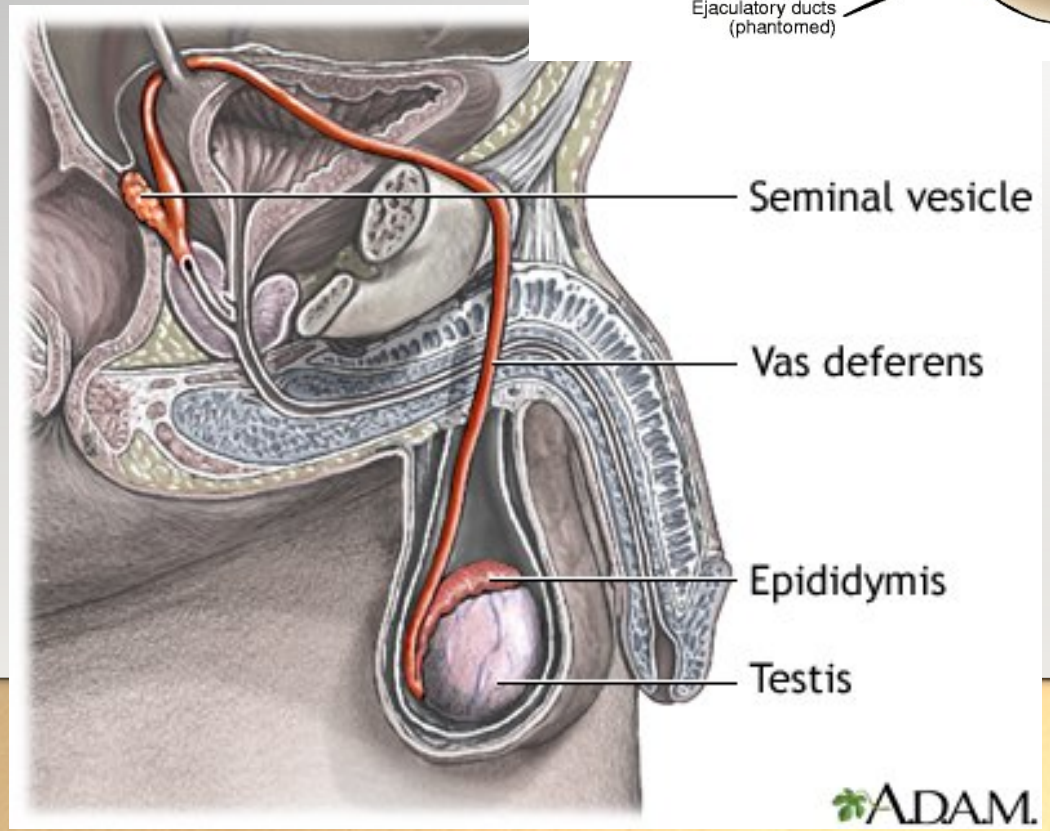
Seminal vesicle
Vas deferens
Epididymis
Testis
ADAM.

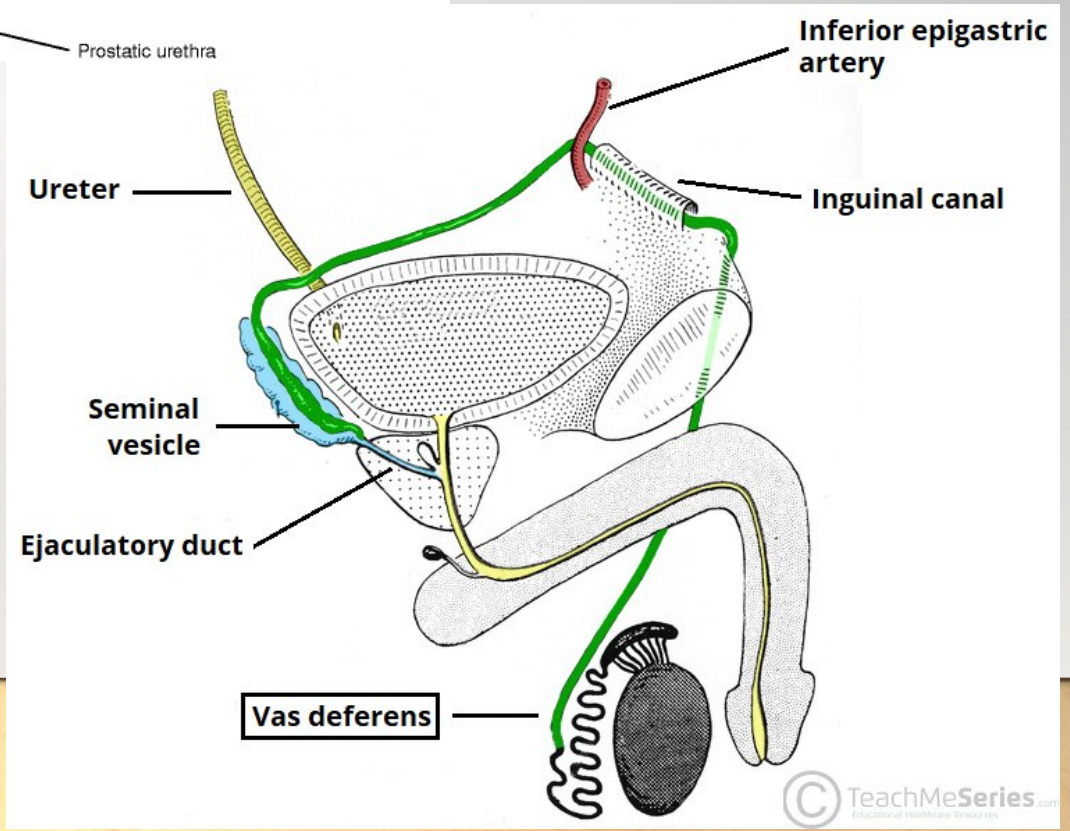
Inferior epigastric artery
Ureter
Inguinal canal
Seminal vesicle
Ejaculatory duct
Vas deferens
TeachMeSeries

Spermatic cord

- The spermatic cord is a collection of structures that pass through the inguinal canal to and from the testis.
- It begins at the deep inguinal ring lateral to the inferior epigastric artery and ends at the testis.

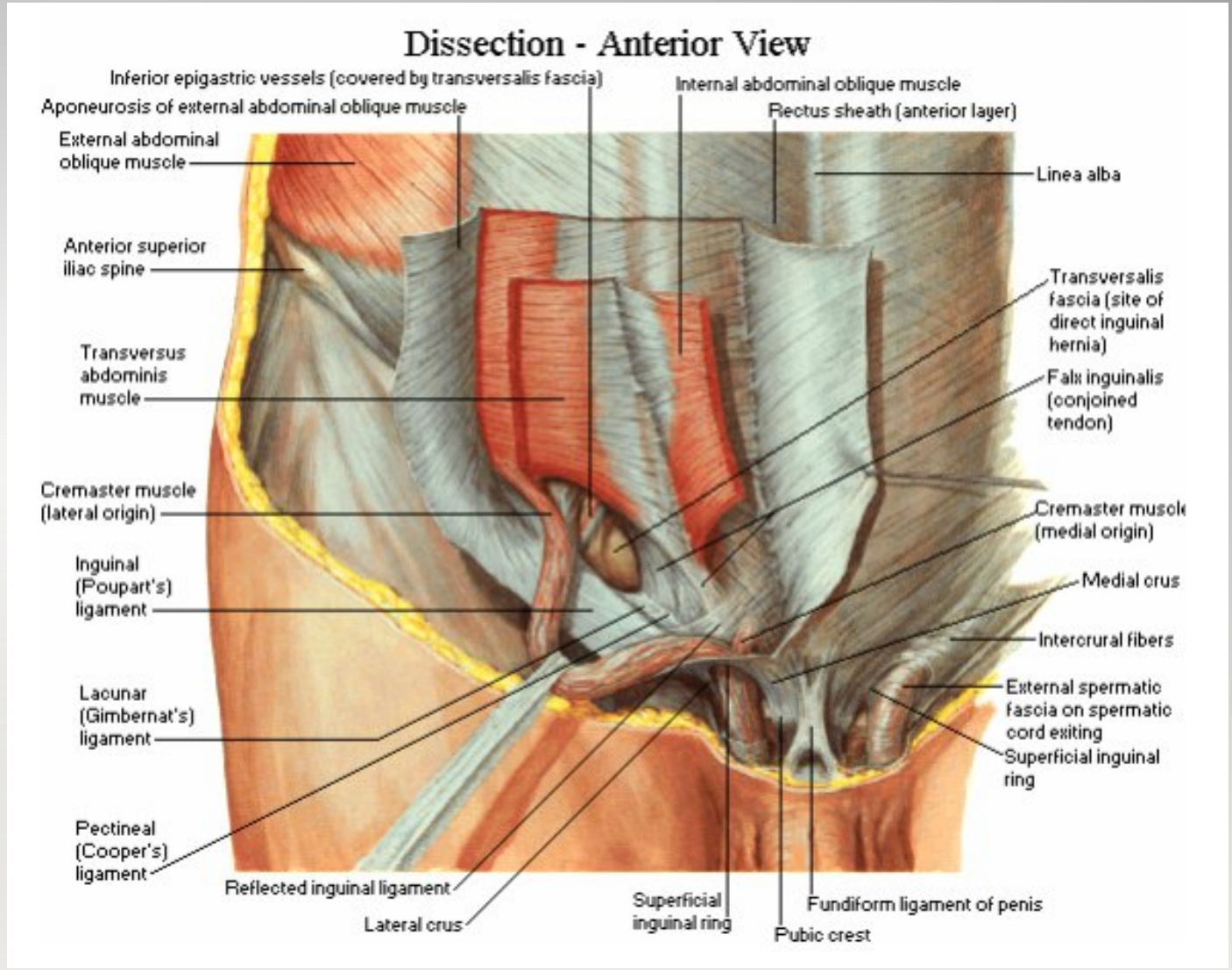

Spermatic cord

- It contains the following structures:

  Vas deferens

  Artery to the vas (branch of superior vesicle artery → umbilical artery → anterior branch of internal iliac artery), sometimes arise from inferior vesicle artery

  Testicular artery

  Testicular veins (pampiniform plexus)

  Testicular lymph vessels

  Testicular autonomic nerves

  Remains of the processus vaginalis

  Genital branch of the genitofemoral nerve, which supplies the cremaster muscle

Seminal vesicles

- The seminal vesicles are two lobulated organs about 5 cm long lying on the posterior surface of the bladder
- On the medial side of each vesicle lies the terminal part of the vas deferens.
- Posteriorly, the seminal vesicles are related to the rectum
- Inferiorly, each seminal vesicle narrows and joins the vas deferens of the same side to form the ejaculatory duct.
- It produce a secretion that is added to the seminal fluid. The secretions nourish the spermatozoa. During ejaculation, the seminal vesicles contract and expel their contents into the ejaculatory ducts, thus washing the spermatozoa out of the urethra.
- It is supplied by The inferior vesicle and middle rectal arteries.

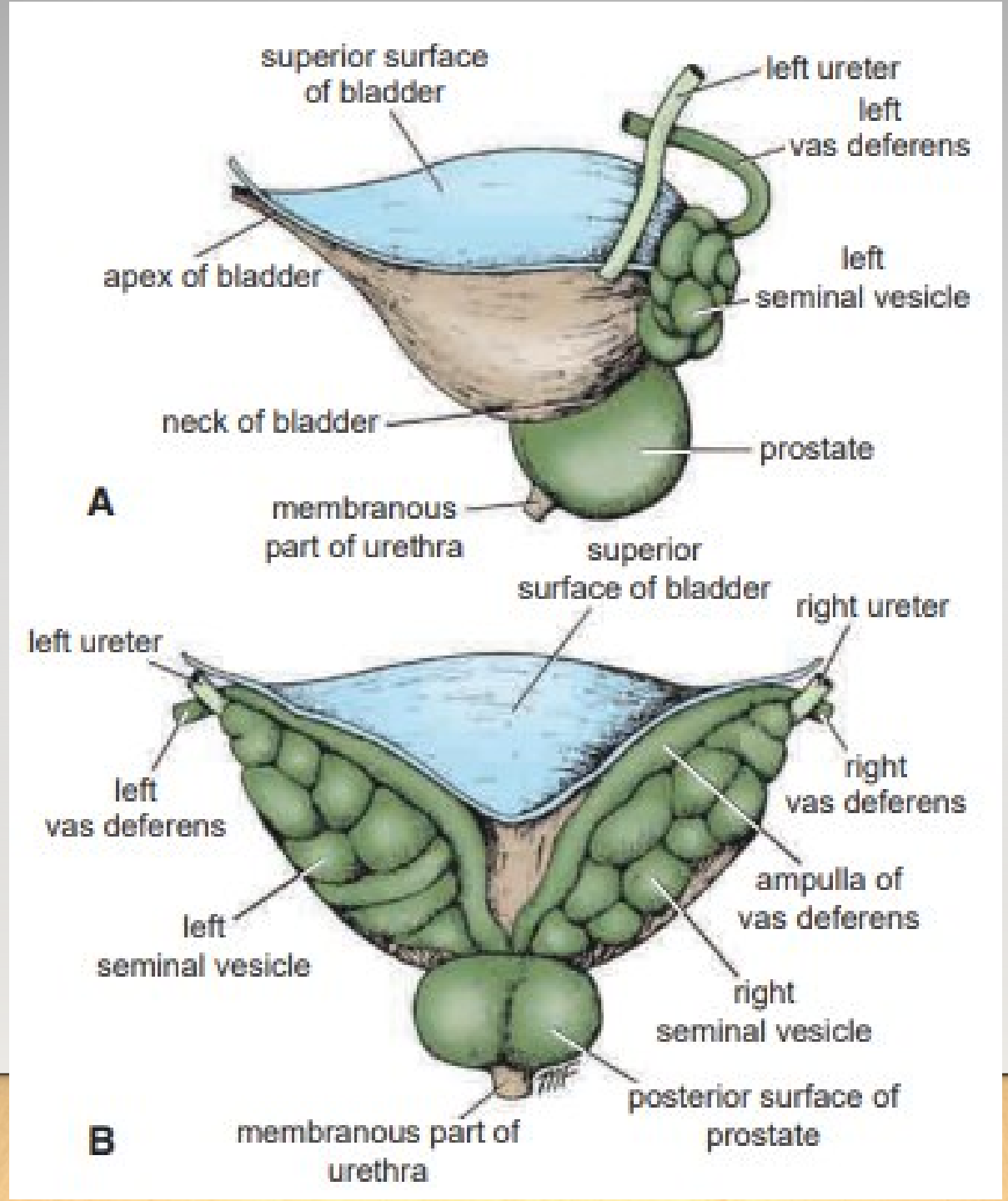
superior surface of bladder
left ureter
left vas deferens
apex of bladder
left seminal vesicle
neck of bladder
prostate
A
membranous part of urethra
superior surface of bladder
right ureter
left ureter
left vas deferens
right vas deferens
ampulla of vas deferens
left seminal vesicle
right seminal vesicle
posterior surface of prostate
membranous part of urethra
B

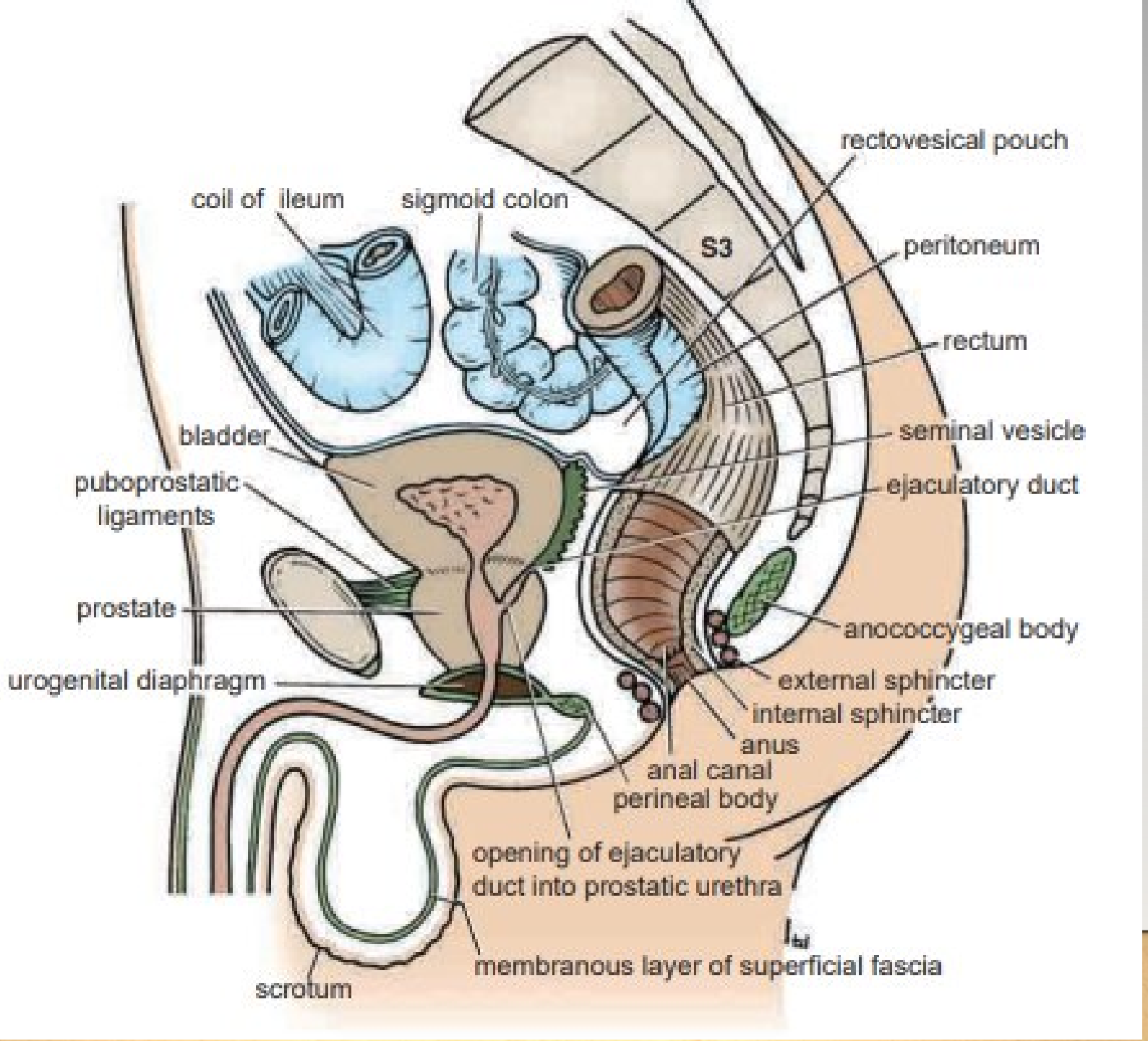
rectovesical pouch
coil of ileum
sigmoid colon
S3
peritoneum
rectum
bladder
seminal vesicle
puboprostatic ligaments
ejaculatory duct
prostate
anococcygeal body
urogenital diaphragm
external sphincter
internal sphincter
anus
anal canal
perineal body
opening of ejaculatory duct into prostatic urethra
membranous layer of superficial fascia
scrotum

Ejaculatory Ducts

- The two ejaculatory ducts are each < 2.5 cm long and are formed by the union of the vas deferens and the duct of the seminal vesicle
- The ejaculatory ducts pierce the posterior surface of the prostate and open into the prostatic part of the urethra
- Their function is to drain the seminal fluid into the prostatic urethra

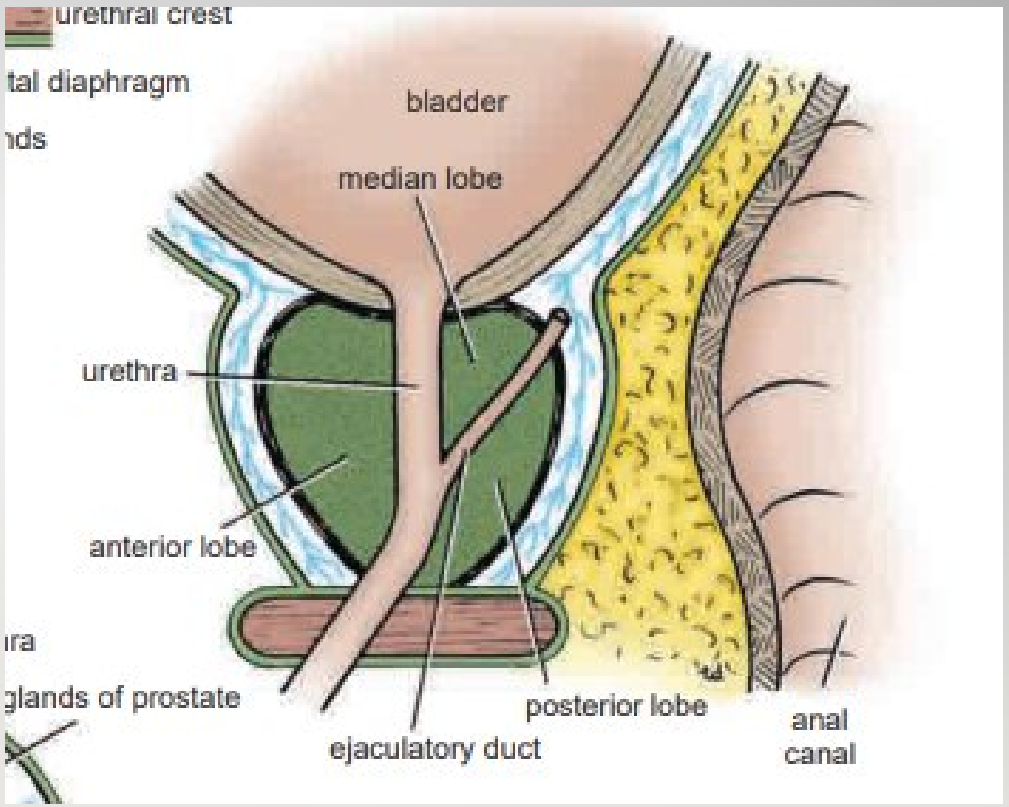

Prostate

- The prostate is a fibromuscular glandular organ that surrounds the prostatic urethra (male urethra consist of three parts: prostatic, membranous and penile urethra).
- The conical prostate has a base, which lies against the bladder neck above, and an apex, which lies against the urogenital diaphragm below. The two ejaculatory ducts pierce the upper part of the posterior surface of the prostate to open into the prostatic urethra
- The prostate produces a thin, milky fluid that is added to the seminal fluid at the time of ejaculation. The smooth muscle, which surrounds the glands, squeezes the secretion into the prostatic urethra. The prostatic secretion is alkaline and helps neutralize the acidity in the vagina.
- Its supplied by branches of the inferior vesical and middle rectal arteries

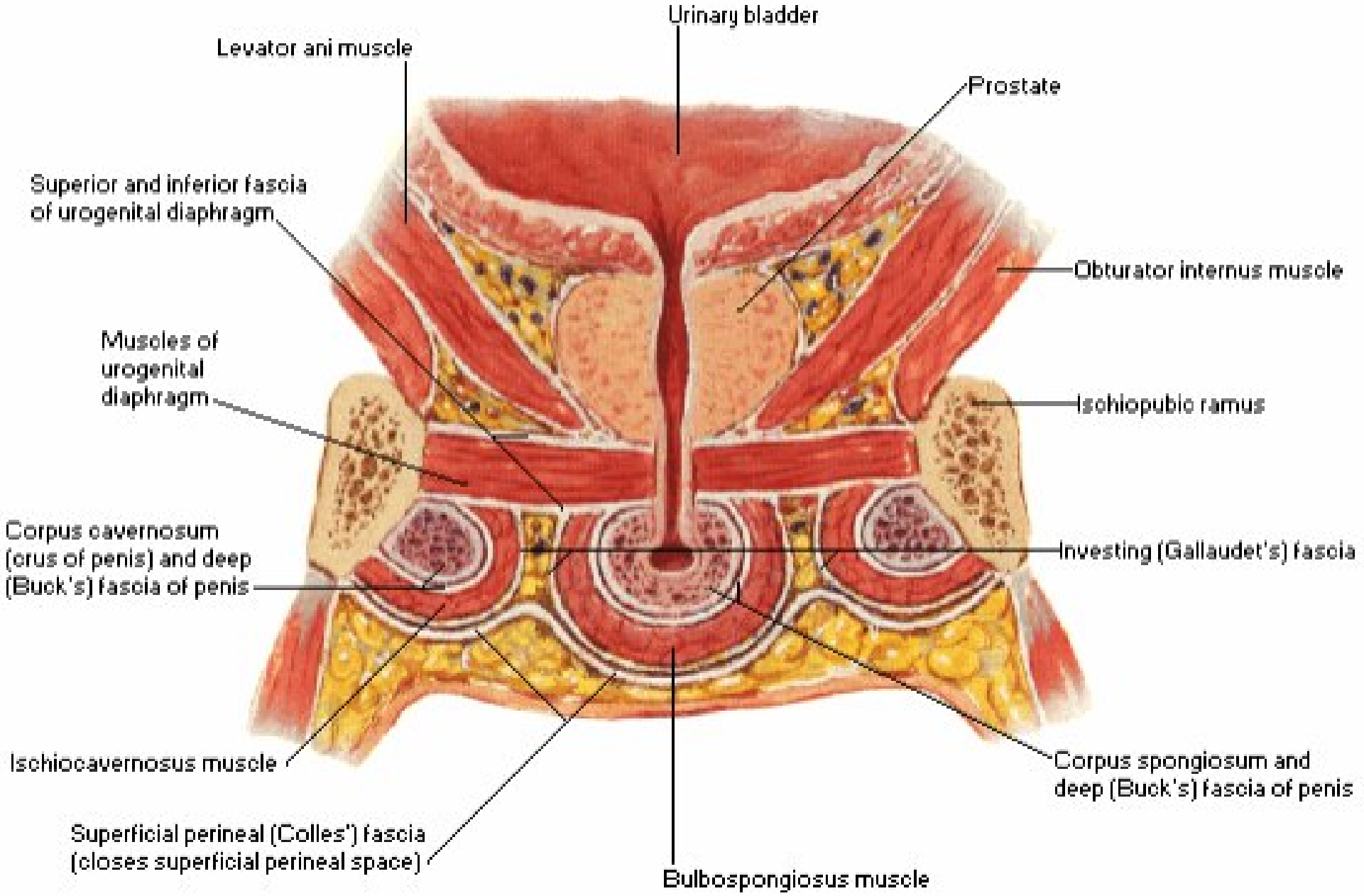
Urinary bladder
Levator ani muscle
Prostate
Superior and inferior fascia of urogenital diaphragm
Obturator internus muscle
Muscles of urogenital diaphragm
Ischiopubic ramus
Corpus cavernosum (crus of penis) and deep (Buck's) fascia of penis
Investing (Gallaudet's) fascia
Ischiocavernosus muscle
Corpus spongiosum and deep (Buck's) fascia of penis
Superficial perineal (Colles') fascia (closes superficial perineal space)
Bulbospongiosus muscle

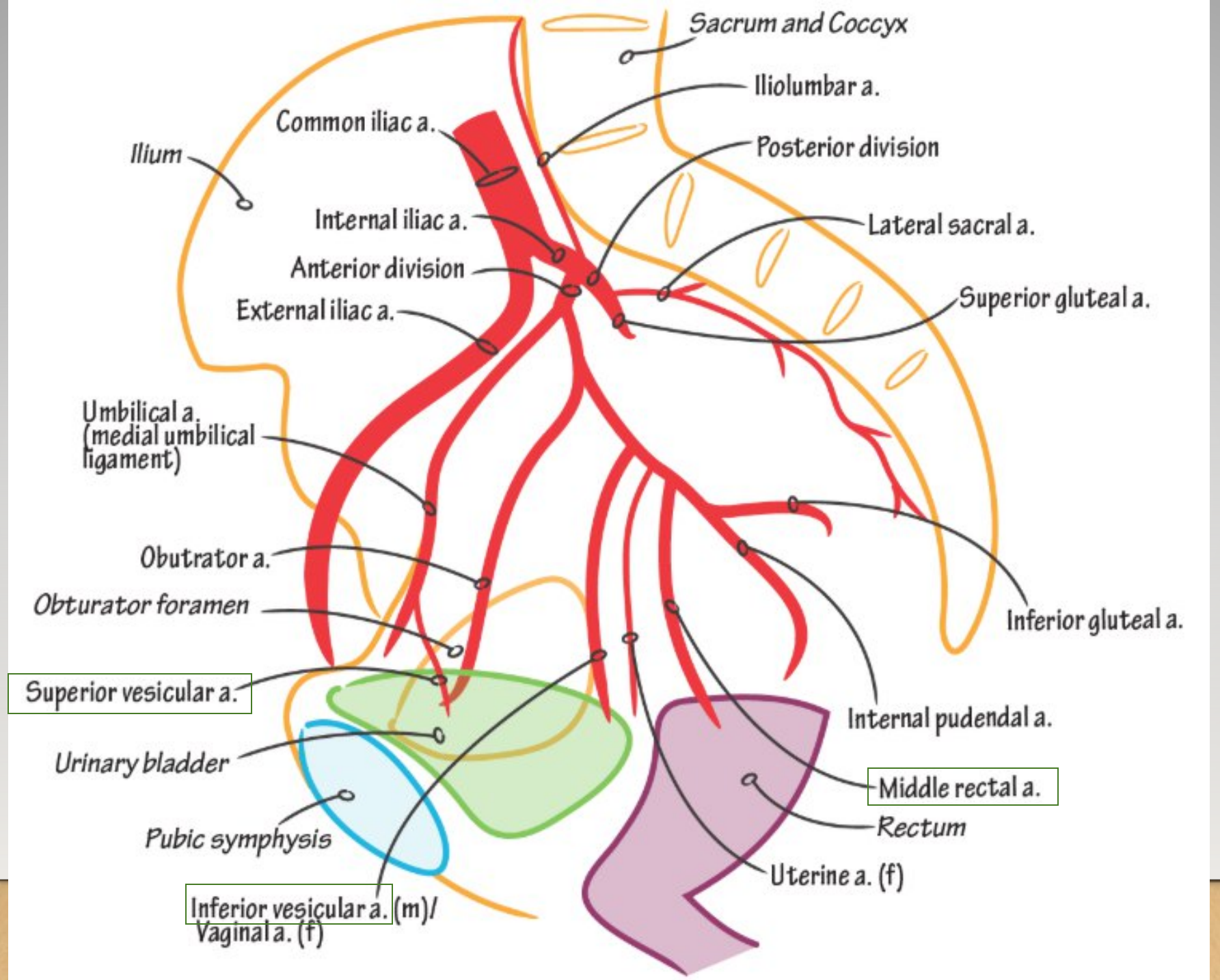
Sacrum and Coccyx
Iliolumbar a.
Common iliac a.
Ilium
Posterior division
Internal iliac a.
Lateral sacral a.
Anterior division
Superior gluteal a.
External iliac a.
Umbilical a.
(medial umbilical
ligament)
Obutrator a.
Obturator foramen
Inferior gluteal a.
Superior vesicular a.
Internal pudendal a.
Urinary bladder
Middle rectal a.
Rectum
Pubic symphysis
Uterine a. (f)
Inferior vesicular a. (m)/
Vaginal a. (f)

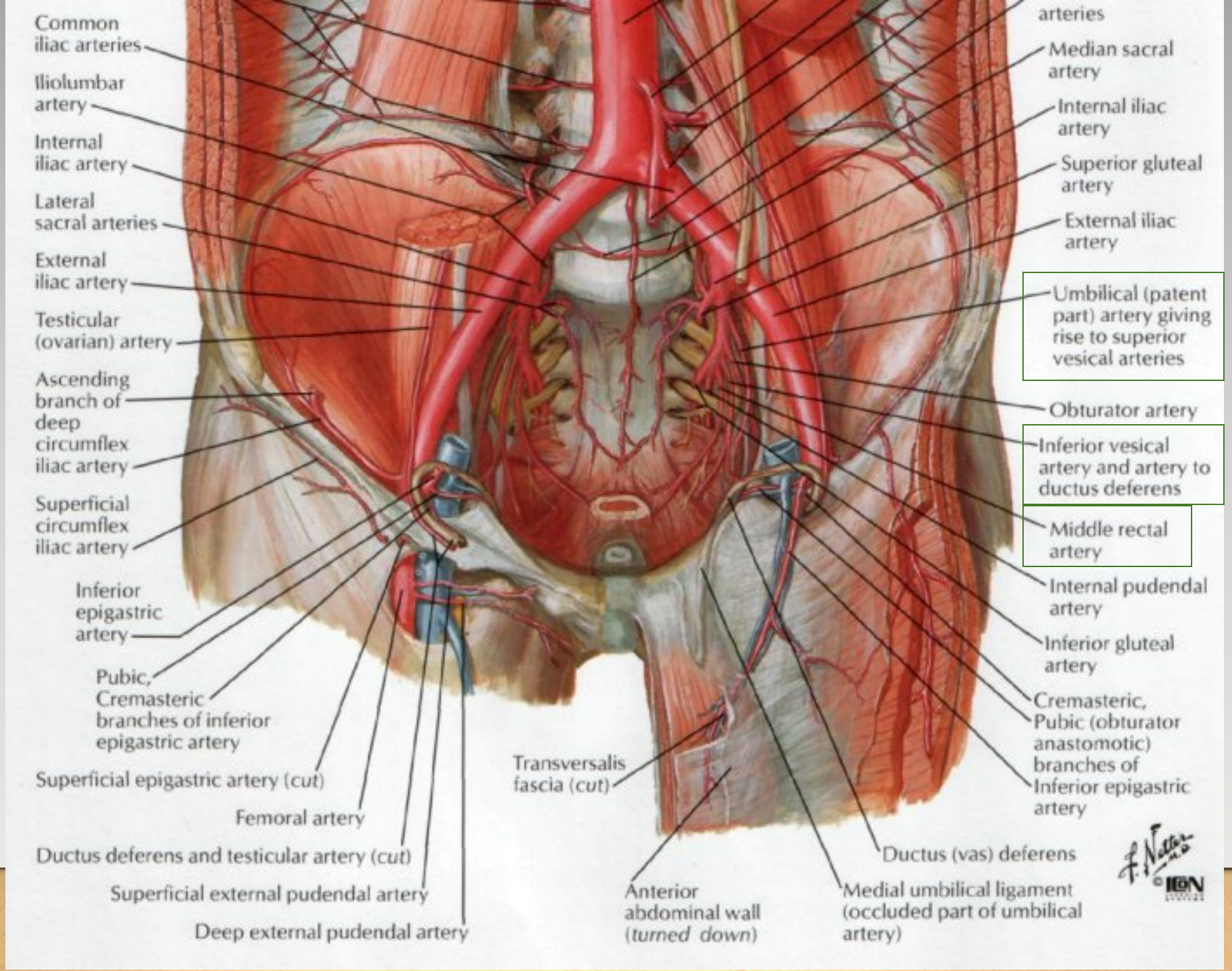
Common iliac arteries
Iliolumbar artery
Internal iliac artery
Lateral sacral arteries
External iliac artery
Testicular (ovarian) artery
Ascending branch of deep circumflex iliac artery
Superficial circumflex iliac artery
Inferior epigastric artery
Pubic, Cremasteric branches of inferior epigastric artery
Superficial epigastric artery (cut)
Femoral artery
Ductus deferens and testicular artery (cut)
Superficial external pudendal artery
Deep external pudendal artery
arteries
Median sacral artery
Internal iliac artery
Superior gluteal artery
External iliac artery
Umbilical (patent part) artery giving rise to superior vesical arteries
Obturator artery
Inferior vesical artery and artery to ductus deferens
Middle rectal artery
Internal pudendal artery
Inferior gluteal artery
Cremasteric, Pubic (obturator anastomotic) branches of Inferior epigastric artery
Transversalis fascia (cut)
Ductus (vas) deferens
Anterior abdominal wall (turned down)
Medial umbilical ligament (occluded part of umbilical artery)

Thank you