منافذ التوزيع داخل جمهورية مصر العربية

القاهرة	مكتبة الشرق الاوسط	داخل كلية طب قصر العينى بجوار قاعة المؤتمرات	01110150022 - 01022466896 01211361734
	مكتبة المروة	داخل كلية طب قصر العينى امام مبني ميديك	01114048571 - 01003484290
	مكتبة المروة	75 ش القصر العيني امام دار الحكمه (نقابة الاطباء)	01200494468 - 01200381085 27930149
	مكتبة المروة	ش غرب القشلاق امام مسجد النور خلف مطعم بريجو	01119838909 - 26825497
	مكتبة الشرق الاوسط	ش غرب القشلاق امام مسجد النور امام كافية افريكانو	01212609632 - 01110150022
	دار الكتب الطبيه	داخل كلية طب قصر العينى	01005705498
	دار الاطباء	ش غرب القشلاق امام مسجد النور خلف مطعم بريجو	01002263199
	مكتبة المنار	ش غرب القشلاق امام مسجد النور خلف مطعم بريجو	01090884144
	مكتبة المنار	امام بوابة كلية طب عين شمس بجوار دار ايتام الراضى	01006541155
6 اكتوبر	المكتبة العالمية	الحى السابع سنتر المختار بجوار نادى 6 اكتوبر الحى المتميز سنتر جمجوم امام جامعة مصر	01114138971 - 01005302503
	دار النفائس	خلف جامعة 6 اكتوبر و دايموند ابراج على الدين	01140590285 - 01140590285
الاسكندرية	مكتبة الشرق الاوسط	23 شارع شامبليون – الازريطه	01148037810 - 0114568217
	مكتبة مروة القصرالعينى	22 ش شامبليون – الازريطه	01221175366 - 4876179
	مكتبة الشروق	2 ش شامبليون – الازريطه	01007388431
بنها	مكتبة ابو بكر	داخل كلية طب بنها	01005654320
المنوفية	مكتبة الصفا	شارع مكسيم خلف كلية الطب شبين الكوم	01060109011 - 01008875800
	مكتبة الحسين	شارع مكسيم خلف كلية الطب شبين الكوم	01275909850 - 01018016174
	مكتبة القصر العيني	شارع مكسيم خلف كلية الطب شبين الكوم	01008005876
طنطا	مكتبة الاطباء	شارع مسجد الدعوة بجوار العباس سكان	01007489733
	مكتبة القصر	شارع الرفاعى	01026284161
المنصوره	المركز العلمى للكتاب	داخل كلية طب المنصوره	01224077740 - 01223741551
	مكتبة فوريو	داخل سنتر جامعة المنصورة	01119990437
الشرقية	المعرض الطبى الشامل	الزقازيق مساكن الاستاد عمارة 3 امام باب مكتب عميد الكلية	01281444531
الاسماعيلية	شركة الشروق مديكال	اول شمال من ش الغابه بجوار البوابة اليمني لمسجد الصالحين	01092516061
دمياط	مكتبة الشرق الاوسط	امام مستشفى الجامعة	01210862959
كفر الشيخ	مكتبة دار الاطباء	امام كلية الطب	01007743765
بنى سويف	دار الكتب الطبيه	داخل كلية طب بنى سويف	01005705498
الفيوم	مكتبة ابن سينا	امام كلية الطب	01158643483 - 01026686028
المنيا	مكتبة الوليد	حى شلبى – ميدان كلية الاداب بجوارفضاتر الاسكندرانى	01010442423 - 01212369046
اسيوط	مكتبة الشرق الاوسط	شارع المكتبات امام جامعة اسيوط	01124676082 - 01141327763
	مكتبة الشرق الاوسط	داخل كلية طب اسيوط مبنى المدرجات	01124676082 - 01003149041
سوهاج	مكتبة الشرق الاوسط	كلية الطب بجوار باب واحد امام نادى القضاه	01143226632
قنا	مكتبة الشرق الاوسط	داخل كلية طب جامعة جنوب الوادى	01118751576 - 01118915727
اسوان	ميديكال ستور للكتب الطبية	امام مركز مجدى يعقوب خلف معمل يوسف البتيتى	01112065059 - 01102989446
	مكتبة ادرنالين	مول ستى سنتر (مول جابر عوض) بجوار مستشفى الهلال	01150434370 – 0111971827

الوكلاء والموزعين خارج مصر

KSA	Abo Zinadah Scientific Bookshop Jeddah.	0569374245 ibrahim70@gmail.com
Jordan	ABC Book L.L.C 235Assaf Building,Queen Rania St., Amman.	+962(6)5336475
Iraq	Alshams Scientific Bookshop Baghdad.	009647901326914 009647715217260 http://www.shamsboohs.com
Sudan	AL-Marwa Bookstore Inside the Medical Specialties Council, Khartoum.	+249900004645
	Erabe's for Books and Medical Equipments Khartoum. (Jackson Position)	+249904687509 +249100937500
	Alkahly for Books and Medical Equipments Khartoum.	+249922881577 +249100313500
	Al-Salam Medical Bookstore Omdurman.	+249909678613 +249912261970
	Medical Scientific Bookstore Omdurman.	+249912665045 +20111311414
Libya	Ghassan for Medical Books Benghazi.	0945791299
	AL-Marwa Bookstore Benghazi, Gardens, land of blame, adjacent to the new mosque, Mosque of Ibn. Taymiyya	0914893275
Yemen	Sindebad Bookstore Taiz and Sana'n. Online Selling is Available.	+967775616191 Sindebad.net
Palestine	Palestine Medical Books Ramallah Online Selling is Available.	+972598419889
Bahrain	Al Mutawa Stationary Kingdom of Bahrain-Samaheej	+97339869822 +97335596967

Contact Us :
Middle East & El Marwa for Publishing & Distribution Cairo, Egypt
00201110150022
00201156819096
me_book2010@yahoo.com

El MARWA publishing and distribution
MEPD

❖ N.B:

- This E-Book series is written to be a focused, to the point yet comprehensive source of studying for USMLE step 1 concentrating mainly on the high yield topics that you will most probably see in the exam.
- The purpose of this E-Book series is to help others achieve their goals and make it easier for everyone to pass with a score of 260+.
- If you are an Arabic USMLER you have the advantage to watch my videos on Youtube.
- The text in the highlight color is the highest yield points in every branch that you need to know by heart.
- High yield means concepts that are frequently tested in the Exam.
- For more information about our program for USMLE, visit our Website: https://elhusseinyusmleprep.com

Contents

1. Routine Management of the Newborn 1

2. Pediatric Cardiology 21

3. Pediatric Gastroentrology 43

4. Pediatric Pulmnology 86

5. Pediatric Endocrinology 97

6. Abnormal Genitourinary Findings 110

7. Pediatric Orthopedics 124

8. Pediatric Neurology 154

9. Genetics and dysmorphology 169

10. Inborn errors of metabolism 189

11. Growth and development 208

12. Pediatric infections 217

CHAPTER 1

Routine Management of the Newborn

Routine Management of the Newborn

- Pediatric medicine begins just after the birth with routine management of the newborn, which involves a physical examination, Apgar scoring, eye care, and routine disease prevention and screening.
- Once the child is delivered, the mouth and nose are suctioned, followed by clamping and cutting of the umbilical cord. The newborn is then dried, wrapped in clean towels, and placed under a warmer as he has just descended from an environment of 98.6° F to approximately 65° F.
- Gentle rubbing or stimulating the heels of the newborn helps to stimulate crying and breathing. Intubation and ABG analysis of the child are indicated only if the newborn is not breathing or is in respiratory distress. Nasogastric tube placement is indicated when GI decompression is needed. Antibiotics are indicated for sepsis.
- Late preterm neonate: between 34 and 37 weeks.
- Term neonate: gestational age 38 weeks or more.

Normal Vital Signs in a Newborn

- Respiratory rate (RR) of 40 to 60 breaths per minute (BrPM).
- Heart rate (HR) of 120 to 160 beats per minute (BPM).

Apgar Score: Newborn Assessment

- After delivery, immediate newborn care involves drying the infant, clearing secretions from the mouth and nares, and providing warmth.
- Apgar scores are a quick measure of overall neonatal status and response to resuscitation. They are routinely measured at 1 and 5 minutes of life.
- Most neonates have scores of 7-9 and require no intervention. Scores <7 may require further evaluation and resuscitation.
- The Apgar score delineates a quantifiable measurement for the need and effectiveness of resuscitation. The Apgar score does not predict mortality.
- One-minute score evaluates conditions during labor and delivery.
- Five-minute score evaluates the response to resuscitative efforts.

	Sign	0 points	1 point	2 points
A	Appearance/ color	Completely blue/pale	Body pink, extremities blue	Completely pink
P	Pulse	Absent	<100/min	>100/min
G	Grimace/ reaction	Absent	Grimace/ whimper	Cough/ sneeze/cry
A	Activity/ muscle tone	Limp	Some flexion	Active/ spontaneous
R	Respiratory effort	Absent	Slow, weak cry	Regular, good cry

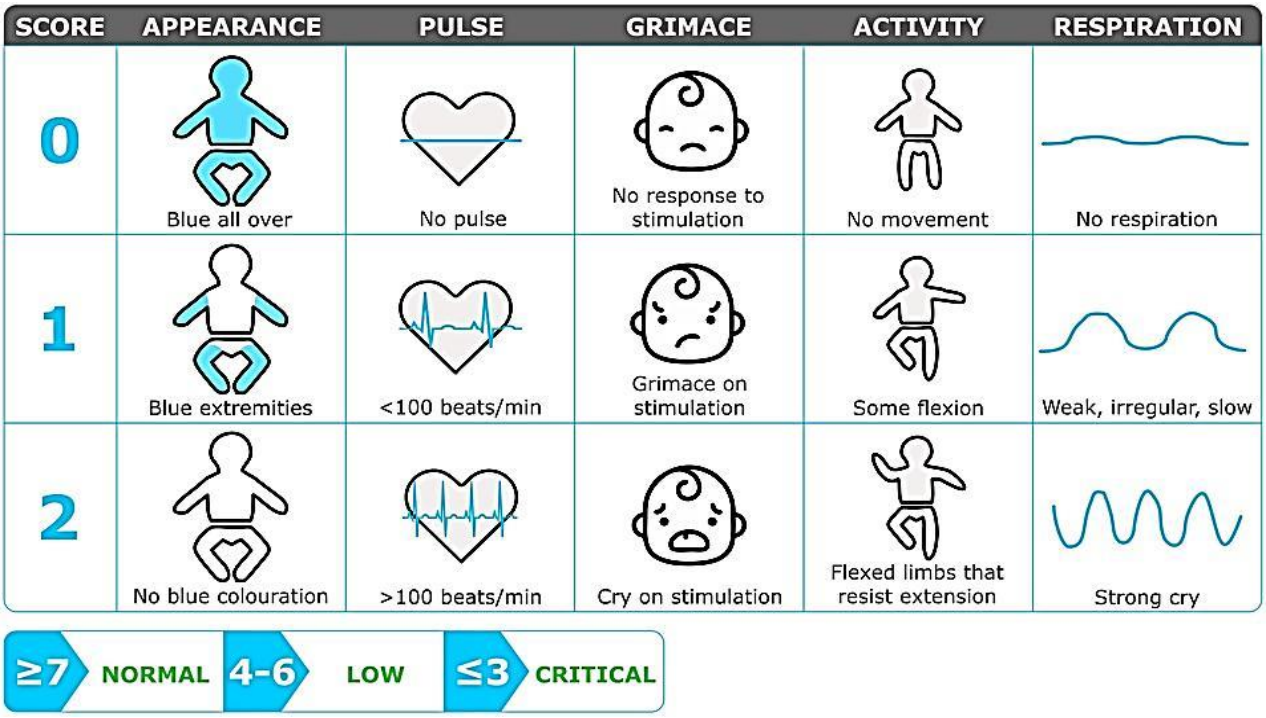

❖ N.B:

- Newborns have an underdeveloped thermoregulatory center and are at risk for hypothermia; therefore, drying and warming the infant is essential to prevent loss of body heat.
- Warming methods include swaddling with warm blankets, placing the infant under a radiant warmer, and/or allowing skin-to-skin contact with the mother.
- Skin-to- skin contact not only provides warmth but also helps to initiate breastfeeding.

Eye Care

- To diagnose the cause of conjunctivitis in the newborn, you must consider when the redness and irritation begins.
- At 1 day, the most likely cause of the conjunctivitis is chemical irritation from silver nitrate.
- From days 2 to 5, the most likely cause is Neisseria gonorrhoeae.
- Conjunctivitis after more than 5 days post-delivery is most likely due to Chlamydia trachomatis.
- Conjunctivitis after 3 weeks or more is most likely due to herpes infection.

Neonatal conjunctivitis

Type	Onset age	Findings	Treatment
Chemical	<24 hr	• Mild conjunctival irritation & tearing after silver nitrate ophthalmic prophylaxis	Eye lubricant
Gonococcal	2-5 days	• Marked eyelid swelling • Profuse purulent discharge • Corneal edema/ulceration	Single IM dose of 3rd-generation cephalosporin
Chlamydial	5-14 days	• Mild eyelid swelling • Watery, serosanguineous, or mucopurulent eye discharge	PO macrolide

IM = intramuscular; **PO** = oral.

- Treatment:

- In the delivery room, all newborns must be given 2 types of antibiotic drops in each eye to prevent ophthalmia neonatorum. This condition can be attributed most commonly to Neisseria gonorrhoeae or Chlamydia trachomatis. Use:
  - Erythromycin ointment or tetracycline ointment.
  - Silver nitrate solution.

❖ N.B:

- First-line treatment for both chlamydial conjunctivitis and pneumonia consists of a course of oral erythromycin. Oral erythromycin is associated with risk of infantile hypertrophic pyloric stenosis, but the benefits of treating and preventing complications of chlamydial infection outweigh this risk.
- The Centers for Disease Control and Prevention recommends that all pregnant women should be screened for chlamydia at the first prenatal visit. Maternal screening should be repeated in the third trimester in all high-risk women (age <25, new or multiple sexual partners). Treatment of maternal chlamydia is the best method to prevent neonatal infection.

Vitamin K-Deficient Bleeding

- Definition:

- Humans obtain vitamin K from diet and gut flora.

- Deficiency in newborns is the result of poor placental transfer, absent gut flora, immature liver function, and inadequate levels in breast milk.

- As the neonate's colonic flora has not adequately colonized, E. coli is not present in sufficient quantities to make enough vitamin K to produce clotting factors II, VII, IX, and X and proteins C and S. Without such factors, the newborn is more likely to have bleeding from the GI tract, belly button, and urinary tract.

- Prophylactic Treatment:

- To prevent VKDB (formerly known as hemorrhagic disease of the newborn), a single intramuscular dose of vitamin K is recommended and has been shown to decrease the incidence of VKDB.

Screening Tests

- All neonates must be screened for these diseases prior to discharge:

- PKU.
- Congenital adrenal hyperplasia (CAH).
- Biotinidase.
- Beta thalassemia.
- Galactosemia.
- Hypothyroidism.
- Homocysteinuria.
- Cystic fibrosis.

Hepatitis B Vaccination

- Every child gets a hepatitis B vaccination, but only those with HBsAg-positive mothers should receive hepatitis B immunoglobulin (HBIG) in addition to the vaccine.

- There is no documented evidence that breastfeeding spreads hepatitis C or hepatitis B. If the mother's nipples or surrounding areola are cracked and bleeding, she should stop nursing temporarily and switch to the other breast.

- HIV and TB are absolute contraindications to breastfeeding. Herpes of the nipple is a contraindication.

Transient Conditions of the Newborn

Transient Polycythemia of the Newborn

- Hypoxia during delivery stimulates erythropoietin and causes an increase in circulating red blood cells.

- The newborn's first breath will increase O_2 and cause a drop in erythropoietin, which in turn will lead to normalization of hemoglobin.

❖ N.B:

- Polycythemia is defined as a hematocrit >65% in term neonates.
- A common cause of neonatal polycythemia is delayed clamping of the umbilical cord, resulting in excess transfer of placental blood. Other predisposing conditions include in-utero hypoxia (maternal hypertension, smoking) or poor placental gas exchange (maternal diabetes).
- Most neonates with polycythemia are asymptomatic other than appearing ruddy/plethoric. However, as the hematocrit rises, the viscosity of the blood increases and impairs blood flow to various organs. The most common symptoms are lethargy, irritability, and jitteriness.
- Other potential manifestations are respiratory distress, tachypnea, cyanosis, and poor feeding. The increased red blood cell mass can lead to hypoglycemia and hypocalcemia due to increased cellular uptake.
- Asymptomatic neonates require only hydration by feeding or parenteral fluids. Symptomatic neonates require partial exchange transfusion, in which blood is removed in exchange for normal saline to normalize the hematocrit.

Neonatal polycythemia	
Definition	• Hematocrit **>65%** in term infants
Causes	• Increased erythropoiesis from intrauterine hypoxia: maternal diabetes, hypertension, or smoking; IUGR • Erythrocyte transfusion: delayed cord clamping; twin-twin transfusion • Genetic/metabolic disease: hypothyroidism or hyperthyroidism; genetic trisomy (13, 18, 21)
Clinical presentation	• Asymptomatic (most common) • Ruddy skin • Hypoglycemia, hyperbilirubinemia • Respiratory distress, cyanosis, apnea • Irritability, jitteriness • Abdominal distension
Treatment	• Intravenous fluids • Glucose • Partial exchange transfusion

IUGR = intrauterine growth restriction.

Transient Tachypnea of the Newborn

- A condition caused by delayed resorption and clearance of alveolar fluid.
- Compression of the rib cage by passing through the mother's vaginal canal helps to remove fluid from the lungs.
- Newborns who are delivered via cesarean birth may have excess fluid in the lungs and therefore be hypoxic.
- Excess pulmonary fluid can cause respiratory distress (tachypnea, grunting, retractions) and hypoxia in newborns within a few hours after delivery.
- However, breath sounds are often clear as fluid remains in the interstitial space rather than in the alveoli.
- Findings on chest x-ray (hyperinflation, fluid in interlobar fissures) confirm the diagnosis, and patients are treated supportively with supplemental oxygen as needed.
- If tachypnea lasts more than 4 hours, it is considered sepsis and must be evaluated with blood and urine cultures.
- Lumbar puncture with CSF analysis and culture is done when the newborn displays neurological signs such as irritability, lethargy, temperature irregularity, and feeding problems.

Transient tachypnea of the newborn	
Pathophysiology	• Retained fetal lung fluid
Risk factors	• Cesarean delivery • Prematurity • Maternal diabetes
Clinical findings	• Tachypnea, increased work of breathing • Clear breath sounds • Chest x-ray: Hyperinflation, fluid in fissures
Management	• Supportive care (eg, oxygen, nutrition) • Self-resolution in 1-3 days

Delivery-Associated Injury in the Newborn

Subconjunctival Hemorrhage

- Minute hemorrhages may be present in the eyes of the infant due to a rapid rise in intrathoracic pressure as the chest is compressed while passing through the birth canal.

- No treatment is indicated.



Skull Fractures

- <u>There are 3 major types of skull fractures in the newborn:</u>

- Linear: most common.
- Depressed: can cause further cortical damage without surgical intervention.
- Basilar: most fatal.

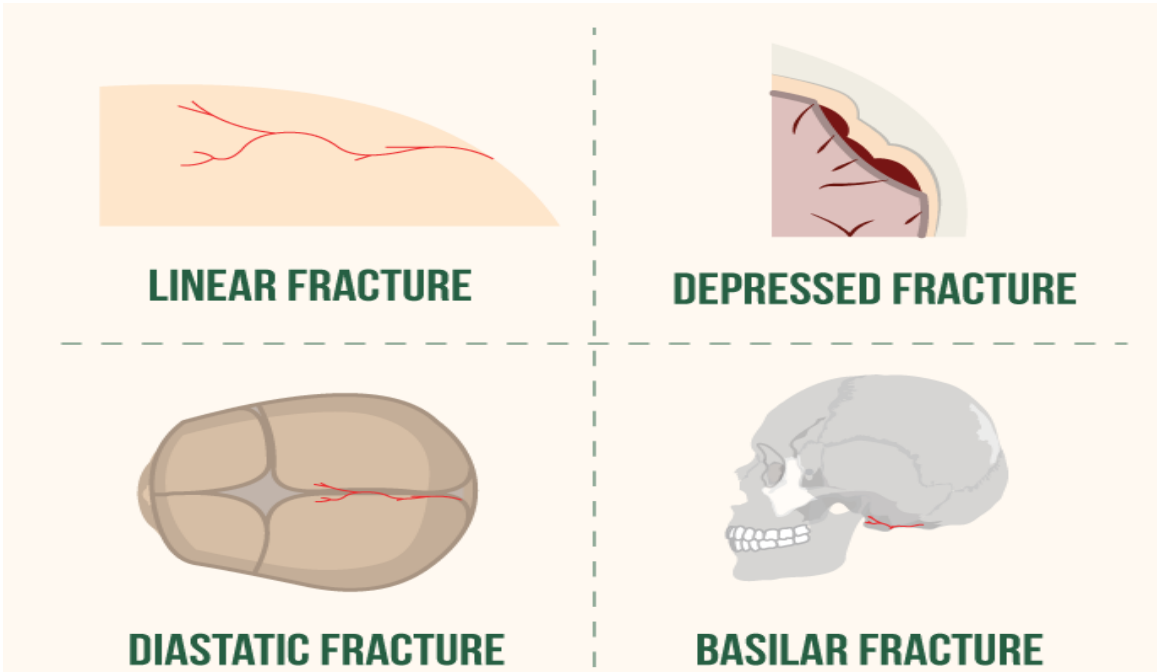

Scalp Injuries

- Caput succedaneum refers to scalp swelling superficial to the periosteum that crosses suture lines. The edema usually involves the portion of the head presenting during vertex delivery and is typically identified at birth.

- Cephalohematoma is a subperiosteal hemorrhage and presents a few hours after birth as scalp swelling limited to one cranial bone (Doesn't cross suture lines). Most cases do not require any treatment and resorb spontaneously within 2 weeks to 3 months, depending on the size. Rarely, phototherapy may be necessary to improve the hyperbilirubinemia.

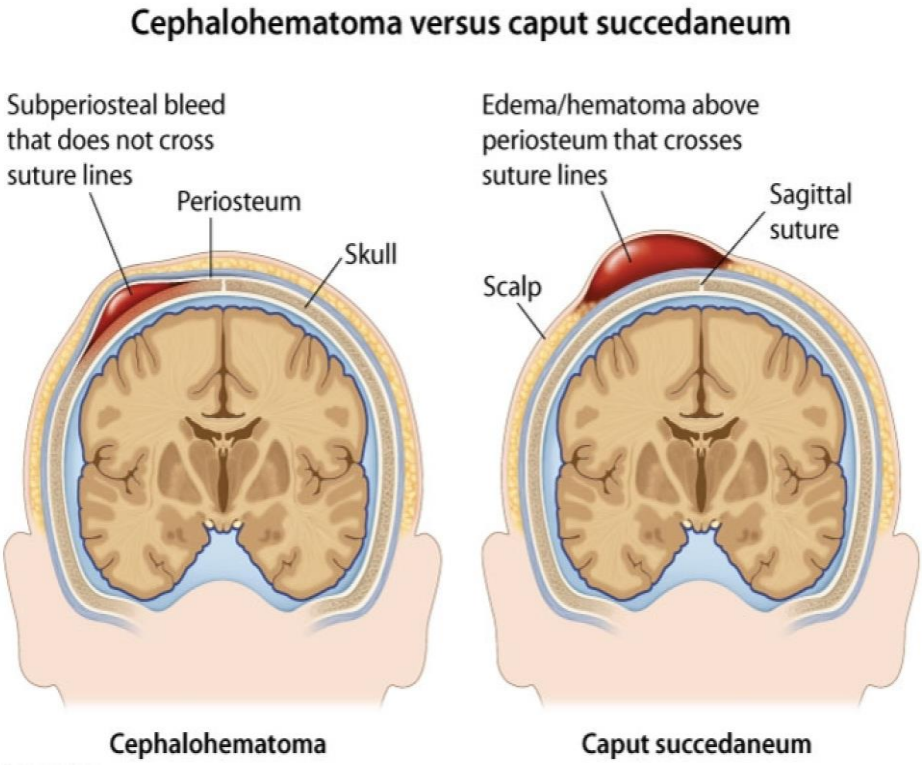

Brachial Palsy

- Etiology:

- Brachial plexus injuries are secondary to births with traction in the event of shoulder dystocia.

- Shoulder dystocia occurs when, after delivery of the fetal head, the baby's anterior shoulder gets stuck behind the mother's pubic bone.

- Brachial palsy is most commonly seen in macrosomic infants of diabetic mothers and has 2 major forms.

A. Duchenne-Erb Paralysis: C5-C6

- "Waiter's tip" appearance; secondary to shoulder dystocia.

- The infant is unable to abduct the shoulder or externally rotate and supinate the arm due to traction of upper trunk (C5, C6 Roots).

- Diagnosis is made clinically, and immobilization is the best treatment.

B. Klumpke Paralysis: C7-C8+/- T1

- "Claw hand" due to traction of lower trunk (C7, C8 Roots).

- Paralyzed hand with Horner syndrome (ptosis, miosis, and anhydrosis).

- Diagnosis is made clinically, and immobilization is the best treatment.

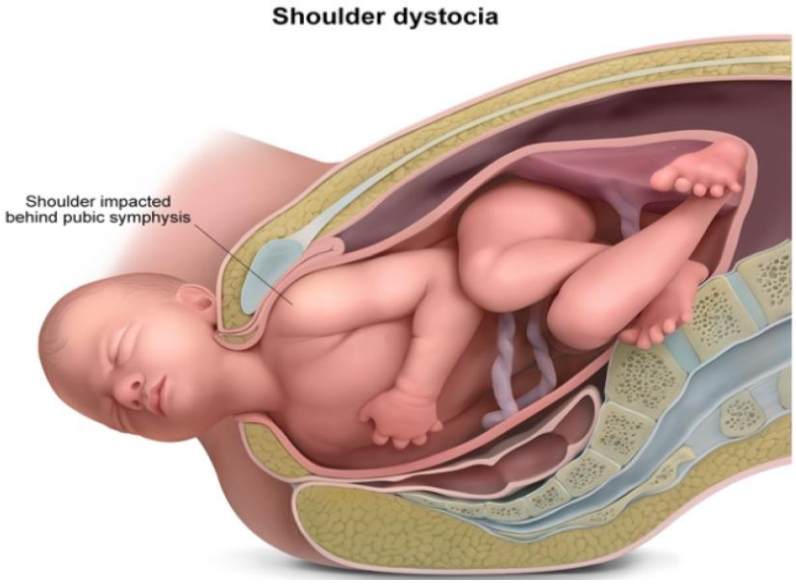

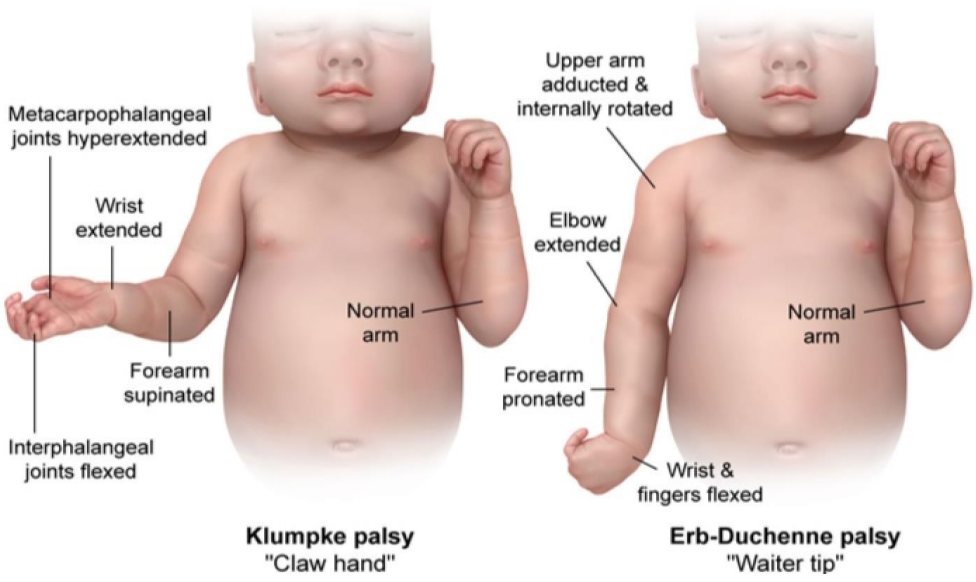

Clavicular Fracture

- This is the most common newborn fracture as a result of shoulder dystocia.
- X- ray is the best diagnostic test, and the fracture is treated with immobilization, splinting, and physical therapy (most neonatal clavicular fractures heal rapidly without complication).

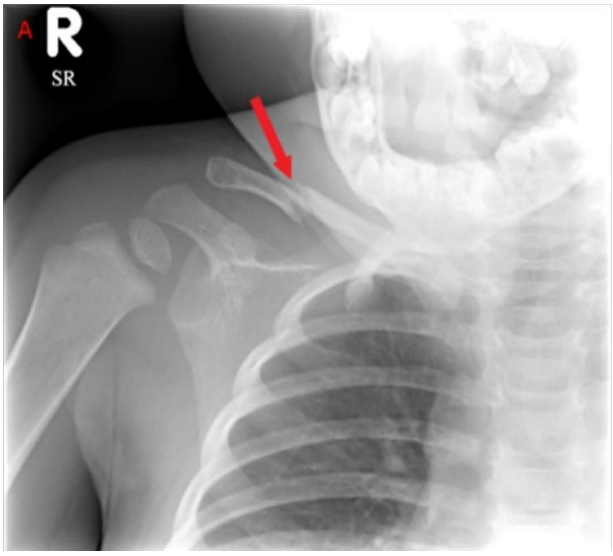

Facial Nerve Palsy

- Facial nerve palsy is paralysis of structures innervated by the facial nerve, caused by trauma secondary to forcep use in delivery.
- Diagnosis is made clinically, and improvement occurs gradually over a few weeks to months. However, if no recovery is seen, then surgical nerve repair is necessary.



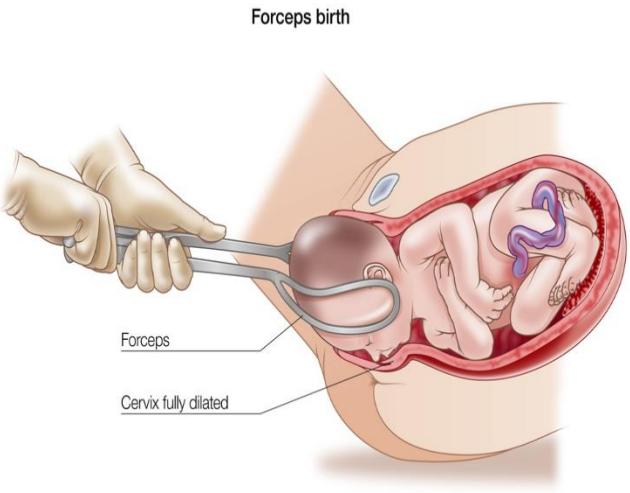

Amniotic Fluid Abnormalities and Associated Manifestations

- Amniotic fluid (AF) is the liquid that surrounds the fetus after the first few weeks of gestation.

- It has a number of functions that are essential for normal growth and development:

- It helps to protect the fetus from trauma to the maternal abdomen.
- It cushions the umbilical cord from compression between the fetus and uterus.
- It has antibacterial properties that provide some protection from infection.
- It serves as a reservoir of fluid and nutrients for the fetus.

- Amniotic Fluid Production:

- In the first half of pregnancy, amniotic fluid is derived from fetal and possibly maternal compartments. Water and solutes freely traverse fetal skin and may diffuse through the amnion and chorion as well.

- By the second trimester, the fetal skin becomes keratinized, making it impermeable to further diffusion. At this time, a fetus contributes to amniotic fluid volume and composition almost exclusively through urination.

- Amniotic Fluid Elimination:

- The primary source of elimination is through fetal swallowing, which is then absorbed by the fetal gastrointestinal tract to the blood stream then to umbilical arteries and cross the placenta to be taken care of by the mother.

- This continuous production and elimination of amniotic fluid should maintain amniotic fluid in a steady state, but any disruption of either sides of this equation we will have abnormal volume of amniotic fluid.

- Oligohydramnios:

- Low amniotic fluid level is called oligohydraminos which occurs if the fetus is not producing urine in normal amounts or if the urinary tract is obstructed preventing amniotic fluid from getting out to the amniotic fluid.

- Causes are:

  - Prune belly: lack of abdominal muscles, so unable to bear down and urinate. Treatment is with serial Foley catheter placements, but carries high risk of UTI

  - Renal agenesis: incompatible with life. Associated with Potter syndrome. Flat facies due to high atmospheric pressure causing compression of the fetus that is normally buffered by the amniotic fluid.

  - Bladder outlet obstruction in male infants: Posterior urethral valves (PUV).

- Polyhydramnios:

- High amniotic fluid level is called polyhydraminos which occurs when there is a problem in swallowing of amniotic fluid.

- So, polyhydraminos is indicative of GIT system defect that prevents amniotic fluid from passing down to the intestine of the fetus to be absorbed to the blood stream as esophageal atresia and duodenal atresia or due to defect in swallowing mechanism as occurs in anencephaly.

- Maternal diabetes mellitus → Fetal hyperglycemia also induces osmotic diuresis and polyuria, which increases amniotic fluid volume, resulting in polyhydramnios.

Physical Examination (Normal and abnormal findings)

Skin

A. Cutis marmorata:

- Lacy, reticulated vascular pattern over most of body when baby is cooled; improves over first month; abnormal if persists.



B. Milia:

- Firm, white papules; inclusion cyst; on palate midline: Epstein pearls; spontaneous resolution.





C. Salmon patch (nevus simplex):

- Pale, pink vascular macules; found in nuchal area, glabella, eyelids; usually disappears.




D. Mongolian spots:

- Blue to slate-gray macules; seen on presacral, back, posterior thighs; arrested melanocytes; usually fade over first few years; differential: child abuse.



E. Erythema toxicum neonatorum:

- Firm, yellow-white papules/pustules with erythematous base; peaks on second day of life; contain eosinophils; benign.



F. Hemangioma:

- Strawberry hemangiomas:

- Also called superficial infantile hemangiomas.

- Benign capillary tumors of childhood (bright red, sharply demarcated plaques that blanch with pressure). They appear during the first weeks of life, initially grow rapidly, and typically regress spontaneously.

- Although most patients require no intervention, beta blockers (propranolol) are recommended for complicated hemangiomas that are disfiguring, ulcerating, disabling (strabismus from eyelid hemangioma), or life- threatening (tracheal lesions). Propranolol promotes involution by causing vasoconstriction and by inhibiting
growth factors.



Head

A. Preauricular tags/pits:

- Look for hearing loss and genitourinary anomalies.





B. Coloboma of iris:

- Cleft at “six o'clock" position; most with other eye abnormalities; CHARGE association (Coloboma, Heart defects, Atresia of the nasal choanae, growth Retardation, Genitourinary abnormalities, and Ear abnormalities).



C. Aniridia:

- Hypoplasia of iris; defect may go through to retina; association with Wilms tumor.



Extremities

A. Syndactyly:

- Fusion of fingers or toes. Get x-ray first for surgical planning.

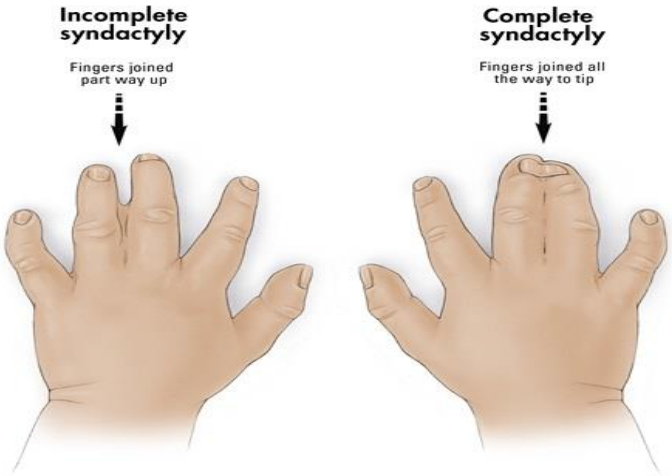

B. Polydactyly:

- >5 number of fingers or toes. No treatment needed if good blood supply.



C. Finger tag:

- Thin stalk, poor circulation; tie off at base → autoamputation.



Gestational Age and Size at Birth

Preterm	Large for Gestational Age (LGA) - Fetal Macrosomia	Post-term
▪ Premature: liveborn infants delivered prior to 37 weeks as measured from the first day of the last menstrual period.	▪ Birth weight >4,500 grams at term ▪ Predisposing factors: obesity, diabetes ▪ Higher incidence of birth injuries and congenital anomalies.	▪ Infants born after 42 weeks' gestation from last menstrual period. ▪ When delivery is delayed >3 weeks past term, significant increase in mortality.

- Low birth weight:

- Birthweight <2,500 grams.

- This may be due to prematurity, IUGR, or both.

❖ N.B:

- Anemia of prematurity (AOP) affects most preterm infants, and the onset and severity of anemia are proportional to the degree of prematurity.
- After delivery, circulating erythropoietin (EPO) normally decreases due to increased oxygen concentration in tissue. Decreased EPO causes decreased reticulocyte production in bone marrow. As a result, a physiologic red blood cell (RBC) nadir is expected and occurs at age 2-3 months in term infants.
- In preterm infants, however, low EPO levels are exacerbated by short RBC life span (40-50 days) and frequent phlebotomy in the neonatal intensive care unit. This can result in a significant, early-onset anemia.
- Most infants with AOP are asymptomatic. Those who do have symptoms generally have mild tachycardia, increased apnea, or poor weight gain.
- AOP often is a diagnosis of exclusion; hemolysis, enzyme defects, hemoglobinopathies, and infection should be ruled out. Laboratory studies show decreased hemoglobin and hematocrit and a low reticulocyte count relative to the degree of anemia. The RBCs appear normal under light microscopy.
- Treatment includes minimizing blood draws and ensuring adequate iron intake. RBC transfusions can be given if the infant is symptomatic but will further suppress EPO levels and delay recovery. Supplemental EPO is not effective in preventing the need for transfusions.

Anemia of prematurity	
Etiology	• Impaired erythropoietin production • Short red blood cell life span • Iatrogenic blood sampling
Clinical manifestations	• Usually **asymptomatic** • Tachycardia, apnea, poor weight gain
Laboratory findings	• **Low** hemoglobin & hematocrit • **Low** reticulocyte count • Normocytic, normochromic red blood cells
Treatment	• Minimize blood draws • Iron supplementation • Transfusions

CHAPTER 2

Pediatric Cardiology

Cardiology

Congenital heart diseases

Right to left shunting

- The 5 Ts:

1. Truncus arteriosus (1 vessel)
2. Transposition (2 switched vessels)
3. Tricuspid atresia (3 = Tri)
4. Tetralogy of Fallot (4 = Tetra)
5. TAPVR (5 letters in the name)

1. Tetralogy of Fallot:

- Tetralogy of Fallot is the most common cyanotic heart defect in children.

- Definition/Etiology:

- TOF is characterized by 4 anomalies that result from deviation of the infundibular septum in utero:

A. Pulmonary stenosis.
B. Right ventricular hypertrophy.
C. Ventricular septal defect (VSD).
D. Overriding aorta.

- Its cause is thought to be due to genetic factors and environmental factors. It is associated with chromosome 22 deletions.

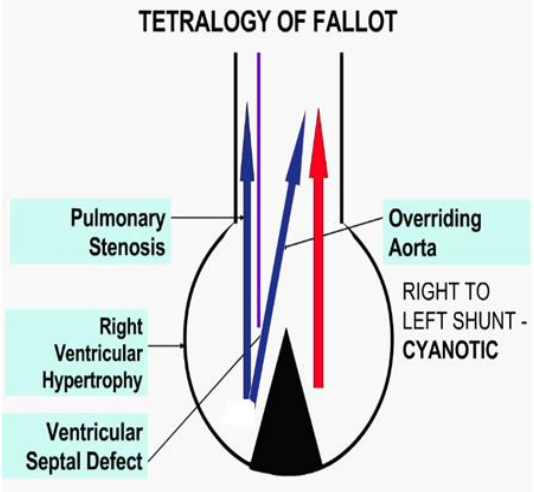

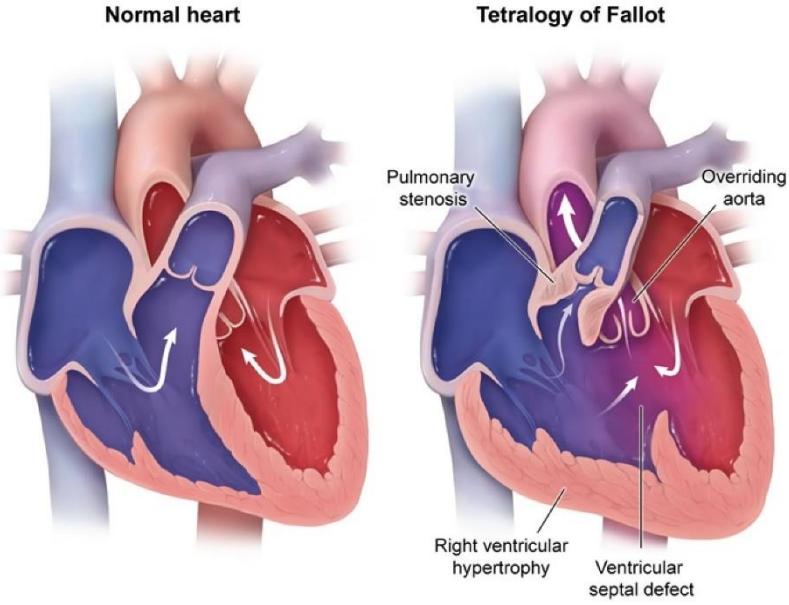

- Presentation:

- Tetralogy of Fallot presents with varying degrees of cyanosis depending on the severity of right ventricular outflow tract obstruction.

- "Tet" spells result from sudden spasm of the right ventricular outflow tract during exertion.

- The murmur is typically a harsh crescendo-decrescendo systolic murmur over the left upper sternal border, reflecting turbulence at the stenotic pulmonary artery.

- Placement of patients in a knee-chest position (Squatting) during a cyanotic spell increases systemic vascular resistance, increases pulmonary blood flow, and improves symptoms and cyanosis.

- Diagnostic Tests/Treatment:

- Chest x-ray showing a boot-shaped heart due to right ventricular hypertrophy.

- Decreased pulmonary vascular marking.

- Surgical intervention is the only definitive therapy. Elective surgical repair is optimally performed before age 6 months to decrease morbidity and mortality from outgrowing the RVOT.



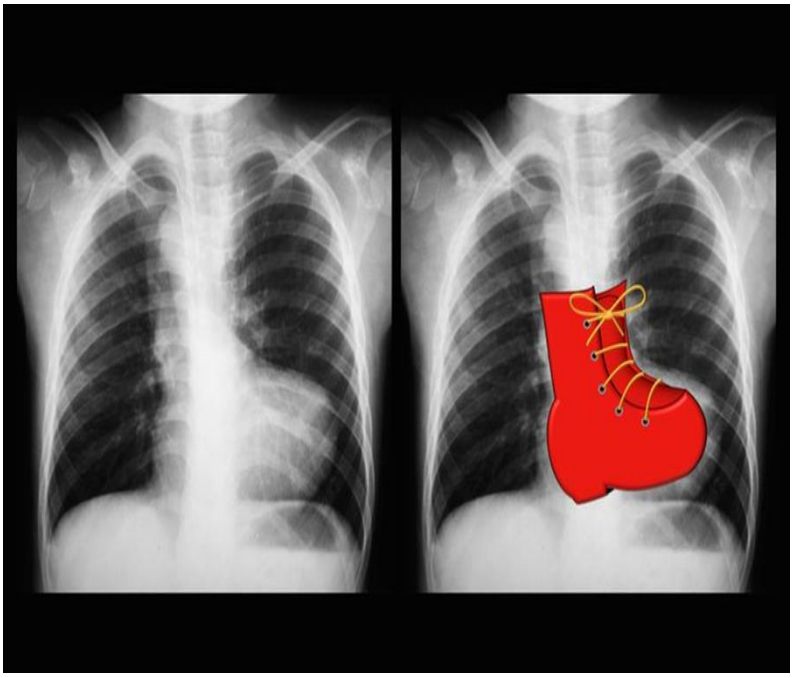

2. Transposition of the Great Vessels:

- Tetralogy of Fallot is the most common cyanotic condition in children after the neonatal period. Transposition of the great vessels (TOGV) is the most common cyanotic lesion during the neonatal period.

- Abnormal rotation of the great vessels during cardiac development (failure of the aorticopulmonary septum to spiral) results in an aorta arising from the right ventricle and the pulmonary artery from the left ventricle ("arterial switch").

- As a result, deoxygenated blood coming from the body goes to the right atrium and ventricle and is cycled back to the body through the aorta. Oxygenated blood from the lungs is returned to the lungs by the left side of the heart through the pulmonary artery.

- No oxygenation of blood can occur without a patent ductus arteriosus (PDA), atrial septal defect (ASD), or VSD.

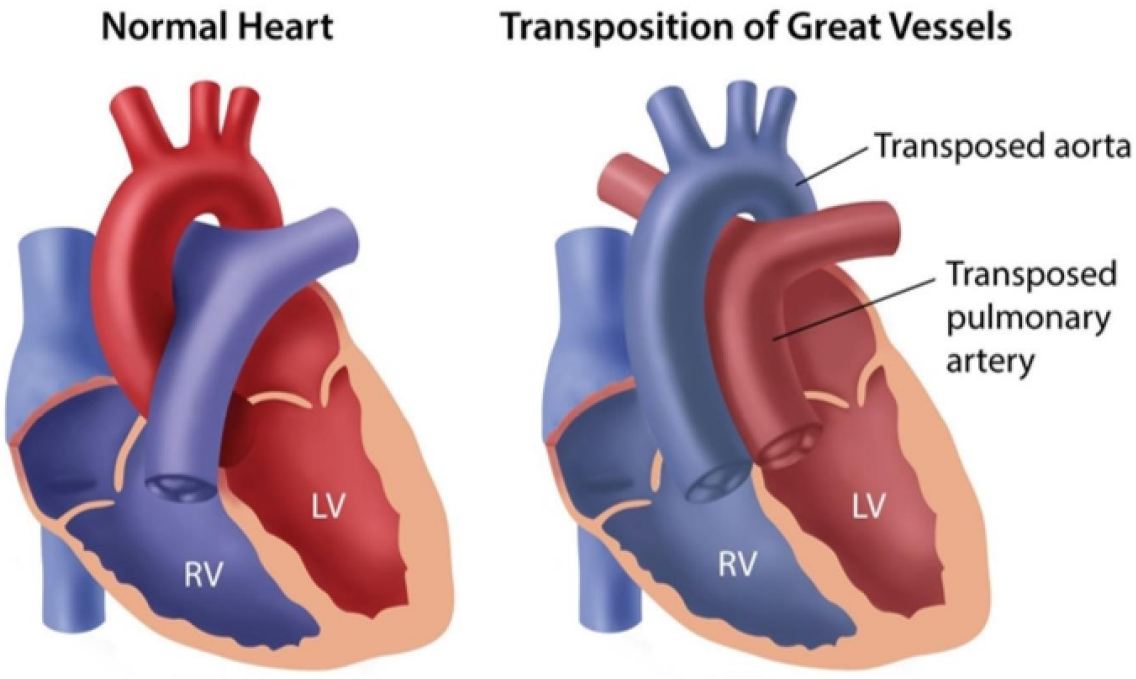

- <u>Presentation/Diagnostic Tests:</u>

- Early and severe cyanosis is seen.

- A single S2 is heard (absent pulmonary component of S2 because the aorta is anterior to the pulmonary artery).

- Chest x-ray will show an "egg on a string" due to narrow mediastinum.

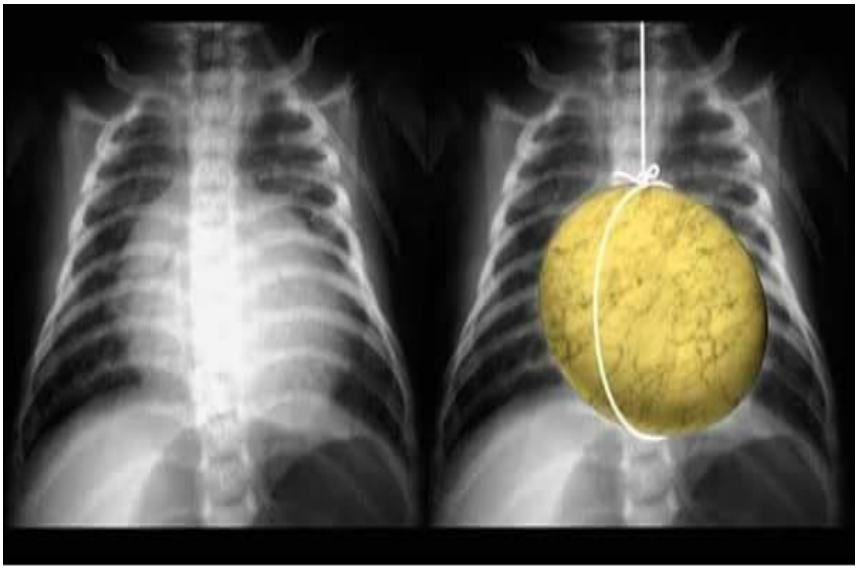

Transposition Of Great Arteries.

(Egg on String Appearance)

- Treatment:

- Neonates must have an open ductus arteriosus (PDA). They require prostaglandin E1 to keep the ductus open, and NSAIDs (especially indomethacin) are contraindicated because they will cause closure of the ductus.

- Two separate surgeries are necessary; however, each surgery carries a 50% mortality rate. Therefore, only 1 in 4 will survive the surgeries.

3. Tricuspid atresia:

- No outlet from the right atrium to the right ventricle; entire venous (systemic) return enters the left atrium from a foramen ovale or ASD (there must be an atrial communication); left ventricular blood to right ventricle (atretic) via a VSD and is augmented by PDA; therefore, pulmonary blood flow depends on presence (and size) of VSD.

- Associated atrial and ventricular septal defects are necessary for survival, allowing for mixing of oxygenated and deoxygenated blood to provide some oxygenated blood for the systemic circulation.

- Clinical presentation:

- Will present at birth with severe cyanosis.

- Holosystolic murmurs along left sternal border (most have a VSD; though right ventricle is small; it is still a conduit for pulmonary blood flow).

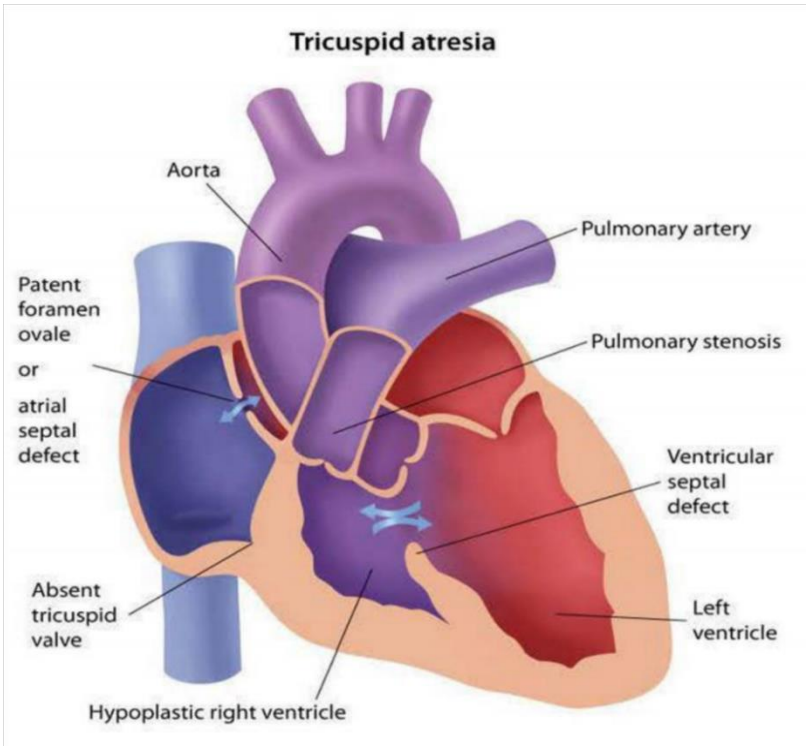

- Diagnosis:

- Chest x-ray: Pulmonary undercirculation is the reason for decreased pulmonary markings on chest x-ray.

- ECG: left axis deviation plus left ventricular hypertrophy (distinguishes from most other congenital heart disease).

- Echocardiogram (gold standard).

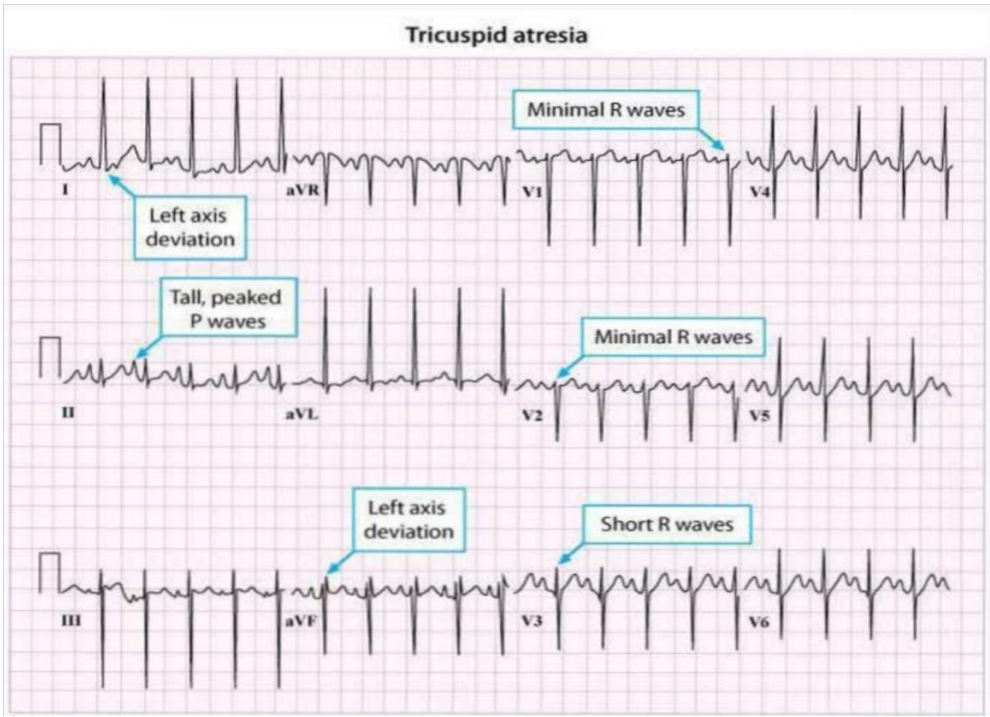

- Treatment:

- PGE infusion until aortopulmonary shunt can be performed.

- May need an atrial balloon septostomy (to make larger ASD) via cardiac catheterization until, a corrective surgery can be performed.

- Later, staged surgical correction.

- In the absence of surgical intervention, most children will die in the first year of life. Surgical repair improves 10-year survival rates to 80%.

❖ N.B:

- Left axis deviation on neonatal electrocardiogram is never normal.
- Tricuspid valve atresia is a cyanotic congenital heart defect characterized by left axis deviation on electrocardiogram and decreased pulmonary markings on chest radiograph due to hypoplasia of the right ventricle and pulmonary outflow tract.

4. Persistent Truncus Arteriosus:

- Truncus arteriosus (TA) occurs when a single trunk emerges from both right and left ventricles and gives rise to all major circulations.

- Presentation:

- Symptoms occur within the first few days of life and are characterized by:
  - Severe dyspnea.
  - Early and frequent respiratory infections.

- Single S_2 is heard as there is only one semilunar valve and a systolic ejection murmur is heard because these valve leaflets are usually abnormal in functionality. Peripheral pulses are bounding.

- The most severe sequela of this condition is pulmonary hypertension, which will develop within 4 months.

- Diagnostic Tests:

- Chest x-ray will show cardiomegaly with increased pulmonary markings.

- Treatment:

- Surgery must be completed early to prevent pulmonary hypertension.

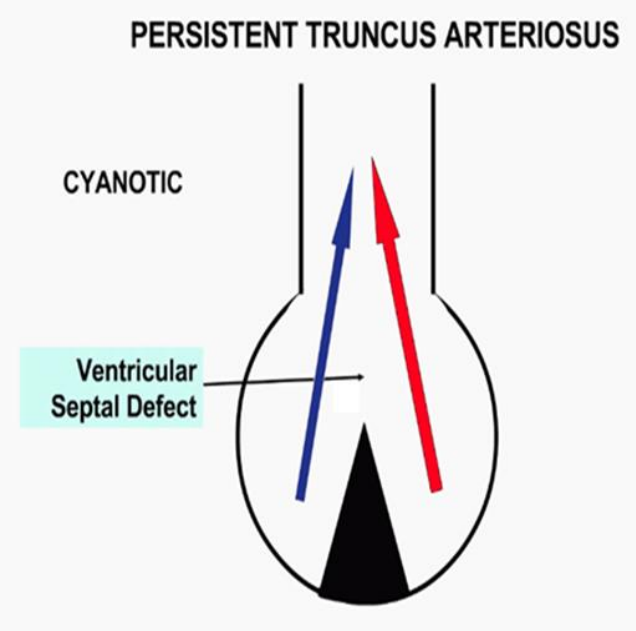

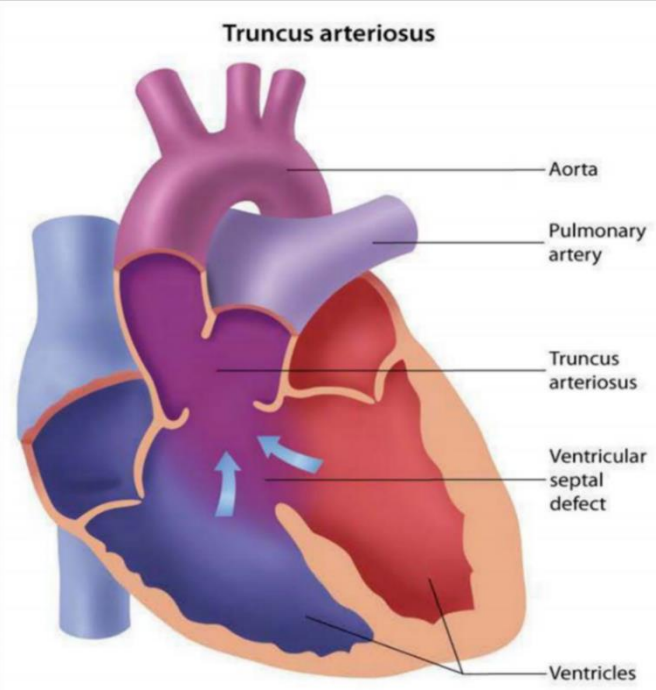

5. Total Anomalous Pulmonary Venous Return:

- In total anomalous pulmonary venous return (TAPVR), a congenital condition in which there is no venous return between pulmonary veins and the left atrium, oxygenated blood instead returns to the superior vena cava.
- ASD allows for right-to-left shunting to maintain cardiac output
- There are 2 forms: with or without obstruction of the venous return. Obstruction refers to the angle at which the veins enter the sinus.
- TAPVR with and without Obstruction:

	Signs/symptoms	Diagnostic tests	Treatment
TAPVR with obstruction	▪ Early in life with respiratory distress and severe cyanosis ▪ Severe pulmonary venous congestion and pulmonary hypertension with decreasing cardiac output and shock	▪ CXR shows pulmonary edema. ▪ Echocardiography is definitive.	Surgery is the definitive choice for treatment.
TAPVR without obstruction	▪ Less likely to be severely symptomatic early ▪ Age 1-2 years with right heart failure and tachypnea	▪ CXR shows snowman or figure 8 sign (large supracardiac shadow with an enlarged cardiac shadow). ▪ Most accurate diagnostic test is an echocardiogram.	Surgical intervention to restore proper blood flow.

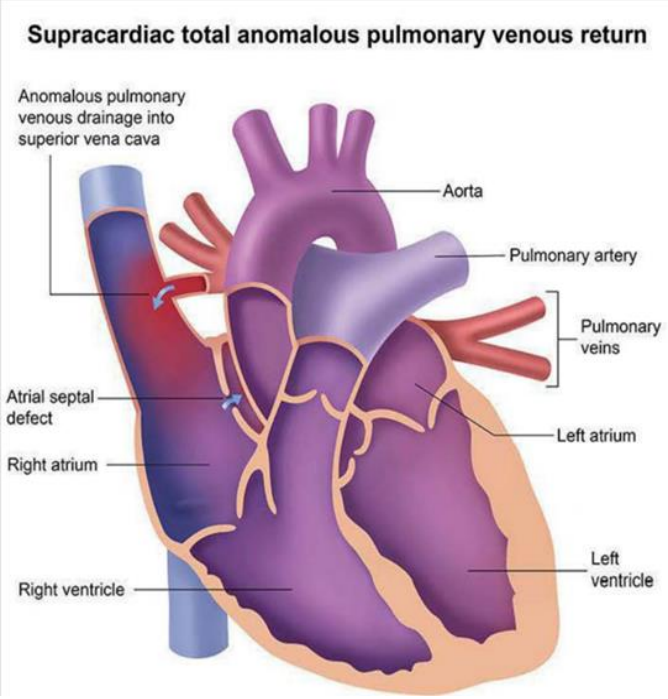



Cyanotic heart disease in newborns		
Diagnosis	**Examination**	**X-ray findings**
Transposition of the great vessels	• Single S2 • +/- VSD murmur	"Egg-on-a-string" heart (narrow mediastinum)
Tetralogy of Fallot	• Harsh pulmonic stenosis murmur • VSD murmur	"Boot-shaped" heart (right ventricular hypertrophy)
Tricuspid atresia	• Single S2 • VSD murmur	Minimal pulmonary blood flow
Truncus arteriosus	• Single S2 • Systolic ejection murmur (increased flow through truncal valve)	Increased pulmonary blood flow, edema
Total anomalous pulmonary venous return with obstruction	• Severe cyanosis • Respiratory distress	Pulmonary edema, "snowman" sign (enlarged supracardiac veins & SVC)

VSD = ventricular septal defect

Left to right shunting

- Right ventricular hypertrophy occurs from blood shunting from the high pressure left system to the low-pressure right system. This could later lead to Eisenmenger syndrome (ES). ES is defined as the process in which a left-to-right shunt caused by a VSD reverses into a right-to-left shunt due to hypertrophy of the right ventricle.

- Uncorrected left-to-right shunt (VSD, ASD, PDA) → ↑ pulmonary blood flow → pathologic remodeling of vasculature → pulmonary arterial hypertension.

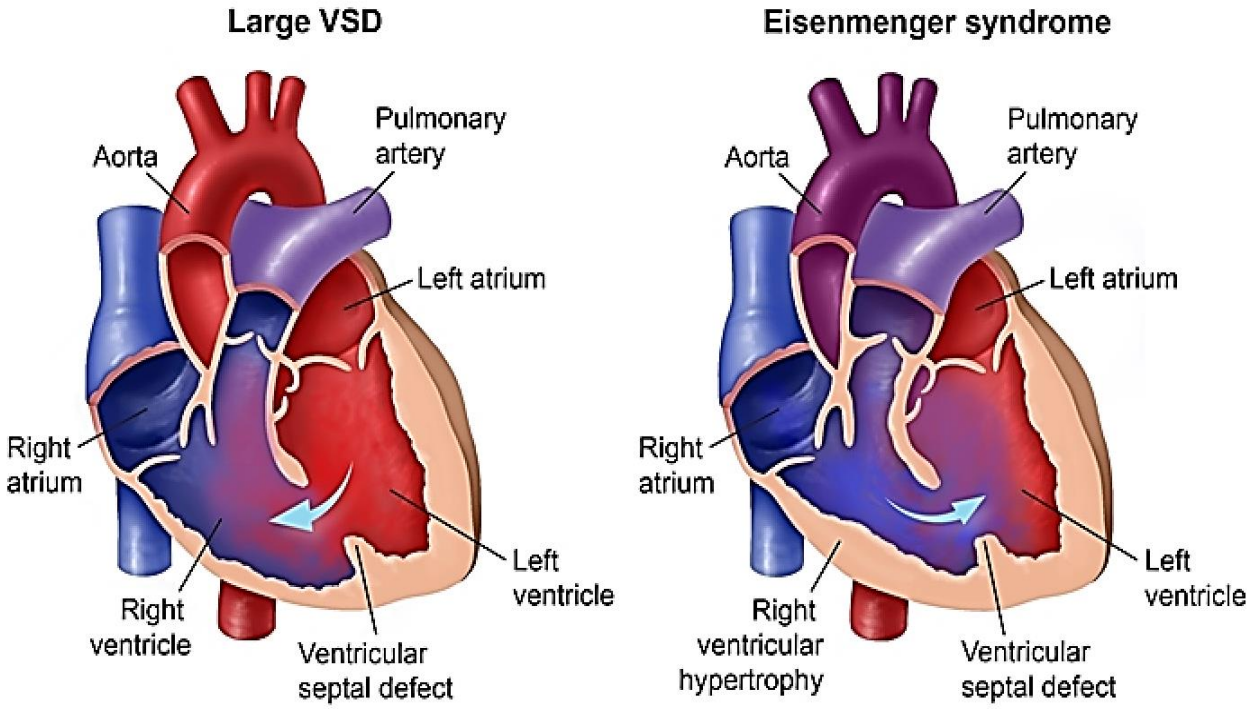

1. Ventricular Septal Defect:

- VSD is the most common congenital heart lesion.

- Presentation:

- Asymptomatic if small defect with normal pulmonary artery pressure (most cases).

- Harsh, holosystolic murmur best heard at the left lower sternal border.

Pansystolic = holosystolic = throughout systole

- Large ventricular septal defects can cause failure to thrive, easy fatigability, and heart failure.

- Diagnostic Tests:

- Chest x-ray shows increased vascular markings.

- Echocardiography should be performed to determine the location and size of the defect and to rule out other defects.

- Treatment:

- Smaller lesions usually close in the first 1 to 2 years while larger or more symptomatic lesions require surgical intervention.

- Diuretics and digoxin can be used for more conservative treatment (control failure and prevent pulmonary vascular disease).

- Surgery in first year if there is failure to thrive or unable to be corrected medically or infants at 6-12 months with large defects and pulmonary artery hypertension.

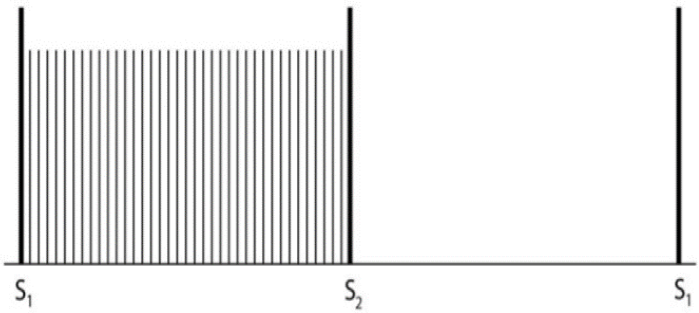

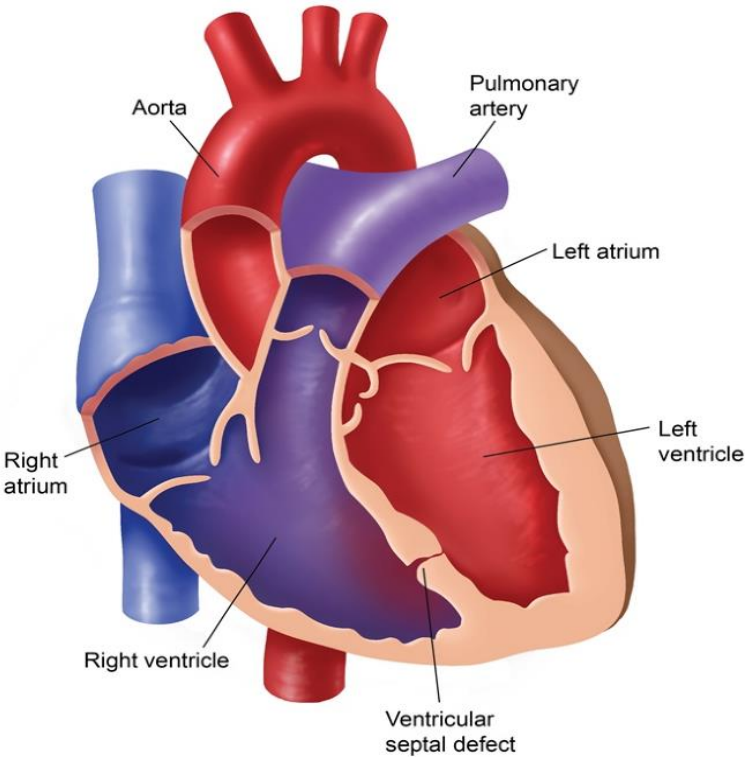

2. Atrial Septal Defect:

- ASD is a hole in the septum between both atria that is twice as common in women as in men.

- There are 2 major types of ASD:

- Primum defect: concomitant mitral valve abnormalities.
- Secundum defect: most common and located in the center of the atrial septum.

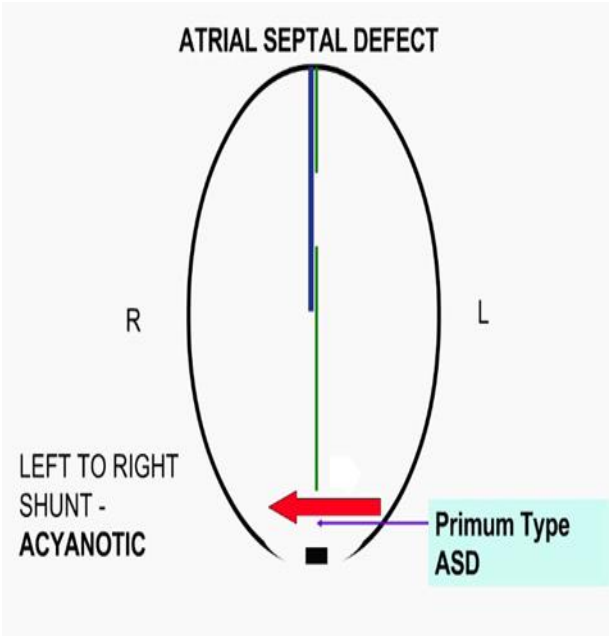

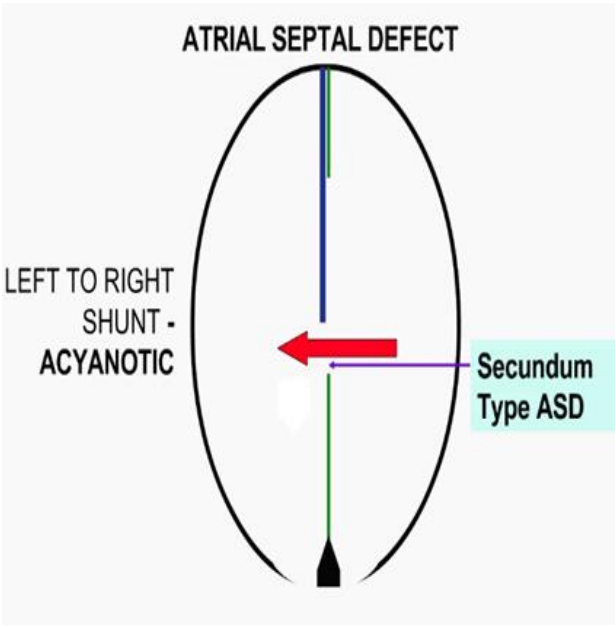

- Presentation/Diagnostic Tests:

- Patients are usually asymptomatic except for a fixed wide splitting of S_2.

- The most definitive test is cardiac catheterization. However, echocardiography is less invasive and can be just as effective.

- Chest x-ray (CXR) shows increased vascular markings and cardiomegaly.

- Treatment:

- Vast majority close spontaneously.

- Surgery or transcatheter closure is indicated for all symptomatic patients.

- Dysrhythmias and possible paradoxical emboli from DVTs later in life.

3. Patent Ductus Arteriosus (PDA):

- PDA is defined as the failure of spontaneous closure of the ductus.

- It usually closes when PO_2 rises above 50 mm Hg. Low PO_2 can be caused by pulmonary compromise due to prematurity. Areas of high altitude have an increased occurrence of PDA due to low levels of atmospheric oxygen.

- Associated with prematurity and congenital rubella.

- PDA is a normal finding in the first 12 hours of life. After 24 hours it is considered pathologic.

- Presentation:

- "Continuous machinery-like" murmur. A patent ductus arteriosus (PDA) is associated with a continuous flow murmur due to constant movement of blood from the high-pressure aorta to the low-pressure pulmonary artery. Small PDAs are often asymptomatic and detected incidentally on routine cardiac auscultation.

- Uncorrected PDA can eventually result in late cyanosis in the lower extremities (differential cyanosis).

- Differential cyanosis is a cyanosis of the lower extremities but not of the upper body.

- Differential cyanosis is the result of reduced arterial oxygen saturation in the distal aorta compared to that in the aorta proximal to the left subclavian artery. The most likely cause is right-to-left shunting of blood through a patent ductus arteriosus (PDA) into the junction between the aortic arch and the descending aorta.

- Diagnostic Tests:

- Echocardiography is the best initial test, while cardiac catheterization is the most accurate test.

- Treatment:

- Give indomethacin (NSAID inhibits prostaglandins) to close the PDA unless it is needed to live in concurrent conditions such as TOF.

- Give prostaglandins to pop open a PDA. Give indomethacin to inhibit popping.

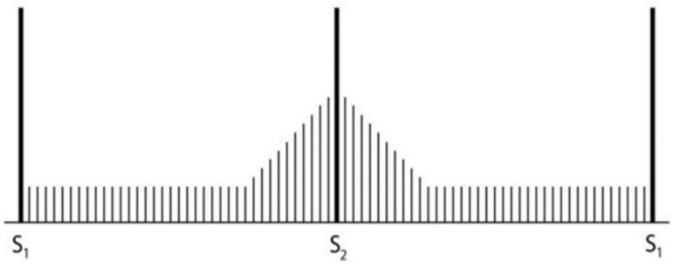

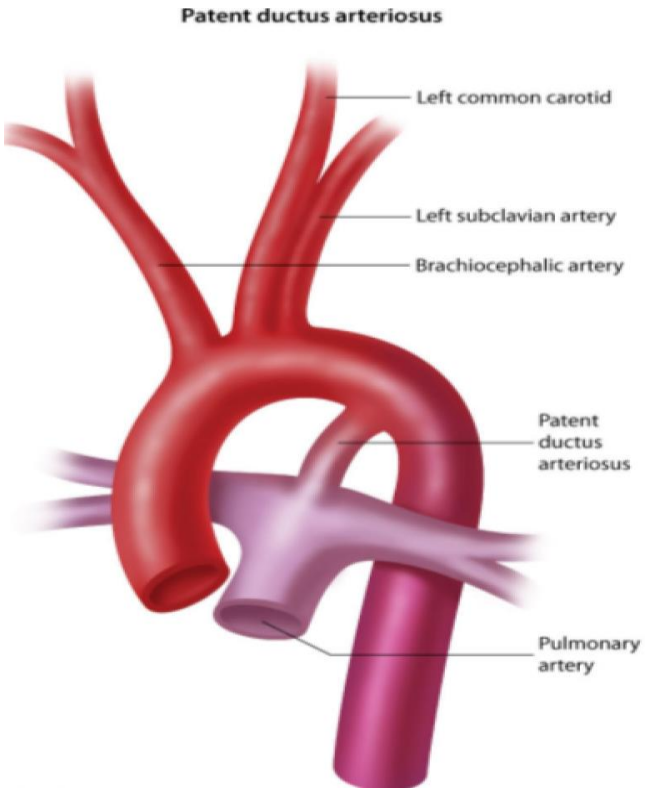

Interrupted left ventricular output

1. Coarctation of the Aorta:

- Classically divided into infantile and adult forms.

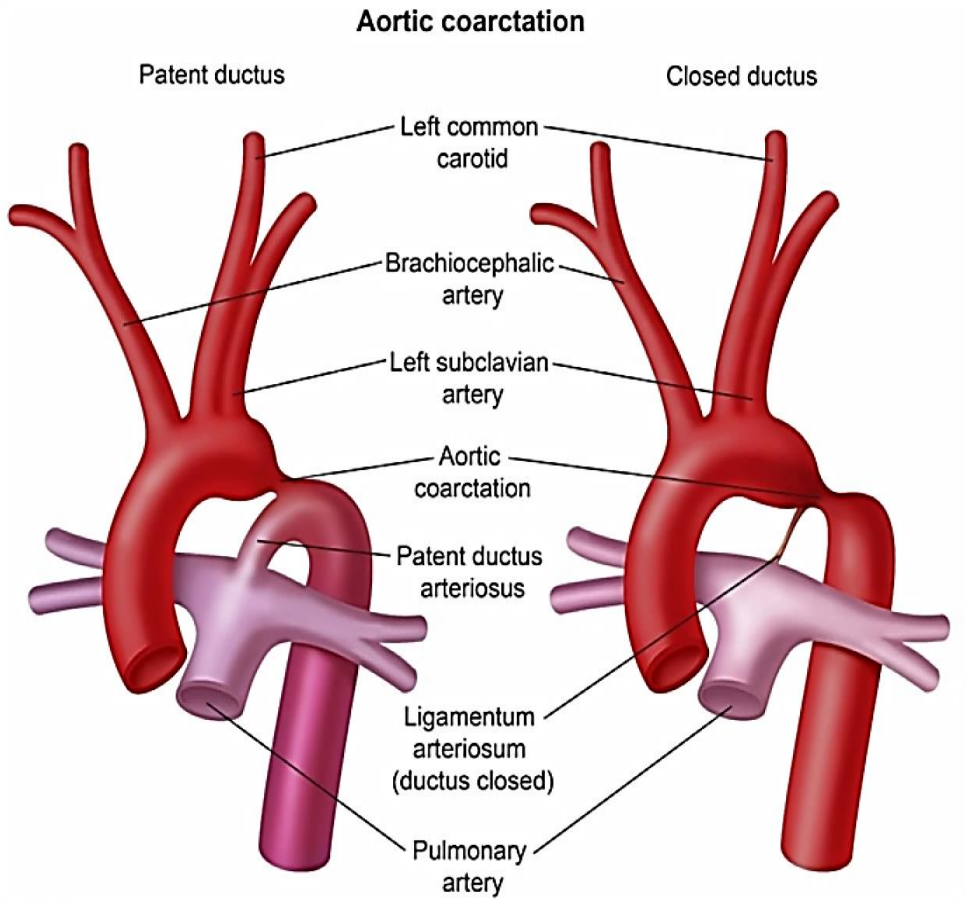

- Presentation:

A. Infantile form (Preductal):

- Coarctation of the aorta results from thickening of the tunica media near the junction of ductus arteriosus and the aortic arch. Luminal narrowing causes a mechanical obstruction to aortic blood flow.

- It is associated with a PDA; coarctation lies after (distal to) the aortic arch, but before (proximal to) the PDA.

- It has a frequent association with Turner syndrome. If the exam question mentions a short girl with webbed neck, shield chest, streak gonads, horseshoe kidneys, or shortened fourth metacarpal, think coarctation of the aorta.

- Presents as lower extremity exercise intolerance in infants.

- Severe aortic narrowing makes systemic blood flow dependent on the ductus arteriosus. As the ductus begins to close (normally around day 3 of life), infants may develop heart failure with tachypnea, poor feeding, fussiness, and lethargy. Patients are also at significant risk of shock, metabolic acidosis, and decreased renal perfusion (decreased urine output).

- Uncorrected cases often don't survive post-neonatal period.

B. Adult form (Postductal):

- Not associated with a PDA; coarctation lies after (distal to) the aortic arch and ligamentum arteriosum.

- Presents as hypertension in the upper extremities and hypotension with weak pulses in the lower extremities (brachial-femoral delay); classically discovered in adulthood.

- Headaches and epistaxis may be caused by hypertension in the arteries supplying the head and neck.

- The triad of upper body hypertension, diminished lower extremity pulses, and enlarged intercostal artery collaterals is typical of adult-type coarctation and is not seen in other congenital cardiovascular malformations.

- Patients with adult-type coarctation of the aorta commonly die of hypertension-associated complications, including left ventricular failure, ruptured dissecting aortic aneurysm, and intracranial hemorrhage.

- Patients should be initially evaluated with simultaneous palpation of the brachial and femoral pulses to assess for brachial-femoral delay, and bilateral upper and lower extremity blood pressure measurement to assess for blood pressure differential.

▪ Diagnostic Tests/Treatment:

- Chest x-ray usually demonstrates inferior notching of the third to eighth ribs. With age, Collateral circulation develops across the intercostal arteries; engorged arteries cause 'notching' of ribs on x-ray.

- A classic "3" sign created by indentation of the aorta with pre- and post- stenotic dilation may also be present.

- Cardiac catheterization is the most accurate test.

- Primary treatment is surgical resection of the narrowed segment and then balloon dilation if recurrent stenosis occurs.

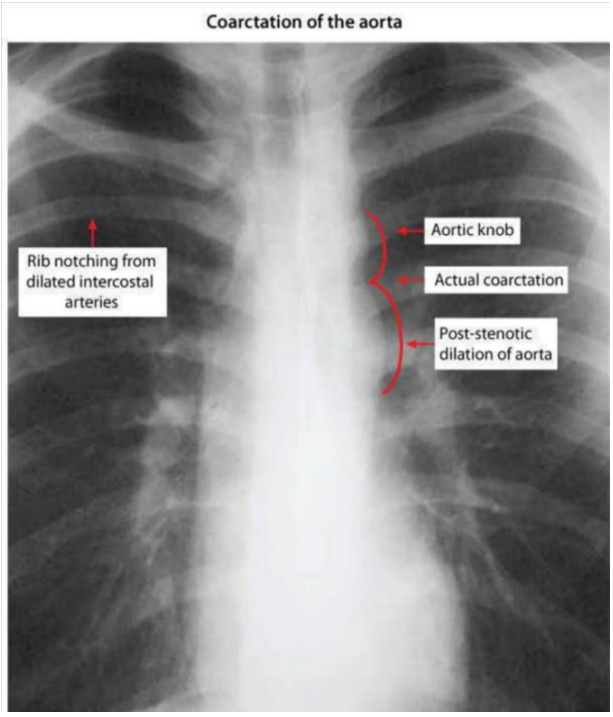

Coarctation of the aorta	
Etiology	• Congenital • Acquired (rare) (eg, Takayasu arteritis)

Clinical features	• Upper body
	  ◦ Well developed
	  ◦ Hypertension (headaches, epistaxis)
	• Lower extremities
	  ◦ Underdeveloped
	  ◦ Claudication
	• Brachial-femoral pulse delay
	• Upper & lower extremity blood pressure differential
	• Left interscapular systolic or continuous murmur

Diagnostic studies	• ECG: Left ventricular hypertrophy
	• Chest x-ray
	  ◦ Inferior notching of the 3rd to 8th ribs
	  ◦ "3" sign due to aortic indentation
	• Echocardiography: Diagnostic confirmation

Treatment	• Balloon angioplasty ± stent placement • Surgery

2. Hypoplastic Left Heart Syndrome:

- This is a syndrome consisting of left ventricular hypoplasia, mitral valve atresia, and aortic valve lesions.

- The neonate is reliant on blood flowing through an atrial septal defect to mix oxygenated and deoxygenated blood, and on a patent ductus arteriosus to allow blood to reach the aorta and the systemic circulation via the right ventricle.

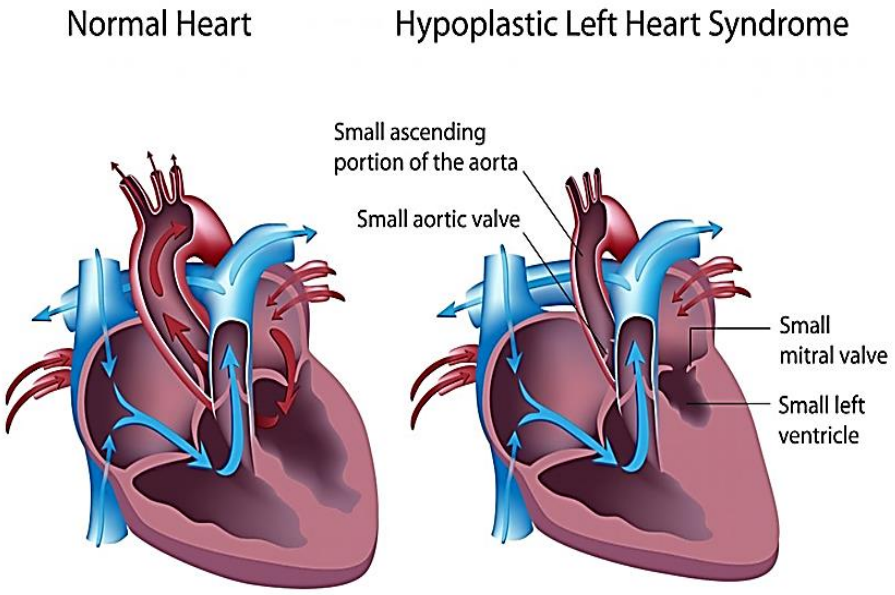

- Presentation:

- Absent pulses with a single S_2.

- Gray rather than bluish cyanosis.

- Diagnostic Tests/Treatment:

- Chest x-ray will show a globular-shaped heart with pulmonary edema.

- Echocardiogram is the most accurate diagnostic test.

- They require prostaglandin E1 to keep the ductus open.

- The only therapy is 3 separate surgeries or a heart transplant. Each surgery carries an extremely high mortality.

Congenital heart disease		
Cause	**Clinical features**	**Examples**
Left-to-right shunting	• Tachypnea • Poor weight gain • Sweating with feeds	• Ventricular septal defect • Atrial septal defect • Isolated patent ductus arteriosus
Right-to-left shunting	• Cyanosis	• Transposition of the great vessels • Tetralogy of Fallot • Tricuspid atresia • Anomalous pulmonary venous return • Truncus arteriosus
Interrupted left ventricular output	• Pallor or shock • Severe acidosis	• Coarctation of the aorta • Hypoplastic left heart syndrome

Rheumatic Fever

- Rheumatic fever is an autoimmune disease resulting from untreated pharyngeal streptococcal infection, caused by cross-reactions between streptococcal antigens and the antigens on joint and heart tissue.

- Rheumatic heart disease (RHD) is a possible long-term consequence of rheumatic fever. While RHD can involve any heart valve, mitral stenosis is the most common outcome.

- The Jones criteria establish the diagnosis of rheumatic fever. A patient is positive for rheumatic fever when either 2 of the major criteria or 1 major criterion plus 2 minor criteria are present, along with evidence of streptococcal infection (elevated or rising antistreptolysin O titer or DNase).

- The major criteria include carditis, migratory polyarthritis, Sydenham chorea, subcutaneous nodules, and erythema marginatum.

Acute rheumatic fever		
Epidemiology	• Peak incidence: age 5-15 • Twice as common in girls	
Clinical features	**Major**	• **J**oints (migratory arthritis) • ♥ (Carditis) • **N**odules (subcutaneous) • **E**rythema marginatum • **S**ydenham chorea
	Minor	• Fever • Arthralgias • Elevated ESR/CRP • Prolonged PR interval
Late sequelae	Mitral regurgitation/stenosis	
Prevention	Penicillin for **group A streptococcal** (*Streptococcus pyogenes*) pharyngitis	

CRP = C-reactive protein; **ESR** = erythrocyte sedimentation rate.



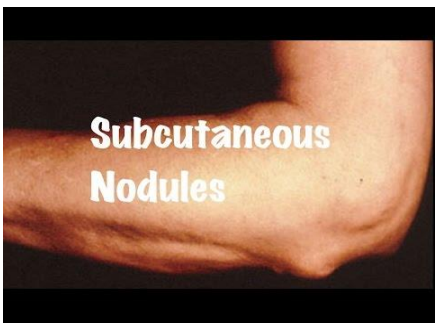

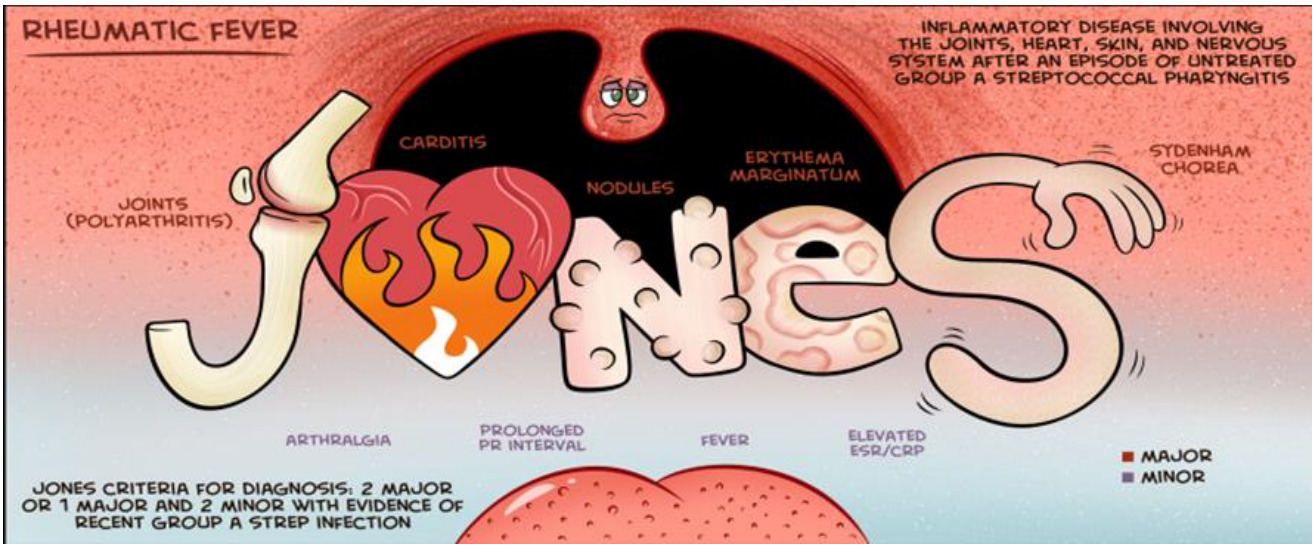

- Treatment:

- All patients with an initial diagnosis of rheumatic fever should be treated with antibiotic therapy to eradicate GAS regardless of the presence or absence of pharyngitis at the time of diagnosis.

- Patients with mitral valve disease from rheumatic fever should receive chronic penicillin therapy to reduce the risk of group A strep pharyngitis recurrence and progression of rheumatic heart disease. Control inflammation with NSAIDs or steroids.

- The preferred regimen is administration of intramuscular benzathine penicillin G every 4 weeks. The total duration of antibiotic prophylaxis depends on the severity of the disease (Table).

Antibiotic prophylaxis for secondary prevention of rheumatic fever

Severity	Duration of therapy following last attack
Uncomplicated rheumatic fever	5 years or until age 21*
With carditis but no valvular disease	10 years or until age 21*
With carditis & valvular disease	10 years or until age 40*

*Whichever duration is longer. Intramuscular penicillin G benzathine every 3-4 weeks is preferred.

❖ N.B:

1. Ebstein's Anomaly is characterized by displacement of tricuspid valve leaflets downward into RV, artificially "atrializing" the ventricle.

- Associated with tricuspid regurgitation and right HF.
- Can be caused by lithium exposure in utero.

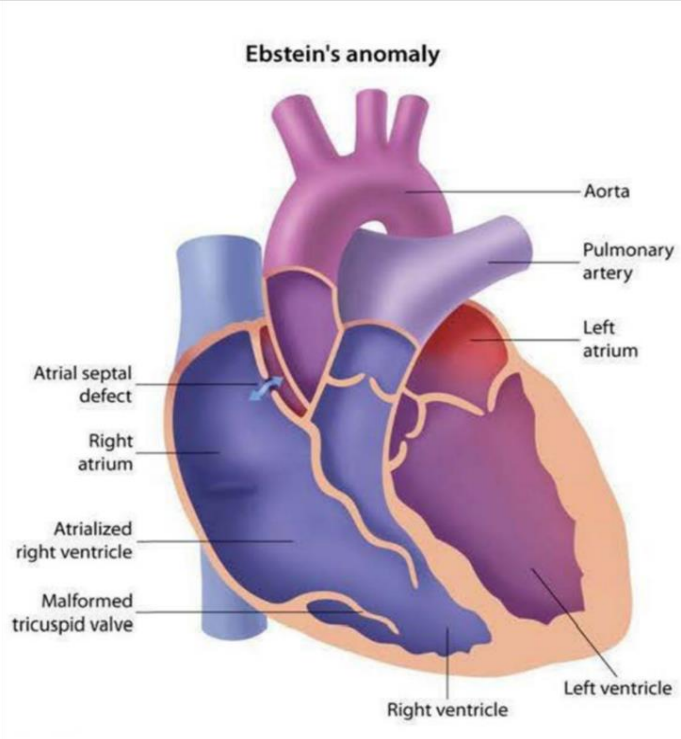

2. Complete atrioventricular septal defect (CAVSD) is the most common congenital heart defect in patients with Down syndrome.

- Failure of the endocardial cushions to merge results in both ventricular septal defect (VSD) and atrial septal defect (ASD) as well as a common atrioventricular valve due to poor mitral and tricuspid valve development.

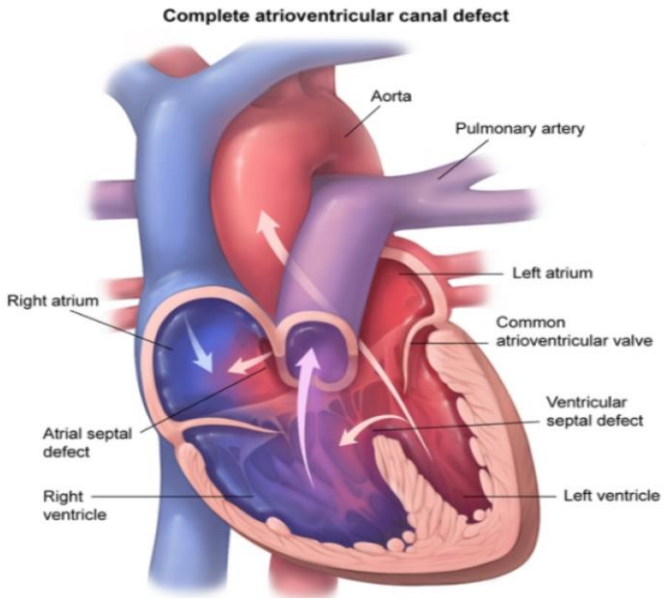

3. Viruses are the most common cause of pediatric myocarditis (especially coxsackievirus B and adenovirus, are the most common offending triggers), which presents with fever, lethargy, and signs of heart failure after a viral prodrome.

- The pathogenesis is thought to be direct viral injury and autoimmune inflammation that leads to myocyte necrosis with subsequent impairment of systolic and diastolic function.
- Treatment includes supportive measures such as diuretics and inotropes. Affected children should be monitored in the intensive care unit due to the risk of shock and fatal arrhythmias.

Viral myocarditis	
Etiology	• Coxsackievirus B, adenovirus
Clinical features	• Viral prodrome • Heart failure: Respiratory distress, murmur, hepatomegaly
Diagnosis	• Chest x-ray: Cardiomegaly, pulmonary edema • ECG: Sinus tachycardia • Echocardiogram: Decreased ejection fraction • Biopsy (gold standard): Inflammation, necrosis
Treatment	• Supportive (eg, diuretics, inotropes) • Intravenous immunoglobulin

4. Most children will have an audible murmur at some point in their lives; the vast majority of these are benign.

- These murmurs are also described as innocent, functional, or physiologic and result from blood flow through a structurally normal heart.
- A Key distinguishing feature from a benign versus a pathologic murmur is the change in intensity in response to positional changes. Maneuvers that decrease venous blood return to the heart (standing, Valsalva maneuvers) typically reduce the intensity of innocent murmurs
- The intensity is typically grade I or II and decreases with standing.
- Management consists of observation and reassurance.

Kawasaki Disease

- Kawasaki disease is necrotizing febrile vasculitis of medium-sized vessels that primarily affects the coronary blood vessels.
- The incidence of KD is greatest among children of East Asian ethnicity < 5 years.
- Diagnosis is based on clinical presentation. The patient should have fever for >5 consecutive days as well as 4 of the following 5 findings:

- Conjunctivitis: bilateral, nonexudative, spares limbus.
- Rash.
- Cervical Adenopathy: >1.5 cm, usually unilateral, least consistent finding (present in <25%-50% of patients).
- Oral mucosal changes: erythema, fissured lips, "Strawberry tongue".
- Hands and foot changes: erythema, edema, desquamation of the hands and feet, usually the last manifestation.

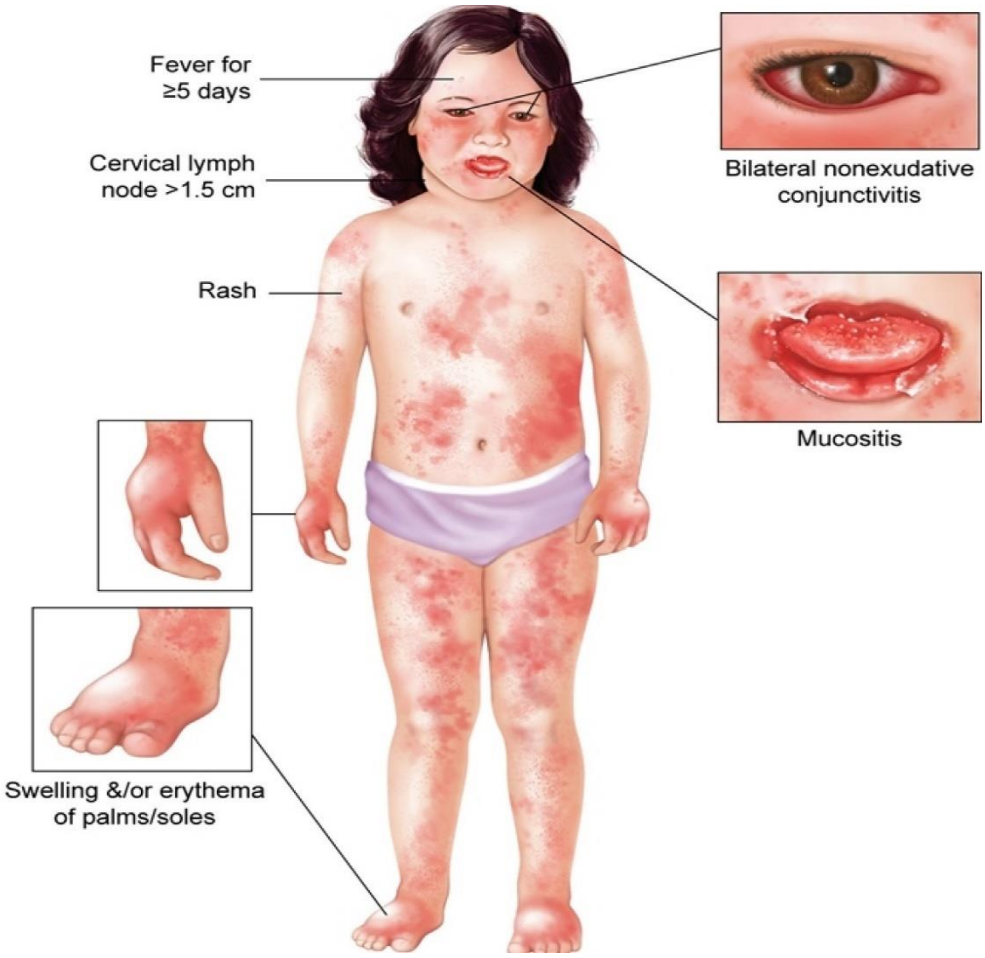

- In patients with atypical presentation, supporting laboratory evidence can include the following:

- Elevated C-reactive protein and erythrocyte sedimentation rate.
- Leukocytosis with neutrophilia (as opposed to lymphocytosis in viral infections).
- Reactive thrombocytosis.
- Sterile pyuria on urinalysis.

- Although the systemic inflammation in Kawasaki disease (KD) typically self-resolves in about 12 days without intervention, untreated patients are at risk for life-threatening cardiovascular sequelae, especially coronary artery aneurysms.

- The dilated arteries are prone to thrombotic occlusion and consequent myocardial ischemia and death.

- Echocardiography should be performed at the time of diagnosis and repeated 6-8 weeks later to look for changes that may require closer monitoring and prolonged therapy.

- Treatment:

- Give IVIG and aspirin as soon as the diagnosis is made to prevent the development of coronary artery aneurysms, the most important complication of the disease. Although the mechanism of action of IVIG is unknown, this treatment regimen reduces the risk of coronary artery aneurysms.

- Reye syndrome is a rare but life-threatening hepatic encephalopathy that can develop in children using aspirin during influenza or varicella infections. However, aspirin is the mainstay of therapy for preventing coronary thrombosis, and caregivers should be warned about this possibility.

Kawasaki disease	
Epidemiology	• 90% age <5 • Increased incidence in East Asian ethnicity
Diagnostic criteria	Fever ≥5 days plus ≥4 of the following findings: • Conjunctivitis: bilateral, nonexudative • Mucositis: injected/fissured lips or pharynx, "strawberry tongue" • Cervical lymphadenopathy: ≥1 lymph node >1.5 cm in diameter • Rash: erythematous, polymorphous, generalized; perineal erythema & desquamation; morbilliform (trunk, extremities) • Erythema & edema of hands/feet
Treatment	Aspirin plus intravenous immunoglobulin
Complications	• Coronary artery aneurysms • Myocardial infarction & ischemia

CHAPTER 3

Pediatric Gastroentrology

Gastroenterology

Esophageal Atresia

- In esophageal atresia, the esophagus ends blindly.

- In nearly 90% of cases it communicates with the trachea through a fistula known as a tracheoesophageal fistula (TEF). If you see recurrent aspiration pneumonia, consider tracheoesophageal fistula.

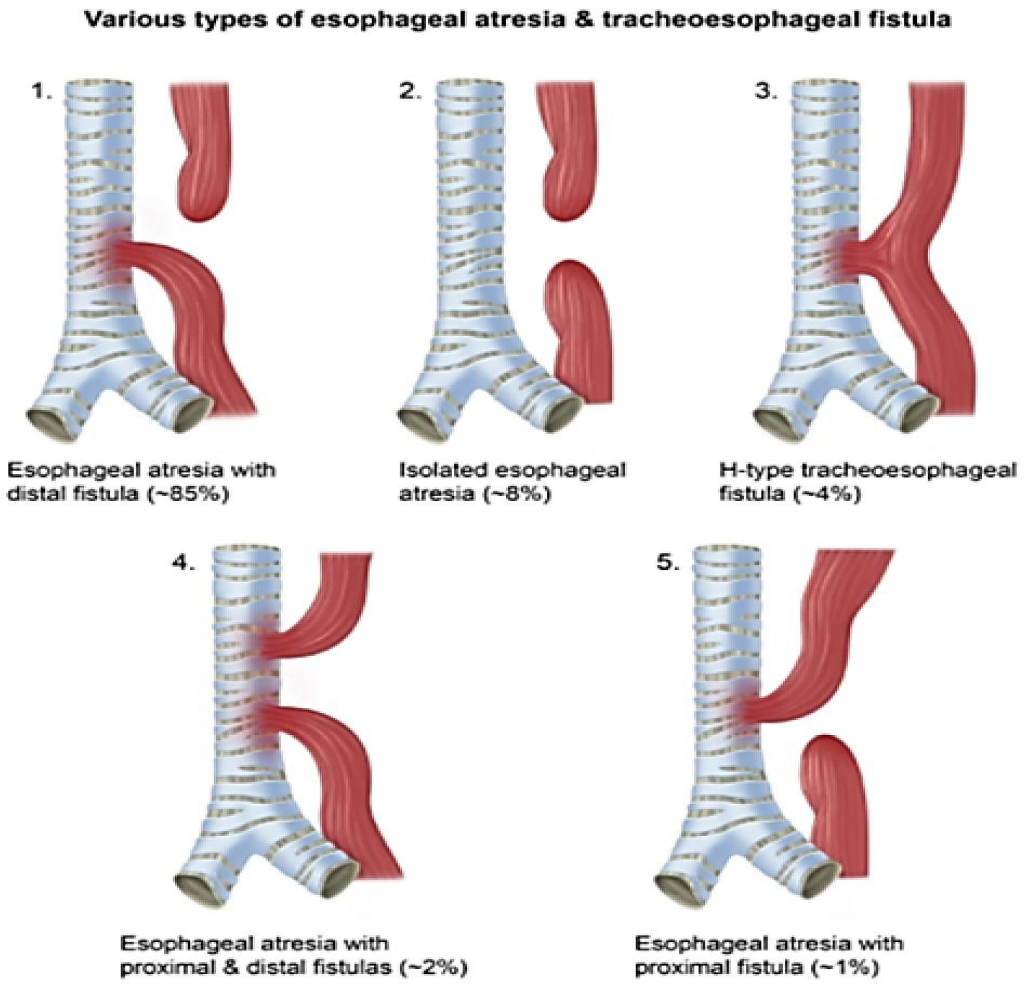

- <u>Presentation:</u>

- The child will typically exhibit "vomiting with first feeding" or choking/coughing and cyanosis due to the TEF.

- Recurrent aspiration pneumonia is due to gastric fluid can reflux into the distal esophagus through the fistula and into the trachea and lungs.

- There will be a history of possible polyhydramnios as the affected fetus cannot swallow amniotic fluid.

- Diagnostic Tests:

- A gastric air bubble and esophageal air bubble can be seen on chest X-ray (CXR). The tracheoesophageal fistula permits air entry into the gastrointestinal tract, and the stomach and intestines can become quite distended with each breath, especially in the ventilated patient.

- Coiling of the NG tube seen on CXR and an inability to pass it into the stomach are diagnostic.

- CT or esophagram can also be used.

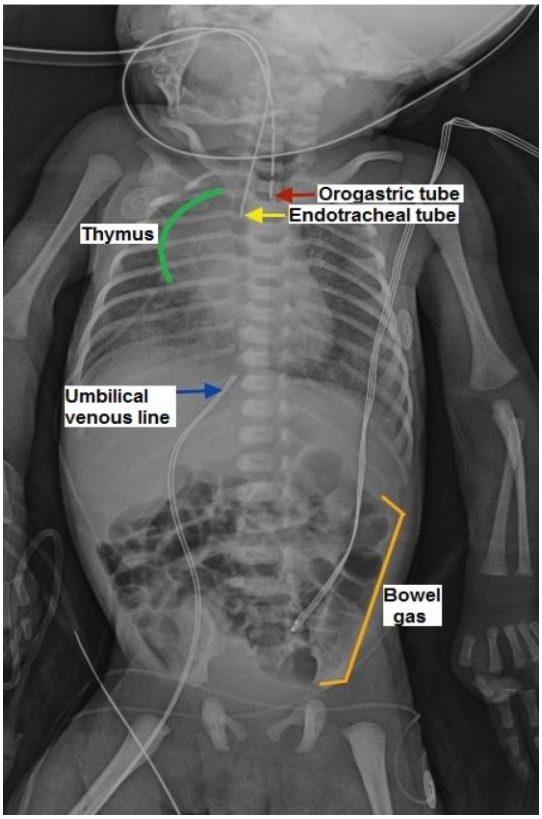

- Treatment:

- Surgical repair must be done in 2 steps to correct the congenital anomaly.

- Fluid resuscitation before surgery must be done to prevent dehydration of the infant.

- Antibiotic coverage for anaerobes must also be considered due to high risk of lung abscess formation secondary to aspiration.

❖ N.B:

- As many as half of patients with tracheal and esophageal defects have additional anomalies. Workup for VACTERL (Vertebral defects, Anal atresia, Cardiac defects, Tracheoesophageal fistula, Renal defects, Limb defects) association should be considered.

Pyloric Stenosis

- A hypertrophic pyloric sphincter prevents proper passage of GI contents from the stomach into the duodenum.

- The most common cause is idiopathic but first-born boys are at significantly higher risk.

- Formula feeding is also thought to cause gradual hypertrophy of the pylorus until symptom onset at age 3-5 weeks. Compared to breastfed infants, formula-fed infants have slower gastric emptying and consume more volume in less time. The increased gastric burden may stimulate growth of the pylorus muscle.

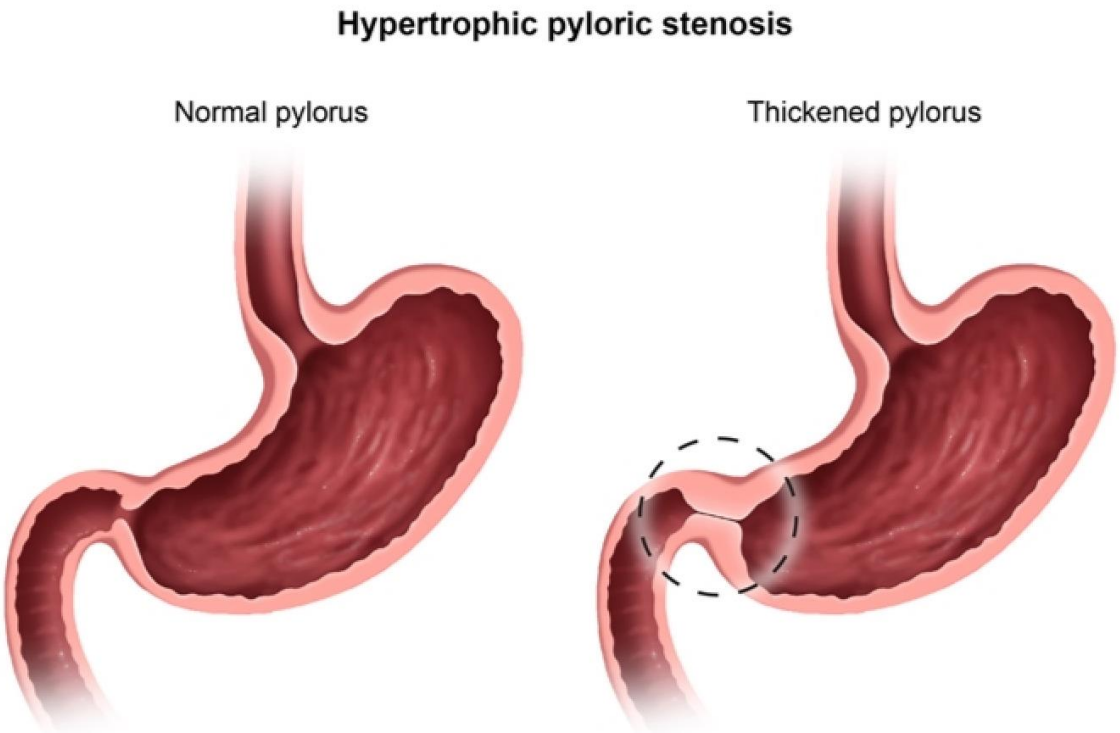

- <u>Presentation:</u>

- Hypertrophy of the pylorus is not commonly found at birth but rather becomes most pronounced by the first month of life. It can present as late as 6 months after birth.

- Nonbilious (obstruction is proximal to the bile duct) projectile vomiting is the hallmark feature followed by hunger ("hungry vomiter").

- Olive sign, which delineates a palpable mass the size of an olive felt in the epigastric region, is highly associated with this condition.

- Auscultation will reveal a succussion splash, which is the sound of stomach contents slapping into the pylorus like waves on a beach.

- Metabolic imbalance demonstrates a hypochloremic, hypokalemic metabolic alkalosis due to the vast loss of hydrogen ions in the vomitus. The potassium loss also worsens from aldosterone release in response to hypovolemia.

- Hypovolemia activates the renin-angiotensin-aldosterone system in attempt to retain water at the expense of hydrogen ions. Some potassium is also lost in the emesis, and hypokalemia is exacerbated as the kidneys secrete potassium in response to aldosterone. The respiratory system responds with compensatory hypoventilation, resulting in secondary respiratory acidosis.

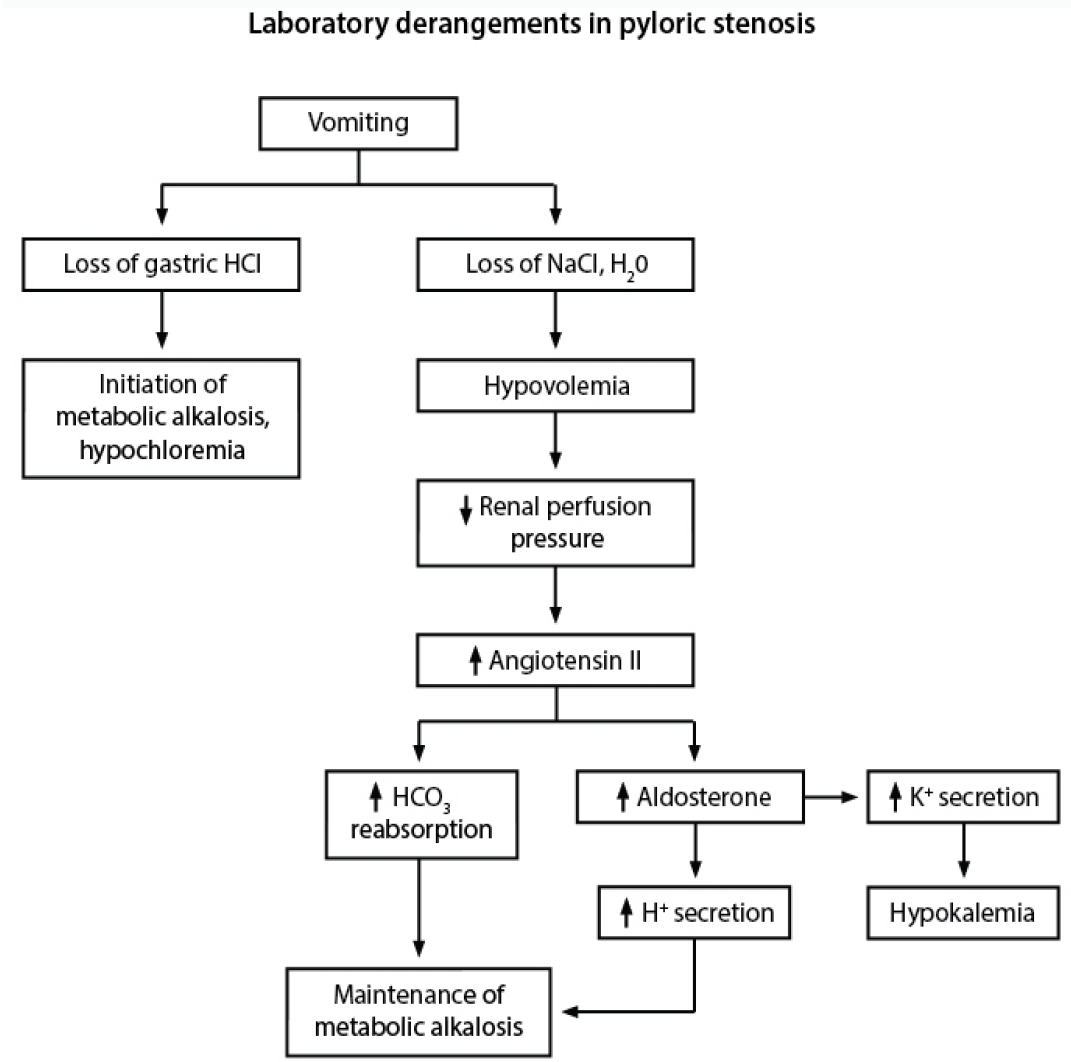

- Diagnostic Tests:

- The best initial test is an abdominal ultrasound that will show a thickened pyloric sphincter.

- The most accurate test is an upper GI series.

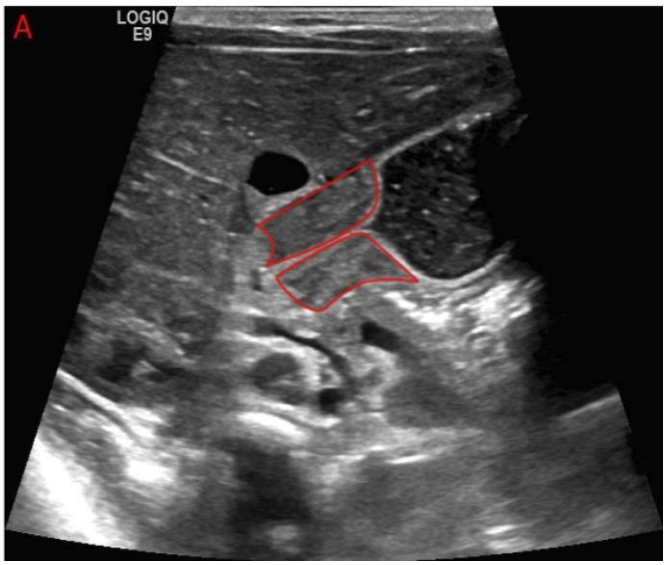

- Treatment:

- Replace lost volume with IV fluids; replace lost electrolytes, specifically potassium, as the closure of the anion gap is crucial.

- Although pyloromyotomy is the treatment of choice, infants with signs of dehydration or laboratory abnormalities should be admitted for intravenous rehydration and normalization of electrolytes prior to definitive surgical treatment to decrease the risk of postoperative apnea.

Infantile hypertrophic pyloric stenosis	
Risk factors	• First-born boy • Erythromycin • Bottle feeding
Presentation	• Projectile nonbilious emesis • Poor weight gain • Dehydration • Olive-shaped abdominal mass
Diagnostic studies	• Hypochloremic metabolic alkalosis • Thickened pylorus on abdominal ultrasound
Treatment	• Intravenous rehydration • Pyloromyotomy

Hirschsprung Disease

- Hirschsprung disease (congenital aganglionic megacolon) is a congenital lack of innervation of the distal bowel by the Auerbach plexus.

- The disorder results from failed development of the enteric nervous system of a variable portion of the distal gut and most commonly involves the rectosigmoid. The affected colonic segment cannot relax and therefore is chronically contracted.

- Neural crest cells start migrating to the intestinal wall very early during embryonic development. They give rise to ganglion cells of the submucosal (Meissner) and myenteric (Auerbach) plexi of the bowel wall.

- The arrest of migration of neural crest cells causes Hirschsprung disease, in which a segment of colon is deprived of ganglion cells. Since neural crest cells migrate caudally, the rectum is always involved in Hirschsprung disease.

- There is frequent association with Down syndrome, and it is more common in boys than in girls (approximately 4:1).

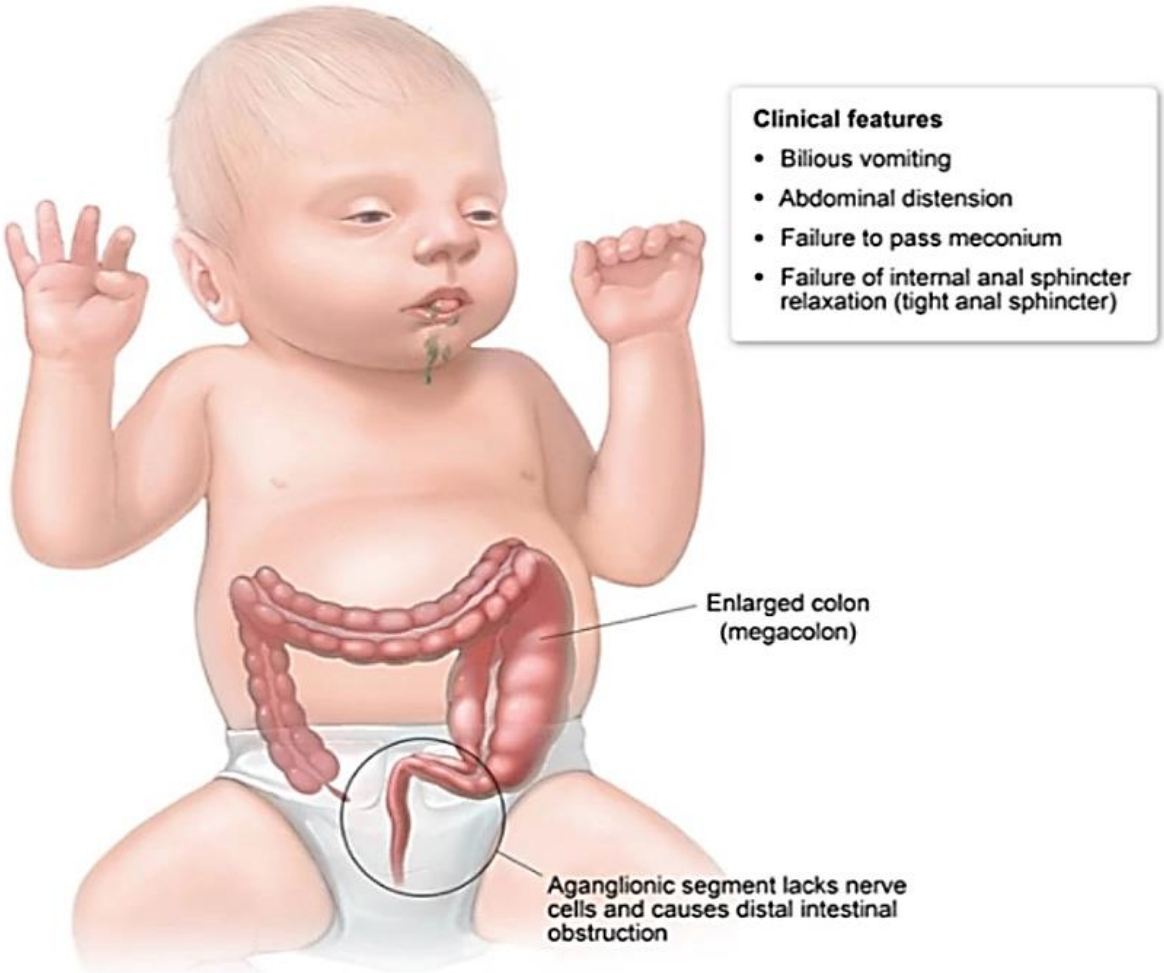

- Presentation:

- Of unaffected infants, 90% pass first meconium within 24 hours, whereas children with Hirschsprung do not pass meconium for over 48 hours or fail to pass meconium at all.

- Extreme constipation is followed by large bowel obstruction (poor feeding, abdominal distension, absent air in the rectum).

- Rectal examination can produce an explosive expulsion of gas and stool ("squirt sign") from temporary relief from the obstruction.

- Diagnostic Tests/Treatment:

- Plain x-rays show distended bowel loops with a lack of air in the rectum.

- If there is no evidence of perforation (free air under the diaphragm), contrast enema can potentially delineate the level of obstruction. A transition zone may be seen between the narrowed aganglionic segment and the normally innervated, dilated colon (megacolon).

- Manometry will show high pressures in the anal sphincter.

- The mainstay of diagnosis is a full thickness biopsy that reveals a lack of ganglionic cells in the submucosa.

- A 3-stage surgery procedure is curative.

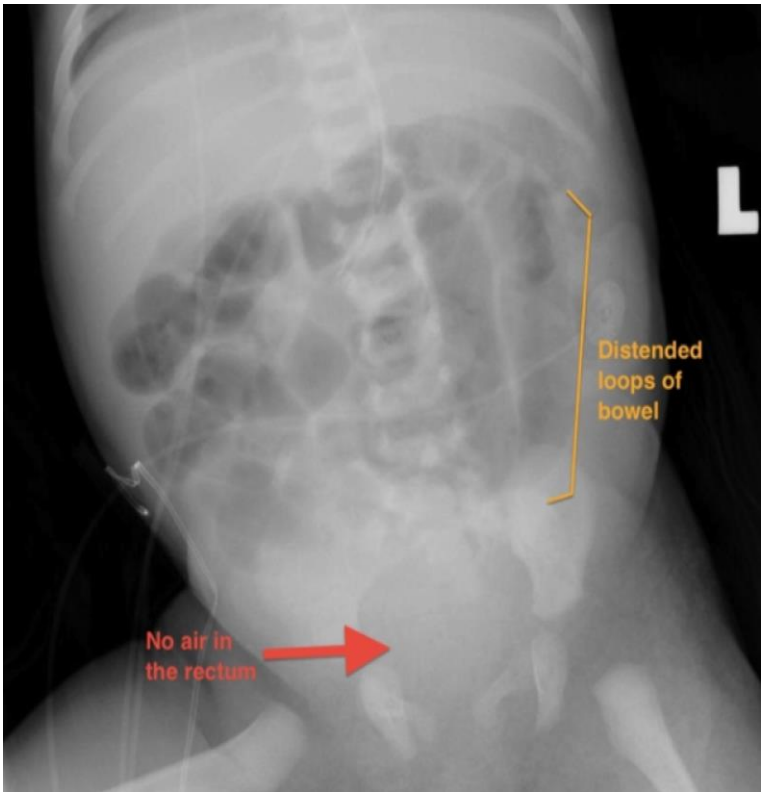

❖ N.B:

- Meconium ileus and Hirschsprung disease (congenital aganglionic megacolon) should be considered in any neonate with delayed passage of meconium as 99% of healthy, full-term infants pass stool within 48 hours of birth.
- These 2 conditions have overlapping clinical features but can usually be differentiated by the level of intestinal obstruction and meconium consistency.
- Meconium ileus is virtually diagnostic for cystic fibrosis (CF). Although only 20% of patients with CF develop meconium ileus almost all newborns with meconium ileus have CF.
- A mutation in the CF transmembrane conductance regulator gene results in abnormal chloride and sodium transport and thick, viscous secretions in multiple organs. Thick, inspissated meconium is difficult to propel, resulting in obstruction at the level of the ileum and a narrow, underdeveloped colon (microcolon) compared to more typical rectosigmoid obstruction seen in infants with Hirschsprung disease.
- Administration of hyperosmolar enema (Gastrografin) can potentially break up the inspissated meconium and dissolve the obstruction. Surgery is required if therapeutic enema is unsuccessful.
- In contrast to Hirschsprung disease, rectal examination would not relieve any meconium due to its inspissated consistency. Meconium ileus is not associated with Down syndrome.

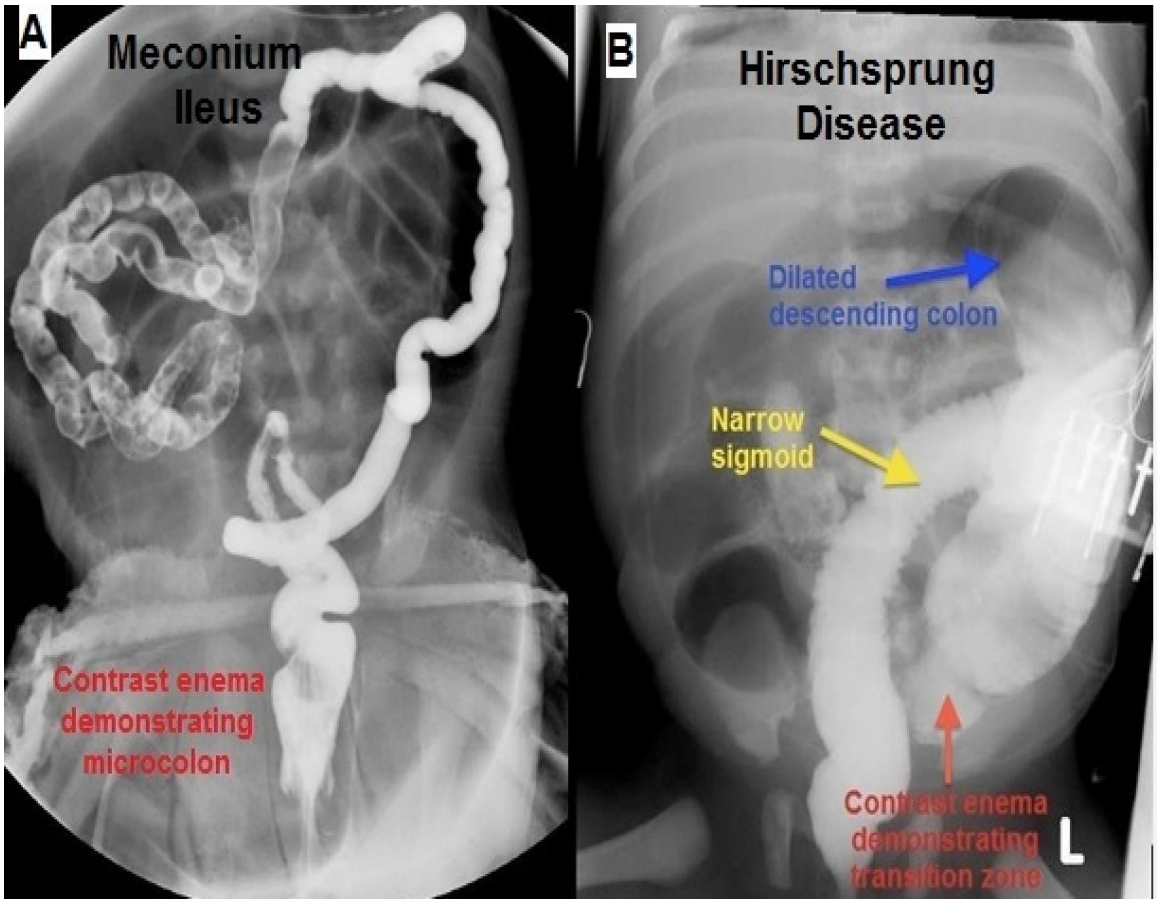

Differentiating features of Hirschsprung disease and meconium ileus		
	Hirschsprung disease	**Meconium ileus**
Associated disorder	Down syndrome	Cystic fibrosis
Typical level of obstruction	Rectosigmoid	Ileum
Meconium consistency	Normal	Inspissated
"Squirt sign"	Positive	Negative

Imperforate Anus

- With imperforate anus, the opening to the anus is missing and the rectum ends in a blind pouch with conservation of the sphincter. The cause is unknown but has a high association with Down syndrome.

- Imperforate anus is one of the components of VACTERL syndrome:

- V: Vertebral anomalies.
- A: Anal atresia.
- C: Cardiovascular anomalies.
- T: Tracheoesophageal fistula.
- E: Esophageal atresia.
- R: Renal anomalies.
- L: Limb anomalies.

- Presentation/Diagnostic Tests/Treatment:

- Complete failure to pass meconium is diagnostic. A physical exam will reveal no anus. Surgery is curative.

- The most common wrong answers for diagnostic testing are barium study and rectal manometry.



Duodenal Atresia

- Duodenal atresia (DA) is a lack or absence of apoptosis (programmed cell death) that leads to improper canalization of the lumen of the duodenum.

- Duodenal atresia is associated with an annular pancreas and Down syndrome.

- Prenatal ultrasound will show polyhydramnios due to inability to swallow and remove amniotic fluid.

- Presentation/Diagnostic Tests:

- Duodenal atresia is typically characterized by the onset of bilious vomiting within 12 hours of birth.

- Chest x-ray will show air trapped in the stomach and the first portion of the duodenum ("double bubble sign") and no distal intestinal gas due to inability for gas to pass the duodenum.

- Treatment:

- Replace lost volume with IV fluids, taking special care to replace lost electrolytes. Potassium is often low from vomiting. NGT must be used to decompress the bowel.

- Surgical duodenostomy is the most common surgical procedure and definitive treatment.

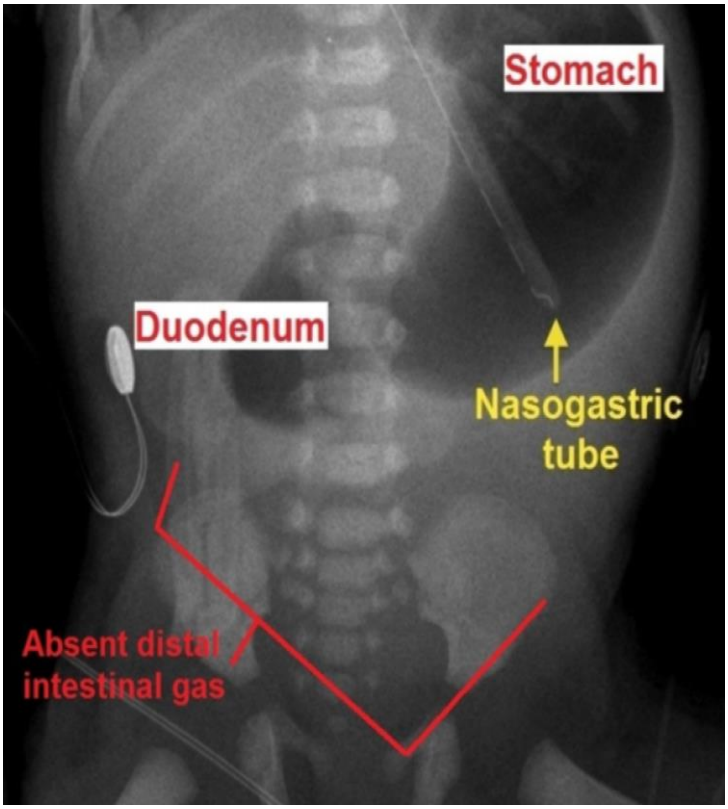

Jejunal atresia

- Intestinal atresia can occur anywhere along the gastrointestinal tract.

- Atresia of the jejunum or ileum is thought to occur due to a vascular accident in utero that causes necrosis and resorption of the fetal intestine, sealing off and leaving behind blind proximal and distal ends of intestine.

- Risk factors include poor fetal gut perfusion from maternal use of vasoconstrictive medications or drugs such as cocaine and tobacco.

- In contrast to duodenal atresia, jejunal and ileal atresia are not associated with chromosomal abnormalities.

- Diagnosis:

- The presence of the "triple bubble" sign and gasless colon on abdominal x-ray reflects gas trapping in the stomach, duodenum, and jejunum.

- Treatment:

- Treatment should be focused initially on resuscitation and stabilization of the patient, followed by surgical correction.

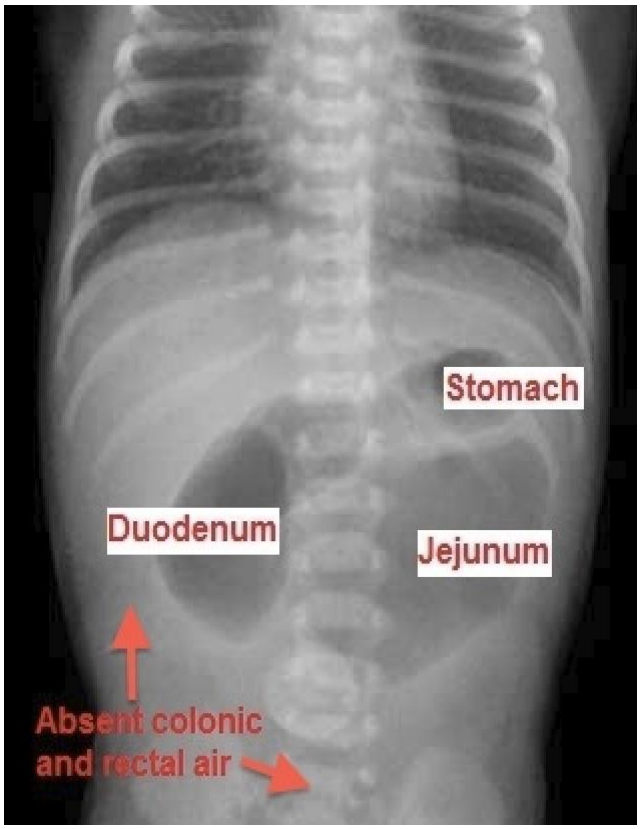

Volvulus

- A volvulus is a bowel obstruction in which a loop of bowel has twisted on itself abnormally.
- In children, volvulus occurs in the midgut, with the majority being in the ileum.
- The primary predisposing factor for volvulus in children is malrotation of the midgut during early fetal development.

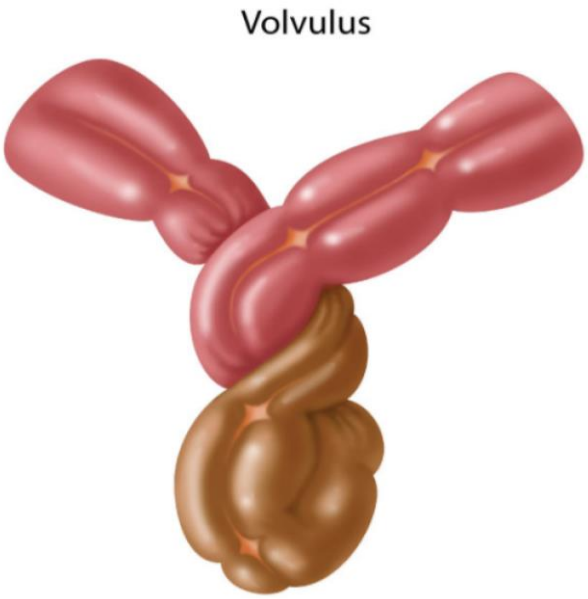

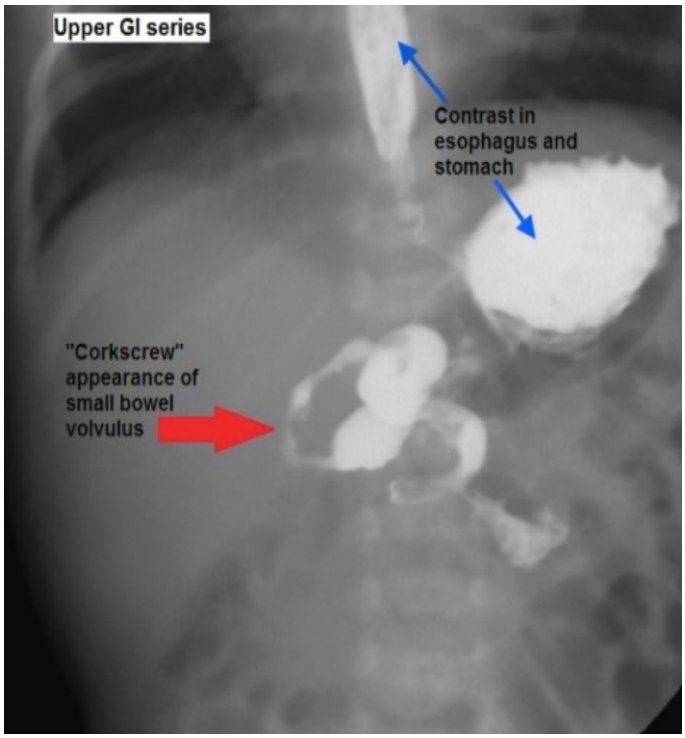

- <u>Presentation/Diagnostic Tests:</u>

- Midgut volvulus classically presents in a neonate (age <1 month) with bilious vomiting.
- Initially, the abdomen is soft and not distended, but ischemia of the twisted bowel can cause bloody stools, abdominal distension, bowel perforation, and peritonitis.
- An x-ray is generally the first step to rule out pneumoperitoneum, which would reflect intestinal perforation and immediate need for emergency surgery.
- If there is no evidence of free air and the bowel gas pattern is not suggestive of duodenal atresia ("double bubble") or distal obstruction (dilated loops of bowel), then an upper gastrointestinal (GI) series (barium swallow) should be performed.
- An upper GI series is the fastest and most accurate method of diagnosing malrotation with midgut volvulus. The finding of the Ligament of Treitz on the right side of the abdomen reflects malrotation while contrast in a "corkscrew" pattern indicates volvulus.

- Treatment:

- Surgical or endoscopic untwisting is emergently needed; bowel necrosis with perforation can lead to life-threatening sepsis.

- The best initial therapy is endoscopic decompression, and the most effective therapy (and if the endoscopy fails) is surgical decompression.

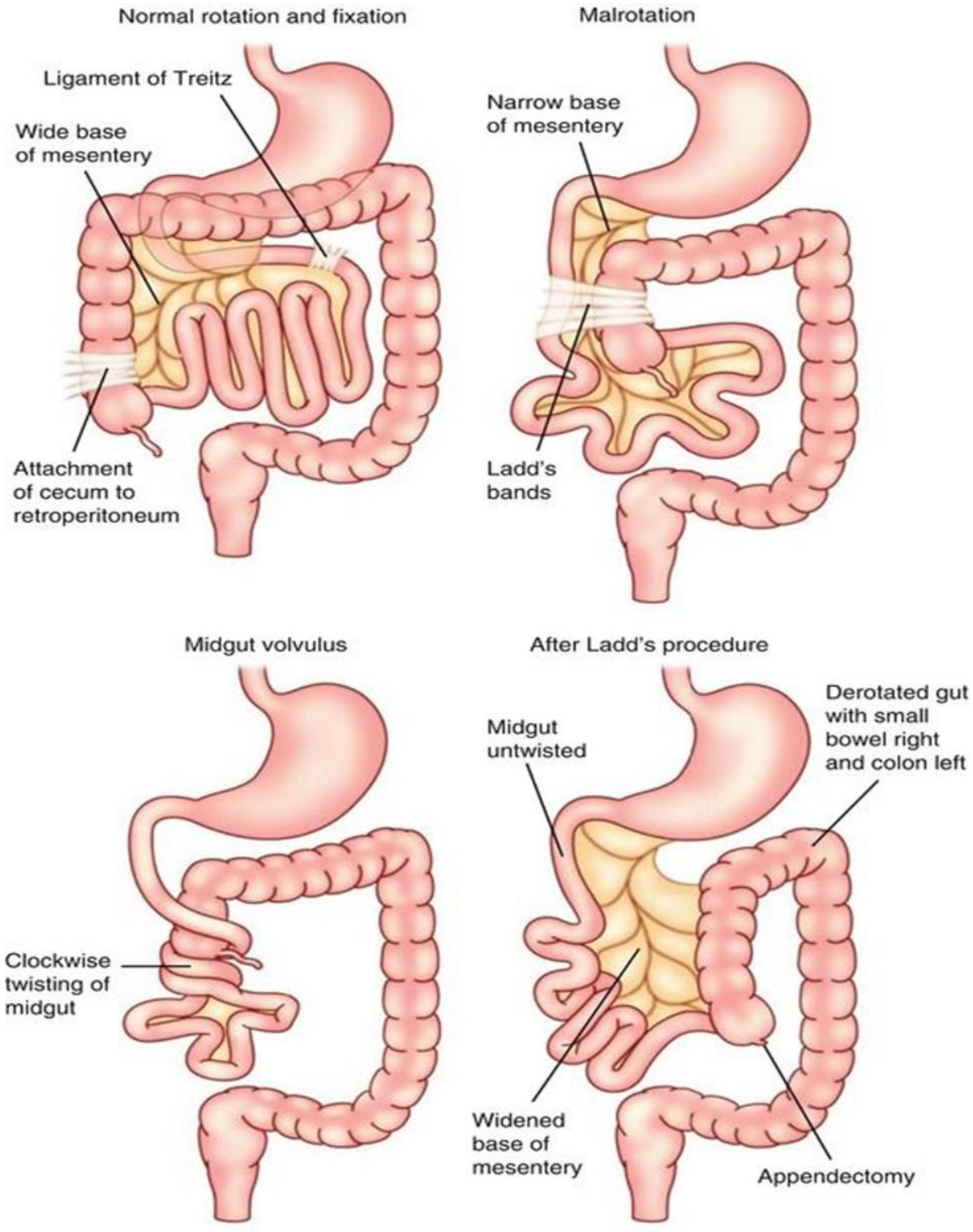

❖ N.B:

- Bilious emesis in the neonate is an ominous sign of intestinal obstruction and requires immediate workup.
- The evaluation of clinically stable neonates with bilious emesis begins with cessation of enteral feeds, nasogastric (NG) tube decompression, and intravenous (IV) fluids.
- An x-ray is generally the first step to rule out pneumoperitoneum, which would reflect intestinal perforation and immediate need for emergency surgery.
- Rarely, the diagnosis may be suspected if the NG tube terminates in the abnormally placed duodenum, but x-ray is usually nonspecific for midgut volvulus.
- If there is no evidence of free air and the bowel gas pattern is not suggestive of duodenal atresia ("double bubble") or distal obstruction (dilated loops of bowel), then an upper gastrointestinal (GI) series (barium swallow) should be performed.
- An upper GI series is the fastest and most accurate method of diagnosing malrotation with midgut volvulus. The finding of the Ligament of Treitz on the right side of the abdomen reflects malrotation while contrast in a "corkscrew" pattern indicates volvulus.



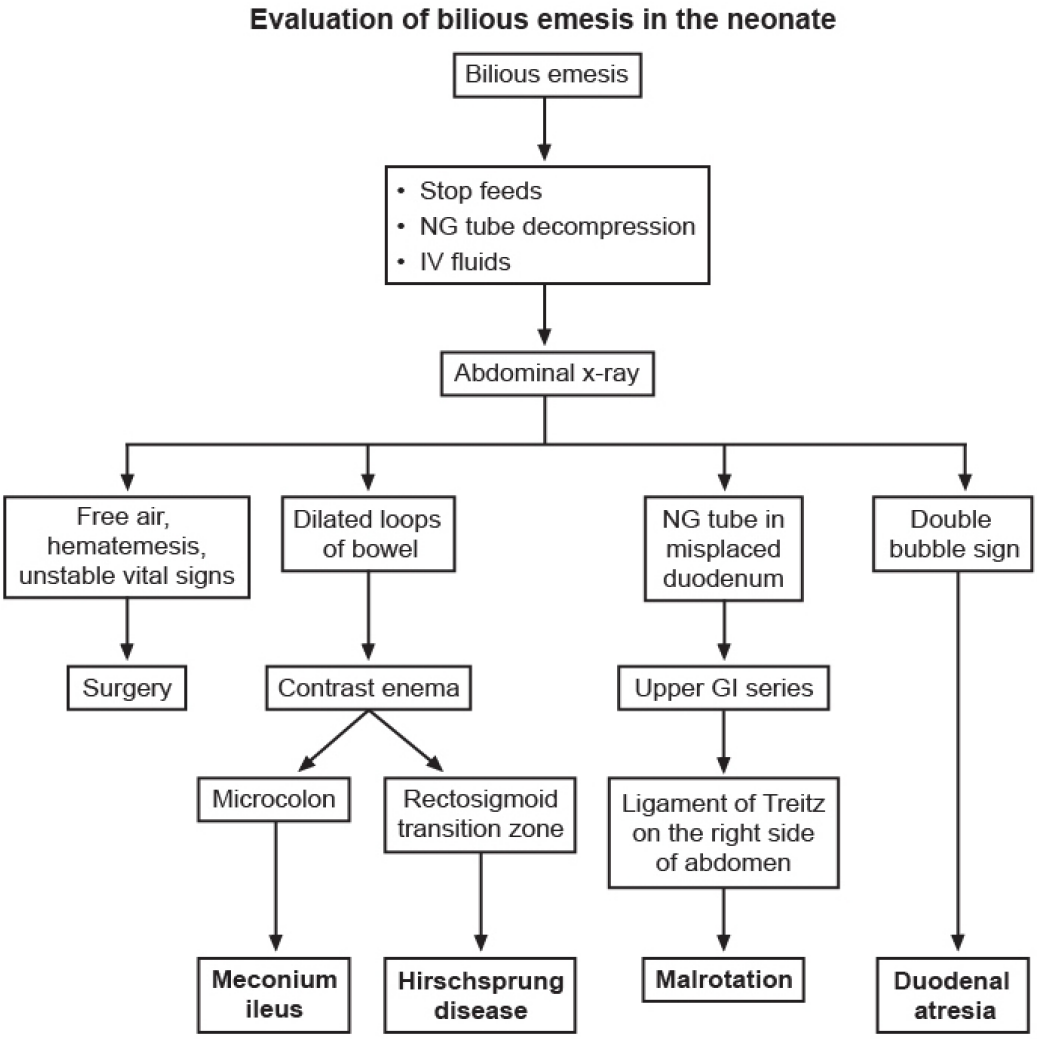

Intussusception

- Intussusception is a condition in which part of the bowel telescopes into another segment of bowel distal to it.

- It can be caused by a polyp, hard stool, he hematomas (Henoch-Schonlein purpura), or lymphoma, or can even have a viral origin (thought to cause hypertrophy of the Peyer patches in the lymphoid-rich terminal ileum, thereby serving as a nidus for telescoping). Most often, however, there is no clear etiology.

- Intussusception is the most common cause of intestinal obstruction in children age 6-36 months.

- The ileocolic junction is most frequently involved, with invagination of the ileum into the colon.

- Presentation:

- Intussusception presents with colicky abdominal pain, bilious vomiting, and currant jelly stool (bloody and mucusy stool).

- Occasionally, the intussusception is palpable as a tubular "sausage-shaped" mass in the right upper quadrant (the invagination of the ileum into the colon causes the obstructive mass to be found in the right upper quadrant).

- Currant jelly: Seen with Klebsiella pneumonia in the lungs as sputum, or as stool in the setting of intussusception.

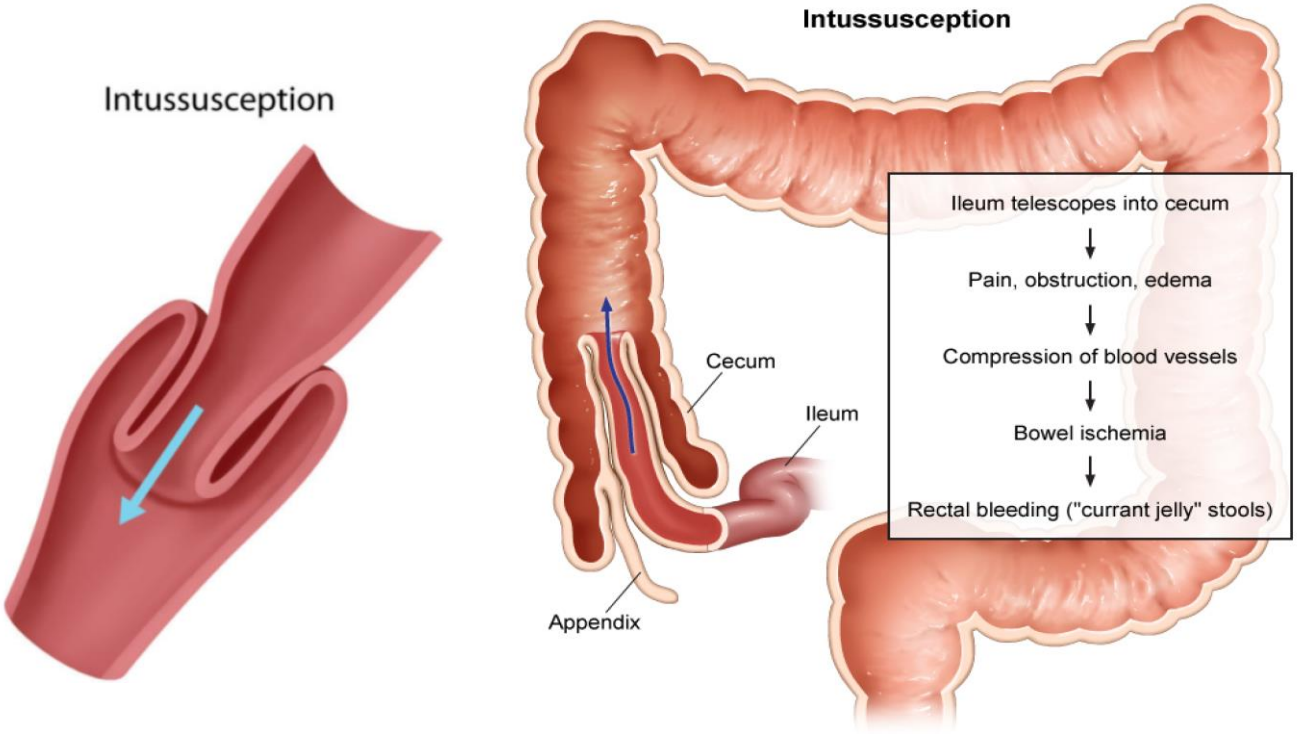

- Diagnostic Tests:

- Ultrasound is the best initial test and will show a doughnut sign or target sign, which is generated by concentric alternating echogenic (mucosa) and hypoechogenic (submucosa) bands.

- Ultrasound-guided air contrast enema, which can lead to nonoperative reduction of the intussusception, is the procedure of choice for diagnosis and treatment; in some institutions, saline enemas are used.

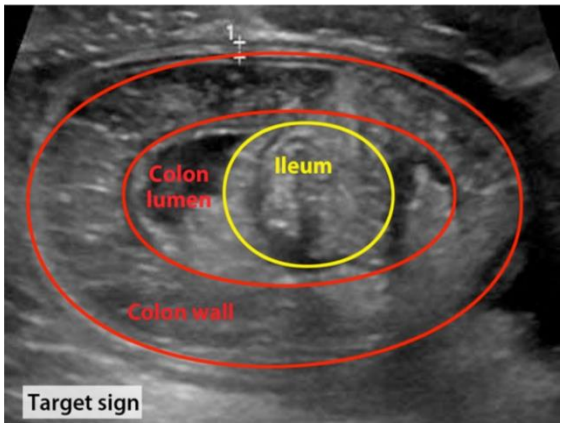

- Treatment:

- Fluid resuscitation and balancing of electrolytes (K, Ca, Mg) are the most important initial steps, followed by NGT decompression of the bowel.

- If enema is not curative, then emergent surgical intervention is necessary to prevent bowel necrosis.

Intussusception	
Risk factors	• Recent viral illness or rotavirus vaccination • Pathological lead point ◦ Congenital malformation of the intestines (eg, Meckel diverticulum) ◦ Henoch-Schönlein purpura ◦ Celiac disease ◦ Intestinal tumor ◦ Polyps
Clinical presentation	• Sudden, intermittent abdominal pain • "Currant jelly" stools • Sausage-shaped abdominal mass • Lethargy or altered mental status
Diagnosis	• "Target sign" on ultrasound
Treatment	• Air or saline enema • Surgery for removal of lead point

Meckel Diverticulum

- Meckel diverticulum is the only true congenital diverticulum (involves all layers of the bowel) in which the vitelline duct persists in the small intestinal tract.

- Meckel's diverticulum is the most common congenital small-intestine anomaly that results from incomplete obliteration of the fetal vitelline (omphalomesenteric) duct that connects the midgut lumen and yolk sac cavity early in fetal life.

- Most (~85%) diverticula contain heterotopic gastric tissue and less commonly contain pancreatic tissue.

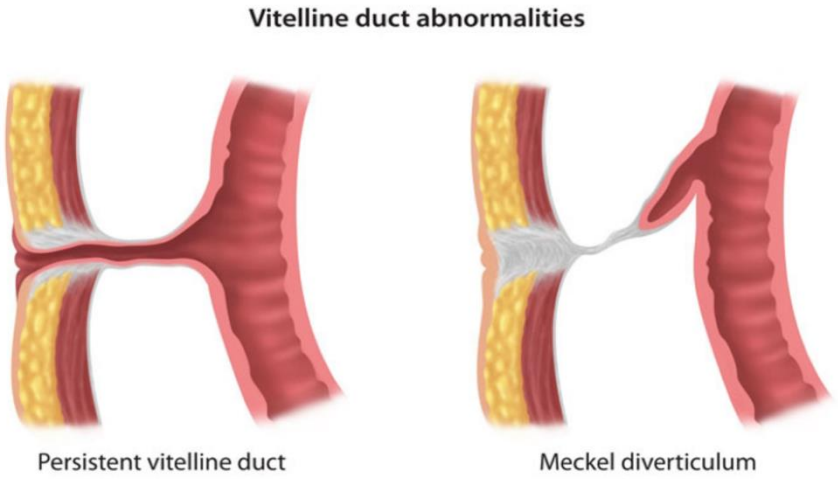

- Presentation:

- The diverticulum is an asymptomatic, incidental finding in most patients.

- Only 2% of diverticula become symptomatic, with painless hematochezia being the most common presentation. Ectopic gastric tissue secretes hydrochloric acid, causing mucosal ulceration of surrounding small bowel. The bleeding is often substantial and causes severe anemia or hemorrhagic shock.

- The diverticulum may also become inflamed and simulate the clinical presentation of acute appendicitis.

- Meckel Diverticulum Rule of 2s:
  - Affects 2% of population.
  - Patient < age 2.
  - Male patients 2 times more affected.
  - Only 2% of patients symptomatic.
  - Affects 2 types of ectopic tissue (gastric and pancreatic).
  - Occurs 2 feet from the ileocecal valve.
  - About 2 inches long.

- Diagnostic Tests/Treatment:

- The best diagnostic test is a technetium-99m pertechnetate scan (Meckel's scan). Accumulation of pertechnetate in the right lower abdominal quadrant is diagnostic of a Meckel diverticulum that contains ectopic gastric mucosa.

- The patient receives a tiny amount of intravenous technetium-99m, and a gamma camera highlights gastric mucosa and ectopic gastric tissue.

- Although the bleeding usually resolves spontaneously, surgical resection is necessary to prevent further bleeding or other complications such as intussusception or complete obstruction.

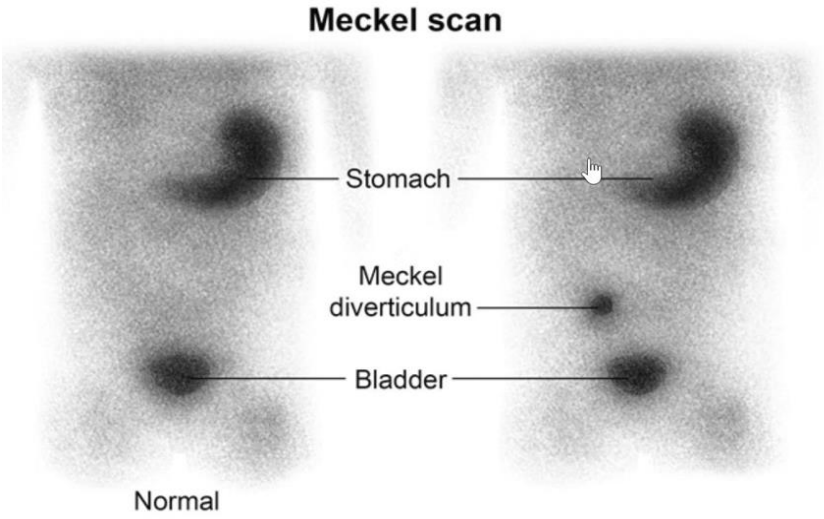

Meckel diverticulum	
Epidemiology	Rule of 2s: • 2% prevalence • Presentation often by age 2 • 2:1 male/female ratio • Location within 2 feet of ileocecal valve
Clinical presentation	• May be asymptomatic, incidental finding • Painless lower gastrointestinal bleeding • ± Anemia
Complications	• Intussusception • Volvulus • Intestinal obstruction
Diagnosis	• Technetium-99m pertechnetate scan

Necrotizing Enterocolitis

- Necrotizing enterocolitis (NEC) is the most common gastrointestinal emergency in the neonatal intensive care unit. The condition carries a mortality of up to 30%.

- Necrotizing enterocolitis (NE) is a condition seen in premature infants where the bowel undergoes necrosis and bacteria invade the intestinal wall.

- The pathogenesis involves a combination of gut immaturity and exposure to bacteria from enteral feeds, leading to a cascade of inflammation and damage to the bowel wall.

- The premature intestinal mucosa is thought to have increased permeability and bacterial penetration. In addition, immature local host defenses and decreased motility allow for bacterial overgrowth.

- If possible, premature infants should receive breast milk instead of formula. Multiple studies have demonstrated decreased rates of NEC in breastfed premature infants as breast milk may counteract some of the problems associated with gut immaturity.

- The poorly perfused intestinal tract may have reduced ability to completely digest and absorb nutrients, leading to bacterial fermentation, excessive mucosal inflammation, and translocation of bacteria and gas into the bowel wall.

- Although >85% of affected infants are premature and/or have very low birth weight, term infants with reduced mesenteric perfusion from congenital heart disease and/or hypotension are also at risk for intestinal ischemia and infarction.

- Up to 30% of affected neonates die, especially when disease is complicated by intestinal perforation.

- <u>Presentation:</u>

- Child born severely premature with low birth weight.

- Vomiting and abdominal distension.

- Fever.

- <u>Diagnostic Tests:</u>

- Abdominal x-ray will reveal the pathognomonic “pneumatosis intestinalis” or air within the bowel wall and CT will reveal air in the portal vein, dilated bowel loops, and pneumoperitoneum if a perforation has occurred.

- In a normal abdominal x-ray, air is visible only in the lumen of the bowel. However, in NEC. the air is visible in the bowel wall, leading to the hallmark finding of pneumatosis intestinalis (red arrows) on x-ray. Linear, branching areas of lucency over the liver are also abnormal and represent portal venous air (yellow arrows). This results from gas produced by the transmigration of gas from the bowel wall to

mesenteric veins and into the portal vein. Severe intestinal necrosis can cause perforation and pneumoperitoneum.

- Frank or occult blood can be seen in stool.

▪ Treatment:

- Feeding must be discontinued for bowel rest.
- IV fluids must be started immediately.
- NGT must be placed for bowel decompression.
- Broad spectrum intravenous antibiotics.
- If medical management does not lead to resolution, then surgery is indicated to remove the affected bowel.
- Survivors are at risk for strictures and bowel obstruction secondary to fibrosis that occurs as the inflammation subsides.

Necrotizing enterocolitis	
Risk factors	• Prematurity • Very low birth weight (<1.5 kg [3.3 lb]) • Enteral feeding (formula riskier than breast milk)
Clinical features	• Vital sign instability • Lethargy • Bilious emesis, bloody stools, abdominal distension
X-ray findings	• Pneumatosis intestinalis • Portal venous gas • Pneumoperitoneum
Treatment	• Bowel rest, parenteral nutrition • Broad-spectrum intravenous antibiotics • ± Surgery

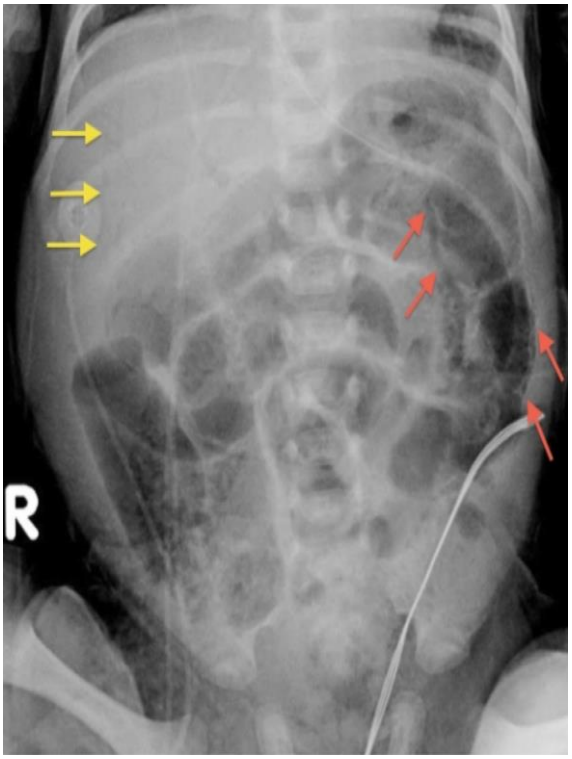

Umbilical Hernia

- Umbilical hernia is due to an incomplete closure of the abdominal muscles around the umbilical ring at birth.
- It is most commonly associated with African American race, premature birth, Ehlers-Danlos syndrome, Beckwith-Wiedemann syndrome, and hypothyroidism.
- Physical examination shows a soft, non-tender bulge covered by skin that protrudes during crying, coughing, or straining.
- The hernia may contain omentum or portions of the small intestine.
- Most umbilical hernias are reduced easily through the umbilical ring with very low risk of incarceration and strangulation.
- <u>Management:</u>

- Small umbilical hernias typically close spontaneously by concentric fibrosis and scar tissue formation.
- Spontaneous closure is less likely with large (>1.5 cm diameter) hernias or in patients with underlying medical problems.
- Surgery is recommended around age 5 for persistent hernias, or sooner if it is bothersome or causing complications.



Omphalocele

- Omphalocele is a defect in which intestines and organs form beyond the abdominal wall with a sac covering.
- It results from failure of the GI sac to retract at 10-12 weeks gestation.
- Omphalocele is highly associated with Edwards syndrome (trisomy 18).
- Diagnosis and treatment:

- Screening is conducted by maternal alpha fetoprotein (AFP) levels and ultrasound.
- Elevated AFP levels indicate both neural tube defects and abdominal wall defects. The most common cause for elevated AFP is incorrect dating.
- Surgical reintroduction of contents is needed.

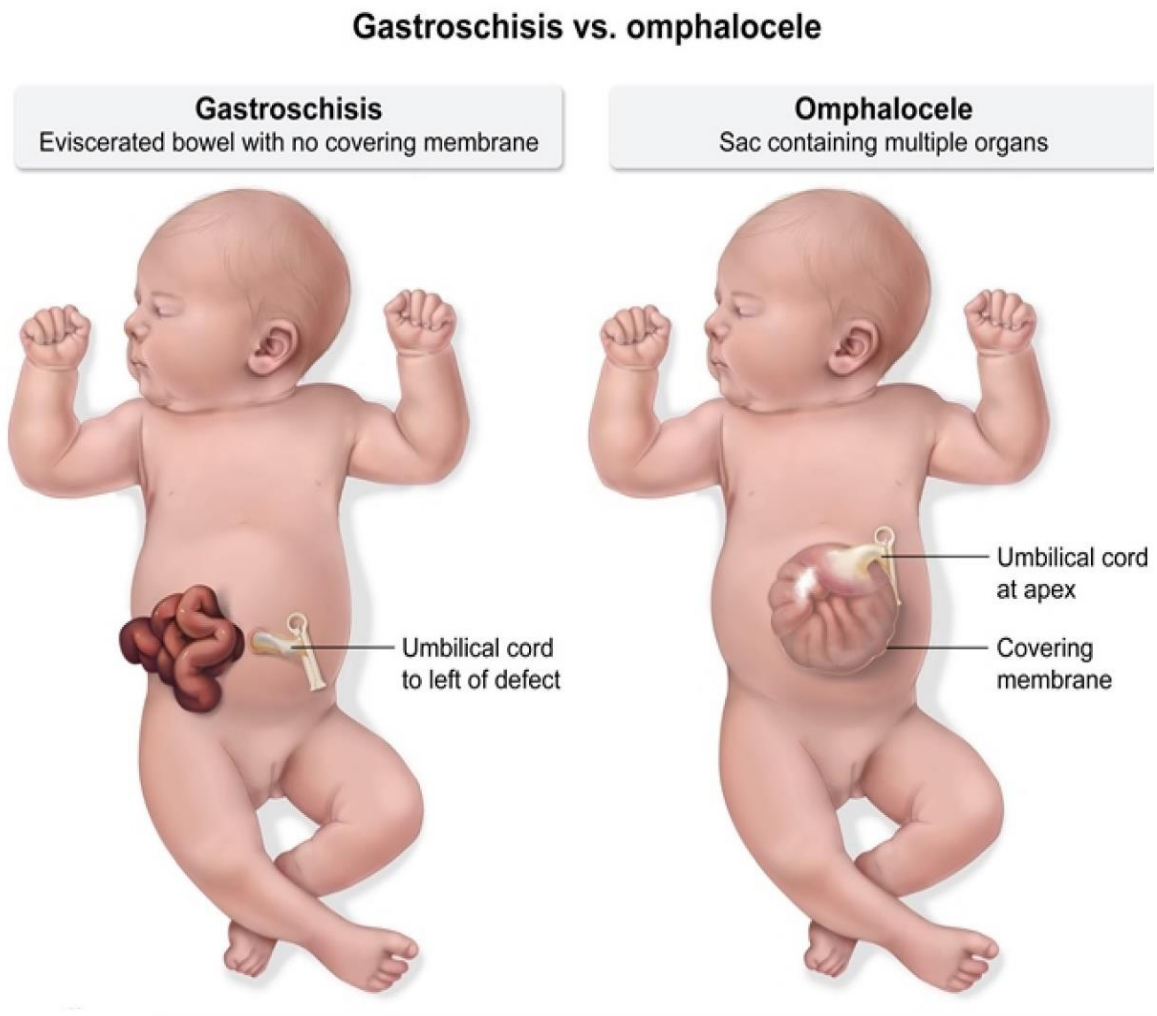

Gastroschisis

- Gastroschisis is a congenital abdominal wall defect resulting in bowel herniation with no sac covering (typically right of umbilicus).
- Not covered by peritoneum or amnion.
- Gastroschisis results in the bowel being exposed to amniotic fluid which causes inflammation and edema of the bowel wall.
- Gastroschisis is generally an isolated defect. Although patients typically do not have other anomalies, continued exposure of the intestines to amniotic fluid causes chronic inflammation and edema, resulting in intestinal thickening.
- This inflammation increases the risk of necrotizing enterocolitis and bowel obstruction, which can lead to short bowel syndrome.
- Nutrients are also lost across the exposed bowel, which can result in fetal growth restriction and oligohydramnios (reduced amniotic fluid).
- Dysmotility (ileus, delayed gastric emptying, intolerance of feeds) occurs in over 50% of cases and may lead to prolonged reliance on total parenteral nutrition.
- <u>Diagnosis:</u>

- The combination of free-floating intestines on prenatal ultrasound and an elevated maternal serum AFP is highly sensitive for diagnosis.
- Elevated maternal serum alpha-fetoprotein (AFP) levels occur in patients with gastroschisis because AFP passes through the exposed bowel wall into the amniotic fluid.

- <u>Treatment:</u>

- After delivery, the exposed bowel should be covered with sterile saline dressings and plastic wrap to minimize insensible heat and fluid losses.
- The infant should have a nasogastric tube placed to decompress the bowel and should be started on antibiotic therapy.
- Prompt surgical repair is necessary and can usually be accomplished in a single-stage closure.

Reye syndrome

- Reye syndrome is characterized by encephalopathy and acute liver failure after a viral infection.
- The incidence has declined significantly after the 1980s due to widespread education about salicylate (aspirin) avoidance in children and adolescents, especially during viral infections. Most cases occur with aspirin use in the setting of influenza B (most common), influenza A, or varicella zoster infection.
- Aspirin is a mitochondrial toxin that can cause acute hepatic dysfunction in young individuals.
- Excess ammonia is neurotoxic and causes cerebral edema and encephalopathy.
- Reye syndrome diagnosis is rare but potentially life-threatening (~30% mortality).
- <u>Diagnosis and treatment:</u>

- Clinical features of hepatic dysfunction include nausea, vomiting, and hepatomegaly.
- Laboratory derangements include elevated transaminases, coagulopathy (prolonged prothrombin time (PT), International normalized ratio [INR], and partial thrombin time [PTT]), and hyperammonemia.
- The presence of microvesicular steatosis on liver biopsy in the context of acute hepatic encephalopathy is consistent with Reye syndrome.
- Treatment is supportive.
- Parents should be reminded that aspirin is generally contraindicated in children, except in the treatment of Kawasaki disease and rheumatologic diseases (juvenile idiopathic arthritis).

Reye syndrome	
Etiology	• Pediatric aspirin use during influenza or varicella infection
Clinical features	• Acute liver failure • Encephalopathy
Laboratory findings	• ↑ AST, ALT • ↑ PT, INR, PTT • ↑ NH_3
Treatment	• Supportive

ALT = alanine aminotransferase; **AST** = aspartate aminotransferase; **NH_3** = ammonia.

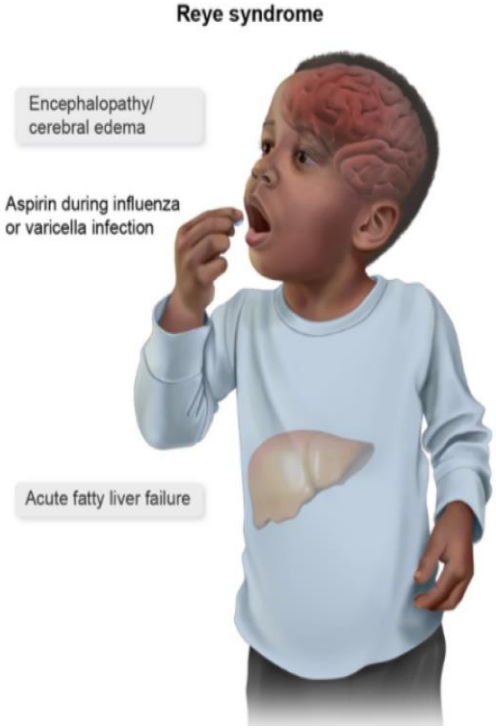

Pediatric Foreign Body Ingestion

- Infants and toddlers put almost everything into their mouths and children with intellectual disability are also at risk of this behavior.

- Difficulty swallowing, feeding refusal and vomiting should raise concern for foreign body ingestion. Coins are the most common foreign body ingested by children.

- Management:

- The management of a child who has ingested a coin differs depending on its location in the digestive tract. Thus, radiographic imaging is required.

- If x-ray reveals that the coin is lodged in the esophagus, immediate endoscopic removal is necessary in order to prevent mucosal damage and esophageal ulceration.

- Flexible endoscopy is the diagnostic and treatment method of choice because the foreign body can be directly visualized and manipulated, and the surrounding gastrointestinal tract can be examined for complications. Rigid endoscopy has a higher risk of esophageal abrasion and perforation and is usually reserved for impacted sharp objects in the proximal esophagus.

- Coin located distal to the esophagus on x-ray pass uneventfully in 90% of cases. Such patients are observed to confirm excretion of the coin by stool examination and/or radiographic follow-up.

- Endoscopic removal should also be considered in cases of ingestion of button batteries (due to the risk of electrical and chemical injury) and of magnets (due to the potential for bowel entrapment as a result of magnetic attraction across intestinal segments).

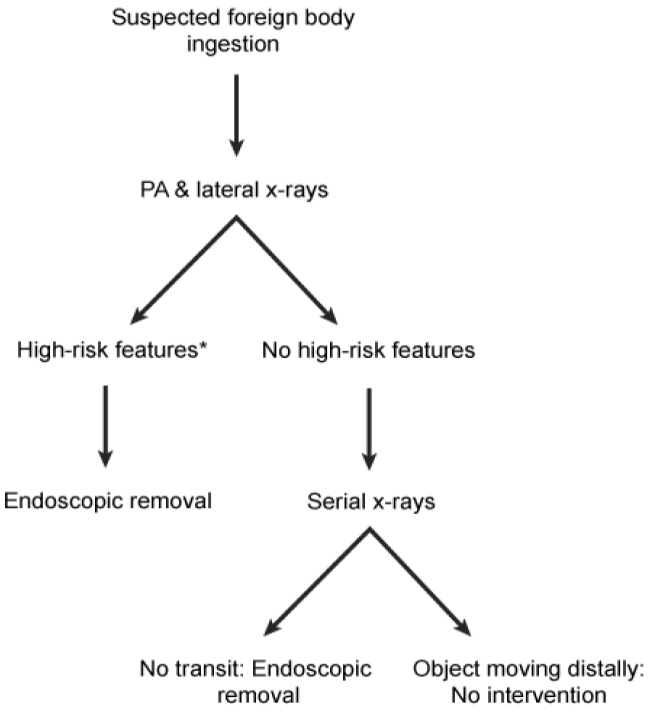

PA = posteroanterior.
*Patient is symptomatic; object is a button battery, magnet, or sharp item.

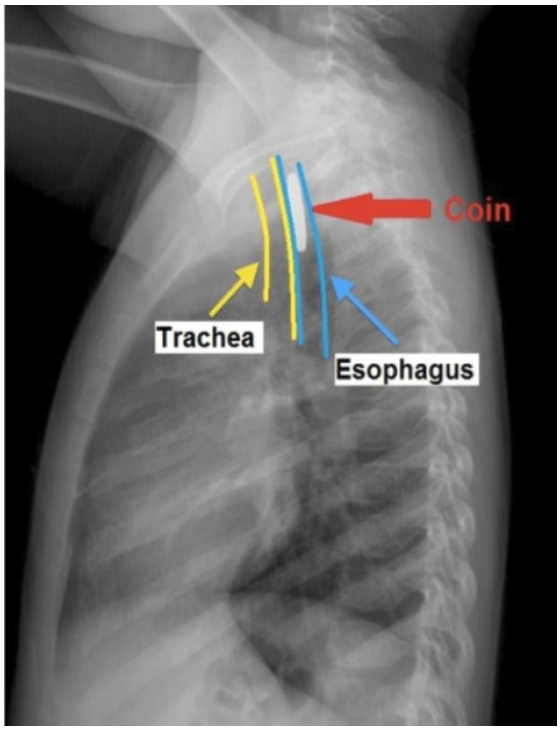

Jaundice

A. Physiologic jaundice of the newborn:

- Almost all newborns have jaundice that appears on days 2-4 of life.

- Although total bilirubin is normally <1 mg/dL in adults, newborns have unconjugated hyperbilirubinemia due to several physiologic differences in bilirubin metabolism:

1. At birth, red blood cell concentration is elevated (hematocrit 50%-60%) with shorter life span (~90 days), resulting in high hemoglobin turnover and bilirubin production.
2. Bilirubin clearance is initially slow because hepatic uridine diphosphogluconurate glucuronosyltransferase (UGT) does not reach adult levels until age 2 weeks.
3. Enterohepatic recycling is increased as the sterile newborn gut cannot break down bilirubin to urobilinogen for fecal excretion. More bilirubin is resorbed in the gut and recycled in the enterohepatic circulation until the gut is colonized and produces bacterial enzymes for reduction to urobilinogen.

- Physiologic jaundice of the newborn is usually benign and resolves on its own by age 1-2 weeks. Newborns should be monitored for persistent or worsening jaundice as high levels can cause brain damage.

- Frequent feeding should be encouraged to promote gut colonization and fecal excretion. Sometimes rapidly rising hyperbilirubinemia requires phototherapy for kernicterus prevention. Exchange transfusion is indicated for total bilirubin levels >20-25 mg/dL.

B. Pathologic Jaundice in the Newborn:

- Hyperbilirubinemia is considered pathological when:

- It appears on the first day of life.
- Bilirubin rises above 13 mg/dL in a term child.
- Bilirubin rises more than .2/dL/hr mg or 5 mg/dL/day.
- Direct bilirubin rises above 2 mg/dL at any time or a direct bilirubin fraction that is >20% of the total bilirubin level.
- Hyperbilirubinemia persists for > 1 week in term or >2 weeks in preterm infants.

- The most serious complication is the deposition of bilirubin in the basal ganglia called kernicterus. Kernicterus presents with hypotonia, seizures, choreoathetosis, and hearing loss.

- Diagnostic Tests/Treatment:

- Direct and indirect bilirubin levels.
- Check blood type of infant and mother for ABO and Rh incompatibility.
- Analyze peripheral blood smear and reticulocyte count for hemolysis.
- Phototherapy with blue-green light helps break down bilirubin to excretable components.
- Consider exchange transfusion if bilirubin rises to 20–25 mg/dL.

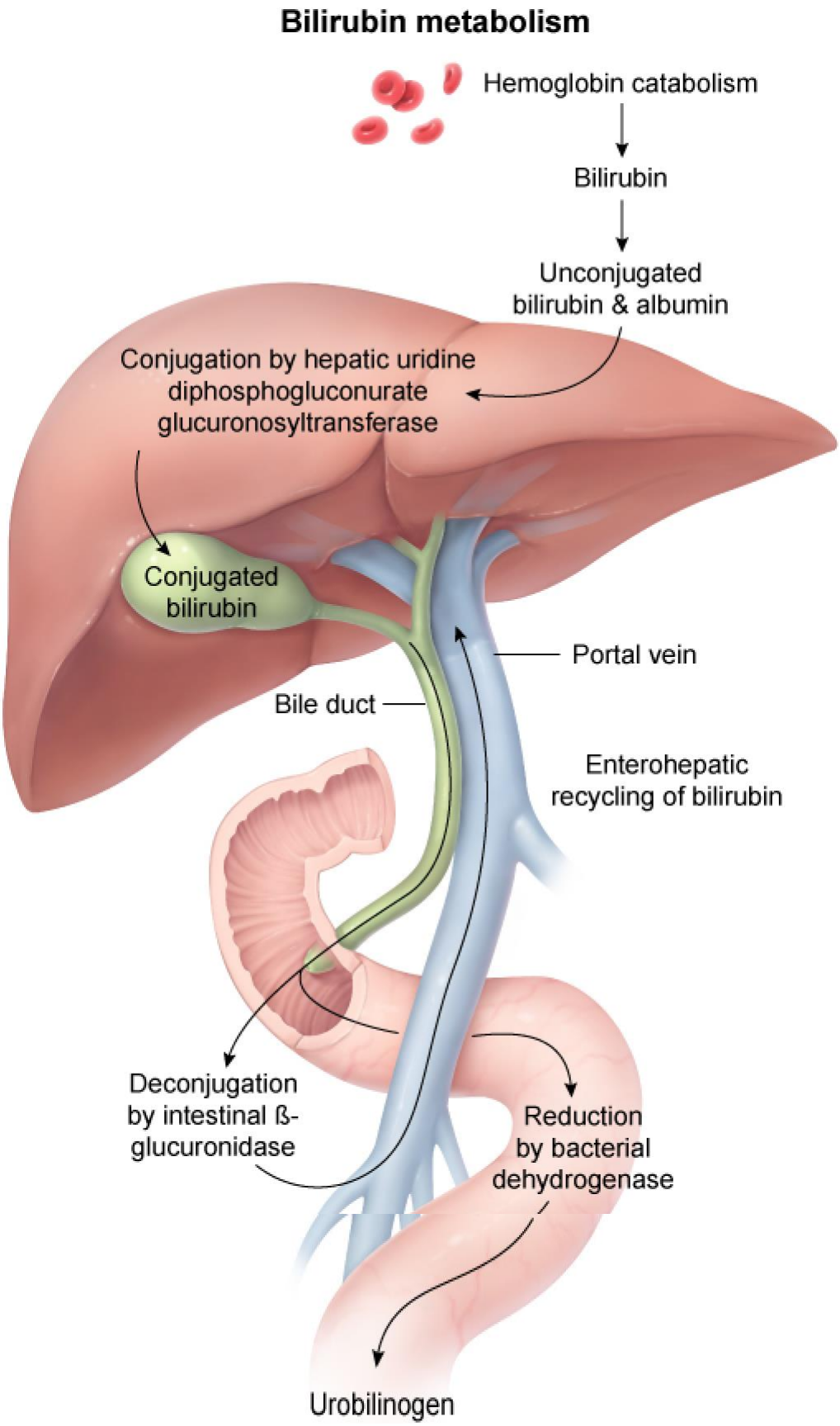
Bilirubin metabolism
Hemoglobin catabolism
Bilirubin
Unconjugated bilirubin & albumin
Conjugation by hepatic uridine diphosphogluconurate glucuronosyltransferase
Conjugated bilirubin
Portal vein
Bile duct
Enterohepatic recycling of bilirubin
Deconjugation by intestinal ß-glucuronidase
Reduction by bacterial dehydrogenase
Urobilinogen

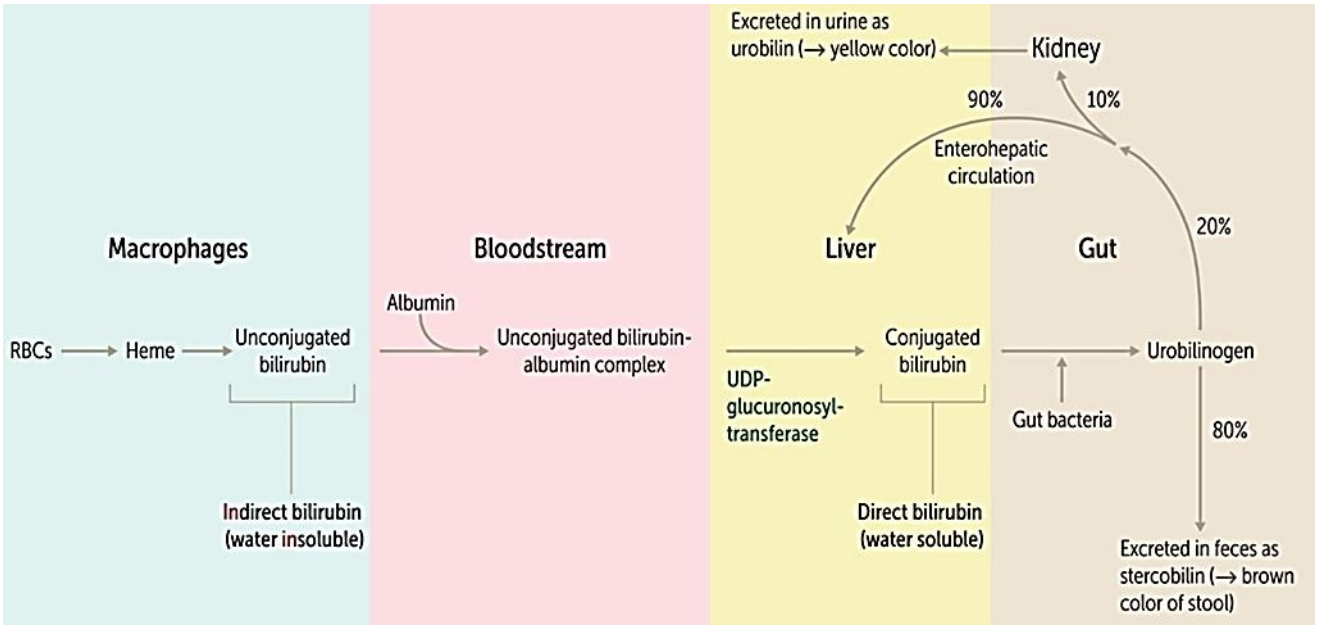
Macrophages
Bloodstream
Liver
Gut
RBCs
Heme
Unconjugated bilirubin
Albumin
Unconjugated bilirubin-albumin complex
Indirect bilirubin (water insoluble)
UDP-glucuronosyl-transferase
Conjugated bilirubin
Direct bilirubin (water soluble)
Excreted in urine as urobilin (→ yellow color)
Kidney
90%
10%
Enterohepatic circulation
20%
Urobilinogen
Gut bacteria
80%
Excreted in feces as stercobilin (→ brown color of stool)

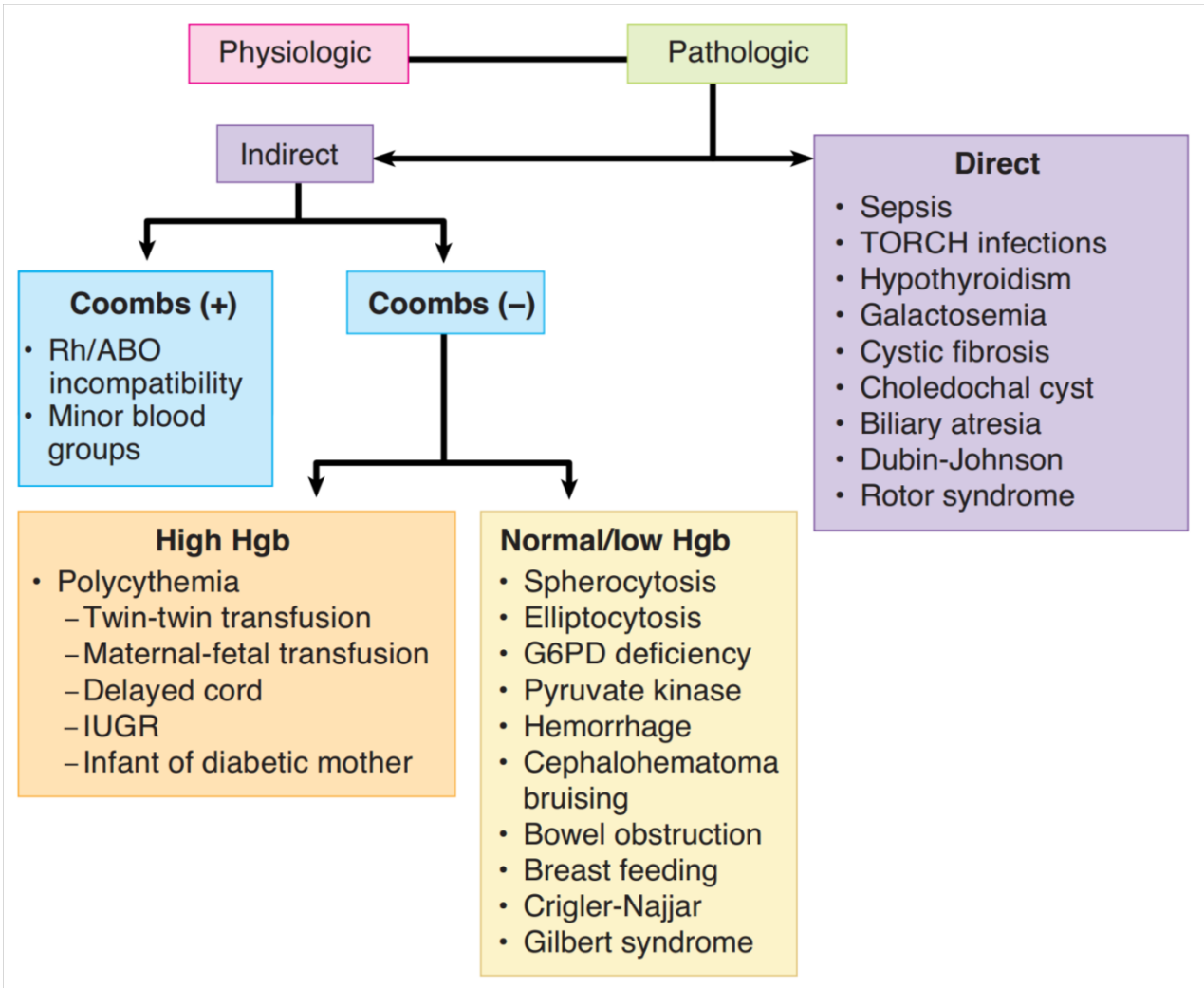
Physiologic
Pathologic
Indirect
Direct
• Sepsis
• TORCH infections
• Hypothyroidism
• Galactosemia
• Cystic fibrosis
• Choledochal cyst
• Biliary atresia
• Dubin-Johnson
• Rotor syndrome
Coombs (+)
• Rh/ABO incompatibility
• Minor blood groups
Coombs (–)
High Hgb
• Polycythemia
– Twin-twin transfusion
– Maternal-fetal transfusion
– Delayed cord
– IUGR
– Infant of diabetic mother
Normal/low Hgb
• Spherocytosis
• Elliptocytosis
• G6PD deficiency
• Pyruvate kinase
• Hemorrhage
• Cephalohematoma bruising
• Bowel obstruction
• Breast feeding
• Crigler-Najjar
• Gilbert syndrome

Breastfeeding failure jaundice

- Breastfeeding failure jaundice is exaggerated unconjugated hyperbilirubinemia in the first week of life that is caused by lactation failure.

- It can be caused by both maternal (inadequate milk supply, cracked/clogged nipples, engorgement, infrequent feeding) and infant (poor latch, ineffective suck, falling asleep) factors.

- Normal infants pass dark, sticky meconium during the first 2 days of life, after which they should transition to yellowish or green stool if ingesting adequate milk. Inadequate stooling results in decreased bilirubin elimination and increased enterohepatic circulation of bilirubin.

- In addition to jaundice, Infants with breastfeeding failure are often dehydrated. During the first week of life, the normal number of wet diapers a day should equal the infant's age in days (a 4-day-old infant should have >4 wet diapers a day).

- Treatment:

- The best treatment for breastfeeding failure jaundice in otherwise healthy full-term newborns is to increase the frequency and duration of feeds to stimulate milk production, maintain adequate hydration, and promote bilirubin excretion.

- Neonates should breastfeed -8-12 times a day (every 2-3 hours) for >10-20 minutes per breast during the first month of life. When bilirubin is eliminated as fecal urobilinogen, less bilirubin is reabsorbed and recycled in the enterohepatic circulation, thereby decreasing serum bilirubin levels.

- If the bilirubin continues to rise despite efforts to optimize lactation, formula supplementation may be necessary.

Breastfeeding jaundice vs breast milk jaundice

Diagnosis	Timing	Pathophysiology	Clinical features
Breastfeeding jaundice	First week of life	Insufficient intake of breast milk resulting in: • Decreased bilirubin elimination • Increased enterohepatic circulation	• Suboptimal breastfeeding • Signs of dehydration
Breast milk jaundice	Starts at age 3-5 days; peaks at 2 weeks	High levels of β-glucuronidase in breast milk deconjugate intestinal bilirubin & increase enterohepatic circulation	• Adequate breastfeeding • Normal examination

Hereditary hyperbilirubinemias

- <u>The hepatic processing of bilirubin is accomplished in three key steps:</u>

1. Carrier-mediated uptake of bilirubin at the sinusoidal membrane.

2. Conjugation of bilirubin with glucuronic acid by UGT (uridine diphosphate glucuronyl transferase) in the endoplasmic reticulum.

3. Biliary excretion of the water-soluble, nontoxic bilirubin glucuronides. Disruption of this process can be fatal, as seen with Crigler-Najjar syndrome.

- In the normal individual, serum total bilirubin is 0.2-1 mg/dL, of which < 0.2 mg/dL is the direct fraction.

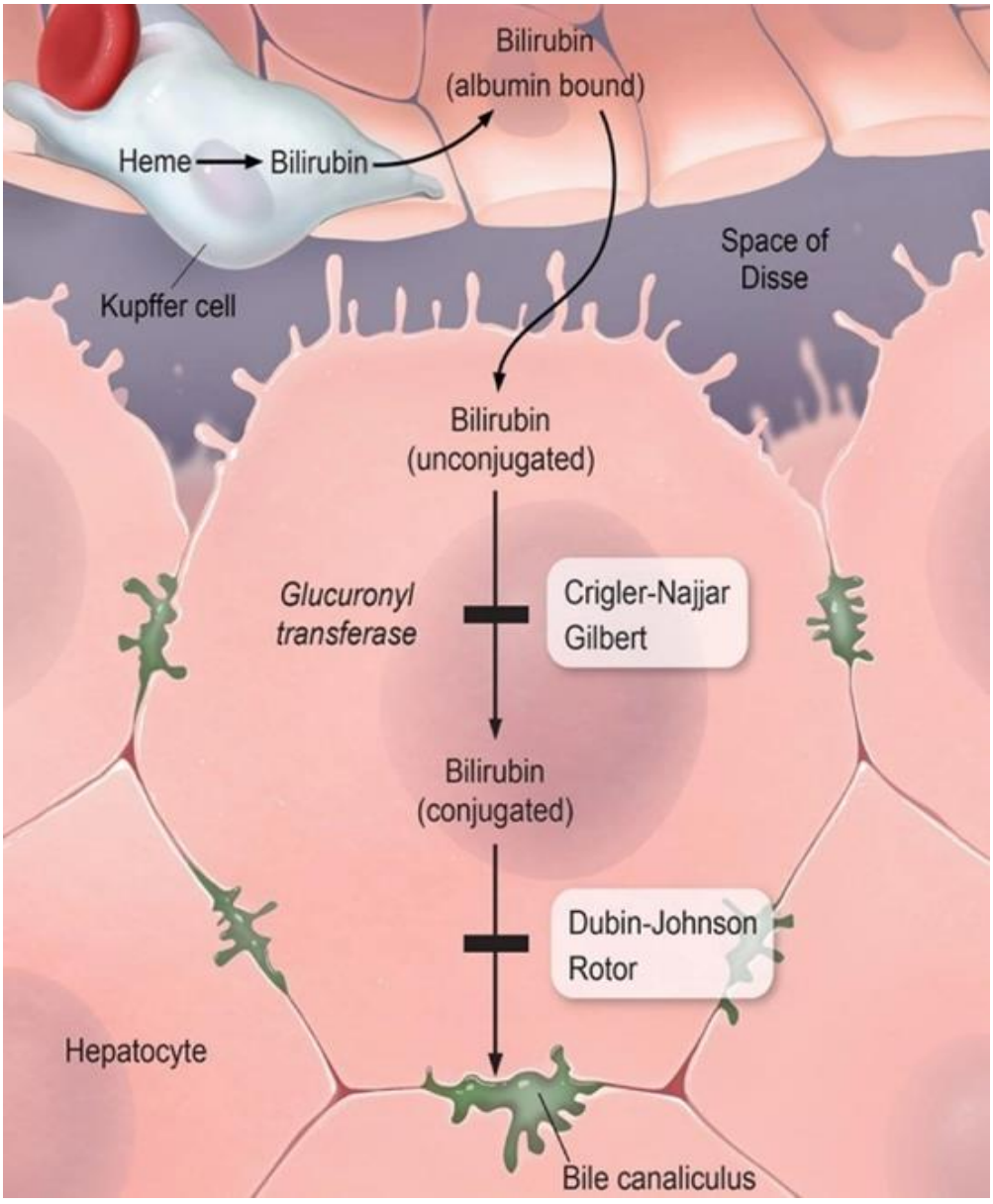

1. Gilbert syndrome:

- Gilbert syndrome is a common familial disorder of bilirubin glucuronidation in which the production of UDP glucuronyl transferases (enzymes that mediate glucuronidation of various substances) is reduced and impaired bilirubin uptake.

- The diagnosis is suggested in those patients with no apparent liver disease and without overt hemolysis who have mild unconjugated hyperbilirubinemia thought to be provoked by one of the classic triggers.

- Examples of such triggers include fasting, physical exertion, febrile illness, stress, and fatigue.

- Presumptive diagnosis can be made when unconjugated hyperbilirubinemia persists with repeat testing but liver function tests, complete blood count, blood smear, and reticulocyte count are normal.

- Management involves reassurance and supportive care.

2. Crigler-Najjar syndrome:

- Crigler-Najjar syndrome is an autosomal recessive disorder of bilirubin metabolism caused by a genetic lack of the UGT enzyme needed to catalyze bile glucuronidation (Absent UDP-glucuronosyltransferase).

- When bilirubin is not correctly enzymatically processed by the liver, unconjugated hyperbilirubinemia develops.

- Indirect bilirubin levels typically approximate 20-25 mg/dl in these infants, but can rise to as high as 50 mg/dL.

- The unconjugated bilirubin is gradually deposited into various tissues, including the brain. These deposits can cause kernicterus (bilirubin encephalopathy), which is a potentially fatal condition characterized by severe jaundice and neurologic impairment.

- Treatment:

- Plasmapheresis and phototherapy.

- Liver transplant is curative.

3. Dubin-Johnson syndrome:

- Dubin-Johnson syndrome is characterized by a defect in the hepatic excretion of bilirubin glucuronides across the canalicular membrane.

- Individuals with this rare, benign condition have predominantly conjugated chronic hyperbilirubinemia.

- Grossly, the liver is strikingly black (Dark).

4. Rotor syndrome:

- It is similar to dubin johnson syndrome, but milder in presentation without black (Regular) liver.

Biliary atresia

- Biliary atresia is caused by progressive obliteration of the extrahepatic biliary ducts connecting the liver to the small bowel.
- It is the most common indication for pediatric liver transplantation.
- Newborns are initially well but develop conjugated hyperbilirubinemia in the first 2 months of life which manifests as jaundice, acholic stools (due to the absence of biliary pigment), and dark urine (due to renal excretion of bilirubin that cannot reach the small bowel).
- Conjugated hyperbilirubinemia is defined as >2 mg/dL of direct bilirubin or a direct bilirubin fraction that is >20% of the total bilirubin level.
- Without treatment, the liver will become inflamed (hepatomegaly, hepatitis) and eventually fibrose.
- The first step in evaluation is abdominal ultrasound, which may show an absent or abnormal gallbladder.
- Failure of the liver to excrete tracer into the small bowel on scintigraphy is highly suggestive of biliary atresia, and the diagnostic gold standard is a cholangiogram obtained in the operating room.
- Once biliary atresia is confirmed, a Kasai procedure (hepatoportoenterostomy) should be performed. Virtually all patients will require liver transplantation, but the Kasai procedure allows time for growth and reduces the morbidity and mortality of hepatic transplant.
- Newborns with conjugated hyperbilirubinemia and hepatomegaly require immediate evaluation for biliary atresia.

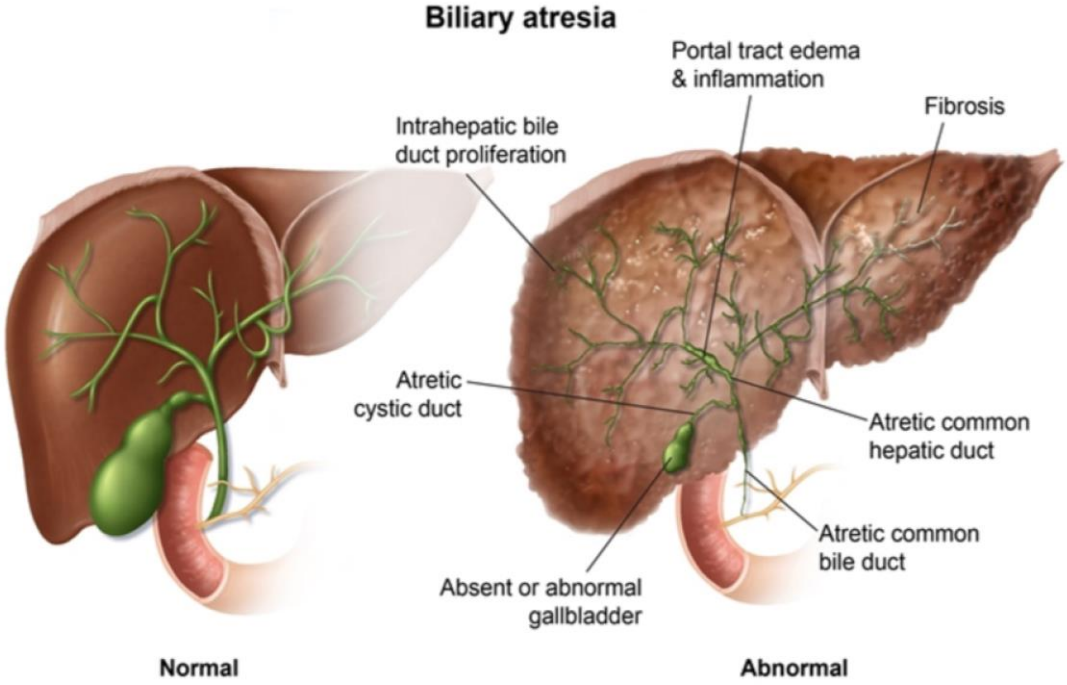

Biliary cyst (or choledochal cyst)

- A biliary cyst (or choledochal cyst) is a congenital dilatation of the biliary tree.
- These dilatations may be single or multiple and can be intra- or extrahepatic. The most common type of biliary cyst (type I) is a single, extrahepatic cyst.
- Classic signs of a biliary cyst include abdominal pain, jaundice (due to obstructive cholestasis), and a palpable mass.
- However, the clinical presentation varies with age. The majority of patients are age <10. Infants can have jaundice and acholic stools, a presentation that resembles biliary atresia.
- Older children may have pancreatitis and occasionally cholangitis (inflammation within the bile ducts caused by the spread of bacteria from the intestine into the bile ducts).
- Biliary cysts can transform into cholangiocarcinoma.
- The diagnosis is generally made by ultrasound or other imaging; endoscopic retrograde cholangiopancreatography may be needed if obstruction is suspected.
- Surgical resection relieves the obstruction and reduces the risk of malignancy.

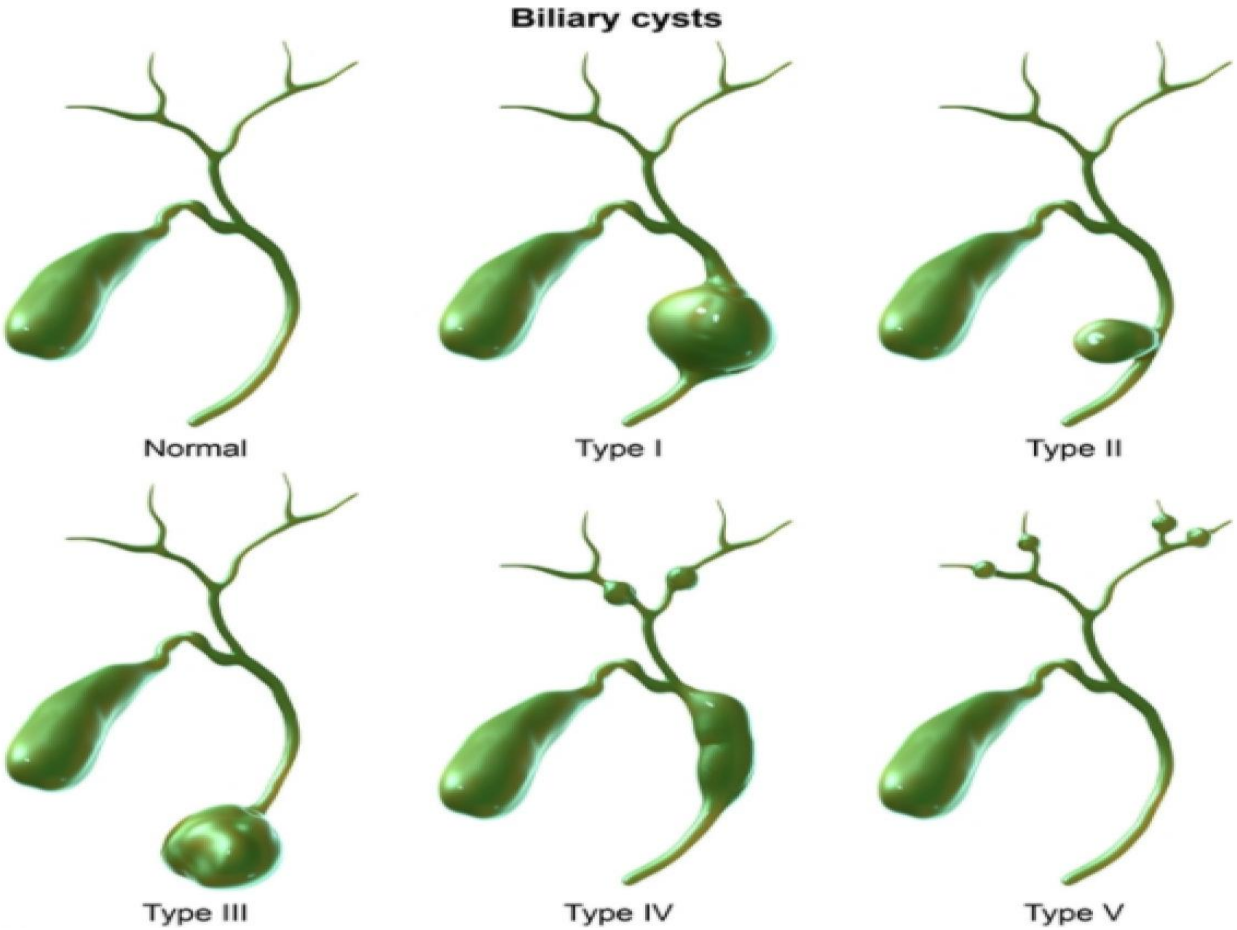

Feeding

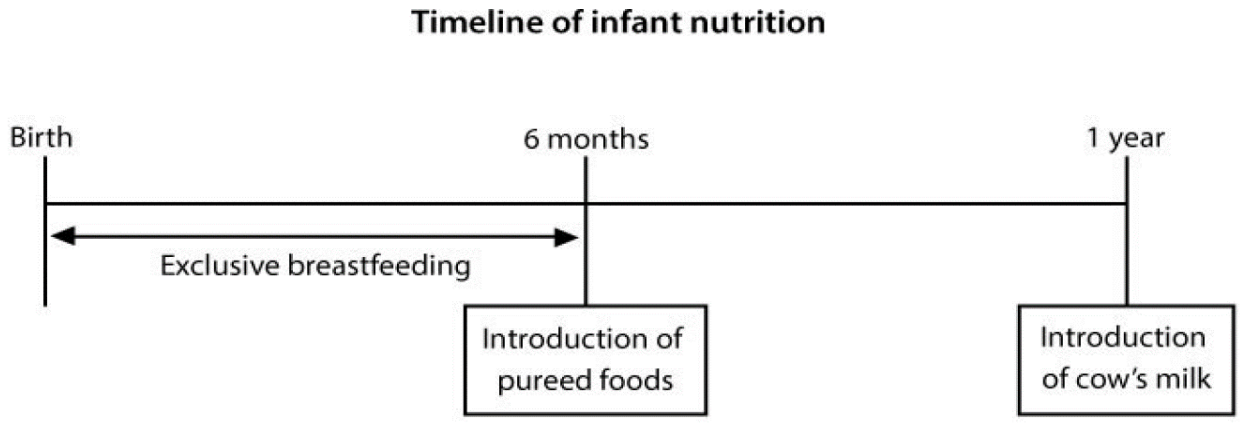

- Human milk is considered to be the ideal nutritional source for full-term infants.
- The American Academy of Pediatrics recommends exclusive breastfeeding until 6 months of age and then continuation of breastfeeding along with the introduction of solid foods until the infant is 1 year old.
- Infant formulas have improved greatly over time to more closely resemble human milk, but differences still exist.
- Breastfeeding has a myriad of advantages both for the mother and infant, however, there are circumstances in which breastfeeding is contraindicated.
- Human milk contains lactoferrin, lysozyme, and secretory immunoglobulin A proteins that confer improved immunity to the infant.
- Breastfed infants have a decreased risk of developing otitis media, respiratory, gastrointestinal, and urinary tract infections; and necrotizing enterocolitis. Breastfed infants also have lower rates of type I diabetes mellitus and childhood cancer.
- For these reasons, mothers should be encouraged to exclusively breastfeed their infants until age 6 months.
- The only absolute infant contraindication to breastfeeding is galactosemia.
- Human breast milk contains only small amounts of vitamin D that are inadequate for meeting the infant's daily requirement. All exclusively breastfed infants should be started on 400 International Units of vitamin D daily within the first month of life.

Breastfeeding benefits & contraindications		
	Benefits	**Contraindications**
Maternal	• More rapid uterine involution & decreased postpartum bleeding • Faster return to prepartum weight • Improved child spacing • Improved maternal-infant bonding • **Reduced risk of breast & ovarian cancer**	• Active untreated **tuberculosis** (mothers may breastfeed after 2 weeks of anti-tuberculin therapy) • Maternal **HIV infection** (in developed countries where formula is readily available) • Herpetic breast lesions • Varicella infection <5 days prior to or within 2 days of delivery • Specific maternal medications • Chemotherapy or ongoing radiation therapy • Active abuse of **street drugs** or **alcohol**

Infant	• Improved **immunity**
	• Improved gastrointestinal function
	• **Prevention** of infectious diseases:
	  ○ **Otitis media**
	  ○ Gastroenteritis
	  ○ **Respiratory illnesses**
	  ○ Urinary tract infections
	• Decreased risk of childhood cancer, type I diabetes mellitus & necrotizing enterocolitis
		• **Galactosemia**

❖ N.B:

- Healthy neonates normally lose up to 7% of their birth weight in the first 5 days of life due to excretion of excess fluid acquired in utero and during labor.
- As a general rule, the number of wet diapers should equal age in days for the first week of life. For example, a 4-day-old neonate should have >4 wet diapers per day. After the first week, infants should have >6 wet diapers per day. Birth weight should be regained by age 10-14 days.
- The weight loss is more pronounced in exclusively breastfed infants as the mother's milk supply gradually increases to meet infant demands. No treatment is required, and exclusive breastfeeding should be continued.

Food protein induced allergic proctocolitis

- Breast milk contains fats, carbohydrates (lactose), and maternal diet-derived proteins (whey, casein) from milk and soy.

- Milk- or soy-protein-induced proctocolitis (milk-protein allergy), a condition exclusive to infants. A non-IgE-mediated immunologic response to proteins in formula or breast milk causes rectal and colonic inflammation.

- The clinical presentation includes eczema, regurgitation or vomiting, and/or painless bloody stools.

- Diagnosis:

- The diagnosis is clinical and confirmed when bleeding ceases in response to dietary modifications.

- Treatment:

- Due to substantial cross-reactivity, both dairy and soy should be avoided. Therefore, the mother of a breastfed infant can continue to breastfeed after eliminating all dairy and soy from her diet.

- Formula-fed infants should be switched to a hydrolyzed formula (containing predigested proteins).

- Visible bleeding should resolve within 3 days, but complete resolution of occult blood may take up to 2 weeks.

- Parents should be reassured that the prognosis is excellent and that almost all affected infants can tolerate dairy and soy products by age 1 year.

Food protein–induced allergic proctocolitis	
Risk factors	• Family history of allergies, eczema, or asthma
Clinical features	• Young infant • Painless, bloody stools • ± Spit-up
Treatment	• Elimination of milk & soy from maternal diet in breastfed infants • Hydrolyzed formula in formula-fed infants
Prognosis	• Spontaneous resolution by 1 year

Iron deficiency anemia in young children

- Iron deficiency anemia is the single most common nutritional deficiency in infants and children and is often asymptomatic.

- Full-term, healthy infants are born with robust Iron stores that generally prevent them from developing iron deficiency anemia until age 4-6 months, regardless of dietary intake. However, the presence of maternal iron deficiency, prematurity, and early introduction of cow's milk before age 12 months increases the risk of iron deficiency anemia in Infants.

- Early introduction or excessive intake of cow's milk is problematic as cow's milk is low in iron and can cause occult intestinal blood loss in infants.

- Children should not be started on cow's milk until age 1 year, and children age >1 year should consume <24 ounces/day.

- Diagnosis:

- The diagnosis is typically based on a complete blood count, typically showing a low hemoglobin (<11 g/dL), low mean corpuscular volume, and elevated red blood cell distribution width.

- The reticulocyte count is classically low (because the bone marrow with iron deficiency cannot increase reticulocyte production).

- A peripheral smear would be expected to show microcytic hypochromic erythrocytes, although it is usually not needed in the initial workup. Further testing (iron studies) is not necessary in children with the classic presentation.

- The most common causes of microcytic anemia in children are iron deficiency and thalassemia. Iron deficiency anemia can be differentiated from thalassemia by an elevated red cell distribution width.

- Treatment:

- The most cost-effective approach to treatment is empiric oral iron therapy. Hemoglobin should be rechecked in 4 weeks; if the hemoglobin level has risen 1 g/dL, the oral iron therapy should be continued for 2-3 months after the hemoglobin normalizes to replete iron stores.

- Iron supplementation should be started at birth in exclusively breastfed preterm infants and continued until age 1 year. All exclusively breastfed infants should also be started on vitamin D supplementation.

Differential diagnosis of crying infants

- Crying is the primary mode of communication during infancy.
- The normal duration is highly variable but is generally 1-2 hours per day.
- Infantile colic is defined as excessive crying for >3 hours a day, >3 days a week, over a period of 3 weeks in an otherwise healthy infant. Colic usually presents in the first few weeks of life and resolves spontaneously by age 4 months.
- The crying generally occurs at the same time of the day, typically early in the evening. The cause of colic is unknown but may be due to overstimulation of the infant and parental unfamiliarity with alternate soothing methods.
- Soothing and feeding techniques should be reviewed and parents should be emotionally supported and reassured.
- Calming techniques include using an infant swing, minimizing environmental stimuli (quiet dark room), and holding and rocking the baby. Feeding patterns should also be reviewed to assess if there is overfeeding, underfeeding, or an inadequate burping technique.

Differential diagnosis for a crying infant	
Diagnosis	**Clinical features**
Colic	Crying that occurs in an otherwise healthy infant for ≥3 hours daily (usually evening), ≥3 times a week & for a duration of ≥3 weeks
Gastroesophageal reflux disease	• Arching of the back during or after feeding (Sandifer syndrome) • Frequent spit-ups or vomiting • Poor weight gain
Corneal abrasion	Positive fluorescein examination
Hair tourniquet	Presence of hair that is accidentally tied or wrapped around an extremity or digit
Milk protein allergy	Blood-streaked, mucousy, loose stools or severe constipation
Normal infant crying	• Intermittent crying that resolves with usual consoling methods • Duration <2 hours a day

Constipation in children

- Constipation is a common problem in toddlers due to transition to solid food and cow's milk, toilet training, and school entry.
- Complications include anal fissures, encopresis, and enuresis.
- Although constipation is common, prevention and treatment are important as straining and painful defecation can be very stressful. Children may avoid defecation, which creates a vicious cycle of further accumulation of hard stool, increased pain, and persistent stool withholding.
- Severe fecal impaction can mimic intestinal obstruction and cause abdominal pain and vomiting. If the rectum dilates progressively, the internal anal sphincter may relax in response to the increasing pressure, resulting in encopresis (fecal incontinence). The stool burden also decreases bladder capacity and can contribute to enuresis (urinary incontinence).
- Recurrent cystitis in toddlers is often caused by constipation as fecal retention can cause rectal distension, which in turn compresses the bladder and prevents complete voiding. The residual urine is a potential breeding ground for bacteria that ascend to the urethra from the perineum. Prevention and treatment of recurrent cystitis requires adequate treatment of constipation.
- Laxative therapy should be initiated promptly to soften stools. ↑ Dietary fibers and water intake.
- Enema in severe cases.

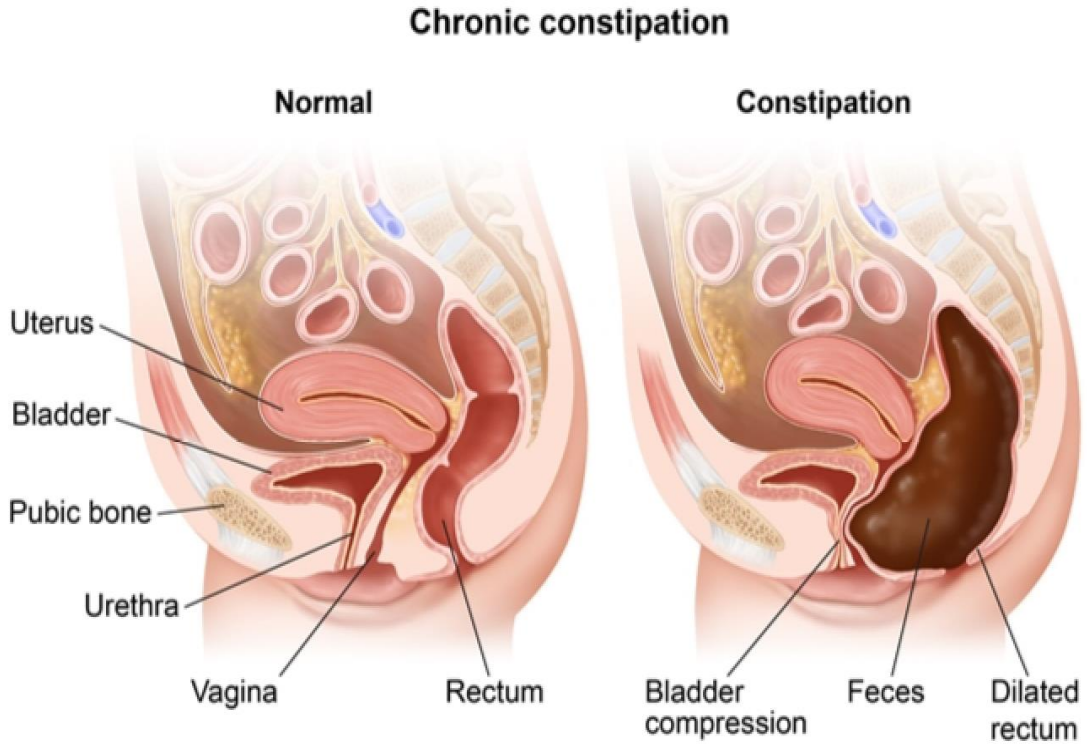

Cyclic vomiting syndrome (CVS)

- In children, recurrent self-limiting episodes of vomiting and nausea without an apparent cause suggest the diagnosis of cyclic vomiting syndrome (CVS).
- The etiology of CVS is unclear, but the incidence of CVS is highest in children whose parents have a history of migraine headaches.
- Vomiting episodes may be triggered by stress or infection and be accompanied by nausea, vague abdominal pain, headache, and lethargy.
- These symptoms self-resolve after 1 or 2 days. Patients typically have regular, predictable symptom intervals (2-4 weeks) and are typically asymptomatic between episodes.
- Complications that may arise from recurrent vomiting include anemia and dehydration.
- Treatment consists of hydration, antiemetics (ondansetron), and reassurance of the parents. Children with a family history of migraines are likely to benefit from anti-migraine therapy such as sumatriptan.
- Approximately 2/3 children with CVS have gradual resolution of their symptoms in 5-10 years.
- Some children progress from CVS to abdominal migraines and migraine headaches.

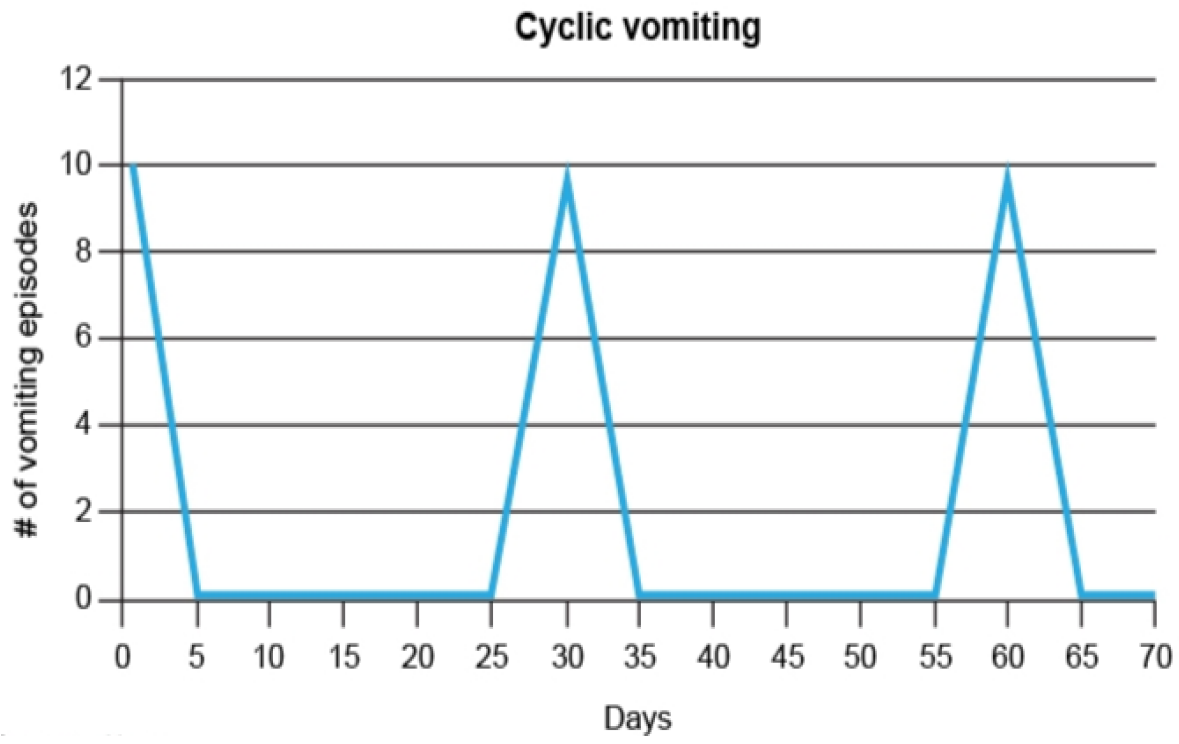

Gastroesophageal reflux in infants

- Gastroesophageal reflux is extremely common and affects more than 50% of infants.
- Compared to adults, infants experience frequent postprandial regurgitation “spitting up" due to physiologic differences.
- These differences include a shorter esophagus, incomplete closure of the lower esophageal sphincter, and greater time spent in the supine position.
- Most infants are otherwise asymptomatic "happy spitter", and parents should be reassured if examination, growth, and development are normal.
- Diagnosis is based on history and physical examination.
- Treatment consists of education and supportive measures. Parents should be advised to give frequent, small-volume feeds; hold the infant upright for 20-30 minutes after feeds, and place the infant prone when awake.
- Activities that increase intraabdominal pressure (fastening the diaper too tight, bringing the knees to the stomach) should be avoided.
- Regurgitation usually improves around age 6 months (when the infant can sit unsupported) and resolves by age 1 year.

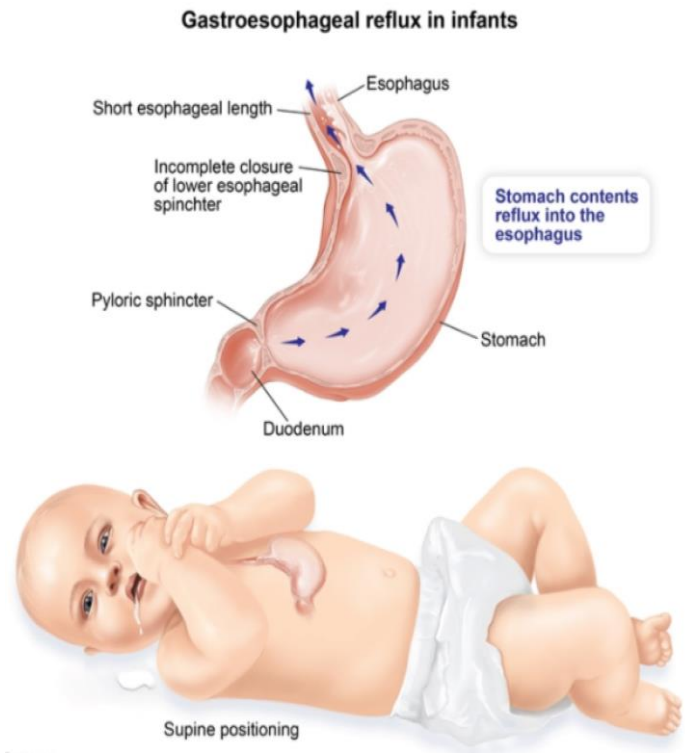

Differential diagnosis of regurgitation & vomiting in infants		
Diagnosis	**Clinical features**	**Management**
Gastroesophageal reflux	• Physiologic o Asymptomatic o "Happy spitter"	• Reassurance • Positioning therapy
	• Pathologic (GERD) o Failure to thrive o Significant irritability o Sandifer syndrome	• Thickened feeds • Antacid therapy • If severe, esophageal pH probe monitoring & upper endoscopy
Milk protein allergy	• Regurgitation/vomiting • Eczema • Bloody stools	• Elimination of dairy & soy protein from diet
Pyloric stenosis	• Projectile nonbilious vomiting • Olive-shaped abdominal mass • Dehydration, weight loss	• Abdominal ultrasound • Pyloromyotomy

GERD = gastroesophageal reflux disease.

CHAPTER 4

Pediatric Pulmonology

Pulmonary Disease

Differential diagnosis of respiratory distress in newborn

Choanal Atresia

- The congenital nasal malformation is caused by failure of the posterior nasal passage to canalize completely, leaving either a bony (90%) obstruction due to outgrowth of the palatine bone or membranous (10%) obstruction due to failed resorption of the oronasal membrane that prevents breathing during feeding.

- The condition may be isolated or part of a syndrome (CHARGE syndrome).

- CHARGE syndrome is a set of congenital defects seen in conjunction:

- C: Coloboma of the eye, central nervous system anomalies.
- H: Heart defects.
- A: Atresia of the choanae.
- R: Retardation of growth and/or development.
- G: Genital and/or urinary defects (hypogonadism).
- E: Ear anomalies and/or deafness.

- Presentation:

- Child will turn blue when feeding and then pink when crying.
- The clinical severity depends on the infant's ability to breathe through the mouth and whether one or both choanae is/are obstructed.
- Infants are usually obligate nasal breathers.
- Bilateral obstruction classically presents with cyclic cyanosis that worsens when infants cannot breathe through the mouth (during feeding) and recovers when they do (while crying).
- Unilateral (most common) choanal atresia may remain undiagnosed until the development of a first upper respiratory infection.

- Diagnostic Tests/Treatment:

- Failure to pass a catheter through the nares into the oropharynx is suggestive of choanal atresia.
- The diagnosis is confirmed by CT scan.
- In contrast to infants with patent choanae, infants with choanal atresia have narrowing at the level of the pterygoid plate in the posterior nasal cavity (as shown by the green arrows in the image below).
- The first step in management consists of placing an oropharyngeal airway and orogastric tube feeding. Definitive treatment involves repairing the obstruction with surgery or endoscopy



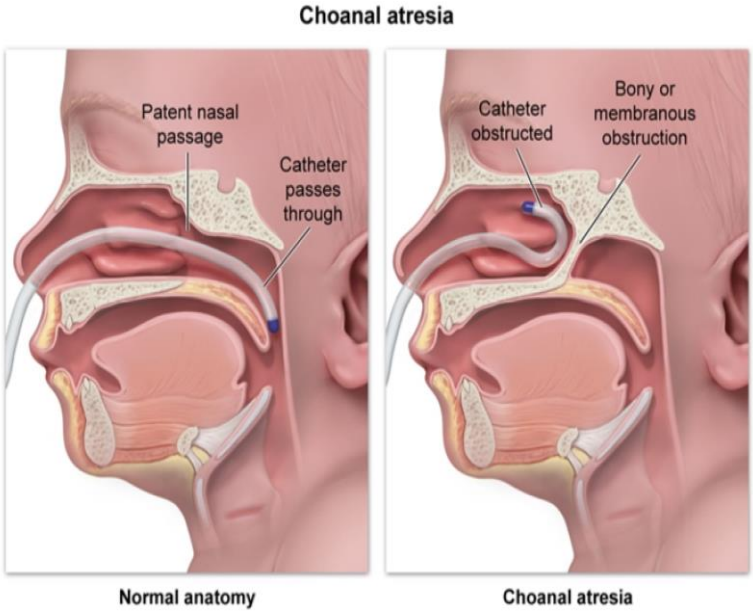

Neonatal respiratory distress syndrome

- Deficiency of mature surfactant (surfactant matures biochemically over gestation; therefore, the incidence of surfactant deficiency diminishes toward term).

- Surfactant which is produced in type II pneumocytes, works to decrease the surface tension in alveoli, facilitating lung expansion during respiration.

- When there is insufficient surfactant, as in neonatal respiratory distress syndrome, the result is collapse of alveoli (atelectasis) due to increased surface tension and formation of hyaline membranes.

- The most important risk factor for RDS is prematurity (surfactant production begins at 28 weeks; adequate levels are not reached until 34 weeks); other factors that increase RDS risk include male sex, perinatal asphyxia, maternal diabetes, and cesarean section without labor (lack of vaginal compression stress on the infant during delivery results in reduced fetal cortisol production and resultant reduction in surfactant production).
- Maternal diabetes increases the incidence of RDS by delaying the maturation of pulmonary surfactant production. Maternal hyperglycemia causes fetal hyperglycemia, which in turn triggers fetal hyperinsulinism. High levels of circulating insulin antagonize cortisol and block the maturation of sphingomyelin, a vital component of surfactant.

- Primary initial pulmonary hallmark is hypoxemia. Then, hypercarbia and respiratory acidosis ensue.

- Affected neonates develop the following symptoms within minutes to hours after birth in an attempt to compensate for diffuse alveolar collapse:

- Tachypnea (respiratory rate >60/min).
- Grunting (to increase end-expiratory pressure).
- Nasal flaring (decreases nasal airway resistance).

- Retractions (intercostal muscles contract and pull in the compliant chest wall).
- Hypoxia and cyanosis (reflect significant atelectasis).

▪ Diagnosis:

- Best initial diagnostic test: chest radiograph (ground-glass appearance, atelectasis, air bronchograms).

- Most accurate diagnostic test: L/S ratio (lecithin to sphingomyelin ratio < 1.5). Done on amniotic fluid prior to birth.

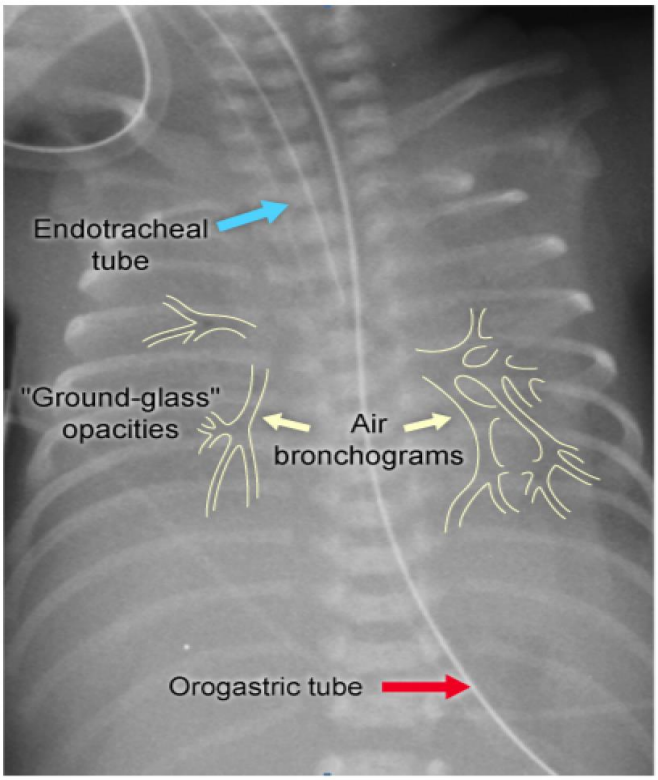

▪ Treatment:

- Best initial treatment: oxygen.

- Most effective treatment:
  - Neonatal treatment includes early continuous positive air pressure ventilation.
  - Intubation, mechanical ventilation, and exogenous surfactant therapy are reserved for severe cases.

- Primary prevention:
  - Avoid prematurity (tocolytics).
  - Antenatal betamethasone (given to women < 34 weeks gestation at increased risk for preterm delivery) which stimulate fetal surfactant synthesis and secretion.

▪ Complications:

- Hypoxemia increases the risk for persistence of patent ductus arteriosus and necrotizing enterocolitis.

- Use of concentrated oxygen therapy for neonatal respiratory distress syndrome may be complicated by retinopathy of prematurity. Retinal vessel proliferation (neovascularization) and possible retinal detachment with blindness may result.

- Lung damage leads to bronchopulmonary dysplasia:
  - Results from repeated insult to the neonatal lung from factors such as mechanical ventilation, prolonged oxygen exposure, and inflammation.
  - Persistent oxygen requirement with tachypnea, rhonchi, and radiographic findings of haziness and decreased lung volumes.
  - Surfactant therapy does not prevent BPD development but may reduce mortality from it. Most patients with BPD improve over 2-4 months; some develop pulmonary arterial hypertension.

Congenital diaphragmatic hernia (CDH)

- Congenital diaphragmatic hernia (CDH) is a defect in the diaphragm that results from incomplete fusion of the pleuroperitoneal folds during fetal development.

- Protrusion of abdominal contents through this defect (most commonly left-sided due to relative protection of right hemidiaphragm by liver) into the thoracic cavity compromises lung development, leading to pulmonary hypoplasia.

- In utero remodeling of pulmonary vasculature also leads to arterial muscular hyperplasia and persistent pulmonary hypertension.
- Shortly after birth, patients develop respiratory distress (tachypnea, cyanosis, retractions), often accompanied by absent breath sounds on the side of the hernia. A barrel-shaped chest and scaphoid abdomen (due to displaced abdominal contents) are characteristic findings.

- Bowel sounds may be heard in chest.

- <u>Diagnosis:</u>

- Prenatal ultrasound.

- Chest x-ray is diagnostic for CDH that is not detected prenatally (lack of prenatal care). Imaging shows intrathoracic bowel loops and a displaced cardiac silhouette.

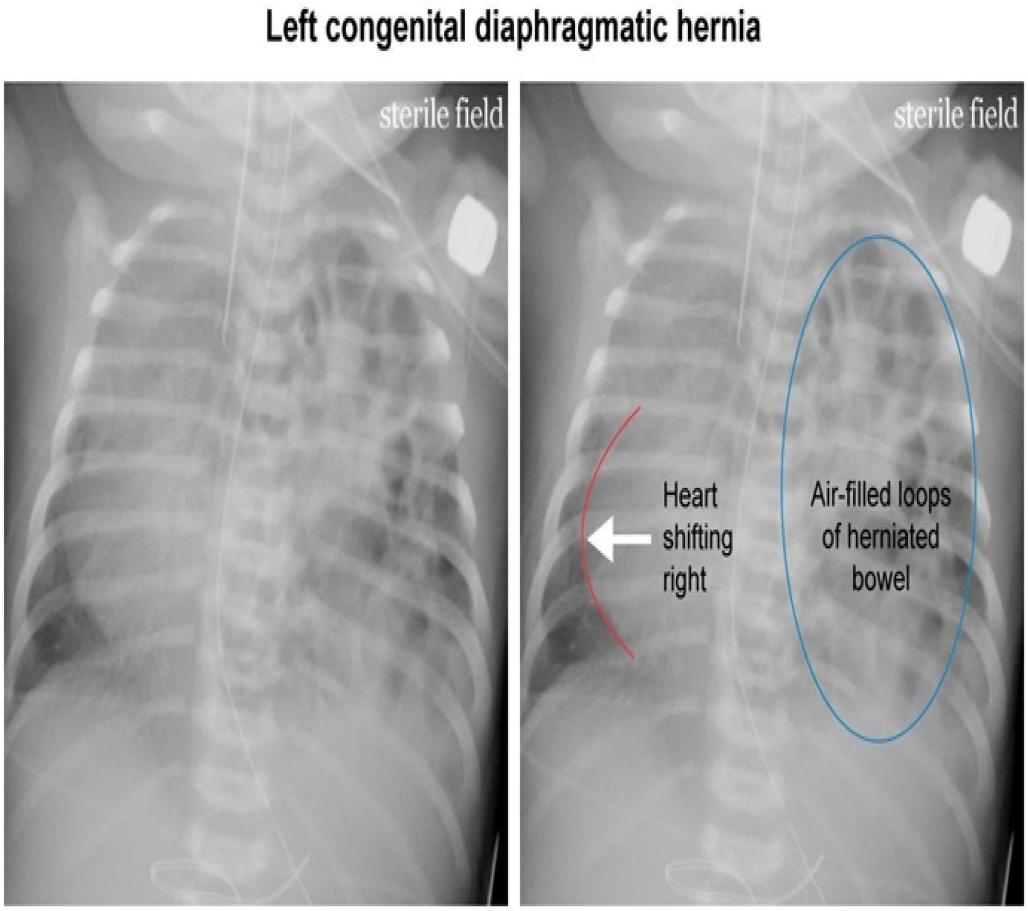

- Treatment:

- Immediate intubation in delivery room for known or suspected CDH, followed by surgical correction when stable (usually days).

- Bag-and-mask ventilation are contraindicated as these maneuvers can pump air into the gastrointestinal tract and further compromise pulmonary function. After the airway has been secured, a nasal or orogastric tube should be placed and connected to continuous suction to prevent bowel distension against the lungs.

Meconium aspiration

- Meconium passed as a result of hypoxia and fetal distress → meconium-stained amniotic fluid; may be aspirated in utero or with the first postnatal breath → airway obstruction and pneumonitis → respiratory distress and pulmonary hypertension.

- Chest x-ray (best test): patchy infiltrates, increased AP diameter, flattening of diaphragm.

- Prevention: endotracheal intubation and airway suction of depressed infants with thick meconium.

- Treatment: positive pressure ventilation.

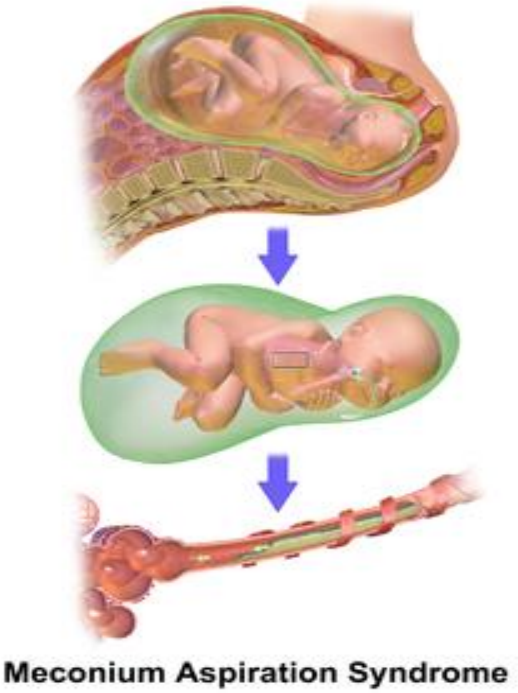
Meconium Aspiration Syndrome

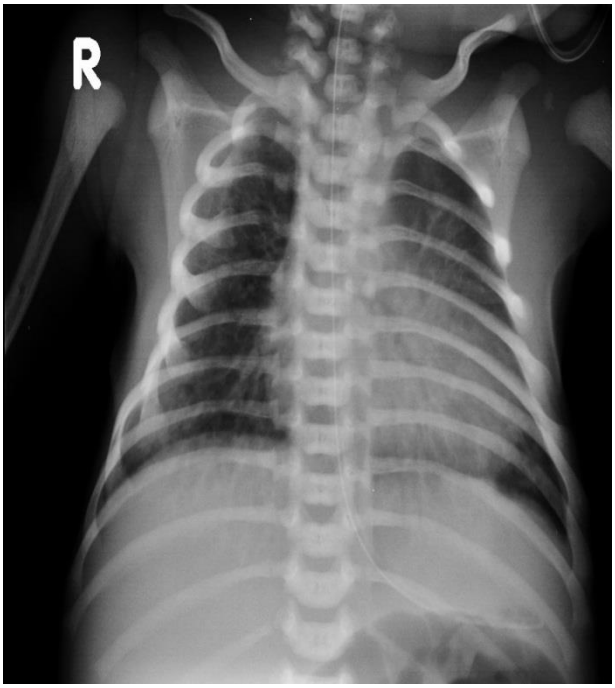

Foreign body aspiration (FBA)

- Although the differential diagnosis for respiratory distress is broad, clinical presentation of sudden-onset respiratory distress without a preceding illness and focal findings on pulmonary examination is most consistent with foreign body aspiration (FBA).
- Patients typically have acute-onset cough, dyspnea, and stridor. Wheezing may be focal or generalized, and decreased breath sounds on the affected side are characteristic. A history of choking, if witnessed, is very helpful in diagnosis.
- FBA is most common in children age 1-3 years.
- Commonly aspirated FBs include foods such as peanuts and popcorn and pieces of toys.
- More than half of aspirated FBs end up in the right mainstem bronchus; laryngeal and tracheal FBs are far less common.
- Although chest radiographs are often obtained in patients with suspected FBA, they are normal in approximately 2/3 of cases given that most aspirated objects are radiolucent.
- If an FB causes partial obstruction, with air trapping during expiration, hyperinflated lungs are seen on imaging. In contrast, complete obstruction can result in atelectasis, post-obstructive pneumonia, and/or localized bronchiectasis (late feature).
- The standard of care for both diagnosis and treatment of FBA is immediate rigid bronchoscopy to remove the foreign body.



Chest x-ray of a child after aspiration of a peanut: hyper-inflated left lung due to a valve mechanism of the peanut in the bronchus

Foreign body aspiration	
Clinical features	• Sudden-onset cough, dyspnea • Cyanosis • ± History of choking episode
Examination findings	• Wheezing and/or stridor • Focal area of diminished breath sounds
X-ray findings	• Hyperinflation of affected side • Mediastinal shift toward unaffected side • Atelectasis if obstruction is complete • ± Foreign body
Management	• Rigid bronchoscopy

Differential diagnosis of stridor

Laryngomalacia

- Laryngomalacia which causes chronic stridor in infants, is caused by "floppy" supraglottic structures (epiglottis, arytenoids) that collapse during inspiration leading to partial obstruction of the airways and thus respiratory instridor.

- Stridor from laryngomalacia usually begins in the neonatal period and is loudest at age 4-8 months.

- Presentation includes inspiratory stridor worse in the supine position and exacerbated by feeding or upper respiratory illnesses; prone positioning improves symptoms.

- <u>Diagnosis and treatment:</u>

- The diagnosis is made clinically but can be confirmed with visualization of the larynx by direct or flexible fiber-optic laryngoscopy (omega-shaped epiglottis and collapse of the supraglottic structures during inspiration).

- Most infants with laryngomalacia will feed, grow, and ventilate normally with spontaneous resolution of stridor by age 18 months. Supraglottoplasty for severe cases.

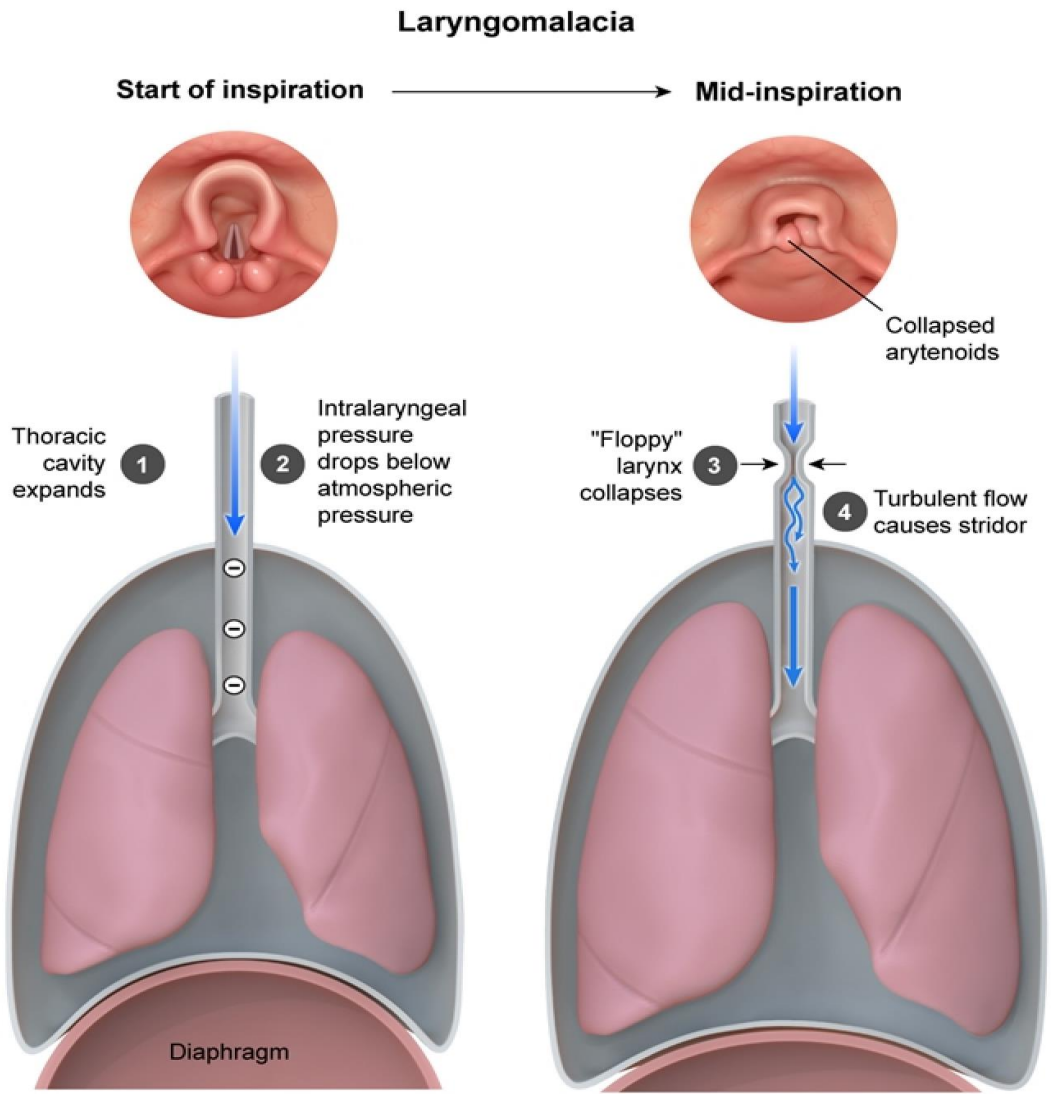

Vascular rings

- Vascular rings, or slings, result from abnormal development of the aortic arch, causing tracheal, bronchial, and/or esophageal compression.
- It is a congenital problem, which means it is present at birth.
- This happens when certain parts of the aorta that normally disappear during fetal development persist abnormally.
- They can be either complete (circumferential around the trachea and/or esophagus), such as a double aortic arch, or incomplete (pulmonary artery sling).
- Vascular rings present in patients age <1 with respiratory (stridor, wheezing, coughing) and/or esophageal (dysphagia, vomiting, difficulty feeding) symptoms.

- The stridor is often biphasic (fixed airway obstruction that leads to biphasic stridor), and improves with neck extension, which decreases tracheal compression.

- Up to 50% of patients also have a cardiac anomaly (ventricular septal defect, tetralogy of Fallot).

- Diagnosis and treatment:

- Diagnosis can be made with a CT scan to delineate the precise anatomy forming the vascular ring and evaluate any associated tracheal abnormalities.

- Due to possible concurrent cardiac and airway abnormalities, all patients require direct laryngoscopy, bronchoscopy, and echocardiogram.

- Treatment is surgical division of the structures creating the ring.

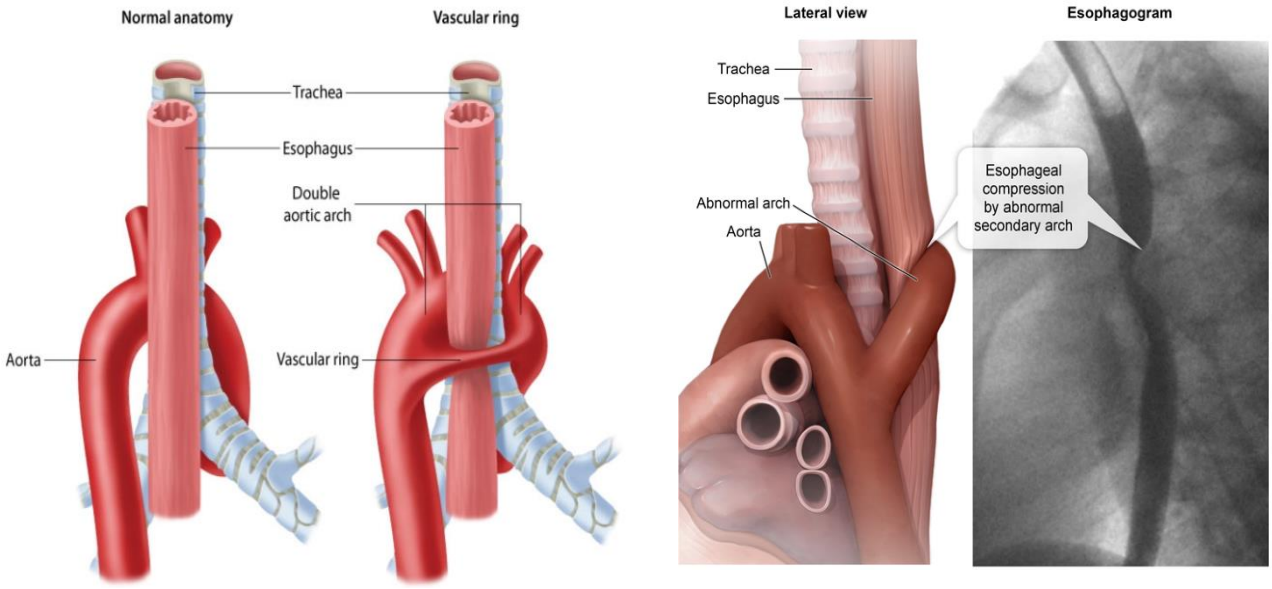

Kartagener syndrome (KS)

- Kartagener syndrome (KS) is a subgroup of primary ciliary dyskinesia (PCD [immotile-cilia syndrome]).

- PCD is an autosomal recessive disorder characterized by dysmotile cilia that result from aberrant production or attachment of ciliary dynein arms.

- These mutations result in impaired cilial function, poor mucociliary clearance of secretions, and chronic infections.

- KS is characterized by a classic triad of situs inversus, recurrent sinusitis, and bronchiectasis.

- Can result in ↓ male and female fertility due to immotile sperm and dysfunctional fallopian tube cilia, respectively; ↑ risk of ectopic pregnancy.

- The typical radiographic finding is dextrocardia (apex of the heart is in the right chest), which can be detected on physical examination by displaced heart sounds and PMI (The point of maximal impulse) to the right.

- Although there is no gold standard for diagnosis, KS can be diagnosed with a suggestive phenotype and demonstration of abnormal mucociliary transport.

Primary ciliary dyskinesia versus cystic fibrosis

	Primary ciliary dyskinesia	Cystic fibrosis
Pathogenesis	• **Dynein arm defect** → abnormal ciliary motion & impaired mucociliary clearance	• Mutation in the ***CFTR* gene** → impaired ion transport
Respiratory tract features	• Chronic sinopulmonary infections • Nasal polyps • Bronchiectasis • Digital clubbing	• Chronic sinopulmonary infections • Nasal polyps • Bronchiectasis • Digital clubbing
Extrapulmonary features	• Situs inversus (50% of cases) • Infertility due to immotile spermatozoa • Normal growth	• Pancreatic insufficiency • Infertility due to absent vas deferens (azoospermia) • Failure to thrive
Diagnosis	• Low nasal nitric oxide levels • Bronchoscopy & electron microscopic visualization of ciliary abnormalities • Genetic testing	• Elevated sweat chloride levels • Abnormal nasal transepithelial potential difference • Genetic testing

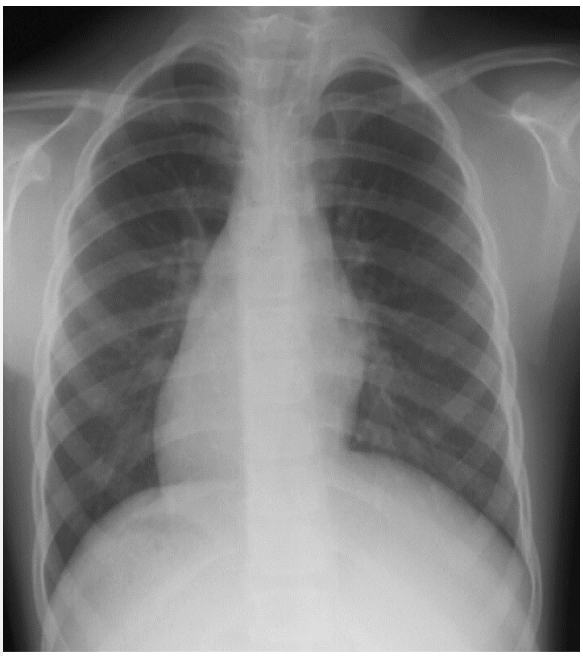

Breath-holding spell (BHS)

- Breath-holding spell (BHS) is an episode of apnea precipitated by frustration, anger, or pain.
- These spells are usually benign and occur most commonly in children age 6 months to 2 years.
- The 2 types are cyanotic and pallid and may represent a variant of vasovagal syncope due to autonomic dysfunction.
- A cyanotic BHS classically presents with crying and breath-holding in forced expiration; this is followed by apnea, limpness, and loss of consciousness. The event is brief with rapid return to baseline.
- In contrast, a pallid BHS is typically triggered by minor trauma. The child experiences fleeting loss of consciousness followed by breath-holding, pallor, and diaphoresis. This episode lasts <1 minute with subsequent confusion and sleepiness for a few minutes.
- <u>Diagnosis and treatment:</u>

- The diagnosis is based primarily on the clinical history and a normal physical examination.
- Parents should be reassured that BHS does not affect development and treatment is generally unnecessary.
- Some children experience recurrent episodes that usually stop by age 5; others develop vasovagal syncope later in life.

Breath-holding spells	
Cyanotic	Crying followed by breath-holding, cyanosis & loss of consciousness
Pallid	Minor trauma followed by breath-holding, pallor, diaphoresis, & loss of consciousness

CHAPTER 5

Pediatric Endocrinology

Endocrinology

Infants of Diabetic Mothers

- Infants of diabetic mothers (IDMs) are at increased risk for a variety of complications.
- Because glucose is actively transported across the placenta to the fetus, maternal hyperglycemia leads to fetal hyperglycemia.

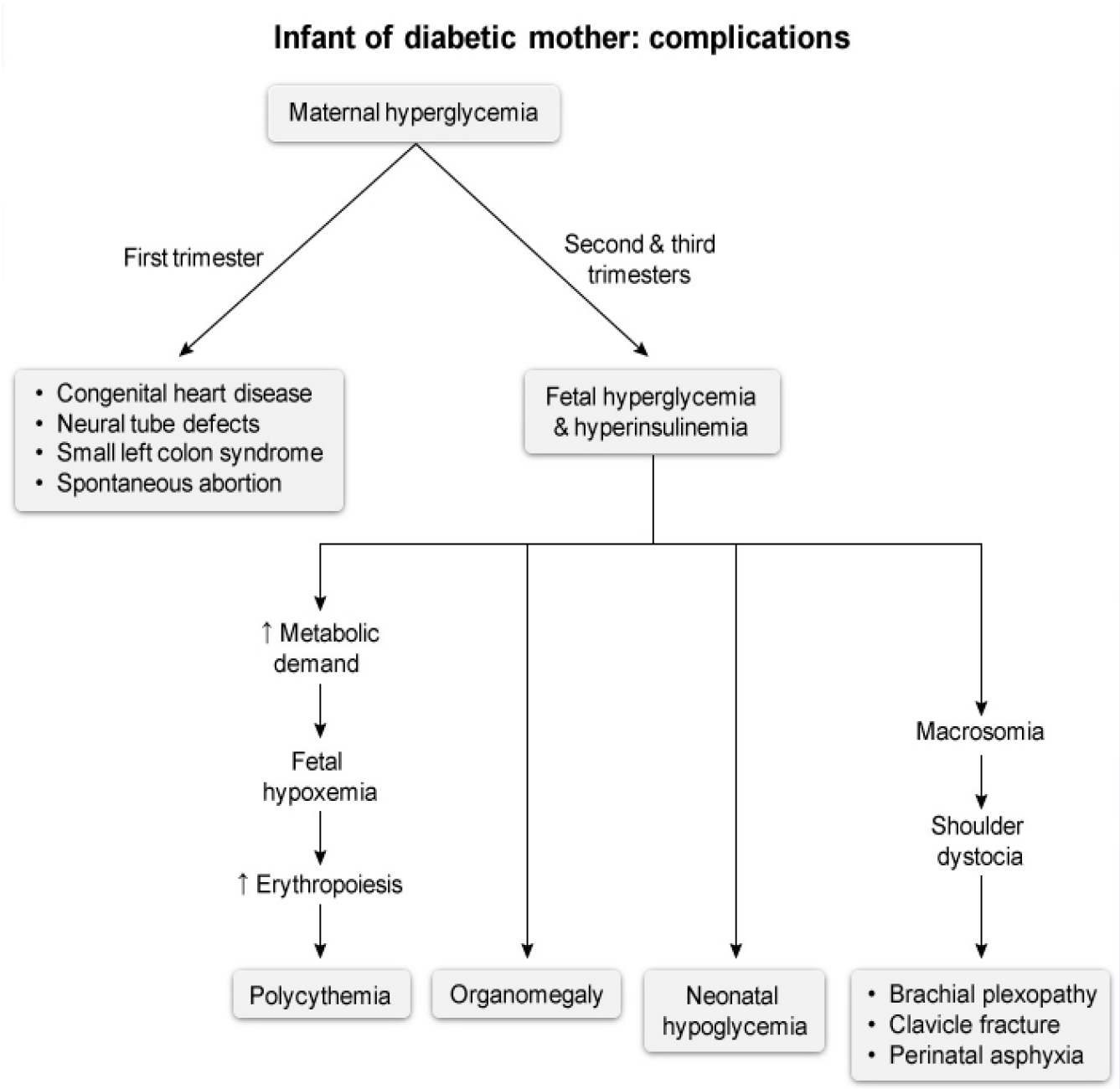

- The effects of fetal hyperglycemia vary, depending on the developmental stage of the fetus:

A. First trimester:

- The fetus cannot produce insulin during the first trimester and therefore cannot protect itself from hyperglycemia.

- Hyperglycemia during the first trimester can disrupt organogenesis, resulting in malformations (congenital heart disease, neural tube defects, small left colon syndrome).

B. Second and third trimesters:

- Once the fetal pancreas is sufficiently developed, hyperglycemia triggers the release of insulin, which results in increased glycogen and fat storage (organomegaly), increased growth factor production (macrosomia), and increased oxygen consumption (polycythemia).

C. Delivery:

- IDMs who are macrosomic are more difficult to deliver vaginally, leading to higher rates of cesarean delivery (due to failure to progress) or device-assisted delivery (forceps, vacuum).

- Clavicle fractures, brachial plexus injuries, and asphyxia are associated with macrosomia.

D. After delivery:

- Fetal insulin production takes time to decrease after delivery, but maternal glucose exposure ends as soon as the umbilical cord is clamped.

- This often results in a period of neonatal hypoglycemia until insulin levels normalize.

- Hypoglycemia is the most common complication among IDMs.

- Findings in IDM:

A. Macrosomia:

- With macrosomia, all organs are enlarged except for the brain.

- An increased output from the bone marrow leads to polycythemia and hyperviscosity.

- Possible shoulder dystocia and brachial plexus palsy can also be in the history.

B. Small Left Colon Syndrome:

- A congenitally smaller descending colon leads to distension from constipation.

- It can be diagnosed by a barium study and treated with smaller and more frequent feeds.

C. Cardiac Abnormalities:

- The major cardiac change in IDM is asymmetric septal hypertrophy due to obliteration of the left ventricular lumen, leading to decreased cardiac output.

- It is diagnosed with EKG and echocardiography and treated with beta blockers and IV fluids.

D. Renal Vein Thrombosis:

- Flank mass and possible bruit can be appreciated.

- Hematuria and thrombocytopenia.

E. Metabolic Findings and Effects:

- Hypoglycemia: seizures.

- Hypomagnesemia: hypocalcemia and PTH decrease.

- Hypocalcemia: tetany, lethargy.

- Hyperbilirubinemia: icterus and kernicterus.

Congenital Adrenal Hyperplasia (CAH)

- Congenital adrenal hyperplasia (CAH) is a group of disorders due to enzyme deficiencies for cortisol synthesis in the adrenal cortex that has 3 forms:

- 21-hydroxylase (the most common).
- 17 hydroxylase.
- 11 -beta-hydroxylase.

- Approximately 90% of cases are due to 21- hydroxylase deficiency, which is involved in the cortisol and aldosterone pathways.

- The low plasma cortisol stimulates the pituitary to increase ACTH production, which leads to adrenal hyperplasia.

- Presentation:

- 21-hydroxylase deficiency prevents progesterone and 17-hydroxyprogesterone from being converted into aldosterone and cortisol, respectively.

- This leads to a mineralocorticoid deficit (hypotension, hyponatremia, hyperkalemia), while the resulting buildup of 17-hydroxyprogesterone is instead shunted toward adrenal androgen synthesis (virilization of females).

- Clinical manifestations depend on the degree of enzyme deficiency:

A. Severe (classic) 21- hydroxylase deficiency:

- Present at birth with salt-wasting, dehydration, and ambiguous genitalia in females.

B. Non-classic (late-onset) 21- hydroxylase deficiency:

- In contrast, the enzyme deficiency in non-classic (late-onset) CAH is relatively mild.
- Females typically present in their teens or twenties with medication-resistant acne, irregular menses, and hirsutism; virilization is not seen.
- Boys usually present with precocious puberty.
- Hyponatremia is variable in both sexes.

- Diagnostic Tests:

- Significantly increased levels of 17-hydroxyprogesterone are diagnostic for classic CAH, although the cosyntropin stimulation test remains the gold standard for diagnosis of suspected partial deficiencies.

- Treatment:

- Fluid and electrolyte replacement along with lifelong steroids to maintain adequate levels of mineralocorticoid/glucocorticoid levels.

- Specific psychiatric counseling to aid with gender identity issues.

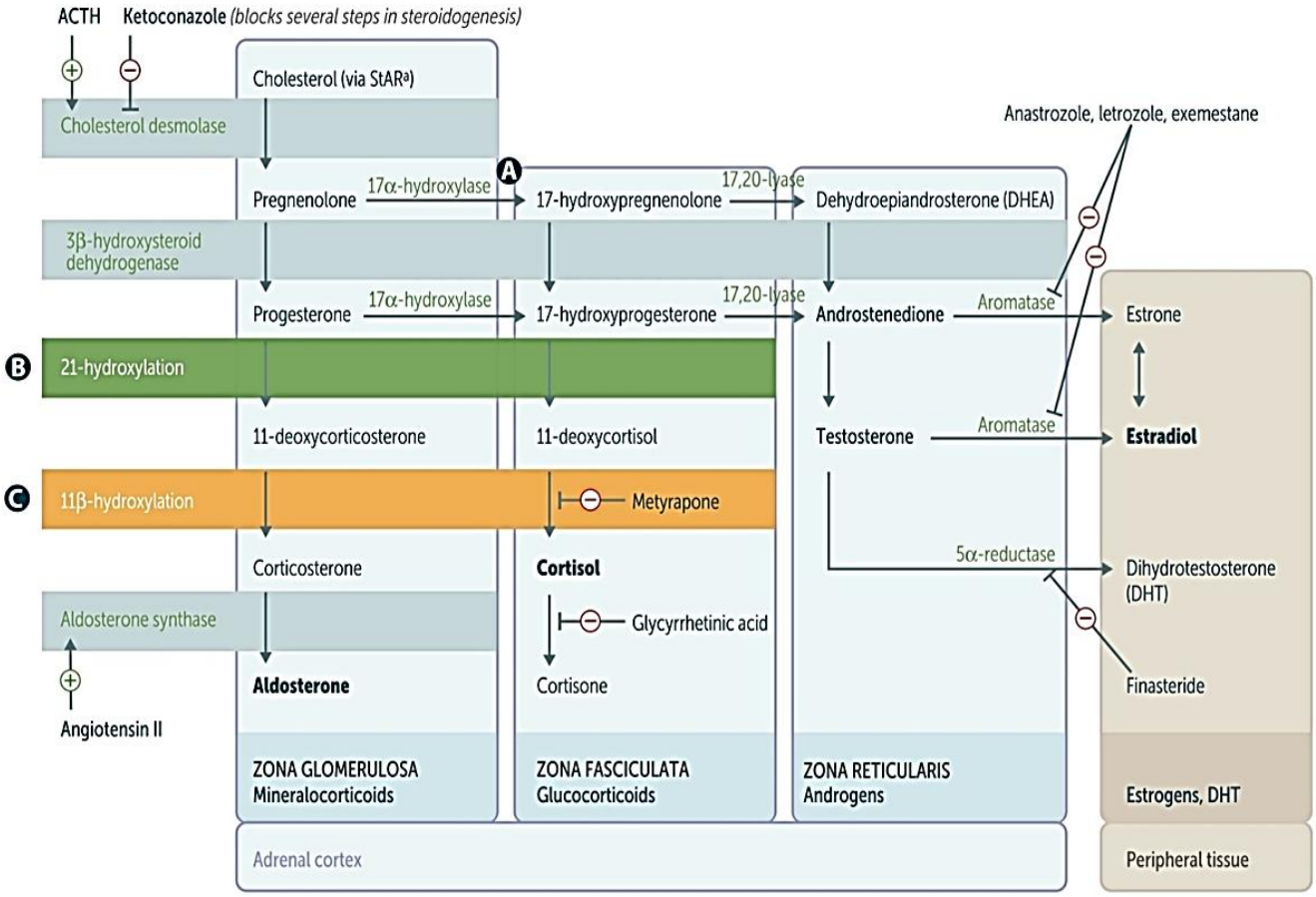

[a]Rate-limiting step.

Enzyme deficiency	Hormonal abnormalities	Symptoms
21-hydroxylase	• ↓ Cortisol & aldosterone • ↑ Testosterone • ↑ 17-hydroxyprogesterone	• Ambiguous genitalia in girls • Salt wasting (vomiting, hypotension, ↓Na^+, ↑K^+)
11β-hydroxylase	• ↓ Cortisol & aldosterone • ↑ Testosterone • ↑ 11-deoxycorticosterone (weak mineralocorticoid) & 11- deoxycortisol	• Ambiguous genitalia in girls • Fluid & salt retention, hypertension
17α-hydroxylase	• ↓ Cortisol & testosterone • ↑ Mineralocorticoids • ↑ Corticosterone (weak glucocorticoid)	• All patients phenotypically female • Fluid & salt retention, hypertension

Precocious puberty

- Precocious puberty is defined as the development of secondary sex characteristics before the age of 8 in girls and 9 in boys.

- Precocious puberty is more common in girls than boys.

- Accelerated bone growth and advanced bone age are also common.

Diagnosis	Female secondary sexual characteristics Accelerated growth <8 years of age in girls	
Normal pubertal landmarks	Thelarche Breast development	9–10 years
	Adrenarche Pubic and axillary hair	10–11 years
	Maximal growth Growth spurt	11–12 years
	Menarche Onset of first menses	12–13 years

- Classification of precocious puberty:

A. Incomplete Precocious Puberty:

- This involves only one change (either thelarche, adrenarche, or menarche).

- This condition is the result of either transient hormone elevation or unusual end-organ sensitivity.

- Management is conservative.

B. Complete Precocious Puberty:

- All changes of puberty are seen including breast development, growth spurt, and menstrual bleeding.

- The primary concern is premature closure of the distal epiphyses of the long bones, resulting in short stature.

- The causes of Complete precocious puberty can be broken into two categories (central and peripheral):

A. Central precocious puberty:

- It is the result of premature activation of the hypothalamic-pituitary-ovarian (HPO) axis.

- Therefore, FSH and LH levels are elevated in central precocious puberty.

- Causes:

1. Idiopathic:

- The most common explanation is constitutional without a pathologic process present, accounting for 80% of precocious puberty.
- The diagnosis is usually one of exclusion after CNS imaging is shown to be normal.
- Management is GnRH agonist suppression (leuprolide) of gonadotropins until appropriate maturity or height has been reached.

2. CNS pathology:

- This is a rare cause of precocious puberty.
- A CNS pathologic process stimulates hypothalamic release of GnRH.
- This may include hydrocephalus, meningitis, sarcoid, and encephalitis.
- CNS imaging is abnormal.
- Management is directed at the specific pathologic process.

B. Peripheral precocious puberty:

- Peripheral precocious puberty is caused by gonadal or adrenal release of excess sex hormones.

- Patients with peripheral precocious puberty present with low FSH and LH levels.

- Causes:

1. McCune-Albright syndrome:

- This disorder is characterized by autonomous stimulation of aromatase enzyme production of estrogen by the ovaries.

- Management is administration of an aromatase enzyme inhibitor.

2. Granulosa cell tumor:

- A rare cause of precocious puberty is a gonadal-stromal cell ovarian tumor that autonomously produces estrogen.

- A pelvic mass will be identified on examination or pelvic imaging.

- Management is surgical removal of the tumor.

3. Congenital adrenal hyperplasia (21, 17 hydroxylase enzyme deficiency).

4. Exogenous testosterone.

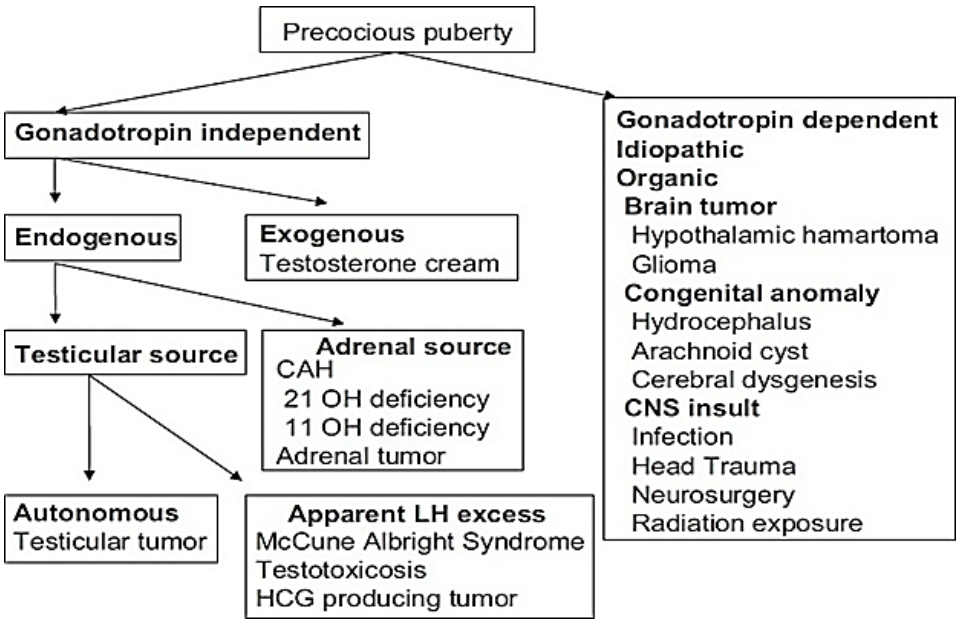

- Diagnosis:

- Patients with precocious puberty are initially assessed by obtaining a bone age, which differentiates true precocious puberty (advanced bone age) from an isolated premature thelarche/adrenarche (normal bone age).

- In patients with advanced bone age (>2 standard deviations above chronological age), LH levels differentiate between peripheral and central precocious puberty.

- Luteinizing hormone (LH) levels should be measured before and after gonadotropin-releasing hormone (GnRH) stimulation to determine whether the patient's precocious development is peripheral or central.

- In gonadotropin-independent (peripheral) precocious puberty, luteinizing hormone levels are low at baseline and do not increase after stimulation with a gonadotropin-releasing hormone agonist.

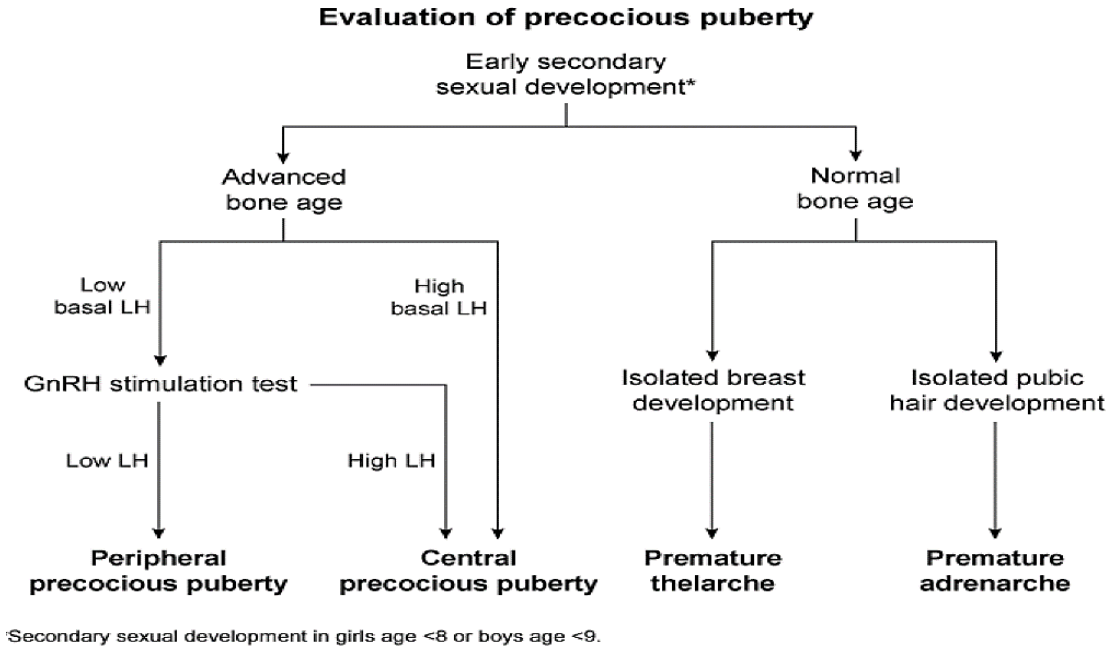

- Treatment:

- Precocious puberty is an important medical and psychosocial issue, as affected children appear different than their peers and physical changes precede emotional maturity.

- The primary treatment option for idiopathic GDPP is GnRH agonist therapy to prevent premature epiphyseal plate fusion and maximize adult height potential.

Management of Precocious Puberty

Idiopathic	GnRH agonist
CNS lesions	Medical or surgical treatment
Ovarian tumor	Surgical excision
McCune-Albright	Aromatase inhibitors

❖ N.B:

- Obese children of all ethnicities are also at high risk for precocious development as increased adiposity can stimulate sexual hormone production centrally and peripherally.

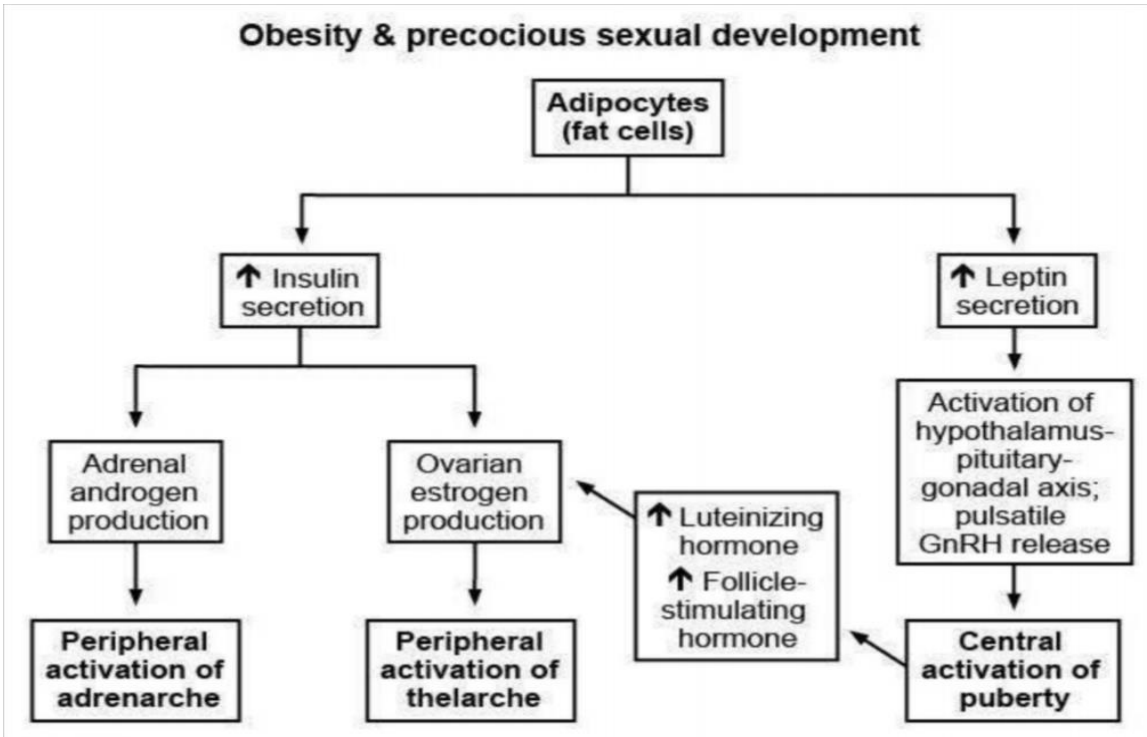

McCune-Albright syndrome

- McCune-Albright syndrome is sporadic and has been recently attributed to a defect in the G-protein cAMP-kinase function in the affected tissue, thereby resulting in autonomous activity of that tissue.
- McCune-Albright syndrome is a rare condition characterized by precocious puberty, cafe au lait spots and multiple bone defects (polyostotic fibrous dysplasia).
- Remember the 3 P's precocious puberty, pigmentation (cafe au lait spots confined to one side of the body) and polyostotic fibrous dysplasia (bone is replaced by fibrous tissue, leading to weak bones, uneven growth, and deformity).
- It is responsible for 5% of the cases of female precocious puberty.
- In addition to GnRH-independent (peripheral) precocious puberty (FSH, LH), MAS can also lead to thyrotoxicosis (TSH), acromegaly (GH), and Cushing syndrome (ACTH).

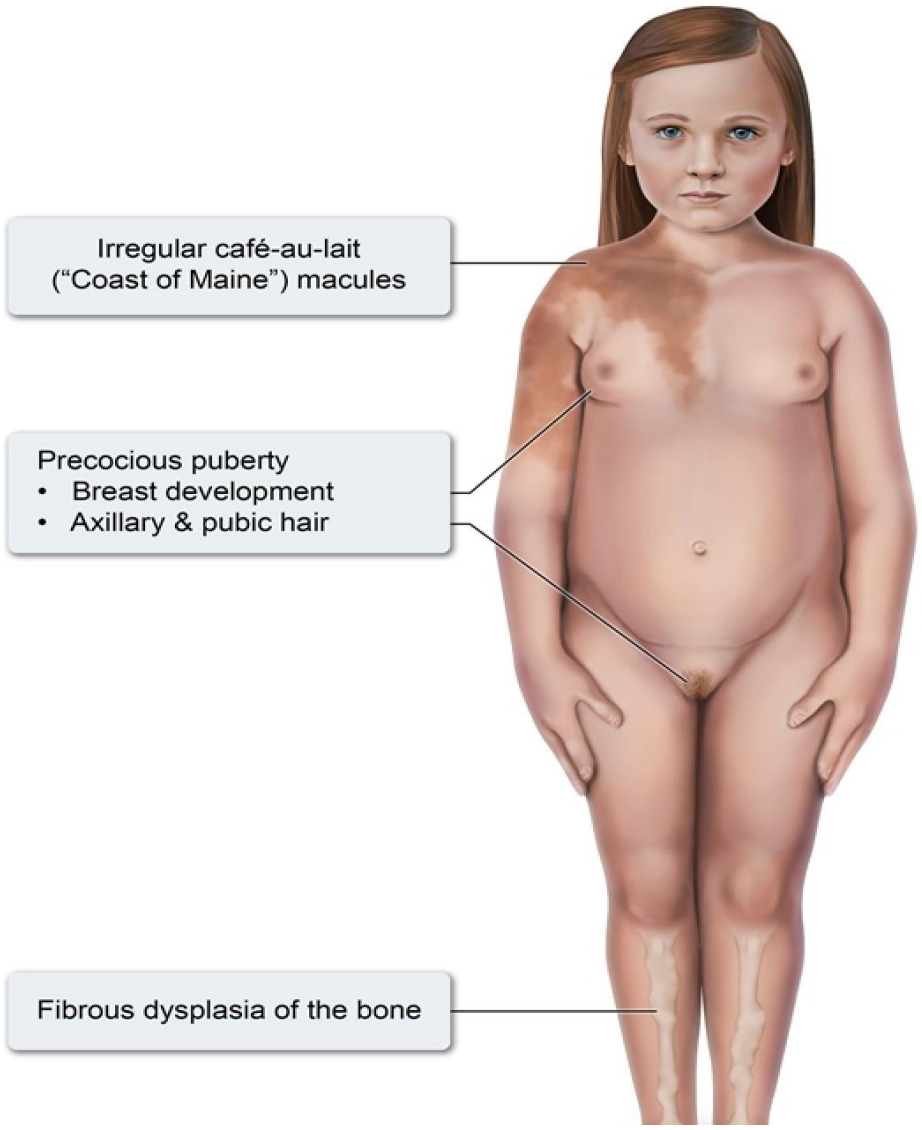

Physiologic Gynecomastia

- Gynecomastia is enlarged benign glandular tissue of the male breast.
- It can occur in up to 2/3 of pubertal boys and present as small (<4 cm), fiem, unilateral or bilateral firm subareolar nodules (sometimes tender to the touch).
- The breast development is due to transiently increased testicular production of estrogen over testosterone and peripheral conversion of prohormones to estrogen.

Pubertal gynecomastia	
Etiology	• Imbalance of estrogens & androgens during mid-puberty (Tanner stage 3-4)
Clinical features	• Small (<4 cm), firm, unilateral or bilateral subareolar mass • No pathologic features (eg, nipple discharge, axillary lymphadenopathy, systemic illness)
Management	• Reassurance & observation • Resolves within 1 year

- No workup or treatment is necessary as it usually resolves within a few months to 1 year.

❖ N.B:

- Mammary gland enlargement, non-purulent vaginal discharge (leukorrhea), and mild uterine withdrawal bleeding are benign transient findings commonly seen in newborns; these are physiologic responses to transplacental maternal estrogen exposure.
- Work-up is unnecessary. Routine care and reassurance should be provided.

Maternal estrogen effects in newborns
• Breast hypertrophy (girls & boys) • Swollen labia • Physiologic leukorrhea (whitish vaginal discharge) • Uterine withdrawal bleeding

Congenital hypothyroidism

- Congenital hypothyroidism may be familial or sporadic.
- The most common cause is thyroid dysgenesis (aplasia, hypoplasia, or ectopic gland), which has been incriminated in 85% of cases.
- Other causes include inborn errors of thyroxin synthesis (10%), and transplacental maternal thyrotropin-receptor blocking antibodies (5%).
- Congenital hypothyroidism is associated with neurodevelopmental injury if not recognized and treated early. For this reason, screening is mandated in all states at birth to allow for the early detection, treatment, and consequent improvement of the prognosis. Screening is done by measuring serum T4 and TSH levels.
- Infants initially appear normal at birth (due to the presence of moderate amounts of maternal hormones in the infant's circulation), but gradually develop apathy, weakness, hypotonia, large tongue, sluggish movement, abdominal bloating, and an umbilical hernia.
- Other signs include pathologic jaundice, difficult breathing, noisy respiration, hypothermia, and refractory macrocytic anemia.
- Prompt recognition and thyroid hormone replacement (levothyroxine) is necessary to prevent permanent neurodevelopmental injury.

Congenital hypothyroidism	

Clinical manifestations	• Initially normal at birth
	• Symptoms develop after maternal T_4 wanes:
	  ◦ Lethargy
	  ◦ Enlarged fontanelle
	  ◦ Protruding tongue
	  ◦ Umbilical hernia
	  ◦ Poor feeding
	  ◦ Constipation
	  ◦ Dry skin
	  ◦ Jaundice

Diagnosis	• ↑ TSH & ↓ free T_4 levels • Newborn screening
Treatment	• Levothyroxine



Neuroblastoma

- The tumor arises from neural crest cells, which are also the precursor cells of the sympathetic chains and adrenal medulla. For this reason, NBL may arise from the adrenal gland or any location along the paravertebral sympathetic chains.
- Neuroblastoma is an adrenal medulla tumor similar to a pheochromocytoma but with fewer cardiac manifestations (Neuroblastoma is Normotensive). Can also present with opsoclonus-myoclonus syndrome ("dancing eyes-dancing feet").
- Neuroblastoma (NBL) is the most common extracranial solid tumor of childhood.
- The median age at diagnosis is 2 years.
- The most common site involved is the abdomen, either from the adrenals or retroperitoneal ganglia.
- The mass is usually firm and nodular in consistency that can cross the midline (vs Wilms tumor, which is smooth and unilateral). Calcifications and hemorrhages are seen on plain x-ray and CT scan.
- Up to 70 percent of patients have metastatic disease at the time of initial presentation, and the most common metastatic sites are the long bones, skull, bone marrow, liver, lymph nodes and skin.
- The levels of serum and urine catecholamines and their metabolites (HVA and VMA) are usually elevated; however, patients do not present with fainting spells, sweating, palpitations and hypertension, as in pheochromocytoma.
- The prognosis depends on clinical factors, tumor histology and genetic characteristics (amplification of N-myc proto-oncogene).

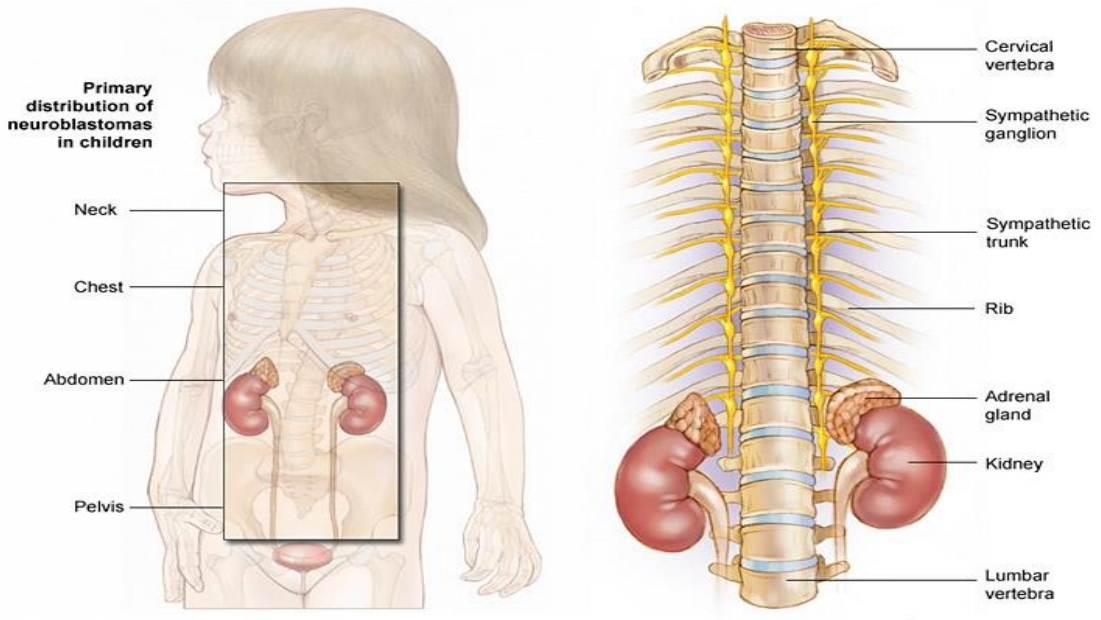

CHAPTER 6

Abnormal Genitourinary Findings

Abnormal Genitourinary Findings

Cryptorchidism

- Cryptorchidism is the most common congenital anomaly of the genitourinary tract due to failure of testicular descent from the abdomen into the scrotum.
- Most boys with unilateral cryptorchidism have no other anomalies, but bilateral cryptorchidism may be one of many manifestations of an endocrinopathy or genetic syndrome.
- Regular scrotal examination should be performed on all boys to evaluate testicular location and scrotal appearance.
- The normal scrotum is thick and rugated and contains palpable testes. Testicles that have not descended by age 6 months are unlikely to descend spontaneously and require surgery.
- Orchiopexy is optimally performed before age 1 year to prevent testicular torsion, improve fertility, and decrease the risk of testicular malignancy.

Cryptorchidism	
Risk factors	• Prematurity • Small for gestational age • Low birth weight (<2.5 kg [5.5 lb]) • Genetic disorders
Clinical features	• Empty, hypoplastic, poorly rugated scrotum or hemiscrotum • ± Inguinal fullness
Treatment	• Orchiopexy before age 1 year
Complications	• Inguinal hernia • Testicular torsion • Subfertility • Testicular cancer



❖ N.B:

- Undescended testis raises concern for torsion of an intraabdominal testis, a potential complication of cryptorchidism.
- Twisting of the spermatic cord; thin-walled veins become obstructed leading to congestion and infarction.
- Torsion is 10 times more likely in an undescended testis compared with that of a scrotal testis.
- Torsion of an intraabdominal testis typically presents with acute, severe abdominal pain and vomiting.
- Although older children may localize pain, infants may have irritability and inconsolable crying because of the pain.
- Torsion of an undescended testis in the inguinal canal can cause inguinal swelling and pain.
- Emergency surgical detorsion and orchiopexy are indicated to salvage the testis. Torsion of undescended testes has a lower salvage rate than torsion of scrotal testes.

Hydrocele

- Hydrocele is a painless, swollen fluid-filled sac along the spermatic cords within the scrotum that transilluminates upon inspection.
- Hydrocele is a fluid collection within the processus or tunica vaginalis (the peritoneal projection that accompanies the testis during its descent into the scrotum).
- When the processus vaginalis fails to obliterate, peritoneal fluid may accumulate within the processus vaginalis causing a communicating hydrocele.
- A collection of fluid within a tunica vaginalis that has properly obliterated its communication with the peritoneum is a noncommunicating hydrocele.
- Hydrocele can be differentiated from other testicular masses by transillumination; a hydrocele will transilluminate while other masses will not.
- Most hydroceles, both communicating and noncommunicating, will resolve spontaneously by the age of 12 months and can be safely observed during that period.
- Hydroceles that do not resolve spontaneously should be removed surgically due to the risk of inguinal hernia.
- Hydrocele and indirect inguinal hernia are formed by a similar mechanism. Both conditions are caused by incomplete obliteration of the processes vaginalis.
- Hydrocele occurs when there is a connection between the scrotum and abdominal cavity that only allows for the leakage of fluid; whereas a hernia occurs when the opening allows the protrusion of abdominal organs along the inguinal canal.

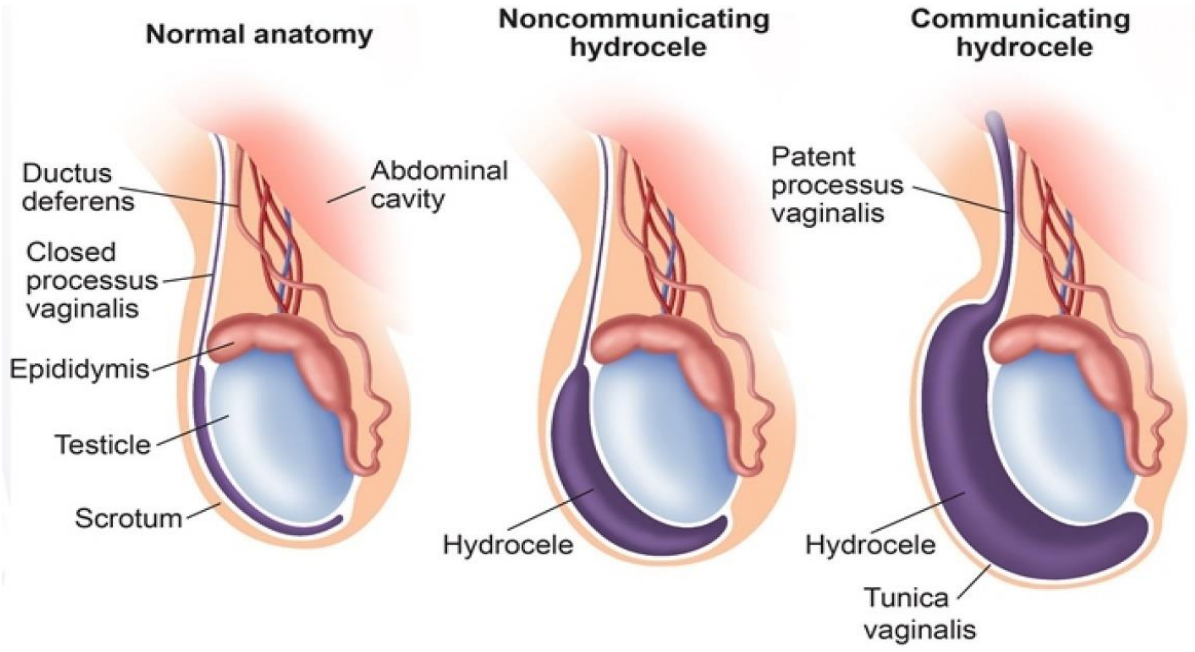

Varicocele

- Varicocele is a varicose vein in the scrotal veins causing swelling of pampiniform plexus and increased pressure.
- The most common complaint is dull ache and heaviness in the scrotum.
- Physical exam coinciding with a "bag of worms" sensation that does not transilluminate.
- Types:

Varicocele		
	Primary	**Secondary**
Pathophysiology	• Compression of left renal vein between SMA and aorta • Incompetent venous valves	• Extrinsic compression (renal or retroperitoneal mass) of IVC • Venous thrombus
Clinical features	• "Bag of worms" mass • Pubertal onset • Left-sided • Decompresses when supine	• "Bag of worms" mass • Prepubertal onset • Right-sided • Persists when supine
Initial management	• Reassurance and observation	• Abdominal ultrasound
IVC = inferior vena cava; **SMA** = superior mesenteric artery.		

A. Primary/idiopathic type:

- Most varicoceles are primary/idiopathic due to compression of the left renal vein (which drains the spermatic [gonadal] vein) between the superior mesenteric artery and aorta.
- Increased pressure in the spermatic vein leads to retrograde blood flow, incompetent valves within the vein, and venous dilation.
- Typical presentation of a primary varicocele is an irregular, left-sided scrotal mass in an adolescent or adult patient that increases with standing/Valsalva maneuver and decompresses in the supine position.

B. Secondary type:

- Varicocele that is secondary to venous thrombus or extrinsic compression of the inferior vena cava (IVC) by an abdominal mass (renal or retroperitoneal tumor) is less common but should be considered in the following circumstances:
  - Prepubertal boy.
  - Right-sided mass.
  - Mass that fails to decrease in size when supine.
- The next step in management is an abdominal ultrasound to assess for a secondary cause.
- Treatment is indicated for delayed growth of the testes or in those with evidence of testicular atrophy.

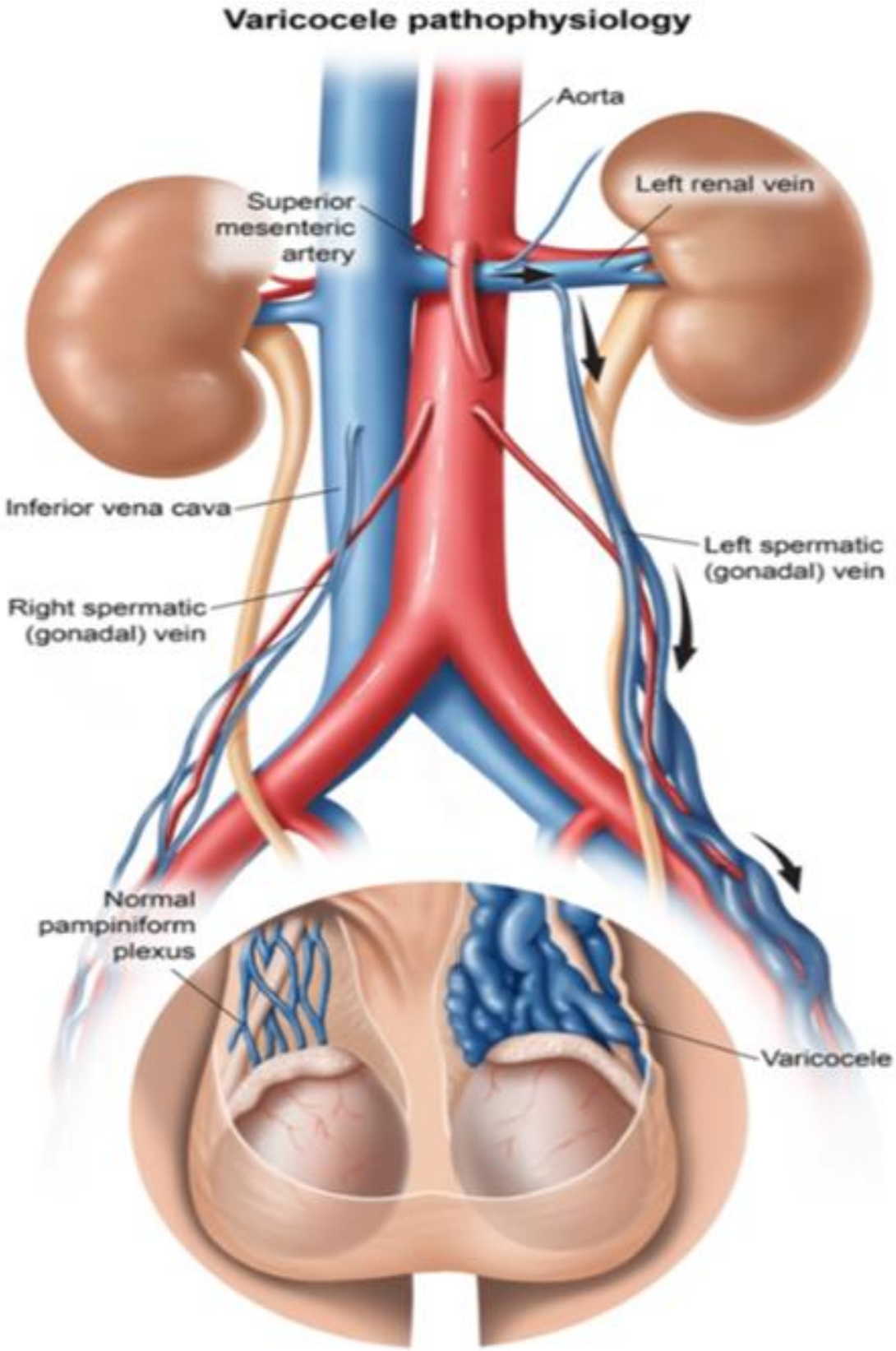

The aorta & superior mesenteric artery compress the left renal vein. The increased pressure in the left renal vein causes retrograde blood flow to testes & dilation of the pampiniform plexus.

Wilms Tumor (Nephroblastoma)

- Wilms tumor (nephroblastoma) is the most common primary renal neoplasm of childhood.
- "Loss of function" mutations of tumor suppressor genes WT1 or WT2 on chromosome 11.
- It is usually diagnosed at age 2-5 years and affects a single kidney.
- Usually sporadic, but may be associated with:
  - Wilms tumor, Aniridia, Genitourinary malformations, and mental Retardation is referred to as WAGR syndrome. Aniridia is highly associated with this malignancy and is usually the clinician's most valuable clue.
  - Beckwith-Weidmann syndrome.
  - Denys-Drash syndrome.
- It should be suspected in a toddler with a firm, smooth, unilateral abdominal mass that doesn't cross the midline and hematuria.
- The most common presentation is an asymptomatic abdominal mass that is found incidentally by a caretaker or physician. Some patients have abdominal pain, hypertension, hematuria, and fever. Less than 10% of patients have bilateral renal involvement (stage V disease).
- Although the lungs are the most common site of metastatic spread, children rarely present with pulmonary symptoms.
- Diagnostic Tests:
  - Wilms tumor is diagnosed with abdominal ultrasonography, which is the best initial imaging study.
  - Contrast-enhanced CT is the most accurate test to evaluate the nature and extent of the mass and of the chest to identify any pulmonary metastases.

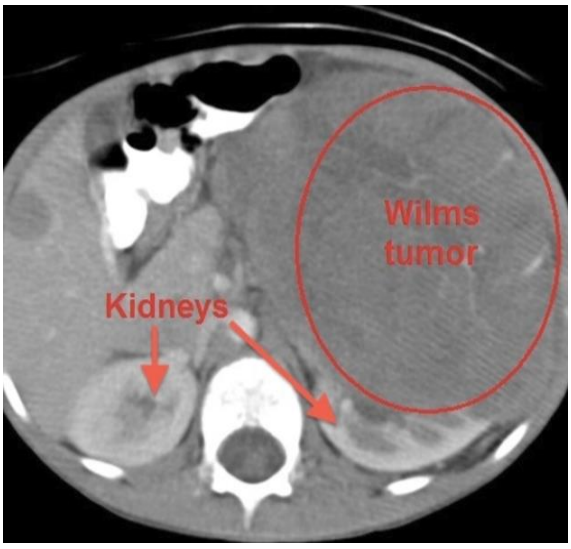

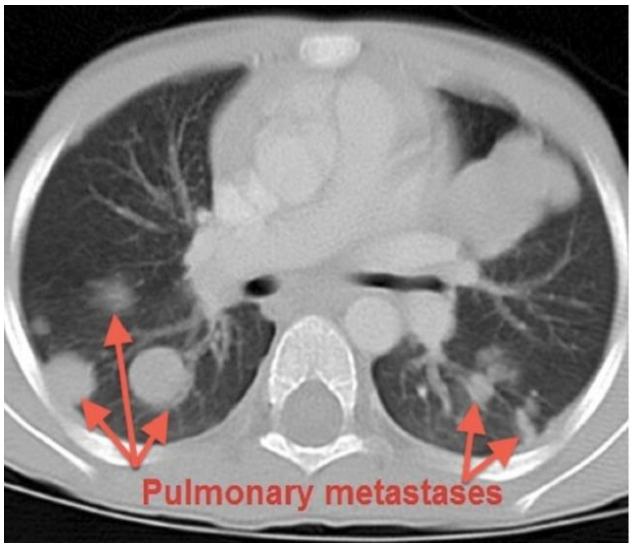

- Treatment:

- Total nephrectomy with chemotherapy and radiation may be indicated based upon staging.

- Bilateral kidney involvement indicates partial nephrectomy.

- Survival rates are excellent especially if treated in the early stages.

Hypospadias

- With hypospadias, the opening of the urethra is found on the ventral surface of the penis due to failure of urethral folds to fuse.

- Hypospadias is more common than epispadias.

- Diagnosis is clinical, and further workup is not required in cases of isolated hypospadias.

- The degree of fusion determines the location of the urethral meatus, and in severe cases the urethral opening is located on the perineum or scrotum. Patients with severe hypospadias may also have an underdeveloped penis with a small glans and/or severe penile curvature.

- In some cases, severe hypospadias can be indicative of a disorder of sex development (androgen receptor mutation). About 10% of hypospadias cases are associated with cryptorchidism (undescended testis), and the condition may represent either virilization of a genotypic female (XX) or undervirilization of a genotypic male (XY). Therefore, the first step in evaluation is karyotype analysis.

- Hypospadias can generally be repaired surgically to allow normal urination and sexual activity.

- The first step in management of hypospadias is urologic evaluation as most cases require surgical correction. Circumcision is deferred until after evaluation because the foreskin may be required in future hypospadias repair.

Hypospadias	
Pathogenesis	• Failure of urethral folds to fuse
Clinical features	• Ventrally displaced urethral meatus • Dorsal hooded foreskin • ± Underdeveloped penis & glans • ± Penile curvature (chordee)
Management	• Defer circumcision • Urologic evaluation for surgical repair • ± Karyotype, pelvic ultrasound (if severe)

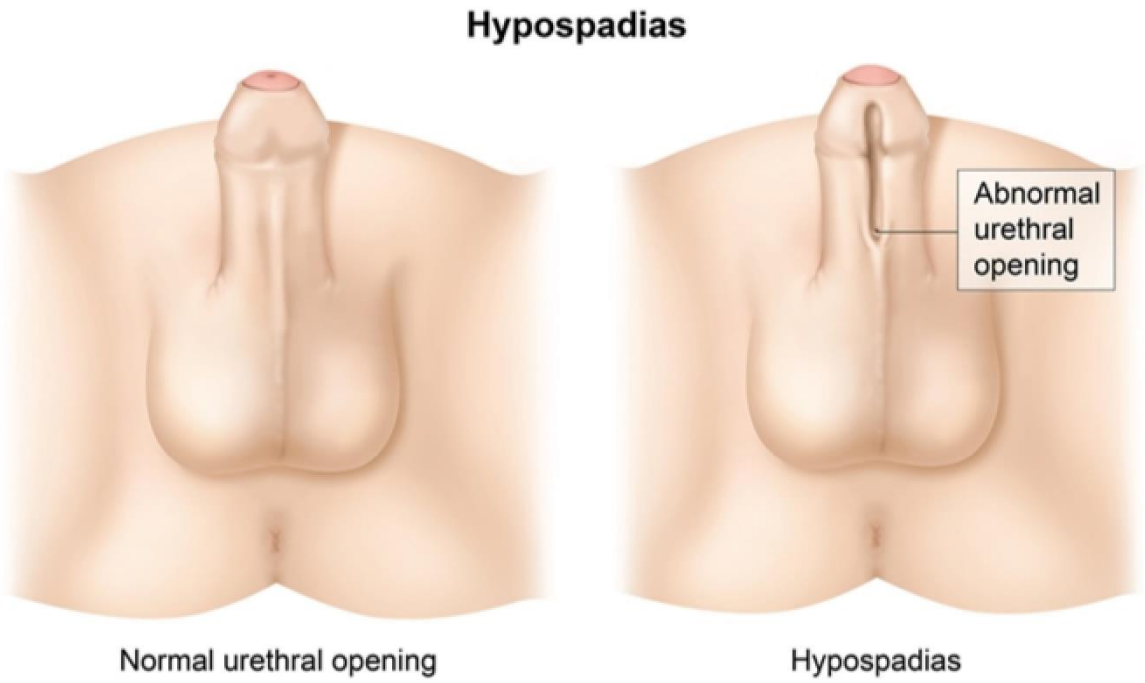

Epispadias

- With epispadias, the opening to the urethra is found on the dorsal surface of the penis due to faulty positioning of genital tubercle.
- Exstrophy of the bladder is associated with Epispadias. Must evaluate for concomitant bladder exstrophy.
- Surgical correction.



Vesicoureteral reflux

- Vesicoureteral reflux is the most common pediatric urologic problem and is present in ~30%-45% of children with recurrent urinary tract infections (UTI).
- Normal urine should have unidirectional flow from the kidneys, ureters, bladder, and out the urethra.
- Patients with severe VUR have urinary reflux from the bladder into the kidney, and the regurgitant urine causes dilation of the ureters (hydroureter) and kidneys (hydronephrosis).
- Recurrent and/or chronic pyelonephritis can lead to blunting of calices (calyceal clubbing) and focal parenchymal scarring.
- Complications include parenchymal scarring, hypertension, and renal insufficiency.
- Recurrent urinary tract infections (UTIs) in infants and children are a serious problem as they often involve the kidney and signify a congenital urinary tract anomaly.
- Vesicoureteral reflux (VUR) is a risk factor for recurrent urinary tract infections (UTIs), which can lead to progressive renal scarring. As such, all children with a first febrile UTI at age 2-24 months should undergo a renal ultrasound to evaluate for anatomic abnormalities. Those with recurrent UTIs should also undergo a voiding cystourethrogram to evaluate for VUR.
- Diagnosis and treatment:

- The definitive diagnosis of VUR is made by contrast voiding cystourethrogram.
- Renal ultrasound is performed to screen for hydronephrosis.
- Renal scintigraphy with dimercaptosuccinic acid is the preferred modality for long-term evaluation for renal scarring.
- Renal function should be followed by serial creatinine.

Vesicoureteral reflux in children	
Pathogenesis	• Retrograde flow of urine
Presentation	• Febrile urinary tract infection
Diagnostic findings	• Renal ultrasound: hydronephrosis • Voiding cystourethrogram: ureteral filling ± dilated collecting system
Management	• Antibiotic prophylaxis • Surgical correction if persistent

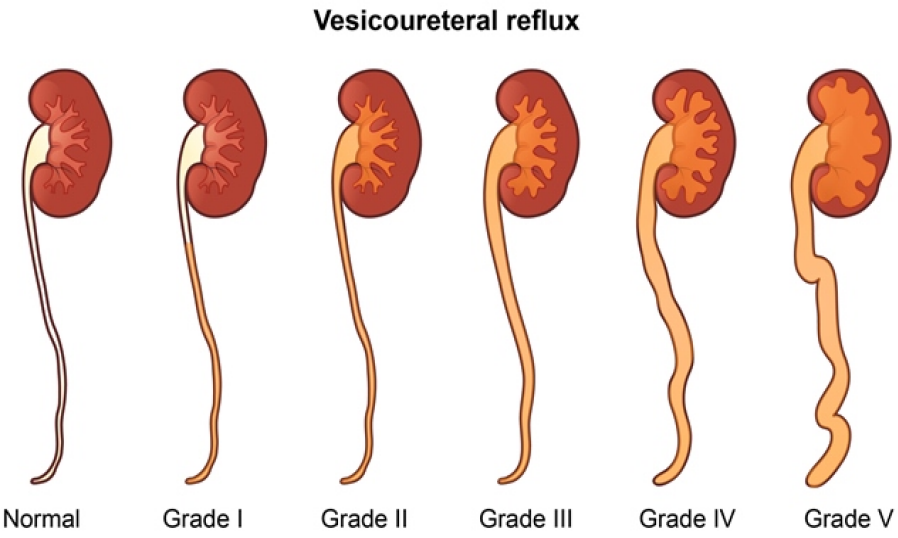

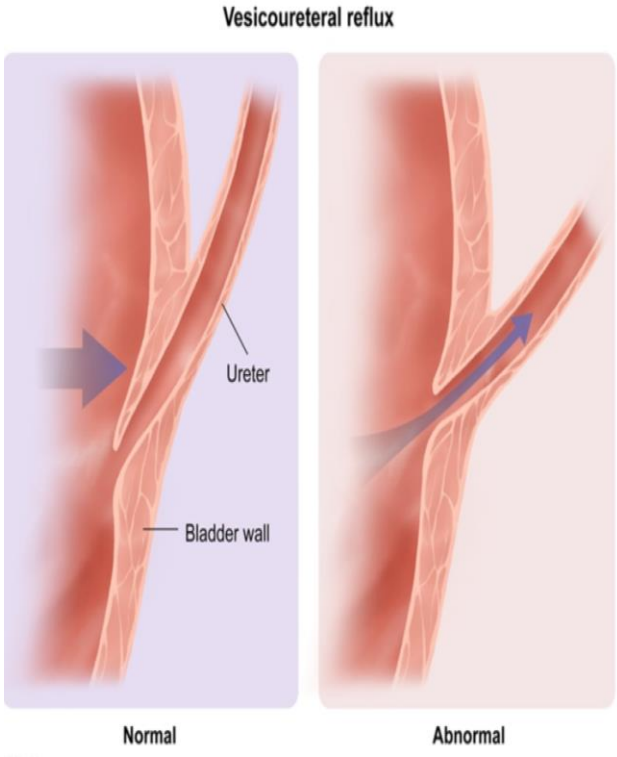

Grade	Description
I	Into a nondilated ureter
II	Into the pelvis & calyces without dilation
III	Mild to moderate dilation of the ureter, renal pelvis & calyces, with minimal blunting of the fornices
IV	Moderate ureteral tortuosity & dilation of the pelvis & calyces
V	Gross dilation of the ureter, pelvis & calyces; loss of papillary impressions; ureteral tortuosity

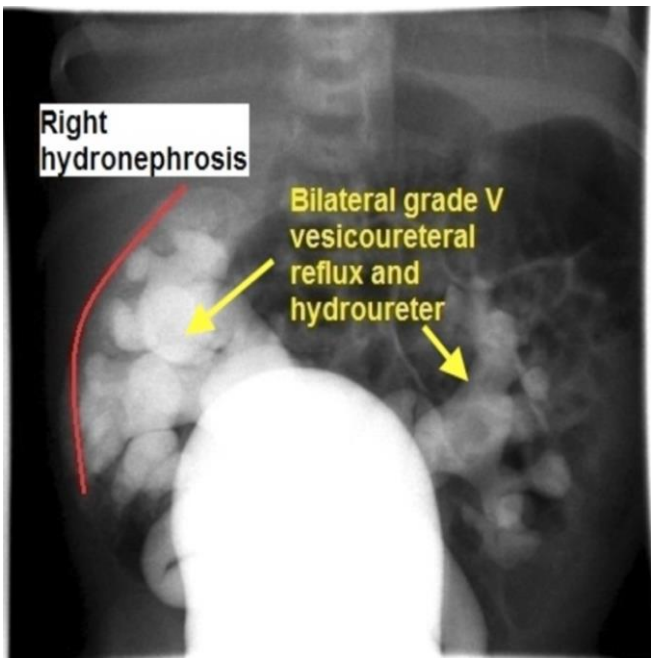

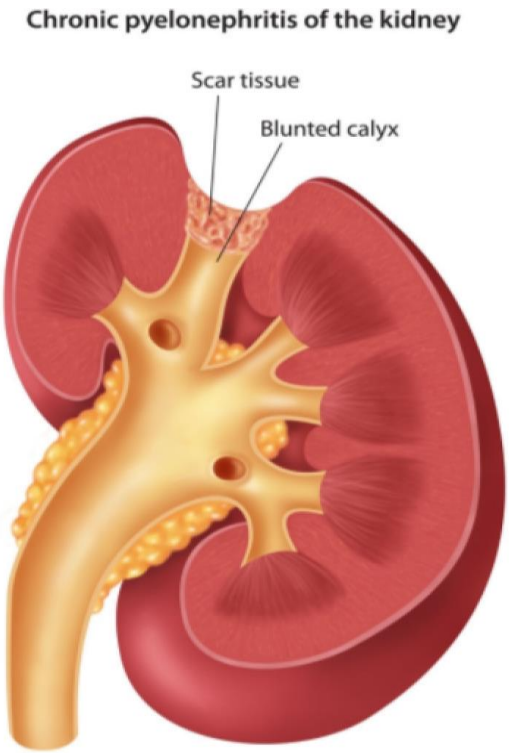

Posterior urethral valves (PUV)

- Posterior urethral valves (PUV) are the most common cause of urinary tract obstruction in newborn boys.
- Abnormal folds in the distal prostatic urethra obstruct urinary flow, resulting in progressive dilation of the bladder, ureters and kidneys.
- Prenatal ultrasonography findings of bladder distention, bilateral hydroureters, and bilateral hydronephrosis are highly suggestive of PUV.
- Poor urine output in utero results in oligohydramnios as fetal urine is a major source of amniotic fluid. Oligohydramnios in the second trimester is ominous and associated with high perinatal mortality because normal amniotic fluid levels are required for lung development.
- Low amniotic fluid also restricts fetal movement, leading to a cascade of physical anomalies including flat facies and limb deformities (Potter sequence).
- Other affected infants can present with poor urinary stream, straining with voiding, urosepsis, failure to thrive, and renal failure.
- <u>Diagnosis and treatment:</u>

- The first step in evaluation is a renal and bladder ultrasound. Findings consistent with PUV include a dilated bladder with bilateral hydroureters and hydronephrosis.
- Diagnosis is confirmed by voiding cystourethrogram and cystoscopy.
- Treatment options include PUV ablation and urinary diversion. Despite prenatal diagnosis and early surgical intervention, patients are at high risk for permanent kidney damage.

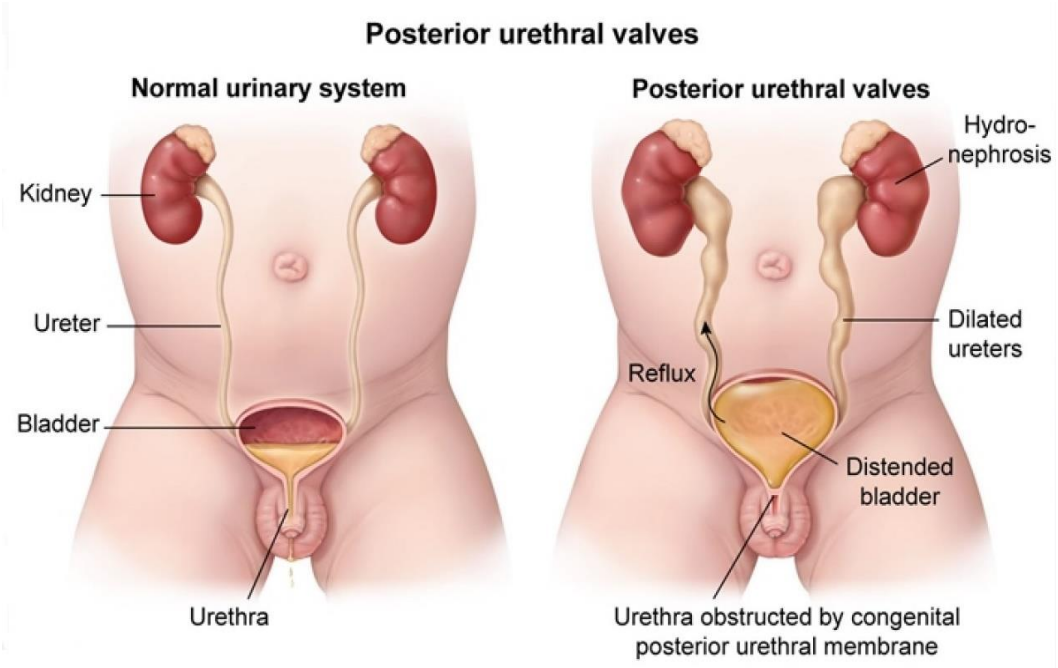

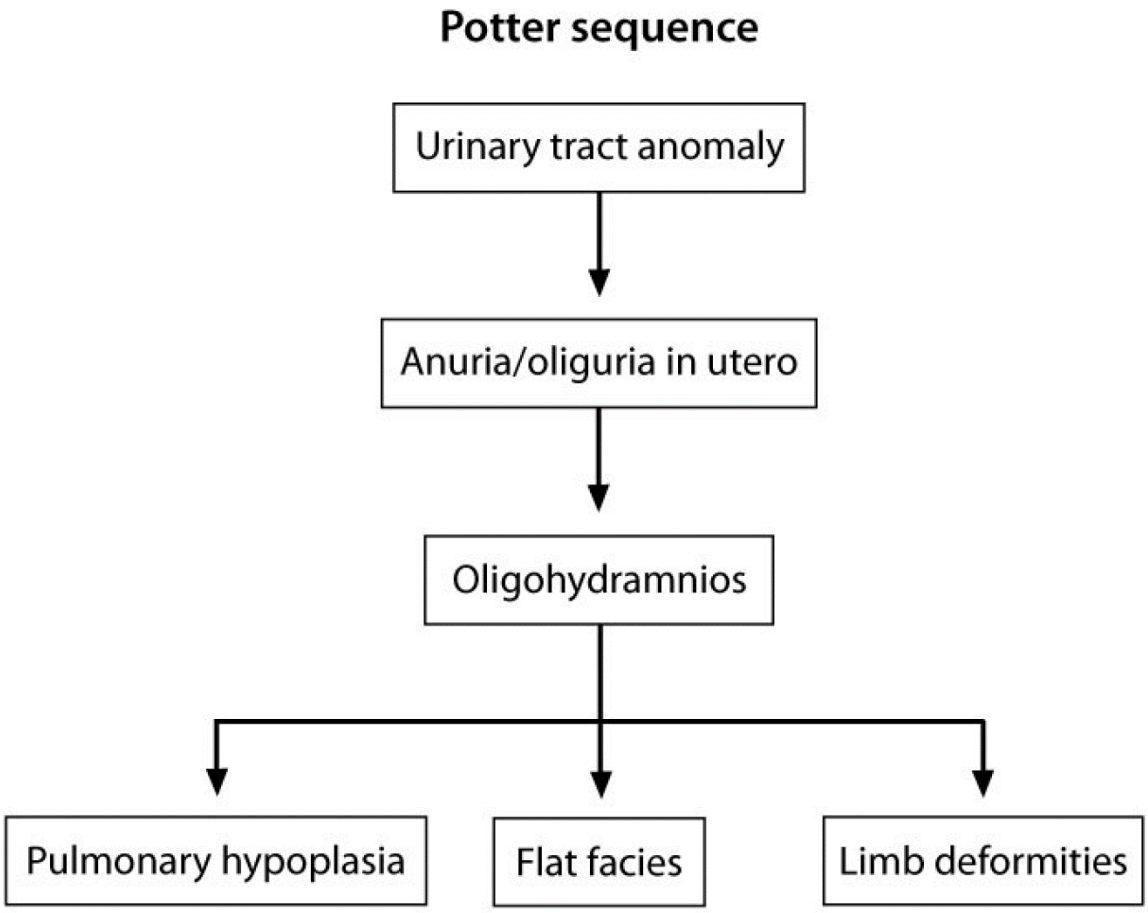
Potter sequence
Urinary tract anomaly
Anuria/oliguria in utero
Oligohydramnios
Pulmonary hypoplasia
Flat facies
Limb deformities

Enuresis

- Enuresis is defined as urinary incontinence in children age >5 and further characterized as primary or secondary.

- Bedwetting is normal before age 5. Mastery of nighttime continence can take months to years, and boys generally achieve this milestone later than girls.

- Children who have never achieved dryness have primary enuresis.

- Secondary enuresis is the return of incontinence after >6 months of dryness and results from psychological stress or a medical problem that requires further evaluation.

Causes of secondary enuresis	
Etiology	**Associated symptoms**
Psychological stress	• Behavior regression, mood lability
Urinary tract infection	• Dysuria, hesitancy, urgency, abdominal pain
Diabetes mellitus	• Polyuria, polydipsia, polyphagia, weight loss, lethargy, candidiasis
Diabetes insipidus	• Polyuria, polydipsia
Obstructive sleep apnea	• Snoring, dry mouth, fatigue, hyperactivity, irritability

- <u>Management:</u>

- The history and examination should be reviewed for medical conditions or medications that could be responsible for the enuresis. Boys with family history of delayed bladder control are predisposed to prolonged bedwetting.

- The next steps in evaluation include urinalysis, serum chemistry, hemoglobin A1c, and blood gas analysis to exclude secondary causes.

- The initial steps for managing primary enuresis include the behavior modifications. Although enuresis has a high rate of spontaneous resolution over time, many families seek active intervention to improve quality of life.

- For children who do not respond to lifestyle changes, enuresis alarms are the most effective long-term intervention but can take 3-4 months to be effective.

- Pharmacotherapy is indicated if these changes are unsuccessful in patients who desire immediate improvement. Bedwetting can be embarrassing and frustrating for children who want to participate in sleepovers.

- Desmopressin, the antidiuretic hormone analogue, can help decrease urine production during sleep. Oral desmopressin is the first-line medication as it has few side effects. The downsides are risk of relapse (up to 70%) and hyponatremia if too much fluid is consumed in the evening. Intranasal desmopressin is no longer used due to increased risk of hyponatremic seizures.

Primary nocturnal enuresis	
Definition	• Urinary incontinence age ≥5

Management	• Urinalysis to rule out secondary causes
	• Lifestyle changes:
	  ◦ Minimize fluid intake before bedtime
	  ◦ Avoid sugary/caffeinated beverages
	  ◦ Void before bedtime
	  ◦ Institute reward system (eg, “gold star” chart)
	• Enuresis alarm
	• Desmopressin therapy

CHAPTER 7

Pediatric Orthopedics

Orthopedics

Rickets

- Rickets is a disorder caused by a lack of vitamin D, calcium, or phosphate → Defective mineralization of osteoid.
- Osteoblasts normally produce osteoid, which is then mineralized with calcium and phosphate to form bone.
- It leads to softening and weakening of the bones, making them more susceptible to fractures.
- Children 6 to 24 months are at highest risk because their bones are rapidly growing.
- Vitamin D is normally derived from the skin upon exposure to sunlight (55%) and from the diet (15%).
- Activation requires 25-hydroxylation by the liver followed by 1-alphahydroxylation by the proximal tubule cells of the kidney.
- Active vitamin D raises serum calcium and phosphate by acting on intestine, kidney and bone.
- Vitamin D deficiency is seen with decreased sun exposure (northern latitudes), poor diet, malabsorption, liver failure, and renal failure → low serum calcium and phosphate.
- <u>There are 3 main etiologies of rickets:</u>

- Vitamin D-deficient rickets caused by a lack of enough vitamin D in the child's diet.
- Vitamin D-dependent rickets is the inability to convert 25-OH to 1,25(OH)2 and therefore the infant is dependent on vitamin D supplementation.
- X-linked dominant hypophosphatemic rickets occurs when an innate kidney defect results in the inability to retain phosphate. Without phosphate, adequate bone mineralization cannot take place and bones are weakened.

- <u>Presentation:</u>

- Most commonly arises in children < 1 year of age; Clinically presents with:
  - Pigeon-chest deformity: inward bending of the ribs with anterior protrusion of the sternum.
  - Rachitic rosary: due to osteoid deposition at the costochondral junction.
  - Indentations in the lower ribs (Harrison's sulci).
  - Bowing of the legs laterally (genu varus) may be seen in ambulating children.
  - Frontal bossing (enlarged forehead): due to osteoid deposition on the skull.
  - Softening of the skull (craniotabes).

- Diagnostic Tests:

- Rachitic rosary-like appearance on CXR of the costochondral joints with metaphyseal cupping/fraying.

- Bowlegs is a characteristic sign.

- Chemical Consequences of Vitamin D Disorders:

Type	Calcium	Phosphate	l,25(OH)2 Vit. D	25(OH) Vit. D
Vitamin D-deficient	Normal or decreased	Decreased	Decreased	Decreased
Vitamin D-dependent	Decreased	Normal	Decreased	Normal
X-linked hypophosphatemia	Normal	Decreased	Normal	Normal

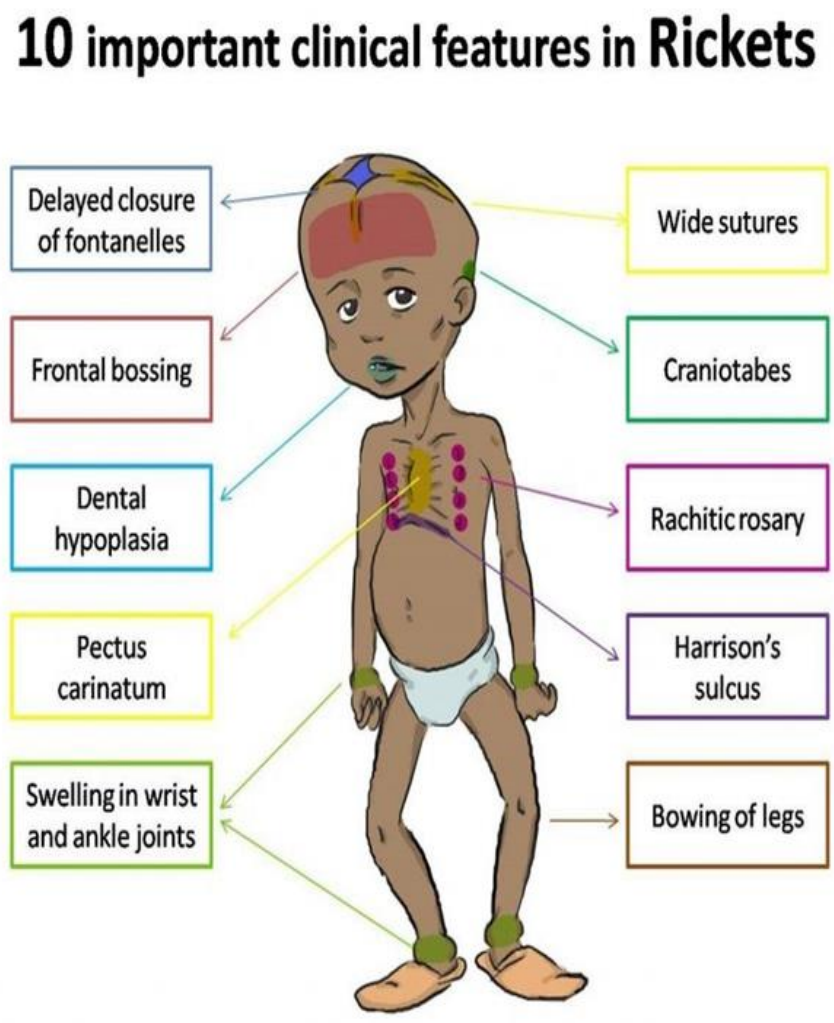



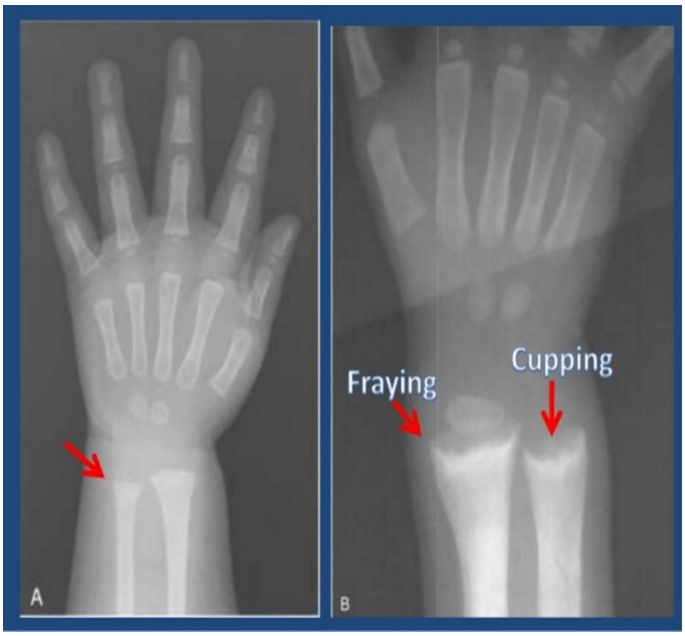



- Treatment:

- Athough breast milk is the gold standard of nutrition for children age <1 year, breast milk alone does not have adequate vitamin D. Homemade baby food is also inadequate. Therefore, infants who do not ingest fortified baby food or formula should receive vitamin D supplementation of 400 IU daily to prevent rickets.

- Treatment consists of vitamin D repletion with 1000-2000 IU daily.

Physiologic genu varum

- Genu varum (bowlegs) is a condition in which the legs angulate away from midline, causing a gap between the knees.
- Varus deformity: the deformity in which the distal part points medially.
- Valgus deformity: the deformity in which the distal part points laterally.
- Physiologic genu varum is a normal bowing that appears from birth to age 2 due to expected lower extremity alignment changes.
- This angulation is often noticeable as the child begins to walk around age 12-15 months.
- Characteristics of physiologic genu varum include:

- Symmetric bowing.
- Normal stature.
- No leg length discrepancy.
- No lateral thrust when walking.

- Diagnosis is clinical.
- Management is reassurance and observation as physiologic genu varum resolves by age 2.

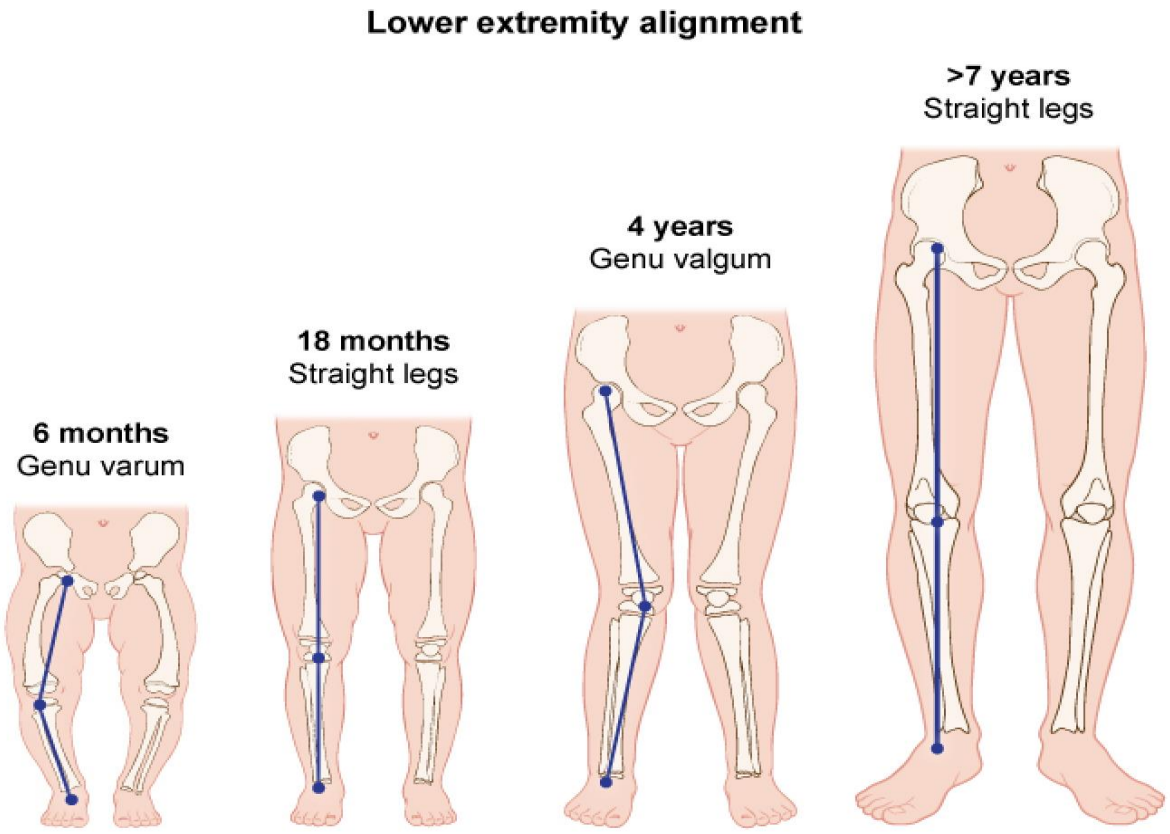

Osteogenesis Imperfecta (OI)

- Osteogenesis imperfecta is inherited connective tissue disorder caused by a mutation in the genes coding for type I collagen.

- Since type I collagen is an important structural protein that is present in the skin, sclera, bone, tendon and ligament.

- Manifestations can include:

- Multiple fractures with minimal trauma; may occur during the birth process. May be confused with child abuse. Treat with bisphosphonates to ↓ fracture risk.

- Blue sclerae due to the translucent connective tissue over choroidal veins.

- Some forms have tooth abnormalities, including opalescent teeth that wear easily due to lack of dentin and weak enamel (dentinogenesis imperfecta). Both primary and permanent teeth are affected.

- Hearing loss (abnormal ossicles).

- Diagnosis and treatment:

- The most accurate test for OI is skin biopsy analyzed for collagen synthesis by culturing dermal fibroblasts.

- There is no cure for OI. Therapy is aimed at fracture management, increasing bone mass, and correcting of deformities.





Clubfoot

- Suspect clubfoot (talipes equinovarus) in a patient who presents with equinus and varus of the calcaneum and talus, varus of the midfoot, and adduction of the forefoot.
- This is a common foot deformity and may be congenital, teratologic, or positional. Congenital cases are usually isolated, idiopathic cases. Teratologic cases are associated with a neuromuscular disorder or a complex syndrome. Positional cases occur due to abnormal positioning of the affected foot in utero.
- Initial treatment involves nonsurgical methods (stretching and manipulation of the foot, followed by serial plaster casts, malleable splints, or taping) because conservative treatment corrects the majority of cases.
- Untreated cases result in further deformation, abnormal gait, and development of ulcerations.
- Surgical treatment is indicated if conservative management gives unsatisfactory results, and is preferably performed between 3 and 6 months of age.





Metatarsus adductus (MA)

- Metatarsus adductus (MA), the most common congenital foot deformity, is characterized by medial deviation of the forefoot with a normal neutral position of the hindfoot.
- This deformity is usually bilateral and occurs most frequently in first-born infants, likely due to the crowded positioning in a smaller, primigravid uterus.
- In the majority of cases, the foot is flexible and the condition resolves spontaneously.

	Metatarsus adductus	Congenital clubfoot
Clinical features	• Flexible positioning • Medial deviation of forefoot • Neutral position of hindfoot	• Rigid positioning • Medial/upward deviation of forefoot & hindfoot • Hyper-plantar flexion of foot
Treatment	Reassurance	Serial manipulation & casting; surgery for refractory cases

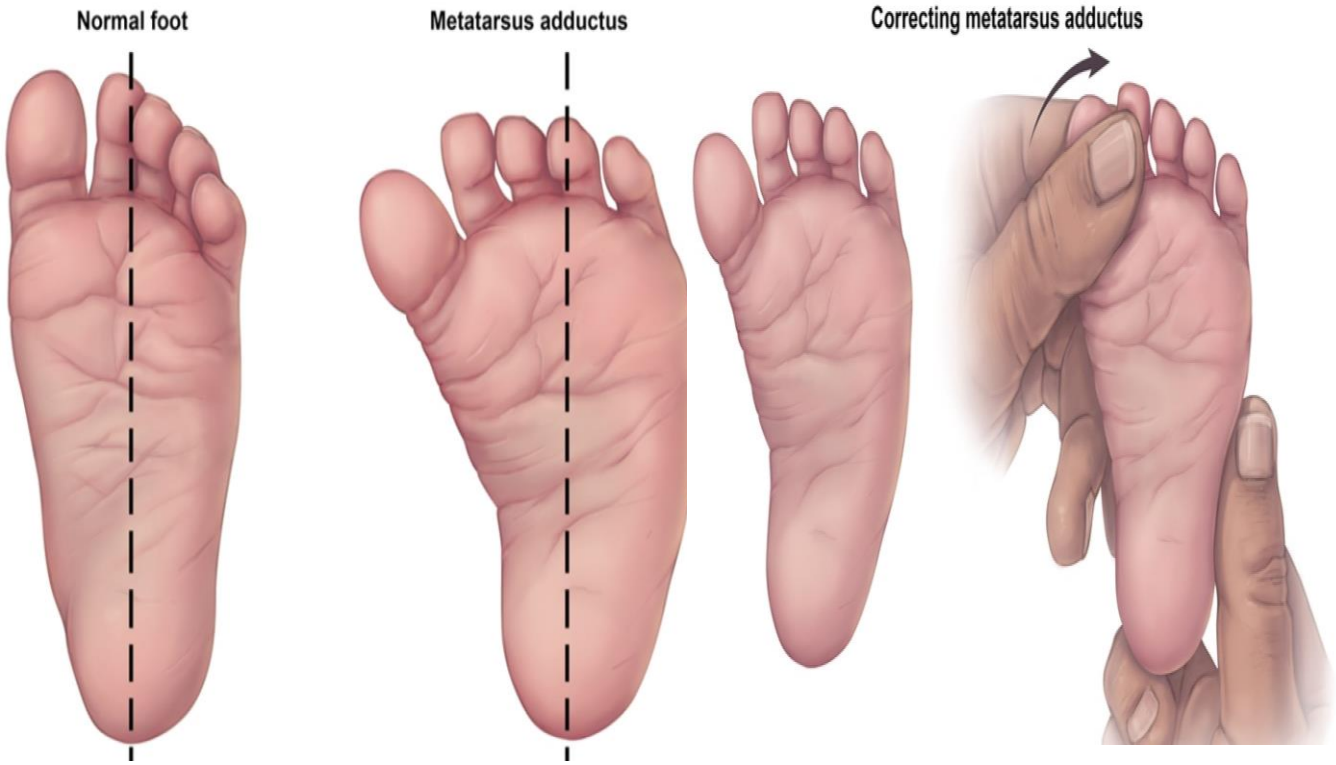

Congenital muscular torticollis (CMT)

- Congenital muscular torticollis (CMT) is a postural deformity that typically presents between age 1-6 months with limited range of motion of the neck due to contracture of sternocleidomastoid muscle.
- Physical examination may reveal a palpable, well-circumscribed mass that does not transilluminate in the inferior portion of sternocleidomastoid muscle, ipsilateral head tilt, and contralateral chin deviation.
- Risk factors for CMT are related to crowding in the uterus, such as multiple gestation, breech positioning, and oligohydramnios.
- Associated conditions, which are also likely related to intrauterine positioning, include developmental dysplasia of the hip, metatarsus adductus, and clubfoot.
- Treatment strategies include positioning (increased tummy time), passive stretching, and physical therapy.
- Missed or delayed diagnosis may lead to craniofacial asymmetry.

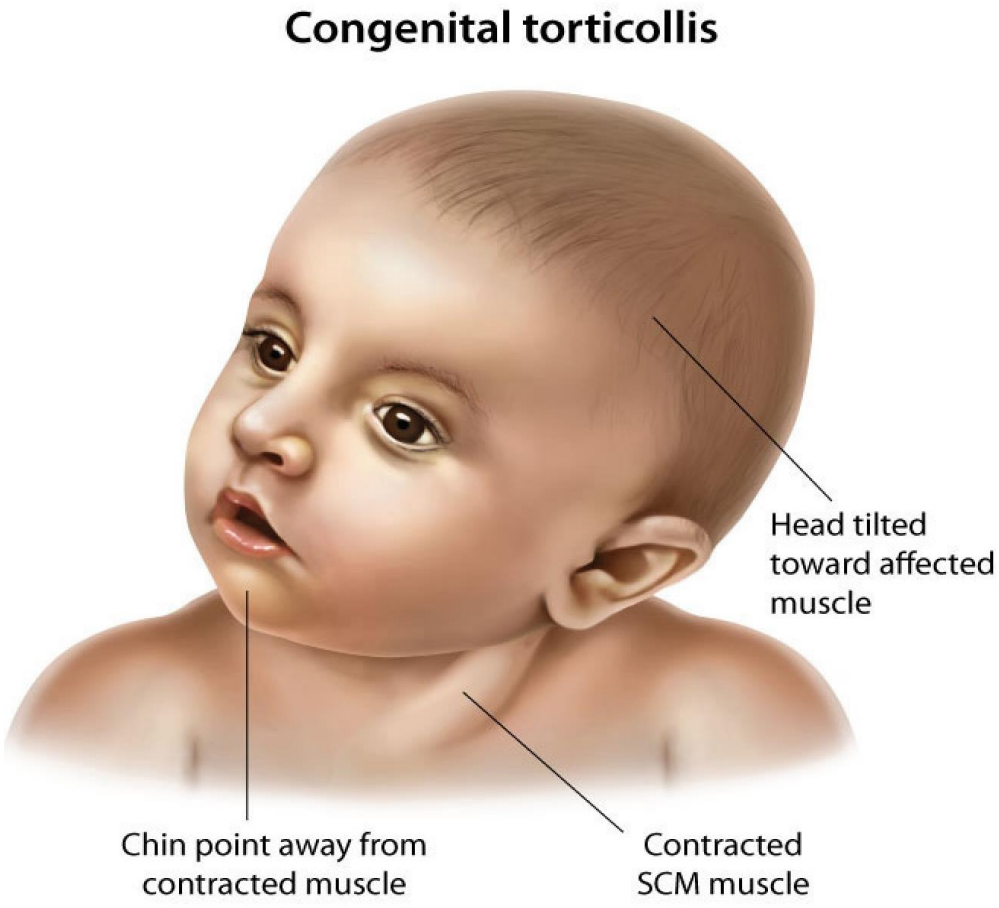

Supracondylar fracture of the humerus

- Supracondylar humerus fractures are the most common type of pediatric elbow fracture, particularly in children age 2-7.
- The typical history involves a high-impact fall onto an outstretched arm with the elbow hyperextended.
- Radiographs may show a fracture line and displacement of the humerus.
- In the case of an occult fracture, inflammation surrounding the fracture displaces the synovial fat. On x-ray, this appears as a wide anterior fat pad (normally narrow or absent) and a posterior fat pad (normally absent).





- These fractures carry a significant risk of neurovascular compromise, particularly if the fracture is displaced.
- The brachial artery, median nerve, and radial nerve all run anterior to the elbow with the brachial artery and median nerve running together medially and the radial nerve running laterally.
- Due to this configuration, supracondylar fractures resulting in anterolateral displacement of the proximal fracture fragment typically cause radial nerve injury. This causes wrist drop (due to denervation of hand/finger extensor muscles) and sensory loss over the posterior forearm/dorsolateral hand.
- Supracondylar fractures resulting in anteromedial displacement of the proximal fracture fragment typically cause median nerve and brachial artery injury. Patients with median neuropathy often have sensory loss over the first 3 digits and weakness on flexion of the first 3 digits and wrist.
- Brachial artery injury may result in a pulseless hand due to vascular insufficiency.

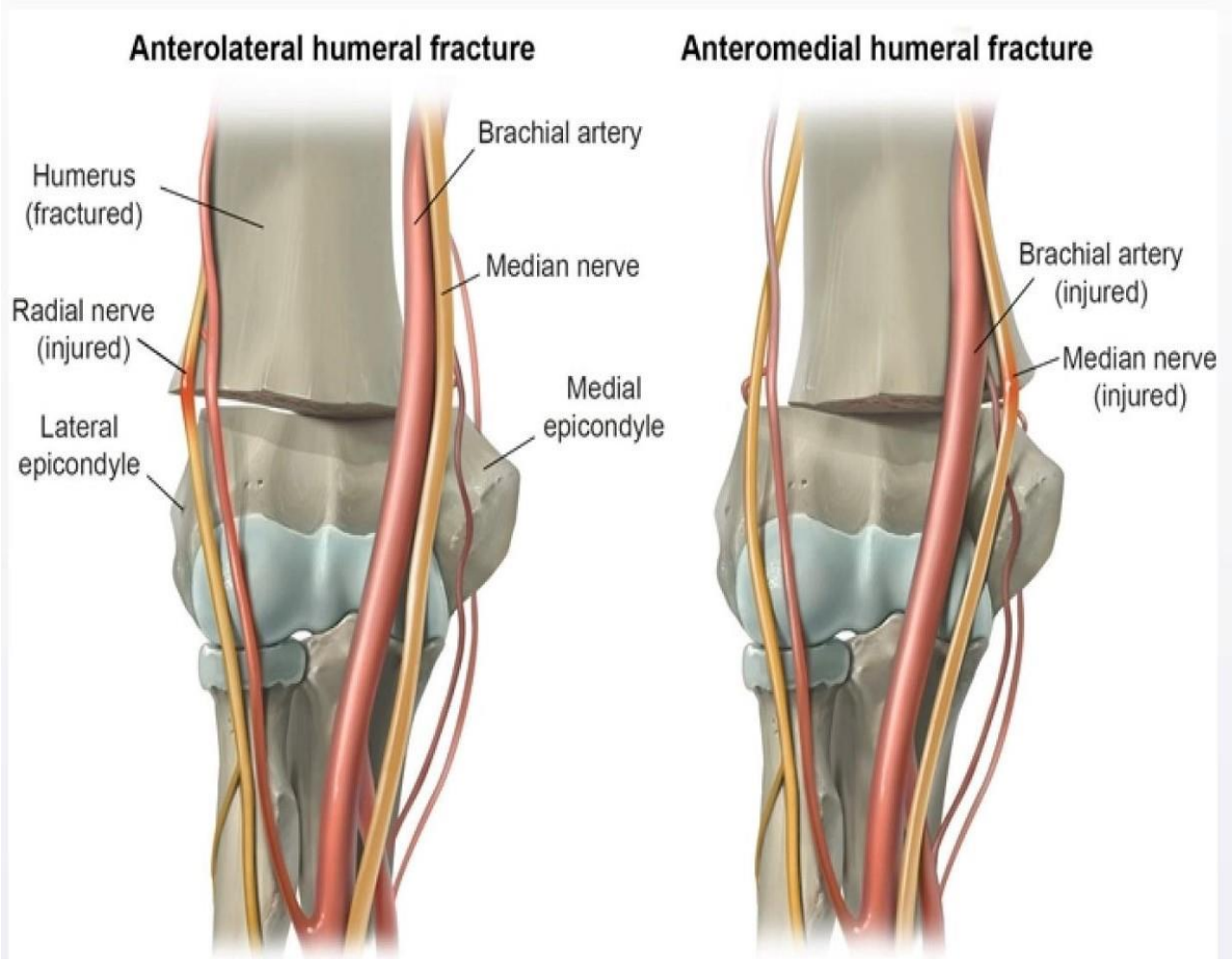

Supracondylar fracture	
Clinical features	• Fall onto outstretched arm • Pain, swelling, limited range of motion
Diagnostic findings	• X-ray with posterior fat pad (occult), fracture line, or displacement of humerus
Treatment	• Nondisplaced: long arm splint & sling • Displaced: surgical reduction & pinning
Complications	• Neurovascular injury • Compartment syndrome

Radial head subluxation (nursemaid's elbow)

- Radial head subluxation (nursemaid's elbow) is one of the most common elbow injuries in children age 1-5.

- The injury characteristically occurs from innocent swinging of a young child by the arms or pulling a child's arm while in a hurry. Pulling causes axial traction on the forearm, which causes the radial head to slip through parts of the annular ligament.

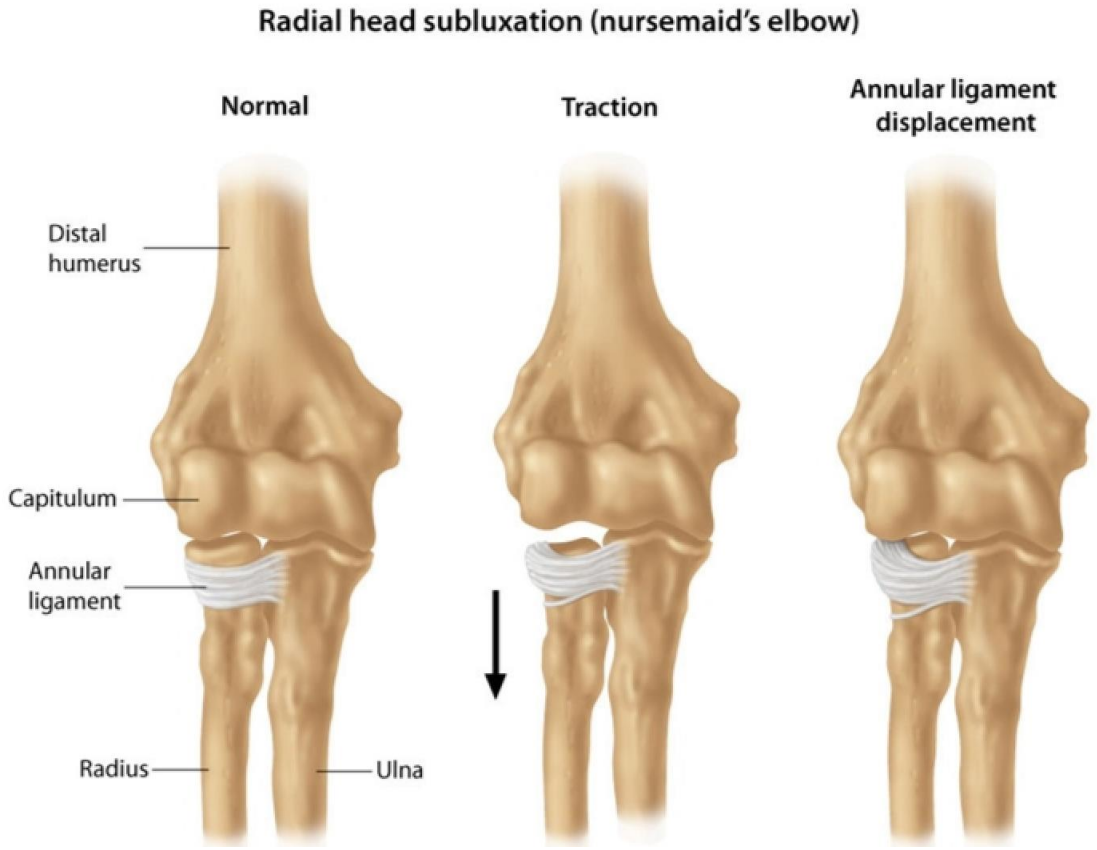

- Physical examination should show no swelling or angular deformity, although the radial head may be mildly tender. The child typically keeps the affected arm in a pronated position; attempted forearm supination will be resisted and cause the child to cry out in pain.

- The preferred treatment of this condition is closed reduction by applying pressure on the radial head and hyperpronating the forearm. Forearm supination with elbow flexion is also commonly performed but may be less successful and more painful. No post-reduction films are needed when the patient resumes full use of the extremity. A pop may also be heard on successful reduction.

- Full recovery after closed reduction by forearm hyperpronation confirms the diagnosis.

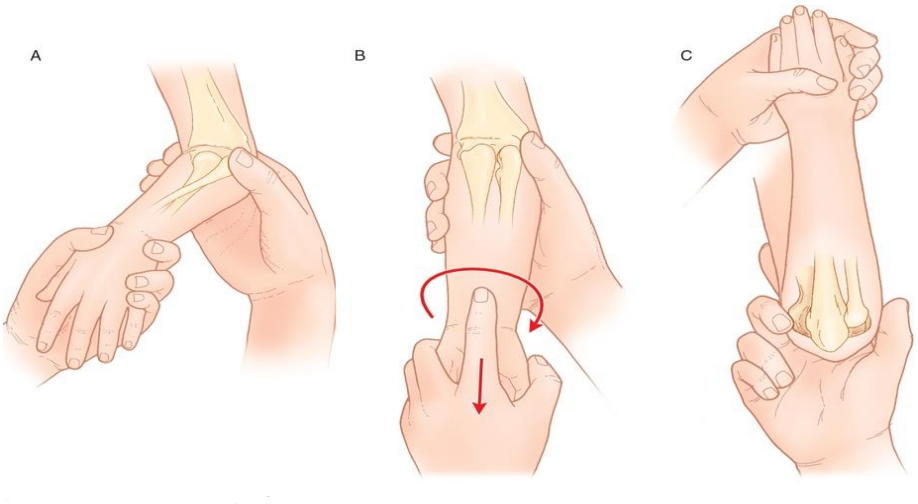

Osgood-Schlatter Disease (OSD)

- Osgood-Schlatter disease is a common cause of knee pain, particularly in adolescent male athletes.
- During early adolescence (typically ages 13-14 for affected males, and ages 10-11 for affected females), there are periods of rapid growth in which the quadriceps tendon puts traction on the apophysis of the tibial tubercle where the patellar tendon inserts.
- Osgood-Schlatter disease is a traction apophysitis of the tibial tubercle. This traction apophysitis is worsened by sports that involve repetitive running, jumping, or kneeling, and it improves with rest.
- Approximately one fourth of affected individuals have bilateral disease.
- Diagnosis:

- The diagnosis is made on clinical history and exam.
- On physical examination, there is edema and tenderness over the tibial tubercle. A firm mass can sometimes be felt due to heterotopic bone formation. Pain can be reproduced by extending the knee against resistance.
- Radiographic findings are nonspecific and include anterior soft tissue swelling, lifting of tubercle from the shaft, and irregularity or fragmentation of the tubercle.

- Treatment:

- Treatment consists of activity restriction, stretching exercises, and non-steroidal anti-inflammatory medications.
- Patients normally have complete relief of symptoms in 12 to 24 months.

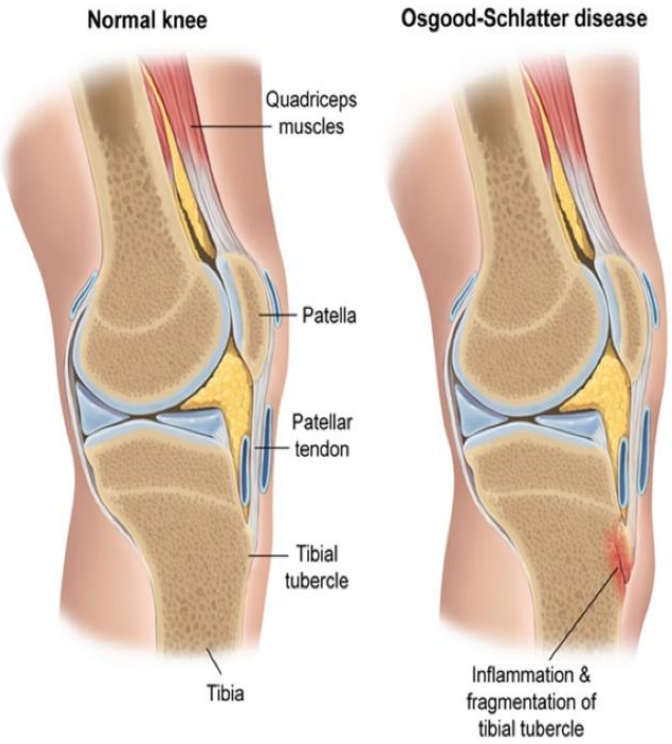



Transient synovitis

- Transient synovitis is the most common cause of hip pain in children, typically occurring in boys age 3-10 years.
- The cause is unknown but usually follows a viral infection or mild trauma.
- Synovial inflammation leads to pain, decreased range of motion, and limping.
- On examination, the affected hip is typically flexed, slightly abducted, and externally rotated. This position maximizes the joint space, thereby providing some pain relief.
- <u>Diagnosis and treatment:</u>

- Because characteristics of transient synovitis overlap with septic arthritis, laboratory studies should be sent to assess for severity of inflammation. In contrast to septic arthritis, children with transient synovitis rarely have fever or significant laboratory abnormalities.
- There are usually no laboratory abnormalities or fever.
- When the diagnosis is unclear, bilateral hip ultrasound is required. Joint effusion in septic arthritis is unilateral, whereas 25% of patients with transient synovitis have bilateral hip effusions (even with unilateral symptoms). If hip ultrasound shows unilateral effusion, arthrocentesis is performed to evaluate for septic arthritis.

- Treatment consists of rest and nonsteroidal anti-inflammatory medications (NSAIDs). NSAIDs (ibuprofen) have both analgesic and anti-inflammatory properties and are recommended over other pain relievers (acetaminophen, opioids).

- Children usually recover within 1-4 weeks and have no complications.

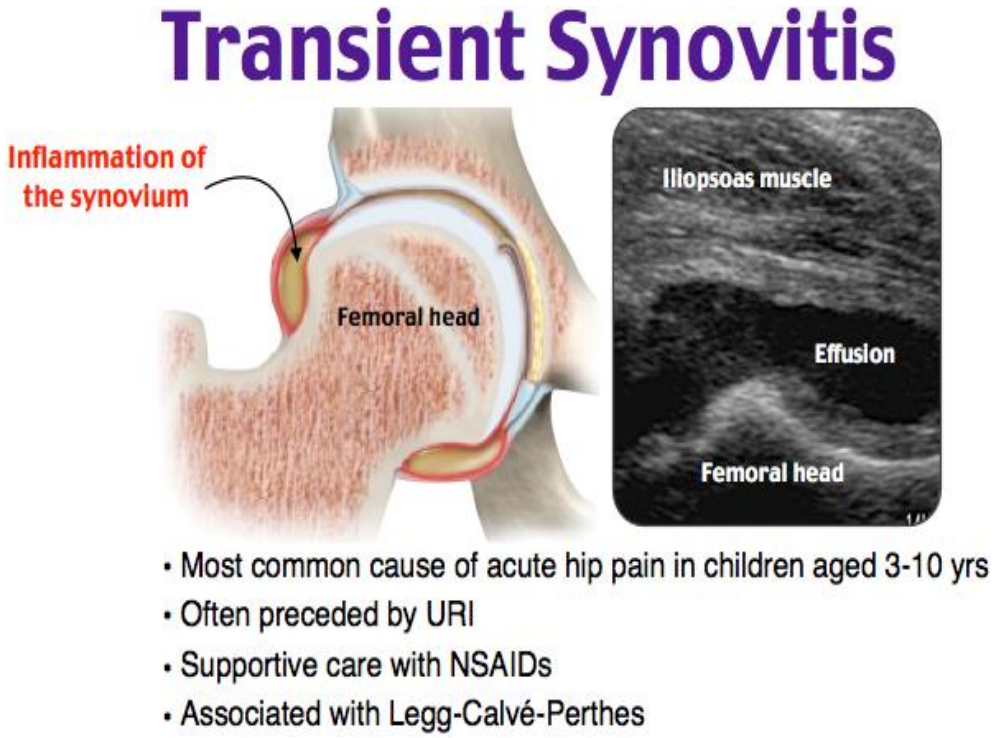

	Transient synovitis	Septic arthritis
Clinical presentation	• Well-appearing • Afebrile or low-grade fever • Able to bear weight	• Ill-appearing • Febrile • Non–weight-bearing
Diagnosis	• Normal or mildly elevated WBC, ESR, CRP • Unilateral/bilateral ultrasound effusion • Diagnosis of exclusion	• Moderately elevated WBC, ESR, CRP • ± Positive blood culture • Unilateral ultrasound effusion • Synovial fluid WBC >50,000/mm^3
Treatment	• Conservative	• Joint drainage & antibiotics

CRP = C-reactive protein; **ESR** = erythrocyte sedimentation rate; **WBC** = white blood cell.

Developmental dysplasia of the hip (DDH)

- Developmental dysplasia of the hip (DDH) is a dislocation of the femoral head from the acetabulum.
- Early diagnosis is critical as treatment initiation before age 6 months portends a favorable prognosis.
- Delayed diagnosis is one of the most common reasons for malpractice suits against pediatricians due to potential complications such as limp (Trendelenburg gait), scoliosis, arthritis, and avascular necrosis.
- Although breech presentation, female sex, white ethnicity, and family history of DDH increase the risk, most patients (~75%) have no risk factors. Therefore, all infants must have serial hip examinations from birth until they are walking (age 1 year).
- Diagnosis and treatment:

- Barlow and Ortolani maneuvers should be performed to assess joint stability. These consist of placing the infant supine with each hip flexed to 90° followed by abduction to feel for dislocatability and adduction to feel for reducibility of an unstable joint. A palpable clunk with either maneuver is an alarming sign of hip dislocation and should prompt referral to an orthopedic surgeon.
- Equivocal signs such as a soft click, leg-length discrepancy (Galeazzi test) , or asymmetric inguinal skin folds suggest possible hip laxity.
- Hip laxity that is present at birth usually resolves by age 2 weeks. Therefore, imaging is not recommended until >2 weeks. Infants age 2 weeks-4 months with abnormal examination should undergo ultrasonography. DDH is bilateral in ~20% of patients and thus both sides should be imaged. X-ray is not helpful until age >4 months because the femoral head and acetabulum are not yet ossified. After ossification, x-ray is better at showing acetabular development and positioning.
- A positive Barlow or Ortolani test or abnormal imaging results should prompt referral for treatment. The Pavlik harness is a splint that holds the hip in flexion and abduction while preventing extension and adduction, which can exacerbate dislocation. It is the treatment of choice for age <6 months as most hip joints are able to remain in a stable position. After age 6 months, however, the harness is far less successful and reduction under anesthesia is required.
- All neonates and infants should be screened for developmental dysplasia of the hip with Barlow and Ortolani maneuvers. A palpable clunk should prompt referral to an orthopedic surgeon. A soft click, leg-length discrepancy, or asymmetric inguinal skin folds require diagnostic imaging with ultrasound (age < 4 months) or x-rays (age >4 months). The treatment of choice for age <6 months is the Pavlik hip harness.

Developmental dysplasia of the hip	
Risk factors	• Breech positioning • Positive family history • Excessively tight swaddling

Clinical features	• Red flags
	  ◦ Positive Ortolani test
	  ◦ Dislocated hip
	  ◦ Limited hip abduction
	• Supportive findings
	  ◦ Limb length discrepancy
	  ◦ Asymmetric gluteal/inguinal/thigh creases

Management	• Red flags: Refer to orthopedic surgery
	• Supportive findings or risk factors
	  ◦ Age <4 months: Hip ultrasound
	  ◦ Age >4 months: Hip radiograph

Barlow & Ortolani maneuvers

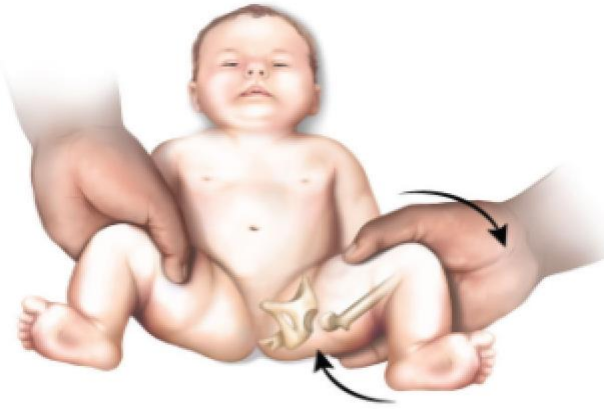

Ortolani Maneuver:
Abduction with anterior lifting of the hip

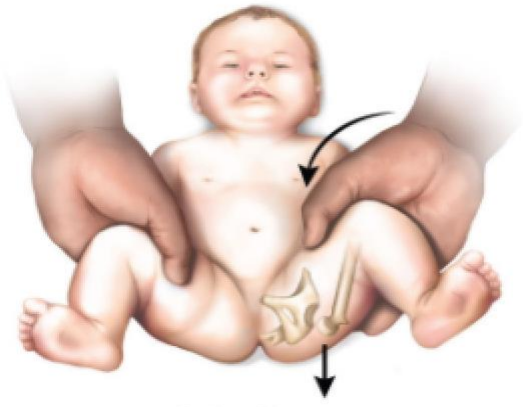

Barlow Maneuver:
Adduction with posterior pressure on the hip

Pavlik harness



Developmental dysplasia of the hip - asymmetric inguinal folds

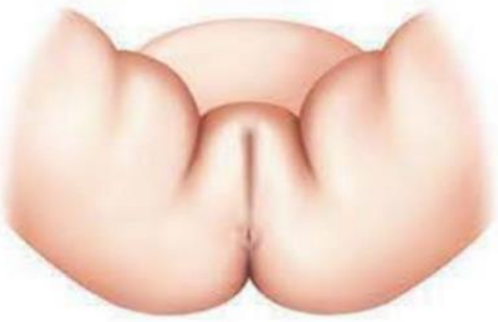

(A) Normal inguinal folds do not extend beyond the anal aperture

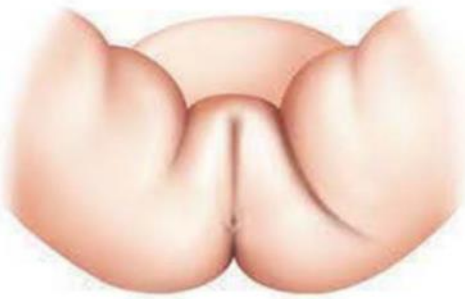

(B) The inguinal fold on the left extends beyond the anal aperture, suggesting possible developmental dysplasia of the left hip

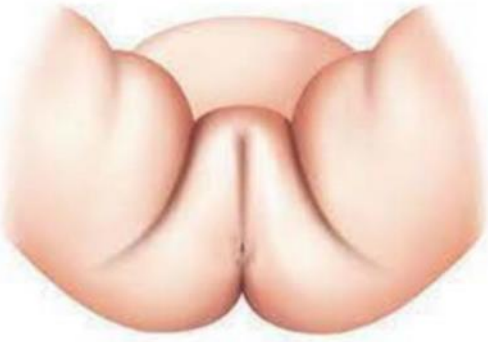

(C) The inguinal folds on both sides extend beyond the anal aperture, suggesting bilateral developmental dysplasia of the hip

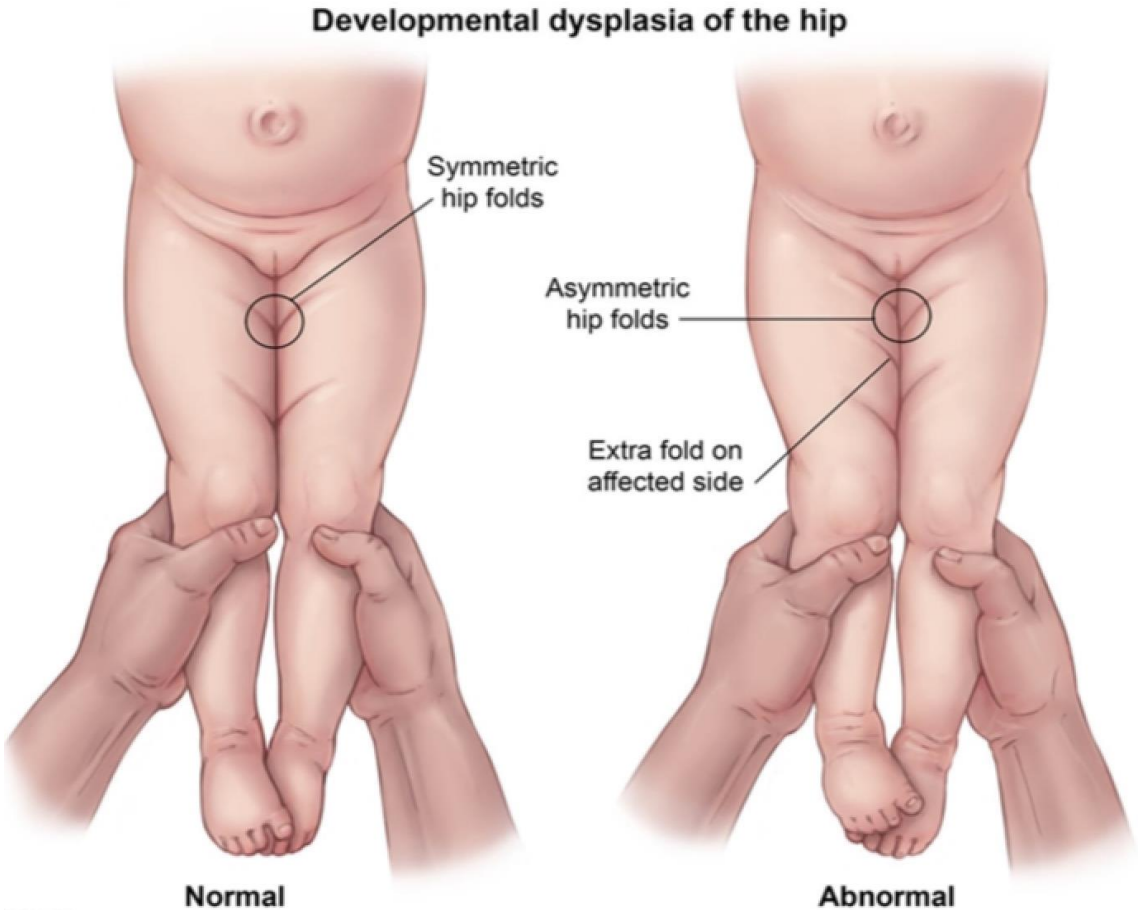
Developmental dysplasia of the hip
Symmetric hip folds
Asymmetric hip folds
Extra fold on affected side
Normal
Abnormal

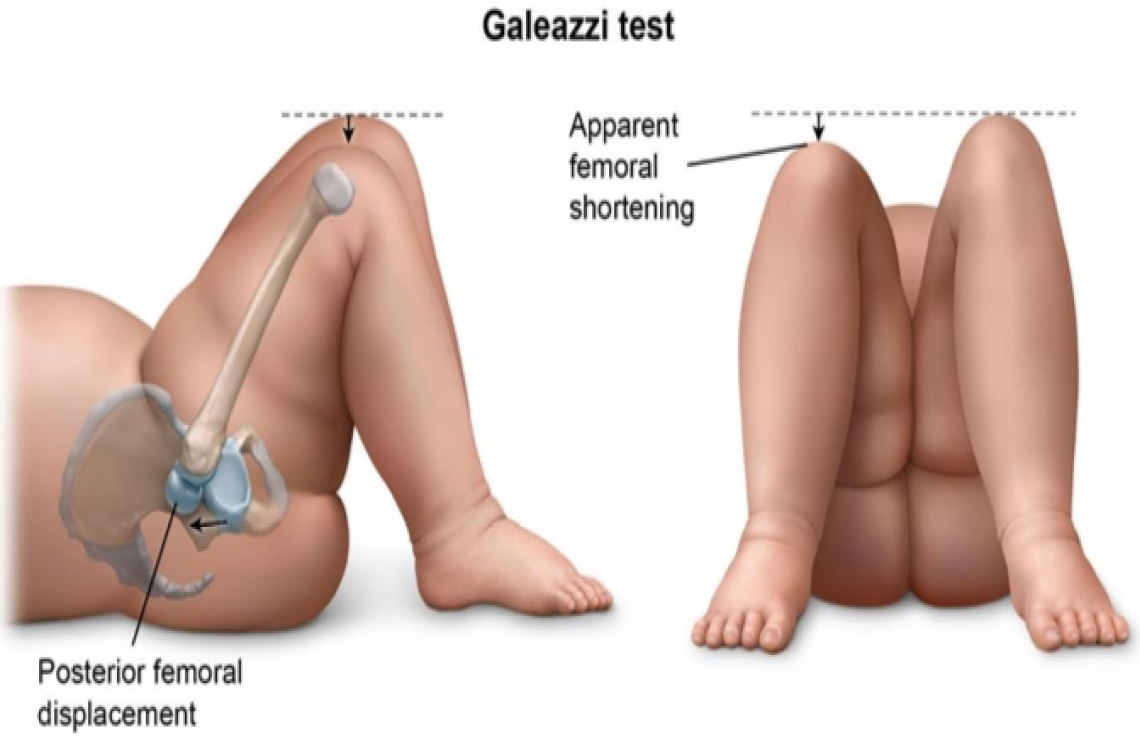
Galeazzi test
Apparent femoral shortening
Posterior femoral displacement

Legg-Calve-Perthes disease (LCP)

- Legg-Calve-Perthes disease (LCP) is a syndrome of idiopathic osteonecrosis (avascular necrosis) of the femoral head.
- This condition most commonly affects boys age 3-12, with a peak incidence between age 5 and 7.
- The etiology for LCP is unclear, but in some patients underlying thrombophilia may be a predisposing factor.
- Patients generally present with mild chronic hip or knee pain of insidious onset as well as an antalgic gait (shorter time weight bearing on the affected side due to pain).
- Diagnosis and treatment:

- Diagnosis requires a high index of suspicion as initial x-rays may be negative, resulting in an initial diagnosis of transient synovitis.
- Although transient synovitis typically follows a viral infection, symptoms should resolve within 1-4 weeks.
- Persistent symptoms should prompt clinicians to repeat imaging as it can take months for concerning changes to appear on x-ray. As the disease progresses, internal rotation and abduction at the hip joint can become markedly limited. Proximal thigh atrophy may also be present.
- The x-ray below shows a flattened and fragmented left femoral head. Magnetic resonance imaging and bone scans can show subtle femoral head necrosis weeks to months earlier than x-rays and may be helpful to aid in early diagnosis.
- Treatment is aimed at maintaining the femoral head within the acetabulum via splinting or surgery. Patients should refrain from weight-bearing activities.

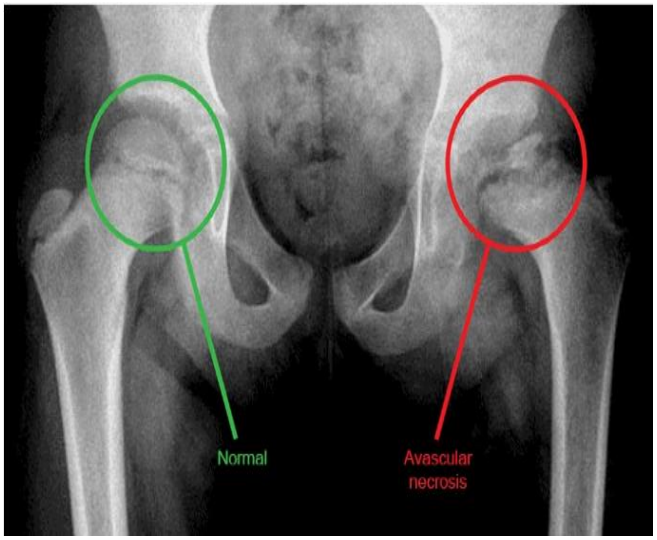

Slipped capital femoral epiphysis (SCFE)

- Slipped capital femoral epiphysis (SCFE) is characterized by posterior displacement of the proximal femur relative to the femoral head due to disruption of the proximal femoral growth plate.
- It is commonly seen in obese adolescent boys (age 10-16).
- The physis (physical junction between the femoral head and neck) weakens during early adolescence because it is rapidly expanding and primarily composed of cartilage, which does not possess the strength of bone.
- When exposed to excessive shear stress, which is magnified by obesity, the physis fractures and the femoral head slips posteriorly and medially relative to the femoral neck.
- Both hips are affected in <40% of cases, and many patients with unilateral SCFE will develop slip in the contralateral hip in the future.
- Patients classically present with an insidious onset of dull hip or referred knee pain and altered gait to avoid bearing weight on the affected leg with no preceding trauma.
- On examination, patients tend to hold the affected hip in passive external rotation and exhibit decreased internal rotation.
- Additional risk factors include endocrinopathies (hypothyroidism because thyroid hormone promotes ossification of the growth plate), renal failure, and radiation history. Children with endocrinopathies almost always have bilateral disease and present at an earlier age.
- <u>Diagnosis and treatment:</u>

- Diagnosis is made with plain radiographs of the hip (anteroposterior and frog-leg lateral views), which show the posteriorly and interiorly displaced femoral head.
- Both hips should be imaged for comparison and to assess for contralateral displacement.
- Patients should be prescribed non-weight-bearing status and may require bedrest if SCFE is bilateral. Definitive treatment is prompt surgical screw fixation to stabilize the physis and prevent further slippage in order to lessen the risks of avascular necrosis of the femoral head and chondrolysis.

Slipped capital femoral epiphysis	
Risk factors	• Obesity • Adolescence
Clinical presentation	• Dull hip pain • Referred knee pain • Altered gait • Limited internal rotation of hip
Diagnosis	• Posteriorly displaced femoral head on x-ray
Treatment	• Non–weight bearing • Surgical pinning
Complications	• Avascular necrosis • Osteoarthritis

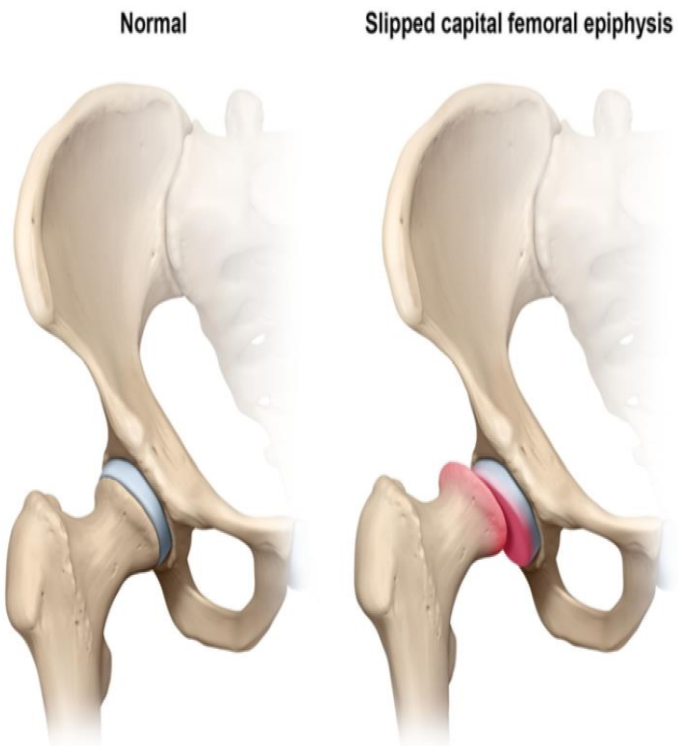

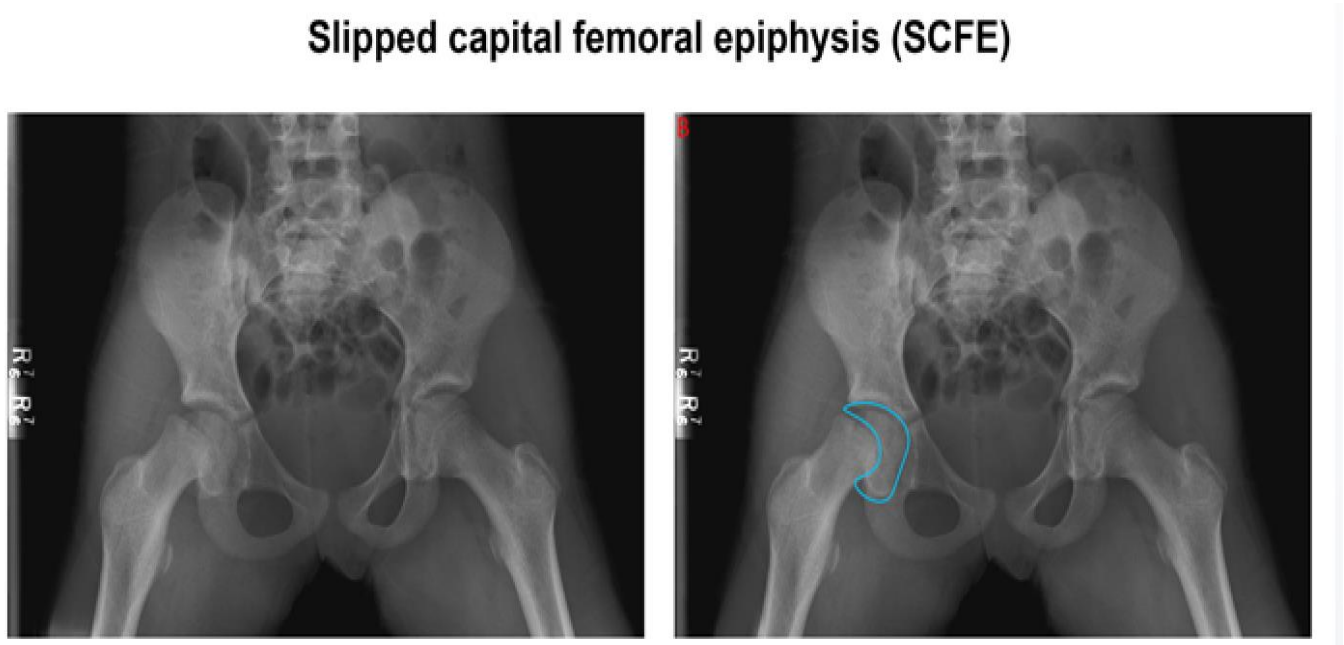

Langerhans cell histiocytosis (LCH)

- Langerhans cell histiocytosis (LCH) is a rare disorder in which histiocytes (macrophages within tissue) proliferate and infiltrate one or more organ systems.

- Bone is most commonly affected, but invasion of the skin (eczematous rash), lymph nodes (lymphadenopathy), lungs (cough, pulmonary nodules), liver, spleen (hepatosplenomegaly), and CNS (central diabetes insipidus with polyuria and hypernatremia) can also occur.

- Bone lesions are frequently found in the skull; the femur, vertebrae, and other bones can also be affected. Lesions may be asymptomatic or associated with local pain and an overlying tender mass.

- X-ray shows characteristic "punched-out" lytic lesions; biopsy is required to confirm the diagnosis showing Langerhans cells on bone/skin biobsy.

- Although the bone tumors are benign, they can be locally destructive and are typically treated with curettage or chemotherapy (prednisone).

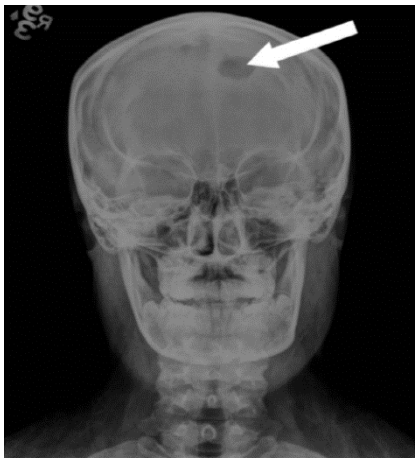

Langerhans cell histiocytosis	
Clinical findings	• Lytic bone lesions (eg, skull, jaw, femur) • Skin lesions (purplish papules, eczematous rash) • Lymphadenopathy, hepatosplenomegaly • Pulmonary cysts/nodules • Central diabetes insipidus
Diagnosis	• Langerhans cells on bone/skin biopsy
Treatment	• Chemotherapy (prednisone ± vinblastine) • Desmopressin for diabetes insipidus

Duchenne muscular dystrophy (DMD)

- X-linked disorder and therefore affects primarily boys. Dystrophin gene (DMD) is the largest protein-coding human gene → ↑ chance of spontaneous mutation.
- Duchenne muscular dystrophy (DMD) is caused by dystrophin gene deletion, which disrupts the amino acid coding sequence for dystrophin, a protein found on the plasma membrane of muscle fibers.
- Onset before 5 years of age.
- Symptoms of DMD include the following:

1. Walking difficulties: Clumsy, slow, waddling gait; cannot keep up with peers.
2. Gower sign: Progressive weakness in proximal musculature, resulting in use of the hands to support weight on standing. Classically seen in Duchenne muscular dystrophy, but also seen in other muscular dystrophies and inflammatory myopathies (polymyositis).
3. Calf pseudohypertrophy: Calf hypertrophy allows affected children to overcome proximal muscle weakness, but it is later replaced by fat and connective tissue (pseudohypertrophy).
4. Asymmetric weakening of the paraspinal muscles leading to kyphoscoliosis.

- Duchenne muscular dystrophy should be suspected in a boy age <5 with proximal muscle weakness, Gower sign, and bilateral calf pseudohypertrophy.
- It progressively worsens to involve respiratory and cardiac muscles, eventually causing death by respiratory or heart failure (Dilated cardiomyopathy is common cause of death).
- Serum creatine phosphokinase and aldolase levels are elevated even before the manifestation of weakness.
- Diagnosis is confirmed by genetic testing, biopsy that shows muscle replacement by fat and fibrosis, and absent dystrophin on immunochemistry staining.

Becker muscular dystrophy

- X-linked disorder typically due to nonframeshift deletions in dystrophin gene (partially functional instead of truncated).
- Less severe than Duchenne.
- Onset in adolescence or early adulthood.

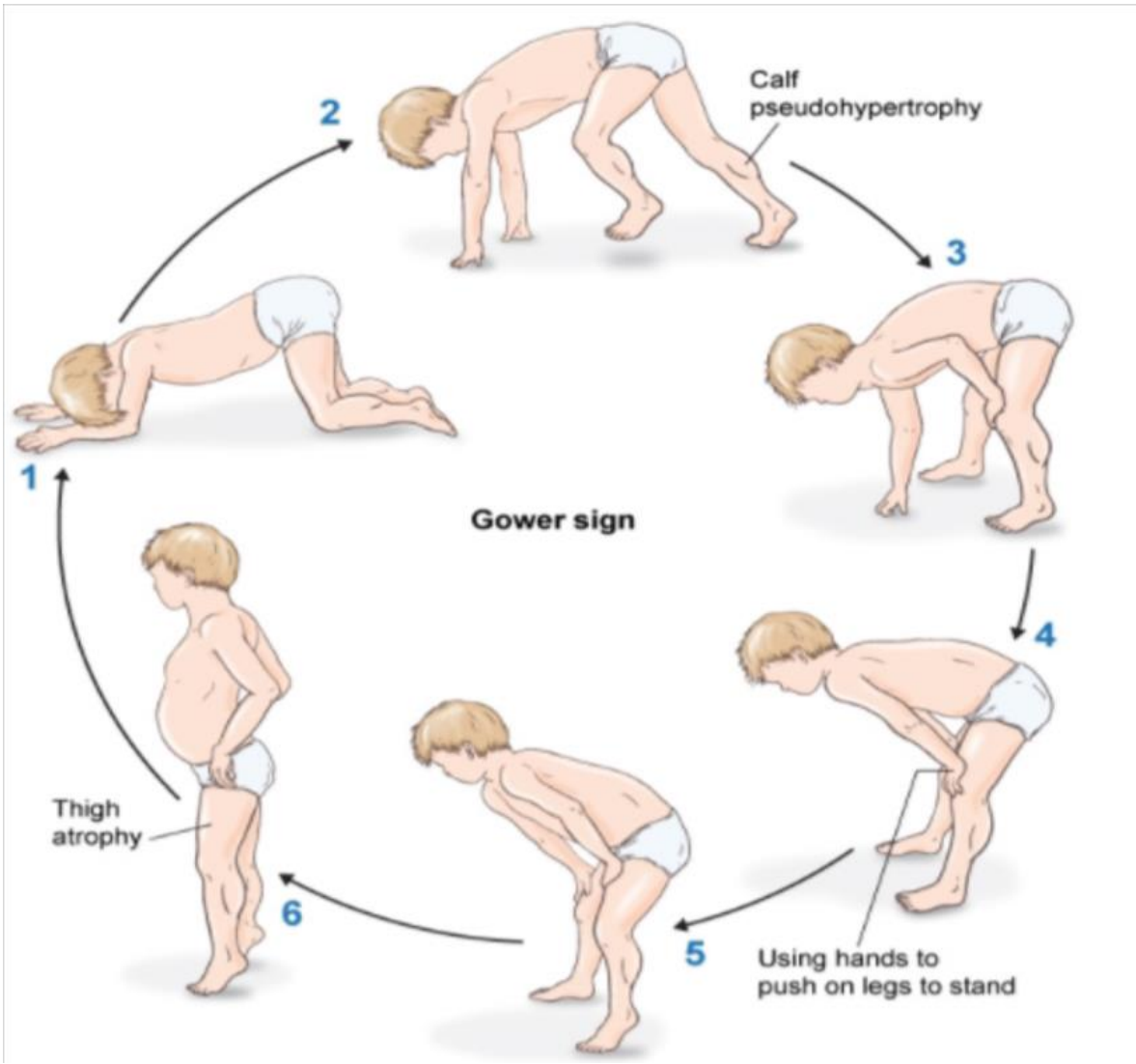

Myotonic muscular dystrophy

- Autosomal dominant.
- CTG trinucleotide repeat expansion in the dystrophia myotonica protein kinase gene (DMPK) gene → abnormal expression of myotonin protein kinase → Myotonia (delayed muscle relaxation) is most notable when the patient is unable to release the hand after a handshake (grip myotonia), muscle wasting, cataracts, testicular atrophy, frontal balding, arrhythmia.
- Dysphagia, the most dangerous smooth muscle manifestation, significantly increases the risk of aspiration pneumonia.
- Cardiac involvement includes conduction problems and arrhythmias.
- Cataracts, Toupee (early balding in men), Gonadal atrophy.

Muscular dystrophies			
Diagnosis	**Duchenne**	**Becker**	**Myotonic**
Genetics	X-linked recessive deletion of dystrophin gene on chromosome Xp21		Autosomal dominant expansion of a CTG trinucleotide repeat in DMPK gene on chromosome 19q 13.3
Clinical presentation	• Onset: age 2-3 • Progressive weakness, Gower maneuver, calf pseudohypertrophy	• Onset: age 5-15 • Milder weakness compared to Duchenne muscular dystrophy	• Onset: age 12-30 • Facial weakness, hand grip myotonia, dysphagia
Comorbidities	• Scoliosis • Cardiomyopathy	• Cardiomyopathy	• Arrhythmias • Cataracts • Balding • Testicular atrophy/ infertility
Prognosis	• Wheelchair-dependent by adolescence • Death by age 20-30 from respiratory or heart failure	Death by age 40-50 from heart failure	Death from respiratory or heart failure depending on age of onset

Growing pains

- Growing pains are a common musculoskeletal complaint in children (bilateral, lower-extremity pain, occurs primarily at night and resolves by morning), occurring in approximately 10%-30% of children age 2-12 years.

- The etiology of growing pains is unknown, but they are unrelated to growth, despite their name.

- Children with growing pains have no systemic symptoms, normal activity levels, and normal physical examinations.

- Diagnosis and treatment:

- The diagnosis of growing pains can be made clinically in the absence of systemic symptoms and abnormal examination findings.

- Laboratory studies and radiographs are not necessary.

- Treatment of growing pains consists of parental education and reassurance along with massage, muscle-stretching exercises, and administration of over-the-counter analgesics.

- Children with growing pains should be followed closely to monitor for pain that increases in frequency or intensity, which may warrant further evaluation.

Growing pains	
Clinical features	• Occurs primarily at **night** & resolves by morning • Affects **lower extremities** (eg, thighs, calves), usually **bilateral** • **Normal** physical examination & activity
Treatment	• Parental education & reassurance • Massage, stretching exercises, heat & analgesics

Bone cancer

Osteoid osteoma

- Benign tumor of osteoblasts (that produce osteoid) surrounded by a rim of reactive bone.
- Occurs in young adults < 25 years of age (more common in males).
- Presents with progressively increasing pain that worsens at night without relation to physical activity and relieved by NSAIDS.
- Arises in cortex of long bones. The proximal femur is the most commonly affected site.
- X-ray appearance:
  - Round central lucency with a sclerotic margin.
- Most accurate diagnostic test:
  - CT scan or MRI of the affected leg.
- Treatment:
  - NSAIDs for pain, because the condition will resolve spontaneously.

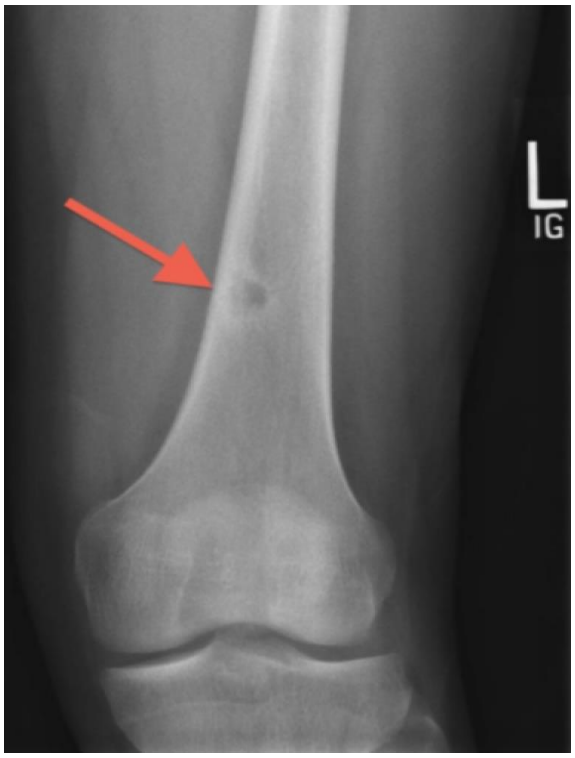

Osteoid osteoma	
Epidemiology	• Benign, bone-forming tumor • Most common in adolescent boys

Clinical features	• Proximal femur most common site
	• Pain
	  ◦ Worse at night
	  ◦ Relieved by NSAIDs
	  ◦ Unrelated to activity
	• No systemic symptoms

X-ray findings	• Small, round lucency
Treatment	• NSAIDs • Monitor for spontaneous resolution

NSAIDs = nonsteroidal anti-inflammatory drugs.

Giant cell tumor of bone (Osteoclastoma)

- Giant cell tumor of bone is a benign and locally aggressive skeletal neoplasm.
- Neoplastic mononuclear cells that express RANKL and reactive multinucleated giant (osteoclast-like) cells.
- Affects Epiphysis of long bones (often in knee region).
- Patients usually present with pain, swelling, and decreased range of joint motion at the involved site.
- Nearly 10%-35% of affected patients experience pathologic fractures due to thinning of the bone cortex in weight-bearing areas.
- X-ray appearance:

- It typically presents as osteolytic lesions (with a "soap-bubble" appearance on radiographs) in the epiphyseal regions of the long bones.

- Most accurate diagnostic test:

- Magnetic resonance imaging can show the tumor containing both cystic and hemorrhagic regions.

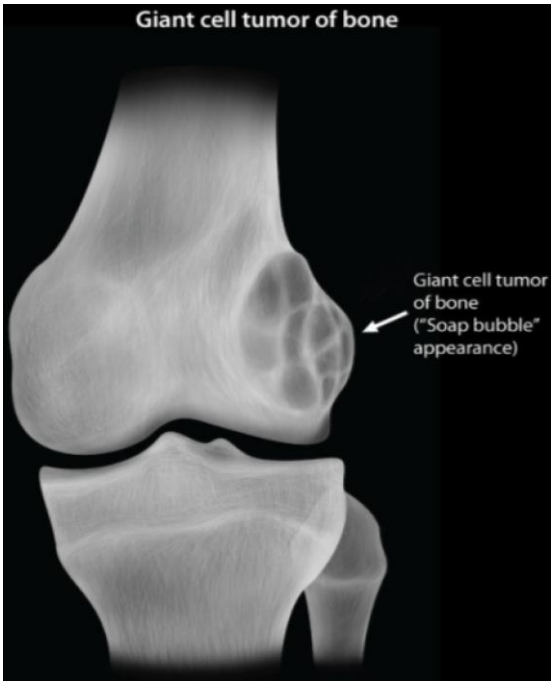

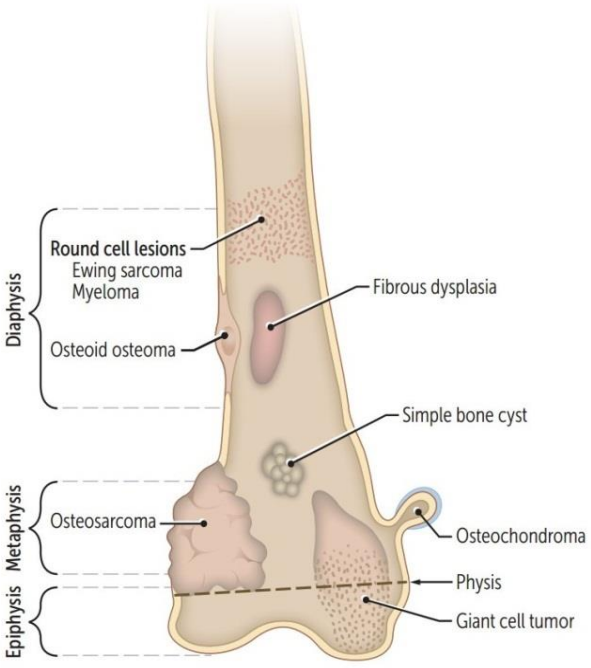

- Treatment:

- Surgery (intralesional curettage with or without bone grafting) is first-line treatment.

Osteogenic sarcoma (Osteosarcoma)

- Malignant proliferation of osteoblasts.

- Osteosarcoma is the most common primary bone tumor in children and young adults and typically involves the metaphysis of long bones.

- Presents as a pathologic fracture or bone pain with swelling.

- X-ray appearance:
- Classic x-ray findings include "sunburst" periosteal reaction and Codman triangle (from elevation of periosteum).

- Most accurate diagnostic test:
- CT scan of the leg.

- Treatment:
- Therapy includes chemotherapy and ablative surgery.

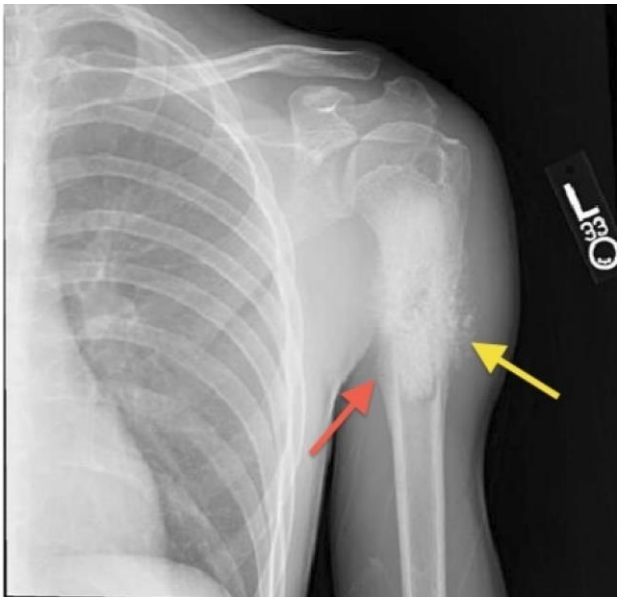

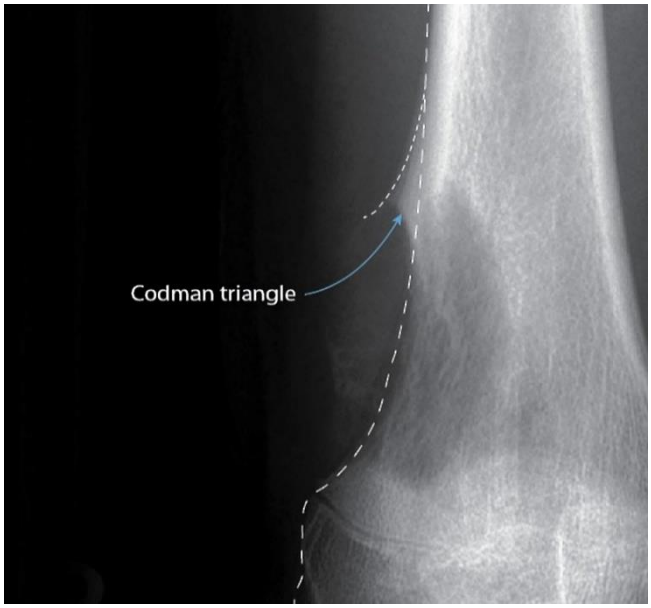



Ewing sarcoma

- Usually in male children (< 15 years of age).
- Ewing's sarcoma is a highly malignant tumor that is found in the lower extremity more than the upper extremity.
- The most common sites are the metaphysis and diaphysis of the femur, followed by the tibia and humerus.
- The tumor is very aggressive and metastasizes early to the lungs and lymph nodes.
- The clinical presentation includes pain and swelling for weeks or months. Erythema and warmth of the local area are sometimes seen.
- Ewing's sarcoma is often confused with osteomyelitis; however, characteristic x-ray findings can point to the diagnosis.
- X-ray appearance:

- Onionskin pattern due to lytic lesions causing laminar periosteal elevation.

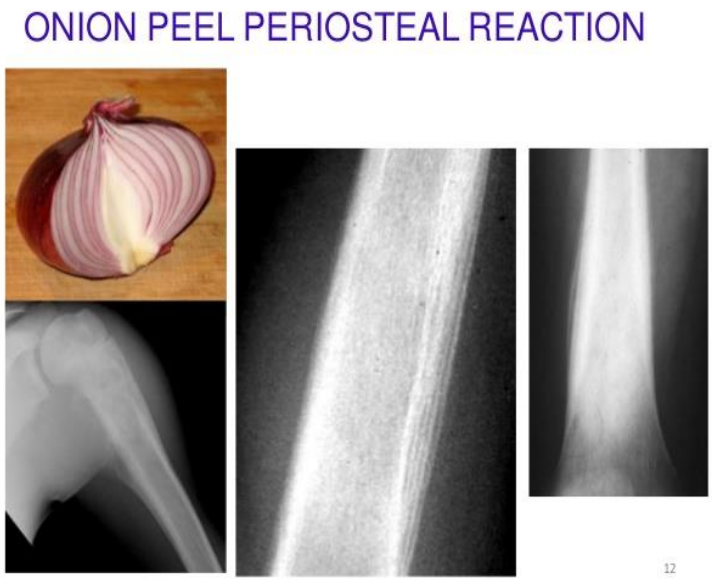

- Most accurate diagnostic test:

- Analysis for a translocation t(11;22) via bone biopsy.

- Treatment:

- Multidrug chemotherapy as well as local disease control with surgery and radiation.

CHAPTER 8

Pediatric Neurology

Neurology

Spina bifida

- After closure of neural tube, it induces bone to form vertebral arches (spinous processes).
- Spina bifida develops either due to failure of neural tube to form vertebral arches (spina bifida occulta, spina bifida cystica) or due to failure of closure of neural tube (spina bifida with myeloschisis).
- Strong evidence that maternal periconceptional use of folate reduces risk by half.

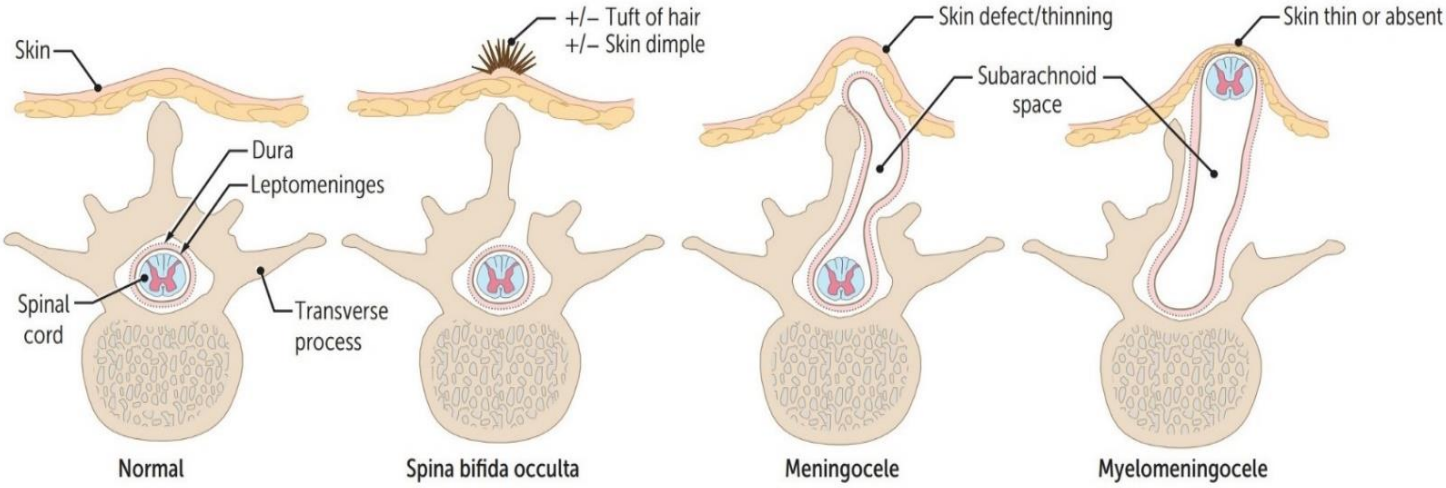

1. Spina bifida occulta (hidden)

- Vertebrae fail to form around spinal cord (missing spinous processes).
- Mildest form.
- More common in lumbar and sacral vertebrae.
- Missed with ultrasound (so it's occulta).
- Asymptomatic with tuft of hair over the defect.
- No cyst.
- Normal AFP level (not open NTDs and the defect is covered with mesoderm that form normal skin with tuft of hair over it).

2. Spina bifida cystica

- Cyst like protrusion at the site of the defect (missing spinous processes).
- If the cyst contains only CSF lined by dura and arachnoid (Herniation of meninges only), it is called → meningocele.
- If the cyst contains CSF and displaced spinal cord lined by dura and arachnoid (Herniation of meninges and spinal cord), it is called → meningomyelocele (seen with Arnold Chiari type 2).
- There is elevated AFP in both of them.
- Meningomyelocele is more severe than meningocele, because the displaced spinal cord may stretch lumbosacral spinal nerves → sensory loss and lower limb weakness.
- Low sacral lesions → bowel and bladder incontinence and perineal anesthesia without motor impairment.
- Must determine extent of neural involvement with MRI.
- CT scan of head for possible hydrocephalus.
- Surgical correction of the defect.

3. Spina bifida with myeloschisis

- Failure of caudal neuropore to close (open neural tube defect).
- Exposed, unfused neural tissue without skin/meningeal covering.
- Rarest but the severest form of spina bifida.
- Increase in AFP because it's an open neural tube defect.
- Surgical correction of the defect.



Posterior fossa malformations

1. Arnold chiari malformation:

- Cause:

- Downward displacement of certain parts of cerebellum through foramen magnum.

- Types:

A. Type 1 (most common):

- Downward displacement of cerebellar tonsils through the foramen magnum (1 structure).

- Usually asymptomatic in childhood, manifests in adulthood with headaches and cerebellar symptoms.

- Associated with spinal cavitations (syringomyelia).

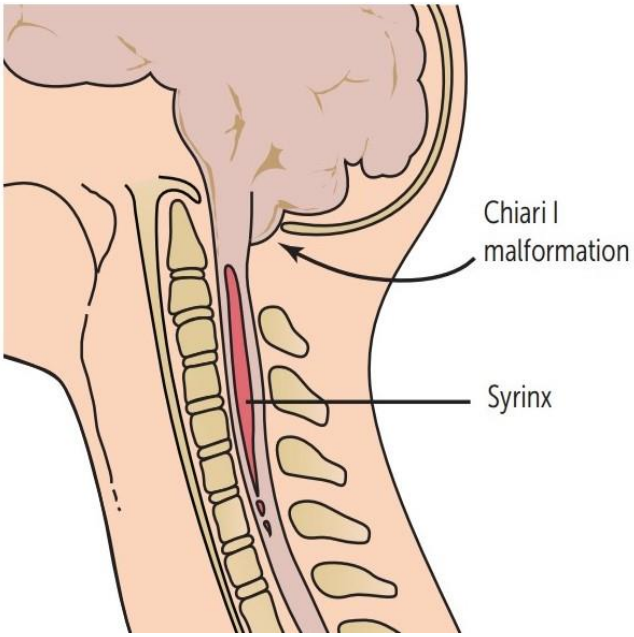

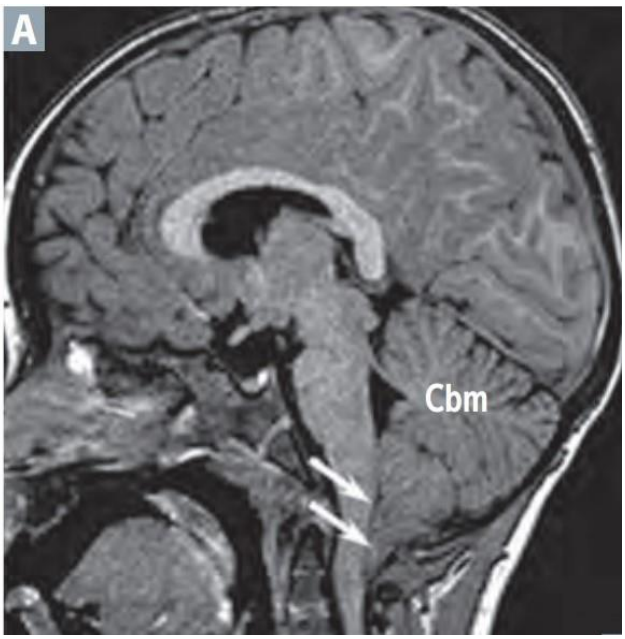

B. Type 2:

- Downward displacement of cerebellar vermis and tonsils (2 structures) through foramen magnum → aqueductal stenosis → noncommunicating hydrocephalus.

- Frequent association with lumbosacral meningomyelocele.

- Symptoms vary widely depending on the degree of cerebellar herniation.

2- Dandy walker malformation:

- Agenesis of cerebellar vermis leads to cystic enlargement of 4th ventricle that fills the enlarged posterior fossa.

- Failure of foramina of Luschka and Magendie to open → Associated with noncommunicating hydrocephalus, spina bifida.

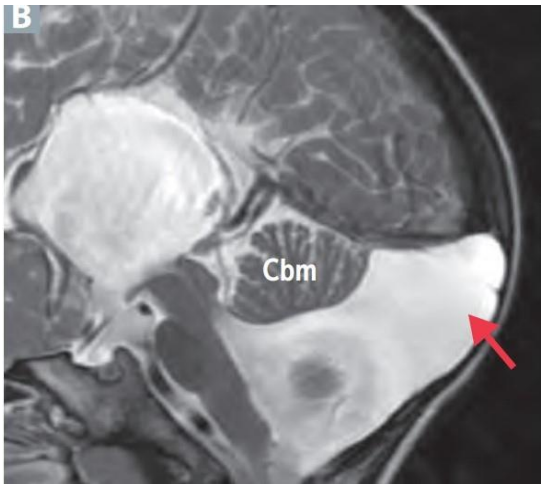

- Arnold chiari type 2 and dandy walker may present with noncommunicating hydrocephalus and spina bifida.

- Diagnosis and treatment:

- CT/MRI are used to identify anatomic abnormality and determine severity of herniation.

- Medical management for symptom control. Headaches and low-neck pain can be treated with muscle relaxants, NSAIDs.

- Surgical intervention is indicated for correction of functional disturbances or halt the progression of herniation and damage.

- Ventriculoperitoneal shunting to treat hydrocephalus.

Ventricular System

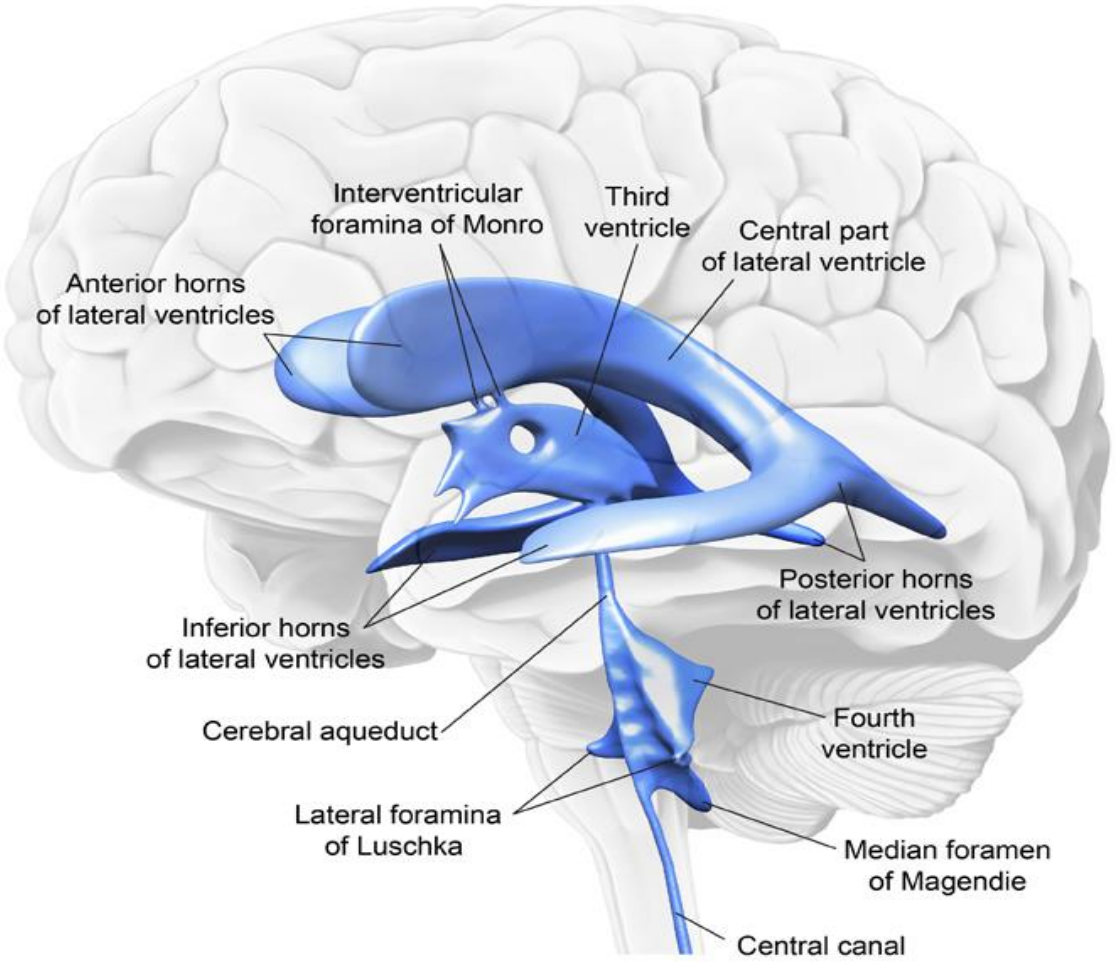

- Choroid plexus (contains choroid epithelial cells and is in the lateral, third, and fourth ventricles) secretes CSF into all ventricles.

- There are 4 interconnected ventricles in the brain: 2 lateral ventricles, a third ventricle, and a fourth ventricle.

- Lateral ventricles →3rd ventricle via right and left interventricular foramina of monro.
- 3rd ventricle → 4th ventricle via cerebral aqueduct of sylvius.
- 4th ventricle → subarachnoid space via:
  - 2 Foramina of Lushka = Lateral.
  - Foramina of Magendi = Medial.

- CSF is reabsorbed by arachnoid granulation and then drains into Dural venous sinuses.

- Dural venous sinuses are large venous channels that run through the dura. It drains blood from cerebral veins and receive CSF from arachnoid granulations, then empty into internal jugular vein.

Hydrocephalus

- Definition: Excess volume and/or pressure of CSF → Dilated ventricles.

- Types:

- Obstructive (noncommunicative) versus nonobstructive (communicative):

A. Obstructive (noncommunicative):

- Obstruction of flow of CSF within ventricles, most commonly occurs at narrow points as foramen of monrow or cerebral aqueduct of sylvius due to tumor or scarring (post-hemorrhage, post infection as meningitis, Chiari malformation type II, Dandy-Walker malformation).

B. Nonobstructive (communicative):

- It usually results from impaired CSF absorption by the arachnoid villi (no drainage) as a sequela of meningeal infection (tuberculosis meningitis) or subarachnoid/intraventricular hemorrhage.

- Rarely it occurs due to increased production of CSF caused by papilloma of the choroid plexus.

- Clinical presentation:

- Depends on rate of rise of intracranial pressure:

A. Infants:

- Increased head circumference.
- Bulging anterior fontanel.
- Distended scalp veins.
- Broad forehead.
- "Setting sun" sign.
- Increased DTRs.
- Spasticity, clonus.



B. Older child (subtler symptoms):

- Irritability.
- Lethargy.
- Poor appetite.
- Vomiting.
- Headache.
- Papilledema.
- Sixth-nerve palsy.

- Diagnosis:

- Both CT and MRI would provide much greater detail than ultrasound, which requires a widely open anterior fontanelle and is most useful in infants under 6 months of age.

- Increasing head circumference and signs of increased intracranial pressure in children should be evaluated with an imaging study such as a CT scan of the brain.

- CT will reveal ventricular dilation as well as the infant's anatomy.

- In an otherwise stable and asymptomatic infant, a sedated MRI could be considered to spare the child radiation exposure.

- Treatment for all types of hydrocephalus:

- Treatment of hydrocephalus consists of a shunt that is placed from the ventricle to the peritoneum (Ventriculoperitoneal shunting), pleura, or right atrium; which allows the excess CSF to drain rather than continue to collect in the ventricles.

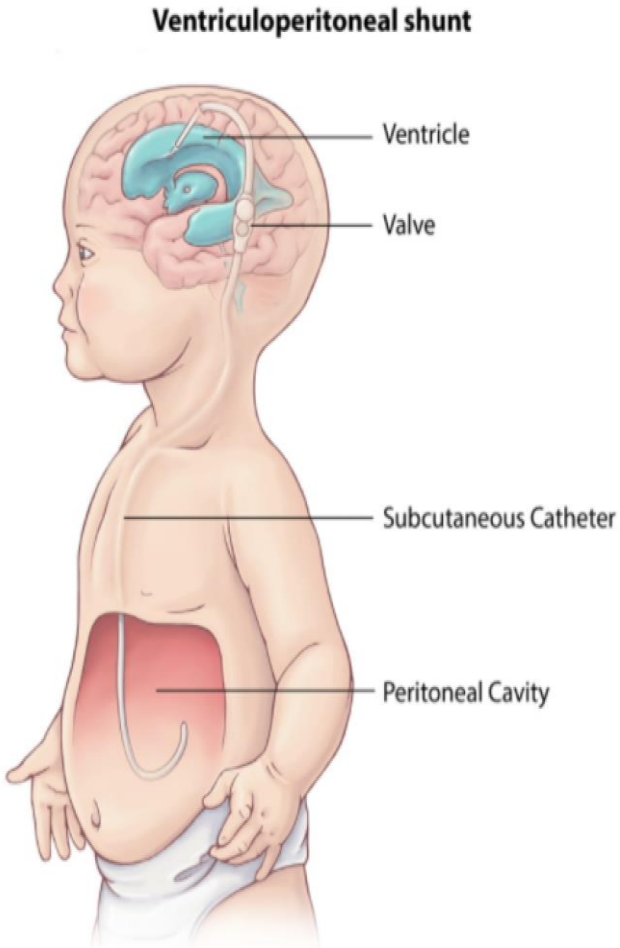

Intraventricular hemorrhage (IVH)

- Intraventricular hemorrhage (IVH) is most commonly seen in premature and LBW infants. Studies have shown that the incidence of IVH is inversely proportional to birth weight (the lower the birth weight, the greater the likelihood of IVH).

- The susceptibility is due to capillary fragility of the subependymal germinal matrix and immature autoregulation of cerebral blood flow. Exposure to vascular perfusion injuries have also been associated with IVH.

- Patients may present with pallor and anemia due to hemorrhage, hypotension, seizures, focal neurologic signs, bulging or tense fontanel, apnea and bradycardia; however, many cases remain asymptomatic, thus mandating transfontanel ultrasound for all newborns with predisposing risk factors.

- Communicating (nonobstructive) hydrocephalus is a complication in one-third of cases, as accumulating blood irritates the arachnoid villi, impairing its ability to absorb cerebrospinal fluid.

- IVH is subdivided into 4 grades, according to the severity of the bleeding. Long-term sequelae include motor and intellectual disabilities, and are seen mainly in severe forms (grade 3 and 4).

- These patients are at greatest risk of death; those who survive high-grade bleeds often suffer from significant neurodevelopmental disability (cerebral palsy).

- <u>Diagnosis and treatment:</u>

- Diagnosis is made by cranial ultrasound. Coagulated intraventricular blood has increased echogenicity compared to cerebrospinal fluid filling a normal ventricle. The degree of ventricular dilation can also be assessed on ultrasound. Repeated scans are typically required to monitor progression of the bleed.

- Prevention of preterm labor and antenatal administration of maternal corticosteroids are the only interventions that can reduce the incidence of IVH and improve overall mortality.

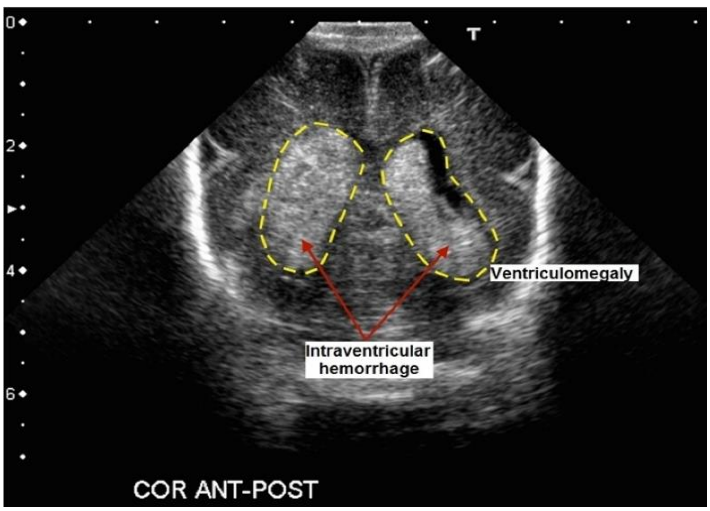

Febrile seizures

- Febrile seizures are a common and generally harmless cause of convulsions in children typically age 3 months to 5 years.
- Although they can be very frightening for parents, most febrile seizures are short and do not cause brain injury.
- Children with a family history of febrile seizures may be more susceptible to convulsions brought on by fever from infection (roseola) or recent immunization (MMR).
- The clinical diagnostic criteria are summarized in the table below.
- Simple febrile seizures are generalized (bilateral upper and lower extremities convulsing), last <15 minutes, and do not recur within 24 hours. Most febrile seizures are simple.
- Complex febrile seizures affect specific parts of the body corresponding to specific area of the brain, lasting > 15 minutes, and may recur within 24 hours.
- Patients may have a short postictal period of sleepiness but typically return to baseline quickly and have a normal neurologic examination.
- Multiple studies have shown that interventions such as imaging or lumbar puncture in the fully vaccinated child with a normal neurologic examination are low yield, unnecessarily invasive, and anxiety- provoking.
- Caregivers should be reassured about the good prognosis and that hospitalization for observation is unnecessary.
- Patients can be discharged home with education about seizure precautions and supportive care (hydration) for the concurrent Infection. Caregivers should be informed that antipyretics can make the child more comfortable, but there is no evidence that these will reduce the risk of future febrile seizures.

Febrile seizure	
Risk factors	• Fever from mild viral illness • Family history
Diagnostic criteria	• Typically age 3 months to 5 years • No previous afebrile seizure • No meningitis or encephalitis • No acute metabolic cause
Management	• Abortive therapy (≥5 minutes) • Reassurance
Prognosis	• Normal development/intelligence • ~30% risk of recurrence • <5% risk of epilepsy

Cerebral palsy (CP)

- Cerebral palsy (CP) is a group of clinical syndromes characterized primarily by nonprogressive motor dysfunction.
- CP is usually caused by prenatal insults to brain development, with premature birth before 32 weeks gestation as the greatest risk factor.
- Premature infants are more likely to have periventricular leukomalacia (white matter necrosis from ischemia/infection) and intraventricular hemorrhage (germinal matrix bleeding due to fragile vasculature and unstable cerebral blood flow) associated with CP. However, in many patients the underlying etiology is not determined.
- The 3 primary subtypes: spastic, dyskinetic, and ataxic are often multifactorial in etiology.
- Spastic subtype is the form most commonly seen (70 %). It presents as hypertonia and hyperreflexia that involve predominantly the lower extremities (spastic diplegia). Resistance to passive muscle movement increases with more rapid movement of the affected extremity ("clasp-knife").
- Many patients with CP suffer from vision, hearing, speech, or other impairments. Approximately 50% of patients also have intellectual disability.
- Management involves multidisciplinary therapies and anti-spastic medications to prevent and improve contractures.

Cerebral palsy	
Risk factors	• Prematurity • Low birth weight
Clinical features	• Delayed motor milestones • Abnormal tone, hyperreflexia • Comorbid seizures, intellectual disability
Diagnostic workup	• MRI of the brain • ± Electroencephalography • ± Genetic/metabolic testing
Management	• Physical, occupational, speech therapies • Nutritional support • Antispastic medications

Shaken baby syndrome

- Abusive head trauma (shaken baby syndrome) is the most common cause of death from child abuse.
- The most common mechanism of inflicted injury in infants involves violent shaking.
- Biological parents who are young, single, uneducated, or have a history of child abuse are the most common perpetrators.
- Infants are particularly susceptible to intracranial injury as they have a relatively large, heavy head, weak neck musculature, immature brain myelination, and a soft brain with higher water content.
- Repetitive acceleration-deceleration forces cause shearing of the dural veins and vitreoretinal traction.
- Repetitive acceleration-deceleration forces cause shearing of the dural veins and coup-contrecoup injury with brain impact on the skull. Subdural bleeding can manifest as seizures, increasing head circumference, bulging/tense anterior fontanelle, and altered mental status.
- In addition, shaking causes vitreoretinal traction and retinal hemorrhages, a virtually pathognomonic finding for abusive head trauma.
- The patient should undergo noncontrast head CT scan to evaluate for intracranial injury, fundoscopic examination to exclude retinal hemorrhage and a skeletal survey to identify other injuries.
- Hospitalization is required to ensure the child's safety from the abuser; child protective services must be notified immediately

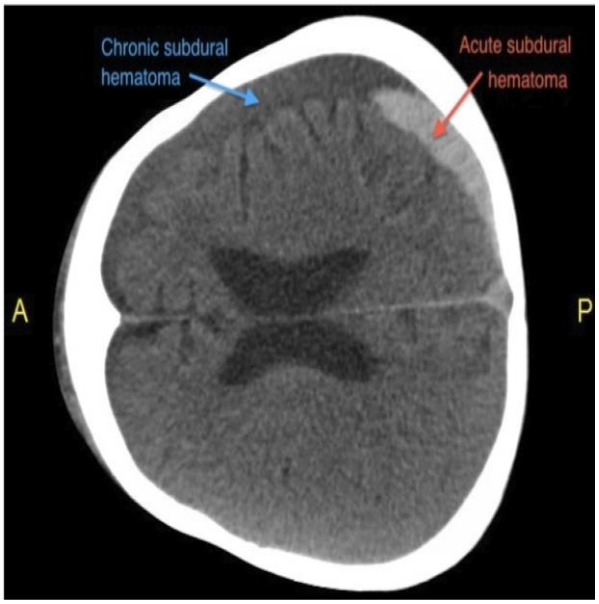

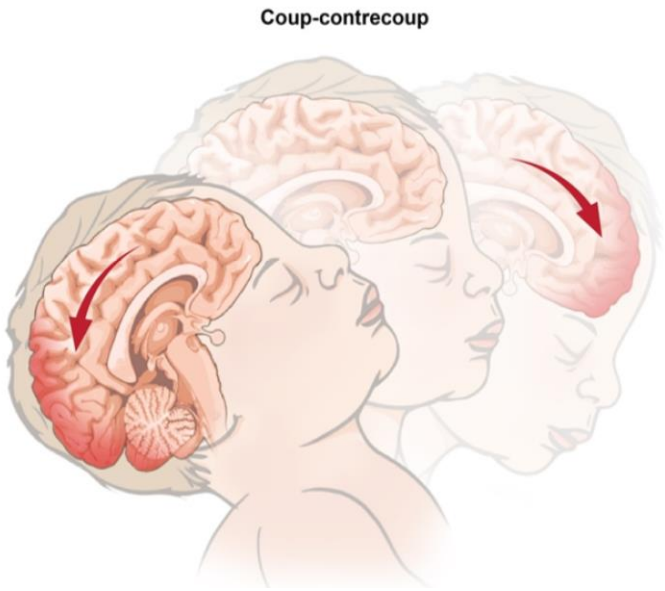

Pediatric Brain Tumors

- In the pediatric population, central nervous system (CNS) tumors are the most common solid tumors and the second most common malignancies after leukemias.
- Low-grade astrocytoma, particularly pilocytic astrocytoma, is the most common brain tumor in children.
- In children, most primary brain tumors arise infratentorially, craniopharyngiomas being an important exception.
- Most common type of benign pediatric primary brain tumor: pilocytic astrocytoma.
- Most common malignant pediatric primary brain tumor: medulloblastoma.

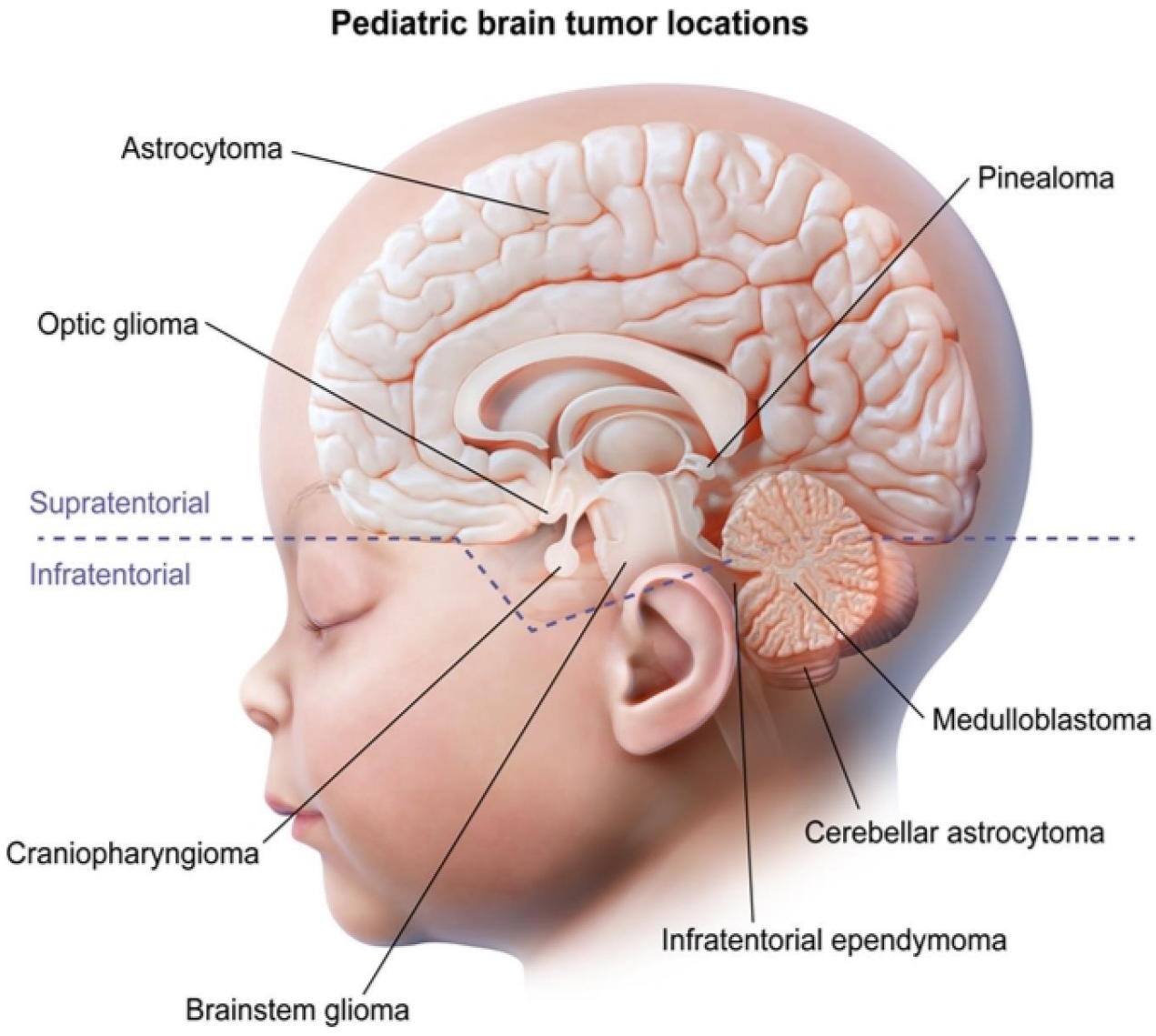

- Presenting symptoms vary depending on tumor location:

- Supratentorial tumor classically presents with seizures, weakness, and sensory changes.

- Posterior fossa tumor typically presents with cerebellar dysfunction (ataxia, dysmetria).

- Signs of increased intracranial pressure (early-morning headache/vomiting, papilledema) can occur as the tumor enlarges, regardless of tumor location.

A. Pilocytic astrocytoma:

- The most common brain tumor in children is pilocytic astrocytoma, a type of low-grade glioma that typically causes symptoms due to local pressure on adjacent structures and do not undergo malignant transformation.

- Pilocytic astrocytomas most commonly arise in the cerebellar hemispheres.

- Lesions of the cerebellum typically affect fine motor planning and coordination, leading to dysmetria and intention tremor (poor handwriting), as well as dysdiadochokinesia, which refers to the impaired ability to perform rapid, alternating movements.

- Given their proximity to the fourth ventricle, pilocytic astrocytomas can also present with signs of increased ICP due to obstructive hydrocephalus (headaches, vomiting, papilledema).

- MRI is the best diagnostic imaging for brain malignancy.

- Treatment: Surgery, radiation, and/or chemotherapy. With complete resection, 80–100% survival

B. Medulloblastoma:

- Medulloblastoma is the second most common posterior fossa tumor in children after cerebellar astrocytoma and originate from embryonic stem cells.

- The vast majority of medulloblastomas occur in the cerebellar vermis (red circle), which is particularly important for balance and gait coordination. As a result, symptoms include truncal or gait instability.

- Less commonly, medulloblastomas occur in the lateral cerebellar hemispheres similar to pilocytic astrocytomas, which affect fine motor planning and cause dysmetria, intention tremor, and dysdiadochokinesia.

- Given the proximity to the fourth ventricle, medulloblastoma can also cause obstructive hydrocephalus (red arrow), resulting in signs of increased intracranial pressure (headache, vomiting).

- Medulloblastomas have a potential for leptomeningeal spread and are treated aggressively with a combination of surgery, craniospinal radiation, and chemotherapy.

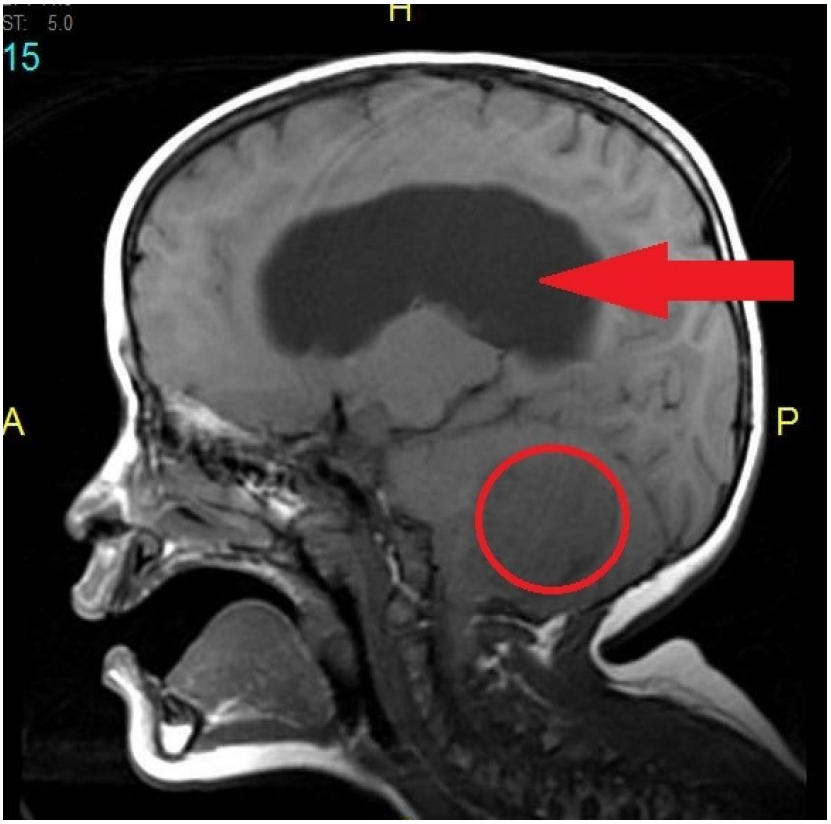

C. Pineal gland tumor, or pinealoma:

- The pineal gland is located in the quadrigeminal cistern and is responsible for melatonin production.
- Pineal gland tumors are rare, and germ cell tumors account for the majority of occurrences. Any abnormal pineal growth can produce serious complications from mass effect (Parinaud syndrome, obstructive hydrocephalus).
- Parinaud syndrome (dorsal midbrain syndrome) results from pressure on the pretectal region of the midbrain near the superior colliculus and cranial nerve III. Classic examination findings include limitation of upward gaze with a downward gaze preference (supranuclear vertical gaze palsy), bilateral eyelid retraction (Collier sign, sclera visible above the superior corneal limbus), and light near dissociation (pupils that react to accommodation but not to light).
- Pineal gland masses can also block cerebrospinal fluid flow in the aqueduct of Sylvius, causing obstructive hydrocephalus and symptoms of headache and vomiting.

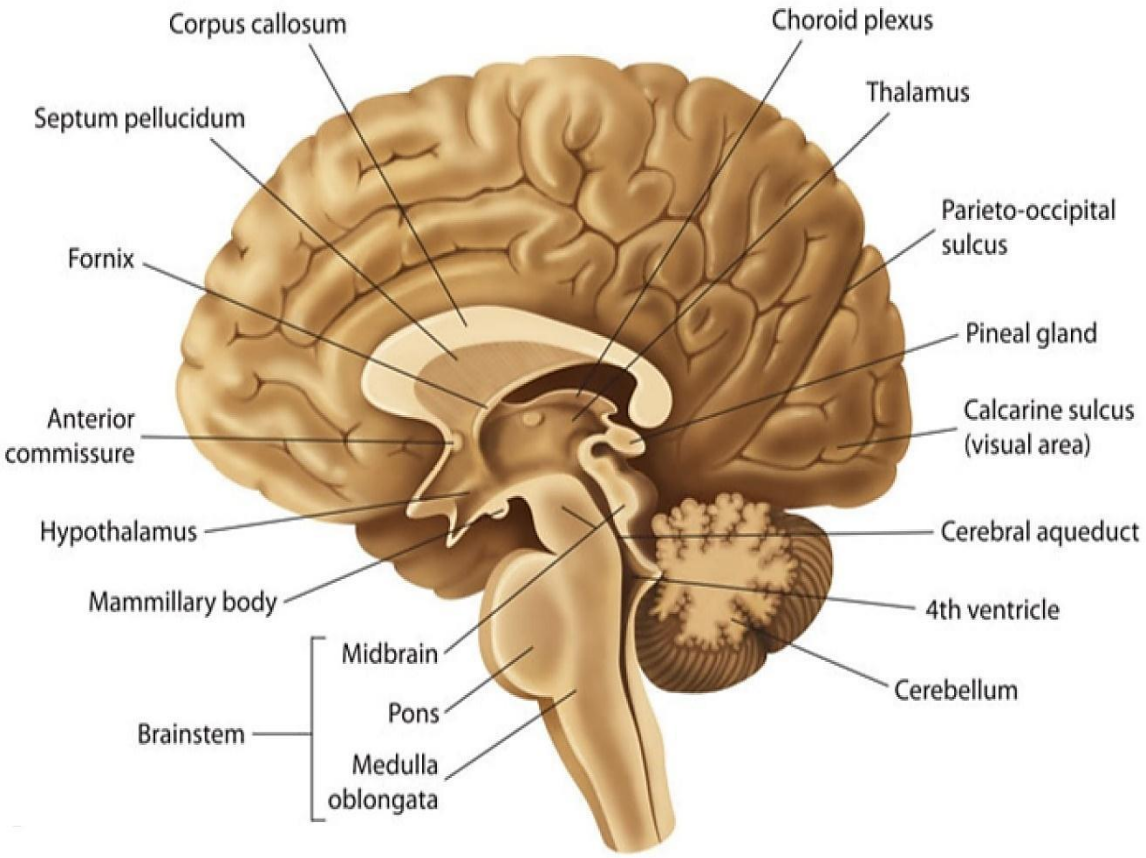
Corpus callosum
Choroid plexus
Thalamus
Septum pellucidum
Parieto-occipital sulcus
Fornix
Pineal gland
Anterior commissure
Calcarine sulcus (visual area)
Hypothalamus
Cerebral aqueduct
Mammillary body
4th ventricle
Midbrain
Cerebellum
Pons
Brainstem
Medulla oblongata

CHAPTER 9

Genetics and dysmorphology

Genetics and dysmorphology

Down syndrome (trisomy 21)

- Most common viable chromosomal disorder and most common cause of genetic intellectual disability.

- The multi-system abnormalities found in Down syndrome are the result of extra genetic material from chromosome 21.

- Three cytogenetic abnormalities can produce Down syndrome:

1. Trisomy 21 due to meiotic nondisjunction (failure of homologous chromosomes to separate during meiosis) accounts for nearly 95% of Down syndrome cases. Nondisjunction is almost always of maternal origin; increased maternal age is a risk factor.
2. Unbalanced Robertsonian translocations account for 2-3% of Down syndrome cases.
3. Mosaicism can also cause Down syndrome. Patients have two cell lines: one with a normal genotype, and one with trisomy 21.

- Findings:

- Intellectual disability, flat facies, slanted palpebral fissures, prominent epicanthal folds, single palmar crease, gap between 1st 2 toes, Brushfield spots.

- Cardiac defects are found in approximately half of all infants with Down syndrome, with the endocardial cushion defect (complete atrioventricular septal defect) and ventricular septal defect most often seen. Complete atrioventricular septal defect (CAVSD) is the most common congenital heart defect in patients with Down syndrome. Failure of the endocardial cushions to merge results in both ventricular septal defect (VSD) and atrial septal defect (ASD) as well as a common atrioventricular valve due to poor mitral and tricuspid valve development.

- Gastrointestinal tract abnormalities are also identified in 10-15% of this patient population, and can include duodenal atresia, Hirschsprung's disease, and tracheoesophageal fistula.

- ↑ risk of early onset Alzheimer disease (chromosome 21 codes for amyloid precursor protein). The extra copy of APP present in Down syndrome is thought to accelerate amyloid accumulation and lead to early-onset Alzheimer's dementia.

- Individuals with Down syndrome have a 10- to 20-fold increased risk of developing acute lymphoblastic leukemia, and their risk for developing acute myelogenous leukemia is also increased.

- Atlantoaxial instability:
  - Atlantoaxial instability is a malformation seen in 10-15% of patients with Down syndrome, and most commonly occurs due to excessive laxity in the posterior transverse ligament, which causes increased mobility between the atlas (C1) and the axis (C2).

- Fortunately, only 1-2% of Down syndrome patients with atlantoaxial instability are symptomatic.
- Symptoms usually progress over several weeks and result from compression of the spinal cord.
- On examination, upper motor neuron symptoms such as leg spasticity, hyperreflexia, a positive Babinski sign, and clonus are often present. Patients with Down syndrome are normally hypotonic, and they may remain hypotonic or have increased tone with symptomatic atlantoaxial instability.
- Atlantoaxial instability is suspected on physical examination and diagnosed with lateral radiographs of the cervical spine in flexion, extension, and in a neutral position.
- Treatment consists of surgical fusion of the first cervical vertebrae (C1) to the second (C2).

- First-trimester ultrasound commonly shows ↑ nuchal translucency and hypoplastic nasal bone.
- Triple test, performed at weeks 16-18 of gestation, detects low alpha-fetoprotein (AFP) levels. A finding of low AFP on triple test is associated with a diagnosis of Down syndrome and is therefore an indication for amniocentesis. Karyotyping of fetal cells contained in amniotic fluid can diagnose Down syndrome.

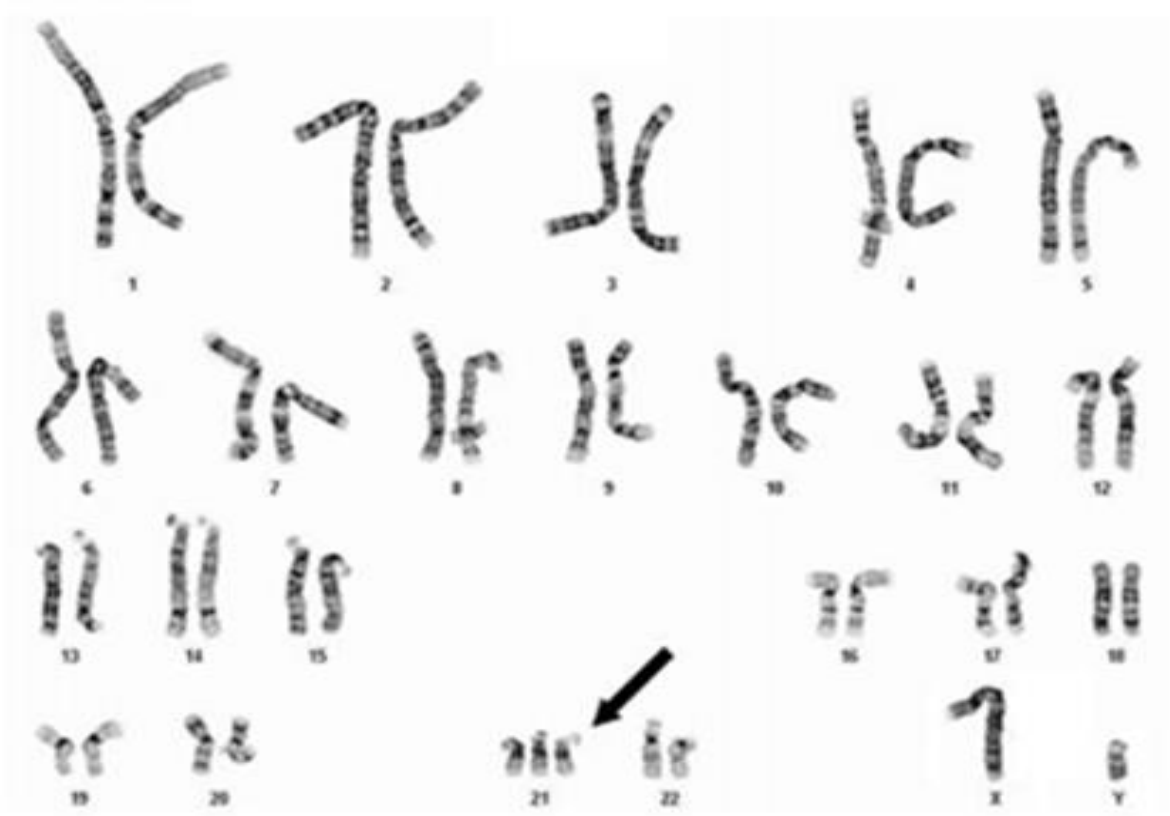

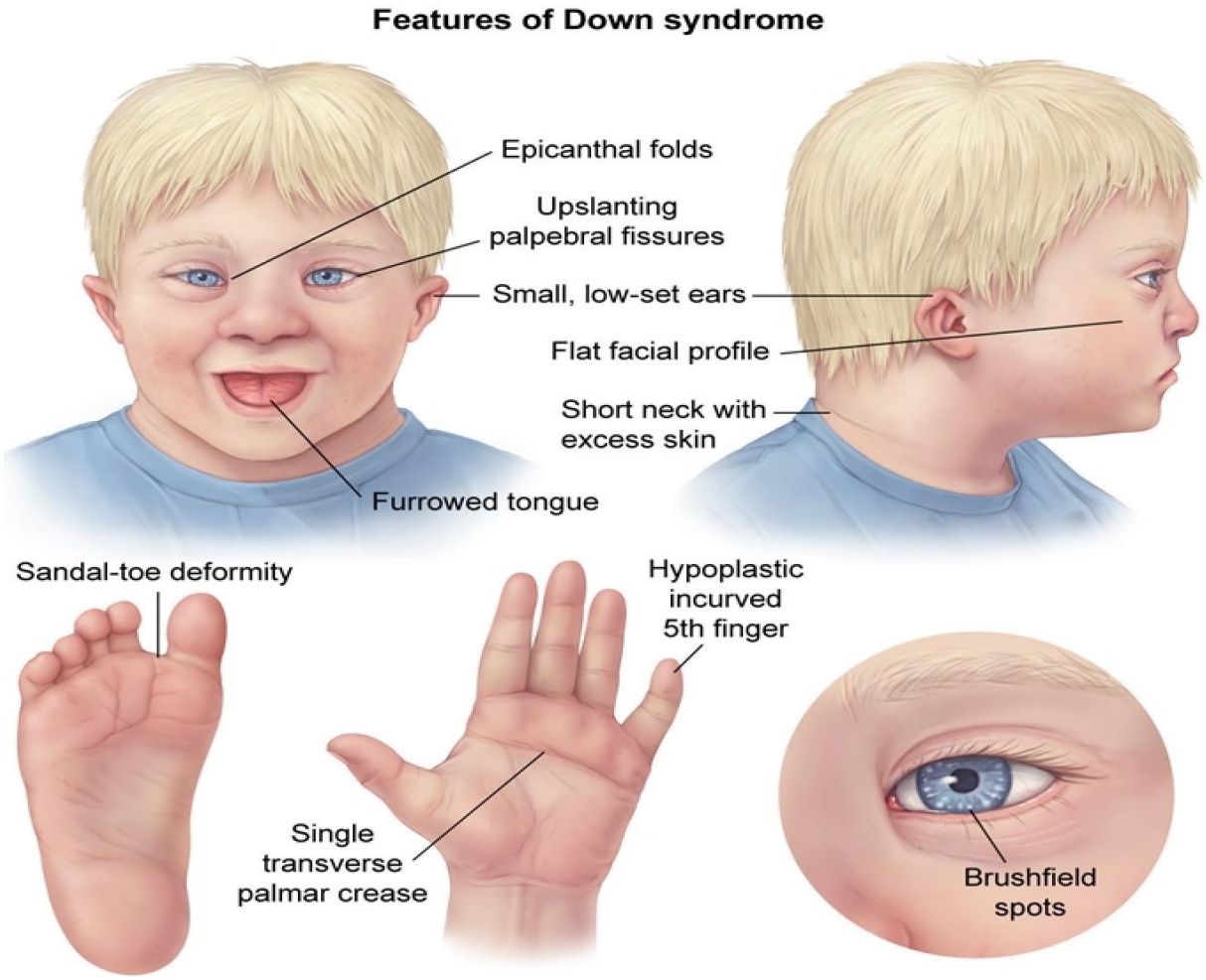

Nondisjunction

- The failure of homologous chromosomes to separate properly during meiosis.

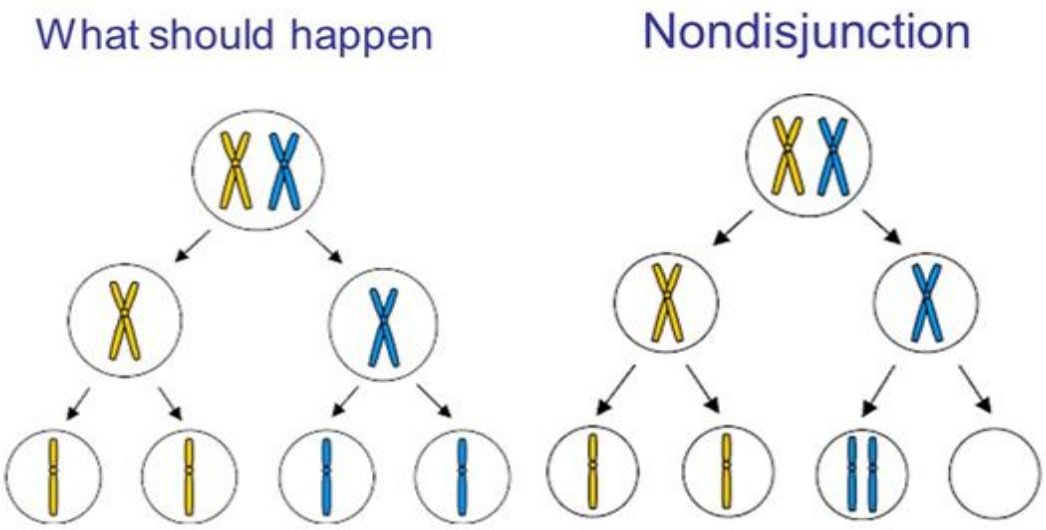

Edwards Syndrome

- After trisomy 21, trisomy 18 (Edwards syndrome) is the second most common autosomal trisomy observed in live births.

- The risk of trisomies increases with maternal age due to meiotic nondisjunction within maternal oocytes.

- Findings:

- PRINCE Edward: Prominent occiput, Rocker-bottom feet, Intellectual disability, Nondisjunction, Clenched fists (with overlapping fingers), low-set Ears, micrognathia (small jaw), congenital heart disease, omphalocele.

- Congenital heart disease occurs in more than half of affected patients with ventricular septal defect (VSD) being the most common abnormality. VSD presents as a holosystolic murmur that is best heard at the left lower sternal border.

- Diagnosis is suspected based on prenatal ultrasonography, and karyotype (prenatal or postnatal) confirms the diagnosis.

- Approximately 95% of trisomy 18 patients die during their first year of life, most commonly due to cardiac failure from congenital heart disease or respiratory failure from hypoventilation or aspiration. Surgical repair of VSD improves survival, but those who survive are severely intellectually disabled.

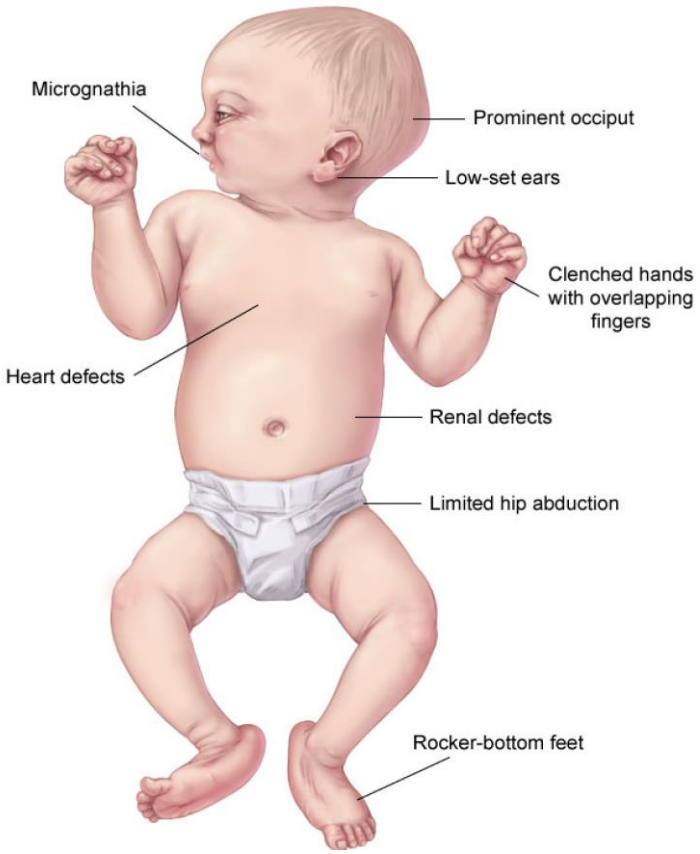

Patau syndrome (trisomy 13)

- Findings:

- Severe intellectual disability, rockerbottom feet, microphthalmia, microcephaly, cleft liP/Palate, holoProsencephaly, Polydactyly, cutis aPlasia (congenital absence of skin most commonly in the scalp), congenital heart disease, Polycystic kidney disease.

- Death usually occurs by age 1.

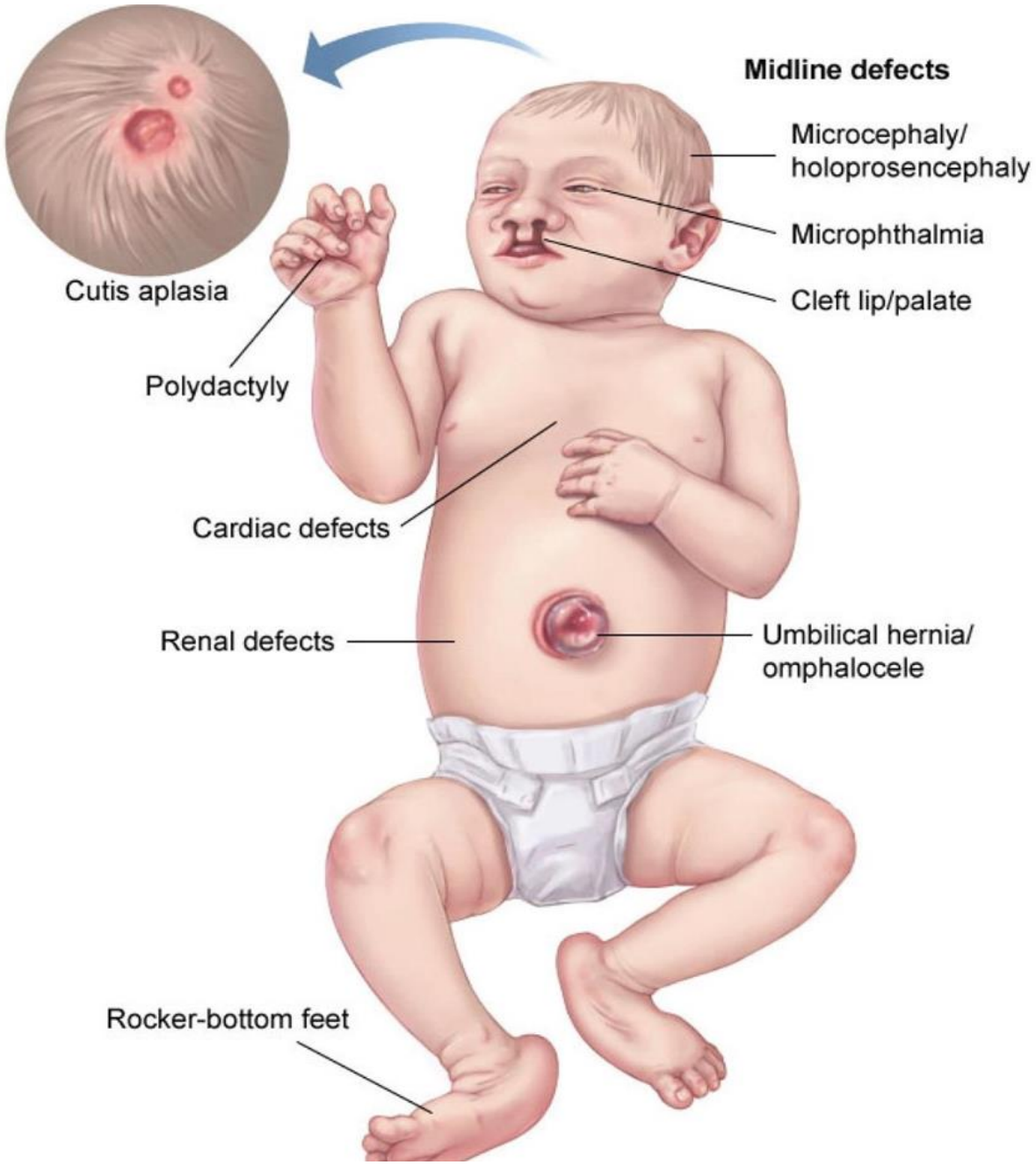

Turner syndrome [female] (45, XO)

- The classic variant of complete monosomy (45, XO) occurs in about 50-60% of Turner syndrome patients, with another 30% demonstrating mosaicism.

- Clinical manifestations of Turner syndrome include the abnormalities listed below:

1. Phenotypic abnormalities:

- Short stature, webbed neck, high palate, low posterior hair line, shield chest: broad chest with widely spaced nipples.

- Short stature is the most common clinical finding in patients with Turner syndrome.

2. Urogenital abnormalities:

- The ovaries become infiltrated with fibrous tissue ("streak ovaries") → decreased estrogen and increased gonadotropins, Primary amenorrhea, absent secondary sex characteristics, minimal or no thelarche (breast development), horseshoe kidney (fusion of kidneys at the midline).

- Because ovaries normally produce estrogen, patients with TS are estrogen deficient. Estrogen normally serves to inhibit osteoclast-mediated bone resorption, leading to increased bone mineral density. The lack of estrogen in patients with TS therefore leads to increased bone resorption, which causes decreased bone mineral density and increased risk of osteoporosis. Estrogen replacement therapy is therefore given to girls with TS to promote normal sexual maturation and reduce the risk of osteoporosis.

3. Cardiac abnormalities: coarctation of the aorta (3%-10%), bicuspid aortic valve 20%-30%). Patients with TS should undergo echocardiography to evaluate for bicuspid aortic valve, coarctation of the aorta, and aortic root dilation.

4. Lymphatic abnormalities:

- Edema of extremities in neonates, cystic hygromas.

- The edema is likely due to congenital lymphedema from abnormal development of the lymphatic network. The dysfunctional lymphatic system causes accumulation of protein-rich interstitial fluid in the hands, feet, and neck (webbed neck). Severe obstruction of lymphatic vessels can result in cystic hygroma of the neck and fetal hydrops.

- Lymphedema is generally nonpitting as opposed to the pitting edema seen with liver failure, congestive heart failure, or nephrotic syndrome.

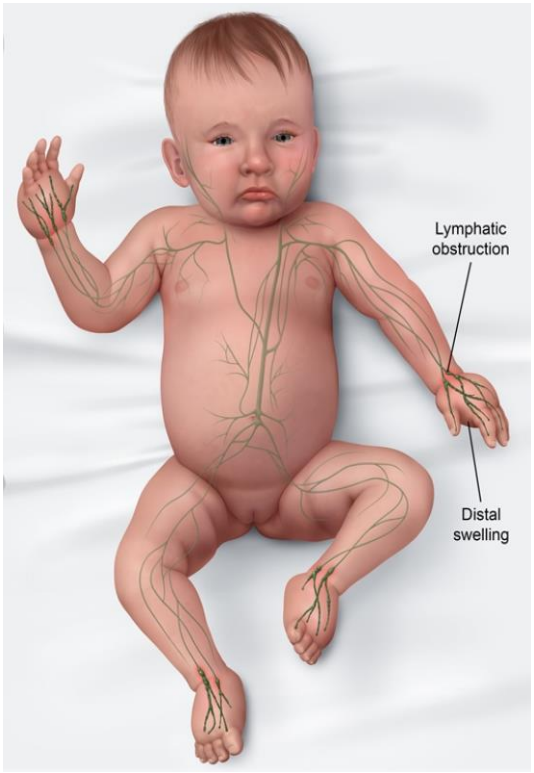
Lymphatic obstruction
Distal swelling

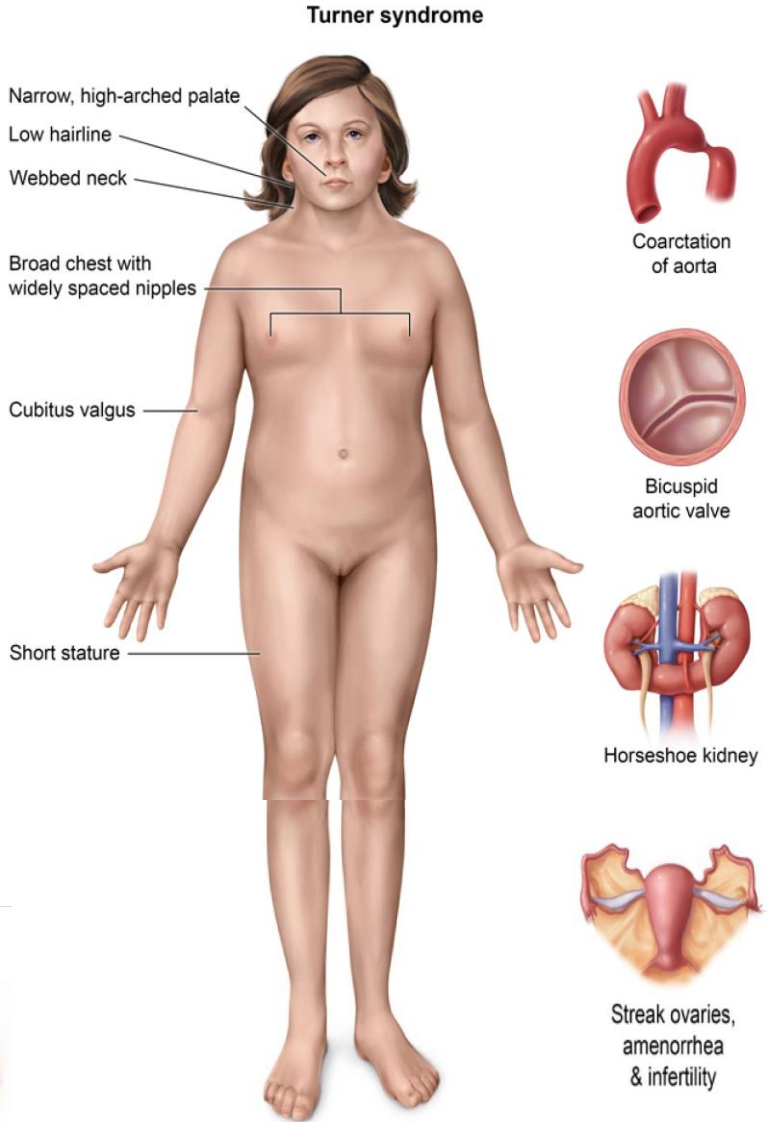
Turner syndrome
Narrow, high-arched palate
Low hairline
Webbed neck
Broad chest with widely spaced nipples
Cubitus valgus
Short stature
Coarctation of aorta
Bicuspid aortic valve
Horseshoe kidney
Streak ovaries, amenorrhea & infertility

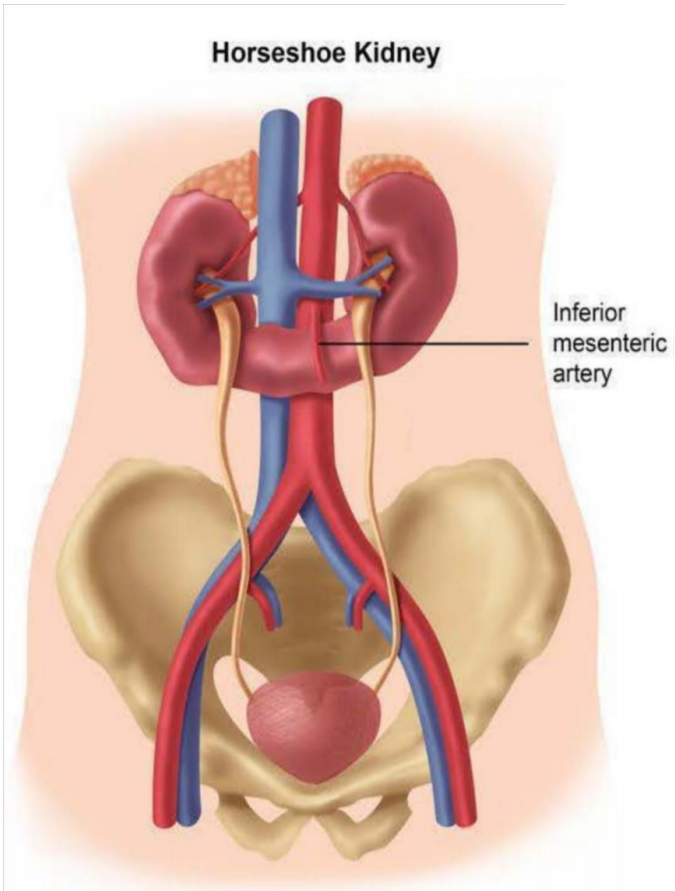
Horseshoe Kidney
Inferior mesenteric artery

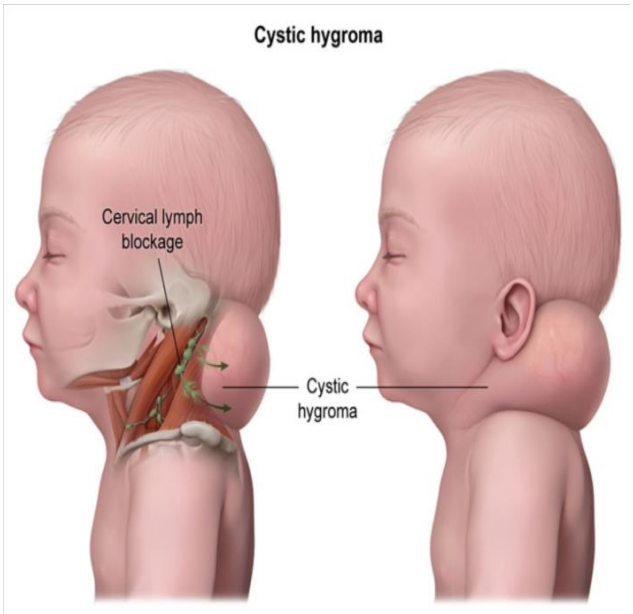
Cystic hygroma
Cervical lymph blockage
Cystic hygroma

Klinefelter syndrome [male] (47, XXY)

- The 47 XXY karyotype is diagnostic of Klinefelter syndrome.

- Neonates are phenotypically normal. Signs do not become evident until puberty.

- <u>The major features of this disorder are described below:</u>

1. Klinefelter syndrome causes primary testicular failure due to hyalinization and fibrosis of the seminiferous tubules causing the testes to be small and firm:

- The interstitial Leydig cells are damaged as well, resulting in low testosterone levels and erectile dysfunction.

- These abnormalities result in oligo/azoospermia, infertility, and absence of secondary sex characteristics.

- Because of the low circulating levels of testosterone, LH and FSH are elevated (loss of feedback inhibition).

- Common cause of hypogonadism seen in infertility work-up.

2. Testosterone deficiency also leads to the characteristic eunuchoid body habitus:

- Patients have tall stature and gynecomastia.

- The hypogonadism causes epiphyseal fusion to be delayed, hence the elongated limbs.

- Facial and body hair is absent and muscle mass is decreased.

3. Cognitive symptoms:

- Mild mental retardation is seen in some patients, though the majority have normal intelligence.

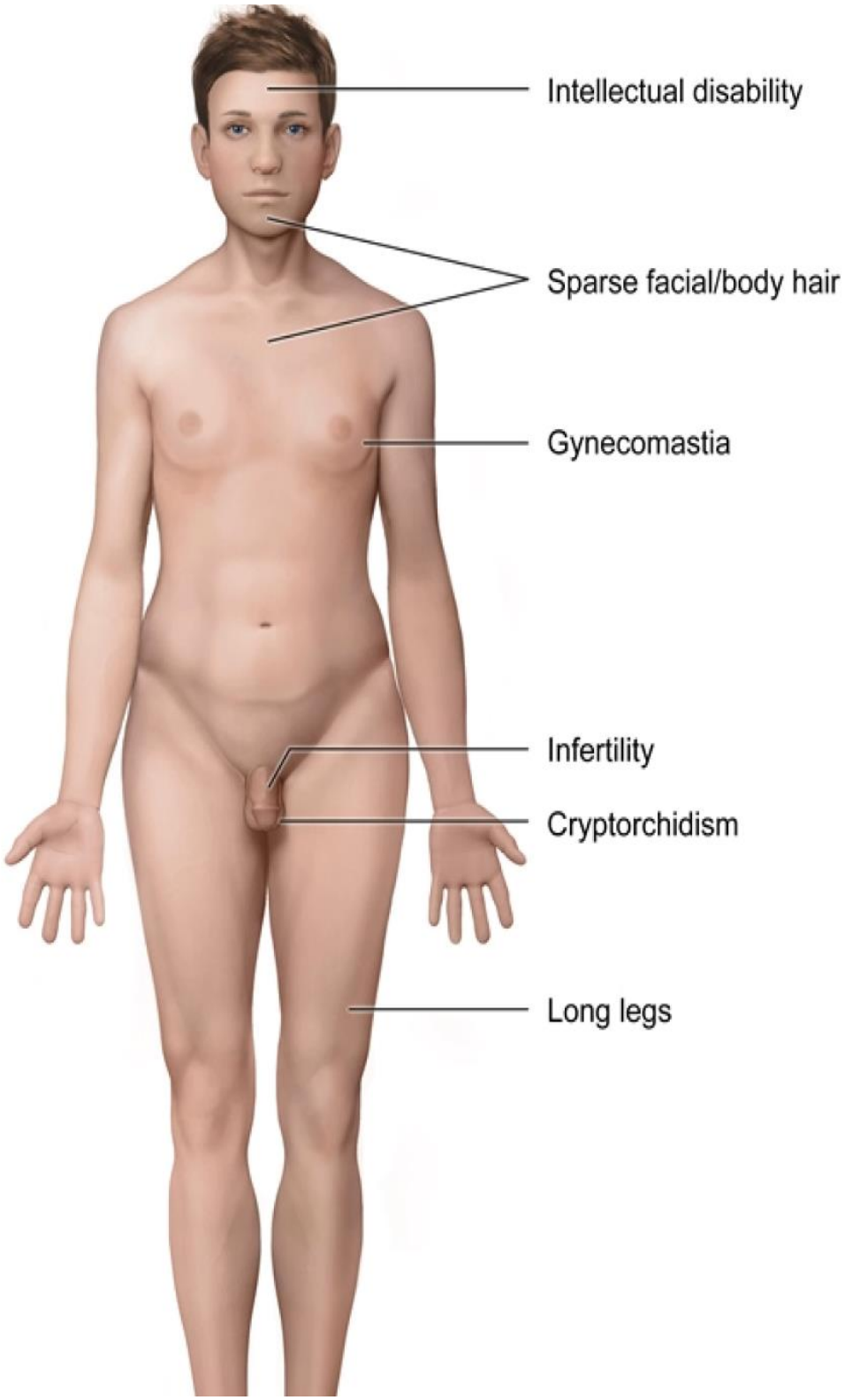
Intellectual disability
Sparse facial/body hair
Gynecomastia
Infertility
Cryptorchidism
Long legs

Friedreich Ataxia (FA)

- It is an autosomal recessive condition characterized by an excessive number of trinucleotide repeat sequences (GAA), resulting in an abnormality of the frataxin protein.
- Frataxin is highly expressed in the brain, heart, and pancreas. Therefore, the typical clinical presentation of FA includes neurologic dysfunction, hypertrophic cardiomyopathy, diabetes mellitus and skeletal deformities (scoliosis and 'hammer toes').
- Neurological manifestations (gait ataxia, frequent falling, dysarthria) result from degeneration of the spinal tracts (spinocerebellar tracts, posterior columns, pyramidal tract).
- The disorder is progressive with poor prognosis. Most patients are wheelchair bound by the age of 25, with death occurring by 30-35 years of age.
- Mean age of death is 30-40 due to complications of cardiomyopathy. Cardiomyopathy develops in up to 90% of the patients.
- The diagnosis of FA can be confirmed with genetic testing.
- Management involves a multidisciplinary approach (including physical therapy and psychological support), as no disease-modifying therapies are currently available.
- May show genetic anticipation (disease severity ↑ and age of onset ↓ in successive generations).

Disease	Trinucleotide Repeat
Huntington disease	(CAG)n
Myotonic dystrophy	(CTG)n
Fragile X syndrome	(CGG)n
Friedreich ataxia	(GAA)n

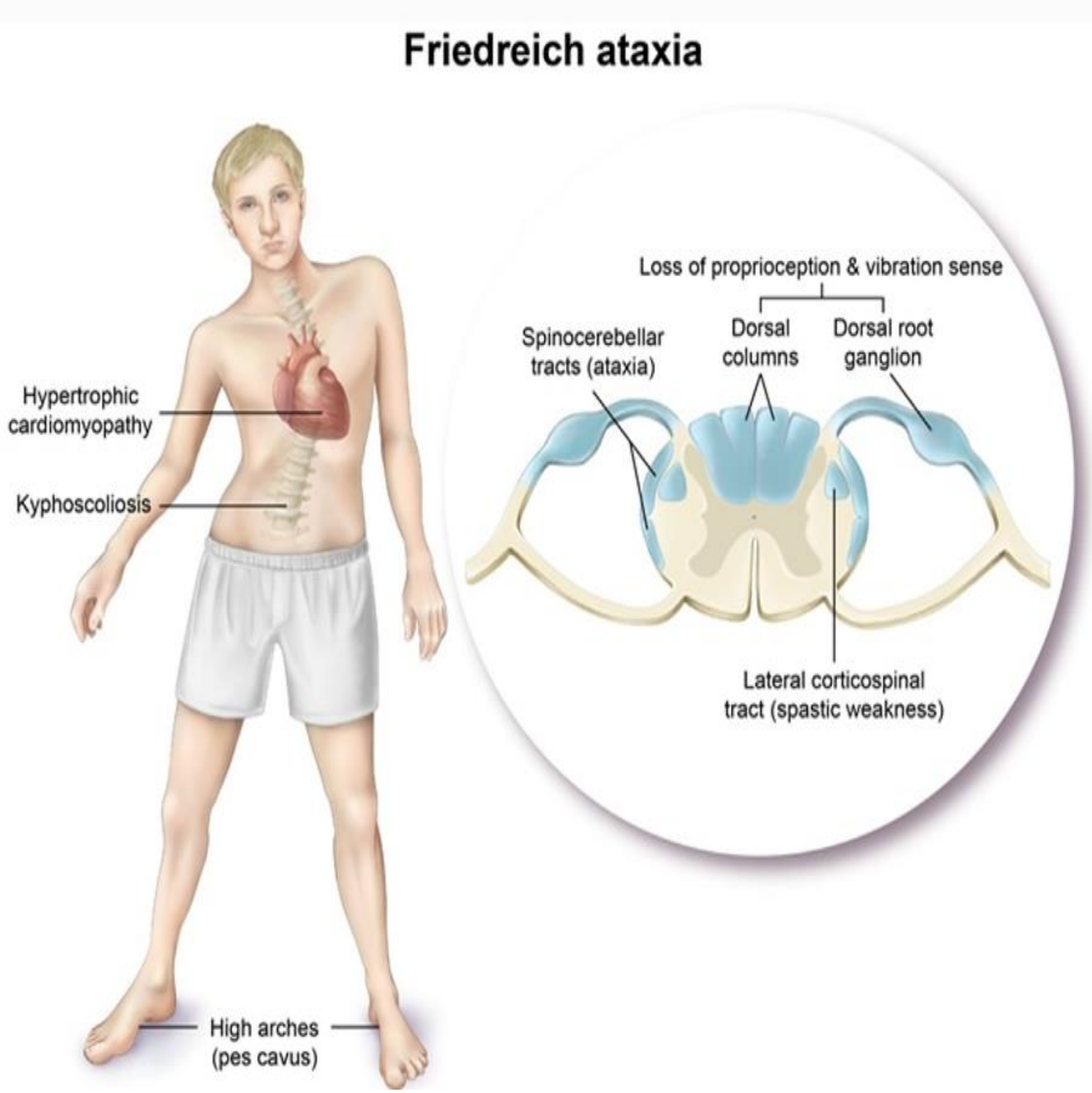

Fragile X syndrome (FXS)

- Fragile X syndrome (FXS) Is an X-linked disorder that is the most common cause of inherited intellectual disability.
- The FMR1 gene product is required for normal neural development.
- Trinucleotide repeat expansion [(CGG)n] occurs during oogenesis.

- Patients with fragile X syndrome display the following features:

1. Body habitus:

- Macrosomia with increased head circumference may be present at birth.

- Older patients have dysmorphic facial features including large jaw, large protruding ears, long thin face and prominent forehead.

- Postpubertal males invariably have macroorchidism (enlarged testes).

2. Cognitive impairment:

- Becomes evident after the 1st year of life.

- Patients demonstrate mild-to-moderate mental retardation, severe language delay and behavioral abnormalities (such as aggressiveness).

- Autistic features are more common in children with fragile X syndrome than in the general population.

- Early diagnosis is crucial for appropriate developmental and behavioral services to be instituted at a young age.

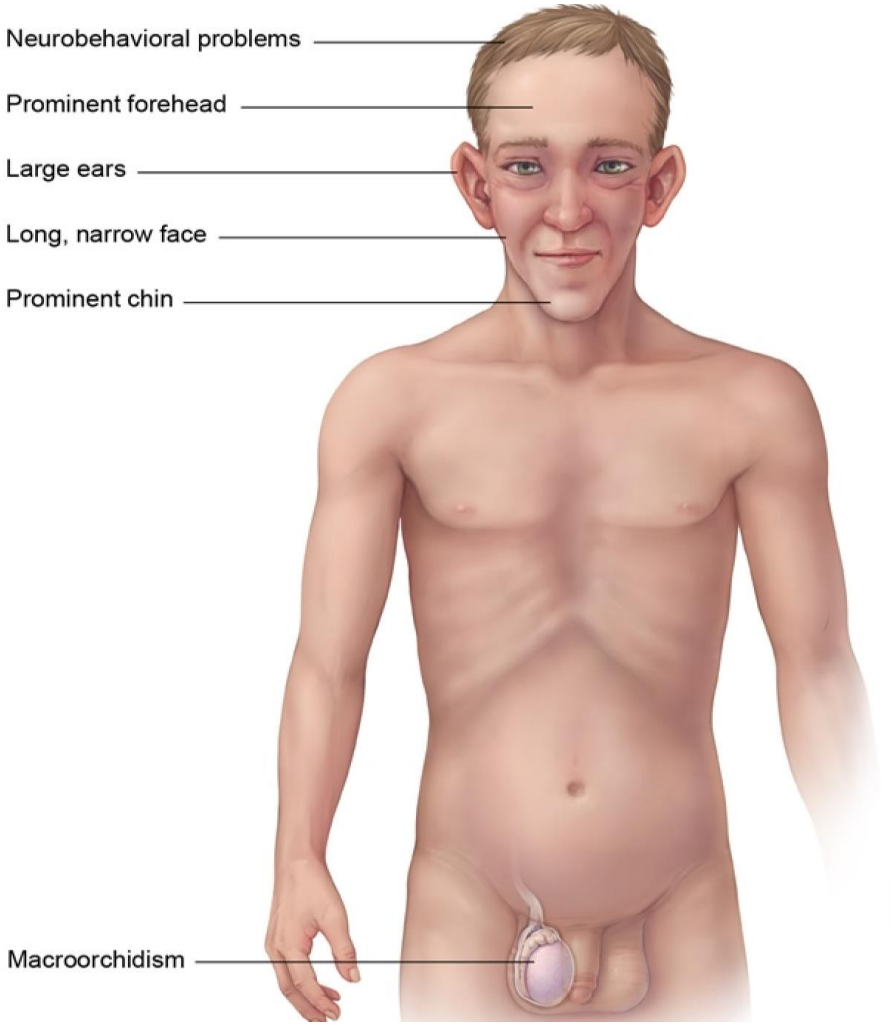

Prader-Willi syndrome (PWS)

- Normally, people inherit 2 active copies of each gene -1 from the mother and 1 from the father.
- In prader-willi syndrome, maternally derived genes are silenced (imprinted) and only paternally derived genes are active.
- Disease occurs when the Paternal allele is deleted or mutated.
- 25% of cases due to maternal uniparental disomy (inherit both copies of a section of chromosome 15 from their mother).
- Results in hyperphagia, obesity, intellectual disability, hypogonadism, and hypotonia.
- The deletion of the paternal copy of chromosome 15q11-q13 results in poor suckling and feeding problems in infancy followed by a life of compulsive binge-eating and obesity-related problems.
- Genetic testing is required to confirm diagnosis.
- Management revolves around obesity and its complications. Patients benefit from a structured eating environment and strict limitation of food intake (locks on refrigerator, close supervision).
- They should be screened for sleep apnea (central and obstructive) as well as type 2 diabetes mellitus.
- Patients with AngelMan syndrome suffer from deletion or mutation of Maternally-derived genes. 5% of cases due to paternal uniparental disomy (inherit both copies of a section of chromosome 15 from their father). Results in inappropriate laughter (“happy puppet”), seizures, ataxia, and severe intellectual disability.

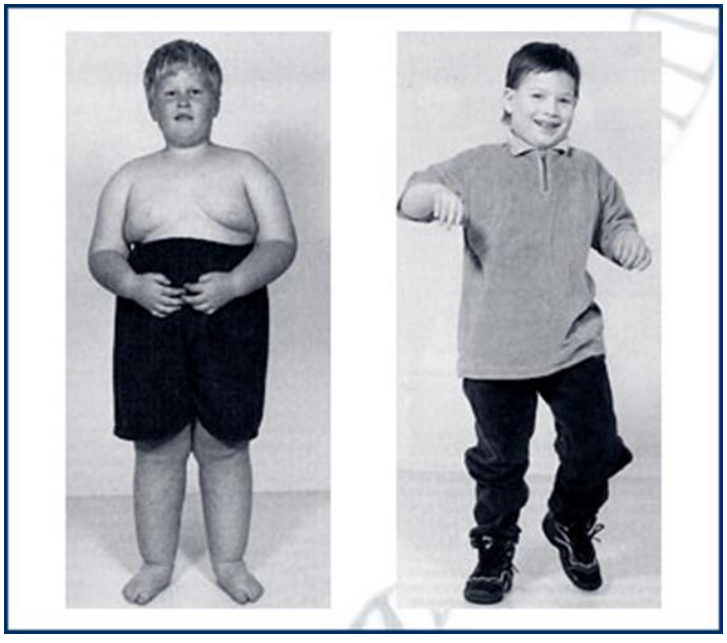

DiGeorge syndrome (DGS)

- DiGeorge syndrome (DGS) is disorder usually caused by the microdeletion of chromosome 22q11, resulting in poor development of the pharyngeal pouch system and subsequent abnormalities of the face, neck, and mediastinum.

- The clinical presentation typically includes the pentad of congenital heart disease, facial dysmorphia, thymic hypoplasia, cleft palate, and hypocalcemia.

- Once DGS is suspected, serum calcium levels and echocardiography must be ordered immediately.

- Hypocalcemia results from hypoplasia of the parathyroid glands. Neonates are at high risk for life-threatening tetany, seizures, and arrhythmias that can further exacerbate co-existing heart problems and may require aggressive calcium repletion.

- Echocardiography is critical as the cardiac anomalies in DGS are variable and place the patient at great risk for heart failure and hypoperfusion. Truncus arteriosus is strongly associated with DGS, and other common conditions include tetralogy of Fallot, interrupted aortic arch, and septal defects.

- Depending on the degree of thymic hypoplasia, patients can have T-cell lymphopenia and increased risk of viral and fungal infections. Humoral immunodeficiency can also result from defective T-cell help in B-cell activation for antibody production, increasing susceptibility to bacterial infections as well. Therefore, all patients with DGS should receive routine killed or subcomponent vaccines. However, the safety of live vaccines (measles-mumps-rubella, intranasal influenza, rotavirus, and oral polio virus vaccines) for these patients depends on the degree of immunodeficiency.

DiGeorge syndrome/velocardiofacial syndrome	
Pathogenesis	• Chromosome 22q11.2 deletion • Defective development of pharyngeal pouches
Clinical features	• **C**onotruncal **c**ardiac defects (tetralogy of Fallot, truncus arteriosus, interrupted aortic arch) • **A**bnormal facies • **T**hymic hypoplasia/aplasia (**T**-cell deficiency) • **C**raniofacial deformities (**c**left palate) • **H**ypocalcemia/**H**ypoparathyroidism

- CATCH-22.

Kallmann syndrome

- Kallmann syndrome is an X-linked recessive disorder of migration of fetal gonadotropin-releasing hormone (GnRH) and olfactory neurons, resulting in hypogonadotropic hypogonadism and rhinencephalon hypoplasia.
- Patients with Kallmann syndrome present with delayed/absent puberty and anosmia. The karyotype will be consistent with their male or female phenotype.
- Affected boys and girls have normal genotype and internal reproductive organs. However, the congenital absence of GnRH secretion results in short stature and delayed or absent puberty.
- Girls may have primary amenorrhea and absent breast development. Adolescent boys have a eunuchoid appearance with small external genitalia and absent secondary sexual characteristics (pubic/axillary hair, voice deepening, libido).
- The most distinguishing clinical feature from other causes of hypogonadism is anosmia/hyposmia (decreased sense of smell).
- Typical laboratory findings include low follicle-stimulating hormone and luteinizing hormone levels.
- Early diagnosis is important as hormonal treatment can help facilitate development of secondary sex characteristics, build and maintain bone and muscle mass, and improve fertility.

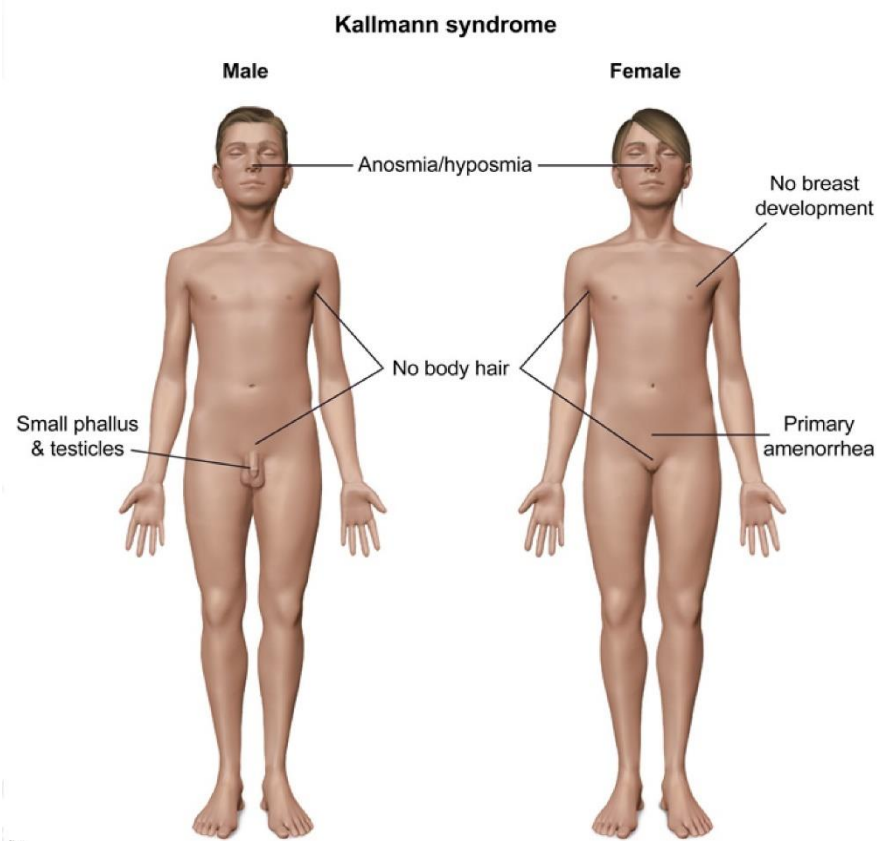

Beckwith-Wiedemann syndrome (BWS)

- Beckwith-Wiedemann syndrome (BWS) is an overgrowth disorder characterized by a predisposition to neoplasms.
- Most patients have a sporadic or inherited alteration of chromosome 11 p15 → deregulation of imprinted gene expression which includes genes that encode insulin-like growth factor 2 (a growth-promoting hormone similar to insulin).
- At birth, classic physical findings include macrosomia, macroglossia, hemihyperplasia and medial abdominal wall defects (umbilical hernia, omphalocele). Some infants also have visceromegaly.
- Newborns must be monitored closely for hypoglycemia. Fetal hyperinsulinemia can result in profound hypoglycemia at birth (similar to infants of diabetic mothers). This problem is usually transient, and older asymptomatic patients usually do not require ongoing glucose monitoring.
- Patients with BWS are at significantly increased risk of Wilms tumor and hepatoblastoma.
- Screening abdominal ultrasound and α-fetoprotein levels should occur every 3 months from birth to age 4 years, abdominal ultrasound every 3 months from age 4-8 years, and then renal ultrasound from age 8 years through adolescence.

Beckwith-Wiedemann syndrome	
Pathogenesis	• Deregulation of imprinted gene expression in chromosome 11p15
Physical examination	• Fetal macrosomia, rapid growth until late childhood • Omphalocele or umbilical hernia • Macroglossia • Hemihyperplasia
Complications	• Wilms tumor • Hepatoblastoma
Surveillance	• Serum α-fetoprotein • Abdominal/renal ultrasound

Marfan syndrome

- Marfan syndrome is an autosomal dominant disorder of the fibrillin-1 gene that results in systemic weakening of connective tissue affecting skeleton, heart, and eyes.
- Classic skeletal manifestations include joint hypermobility, skin hyperelasticity, long fingers (arachnodactyly ["thumb sign"]), pectus excavatum, and scoliosis/kyphosis.
- Lens dislocation typically upward and temporally (vs downward and medially in homocystinuria).
- The cardiovascular lesions are the most potentially life-threatening. The two most common cardiac abnormalities are mitral valve prolapse and cystic medial degeneration of the aorta.
- Cystic medial aortic degeneration (Myxomatous changes in the media of large arteries) may lead to aortic dilatation and dissection. Aortic dissection is the cause of death in 30% to 45% of patients with Marfan syndrome, followed by cardiac failure (which may be secondary to mitral and/or aortic regurgitation).
- The syndrome requires close monitoring with echocardiography for the development of aneurysms and aortic arch dissection.

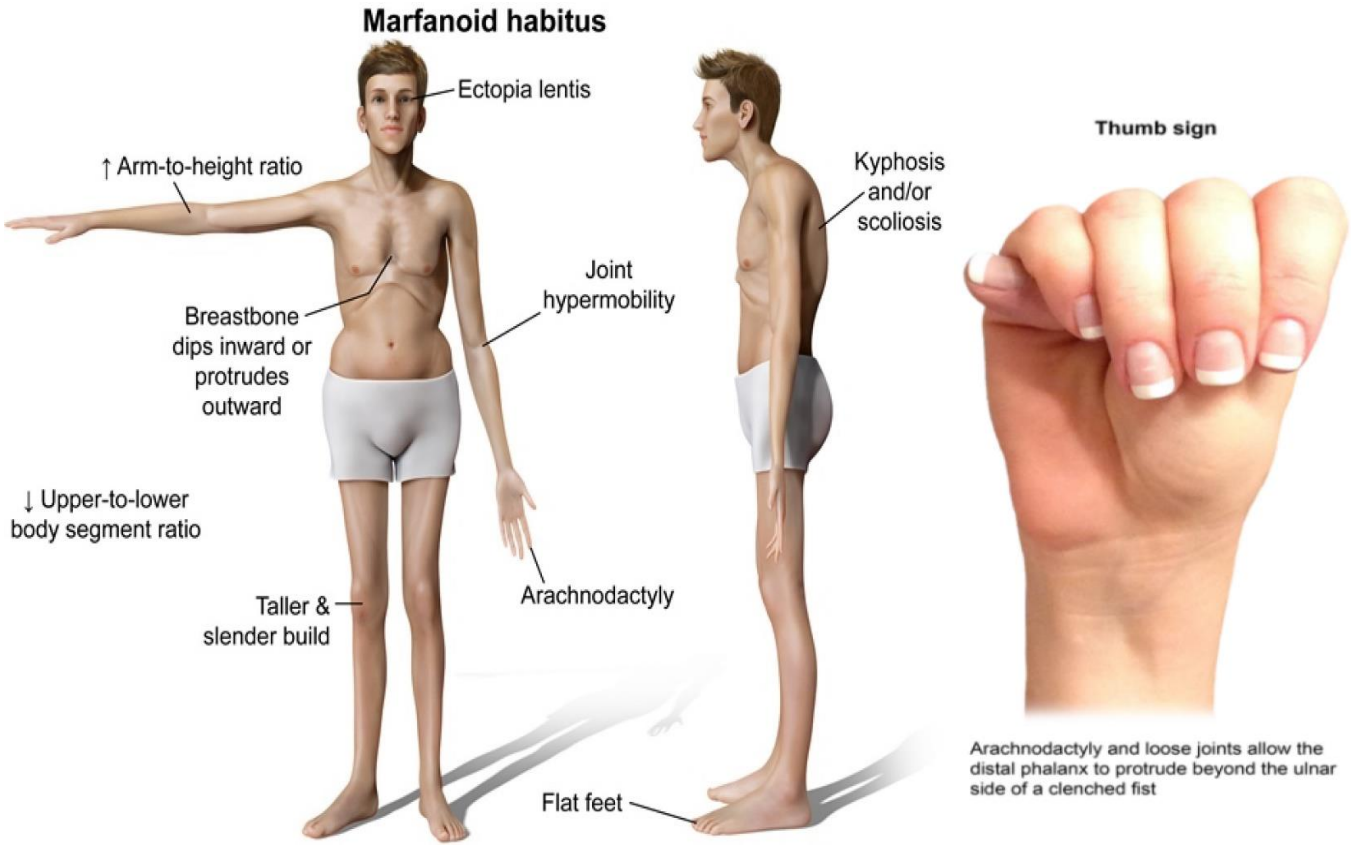

Fetal hydantoin syndrome

- Fetal hydantoin syndrome occurs due to in utero exposure to an antiepileptic (phenytoin, carbamazepine, valproate).
- Multiple antiepileptics have teratogenic effects due to their ability to cross the placenta, resulting in low folate levels and high oxidative metabolites levels in the fetus.
- The likely combined effects result in the associated cleft lip and palate, wide anterior fontanelle, distal phalange hypoplasia, and cardiac anomalies (pulmonary stenosis, aortic stenosis).
- The associated neural tube defects and microcephaly can also result in developmental delay and poor cognitive outcomes.
- Therefore, to minimize the risk of congenital malformation, patients who require antiepileptics during pregnancy should be titrated to the lowest dose for seizure control prior to conception and started on
- high-dose (4 mg) folic acid supplementation.

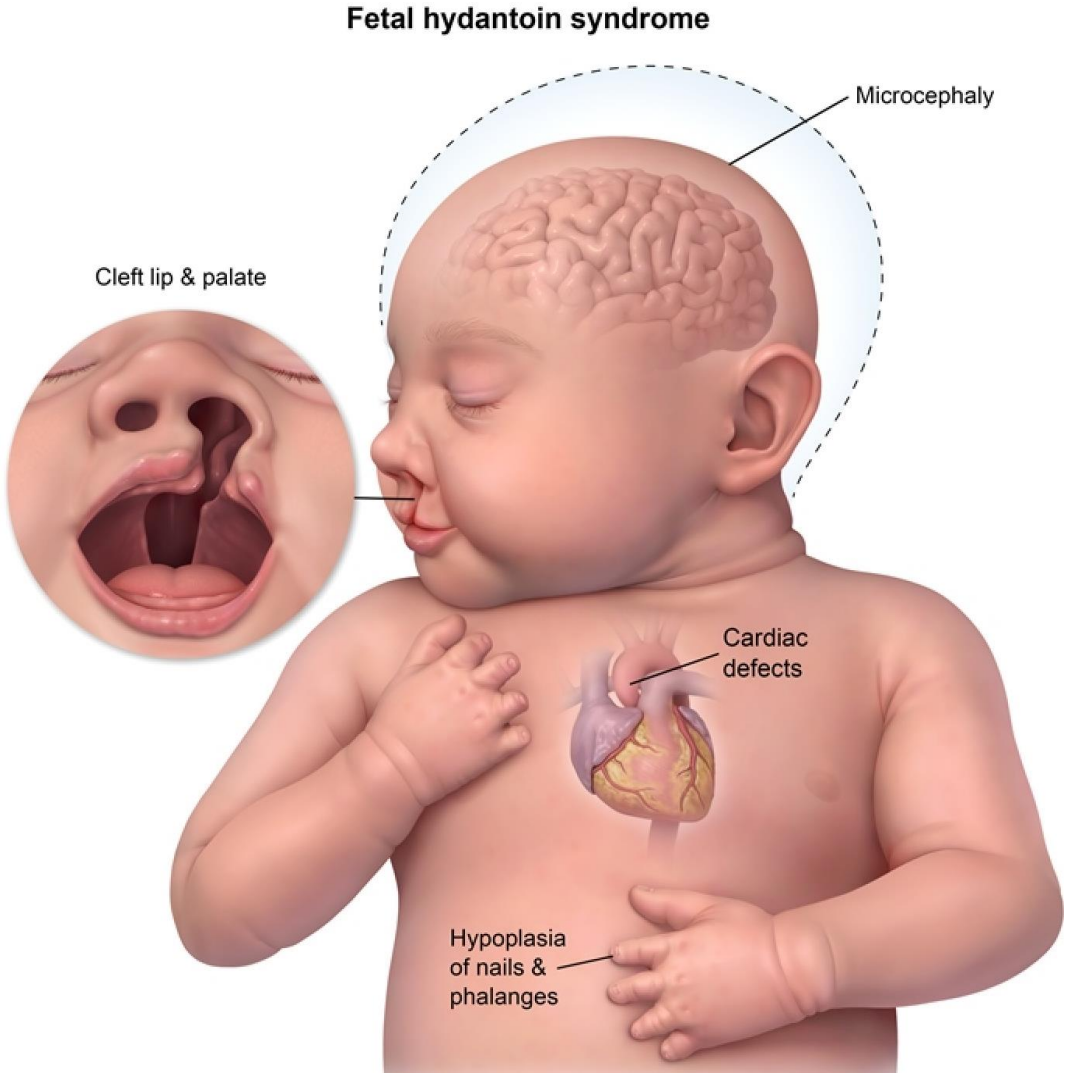

Fetal alcohol syndrome (FAS)

- Fetal alcohol syndrome (FAS) is one of the leading preventable causes of birth and neurodevelopmental problems.

- Although in utero alcohol exposure may result in no apparent sequelae for some fetuses, others may suffer from FAS or be stillborn. Women who are pregnant or trying to conceive should be advised to abstain completely from alcohol as there is no known safe amount of prenatal alcohol consumption.

- FAS is characterized by 3 pathognomonic facial dysmorphisms:
- Small palpebral fissures.
- Smooth philtrum (vertical groove above the upper lip).
- Thin vermilion border.

- Microcephaly is often present, and these children suffer from cognitive and behavioral disorders. The phenotypic range of neurodevelopmental problems is wide and includes intellectual disability, attention-deficit hyperactivity disorder, social withdrawal, and delays in motor and language milestones.

- Early diagnosis is critical for affected children to benefit from aggressive speech, physical, and
- occupational therapies.

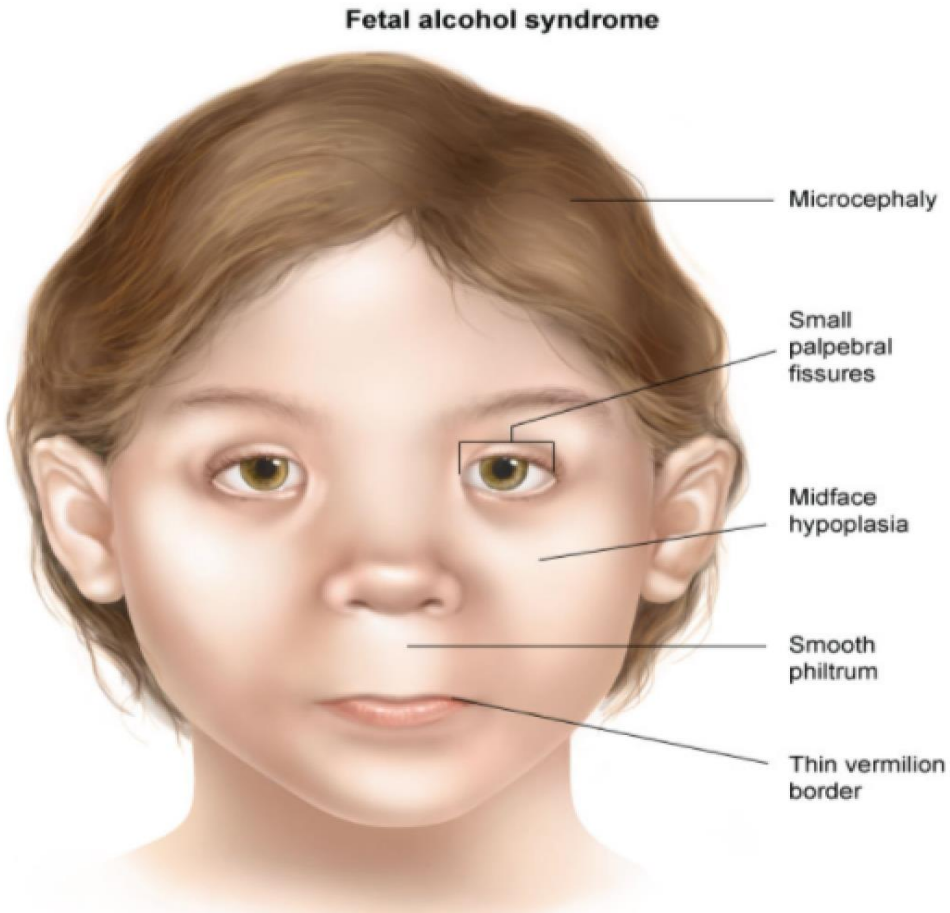

Common causes of intellectual disability	
Syndrome	**Key physical findings**
Fetal alcohol syndrome	Face • Smooth philtrum • Thin vermillion border • Small palpebral fissures • Microcephaly
Down syndrome	Face • Flat facial profile • Slanted palpebral fissures • Small low-set ears Body • Excessive skin at nape of the neck • Single transverse palmar crease • Clinodactyly • Large space between the first 2 toes
Fragile X syndrome	Face • Long narrow face • Prominent forehead & chin • Large ears • Macrocephaly Body • Macroorchidism

CHAPTER 10

Inborn errors of metabolism

Inborn errors of metabolism

Glycogen storage diseases

- At least 15 types have been identified, all resulting in abnormal glycogen metabolism and an accumulation of glycogen within cells.
- Periodic acid–Schiff stain identifies glycogen and is useful in identifying these diseases.
- Types I, II, III, and V are autosomal recessive.

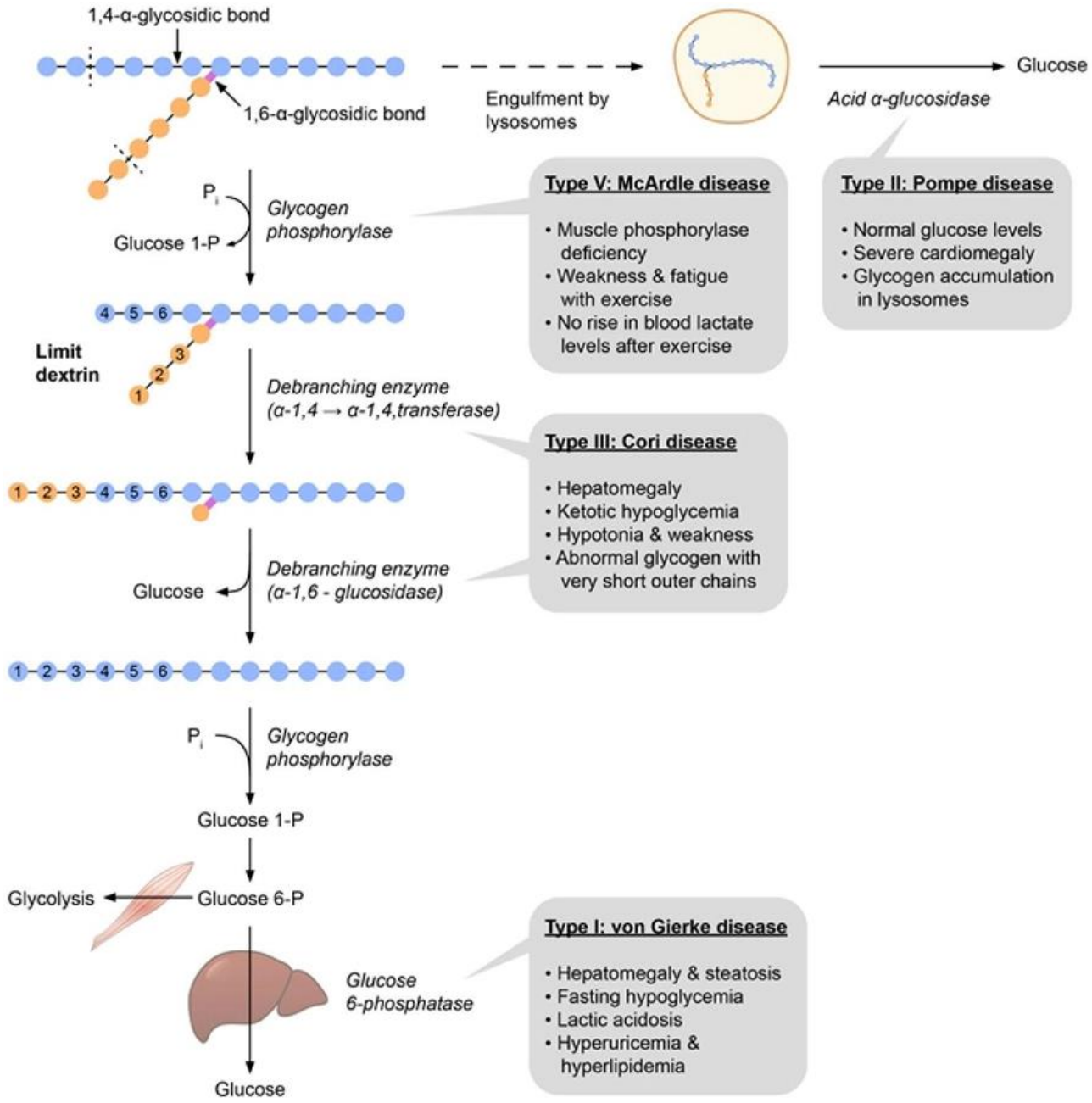

1. Von Gierke disease (type I):

- Deficient enzyme:

- Glucose-6-phosphatase.

- Findings:

- Deficiency of hepatic glucose-6-phosphatase produces a profound fasting hypoglycemia, lactic acidosis, and hepatomegaly.

- Liver does not regulate blood glucose (Impaired gluconeogenesis and glycogenolysis).

- ↑ blood lactate.

- ↑↑ Glycogen in liver and kidneys (hepatomegaly and renomegally): Glycogen deposits in the liver (glucose 6-P stimulates glycogen synthesis, and glycogenolysis is inhibited).

- Hyperuricemia predisposing to gout. Decreased Pi causes increased AMP, which is degraded to uric acid. Lactate slows uric acid excretion in the kidney.

- Hyperlipidemia with skin xanthomas.

- Fatty liver.

- Treatment:

- Frequent oral glucose/cornstarch; avoidance of galactose and fructose.

- In a person with glucose-6-phosphatase deficiency, ingestion of galactose or fructose causes no increase in blood glucose, nor does administration of glucagon or epinephrine.

2. Pompe disease (type II):

- Deficient enzyme:

- Deficiency of lysosomal enzyme alpha 1,4-glucosidase (acid maltase), an enzyme responsible for breaking down glycogen within the acidic environment of lysosomes.

- Although most glycogen is degraded in the cytoplasm, a small amount is inadvertently engulfed by lysosomes, especially in cells containing high amounts of glycogen such as hepatocytes and myocytes.

- As such, deficiency of acid maltase results in pathologic accumulation of glycogen within liver and muscle lysosomes. Cardiac and skeletal muscle are particularly susceptible, as the ballooning lysosomes interfere with contractile function.

- Pompe disease is different from the other diseases described here because the enzyme missing is not one in the normal process of glycogenolysis.

- Findings:
- The classic form of the disease presents in early infancy with marked cardiomegaly, severe generalized hypotonia, exercise intolerance, macroglossia, and hepatomegaly.
- With infantile onset, massive cardiomegaly is usually the cause of death, typically age <2.
- Blood glucose levels are normal, unlike with glycogen storage diseases that primarily affect the liver (von Gierke).
- A key distinguishing feature is that muscle biopsy will show accumulation of glycogen in lysosomes.
- PomPe trashes the PumP (1st and 4th letter; heart, liver, and muscle)

3. Cori disease (type III):

- Deficient enzyme:
- Debranching enzyme (α-1,6-glucosidase).

- Findings:
- Milder form of von Gierke (type I) with normal blood lactate levels.
- Gluconeogenesis is intact.
- Patients with this illness present with the non-specific findings of hypoglycemia, hypertriglyceridemia, and hepatomegaly.
- These manifestations are also common with other glycogen storage diseases; however, debranching enzyme deficiency can be differentiated from other glycogen storage diseases by demonstrating the accumulation of abnormally short outer dextrin-like structures in the cytosol of hepatocytes with an absence of histopathological fatty infiltration of the liver (Debranching enzyme deficiency leads to incomplete glycogen degradation).
- Alpha-1,6- glucosidic branch points cannot be degraded, so small chain dextrin-like material accumulates within the cytosol of hepatocytes).

4. McArdle disease (type V):

- Deficient enzyme:
- Skeletal muscle glycogen phosphorylase (Myophosphorylase).
- McArdle = Muscle.

- Findings:
- Deficiency of this enzyme leads to decreased breakdown of glycogen during exercise → ↑ glycogen in muscle → poor exercise tolerance, painful Muscle cramps, Myoglobinuria (red urine) with strenuous exercise, and arrhythmia from electrolyte abnormalities.
- Without an adequate supply of glucose, sufficient energy via glycolysis for carrying out muscle contraction cannot be obtained, explaining why the muscles are not functioning well (weakness and cramps).
- The prognosis is generally good and symptoms can be improved by consuming simple sugars before beginning physical activity.
- Blood glucose levels typically unaffected.

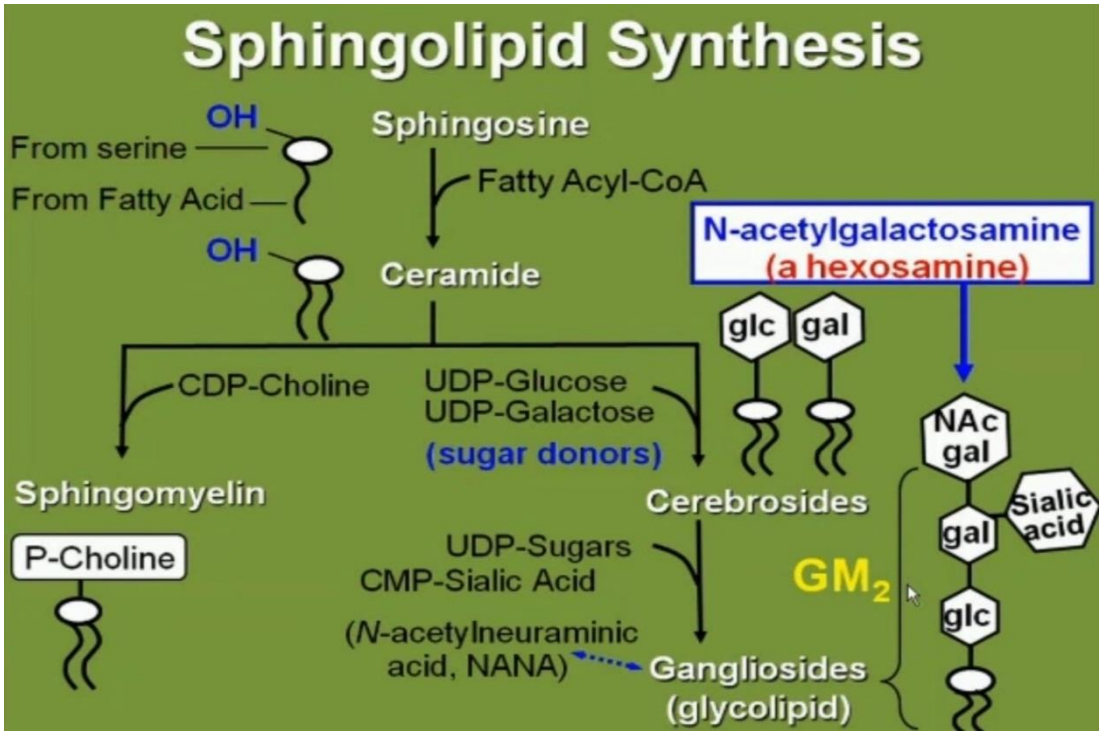

Sphingolipids

- Sphingolipids are important constituents of cell membranes. They have a hydrophilic region and 2 fatty acid-derived hydrophobic tails.

- The various classes of sphingolipids differ primarily in the nature of the hydrophilic region.
- Sphingolipids released when membrane is degraded are digested in endosomes after fusion with lysosomes. Lysosomes contain many enzymes, each of which removes specific groups from individual sphingolipids. Genetic deficiencies of many of these enzymes are known, and the diseases share some of the characteristics of I-cell disease.

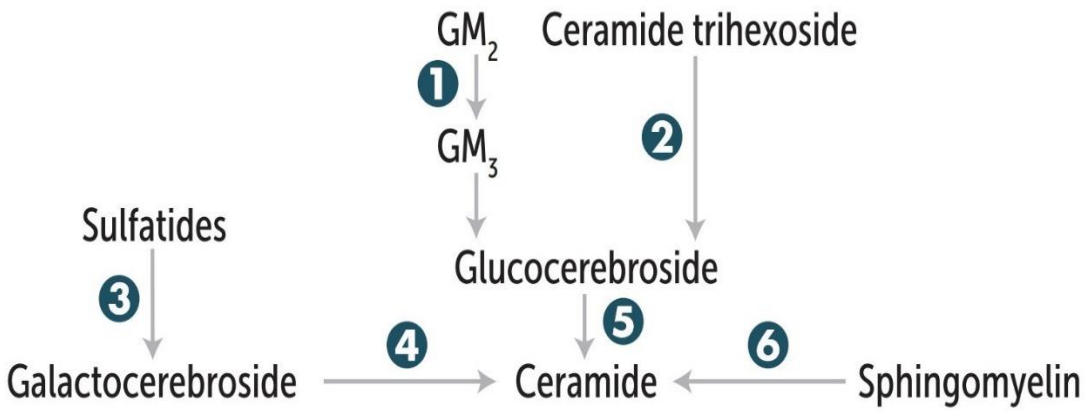

Lysosomal storage diseases

- Each is caused by a deficiency in one of the many lysosomal enzymes.
- Results in an accumulation of abnormal metabolic products.
- ↑ incidence of Tay-Sachs, Niemann-Pick, and some forms of Gaucher disease in Ashkenazi Jews due to loss of genetic variability within a group that historically conceived within their own community.

Sphingolipidoses

A. Tay-Sachs disease:

- Inheritance:

- AR.
- It is commonly seen in the Ashkenazi Jewish population.

- Deficient enzyme:

- HeXosaminidase A ("TAy-SaX").

- Accumulated substrate:

- Accumulation of the cell membrane glycolipid GM2 ganglioside within cell lysosomes.

- Findings:

- A Progressive neurodegeneration, developmental delay, "cherry-red" spot on macula, no hepatosplenomegaly (vs Niemann-Pick).
- The center of the fovea (blue arrow) appears bright red (cherry-red macula spot) as it is surrounded by white macula appearing as a halo. The halo results from a loss of retinal transparency due to ganglioside buildup in ganglion cells. The center of the fovea lacks ganglion cells, so the underlying choroid transmits its red color.
- Infants also develop macrocephaly due to accumulation of glycolipid material in the brain.
- Patients eventually develop seizures, blindness, and spasticity.
- Life expectancy is 2-5 years.

B. Niemann-Pick disease:

- Inheritance: AR.
- Deficient enzyme: Sphingomyelinase.
- Accumulated substrate: Sphingomyelin.
- Findings:

- Progressive neurodegeneration (Progressive sphingomyelin accumulation in the central nervous system).
- Following a period of normal development, infants fail to attain new skills and lose previously acquired milestones (sitting with support, head control, social smile).
- Sphingomyelin accumulate in the liver and spleen causing massive hepatosplenomegaly.
- Sphingomyelin deposition in the retina causes blindness as well. A cherry-red macular spot, similar to that seen in Tay-Sachs disease, is also often found.
- Death usually occurs before age three.
- No man picks (Niemann-Pick) his nose with his sphinger (sphingomyelinase).



C. Gaucher disease:

- Inheritance: AR. Gaucher disease is the most common lysosomal storage disease.
- Deficient enzyme: Glucocerebrosidase.
- Accumulated substrate: Glucocerebroside (β-glucosidase); treat with recombinant glucocerebrosidase.
- Findings:

- Hepatosplenomegaly, pancytopenia, osteoporosis, avascular necrosis of femur, bone crises.

D. Fabry disease (angiokeratoma corporis diffusum):

- Inheritance: XR.
- Deficient enzyme: α-galactosidase A.
- Accumulated substrate: the globoside ceramide trihexoside accumulates in tissues.
- Findings:

- Ceramide trihexoside accumulation in vascular smooth muscle cells, glomerular/distal tubule cells, cardiac myocytes, and dorsal root and autonomic ganglia accounts for the adverse manifestations of Fabry disease.
- Early: Triad of episodic acroparesthesia (debilitating, burning neuropathic pain in the extremities), angiokeratomas (punctuate, dark red, non-blanching macules and papules that classically occur between the umbilicus and the knees), hypohidrosis.
- Late: progressive renal failure, cardiovascular disease. Without enzyme replacement therapy, progressive renal insufficiency leading to renal failure and death may occur.

E. Krabbe disease:

- Inheritance: AR.
- Deficient enzyme: Galactocerebrosidase.
- Accumulated substrate: Galactocerebroside.
- Findings:

- Peripheral neuropathy, destruction of oligodendrocytes, developmental delay, spasticity, optic atrophy.

Cherry Red Macula

NO Hepatosplenomegaly

Tay Sachs

- Neurodegeneration, developmental delay
- ONION SKINNING

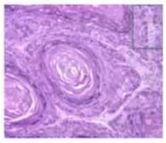

- Absent Hexosaminidase → accumulation of Ganglioside GM2

Hepatosplenomegaly
"palpable abdominal mass"

Niemann Pick

- Neurodegeneration
- FOAM cells

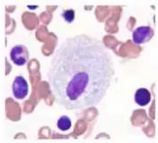

- "**No** man **Picks** his nose with his **sphinger**" = Sphingomyelinase

Hepatosplenomegaly

- "Palpable abdominal mass" – They are talking about HSM!
- "Abdominal exam unremarkable" – look elsewhere!

Cherry Red Macula

Niemann-Pick

- Neurodegeneration
- FOAM cells

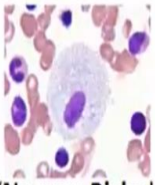

- "**No** man **Picks** his nose with his **sphinger**" = Sphingomyelinase

Gaucher

Most common

- TISSUE PAPER cells

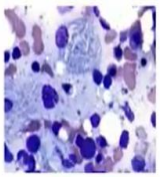

- Use tissues for mucus, **muco** rhymes with **Glucocerebrosidase**

Bone Issues:

- Osteoporosis
- Asepetic necrosis of femur
- Bone Crisis

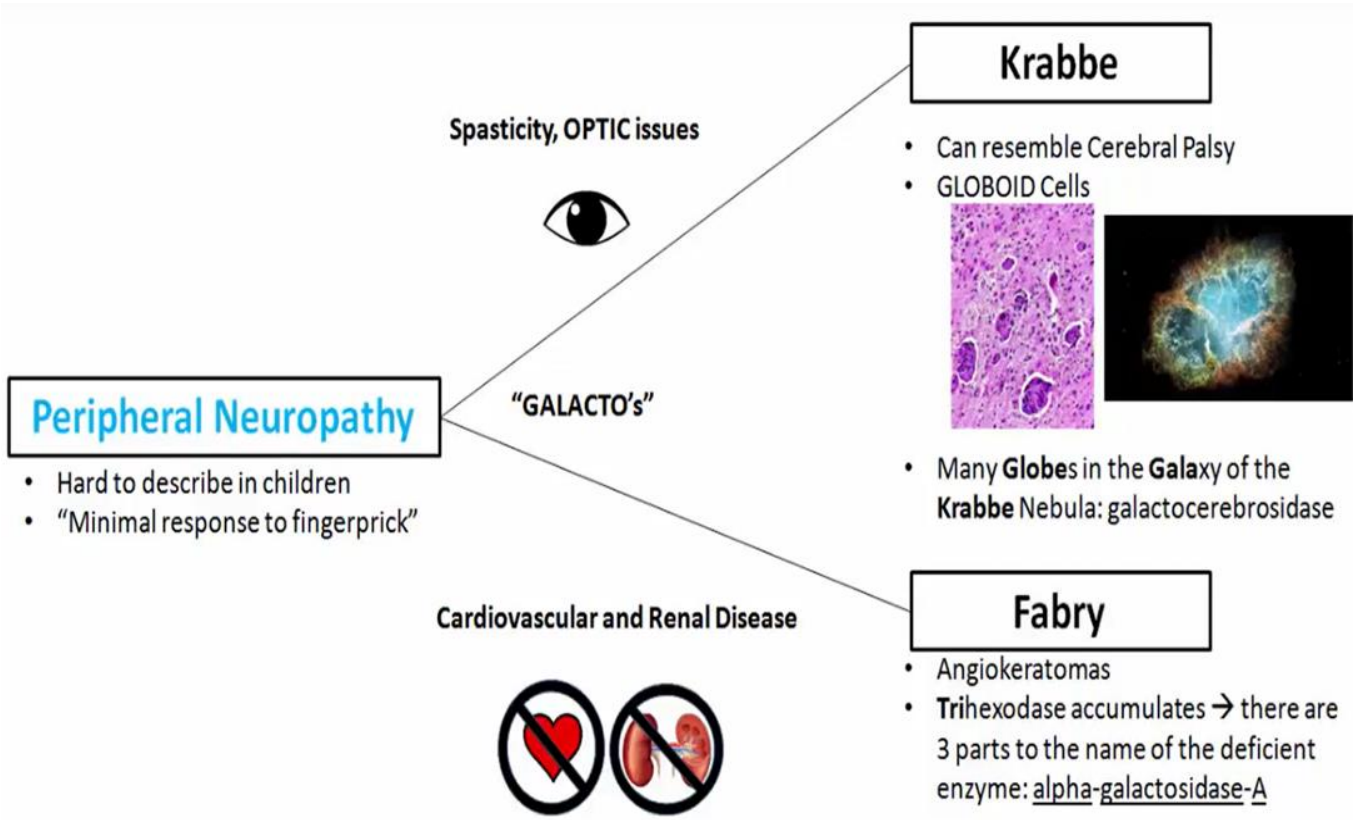
Krabbe
Spasticity, OPTIC issues
• Can resemble Cerebral Palsy
• GLOBOID Cells
Peripheral Neuropathy
• Hard to describe in children
• "Minimal response to fingerprick"
"GALACTO's"
• Many Globes in the Galaxy of the Krabbe Nebula: galactocerebrosidase
Cardiovascular and Renal Disease
Fabry
• Angiokeratomas
• Trihexodase accumulates → there are 3 parts to the name of the deficient enzyme: alpha-galactosidase-A

Classic Galactosemia

- Galactosemia is a metabolic disorder caused by galactose-1-phosphate uridyl transferase deficiency, thereby leading to elevated blood levels of galactose.
- Galactose 1-P accumulates in the brain, liver, kidney and other tissues.
- Symptoms develop when infant begins feeding (lactose present in breast milk and routine formula) and include failure to thrive, jaundice, hepatomegaly, and renal dysfunction (hyperchloremic metabolic acidosis, aminoaciduria), infantile cataracts, intellectual disability.
- Patients are also predisposed to Escherichia coli (gram-negative rod) sepsis.
- Early diagnosis and treatment by elimination of galactose from the diet are mandatory.
- <u>Treatment:</u>

- Exclude galactose and lactose (galactose + glucose) from diet.
- Initiation of soy-milk-based formula can result in regression of cataracts and improvement in renal and liver function.
- Soy-milk consists of sucrose, which is metabolized to glucose and fructose.

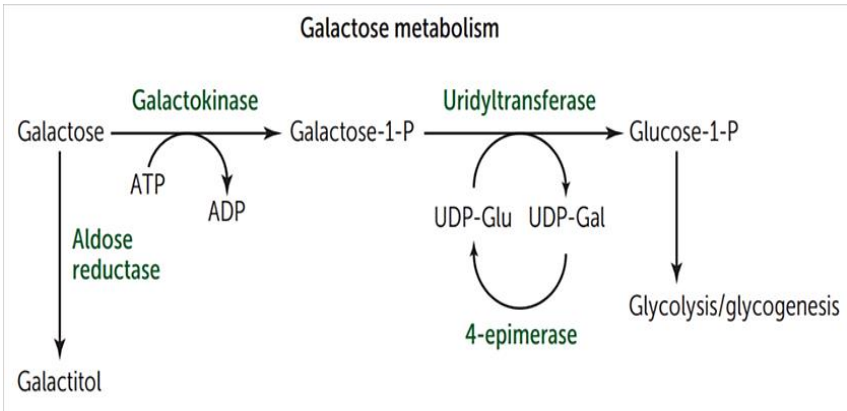

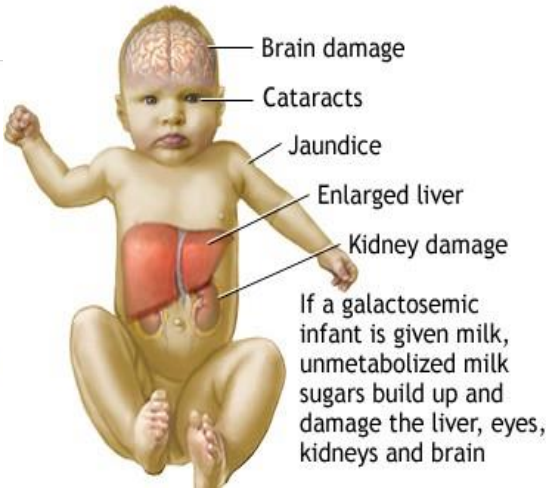

Phenylketonuria

- Due to ↓ phenylalanine hydroxylase or ↓ tetrahydrobiopterin (BH_4) cofactor (atypical or malignant phenylketonuria).
- PKU results from the inability to convert phenylalanine into tyrosine, a reaction which is normally catalyzed by phenylalanine hydroxylase. This enzyme requires the cofactor tetrahydrobiopterin (BH_4), which is regenerated from dihydrobiopterin (BH_2) by the enzyme dihydropteridine reductase.
- Although neonatal hyperphenylalaninemia can be caused by deficiency of either enzyme, most cases are attributable to abnormalities in phenylalanine hydroxylase.
- Tyrosine is a non-essential amino acid that becomes essential in the setting of phenylketonuria (PKU).
- ↑ phenylalanine → excess phenyl ketones in urine.

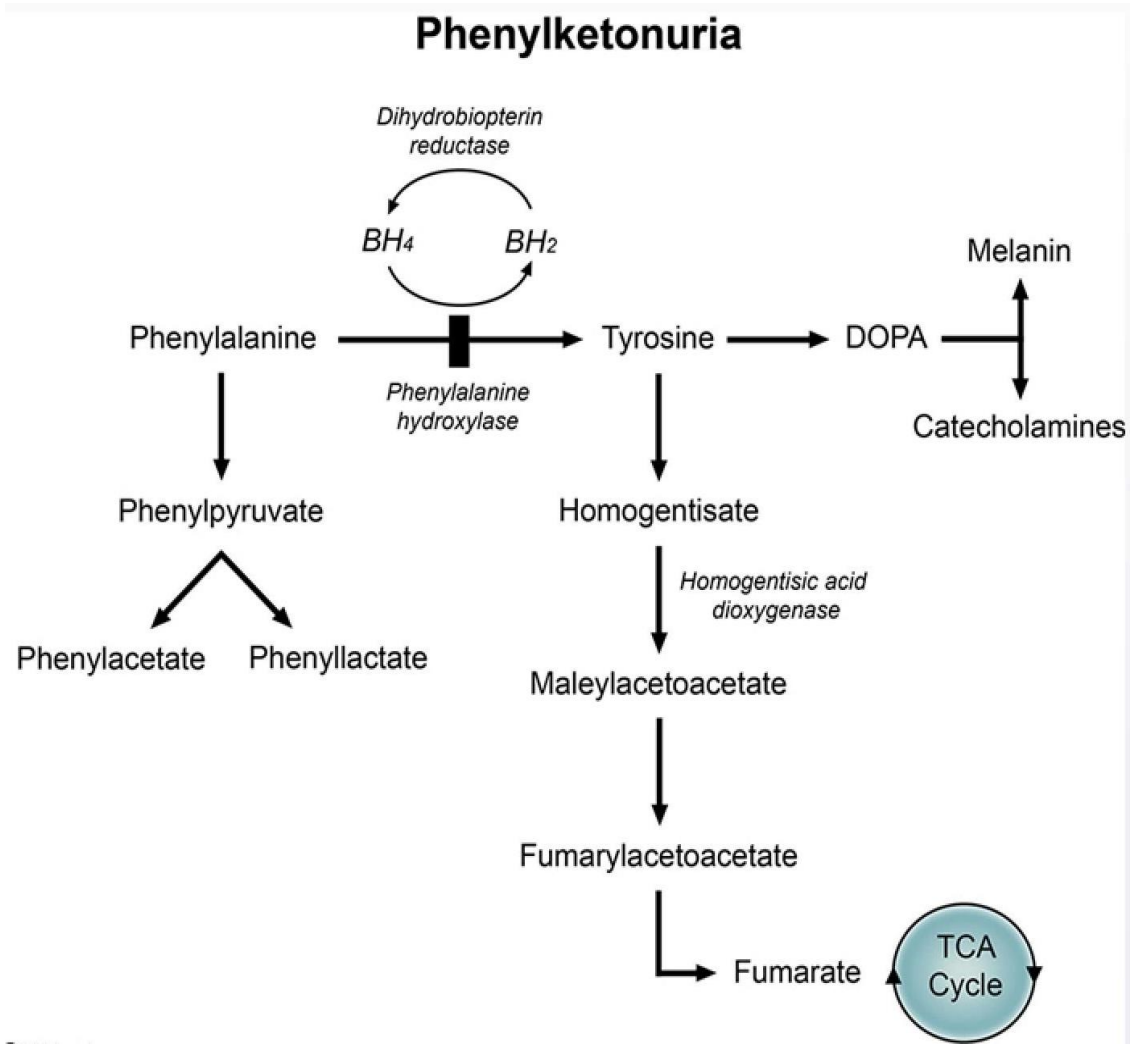

- Findings:

- Intellectual disability, growth retardation, seizures, blue eyes, fair complexion, eczema, musty body odor.

- It is believed that excess phenylalanine and the presence of large concentrations of phenylalanine metabolites (phenyllactate & phenylacetate) contribute to the brain damage seen in PKU.

- Hypopigmentation involving the skin, hair, eyes, and catecholaminergic brain nuclei (which produce a dark pigment known as neuromelanin) results from the inhibitory effect of excess phenylalanine on melanin synthesis (the excess phenylalanine present inhibits tyrosinase, the enzyme responsible for the synthesis of melanin from tyrosine).

- The classic musty or mousy body odor is due to the accumulation of abnormal phenylalanine metabolites.

- Treatment:

- ↓ phenylalanine and ↑ tyrosine in diet, tetrahydrobiopterin supplementation.

- PKU patients must avoid the artificial sweetener aspartame, which contains phenylalanine.

❖ N.B:

- Newborn screening is extremely important as early diagnosis and treatment can allow these patients to live relatively healthy lives with normal intellect.
- Most infants with PKU are asymptomatic initially; diagnosis is typically made from positive newborn screening tests.
- Tandem mass spectrometry of dried blood spots can detect the presence of metabolic products of phenylalanine. Mass spectrometry screening for PKU is mandated in all 50 states and is the most cost-effective screening test.
- If PKU is suspected later in life, quantitative amino acid analysis will show elevated phenylalanine levels.

Homocystinuria

- Types (all autosomal recessive):

- Cystathionine synthase deficiency (treatment: ↓ methionine, ↑ cysteine, ↑ B6, B12, and folate in diet). The most common cause of homocystinuria.

- ↓ affinity of cystathionine synthase for pyridoxal phosphate (treatment: ↑↑ B6 and ↑ cysteine in diet). Many patients respond dramatically to pyridoxine (B6) supplementation, which improves residual enzymatic activity and reduces plasma homocysteine levels.

- Methionine synthase (homocysteine methyltransferase) deficiency (treatment:↑ methionine in diet).

- All forms result in excess homocysteine.
- Cysteine becomes an essential amino acid in patients with homocystinuria, as the defective enzyme cystathionine synthetase produces the substrate used by cystathionase for the endogenous production of cysteine.

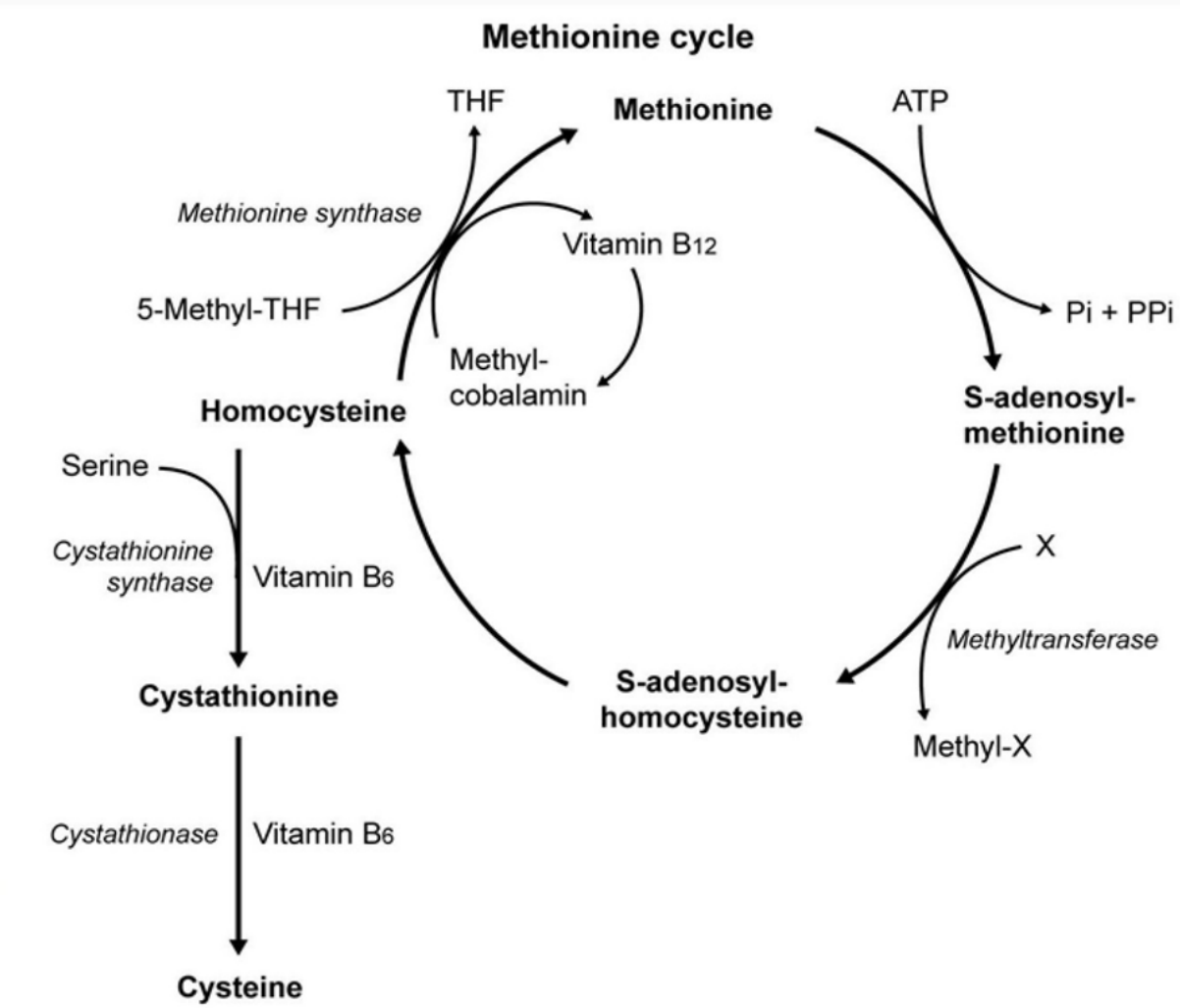

- HOMOCYstinuria:

- ↑↑ Homocysteine in urine, Osteoporosis, Marfanoid habitus, Ocular changes (downward and inward lens subluxation), Cardiovascular effects (thrombosis and atherosclerosis → stroke and MI), kYphosis, intellectual disability.

- Most patients present at age 3-10 with ectopia lentis (dislocated lens). About half of patients have intellectual disability.

- Other clinical manifestations include a Marfanoid habitus (elongated limbs, arachnodactyly, scoliosis).

- Patients are at high risk for thromboembolic occlusion of both large and small vessels due to pathologic changes in the vessel walls and increased adhesiveness of the platelets, especially those of the brain, heart, and kidneys. Thromboembolic complications are the major cause of morbidity and mortality in these patients.

- Antiplatelets or anticoagulation should be administered to prevent stroke, coronary heart disease, and venous thromboembolic disease.

- In homocystinuria, lens subluxes "down and in" (vs Marfan, "up and fans out").

Differential diagnosis of Marfanoid body habitus

Diagnosis	Overlapping features	Distinguishing features

Marfan syndrome	• Pectus deformity
	• Tall stature
	  ◦ ↑ Arm : height ratio
	  ◦ ↓ Upper : lower segment ratio
	• Arachnodactyly
	• Joint hyperlaxity
	• Skin hyperelasticity
	• Scoliosis
		• Autosomal dominant
		• Normal intellect
		• **Aortic root dilation**
		• Upward lens dislocation

Homocystinuria		• Autosomal recessive • **Intellectual disability** • **Thrombosis** • Downward lens dislocation • Megaloblastic anemia • Fair complexion

Lesch-Nyhan syndrome

- Defective purine salvage due to absent HGPRT, which converts hypoxanthine to IMP and guanine to GMP. X-linked recessive.

- Results in excess uric acid production and de novo purine synthesis.

- Findings:

- Intellectual disability, compulsive self-mutilation, aggression, hyperuricemia (orange "sand" [sodium urate crystals] in diaper), gout, dystonia.

- Cells in the basal ganglia of the brain (fine motor control) normally have very high HPRT activity. Patients also all have hyperuricemia because purines cannot be salvaged, causing gout.

- Treatment: allopurinol or febuxostat (2nd line).

- HGPRT:

- Hyperuricemia, Gout.
- Pissed off (aggression, self-mutilation).
- Retardation (intellectual disability).
- DysTonia.

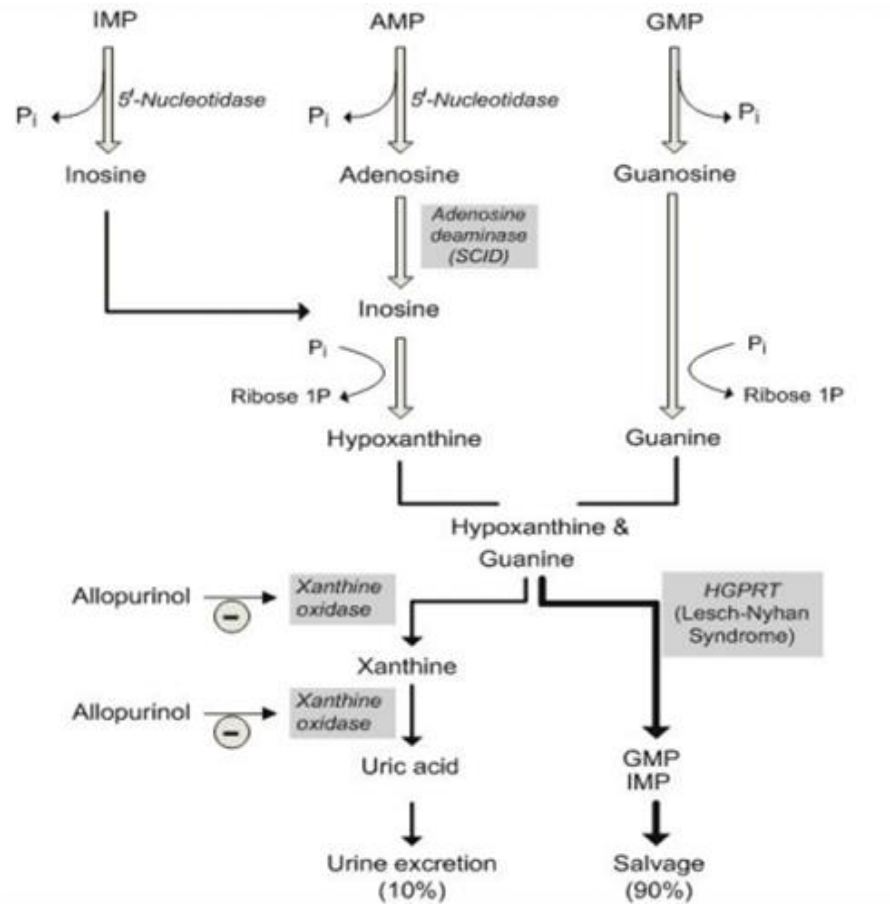

Vitamin Deficiency

- Lipid soluble vitamins (A, D, E, K) Absorption dependent on gut and pancreas. Toxicity more common than for water-soluble vitamins because fat-soluble vitamins accumulate in fat.

- Malabsorption syndromes with steatorrhea (cystic fibrosis and celiac disease) or mineral oil intake can cause fat-soluble vitamin deficiencies.

Water-soluble vitamins		
Vitamin	**Source**	**Deficiency**
B_1 (thiamine)	Whole grains, meat, fortified cereal, nuts, legumes	• Beriberi (peripheral neuropathy, heart failure) • Wernicke-Korsakoff syndrome
B_2 (riboflavin)	Dairy, eggs, meat, green vegetables	• Angular cheilosis, stomatitis, glossitis • Normocytic anemia • Seborrheic dermatitis
B_3 (niacin)	Meat, whole grains, legumes	• Pellagra (dermatitis, diarrhea, delusions/dementia, glossitis)
B_6 (pyridoxine)	Meat, whole grains, legumes, nuts	• Cheilosis, stomatitis, glossitis, • Irritability, confusion, depression
B_9 (folate, folic acid)	Green leafy vegetables, fruit, meat, fortified cereal/grains	• Megaloblastic anemia • Neural tube defects (fetus)
B_{12} (cobalamin)	Meat, dairy	• Megaloblastic anemia • Neurologic deficits (confusion, paresthesias, ataxia)
C (ascorbic acid)	Citrus fruits, strawberries, tomatoes, potatoes, broccoli	• Scurvy (punctate hemorrhage, gingivitis, corkscrew hair)

Vitamin B_2 (riboflavin) deficiency

- Vitamin B2 (riboflavin) is a precursor to important coenzymes that participate in oxidation-reduction reactions for energy production.

- Riboflavin deficiency is characterized by angular cheilitis (fissures at comers of lips), glossitis (hyperemic tongue), stomatitis (hyperemic/edematous oropharyngeal mucous membranes, sore throat), and seborrheic dermatitis.

Vitamin B3

- Also called niacin.

- Niacin is either obtained through dietary consumption (grains, fruits, vegetables, meats) or is synthesized endogenously from tryptophan.

- Synthesis requires vitamins B2 and B6.

- Function:

- Constituent of NAD, NADP (used in redox reactions).

- Used to treat dyslipidemia; lowers levels of VLDL and raises levels of HDL.

- Deficiency:

- In developed countries, it Is primarily seen in patients with impaired nutritional intake (alcoholism, chronic illness). Pellagra can also be seen occasionally in those with carcinoid syndrome (due to depletion of tryptophan) or Hartnup disease (congenital disorder of tryptophan absorption). Prolonged isoniazid therapy can interfere with metabolism of tryptophan and occasionally lead to pellagra.

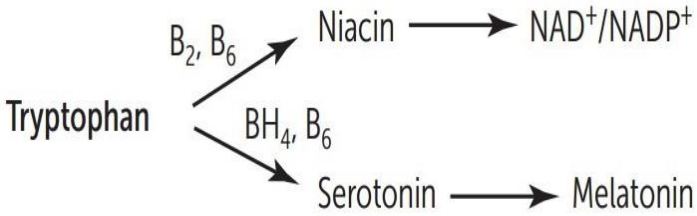

- Tryptopha , serotonin, and melatonin.

- Symptoms of pellagra:

- Pellagra (which means "rough skin" in Italian vernacular) is a clinical syndrome arising secondary to niacin deficiency that is characterized by the "three Ds": dermatitis, diarrhea, and dementia.

- The 3 D's of B3.
- The dermatitis is usually bilateral and symmetric on the sun-exposed areas of the body, consisting of roughened, thickened, and scaly skin.

- The diarrhea arises as a result of columnar epithelium atrophy (and occasionally ulceration) of the gastrointestinal tract.

- The dementia develops secondary to neuronal degeneration in the brain and spinal cord, with lesions similar in appearance to those associated with pernicious anemia.

▪ Excess:

- Facial flushing (induced by prostaglandin, not histamine; can avoid by taking aspirin with niacin), hyperglycemia, hyperuricemia.



CHAPTER 11

Growth and development

Growth and development

- A newborn typically loses up to 10% of birth weight (BW) in the first week of life due to elimination of large amount of extravascular fluid. Should regain or surpass BW by 2 weeks.
- A neonate should gain about 30 grams (1 oz) per day in the first month of life, which slows to about 20 grams/day at 3-4 months.
- An infant typically doubles BW by 6 months and triples by 1 year.
- Between age 6 and 12 years: 3-6 growth spurts each year for 8-week periods each; slower brain growth; myelination complete by age 7.
- Between age 10 and 20 years:

- Acceleration in early adolescence.
- Boys' highest growth stops at age 18. Their average peak is 13.5 years (2-3 years later than girls, and continues 2-3 years after girls have stopped).
- Girls' average peak is 11.5 years and it stops at age 16.

Assessment of Growth

- The growth chart is the best tool to determine patterns of growth, with separate charts for boys and girls.
- The charts measure weight for age, height for age, head circumference for age, weight for height, and body mass index (BMI).
- Each chart has multiple curves (either 5-95% or 3-97%).
- Weight/height <5th percentile is the single best growth curve indicator for acute malnutrition. In nutritional insufficiency, weight decreases before length, and weight/height is low. For causes of decreased linear growth, length decreases first or at the same time as weight (GH deficiency).
- BMI is accepted as best clinical indicator for measure of under- and overweight.
- Growth velocity (GV): yearly increments of growth; should follow a growth curve.

$$\text{slope} = \frac{\text{change in height}}{change\ in\ age}$$

- Chronologic age (CA): actual age.
- Bone age (BA): x-ray of left hand and wrist (non-dominant hand).

	Normal	Abnormal
Bone age = chronological age	Ideal Genetic (familial) **short stature**	• Genetic • Chromosomal
Bone age < chronological age	Constitutional delay	• Chronic systemic disease • Endocrine related
Bone age ≥ chronological age	Obesity (tall) Familial **tall stature**	• Precocious puberty • Congenital adrenal hyperplasia • Hyperthyroidism

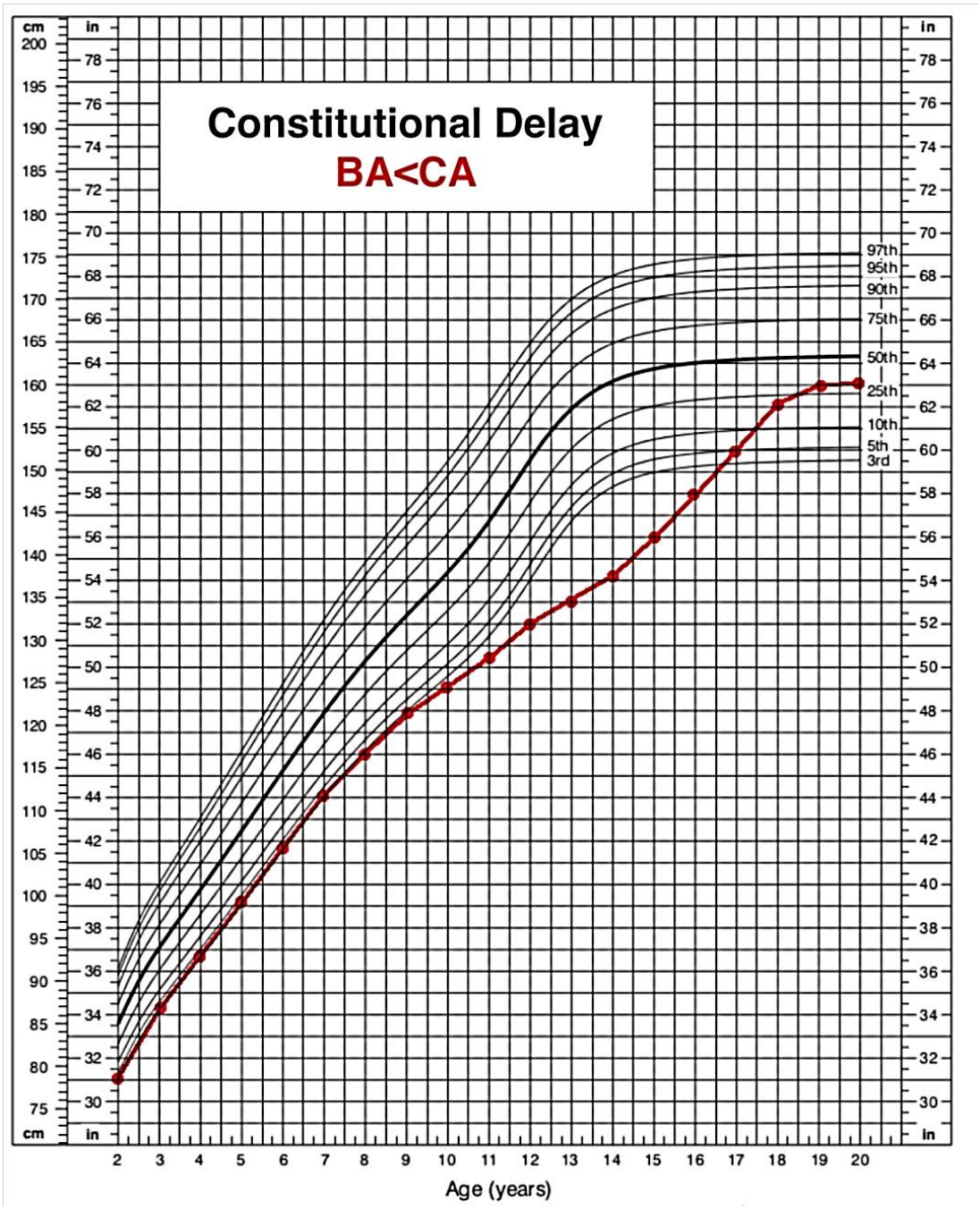

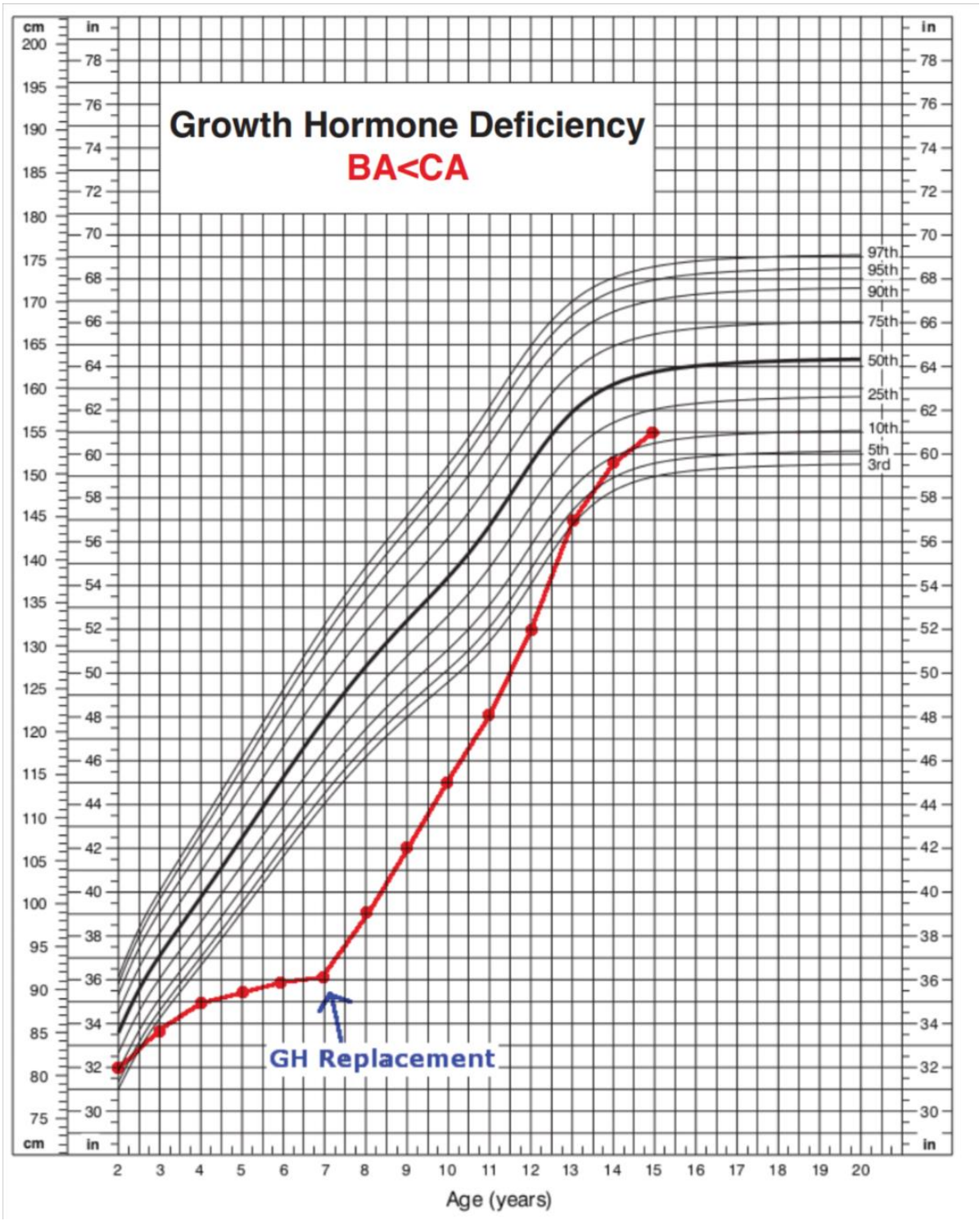

- Constitutional growth delay (late bloomers) is characterized by a delayed growth spurt, delayed puberty, and delayed bone age (Bone age radiographs show a bone age that is delayed compared to the chronological age), but eventually occur. The child will have a normal growth spurt and reach a normal adult height.

- Constitutional growth delay is the most common cause of short stature and pubertal delay in adolescents. The child regains a normal growth velocity and follows the growth curve at the 5th to 10th percentile.

Developmental Achievements

Reflexes

- Sucking reflex: Baby will automatically suck on a nipple-like object.
- Grasping reflex.
- Babinski reflex: toe extension.
- Rooting reflex: If you touch a baby's cheek, the baby will turn to that side.
- Moro reflex: Arms spread symmetrically when the baby is scared.
- Stepping reflex: walking-like maneuvers when toes touch the ground.
- By age 4 months, primitive reflexes (Moro, grasp) have either already disappeared, or are starting to disappear as the infant initiates purposeful movement of the extremities.
- The Babinski reflex is the only primitive reflex that may persist in healthy children up to age 2 years but can disappear as early as age 12 months.



Developmental milestones

- Assessment of developmental milestones is essential at every well-child examination.
- Developmental delays can be an ominous sign of a serious medical condition, such as a brain tumor or other neurologic problem.
- Prompt recognition is also important as early intervention with physical, occupational, and/or psychosocial therapies is critical in optimizing skill acquisition and overall long-term health.
- Evaluation for developmental delay includes assessment of motor, cognitive, social/emotional, and verbal milestones.



Developmental milestones during first year of life				
Age (months)	**Gross Motor**	**Fine Motor**	**Language**	**Social/cognitive**
2	• Lifts head/chest in prone position	• Hands unfisted 50% of the time • Tracks past midline	• Alerts to voice/sound • Coos	• Social smile • Recognizes parents
4	• Sits with trunk support • Begins rolling	• Hands mostly open • Reaches midline	• Laughs • Turns to voice	• Enjoys looking around
6	• Sits momentarily propped on hands (unsupported by 7 months)	• Transfers objects hand to hand • Raking grasp	• Responds to name • Babbles	• Stranger anxiety
9	• Pulls to stand • Cruises	• 3-finger pincer grasp • Holds bottle or cup	• Says "dada," "mama"	• Waves "bye" • Plays "pat-a-cake"
12	• Stands well • Walks first steps independently • Throws ball	• 2-finger pincer grasp	• Says first words other than "dada," "mama"	• Separation anxiety • Comes when called

Developmental milestones during toddlerhood				
Age	**Gross motor**	**Fine motor**	**Language**	**Social/Cognitive**
12 months	• Stands well • Walks first steps independently • Throws a ball	• 2-finger pincer grasp	• Says first words (other than "mama" & "dada")	• Separation anxiety • Follows 1-step commands with gestures
18 months	• Runs • Kicks a ball	• Builds a tower of 2-4 cubes • Removes clothing	• 10- to 25-word vocabulary • Identifies ≥1 body parts	• Understands "mine" • Begins pretend play
2 years	• Walks up/down stairs with both feet on each step • Jumps	• Builds a tower of 6 cubes • Copies a line	• Vocabulary ≥50 words • 2-word phrases	• Follows 2-step commands • Parallel play • Begins toilet training
3 years	• Walks up/down stairs with alternating feet • Rides tricycle	• Copies a circle • Uses utensils	• 3-word sentences • Speech 75% intelligible	• Knows age/gender • Imaginative play
4 years	• Balances & hops on 1 foot	• Copies a cross	• Identifies colors • Speech 100% intelligible	• Cooperative play
5 years	• Skips • Catches ball with 2 hands	• Copies a square • Ties shoelaces • Dresses/bathes independently • Prints letters	• Counts to 10 • 5-word sentences	• Has friends • Completes toilet training

❖ N.B:

1. Delayed verbal milestones should be assessed with an audiological evaluation.

- Hearing impairment in children can be due to a variety of causes, both hereditary and acquired.
- The most common cause is conductive hearing loss due to repeated ear infections.
- Undetected hearing impairment can lead to poor language development and social skills. Often, these children suffer from poor self-esteem and isolate themselves as a result.
- Undetected hearing impairment can easily be confused with certain pervasive and behavioral disorders of childhood. Therefore, hearing tests should be routinely conducted in all children with any behavioral concerns.

2. Having an imaginary friend is most common in children age 3-6 but can be seen throughout school-age years.

- Although parents may become concerned when children report imaginary friends or when these relationships persist, this stage of development is considered healthy and normal.
- It aids a child's creativity and helps the child to navigate social relationships as a form of rehearsal. There is no evidence that imaginary friends negatively impact real friendships.
- Other normal creative behaviors in this age group include pretend play, dress-up, and storytelling with fanciful details.

Sudden infant death syndrome (SIDS)

- Sudden infant death syndrome (SIDS) is the leading cause of mortality in infants age 1 month to 1 year in the United States.
- It is defined as a sudden, unexpected death that cannot be explained by history or postmortem examination (investigation of the scene, autopsy).
- Sleep position is an important modifiable risk factor for SIDS prevention. In 1992, the American Academy of Pediatrics recommended that infants be placed in a supine position while sleeping ("Back to Sleep" campaign) to reduce the risk of SIDS. This measure proved to be highly effective, resulting in a dramatic decline of SIDS in the United States.
- Other factors associated with a decreased rate of SIDS include limiting prenatal and postnatal smoke exposure, pacifier use during sleep, and room-sharing (without bed-sharing) with a caretaker.
- Bed-sharing with parents and siblings is generally discouraged, especially when parents smoke in bed or use a substance that may impair alertness (alcohol, illicit drugs).

Sudden infant death syndrome

	Risk factors	Prevention
Maternal factors	• Smoking during or after pregnancy • Maternal age <20 • Inconsistent prenatal care	• Smoke avoidance during & after pregnancy • Routine prenatal care
Infant factors	• Prone/side sleep position • Soft sleep surface, loose bedding • Bed-sharing • Prematurity • Sibling with SIDS	• Supine sleep position • Firm sleep surface • Room-sharing • Pacifier use

SIDS = sudden infant death syndrome.

CHAPTER 12

Pediatric infections

Pediatric infections

Pharyngitis

- Pharyngitis is irritation or inflammation of the back of the throat (or the pharynx).
- Although most pharyngeal infections are caused by viruses, the most important cause is group A beta-hemolytic streptococci (S. pyogenes). This is because of the possibility of the organism progressing on to rheumatic fever or glomerulonephritis.
- Viral pharyngitis is more common in children, particularly among those age <5.
- S. pyogenes only accounts for 15-20% of cases of pharyngitis.
- Obvious viral manifestations are conjunctivitis, rhinorrhea, cough, or oral ulcers.
- Sore throat with cervical adenopathy and inflammation of the pharynx with an exudative covering is highly suggestive of S. pyogenes.
- Diagnosis:
  - The diagnosis of bacterial pharyngitis in children should be confirmed prior to treatment to avoid unnecessary antibiotic prescription for viral pharyngitis.
  - Options include rapid streptococcal antigen testing (RSAT) or throat culture.
  - Although RSAT is quick, widely available, and highly specific, it has limited sensitivity (70%-90%). Therefore, although positive RSAT testing is sufficient for diagnosis, all negative RSAT results in children must be confirmed with follow-up throat culture. Throat culture is the gold standard due to its high sensitivity (90%-95%).
- Treatment: Penicillin remains the mainstay of therapy.

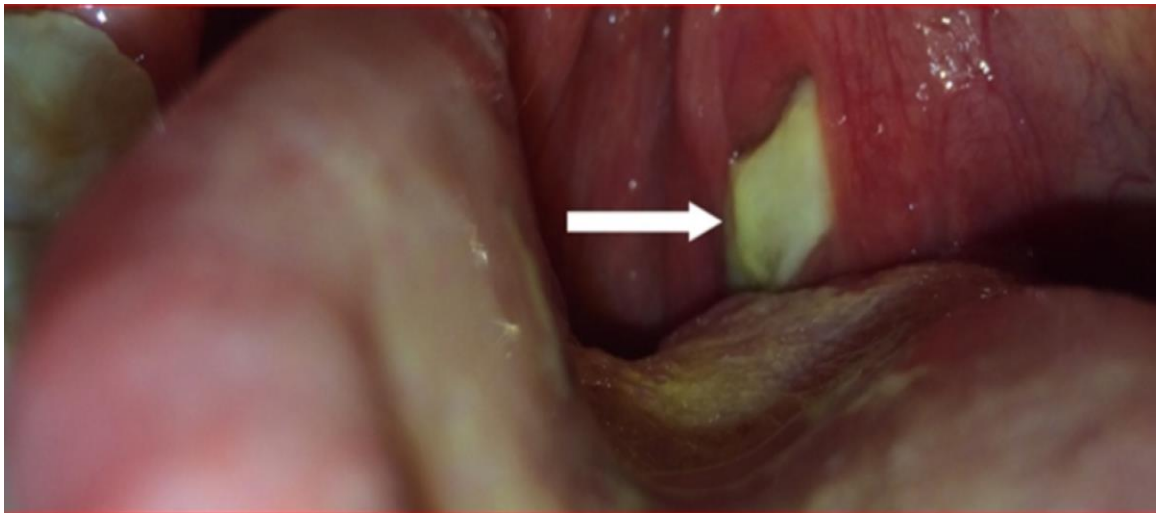

❖ N.B:

- The approach to pharyngitis in children is different from that in adults due to the high incidence of viral pharyngitis in children.

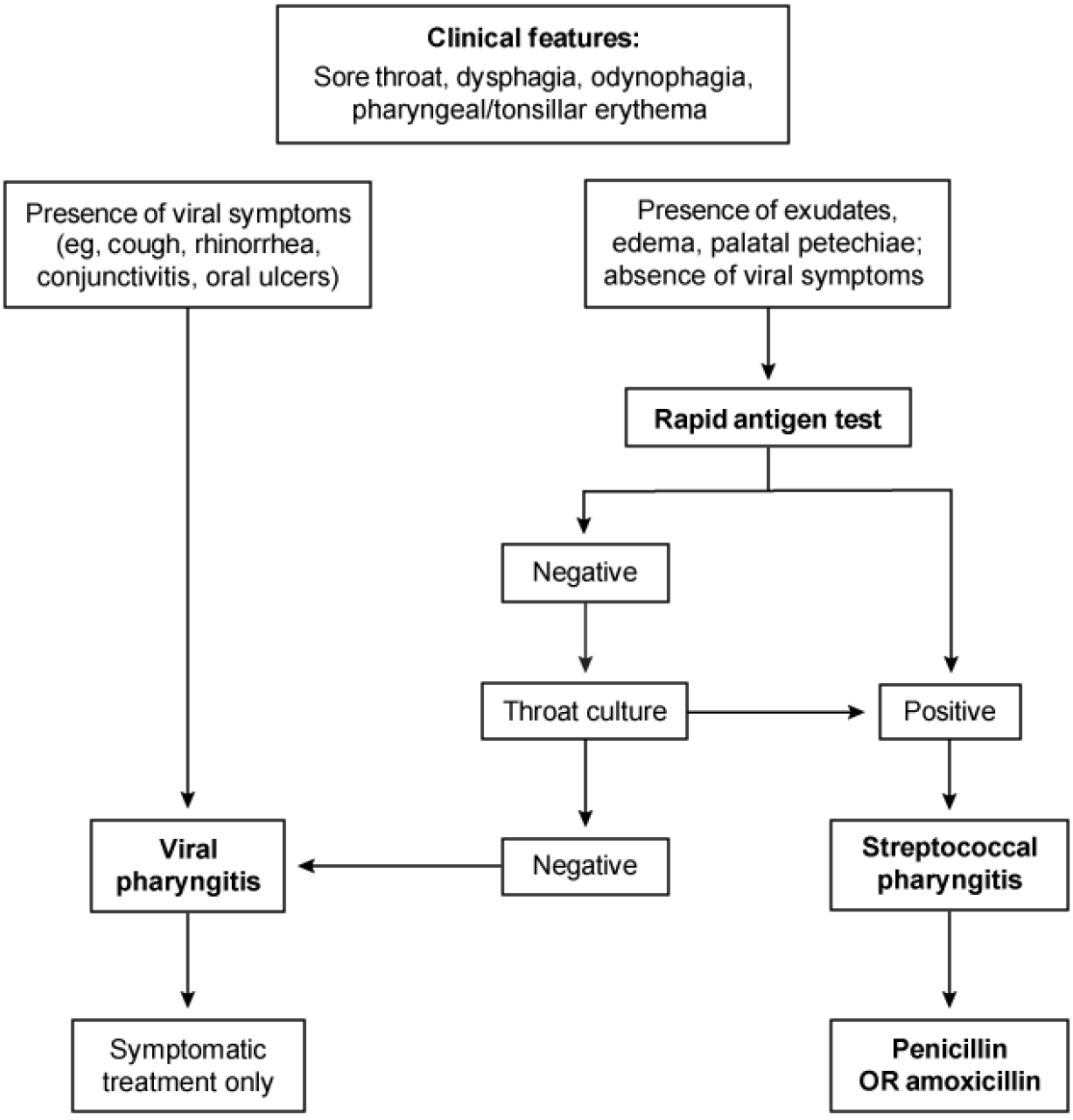

Scarlet fever

- Scarlet fever occurs when pharyngitis or any other type of streptococcal infection is caused by an erythrogenic toxin-producing S. pyogenes.
- It is most often associated with streptococcal pharyngitis, which begins acutely after an incubation period of 1-5 days.
- Initial symptoms include fever, malaise, abdominal pain, and sore throat.
- In addition, the tongue can have inflamed red papillae with an appearance similar to that of a red strawberry.
- After 1-2 days, a rash appears on the neck, armpits, and groin that subsequently generalizes to the rest of the body (palms and soles are usually spared).
- The rash begins as scarlet spots, as the rash progresses and becomes more widespread, it begins to resemble sunburn with goose pimples ("sandpaper-like" rash).
- The cheeks commonly appear flushed, giving the area around the mouth a pale appearance in comparison (circumoral pallor).
- Toward the end of the first week, desquamation begins and is most pronounced in the armpits, groin, and tips of the fingers and toes.
- As with any streptococcal upper respiratory infection, scarlet fever can predispose to acute rheumatic fever and glomerulonephritis.



Epiglottitis

- Epiglottitis is an uncommon but potentially fatal infection that presents with acute onset of fever with dysphagia, drooling, and respiratory distress.

- Signs of impending airway obstruction include restlessness, anxiety, worsening inspiratory stridor, and a muffled "hot potato" voice.

- Patients may hyperextend the neck and maintain a tripod position (upright/forward positioning with neck hyperextension) to maximize airway diameter when significant airway swelling is present.

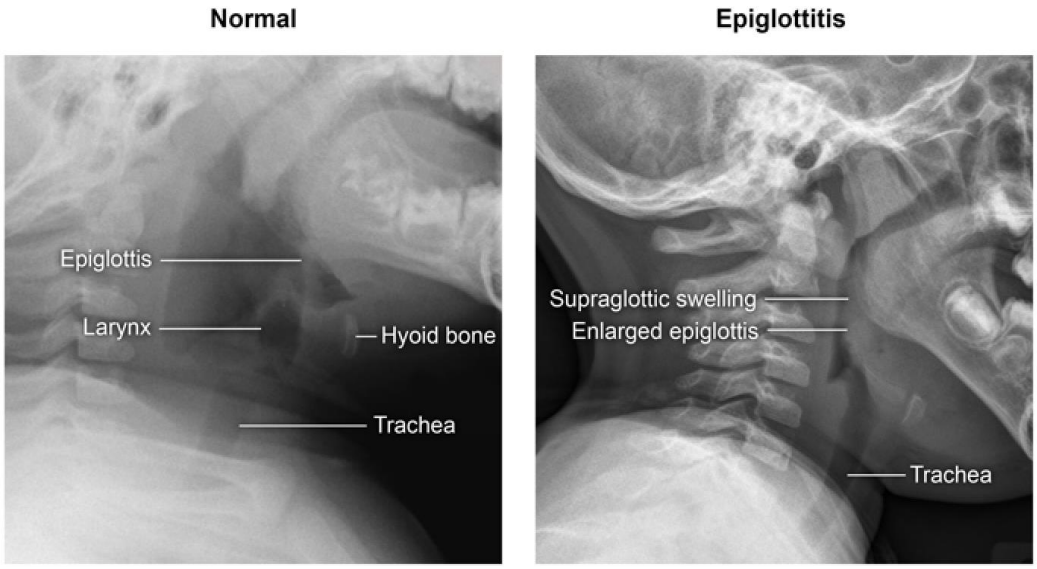

- Isolated pathogens are usually nasopharyngeal bacteria, most commonly Haemophilus influenzae type b (Hib). Due to widespread vaccination against Hib, the incidence of epiglottitis has diminished. However, the proportion of epiglottitis caused by other pathogens, such as other strains of H influenzae, Streptococcus species (S pneumoniae, S pyogenes), and Staphylococcus aureus, has increased.

- <u>Diagnosis and treatment:</u>

- X-ray is not required for diagnosis if clinical suspicion is high, but lateral view shows an enlarged epiglottis "thump sign", suggestive of edema. Diagnosis is confirmed via direct visualization of an edematous epiglottis. However, detailed oropharyngeal examination is often deferred in children due to risk of laryngospasm from provoked aggravation. Direct laryngoscopy during intubation (a controlled setting to secure the airway) is often preferred for diagnosis and management.

- The first step in management of epiglottitis is to secure the airway, usually via endotracheal intubation.

- Once the airway is secured, broad-spectrum antibiotic therapy with ceftriaxone (targeting H influenzae and Streptococcus species) and vancomycin (targeting S aureus, including methicillin-resistant strains) should be initiated promptly.

Epiglottitis	
Microbiology	• *Haemophilus influenzae* type b (Hib)
Clinical features	• Distress (tripod position, sniffing position, stridor) • Dysphagia, dysphonia • Drooling • High fever
X-ray	• "Thumb sign" (enlarged epiglottis)
Management	• Endotracheal intubation • Antibiotics
Prevention	• Immunization against Hib

Tripod position & epiglottitis

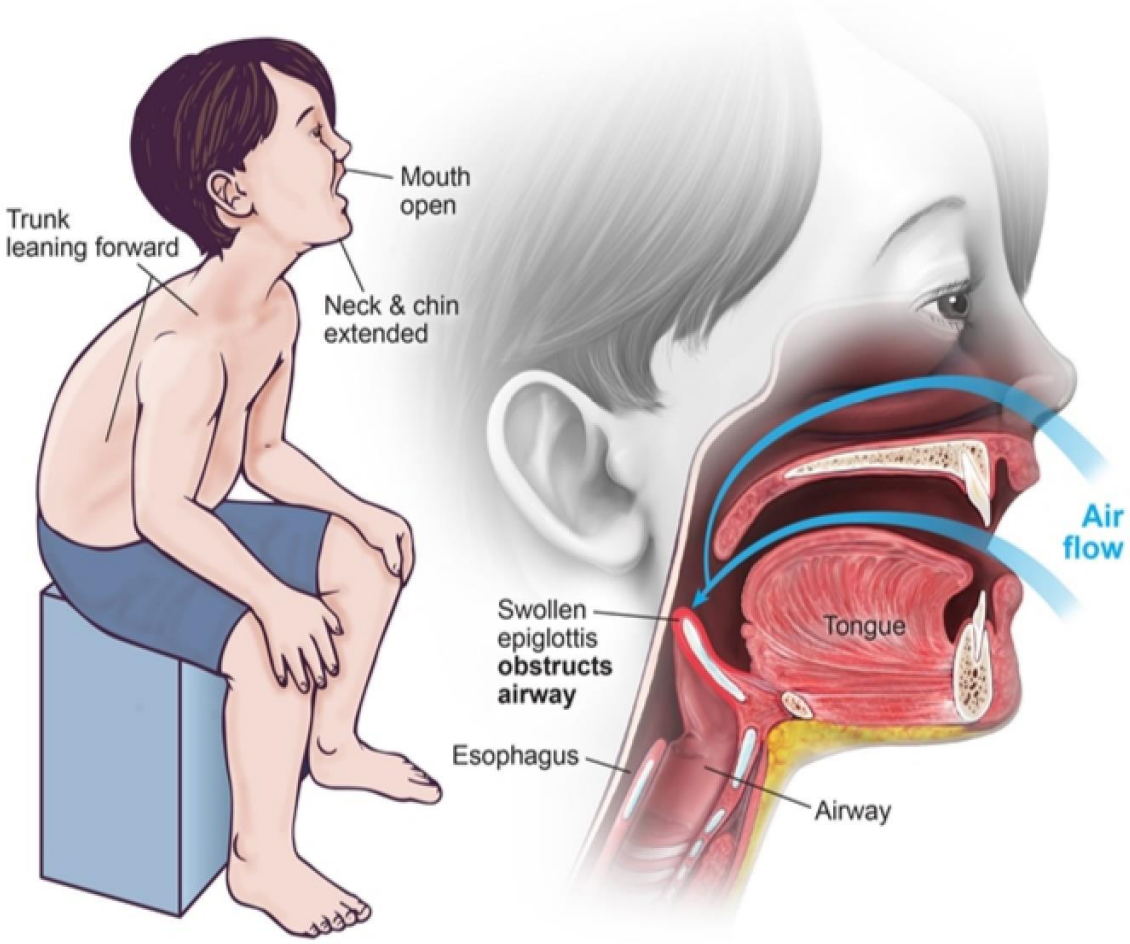

Croup

- Croup, or laryngotracheitis, is a viral respiratory illness most commonly caused by parainfluenza virus and typically presents in children age 3 months to 3 years.
- The virus spreads from the nasopharyngeal mucosa to the larynx and trachea, causing edema and narrowing of proximal trachea (subglottis). Inflammation of the cricoid cartilage creates a partial upper airway obstruction.
- The illness usually begins with nonspecific symptoms (rhinorrhea, congestion, fever); classic croup then presents with a dry, "barky," seal-like cough, hoarseness, and inspiratory stridor due to upper airway obstruction.
- Croup is typically a clinical diagnosis. If the diagnosis is unclear, anteroposterior neck radiographs will reveal subglottic edema known as the "steeple sign" (red arrow).
- Patients with moderate to severe croup (respiratory distress, stridor at rest) should be treated with corticosteroids and nebulized epinephrine, which constricts mucosal arterioles in the upper airway and alters capillary hydrostatic pressure, leading to decreased airway edema and reduced secretions.

Croup (laryngotracheitis)	
Pathogenesis	• Parainfluenza viral infection of the larynx & trachea
Epidemiology	• Age 6 months to 3 years • Fall/early winter
Clinical features	• Inspiratory stridor • Barking cough • Hoarseness
Treatment	• Mild (no stridor at rest): humidified air ± corticosteroids • Moderate/severe (stridor at rest): corticosteroids + nebulized epinephrine
Prevention	• Handwashing • Decontamination of surfaces • Proper ventilation

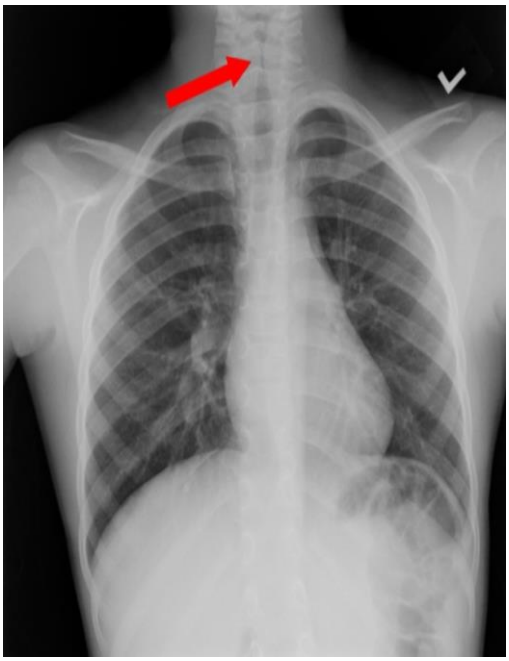

Bronchiolitis

- Bronchiolitis is a common winter respiratory tract infection caused primarily by respiratory syncytial virus (RSV).
- In older children, RSV infection is generally a self-limiting, mild, upper respiratory tract infection (nasal congestion, rhinorrhea).
- However, children age <2 years tend to have lower respiratory tract involvement with wheezing and/or crackles and respiratory distress symptoms (tachypnea, retractions, nasal flaring).
- Infants age <2 months are at high risk of developing apnea and respiratory failure from bronchiolitis.
- Diagnosis is primarily clinical, and treatment is largely supportive (hydration, saline nasal drops, nasal bulb suction).
- Palivizumab is a monoclonal antibody against RSV that is used for prophylaxis in children age <2 years who are at exceptionally high risk of complications.

Bronchiolitis	
Epidemiology	• Age <2 years • RSV most common cause
Clinical presentation	• Antecedent nasal congestion/discharge & cough • Wheezing/crackles & respiratory distress (eg, tachypnea, retractions, nasal flaring)
Treatment	• Supportive care
Prevention	Palivizumab for infants with the following conditions: • Preterm birth <29 weeks gestation • Chronic lung disease of prematurity • Hemodynamically significant congenital heart disease
Complications	• Apnea (especially infants age <2 months) • Respiratory failure

RSV = respiratory syncytial virus.

Whooping cough

- Bordetella pertussis is a Gram-negative coccobacillus that causes "whooping cough", a highly contagious illnesses characterized by paroxsyms of coughing.

- The illness begins with a mild catarrhal phase that resembles the common cold. This is followed by the paroxysmal phase in which severe, periodic coughing bouts can last up to 30 minutes.

- Each coughing episode often starts with a "whoop" caused by forced inspiration.

- Forceful coughing often triggers posttussive emesis, which may result in weight loss.

- Diagnosis:

- The diagnosis can be made clinically when classic symptoms are present. However, polymerase chain reaction testing of the nasopharynx is helpful for gathering epidemiologic data or when the diagnosis is uncertain.

- Treatment:

- Macrolides (azithromycin, clarithromycin) are the gold standard treatment and should be initiated based on clinical suspicion without waiting for confirmatory diagnosis.

- Although immunization can prevent 70%-90% of cases of pertussis, natural infection and vaccination confer only transient protection as immunity wanes over time. Despite immunization, many exposed household contacts will develop some symptoms of pertussis. Therefore, prophylaxis is recommended for all close contacts despite vaccination status. Macrolides are also the preferred antibiotics for prophylaxis.

- Contacts age >1 month should receive azithromycin, erythromycin, or clarithromycin.

- Those age <1 month should receive only azithromycin for 5 days as erythromycin use in neonates is associated with pyloric stenosis and safety data of clarithromycin are not available.

Pertussis postexposure prophylaxis	
Indications (regardless of vaccination history)	• Close contact (eg, household members) to symptomatic patient • High-risk patient (eg, pregnant, infant, immunodeficient) with exposure to asymptomatic patient
Treatment	• Age <1 month: azithromycin • Age ≥1 month: azithromycin, clarithromycin, or erythromycin

Mumps

- Mumps is a highly contagious viral infection that is transmitted via airborne droplets.
- Presents with fever and parotitis after a nonspecific prodrome (headache, and malaise).
- Parotitis initially occurs unilaterally, but typically progresses to involve both sides.
- Mumps is most common in school-age children, who often have a mild disease or may even be asymptomatic. The incidence is now very low in the US because of the combined measles, mumps, and rubella (MMR) vaccine.
- Symptoms can be more severe in adolescents and adults, and complications are more likely in older patients.
- The diagnosis of mumps is largely based on clinical findings. Many cases, however, present with nonspecific features and are not easily recognizable as mumps. If possible, diagnosis should be confirmed with laboratory tests (antibody titer).
- Treatment is symptomatic.
- In general, mumps is a self-limited condition, but serious complications are possible. Aseptic meningitis is the most common complication of mumps, with cardinal symptoms including headache, fever, and nuchal rigidity.
- Orchitis is another potential complication that occurs primarily in postpubertal males and can impair fertility.

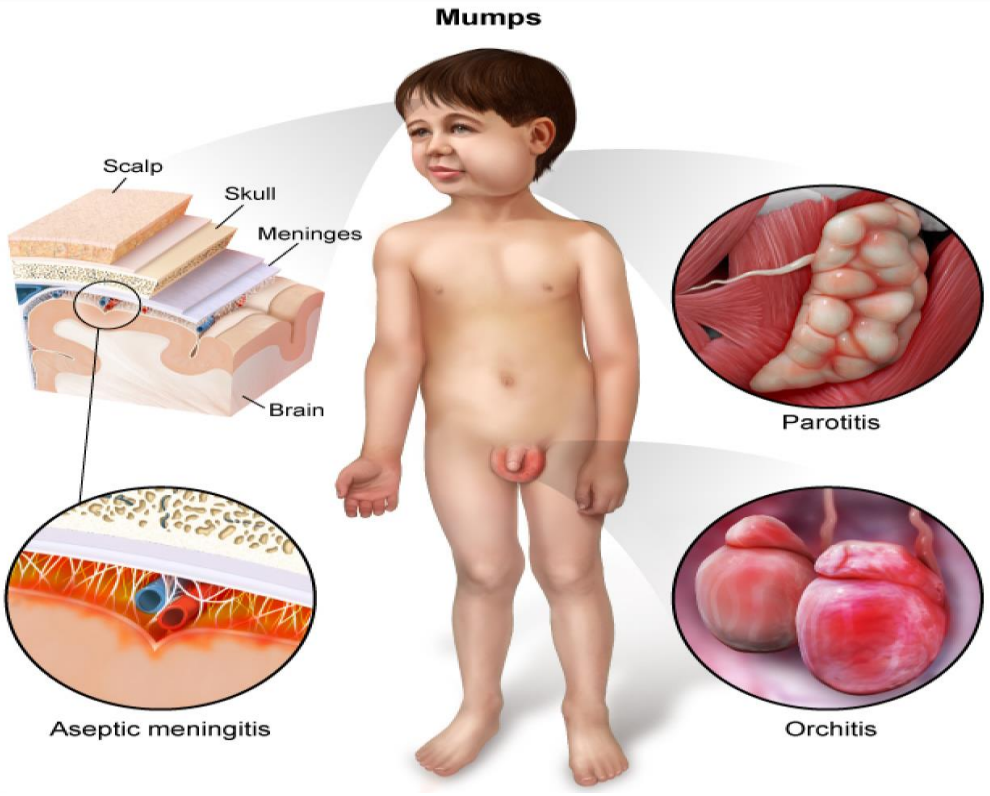

Measles (rubeola)

- Measles (rubeola) is an extremely contagious disease that is spread by infected droplets from respiratory secretions.

- A classic clinical manifestation of measles is the presence of Koplik spots, small whitish, bluish, or grayish specks on the buccal mucosa adjacent to the second molars. Koplik spots are sometimes likened to "grains of sand" on an erythematous base.

- When the spots are accompanied by cough, coryza, and conjunctivitis, measles infection is likely (mnemonic: CCCK: Cough, Coryza, Conjunctivitis, and Koplik spots).

- On days 3-5 of illness, the erythematous, macular exanthem is sometimes pruritic; begins on the face; and spreads in a cephalocaudal and centrifugal pattern to the rest of the body. The rash persists for a week, coalesces, and darkens to a reddish-brown color.

- Measles is a highly contagious virus that can cause outbreaks in unvaccinated persons. Patients are most contagious during the prodrome but can spread disease for several days even after the resolution of the rash. Patients with known or suspected measles should be isolated and placed on airborne precautions (negative pressure room, N95 facemask for health care personnel).

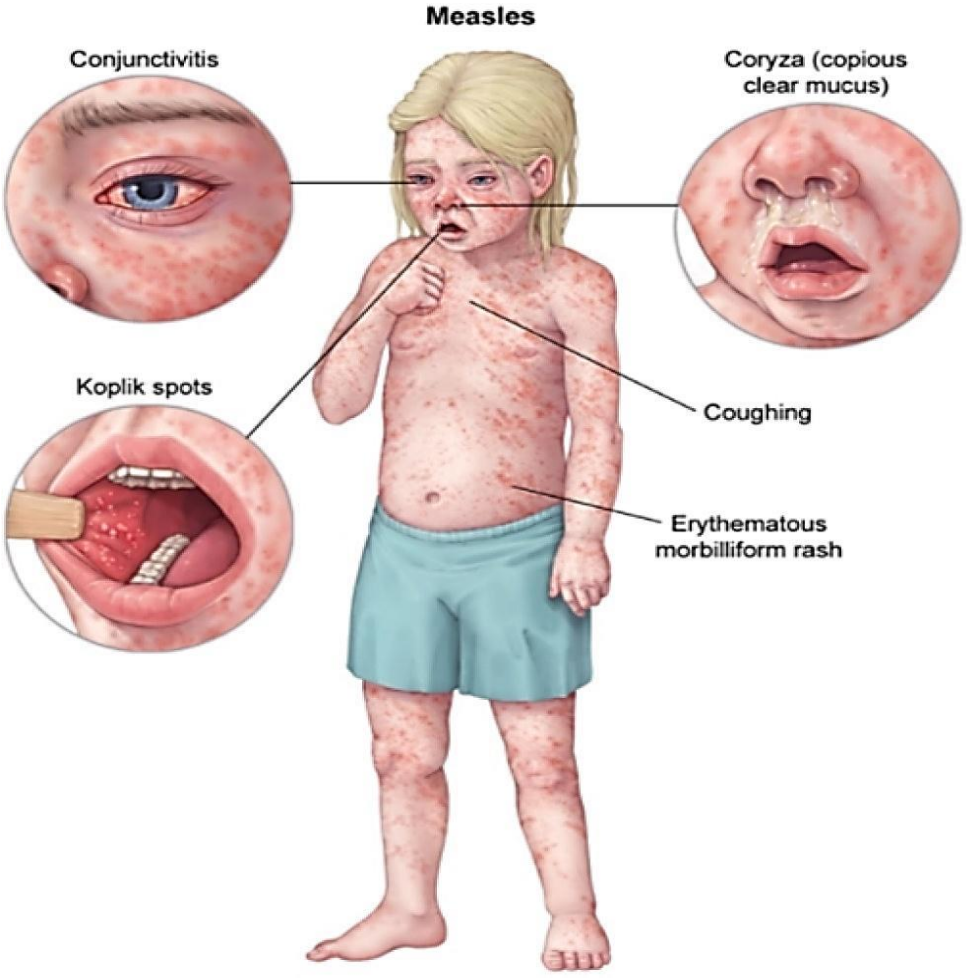

- Diagnosis:

- The diagnosis is supported by a fourfold rise in antibody titers and confirmed by polymerase chain reaction.

- Treatment:

- Treatment is primarily nonspecific symptomatic relief with antipyretics and hydration as no specific antiviral therapy is available.

- Measles causes transient immunosuppression and may lead to serious complications such as encephalitis, otitis, or pneumonia. A rare but lethal late complication of measles is subacute sclerosing panencephalitis (SSPE), which may also affect immunocompetent individuals.

- Treatment with vitamin A reduces the morbidity and mortality rates for patients with severe measles (those requiring hospitalization) through the promotion of antibody-producing cells and regeneration of epithelial cells (in the gut, lungs, and retina).

Measles virus (rubeola)	
Transmission	• Airborne
Clinical presentation	• Prodrome (eg, cough, coryza, conjunctivitis, fever, Koplik spots) • Maculopapular exanthem ◦ Cephalocaudal & centrifugal spread ◦ Spares palms/soles
Prevention	• Live-attenuated measles vaccine
Treatment	• Supportive • Vitamin A for hospitalized patients

Rubella (German measles)

- Rubella, or German measles, is an infectious disease that is caused by the rubella virus.
- Since the introduction of the measles, mumps, and rubella (MMR) vaccine, it is a relatively rare condition. Rubella is transmitted via airborne droplets and has a mild clinical course.
- Vaccination with the live attenuated rubella vaccine is important as active infection in women during the first trimester of pregnancy can cause congenital rubella syndrome.
- Rubella presents with low-grade fever, a maculopapular rash with rapid cephalocaudal spread, and posterior auricular and suboccipital lymphadenopathy.
- Adolescents, especially females, may also present with arthralgias or arthritis that can persist after the rash resolves.
- Diagnosis: serology.
- Treatment: Rubella is usually self-limiting and involves symptomatic treatment.

Rubella (German measles)	

Clinical presentation	• **Congenital:**
	  ◦ Sensorineural hearing loss
	  ◦ Cataracts
	  ◦ Patent ductus arteriosus
	• **Children:**
	  ◦ Fever
	  ◦ Cephalocaudal spread of maculopapular rash
	• **Adolescents/Adults:**
	  ◦ Same as children + arthralgias/arthritis

Diagnosis	• Serology
Prevention	• Live attenuated rubella vaccine

Chickenpox

- Varicella (chickenpox) is caused by the highly infectious varicella-zoster virus (VZV) that occurs most frequently during childhood.
- The incidence of varicella in the United States has declined significantly due to universal vaccination (2 doses at ages 1 and 4 years old).
- Approximately 2 weeks after exposure to airborne particles, patients with varicella develop a brief prodrome (fever, malaise) followed by onset of rash within 24 hours.
- The rash is initially maculopapular but rapidly becomes intensely pruritic and vesicular involving the trunk, face, and extremities. The vesicles can become pustular and subsequently crust over.
- Successive "crops'' of vesicles appear daily over a week, resulting in vesicles at different stages.
- Superimposed aggressive group A streptococcal infection can also develop and should be treated with antibacterial therapy.
- Varicella is generally a self-limiting infection that does not require antiviral therapy.
- In rare cases, varicella can cause cerebellar ataxia or pneumonia.
- Reactivation of latent VZV results in shingles (herpes zoster)



Varicella infection	
Clinical features	• Aerosolized transmission with 2 week incubation • Prodrome (eg, fever, malaise) • Maculopapular rash followed by successive "crops" of vesicles
Prognosis	• Usually self-limiting • Antiviral therapy for immunocompromised or complicated disease (eg, cerebellar ataxia, pneumonia)
Prevention	• 2 doses of varicella-zoster virus vaccine (ages 1 & 4)

Erythema infectiosum

- Children with parvovirus infection often develop a "slapped cheek" rash as part of erythema infectiosum.

- Erythema infectiosum begins with a mild febrile illness followed two to five days later by a maculopapular rash that is especially noticeable on the cheeks ("slapped-cheek" rash) and may be pruritic.

- Parvovirus infection most commonly affects adults who have frequent contact with children (school teachers, daycare workers).

- Adults most commonly develop a polyarticular, symmetric arthritis (60% of cases) involving peripheral joints, including the hands (metacarpophalangeal [MCP], proximal interphalangeal [PIP], and wrist), knees, and ankles. Arthritis due to parvovirus B19 typically does not cause joint destruction or chronic arthritis.

- Diagnosis:
- Parvovirus B19 infection is diagnosed by detecting anti-B19 IgM antibodies in the serum.

- Treatment:
- The symptoms typically resolve spontaneously in 2-3 weeks without the need for specific treatment.



Enterobiasis

- Enterobiasis is the most common helminthic infection in the United States.
- Enterobius vermicularis, most frequently infects school-aged children (age 5-10).
- Transmission occurs via ingestion of eggs, typically due to autoinoculation from contaminated hands. The larvae develop to adult worms within the small intestine.
- The adult pinworm thrives primarily in the human cecum and appendix. At night, the female worms migrate out through the rectum and deposit eggs in the perianal region, resulting in nocturnal perianal pruritus.
- Other symptoms may include abdominal pain, nausea, vomiting, and vulvovaginitis.
- Diagnosis:

- Diagnosis is made using cellophane tape ("scotch tape test") to detect the presence of Enterobius eggs.

- Treatment:

- Albendazole and pyrantel pamoate are the first-line treatment options, but the latter is preferred for pregnant patients.
- The patient and all household contacts should be treated as the infection is highly contagious.

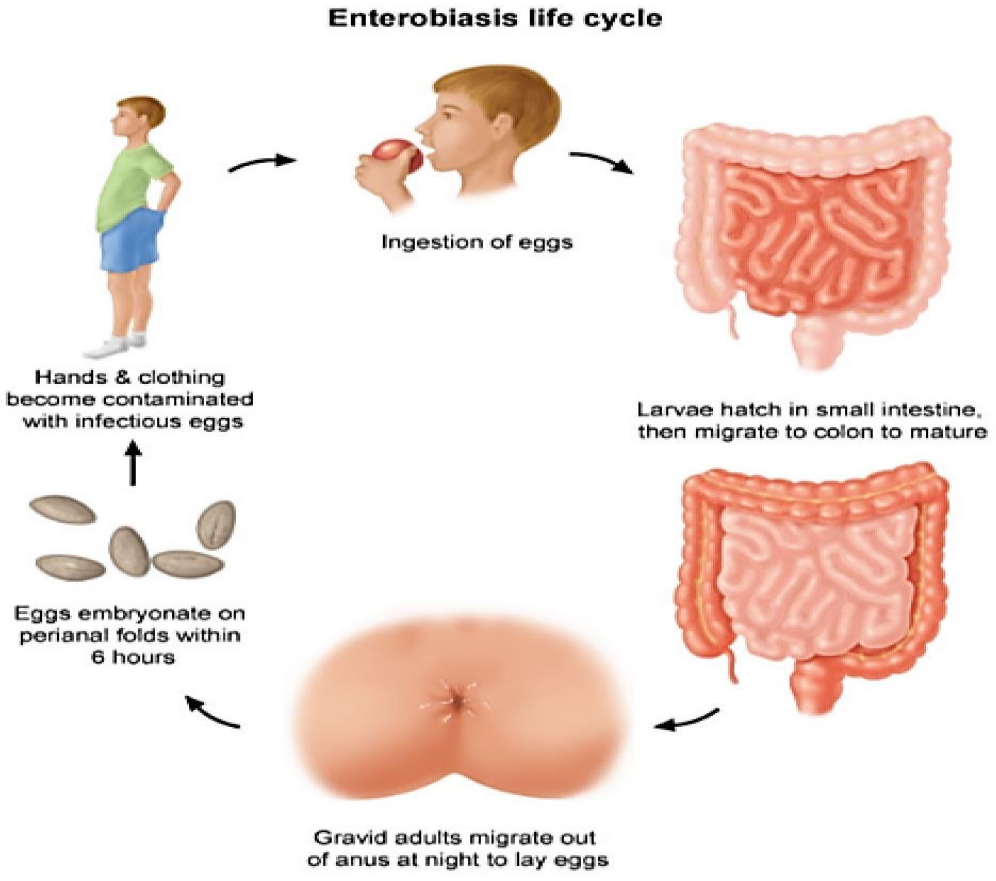

Neonatal sepsis

- Neonatal sepsis is a systemic bacterial infection that occurs in infants <28 days old.
- Although Group B Streptococcus (GBS) sepsis rates have declined due to universal screening and use of intrapartum antibiotic prophylaxis, GBS and Escherichia coli continue to be the most frequent causes of both early-onset (age <3-7 days) and late-onset sepsis.
- Infection with these pathogens occurs during passage through the birth canal. Studies have shown that sepsis in most term infants is due to GBS, whereas preterm infants are infected with E coli.
- Clinical manifestations of neonatal sepsis are often subtle and nonspecific.
- Sepsis should always be high on the differential for neonates (age <28 days) with decreased activity or poor feeding, which can be among the earliest signs of serious infection.
- Neonates may have fever or hypothermia due to temperature instability.
- Mild jaundice due to transient conjugation deficiency is also common with neonatal sepsis.
- Finally, unlike older children or adults, neonates with meningitis may not have neck stiffness, and Kernig and Brudzinski signs are not useful. Instead, neonates with meningitis generally are irritable, lethargic, or hypotonic.
- Diagnosis: Neonates with suspected infection require a full evaluation, including a complete blood count, blood cultures, lumbar puncture, urinalysis, and urine cultures.
- Treatment: Neonates should also receive empiric antibiotics (ampicillin and gentamicin, or ampicillin and cefotaxime) after culture.

Neonatal sepsis	
Clinical features	• Temperature instability (fever or hypothermia) • Poor feeding • Jaundice • CNS signs (lethargy, irritability, apnea) • Abnormal white blood cell count (high or low) • Left shift (bandemia)
Diagnosis	• Blood, urine & cerebrospinal fluid culture
Treatment	• Parenteral antibiotic therapy

CNS = central nervous system.

Pediatric vaccination

- Premature infants are at high risk of complications from vaccine-preventable diseases due to immature immune systems.
- Vaccinations for preterm infants should not be delayed; they are safe and proven to induce an adequate antibody response to confer immunity. In addition, mild intercurrent illness is not a contraindication to vaccination. Therefore, medically stable premature infants should receive routine immunizations on the same schedule as full-term infants, based on their chronologic age (age since birth).

Standard pediatric immunizations in the United States	
Inactivated (killed)	• Polio • Hepatitis A
Toxoid (inactivated toxin)	• Diphtheria, tetanus
Live attenuated	• Rotavirus • Measles • Mumps • Rubella • Varicella
Subunit/conjugate	• Hepatitis B • Pertussis • *Haemophilus influenzae* type B • Pneumococcal • Meningococcal • Human papillomavirus • Influenza (injection)

❖ N.B:

1. The two potential causes of varicella-like rashes after VZV vaccine include:

- Attenuated vaccine virus can replicate after immunization and cause mild infection in approximately 3% of immunized children.
- Wild-type VZV can cause classic varicella if acquired before the child's immunization results in protective antibody

- The lesions of the vaccine-strain virus are generally few in number (<10) and are more likely to be maculopapular rather than entirely vesicular. In contrast, classic varicella disease presents with >100 vesicular lesions in successive "crops" over several days.
- The disease caused by vaccine-strain virus is very mild and is not a contraindication to future VZV vaccine administration.
- The vaccine-strain virus is less contagious than wild-type varicella, but it can be transmitted to other individuals. Therefore, patients who develop a rash after receiving the VZV vaccine should avoid contact with high-risk individuals who are susceptible to varicella (pregnant women, people receiving chemotherapy) until the rash has completely crusted over.

Vaccine-strain versus wild-type varicella	
Vaccine strain	**Wild type**
• <10 lesions • Maculopapular &/or vesicular • Mildly contagious	• >100 lesions • Vesicular in successive crops • Highly contagious

2. The diphtheria-tetanus-acellular pertussis (DTaP) vaccine is a combination vaccine containing acellular pertussis antigen with diphtheria and tetanus toxoids.

- Combination vaccines are safe, effective at preventing infection, and beneficial in reducing the number of needlesticks required (resulting in decreased pain and improved compliance).
- Children should receive 5 doses of the inactivated DTaP vaccine at ages 2, 4, and 6 months; 15-18 months; and 4-6 years.
- The risk of an adverse reaction to the DTaP vaccine is low and generally includes minor erythema/swelling at the injection site and/or fever. Seizure, triggered by fever or by the pertussis vaccine component, is rare and is typically short (<5 minutes) and self-limited.
- Patients with a family history of febrile seizures or epilepsy may be at increased risk.
- However, neither personal nor family history of seizures is a contraindication to immunization. Specifically, uncomplicated seizure following vaccine administration is not a contraindication to future vaccination. The benefit of DTaP vaccination, especially in the setting of a pertussis outbreak, outweighs the unlikely risk of significant side effects.
- The DTaP vaccine is contraindicated in a few circumstances. When anaphylaxis develops following DTaP administration, the patient should not receive future doses. In addition, unstable neurologic disorders (infantile spasms, uncontrolled epilepsy) and encephalopathy (coma, decreased level of consciousness, prolonged seizures) within a week of DTaP vaccine administration are contraindications to the combination vaccine; as a result, diphtheria and tetanus toxoids should be administered without pertussis.

- Immediate anaphylaxis, unstable neurologic disorders, and encephalopathy within a week of administration of the diphtheria-tetanus-acellular pertussis vaccine are contraindications for further administration of pertussis-containing vaccines.Immunization against pertussis should be provided in the absence of these conditions.

Diphtheria–tetanus–acellular pertussis immunization	
Components	• Diphtheria toxoid • Tetanus toxoid • Conjugated pertussis antigen (pertactin)
Schedule	• 5 doses given at ages: ◦ 2, 4 & 6 months ◦ 15-18 months ◦ 4-6 years
Contraindications	• Encephalopathy after previous dose • Anaphylaxis to vaccine component

3. Sickle cell disease (SCD) causes functional asplenia due to recurrent splenic infarction. Intermittent sickling of red blood cells in the spleen leads to splenic infarction and ultimately functional asplenia.

- As a result, patients with sickle cell disease (SCD) are at high risk for sepsis from Streptococcus pneumoniae, Haemophilus influenzae, and Neisseria meningitidis.
- The incidence of bacteremia has decreased as a result of improved vaccination approaches (pneumococcal conjugate and polysaccharide vaccines, meningococcal conjugate vaccine).
- Despite vaccination, S pneumoniae remains by far the most common cause of sepsis in patients with SCD, usually from non-vaccine serotypes. Therefore, patients with SCD should receive prophylactic penicillin until at least age 5.

4. Rotavirus is the most common cause of gastroenteritis in infants and young children worldwide. The virus is highly contagious and is transmitted by the fecal-oral route through direct contact and through fomites.

- The typical course of illness consists of fever, vomiting, and watery osmotic diarrhea. Affected children often suffer from severe dehydration.
- The rotavirus vaccine is the best defense against rotavirus gastroenteritis and prevents most cases of infection. The vaccine series is typically administered at age 2-6 months and has dramatically reduced the incidence of rotavirus-related hospitalizations and deaths globally.
- This live attenuated virus vaccine (LAW) can be administered safely with routine inactivated vaccinations.
- Although the vaccine is generally well tolerated, caregivers should be advised about the small risk of intussusception. The mechanism is not clear but may be related to rates of viral replication in the intestines. Infants with a history of intussusception should not receive the vaccine. In most other infants, the benefit of disease prevention outweighs the low probability of intussusception. Therefore, vaccination against rotavirus is recommended in the absence of contraindications.

References

- KAPLAN USMLE STEP 2 LECTURENOTES
- BECKER USMLE STEP 2 LECTURENOTES
- MASTER THE BOARD STEP 2 AND 3
- USMLE WORLD QUESTION BANKS
- NBME SELF ASSESSMENT EXAMS
- STEP 2 SELF ASSESSMENT EXAMS