① ACS :- STEMI - non-STEMI - unstable angina - sudden cardiac death

- occlusion of coronary a. 100% → STE ACS (ischemia)
- partial occlusion → non-STE ACS or unstable angina

ST elevation in V_1 → V_4 → anterior MI (LAD occlusion)

A) pt. presented to ER with MI → primary PCI ✓ → we found thrombus in the circumflex a.
- ST elevation in V5-V6 (lateral leads)

B) Pt. presented with severe chest pain to ER, burning or crushing or heavier character + sweating
- problem in ECG
  - ST elevation
- character of ACS

---

② HF :-

- Rt-sided HF → pleural effusion
- lt-sided HF → pulmonary congestion [orthopnea - dyspnea - PND →]

CHF → anasarca

. pt. with AS → lt-sided HF
- orthopnea - dyspnea - syncope - chest pain
- لكل واحد life expectancy لأنه نزف ال
- chest pain → 5 years
- syncope/dizziness → 3 years
- dyspnea → 2 years

worst complain of ↓

HF لأنه معناه AS

⇐ في ال ٣ ← risk of death بكون 50% لو ما تعالج المريض

---

③ Heart murmurs :- has propagative tests, عشان تقويها → manuvers

- AS → best heart in 1st aortic area → 2nd Rt ICS
- MS - MR → at apex بنسمعه أكثر لما يلف ع جنبه الشمال
  - radiates to axilla

الالوكي في MR مع rupture of papillary M. ← بصيرة ال radiation حسب مين ال papillary muscle اللي صار بها rupture
- anterior papillary ms. → radiates to sternum
- posterior " " → radiating to back

④ Cases:- ① 66-year old male pt, has dyspnea since 3 days - pleuritic chest pain - hx. of recent surgery
normal examination - وقاعد في البيت من أسبوع - cholecystectomy
⇒ Most likely diagnosis is PE

- Wells score of PE:- dyspnea - palpitation → no risk.
① unexplained dyspnea (مش لاهية بسبب تاني) → 3 points
② clinical evidence of DVT → 3 points
③ Bedridden for 4 weeks → 1.5 point
④ tachycardia → 1.5
⑤ Chest pain → 0.5

Wells score

Criteria	Points
Clinical signs/symptoms of DVT	3
PE is most likely diagnosis	3
Tachycardia (>100 bpm)	1.5
Immobilization/surgery in previous 4 weeks	1.5
Prior DVT/PE	1.5
Hemoptysis	1
Active malignancy (trt w/in 6 month)	1

Low Risk	Intermediate risk	High risk
< 2 points	2-6 points	>6 points

PE unlikely	PE Likely
0-4 points	>4 points

> 6 points → high probability risk of PE

② pt. presented to ER with severe chest pain radiating to back + hx. of uncontrolled HTN, the most likely diagnosis → aortic disection
↳ auscultation → early diastolic murmur at lt sternal border (AR)
AR associated with type A aortic disection

③ Pt. presented to ER with dyspnea - orthopnea - dyspnic - tachypnic - LL edema - irregular irregularity pulse + congested neck veins
↳ AF
V wave ل بنشوف
absent P wave
absent A wave (JVP)

AF → no atrial contraction
↳ loss of A wave

JVP → 3 waves
- a wave → atrial contraction
- v wave → ventricular contraction
- c wave → RA filling

في هاي الحالة لو ما كان في AF ← بنشوف ال A wave و V wave
↳ بنميز بينهم من ال pulse
↳ إذا ال peak تاع ال JVP بنفس اللحظة مع ال pulse
↳ v waves ventricle contraction
↳ لو كان ال peak قبل ال pulse ← a wave

5) Side effects of drugs:- (مهمة)

ACEFs → dry cough
CCB → angioedema
Spironolactone → hyperkalemia

ما عندي renal failure وال creatinine = 2.5 ← بنقدر نعطيه ACEFs ولكن لو عندي hyperkalemia ما بنعطيه (ممنوع)

- 16 year-old patient - BP: 165/85 - short stature - has neck web - has radio femoral delay
↳ coarctation of aorta
↳ mid diastolic or late diastolic murmur radiates to back

- 62 year old pt. presented to ER with retrosternal chest pain + sweating (ACS) + ST depression → non-STE ACS
أعطيناه aspirin و O2 و sublingual nitrate صار stable
↳ next step is giving him anti-coagulant ↳ مارح يعمل primary PCI

- 50 year old pt. / BP = 160/60 - regular heart beat - decrescendo murmur → AR
↳ diastolic ↳ نحفظ ال signs of AR
double durziez murmur - pistol shot ← femoral a. ↳
↳ diastolic and systolic

- 50 year old female pt. presented to ER in early morning with severe chest pain [retro-sternal, radiating to both arms] + sweating - ST elevation in all leads then after 15 mins (STE اختفى)
↳ variant angina
↳ more likely in females - smokers - has emotional stress
transient ST elevation ومعها mid-night ال early morning بتجي في ال

- 19 y/o pt. has a central chest pain - loud mid-systolic murmur in the retrosternal edge - has jerky pulse

لاحظ بفكرة AS

$\boxed{\text{HOCM}}$ #

HOCM	vs.	AS
- jerky pulse		- pulsus parvus et tardus [slow raising pulse + delayed emptying]
- No radiation		- Radiated to carotid
- normal S_2		- muffled S_2
- best heard at the lt sternal border		- best heared at the 1st aortic area

- Drug of choice for HOCM → β-blocker or amiodarone

contraindication ← digoxin - nitrate زي VD أما الشغلات اللي بتعمل

- pt. with acute inferior MZ [ST elevation in lead lead II - III - aVF] + took treatment

most likely occluded (سكر) ← ال دخلناه قسطرة

Rt coronary a. ↓

or lt circumflex a.

To differentiate between lt circumflex a. or RCA occlusion on ECG:-

- ST elevation in lead II more than lead III
- no ST elevation in V4 [distal] (isoline)

- ST elevation in lead III more than lead II
- ST elevation in V4 in Rt side ECG (proximal)

$\boxed{\text{كل واحد بيجي ب acute inferior MZ لازم نحله ECG ع ال Rt side}}$

في ال cardiogenic shock ممكن نتتبع كل الزوايا

- 2 specific localization ← عشان نميز ال calliprit lesion نشوف إنا في أو لا RV infarction + dorsal MZ
  - Rt side
  - dorsal side

- The main treatment of HF:-
  - Diuretics (lasix)
  - β-blockers
  - spironolactone
  - SGLT-2 inhibitors

± Entresto

↳ if not available → ACEIs or ARBs

- pt. has acute old MI [ischemic], 70 years old, presented with dyspnea - orthopnea - Ledema
EF = 40% → all of the following drugs should be described except CCB

normal = 50-75 ↓ → HF due to ischemi

EF < 35 → HFrEF
EF > 45 → HFpEF
EF 35-45 → HF mid range

- patient with Rheumatic heart dz. & mitral stenosis → has AF - HF - old stroke - COPD ---
mitral ↓ regurge
combined [2 lesions in the same valve]
- the main etiology is Rheumatic heart dz.
- anatomy → MS - MR
- Functional class → HF - NYHA class 2-3-4

- لازم ياخذ lasix
- لازم ياخذ Aspirin
- لازم ياخذ B-blockers ← HF و IHD
- ACEIs ~ ~
- statins ~ ~

But not CCB

- 30 year old female pt. complains of dyspnea - palpitation - has mid-diastolic rumbling murmur in the apex → MS
ECG → AF

بشكل عام طالعي indications of surgery سواء valvoplasty أو replacement :-

① General to all vhd → ① pulmonary HTN < 50 mmHg
② Severe symptoms despite Hx.
③ Patient is undergoing another cardiac surgery

③ Special for each valve:-

regurge
- ① EF < 55% (ثابتة)
- ② systolic diameter
  - mitral > 45mm / 4.5cm
  - aorta > 55mm / 5.5cm

Stenosis
- ① ΔP → mitral → > 10 mmHg
  - aorta → > 40 mmHg
- ② valve area → mitral < 1.5cm²
  - aorta < 1cm²

- surgery → valvoplasty
  → valve replacement [mechanical or biological]

- Indications of mitral valve replacement:-
  - associated with MR grade 2 or more
  - severly calcified valve (unbliable)
    - not mobile

لا بنخاف من الـ rypture زي الـ stroke

valvoplasty ← لو ما في هدول
- open → الجراح بفتح وبأصبعه بوسع الصمام
- close → by catheter

لازم نحل TEE لحتى نشوف الـ appendage
لو في thrombus ← open لو ما في close

- A female pt. with severe MS - without MR - no severe calcification - by TEE → lt atrial appendage thrombi
  - open valvo plasty

- Pulmonary HTN:- activin receptor inhibitor
  - balance في هو Fibrinolysis, activin في
  - if there's chronic HTN - severe → ↑ proliferation → ↑ resistance → ↑ BP
    - اسمه مش مهم للامتحان activin receptor inhibitor
  - Signs:- Rt ventricular hypertrophy
    - epigastric pulsation
    - lt parasternal pulsation
    - pulmonary a. pulsation
    - JVP pulsation
  - auscultation → most important sign of pulmonary HTN
    - accentuated S_2 on the pulmonary area

- Cardiomyopathies (1-2 questions):-

DCM - hypertrophic - restrictive - arrhythmogenic
- all chambers are dilated (بغض النظر عن السبب) idiopathic - ischemia - HTN
  - hypokinesia (global)
    - secondary MR or TR
    - ↓ EF
    - eccentric hypertrophy

eccentric vs. concentric
- eccentric: dilated (thin)
- concentric: thick wall [HTN]

supravalvular AS → Williams syndrome
↑ ΔP → ↑ risk of destruction of LV

- HOCM :-
  1. ASH → asymmetrical septal hypertrophy — ال septum بتضخم أكثر من ال lateral wall
  2. ventoli effect (دوارة) → anterior mitral leaflets toward septum
     [SAM] → systolic anterior motion of the anterior mitral leaflets towards septum
  3. MR as a result of ventoli effect

→ systolic murmur - jerky pulse

Auscultatory finding of MS [مهمة] → 3-4 questions
[murmur - heart sounds - متى بخف - متى بزيد ——]

- Which of the following is considered as primary indication for AICD [automated implantable cardioverter defibrillator] to prevent sudden cardiac arrest

→ primary indication - secondary

- ال قبل ما يصير arrest
  عنده أمراض معروفة زي HOCM -
  old acute MI (acute)
  → without arrhythmia لأنه كتير ناس بحتاجوا ICD
  ال أي مريض عنده hx. of acute MI
  وال EF أقل من 35% ، بعد 3 شهور لازم
  AICD ولكن

- أي واحد arrested و
  survived بتركيبه ICD
  عشان ما يصير تاني
  → كل هدول ال survived لازم نعطيهم AICD
  ما عدا لو كان مثلاً correctable ال cause زي مثلاً
  acute treated MI أو hyperkalemia
  لأنه غالي

- CRT → gives DC shock + بقوي العضلة
  → cardiac resynchronization therapy
  بيرجع يخلي القلب يشتغل synchronized يعني ال atrium يعمل
  contraction → ventricular relaxation
  والعكس والاشتغال بعض

- لو ال RV عمل contraction قبل ال LV ← LBBB
  (atrioventricular synchronization)

- في ال advanced HF ← القلب بيشتغل non-synchronized خصوصاً لو في LBBB ولو عملنا Cardiac resynchronization
  حيستفيد المريض (CRT) لأنه كله يشتغل مع بعض

[مهم] - idications of CRT:-
  → EF < 35%
  → LBBB in ECG / [non-synchronized activity of heart] ← wide complex M shape
  → took medical therapy and still symptomatic

case ممكن all of the following ممكن يرجى except

- 70 year old pt. - HF - post MI - symptomatic - took guidline medical therapy - EF = 20% - very wide complex > 140 msec
↳ LBBB

the best intervention → CRTD

لأنه ischemic ممكن يموت بـ sudden cardiac death

↳ CRT + ICD

لا يقوي العضلة ما يعطي DC shock

↳ DC shock

- LV assess device → بنحط pumb جنب القلب وانبوبة بيصبح جنب الـ ventricle ولكن بدو بطارية كل ١٢ ساعة

↳ ممكن نستخدمها في الـ HF لو ما زبط كل اشي (آخر خيار)

- 35 year old pt. has AF - palpitation (1 week)

rhythm control يعني عدا الوقت تاع

هاد بنعمل rate control + anti-coagulant 3 weeks وبعدها بنعمل TEE

→ thrombus → نكمل

→ no thrombus → we can do rhythm control

مهمة إذا stable ولا لا الـ duration

organic heart dz - WPW $

AF

- stable
  - ↳ < 48 hs
    - thrombus ما تكون ↳ rate and rhythm control
  - ↳ > 48 hs بنخاف تكون في thrombus ويرضى في stroke
    - ↳ rate control + anti-coagulant + TEE
- unstable (shock - pulmonary edema - hemodynamically compromized)
  - ↳ DC shock

إجا السؤال قبل - pt. 35 years old - palpitation for 5 days - BP = 120/75 (stable) - ECG → AF - HR = 120-125

which management is the best option Rate control - anti-coagulants for 3 weeks - TEE

rhythm control ✗

rate and anti-coagulant for 1 year ✗

rate control and oral anti-coagulant long-life ✗

- pt. has chronic AF
  - needs anti-coagulants
    - according to CHADS2 vas score

	CHA_2DS_2-VASc risk factor	Points
C	Congestive heart failure	+1
H	Hypertension	+1
A_2	Age 75 years or older	+2
D	Diabetes mellitus	+1
S_2	Previous stroke, transient ischaemic attack or thromboembolism	+2
V	Vascular disease / IHD	+1
A	Age 65–74 years	+1
Sc	Sex category (female)	+1

- 0 score + young age → no intervention
- young age + risk factor → aspirin
  - DM-HTN
- ≥2 score → anti-coagulants
  - target INR 2-3 ← Warfarin
  - NOACs

- 70 year old pt. (1 point) - HTN (1) - DM (1) - severe MS

3 points → Warfarin
- not NOACs [MS]

- Complications of MI (1-2 questions):-

- acute MI → killip classification

① class 1 → Dyspnea, no cripitation, with gallop rhythm → tachycardia - MI
HF
5% mortality

② class 2 → Dyspnea, gallop rhythm, basal cripitation
25% mortality

③ Class 3 → Pulmonary edema, cripitation in all chest
scapular angle
≥ 40% mortality

④ Class 4 → Cardiogenic shock "pump failure"
→ 40% of Lt ventricle necrosis
≥ 60% mortality

Indications for thrombolytic therapy:

① كل ما كان أبعد أحسن أبعد ١٢ ساعة لا يمكن إعطاؤه.

Lecturing Not 10-15 mins.

② ST elevation in ECG [in 2 or more leads].
- → ≥ 1 mL in limb leads. [lead 1-2-3 - avF]
- or
- → ≥ 2 mL in chest leads.

لأنه أحيانا يكون طبيعي منهم

ماعدا الـ females ← ≥ 1.5 mL

③ It BBB + Sgarbusca criteria.

Contraindication of thrombolytics:

في absolute وفي relative

absolute:

① Active non-compressible bleeding [GI bleeding - aortic dissection - brain hemorrhage - brain tumor]

② Brain tumor - brain hemorrhage.

③ Ischemic stroke أول شهر يكون absolute contraindication بعدها relative

بعدها relative لأنه بنفاوت الـ hemorrhage لأنه

الـ brain tissue يكون Fragile

④ High pressure. > 180/100

⑤ PUD - previous GI bleeding

⑥ pregnancy

⑦ pericarditis

⑧ Liver problem / problem in platelets.

⑨ Takes anti-coagulants.

relative

لو اقتنيا في indication وما في contraindication ← هبطي thrombolytics

لو كان في contraindication حتى لو نص الليل بنعمله PCI. وكان Failed thrombolytics لا يكون

↳ rescue PCI.

- Diagnosis of HF without Echo:-

Framingham criteria

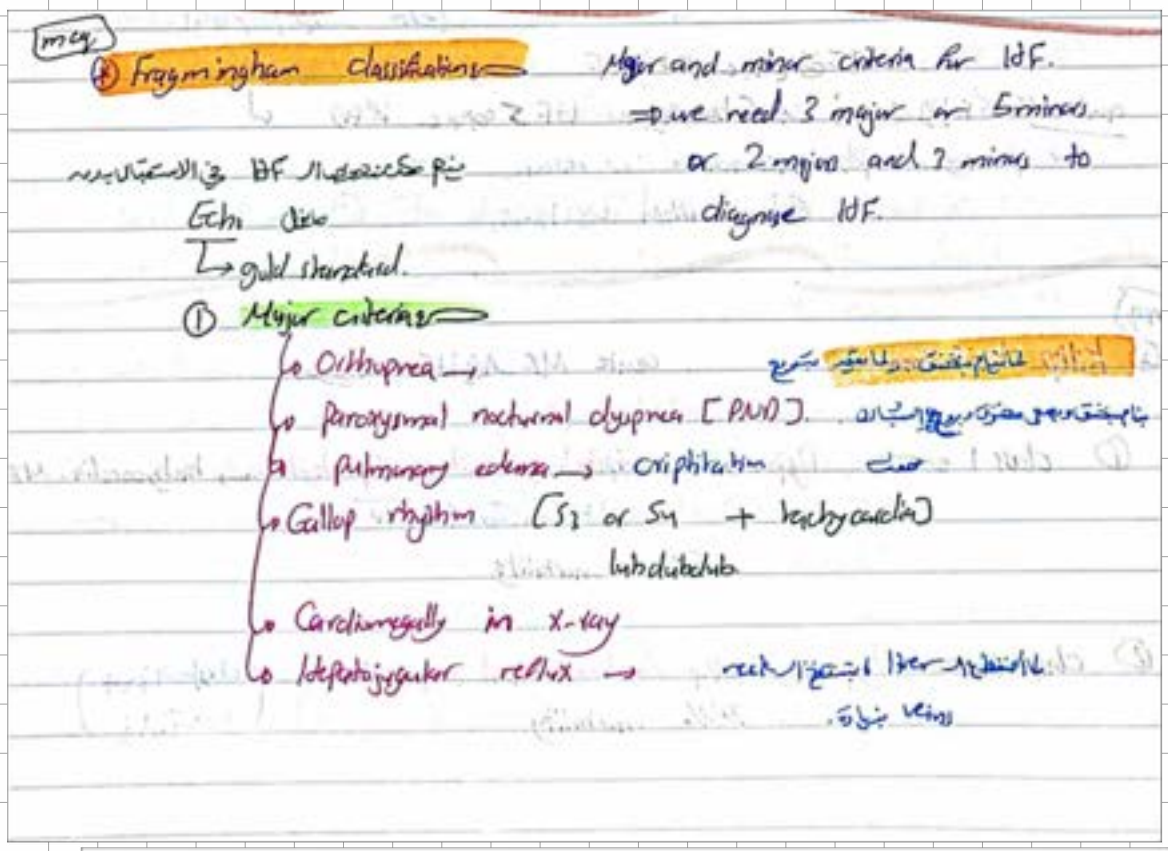

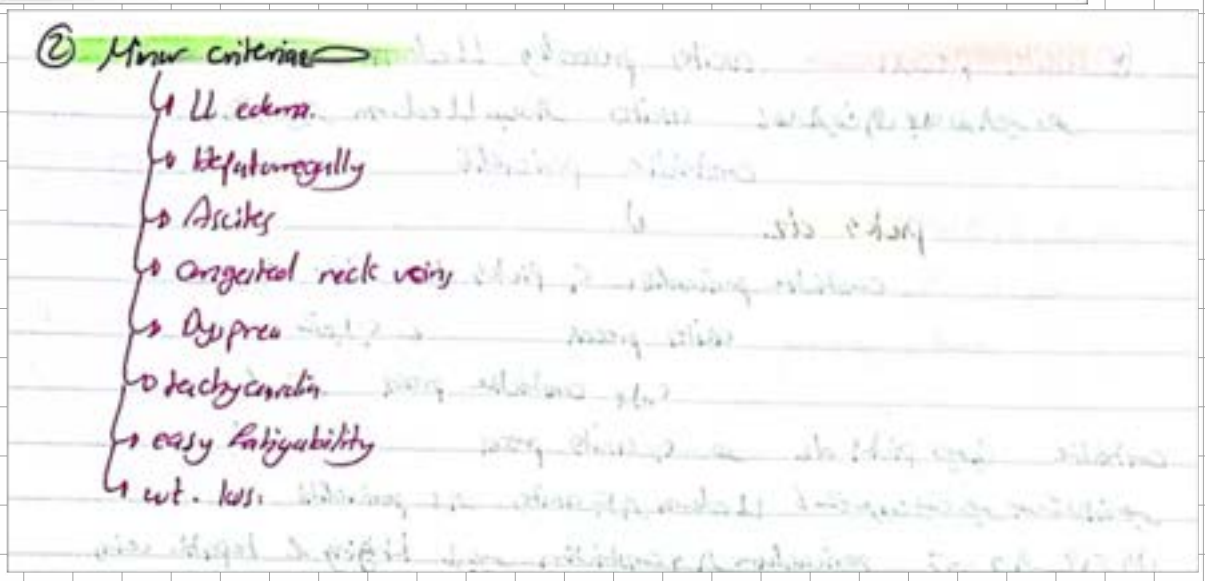

- Ivabradine :- funny IF receptor inhibitor used in HT

alternative to β-blocker

- indications:- ① Contraindication of β-blocker
② Maximum dose of β-blocker but HR still >70

- Congenital heart dz.:-

⊛ Complex congenital heart disease [5 Ts] :- cyanotic.

بنولد الطفل بـ cyanosis

① Tetralogy of Fallot :-

pulmonary stenosis - Rt ventricular hypertrophy - overriding aorta - ventricular septal defect

② Tricuspid atresia :- يعني ما في tricuspid valve

- حيكون في VSD أو ASD عشان يعيش.

③ Truncus arteriosus :- بدل ما يطلع aorta و pulmonary

يطلع أنبوب واحد وبنقدم لإثنين فالدم بصير له mixing ← cyanotic

④ Transposition of great atresia (TGA) :-

يعني الـ aorta طالع من الـ Rt. والـ pulmonary من الـ Lt عشان يعيش

لازم يكون ASD أو VSD.

⑤ Total anomalous pulmonary venous drainage (TAPVD) :-

إنه الـ 4 pulmonary veins يصبوا في مكان آخر غير الـ Lt atrium.

⊛ Cyanosis → bluish discoloration of skin and mucous membranes due to increased amount of reduced Hb more than 5gm/dm.