# C ENRTAL NERVOUS SYSTEM RADIOLOGY

DR. MOHAMAD MATAR

# Skull fractures

- ❑ closed traumatic brain injury
- ❑ penetrating brain injury

***Skull fractures can be broadly divided in a variety of way:***

- anatomically
  - base of skull
  - skull vault
- associated with overlying wound
  - open (compound)
  - closed
- degree of displacement
  - undisplaced
  - depressed (5-10 mm)
- number of fracture lines/fragments
  - linear
  - comminuted

- Diagnosis :
  - X-ray
  - CT.




R

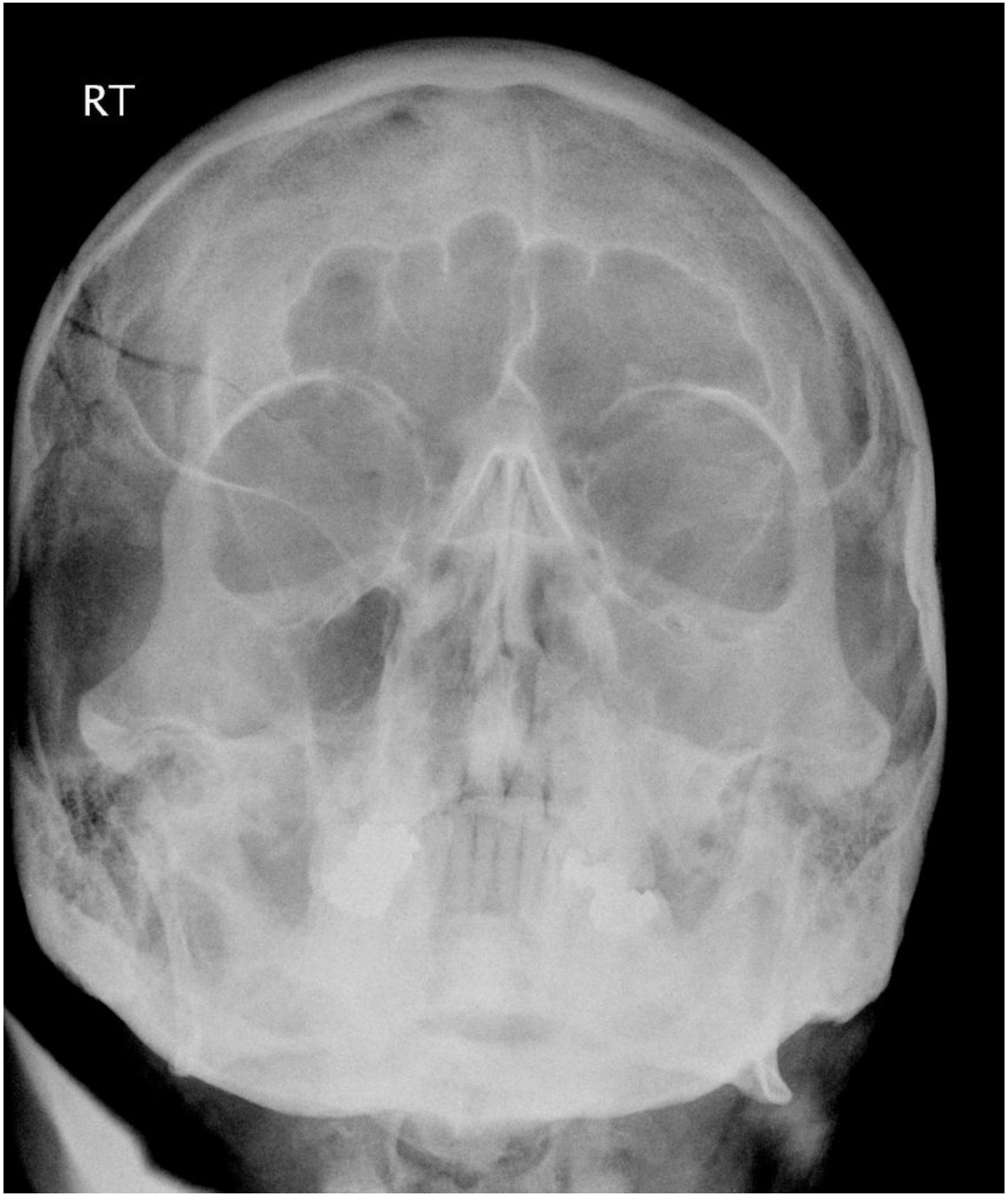
RT



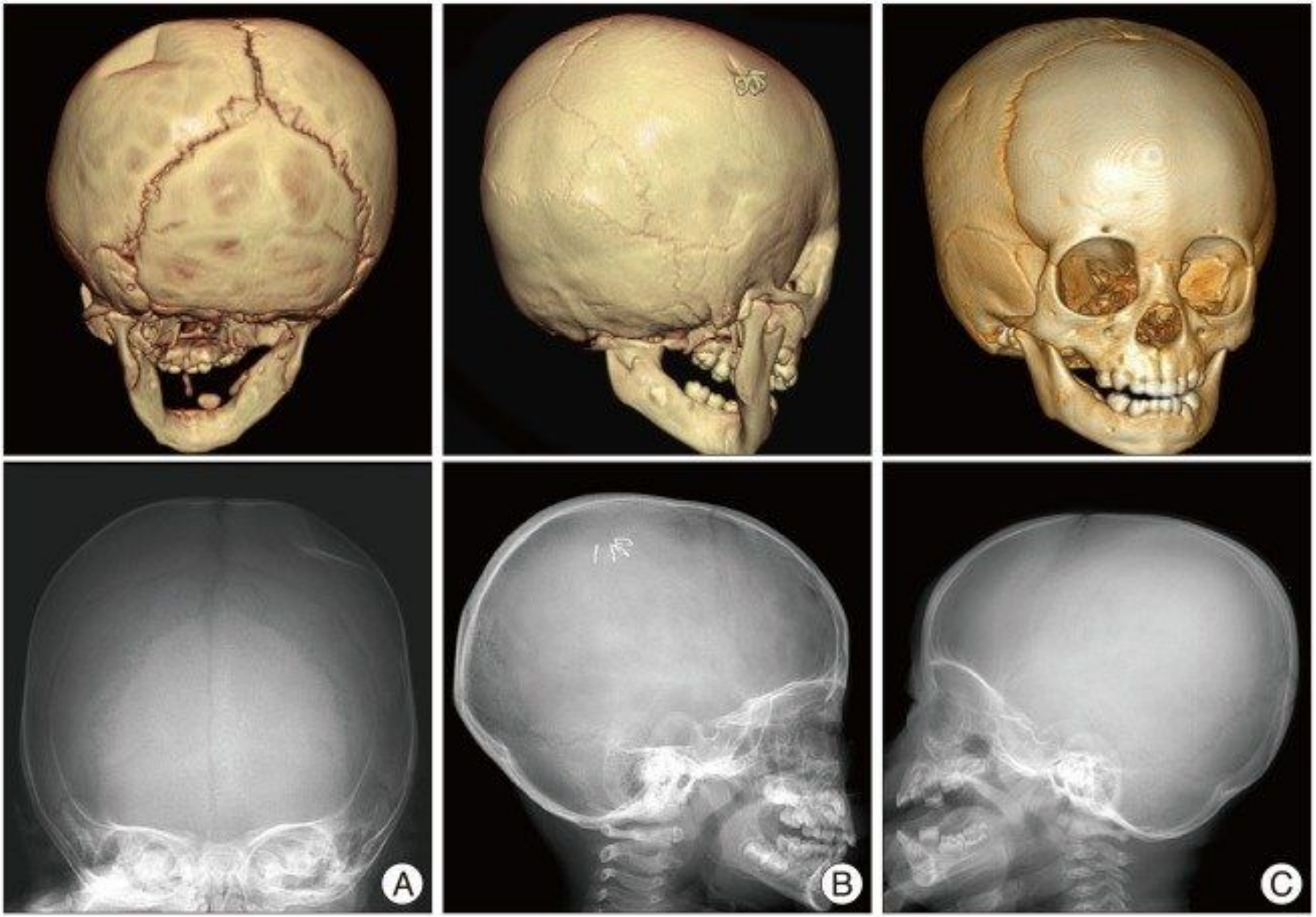
A
B
C

- **presentation**head injury following impact trauma, e.g. fall, RTC
- symptoms associated with underlying injury
  - extradural hemorrhage
  - subdural hemorrhage
  - subarachnoid hemorrhage
- there may be an associated base of skull injury
  - CSF rhinorrhea
  - Battle sign (bruising over mastoid process)
  - raccoon eyes

Battle sign : middle cranial fossa fracture.
result of extravasation of blood along the path of the posterior auricular artery



# Raccoon Eyes

- blood from skull fracture seeps into the soft tissue around the eyes.
- Raccoon eyes may be accompanied by Battle's sign, an ecchymosis behind the ear.
- If bilateral, it is highly suggestive of basilar skull fracture



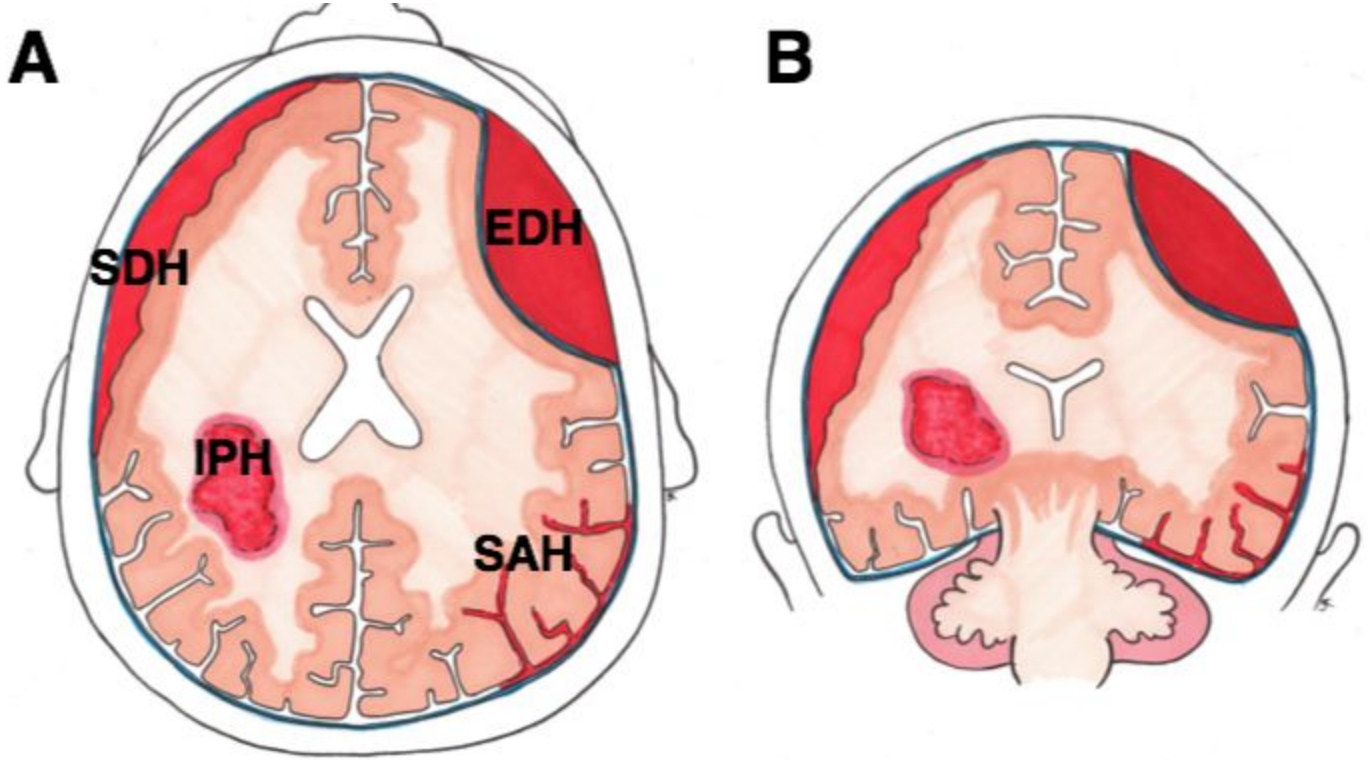
A
SDH
EDH
IPH
SAH
B

# intra axial haematoma

- HT related ( mostly basal ganglia).
- Vascular anomaly.
- Lesions ( benigen / malignanat.
- Trauma.

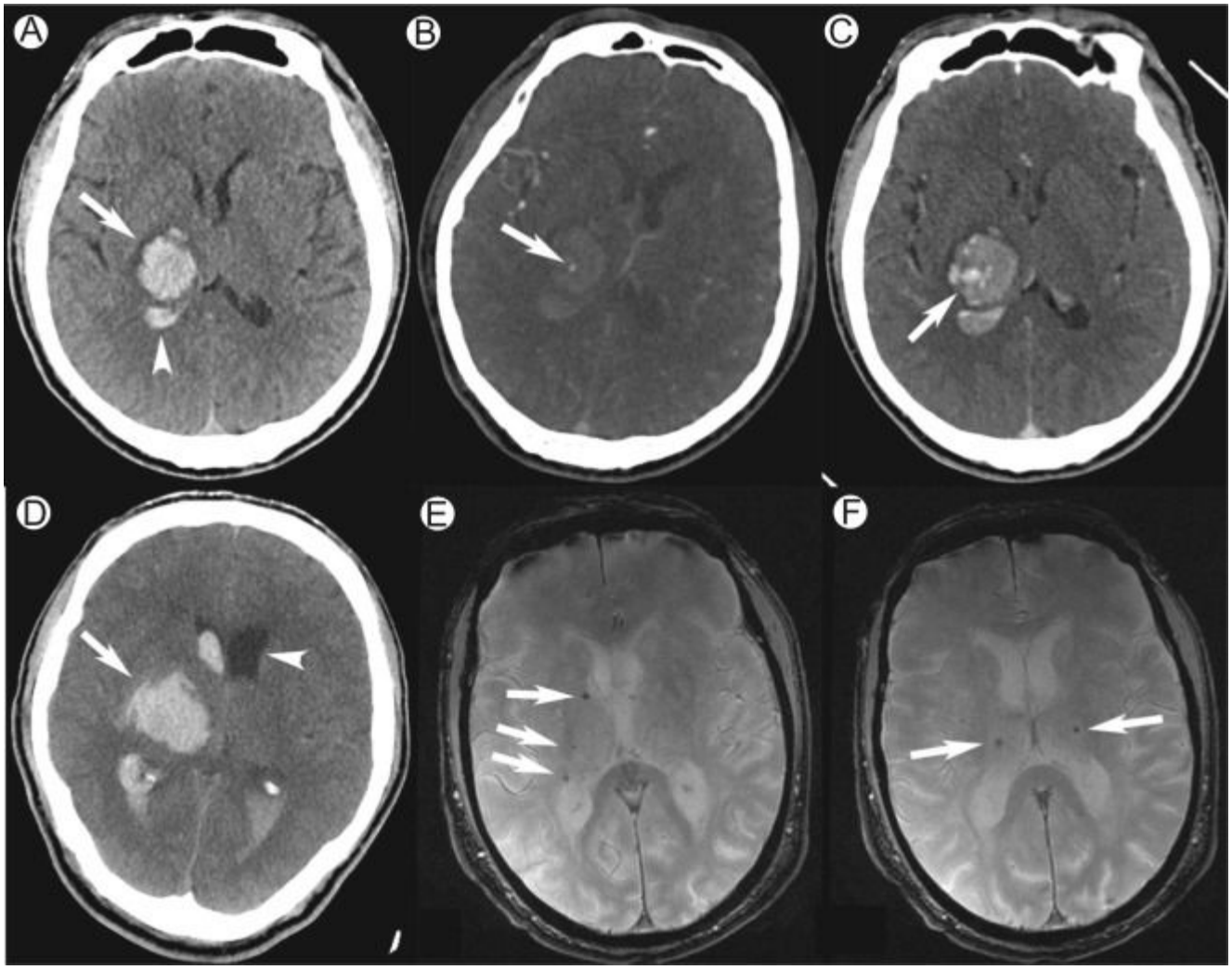
A
B
C
D
E
F



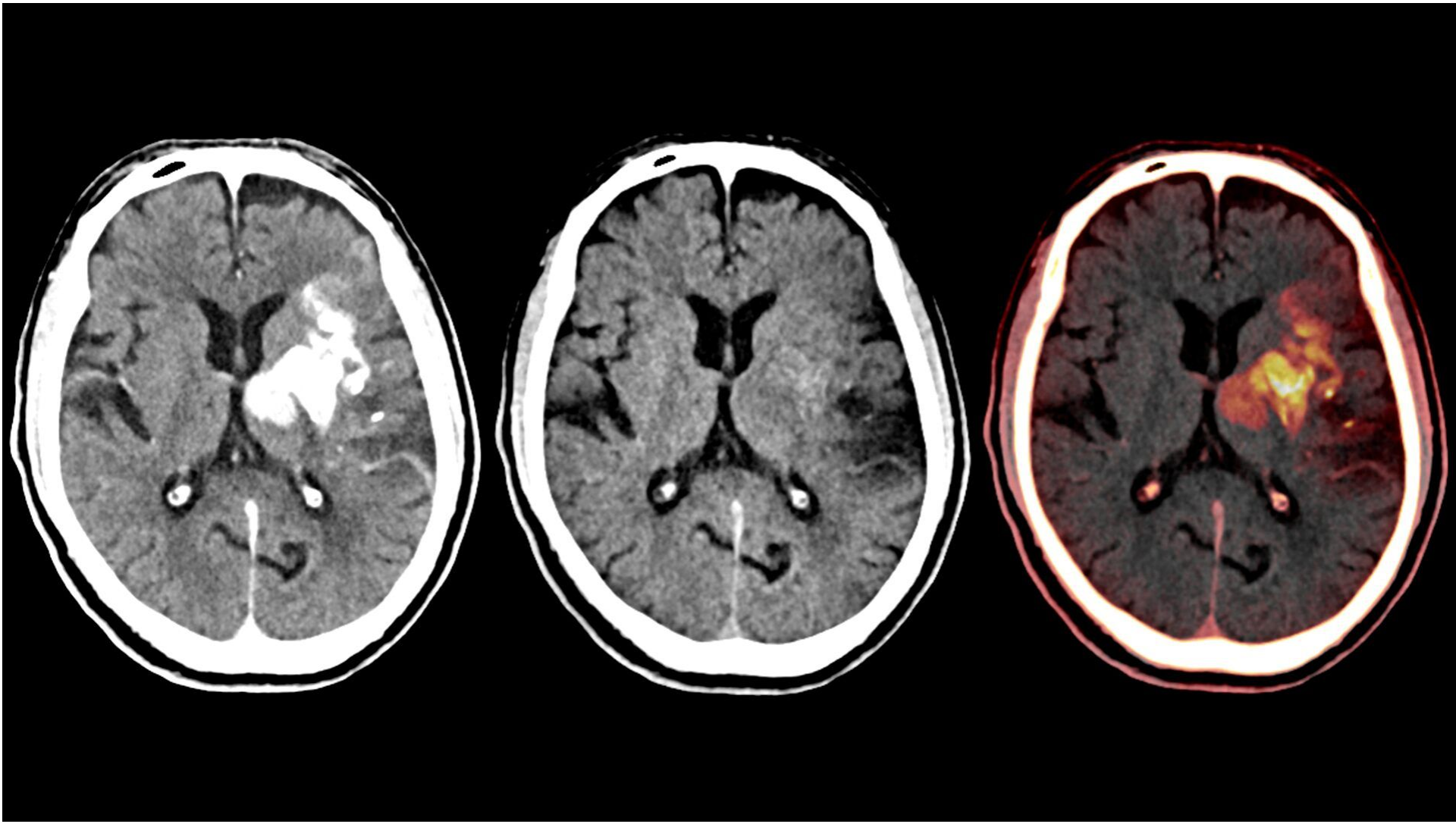

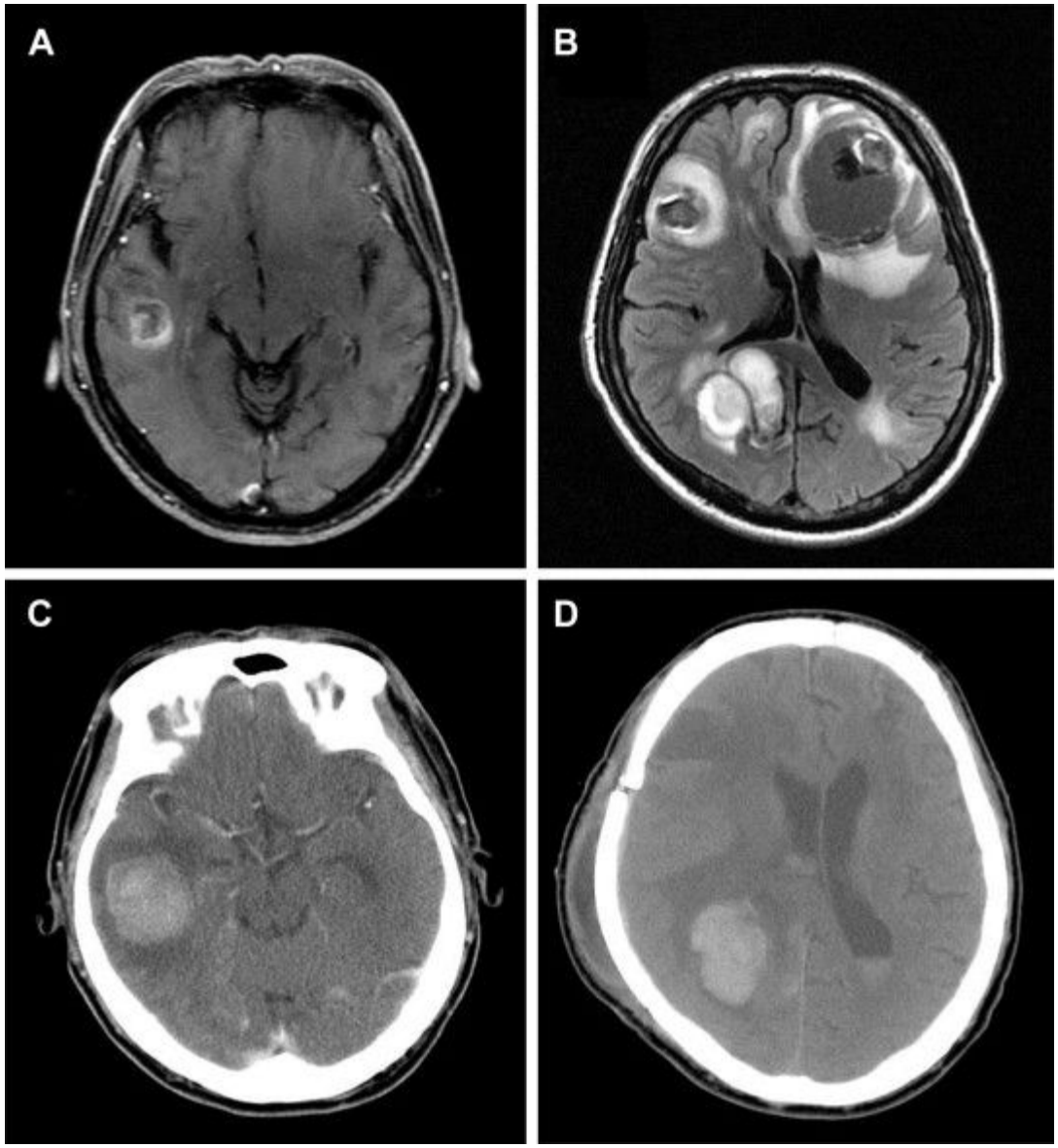


hemorrhagic brain tumors

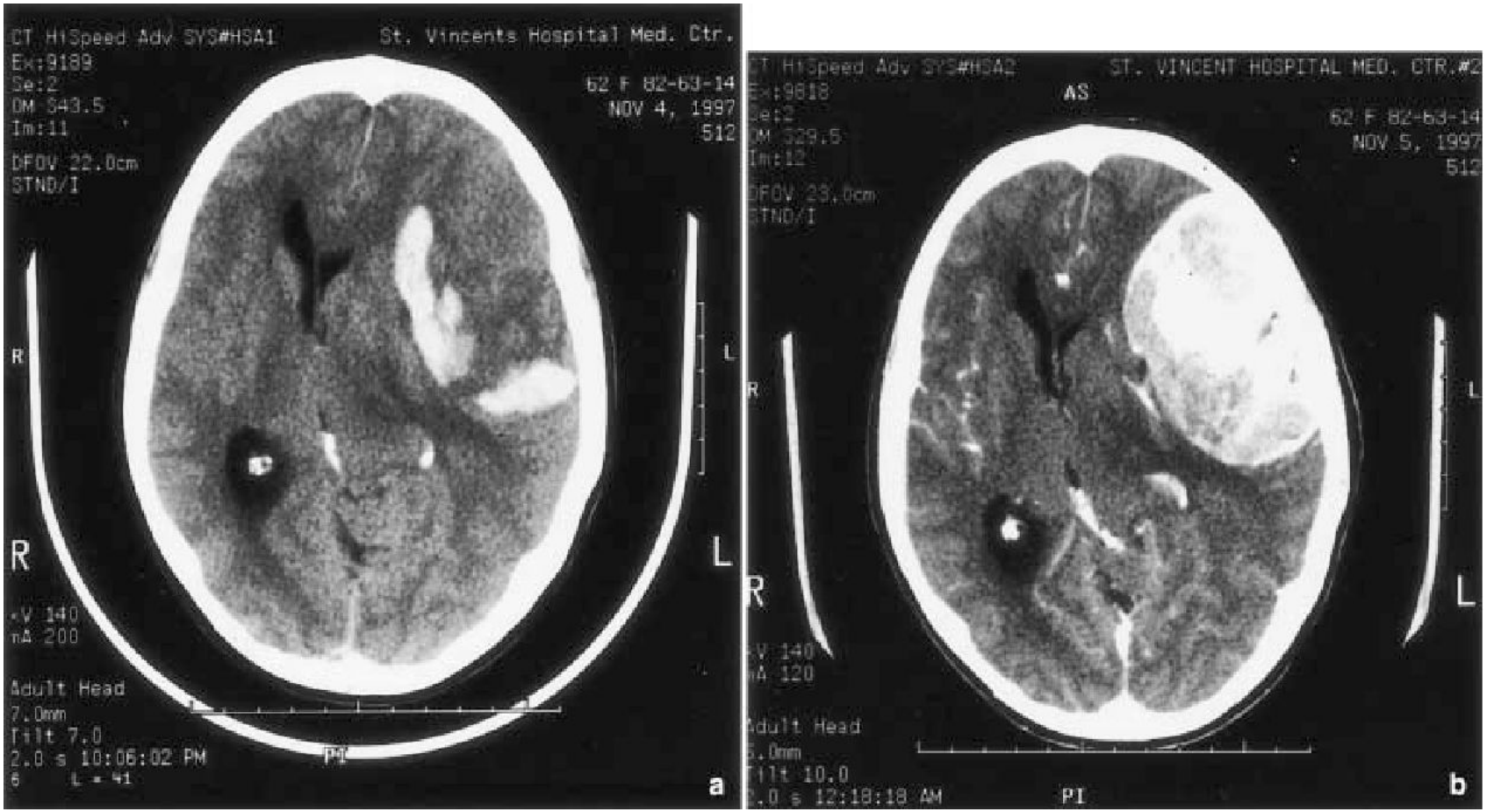


hemorrhagic brain tumors

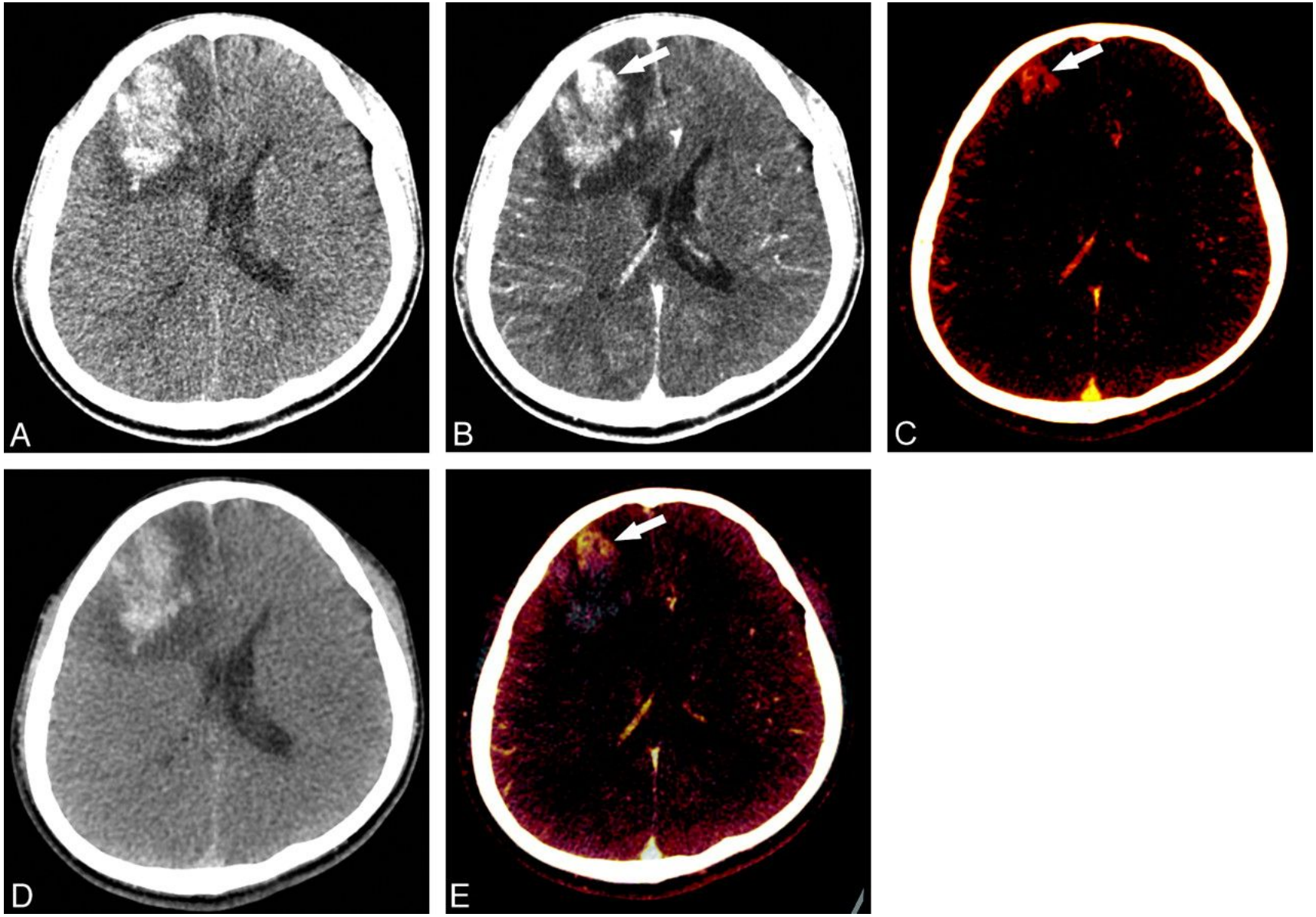
A
B
C
D
E

# Extra axial  haematoma.

- extradural hemorrhage
- subdural hemorrhage
- subarachnoid hemorrhage

# Subdural hematomas

- Subdural hematomas are interposed between the dura and arachnoid.
- Typically crescent-shaped.
- They are usually more extensive than extradural hematomas.
- In contrast to extradural hemorrhage, SDH is not limited by sutures but are limited by dural reflections, such as the falx cerebri, tentorium, and falx cerebelli.




acute SDH causing sub-falcine herniation



bilateral chronic subdurals



isodense left SDH


2
1
(1) Length: 16.02 cm
(2) Length: 1.56 cm, Ratio 1/2: 10.26

# Extradural hemorrhage

- Also known as an epidural hematoma, is a collection of blood that forms between the inner surface of the skull and outer layer of the dura, which is called the endosteal layer.
- They are usually associated with a history of head trauma and frequently associated skull fracture.
- The source of bleeding is usually arterial, most commonly from a torn middle meningeal artery.

- EDHs are typically biconvex in shape and can cause a mass effect with herniation. They are usually limited by cranial sutures, but not by venous sinuses.



typical bi-convex shape

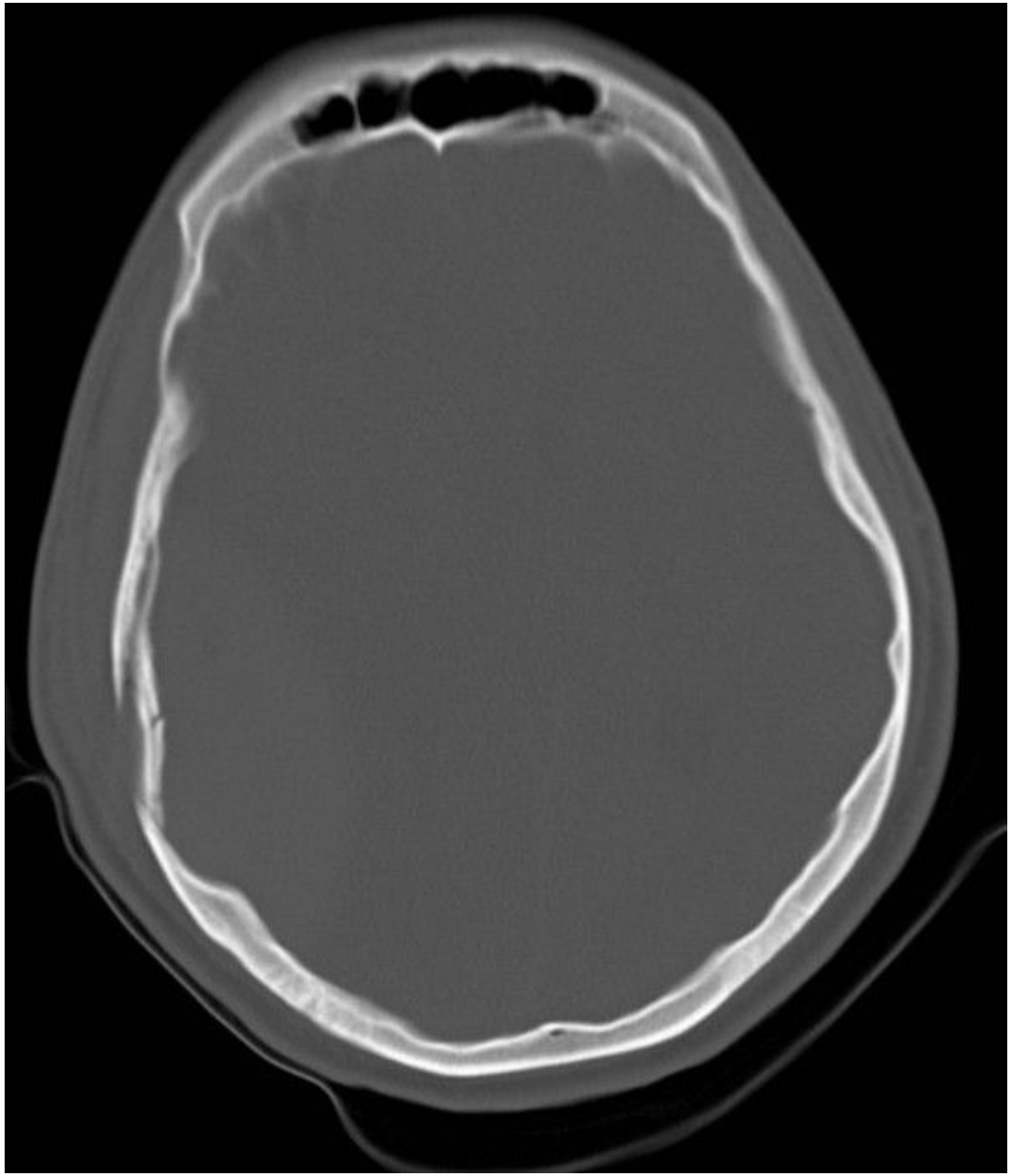



massive EDH

# Subarachnoid hemorrhage

- Risk factors include [2]:
  - family history
  - hypertension
  - heavy alcohol consumption
  - abnormal connective tissue
    - autosomal dominant polycystic kidney disease
    - Ehlers-Danlos disease type IV
    - Marfan syndrome
    - neurofibromatosis type 1

## *Causes include [1]:*

- trauma
- spontaneous
  - ruptured berry aneurysm: 85% [1]
  - perimesencephalic hemorrhage: 10% [4]
  - arteriovenous malformation
  - cerebral amyloid angiopathy
  - ruptured mycotic aneurysm
  - reversible cerebral vasoconstriction syndrome
  - dural arteriovenous fistula
  - spinal arteriovenous malformation
  - venous infarction [1]
  - intradural arterial dissection
  - pituitary apoplexy
  - cocaine use
  - cerebral vasculitis [6]
  - anticoagulation therapy [9]

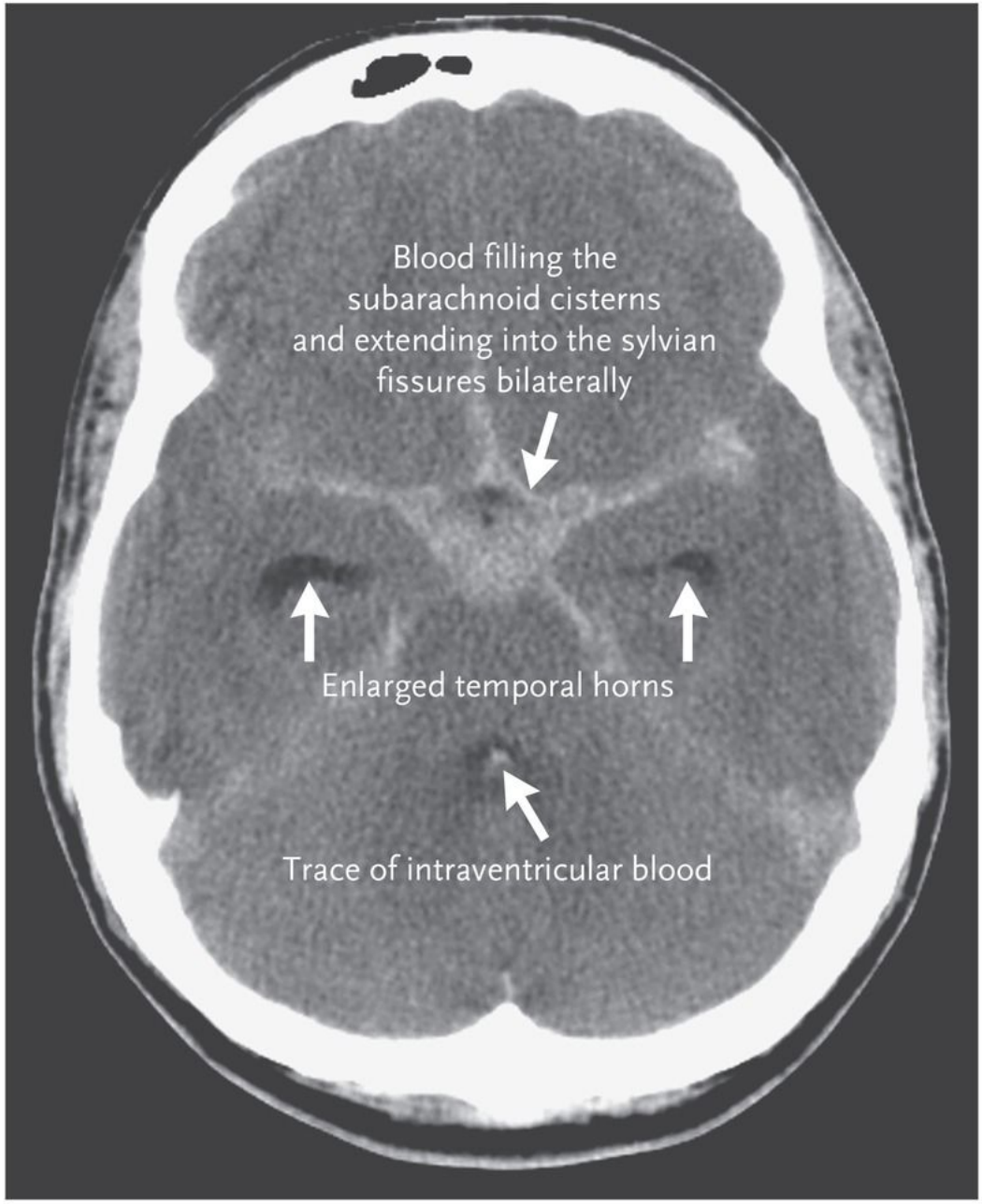
Blood filling the
subarachnoid cisterns
and extending into the sylvian
fissures bilaterally
Enlarged temporal horns
Trace of intraventricular blood

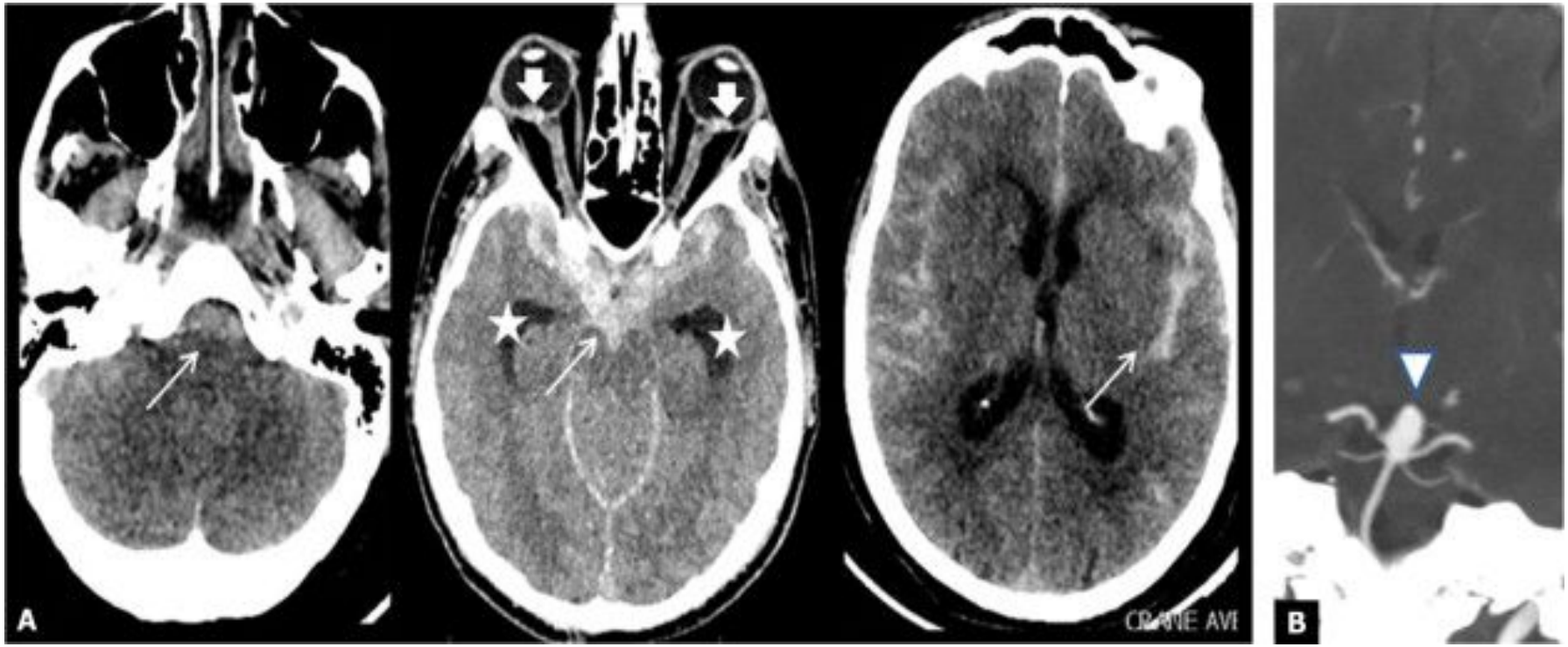
A
B

# ACUTE CVA

- Stroke is a leading cause of death and disability worldwide. Imaging plays a critical role in evaluating patients suspected of acute stroke and transient ischemic attack (TIA), especially prior to initiating treatment
- The primary goal of imaging patients with acute stroke symptoms is to distinguish between hemorrhagic and ischemic stroke.

# WHAT imaging technique

- NCCT.
- Contrast CT.
- MRI .
- MRI & MRA.
- perfusion CT/MRI.

- Sensitivity of imaging modality is variable and depends in time window between imaging and onset of symptoms , location of affected area ( low sensitivity of CT in posterior fosse) and size of area involved. But as general role :
  - Non contrast CT has low sensitivity in acute stroke ~35%.
  - MRI has higher sensitivity for acute stroke when using DWI reaching 99% .

| Imaging characteristics | CT | MRI |
|---|---|---|
| Availability in the acute setting (0–6 hours) | ++ | – |
| Rapid image acquisition | ++ | + |
| Lack of vulnerability to motion artifact | + | – |
| Accessibility for patients with monitors and/or ventilators | ++ | – |
| Feasibility and safety for patients with metallic implants (pacemakers, implantable defibrillators) | ++ | – |
| Lower cost | + | – |
| Lack of ionizing radiation | – | ++ |
| Renal toxicity associated with contrast administration | + | + |
| Time for post-processing angiography and perfusion imaging | – | – |
| Sensitivity to lacunar and posterior fossa infarcts | – | ++ |
| Differentiation between acute and chronic ischemia | – | ++ |
| Ability to assess causes of ICH or SAH while in the scanner | + | + |
| Detection of chronic hemorrhage including microbleeds | – | + |

- The accuracy of MRI techniques for detection of intracranial hemorrhage in the acute stroke setting (within 6 hours) has been reported as likely equivalent to NCCT .
- But T2*-weighted sequences (including gradient-recalled echo [GRE] and susceptibility-weighted imaging [SWI] sequences) have superior accuracy in the detection of chronic microhemorrhages

- NCCT is the accepted standard-of-care imaging modality for exclusion of intracranial hemorrhage and has been incorporated in the inclusion criteria in randomized clinical trials evaluating the efficacy of IV thrombolysis.
- NCCT is often referred to as the *"reference standard"* for detection of acute intracranial hemorrhage based on reports describing its accuracy with early CT scanners.

- The primary goals of imaging during the 0–4.5-hour time window are to exclude the presence of intracranial hemorrhage and assess the presence and extent of ischemic changes.
- The presence of intracranial hemorrhage (excluding microbleeds) is an absolute contraindication to administering IV thrombolytic therapy.

- Early signs of ischemia involving more than one-third of the middle cerebral artery (MCA) territory in the 0–6-hour time window have been associated with large infarcted regions, increased risk of hemorrhagic transformation, and poor outcomes, and thus constitute a relative contraindication to IV thrombolysis.

- NCCT is also used to assess for early signs of infarction, including :
  - loss of gray-white differentiation.
  - Sulcal effacement.
  - Hyperdense clot in the proximal vessels.

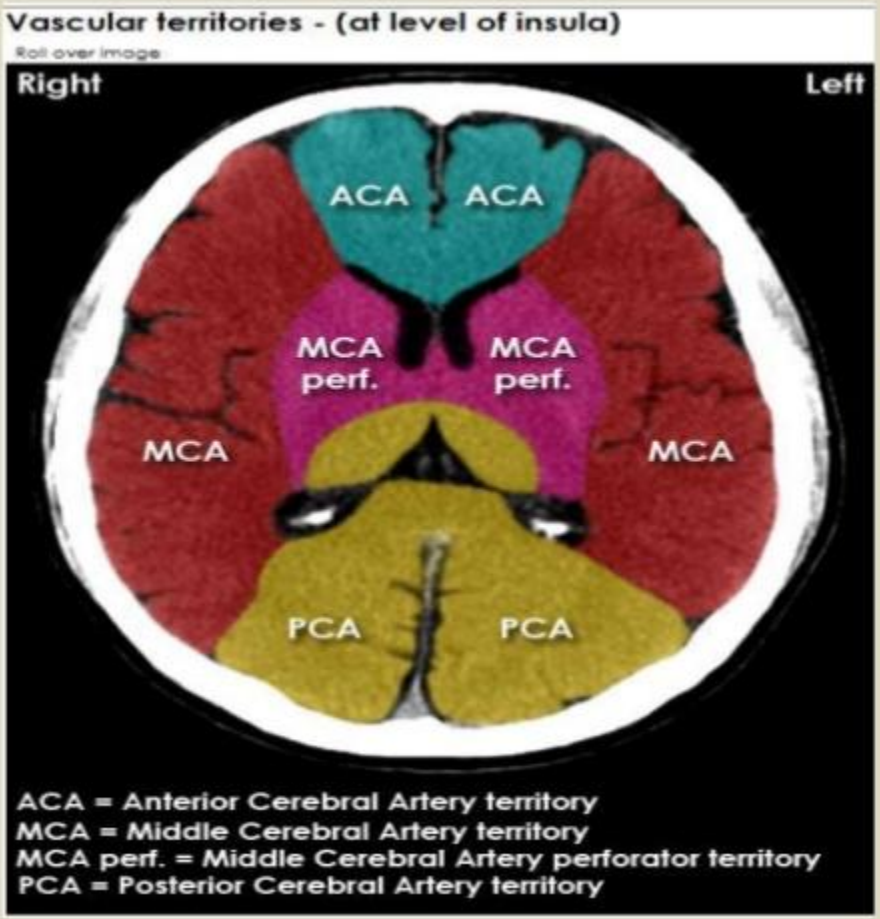


*Vascular territories - (at level of insula)*

***Multiple tiny perforating branches of the middle cerebral artery supply the region of the basal ganglia and insula***

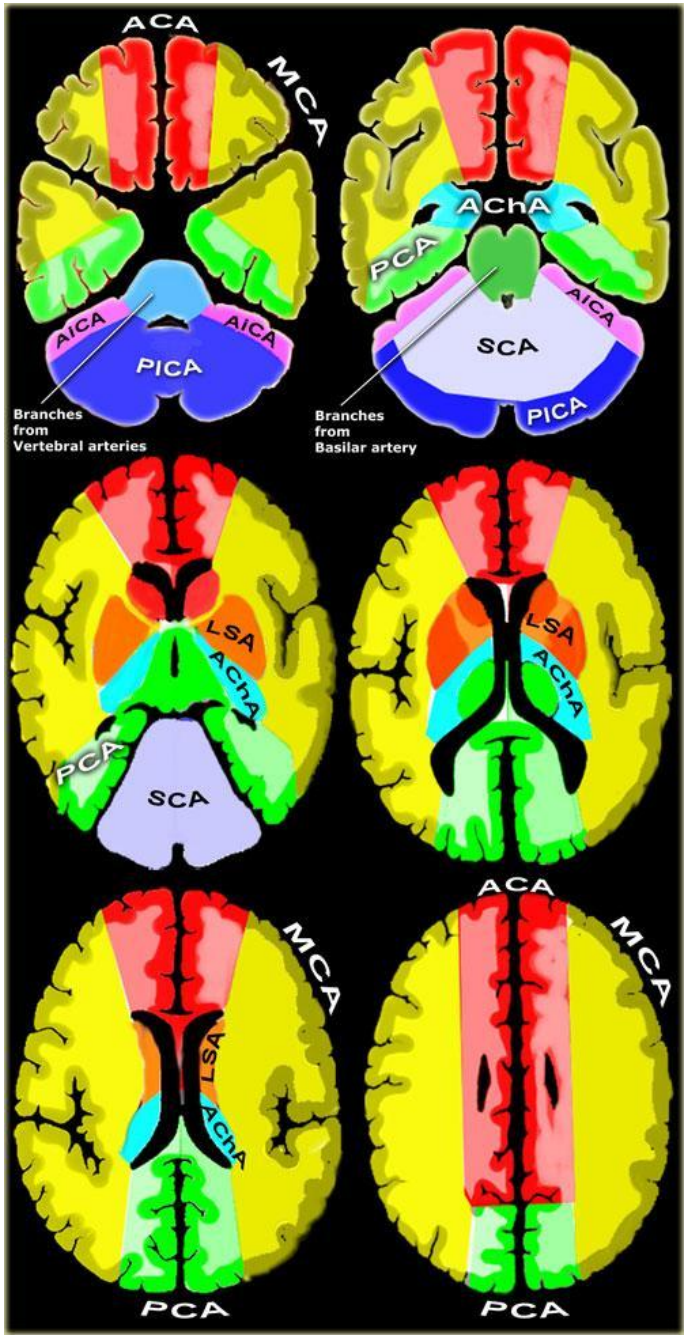
ACA
MCA
AICA
AICA
PICA
Branches from Vertebral arteries
AChA
PCA
AICA
SCA
PICA
Branches from Basilar artery
LSA
AChA
PCA
SCA
LSA
AChA
MCA
LSA
AChA
PCA
ACA
MCA
PCA

- The middle cerebral artery can be classified into 4 parts:[2]
  - **M1**: The *sphenoidal* segment, so named due to its origin and loose lateral tracking of the sphenoid bone. Although known also as the *horizontal* segment, this may be misleading since the segment may descend, remain flat, or extend posteriorly the anterior (dorsad) in different individuals. The M1 segment perforates the brain with numerous *anterolateral central* (lateral lenticulostriate) arteries, which irrigate the basal ganglia.
  - **M2**: Extending anteriorly on the insula, this segment is known as the *insular* segment. It is also known as the *Sylvian* segment when the opercular segments are included. The MCA branches may **bifurcate** or sometimes **trifurcate** into trunks in this segment which then extend into branches that terminate towards the cortex.
  - **M3**: The *opercular* segments and extends laterally exteriorly from the insula towards the cortex. This segment is sometimes grouped as part of **M2**.
  - **M4**: These finer *terminal* or *cortical* segments irrigate the cortex. They begin at the external of the Sylvian fissure and extend distally away on the cortex of the brain.

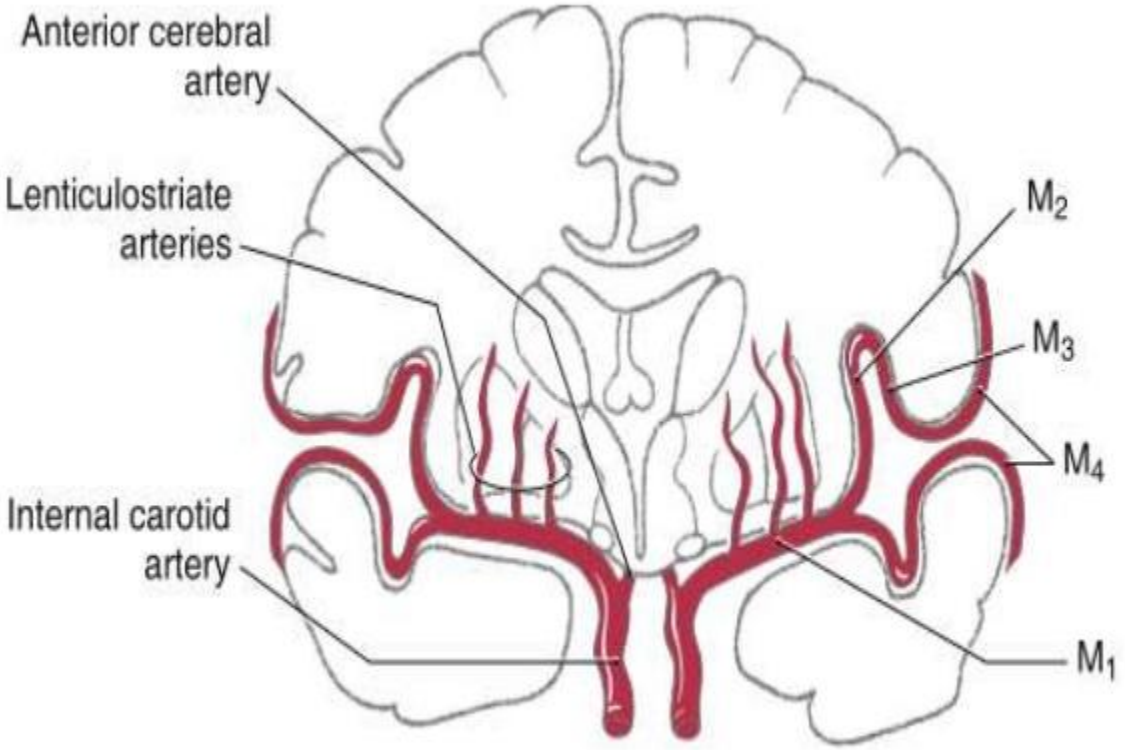
Anterior cerebral artery
Lenticulostriate arteries
Internal carotid artery
M2
M3
M4
M1

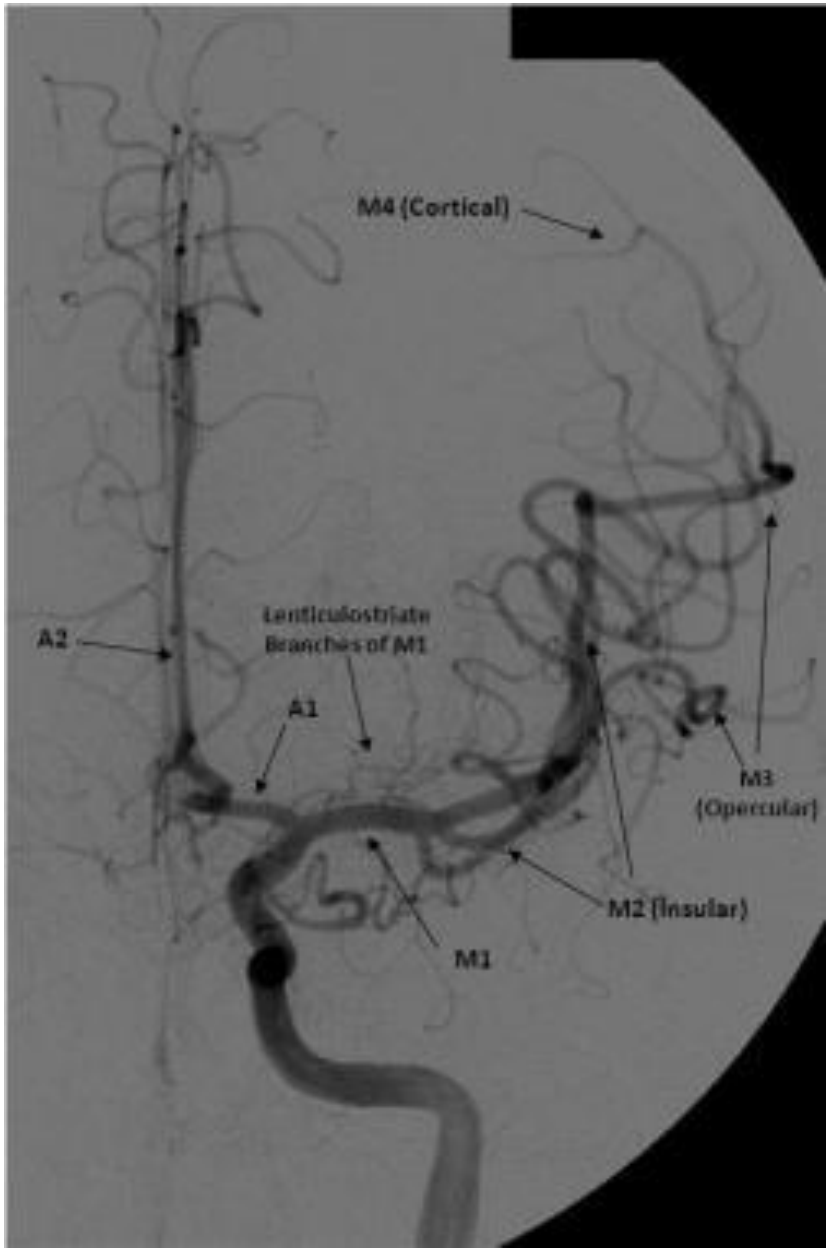
M4 (Cortical)
A2
Lenticulostriate
Branches of M1
A1
M3
(Opercular)
M2 (Insular)
M1

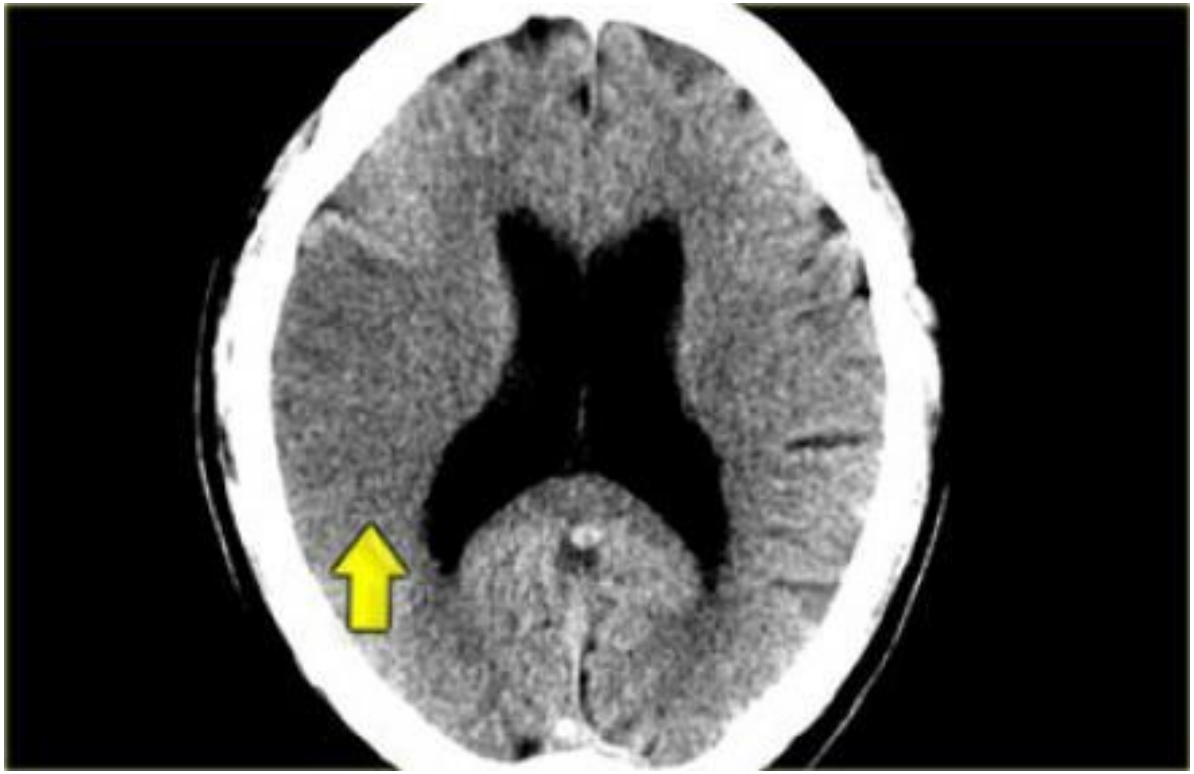

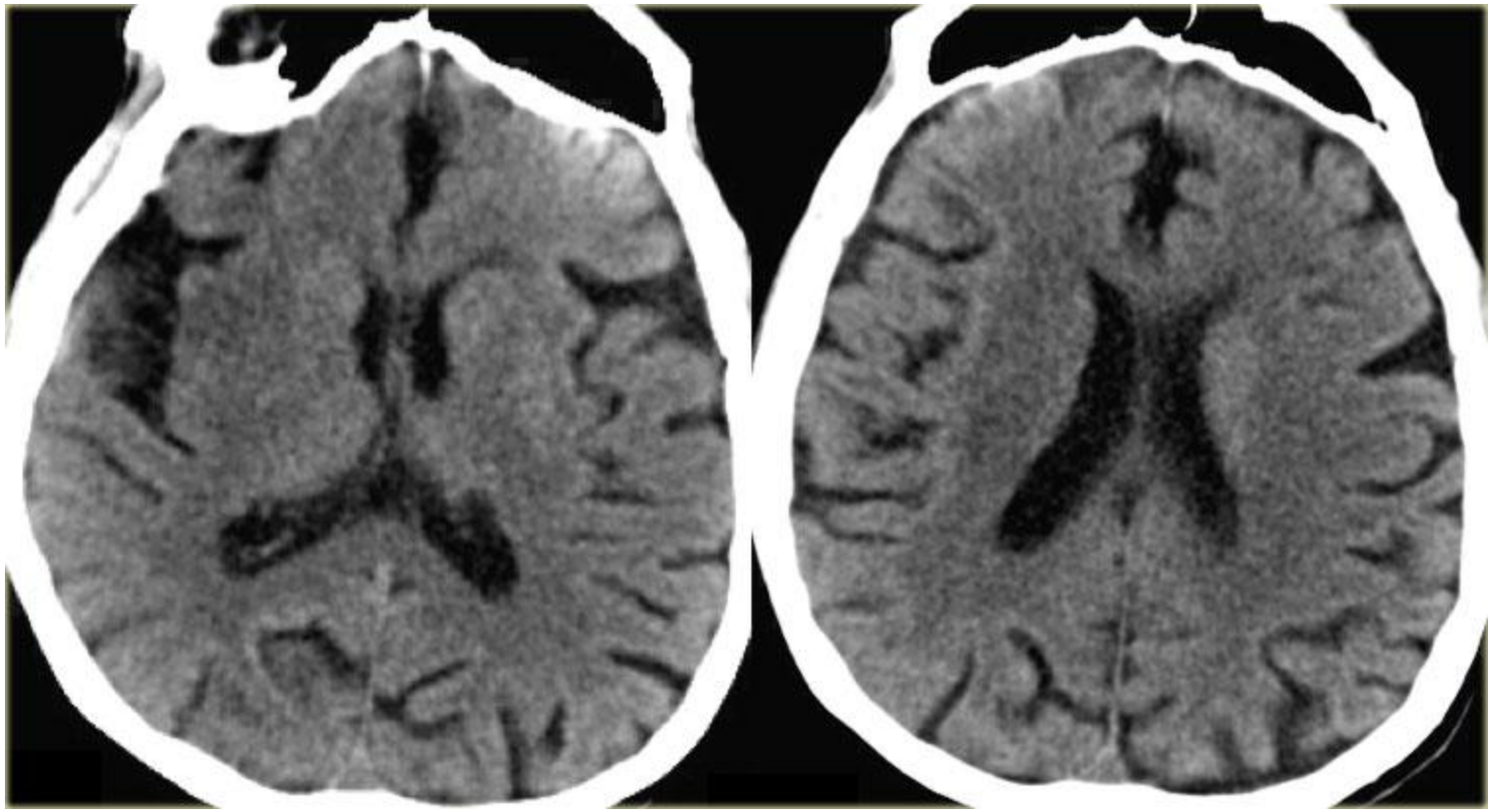

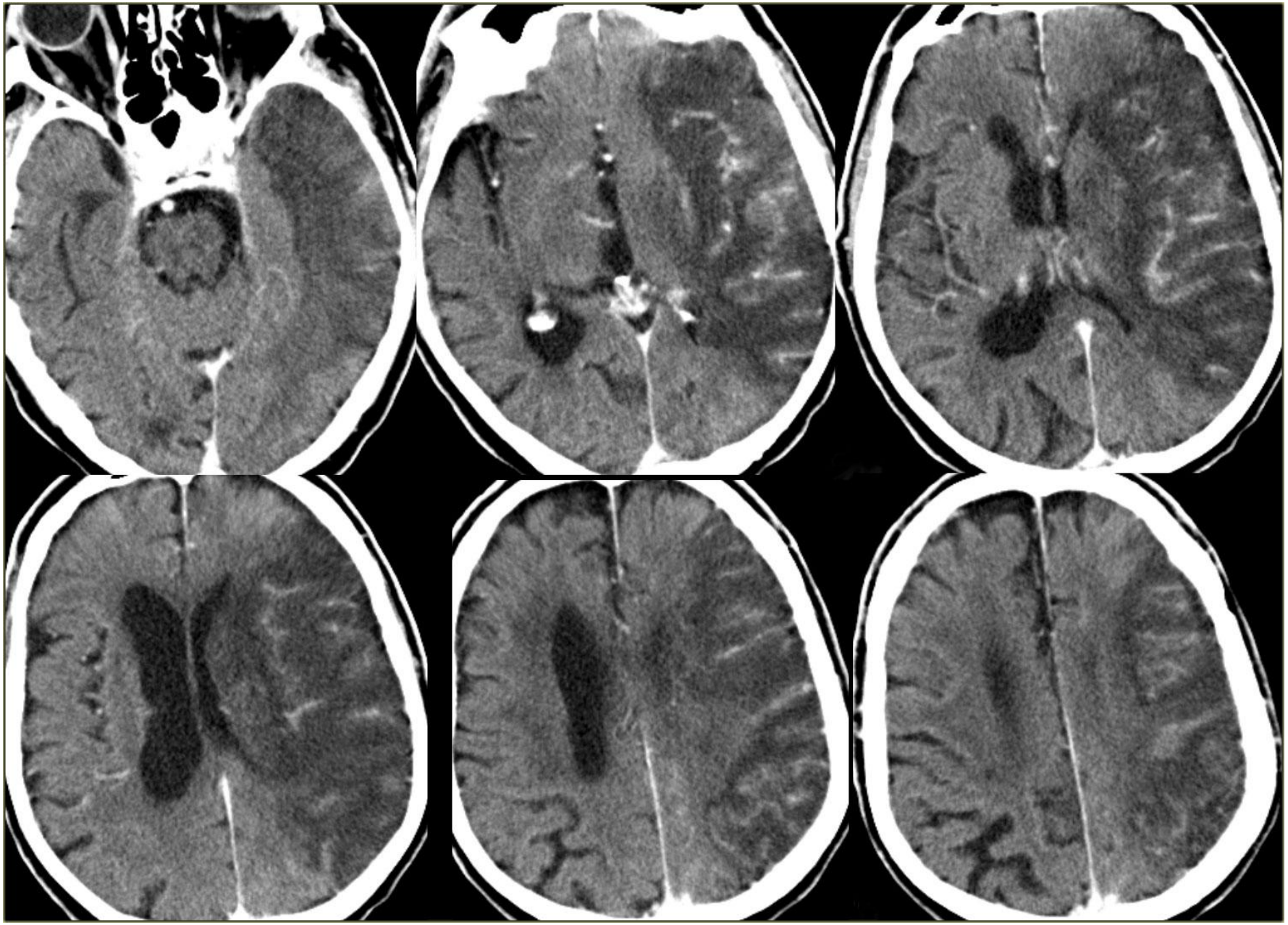

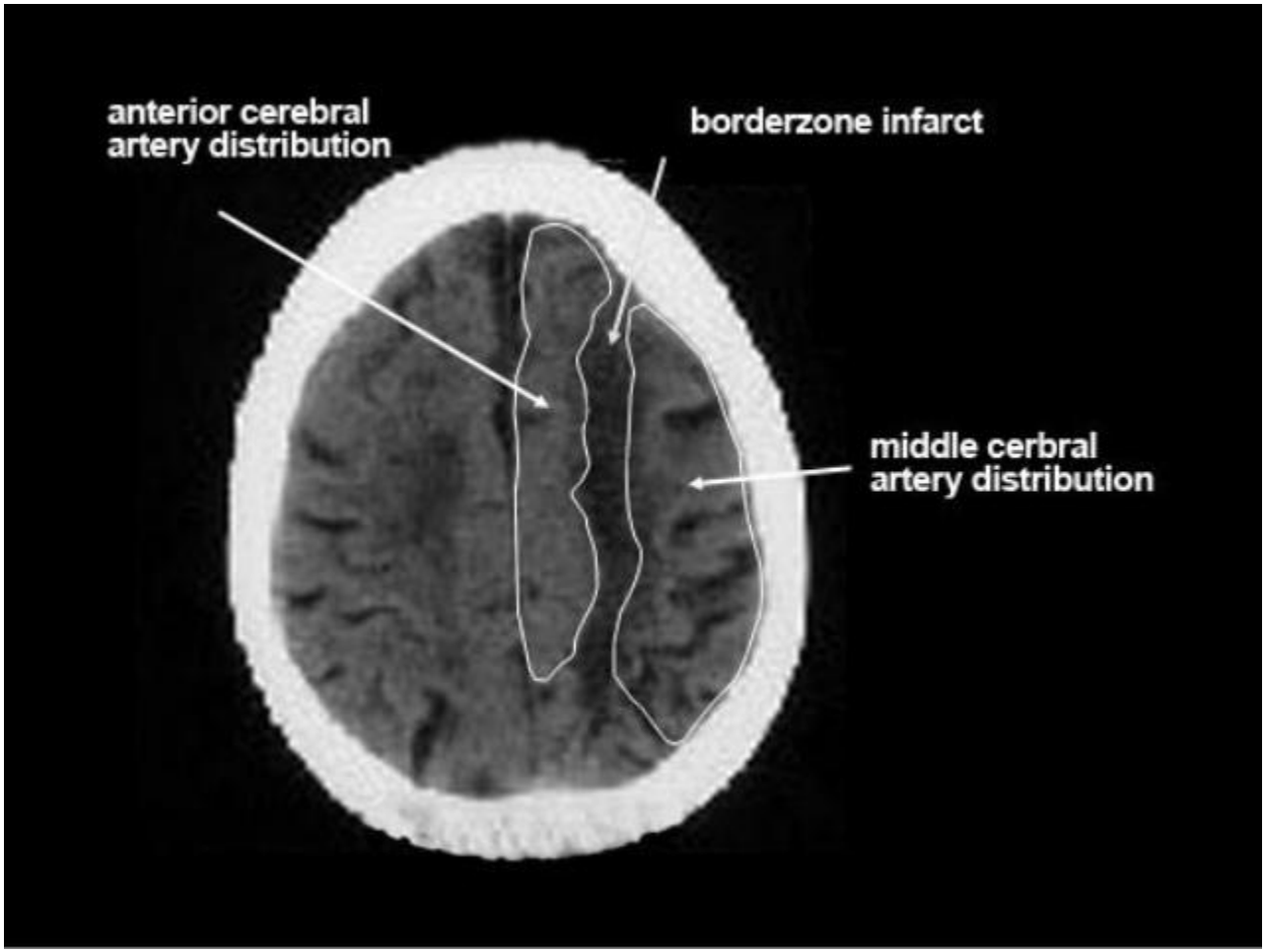
anterior cerebral
artery distribution
borderzone infarct
middle cerbral
artery distribution



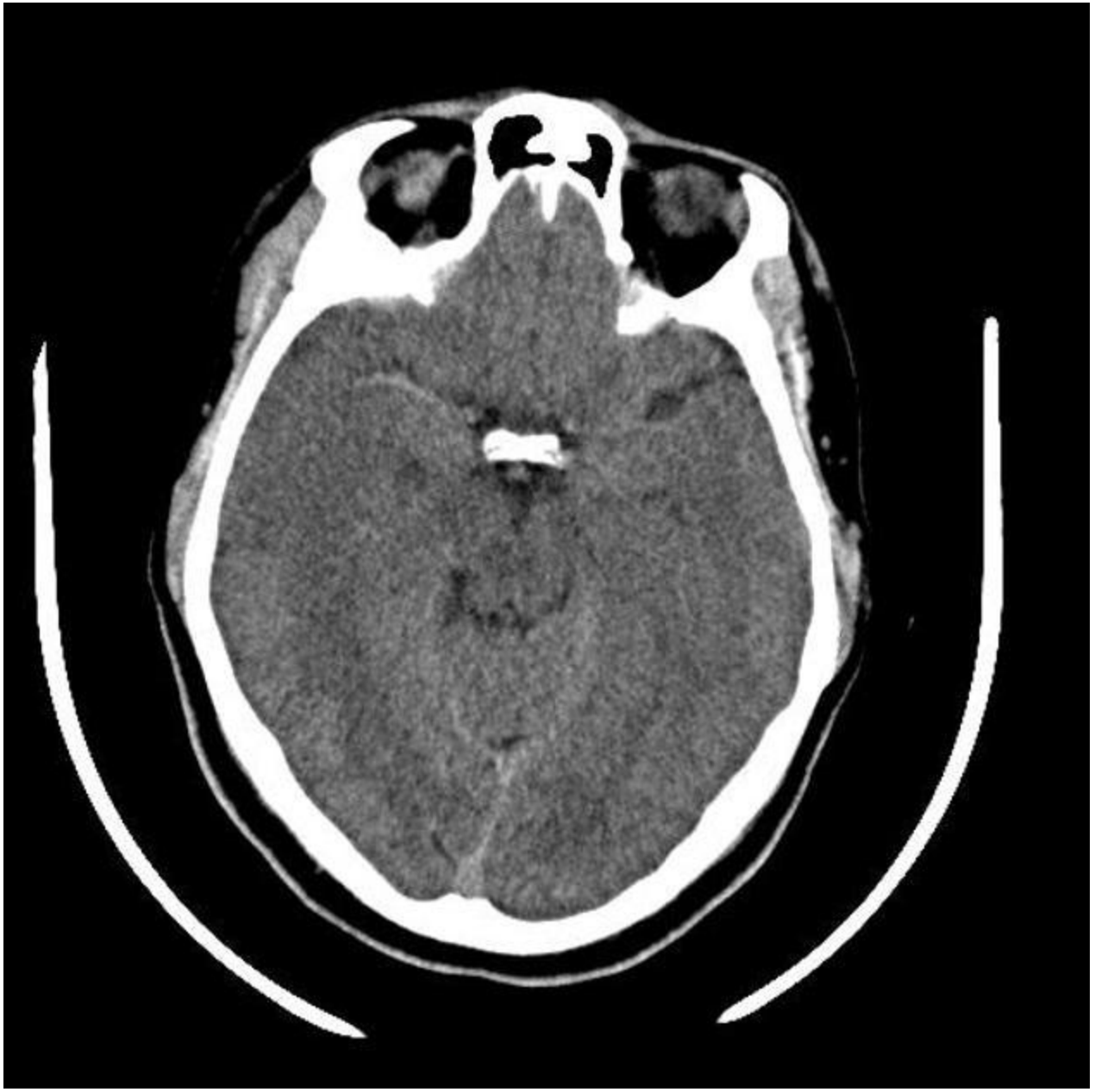



# Alberta stroke program early CT score (ASPECTS)

- **Scoring system**
- Segmental assessment of the middle cerebral artery (MCA) vascular territory is made and 1 point is deducted from the initial score of 10 for every region involved:
  - caudate
  - putamen
  - internal capsule
  - insular cortex
  - M1: "anterior MCA cortex," corresponding to frontal operculum
  - M2: "MCA cortex lateral to insular ribbon" corresponding to anterior temporal lobe
  - M3: "posterior MCA cortex" corresponding to posterior temporal lobe
  - M4: "anterior MCA territory immediately superior to M1"
  - M5: "lateral MCA territory immediately superior to M2"
  - M6: "posterior MCA territory immediately superior to M3"

- The initial paper [1] specifically referred to the internal capsule only involving the posterior limb, however, subsequent articles indicate any portion of the internal capsule may be included
- M1 to M3 are at the level of the basal ganglia
- M4 to M6 is at the level of the ventricles immediately above the basal ganglia

## MCA Alberta stroke program early CT score (ASPECTS)

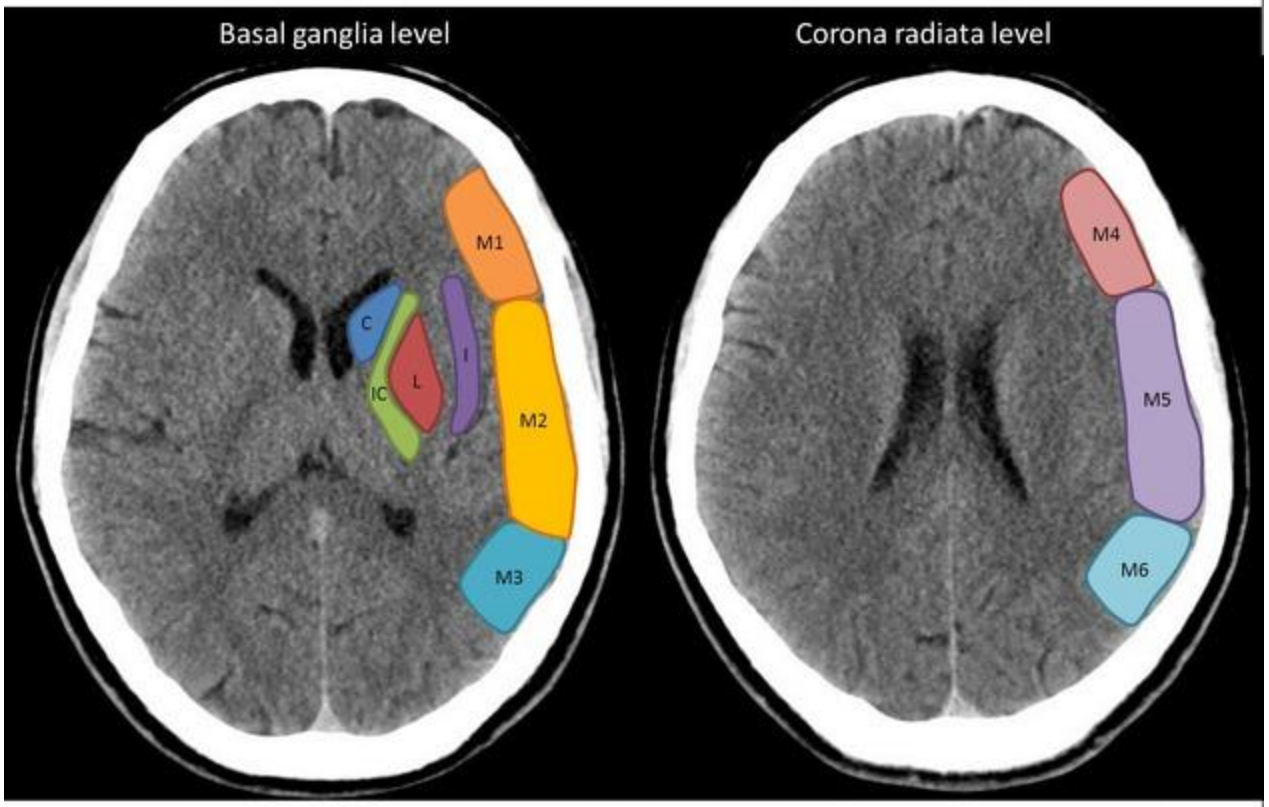


C: Caudate; IC: internal capsule; L: lentiform nucleus; I: Insular Cortex.

Osamah Alwalid
Radiopaedia.org

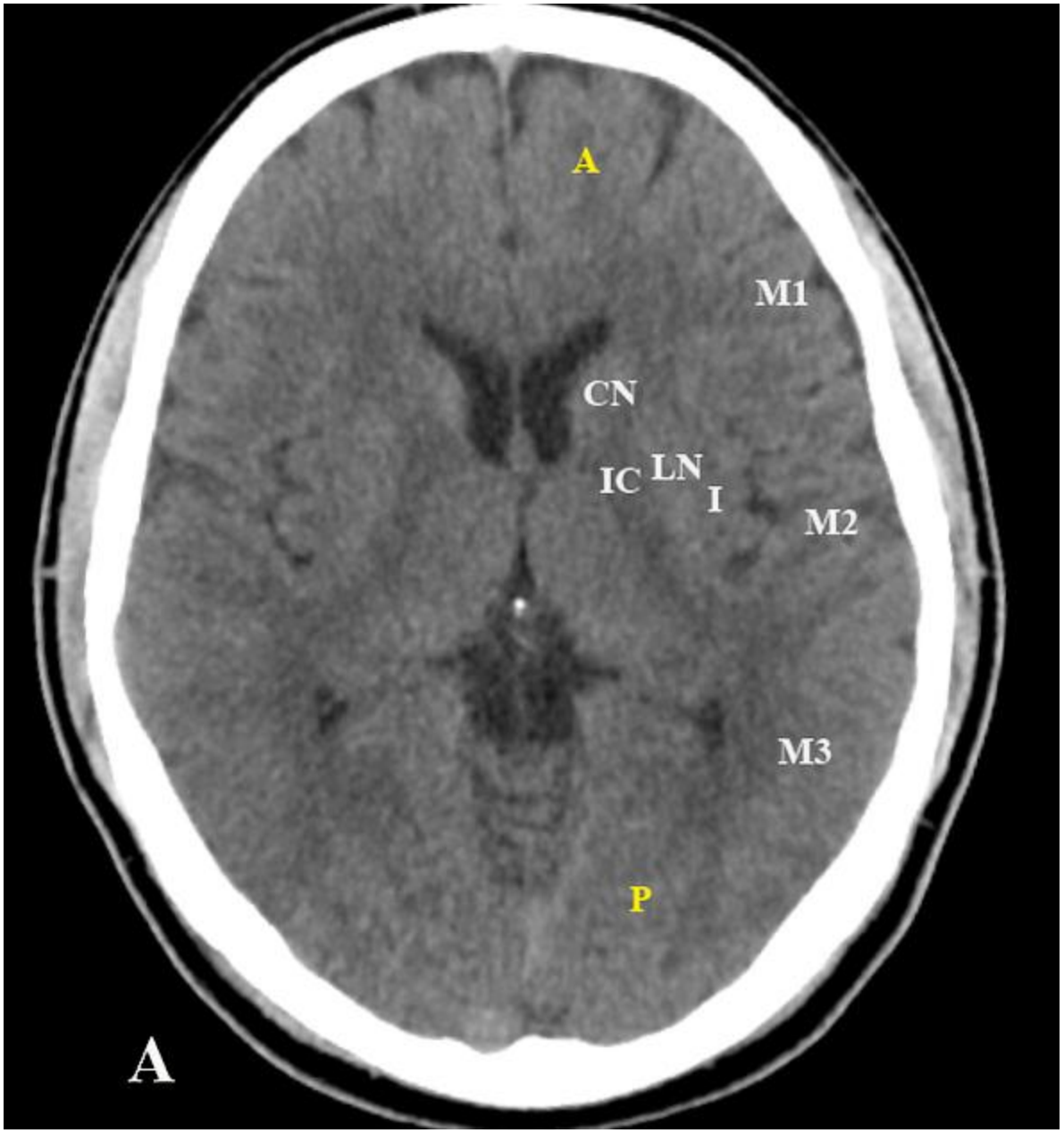
A
M1
CN
IC
LN
I
M2
M3
P
A

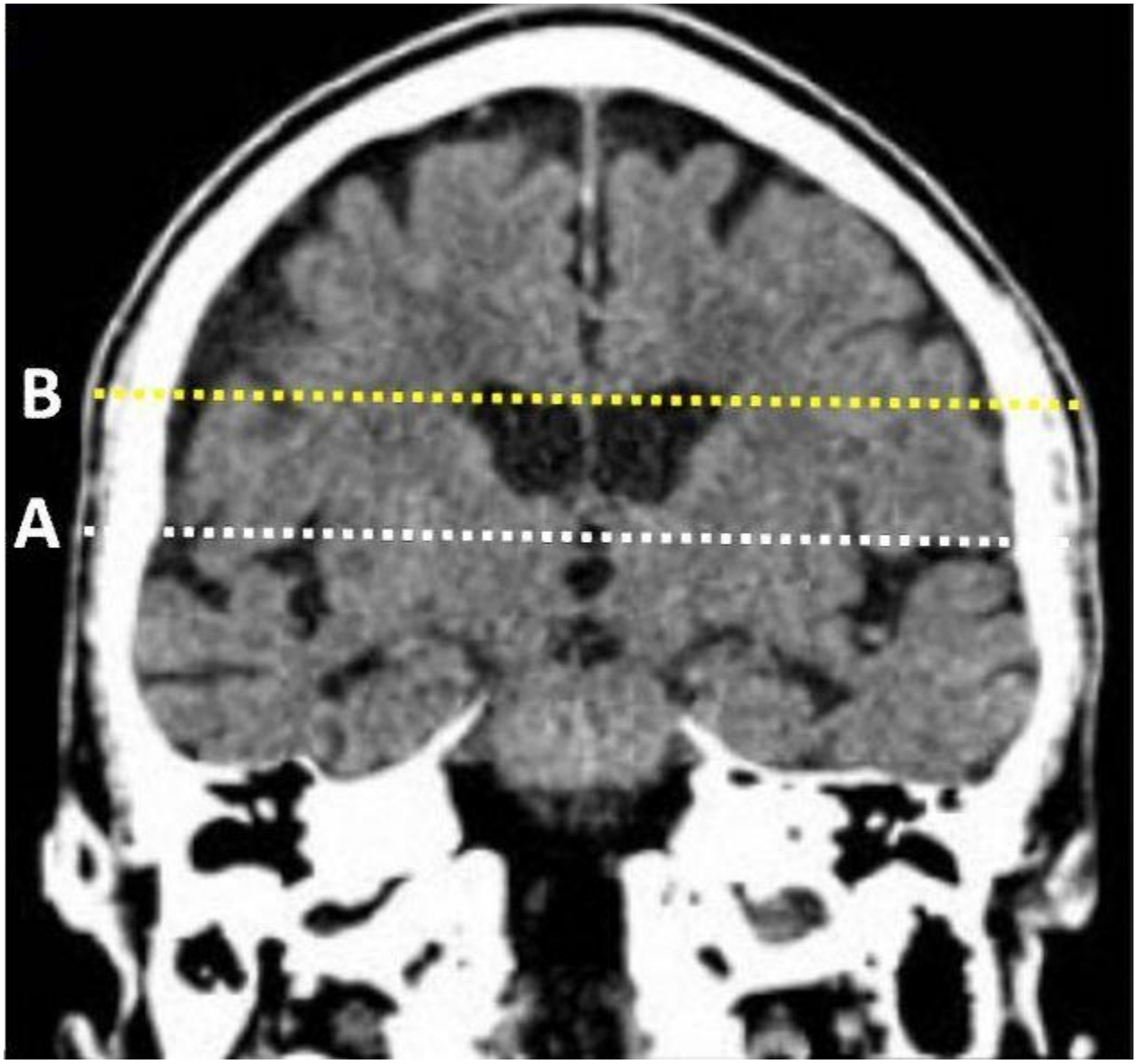
B
A

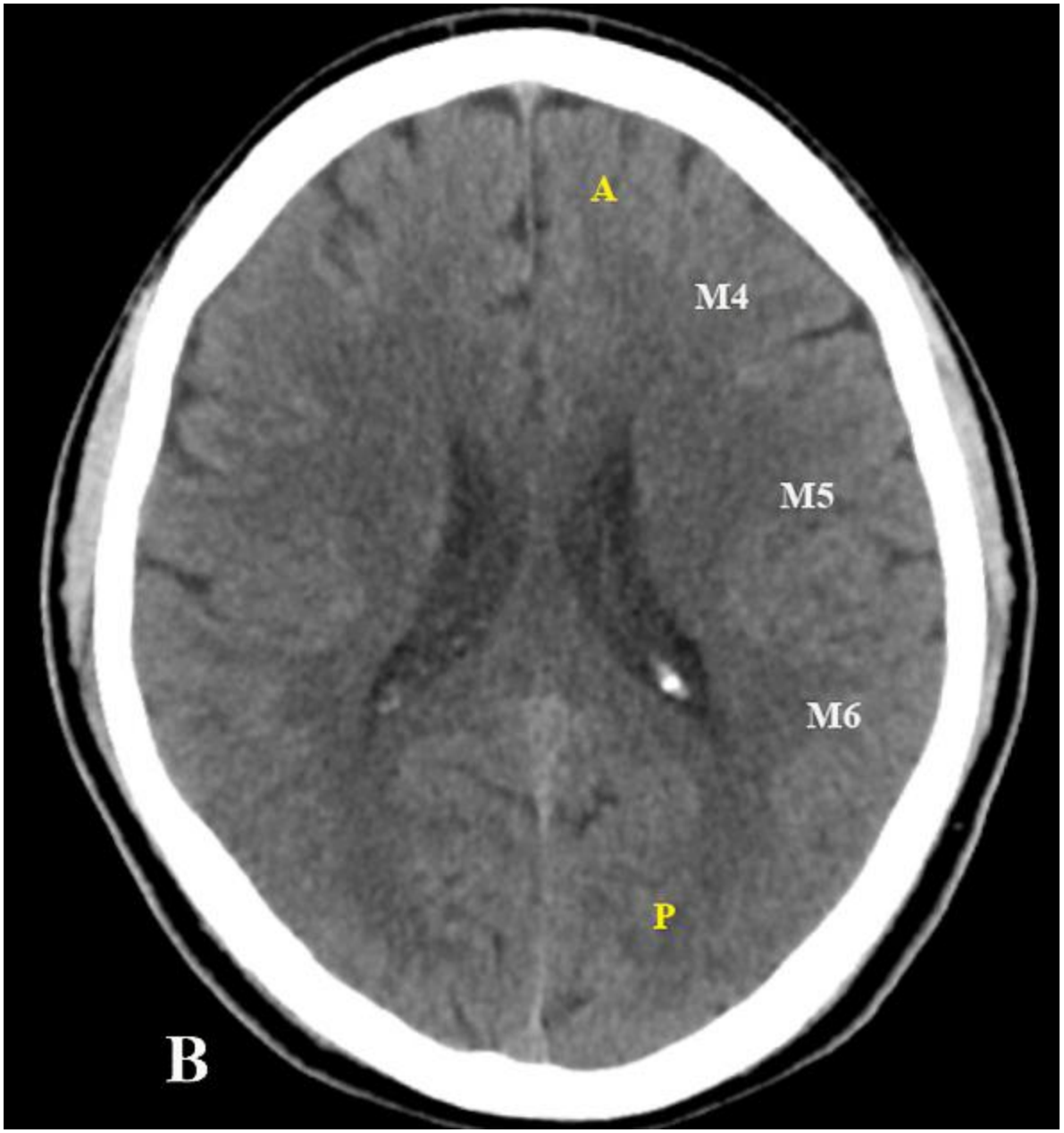
A
M4
M5
M6
P
B

- **Clinical use**
  - An ASPECTS score less than or equal to 7 predicts a worse functional outcome at 3 months as well as symptomatic hemorrhage.
  - According to the study performed by **R I Aviv** et al., patients with ASPECTS score less than 8 treated with thrombolysis did not have a good clinical outcome .

# **Posterior circulation**
## pc-ASPECTS

- thalami (1 point each)
- occipital lobes (1 point each)
- midbrain (2 points)
- pons (2 points)
- cerebellar hemispheres (1 point each)

**Posterior circulation Acute stroke prognosis early CT score (pc-ASPECTS)**




T: thalamus; OL: occipital lobe; M: any part of the midbrain; P: any part of the pons;
C: cerebellar hemisphere.

Osamah Alwalid
Radiopaedia.org

# BRAIN TUMORS

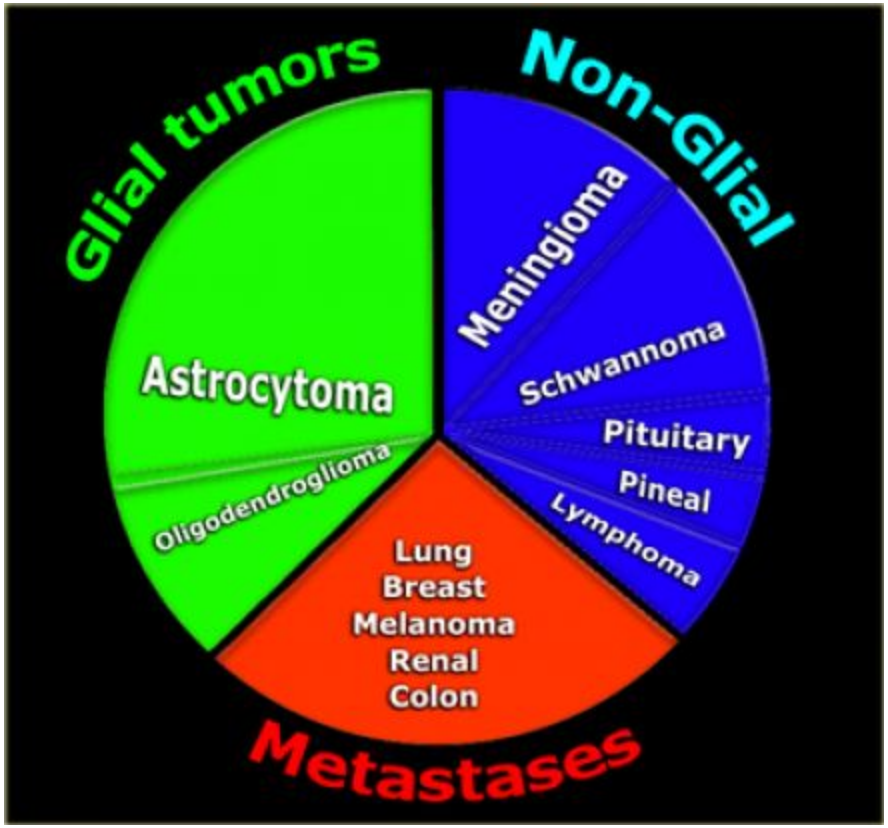

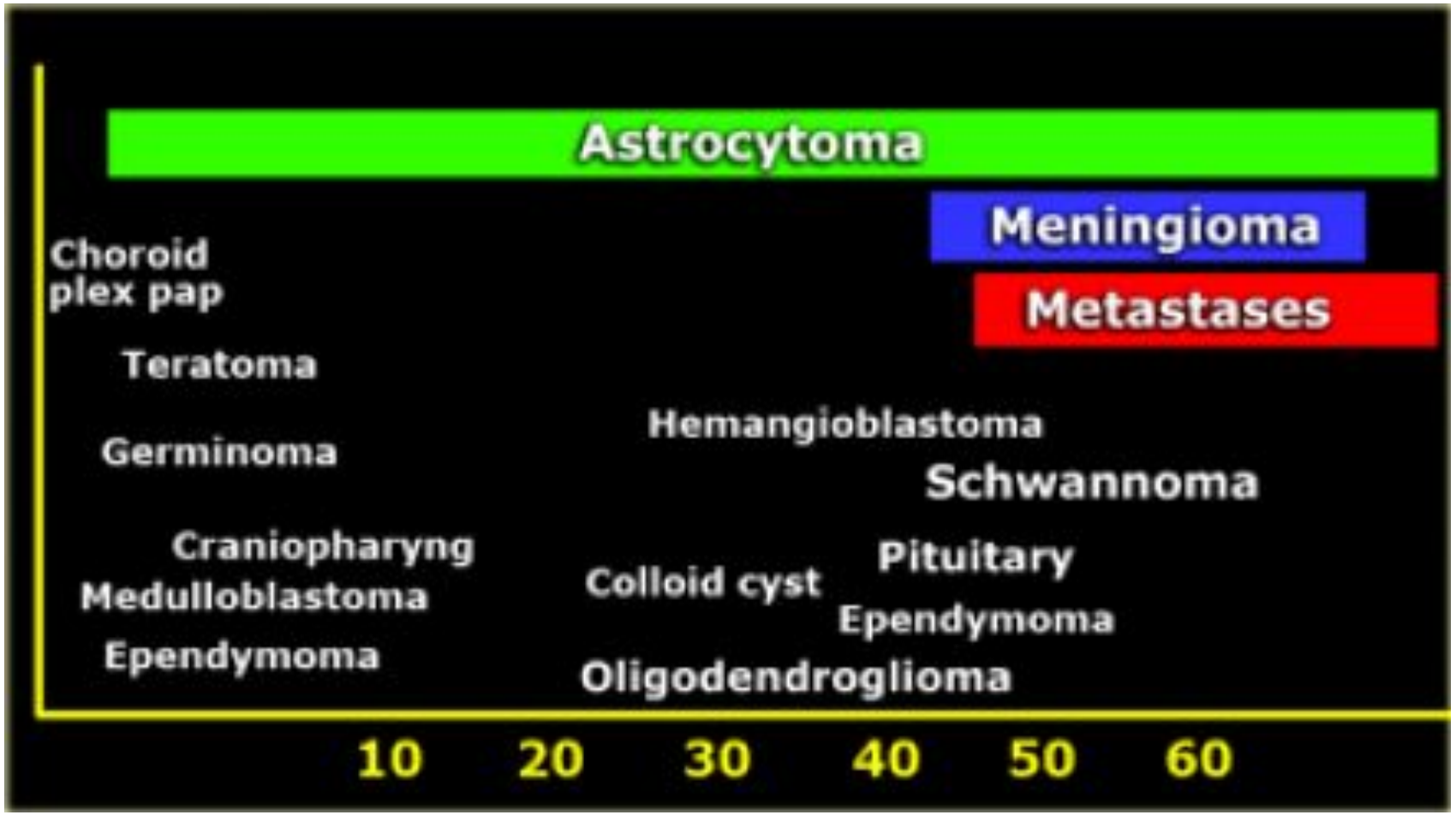
Astrocytoma
Meningioma
Metastases
Choroid plex pap
Teratoma
Germinoma
Hemangioblastoma
Schwannoma
Craniopharyng
Medulloblastoma
Ependymoma
Colloid cyst
Pituitary
Ependymoma
Oligodendroglioma
10
20
30
40
50
60

# Common Intra-Axial Tumors in Pediatric

## Supratentorial:

Astrocytoma
Pleomorphic xanthoastro (PXA)
PNET
DNET
Ganglioglioma

## Infratentorial:

Juvenile Pilocytic Astro
PNET (Medulloblastoma)
Ependymoma
Brainstem Astrocytoma

# Common Intra-Axial Tumors in Adult

## Supratentorial:

**Metastases ++**

Gliomas (25%)

- Fibrillary Astrocytoma
- Anaplastic Astrocytoma
- Glioblastoma Multiformi
- Oligodendroglioma

## Infratentorial:

**Metastases ++++**

Hemangioblastoma

## Signs of Extra-Axial Location

- ✓ CSF cleft
- ✓ Displaced subarachnoid vessels
- ✓ Cortical gray between mass and white matter
- ✓ Displace and expand subarachnoid space
- ✓ Broad Dural base
- ✓ Bony reaction

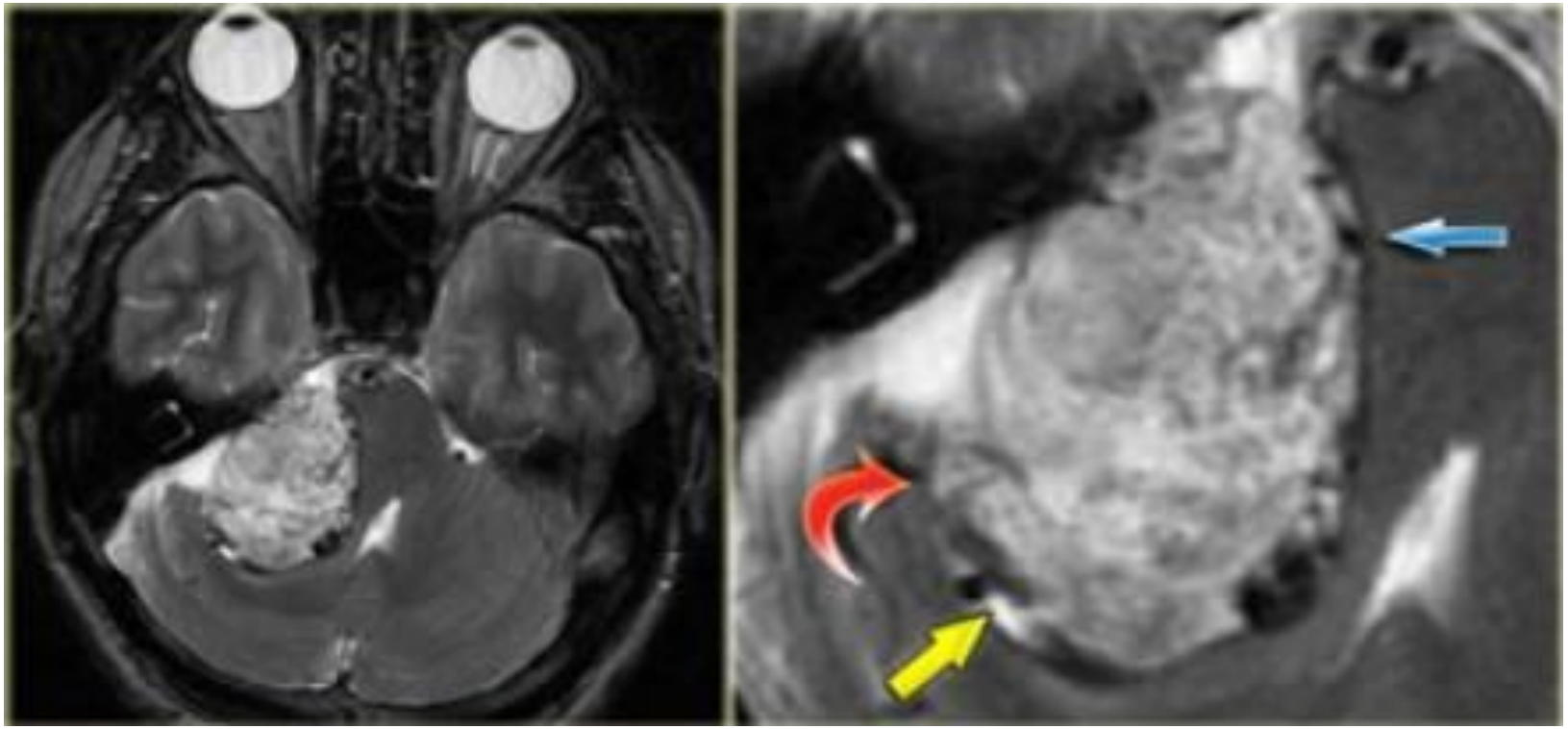

Meningioma

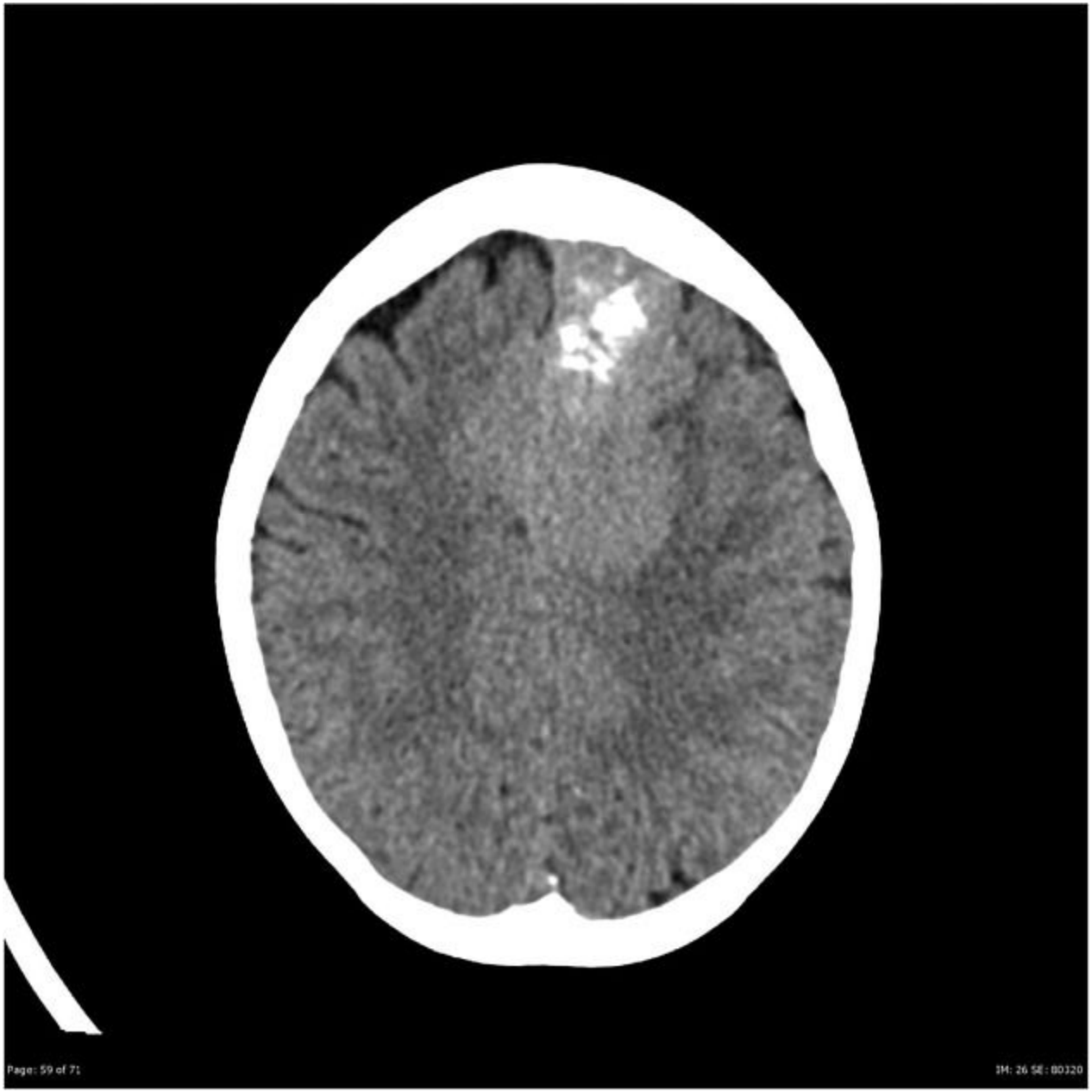

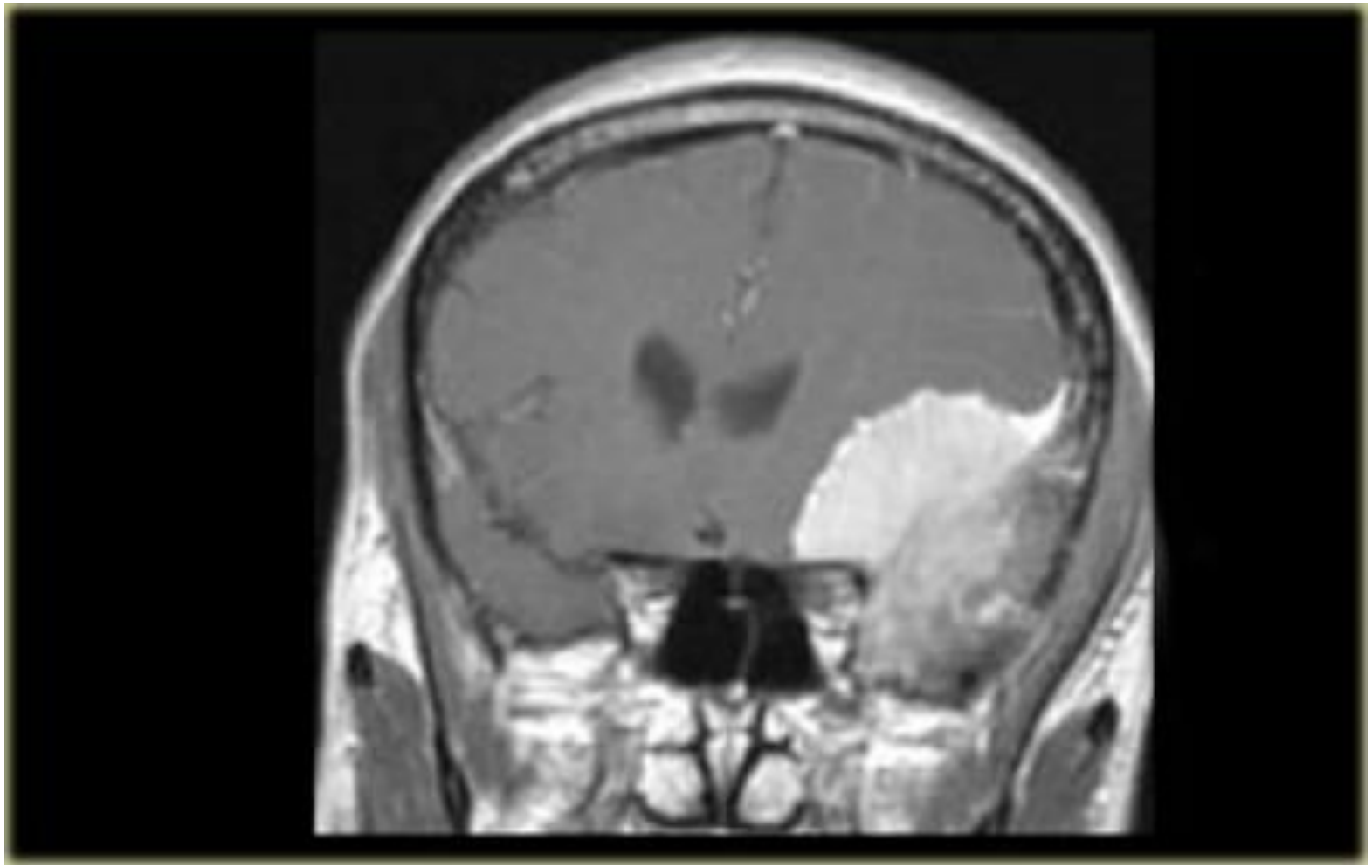

Schwanoma

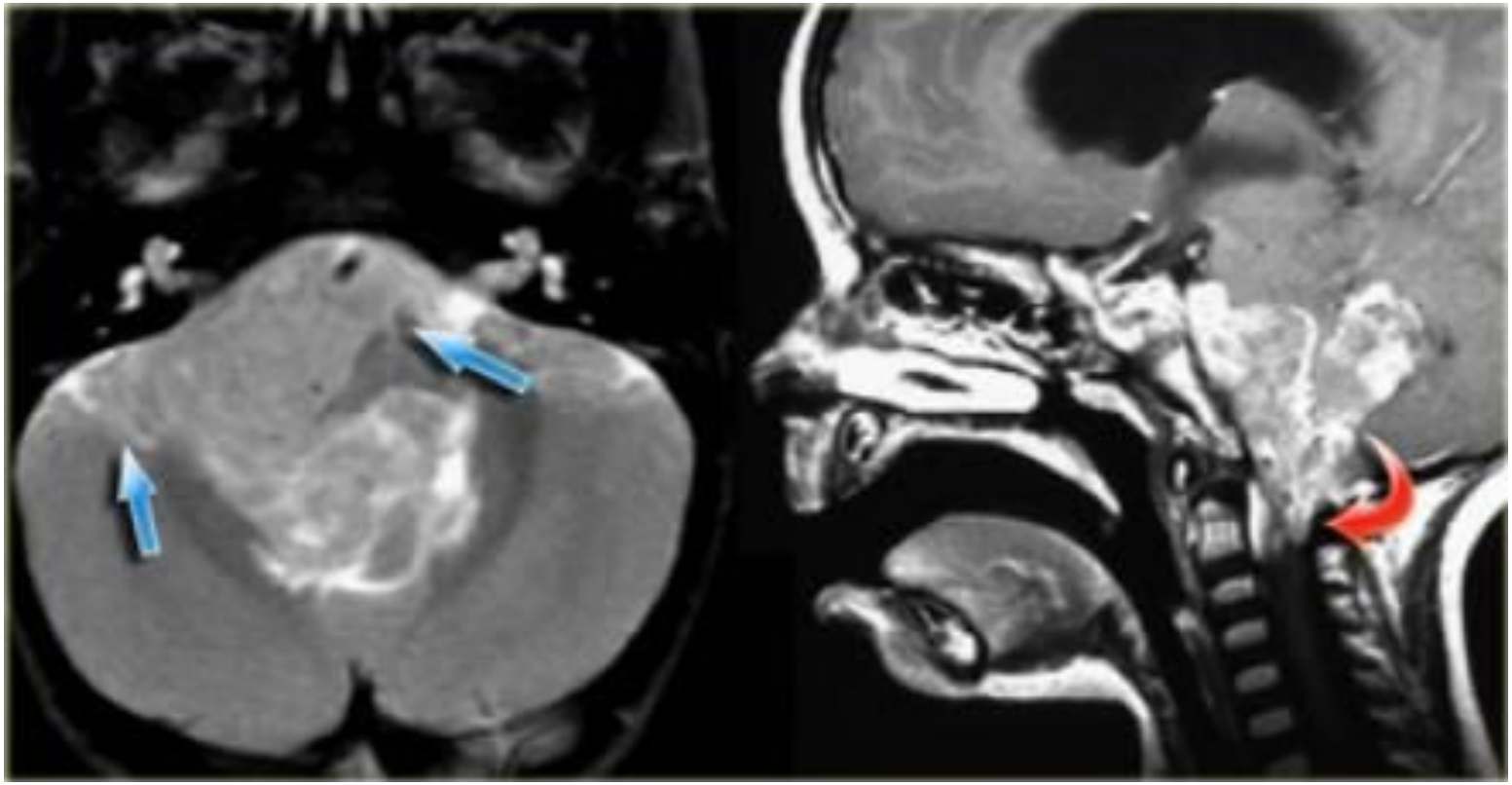

Glioblastoma multi formi

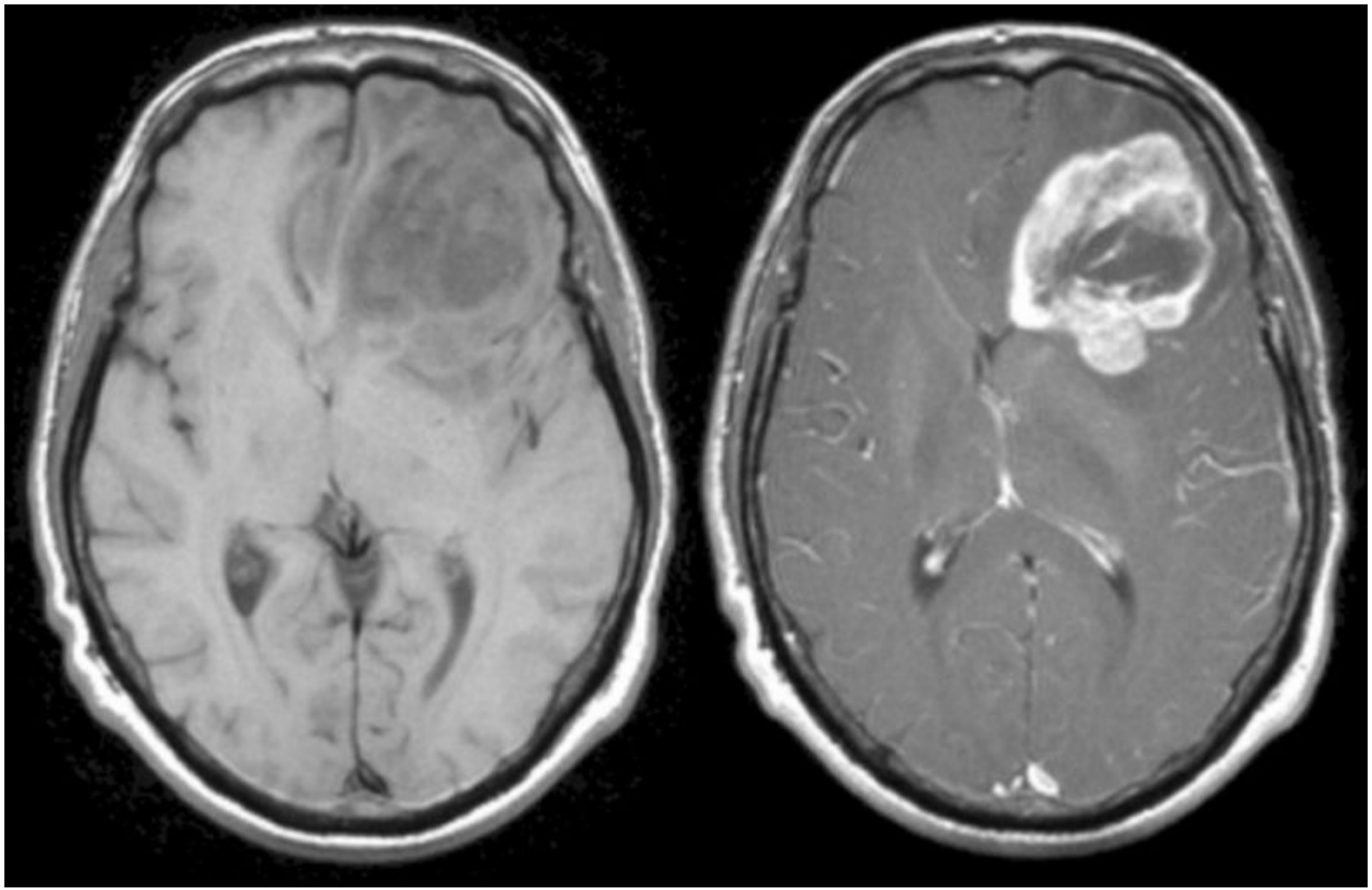

# hydrocephalus

- Communicating
- Non communicating

- communicating (i.e. CSF can exit the ventricular system)
- without obstruction to CSF absorption particular group of conditions with disparate, and often poorly understood, abnormal CSF dynamics, including:
  - normal pressure hydrocephalus (NPH)
  - choroid plexus papillomas (part of the associated hydrocephalus is thought to be due to overproduction of CSF [1]. An obstructive component in larger masses is often also present).
  - sub archnoid haemorrhage ( obstrcutive).

- non-communicating (i.e. CSF cannot exit the ventricular system, and thus there is by definition obstruction to CSF absorption)often merely referred to as obstructive hydrocephalus
- upstream ventricles are dilated and exert mass effect upon adjacent brain (e.g. effacement of sulci)
- numerous causes including:
  - foramen of Monro: colloid cyst
  - aqueduct of Sylvius: aqueduct stenosis, tectal glioma
  - fourth ventricle: posterior fossa tumor, or cerebellar infarct or cerebellar hemorrhage

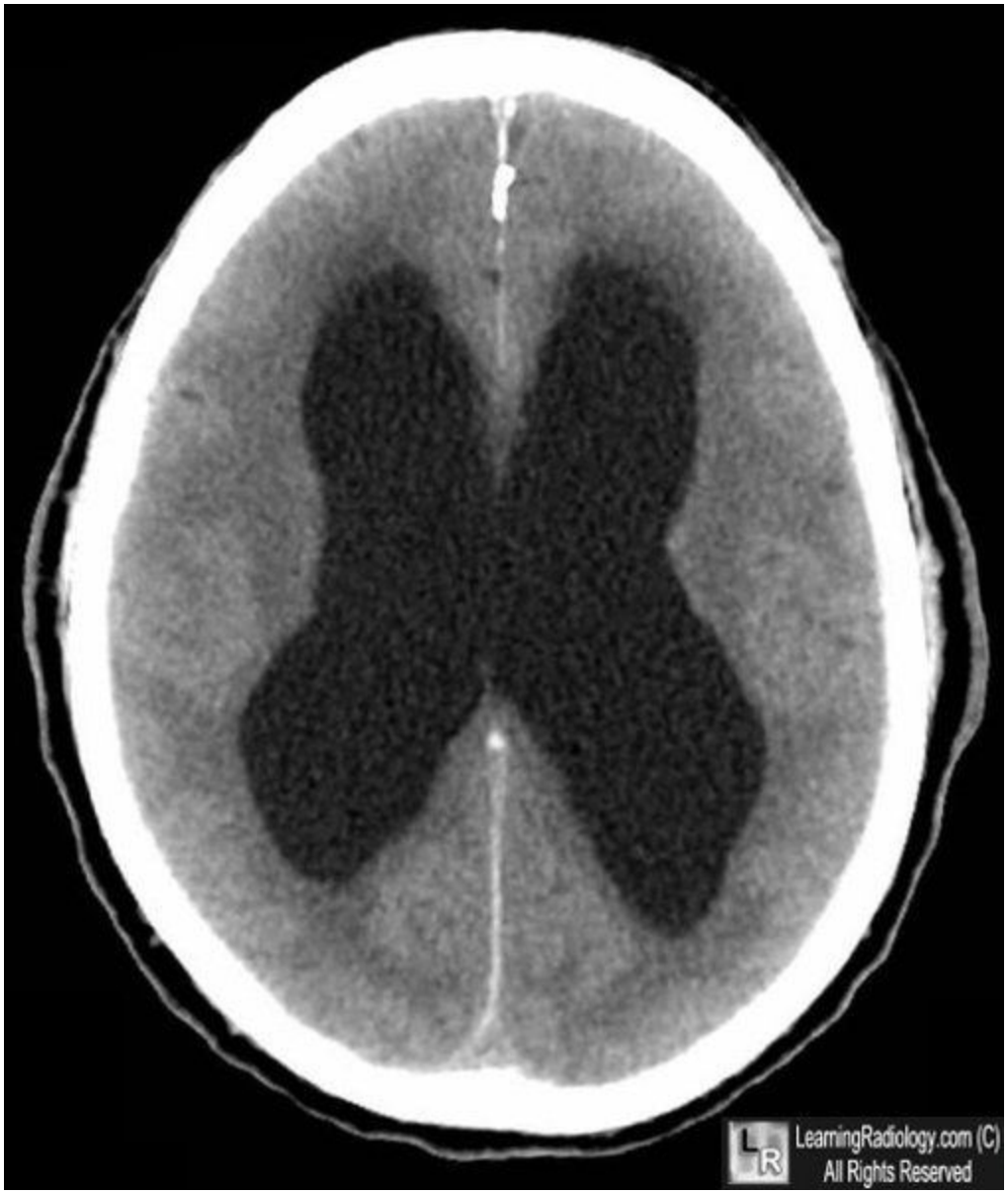
LearningRadiology.com (C)
All Rights Reserved



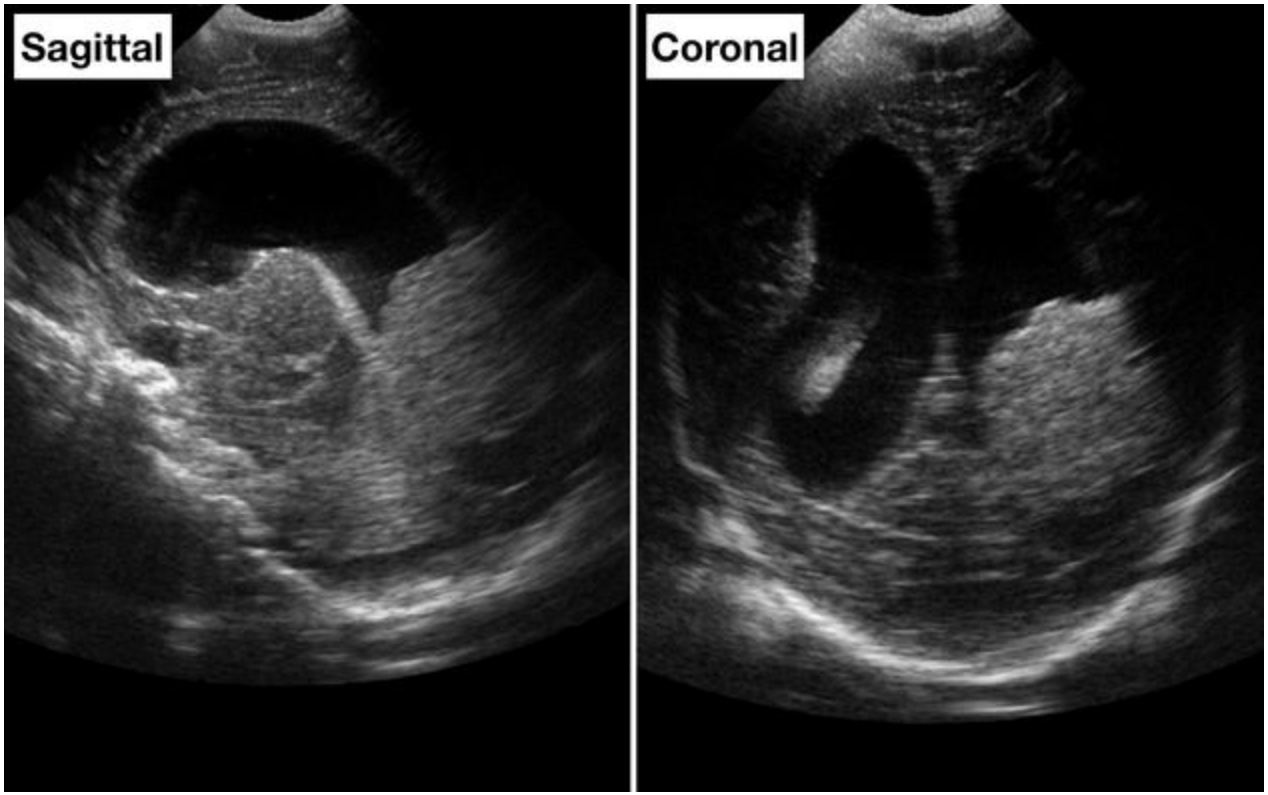
Sagittal
Coronal

- THANK  YOU FOR YOUR ATTENTION.