CARDIOVASCULAR INVESTIGATIONS

1-PLAIN FILMS

2-ULTRASOUND

3-ISOTOPE SCANNING

4-CT

5-MRI

6-ANGIOGRAPHY



Hand mit Ringen (Hand with Rings): print of Wilhelm Röntgen's first "medical" X-ray, of his wife's hand, taken on 22 December 1895 and presented to Ludwig Zehnder of the Physik Institut, University of Freiburg, on 1 January 1896

ISOTOPE SCAN

ISOTPE SCAN

- Rest isotope scan using thallium (Ti201) injection.
- Dual-isotope imaging is a hybrid protocol that combines a resting thallium injection and subsequent scan with the injection of either Tc-99m sestamibi or tetrofosmin during stress.
- Adenosine stress test if patient cant physically do exercise (Pharmaceutical **stress** is used to increase blood flow to the heart muscle) .

Radionuclide	Symbol	Physical half-life	Chemical form	Diagnostic use
Chromium	^{51}Cr	27.8 days	Sodium chromate	Red blood cell volume and survival
			Albumin	Gastrointestinal protein loss
Cobalt	^{57}Co	270 days	Cyanocobalamin (vitamin B_{12})	Vitamin B_{12} absorption
Fluorine	^{18}F	110 min	Fluorodeoxyglucose	Oncology and myocardial hibernation
Gallium	^{67}Ga	77 hr	Gallium citrate	Inflammatory process and tumor imaging
Indium	^{111}In	67.4 hr	DTPA	Cerebrospinal fluid imaging
			Ibritumomab tiuxetan	Localization of tumor
			OctreoScan (pentetreotide)	Neuroendocrine tumors
			ProstaScint (capromab-pendetide)	Prostate cancer
			Oxine	White blood cell/abscess imaging
Iodine	^{123}I	13.3 hr	Sodium iodide	Thyroid function and imaging
			Human serum albumin	Plasma volume
	^{131}I	8 days	Sodium iodide	Thyroid function, imaging, and therapy
			Hippurate	Renal function
Nitrogen	^{13}N	10 min	Ammonia	Myocardial perfusion
Rubidium	^{82}Rb	75 sec	Rubidium chloride	Cardiovascular imaging
Technetium	^{99m}Tc	6 hr	Sodium pertechnetate	Imaging of brain, thyroid, scrotum, salivary glands, renal perfusion, and pericardial effusion; evaluation of left-to-right cardiac shunts
			Sulfur colloid	Imaging of liver and spleen and renal transplants, lymphoscintigraphy
			Macroaggregated albumin	Lung imaging
			Sestamibi	Cardiovascular imaging, myocardial perfusion
			DTPA	Brain and renal imaging
			DMSA	Renal imaging
			MAG3	Renal imaging
			Diphosphonate	Bone imaging
			Pyrophosphate	Bone and myocardial imaging
			Red blood cells	Cardiac function imaging
			HMPAO	Functional brain imaging and white blood cell/abscess imaging
			Iminodiacetic derivations	Liver function imaging
			Neurolite (Bicisate)	Brain imaging
			Myoview (Tetrofosmin)	Myocardial perfusion
			CEA-scan (Arcitumomab)	Gastrointestinal tract
			Cardiolite (Sestamibi)	Myocardial perfusion
			Apcitide (AcuTect)	Acute venous thrombosis
Thallium	^{201}Tl	73.5 hr	Thallous chloride	Myocardial imaging
Xenon	^{133}Xe	5.3 days	Xenon gas	Lung ventilation imaging



Myocardial Perfusion Imaging
SPECT

- Indications
  - Detects presence/location/extent of myocardial ischemia in patients with R/O ACS.
  - Risk stratification after ACS.
  - Identify fixed defects, evaluate EF and viability.
  - CP with abnormal EKG's.
  - Equivocal ETT.
  - Inability to exercise (pharmacological stress).

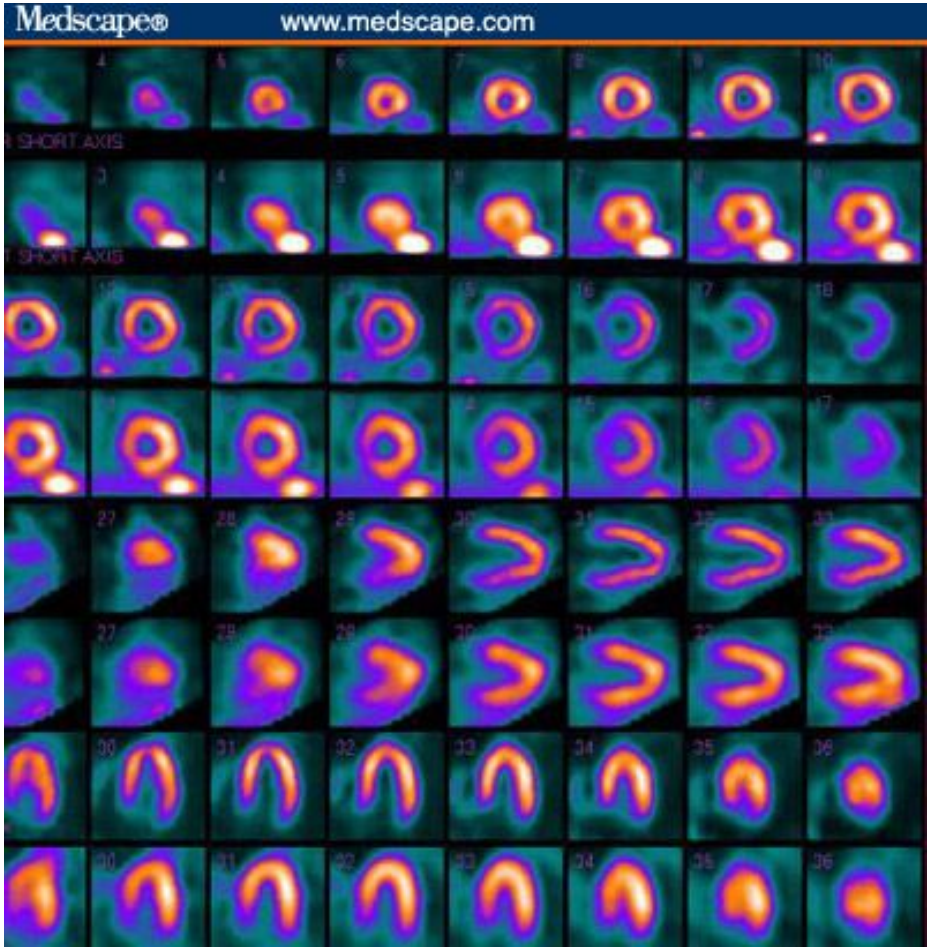

Stress ^{99m}Tc-tetrofosmin/rest ^{201}Tl images in a patient with a low likelihood of CAD. The first and third rows are stress short-axis slices from apex to base. The second and fourth rows are matching rest slices. The fifth and sixth rows are the stress and rest vertical-long-axis slices, while the seventh and eighth rows are the stress and rest horizontal-long-axis slices.

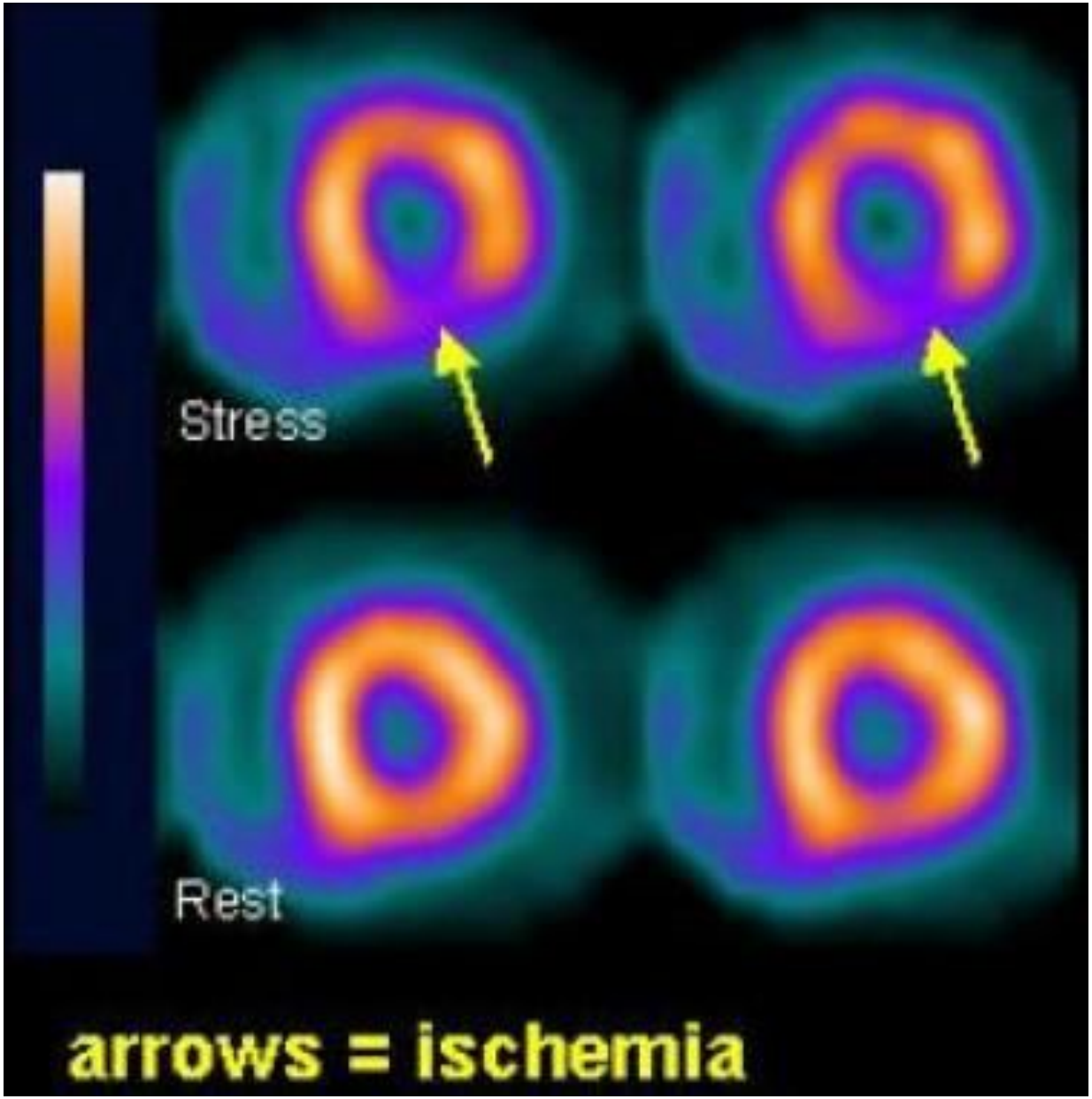
Stress
Rest
arrows = ischemia

Fig 1. **Myocardial perfusion imaging: irreversible ischaemia**

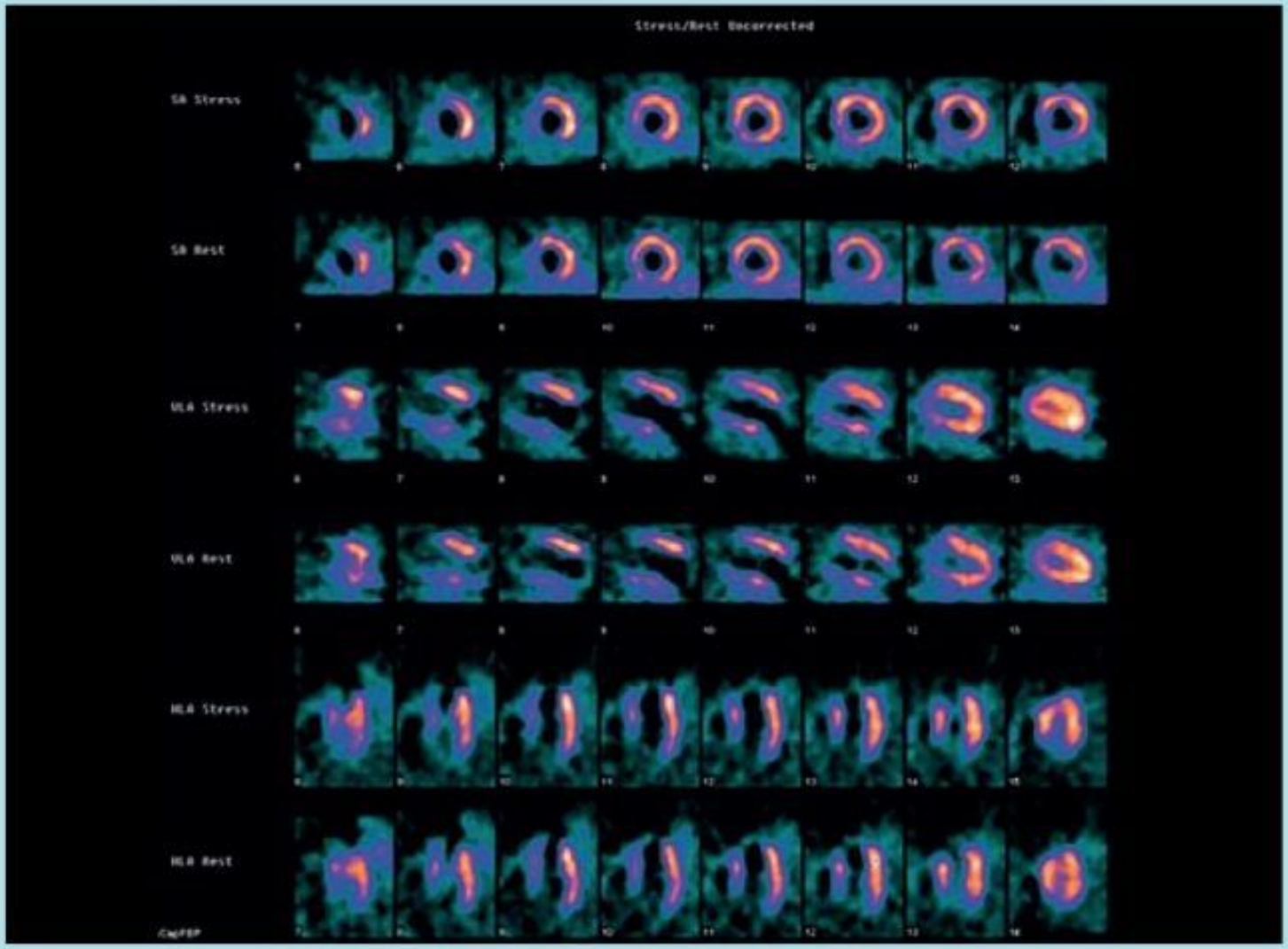

Absent/reduced counts in anteroapical segments, including apex and inferior apical segments. Shows full-thickness infarction. No reversible ischaemia, evidence of myocardial infarction.

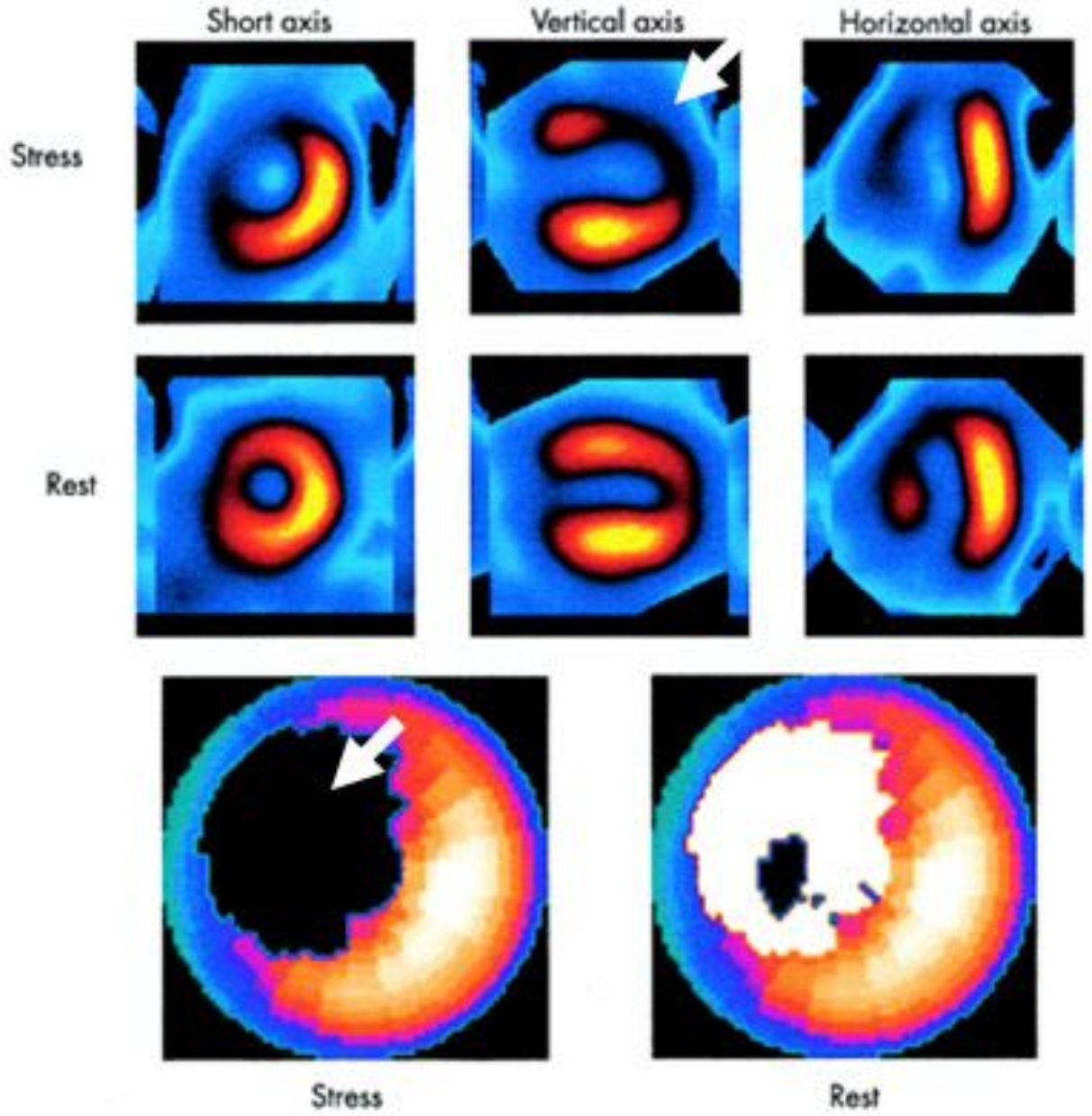
Short axis
Vertical axis
Horizontal axis
Stress
Rest
Stress
Rest

Coronary CT

What is needed?

- Good CT scanner (64 detector or more).
- Patient cooperation.
- Stable heart rate , heart rate around 60p/m.
- Regular CT Contrast injection (iodin) at high rate .
- ECG gating.

Cardiac Ct assess:

- Coronary vessels.
- Aorta .
- Functional (thrombus , EF , contractility,….)
- Muscles viability (dual source/spectra CT).

Usage , limitation :

- Mainly used for low- intermediate risk patients .
- Not indicated for high risk paints except in some advanced centers.
- In case of heavy coronary vessels calcification , it has low resolution.
- high heart rate , Arrhythmia and irregular heart rate is limitation for some type of CT scanners.
- Used to assess complex cardiac congenital anomaly.

Ca score

- Used for risk stratification for coronary , valve and aortic calcification.
- low , intermediate risk patients.
- Not used in case of previous bypass surgery or coronary stenting.
- With /without ECG gating , but not affected by heart rate and arrhythmia.

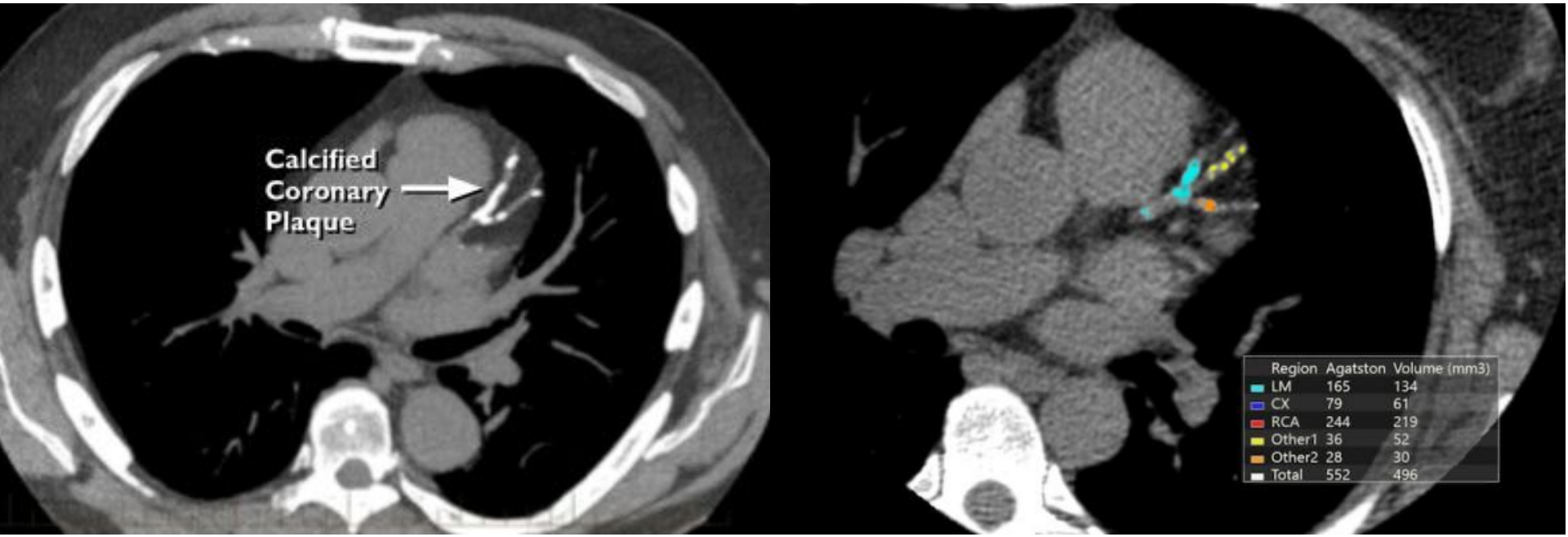
Calcified
Coronary
Plaque
Region Agatston Volume (mm3)
LM 165 134
CX 79 61
RCA 244 219
Other1 36 52
Other2 28 30
Total 552 496

The result of the test is usually given as a number called an <u>Agatston</u> score. The score reflects the total area of calcium deposits and the density of the calcium.

- A score of zero means no calcium is seen in the heart. It suggests a low chance of developing a heart attack in the future.
- When calcium is present, the higher the score, the higher your risk of heart disease.
- A score of 100 to 300 means moderate plaque deposits. It's associated with a relatively high risk of heart attack or other heart disease over the next three to five years.
- A score greater than 300 is a sign of very high to severe disease and heart attack risk.

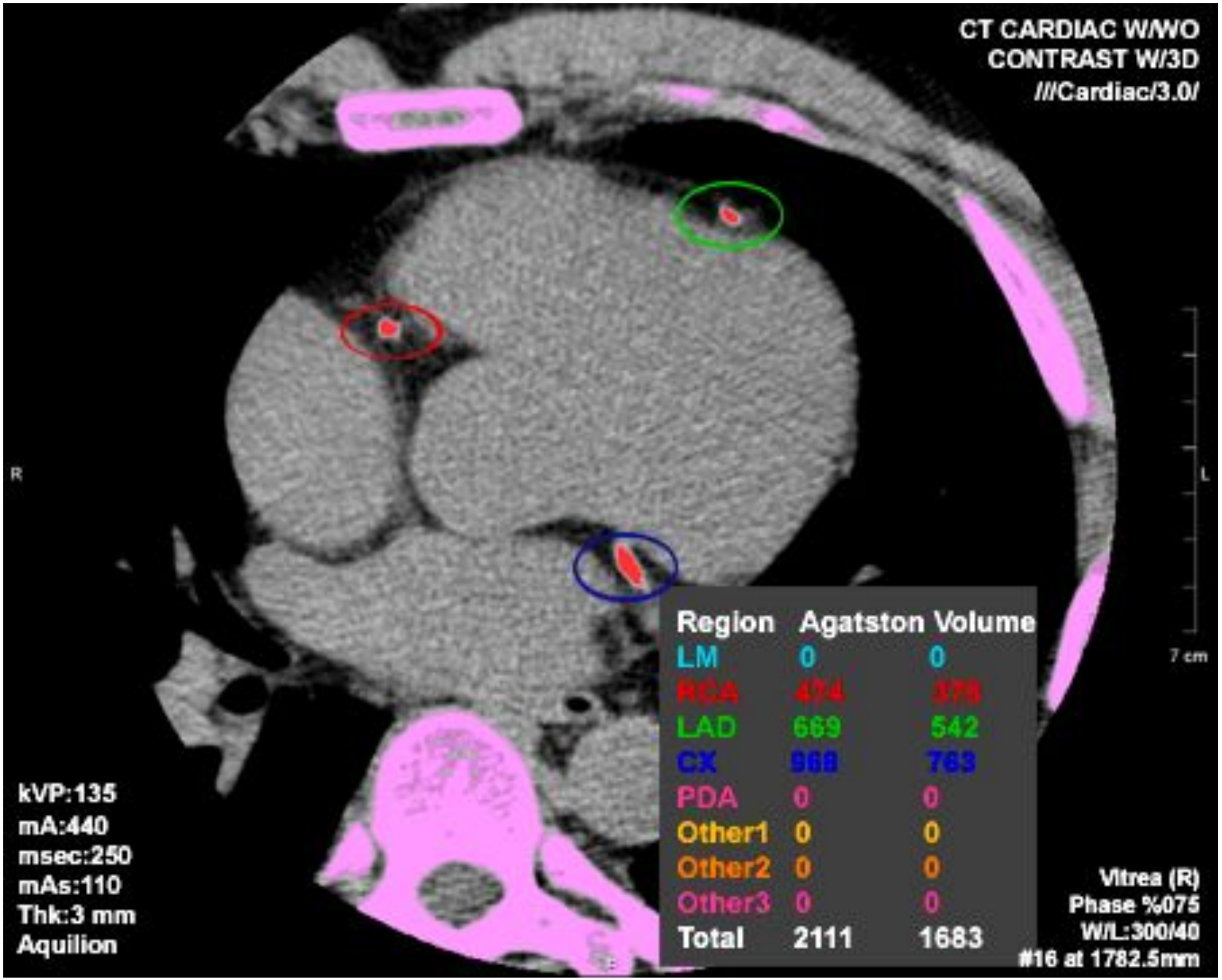
CT CARDIAC W/WO
CONTRAST W/3D
///Cardiac/3.0/
R
L
7 cm
Region Agatston Volume
LM 0 0
RCA 474 378
LAD 669 542
CX 968 763
PDA 0 0
Other1 0 0
Other2 0 0
Other3 0 0
Total 2111 1683
kVP:135
mA:440
msec:250
mAs:110
Thk:3 mm
Aquilion
Vitrea (R)
Phase %075
W/L:300/40
#16 at 1782.5mm

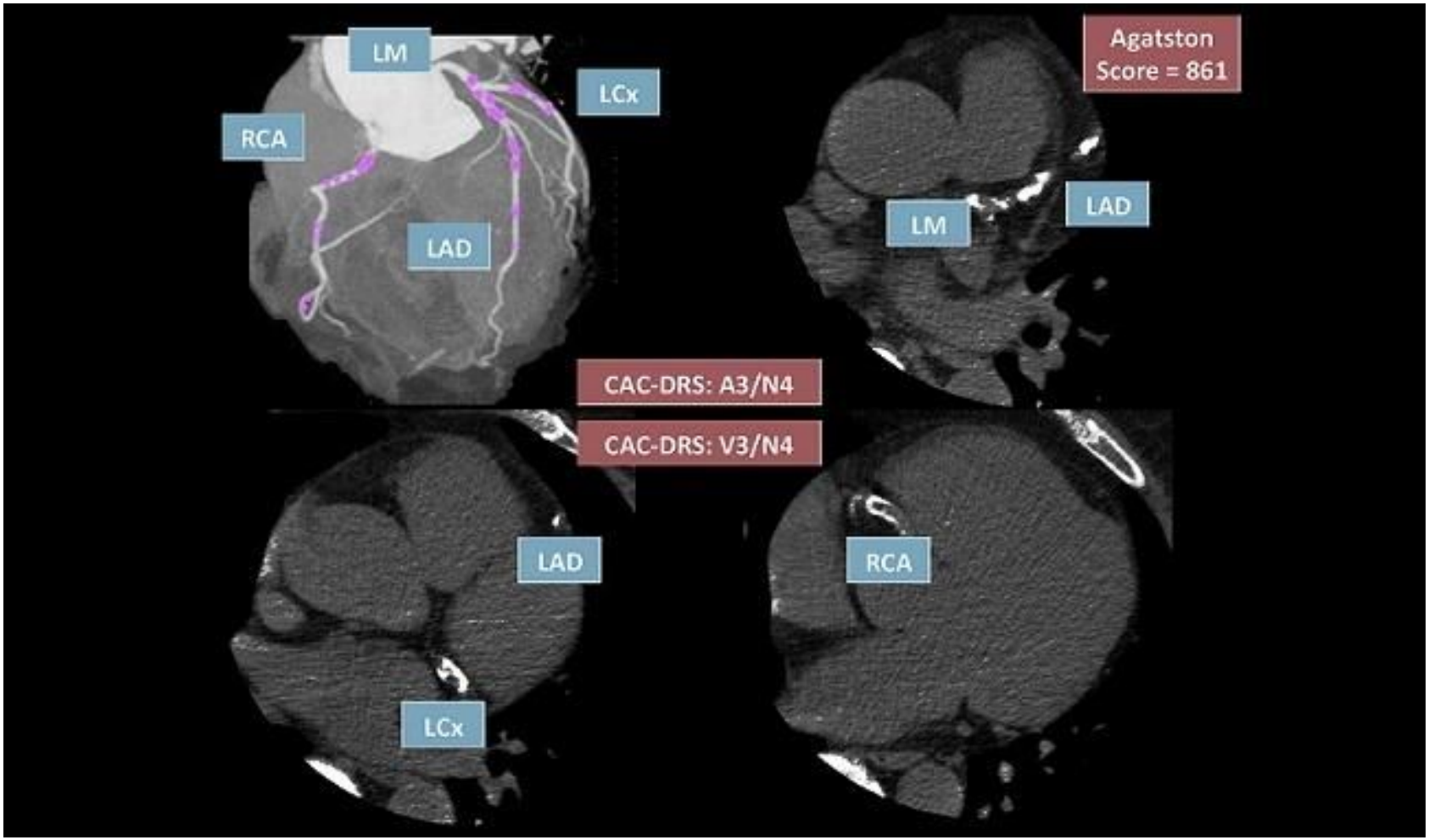
LM
LCx
RCA
LAD
Agatston
Score = 861
LM
LAD
CAC-DRS: A3/N4
CAC-DRS: V3/N4
LAD
RCA
LCx

According to the American College of Cardiology and the American Heart Association guidelines, a heart scan may not be recommended for the following people:

- Men under age 40 and women under age 50, because it's unlikely calcium can be detected at younger ages
- People who have a very low risk, because detectable calcium is highly unlikely if you don't have a family history of heart attacks at an early age
- People who already have a known high risk (especially heavy smokers or those with diabetes or very high cholesterol), because the heart scan will likely not provide any additional information to guide treatment
- People with symptoms or a diagnosis of coronary artery disease, because the procedure won't help doctors better understand the disease progression or risk
- People who already had an abnormal coronary calcium heart scan

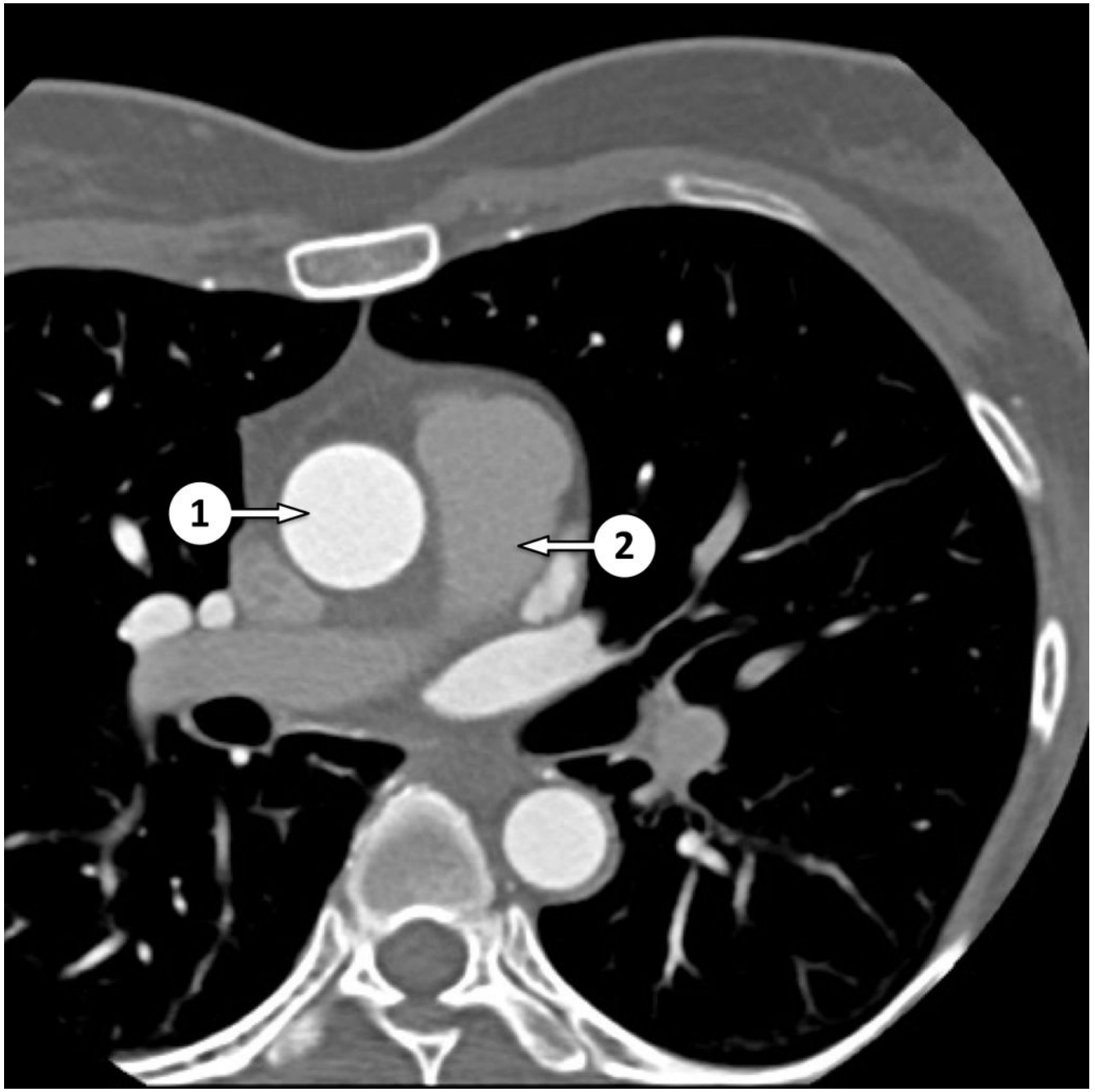
1
2

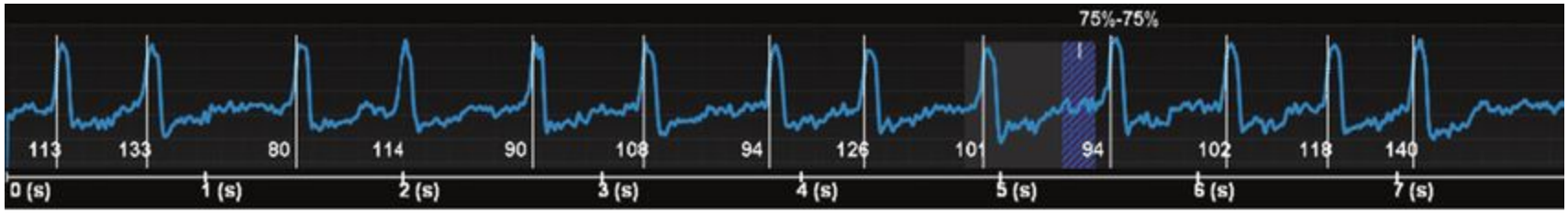
75%-75%
113
133
80
114
90
108
94
126
101
94
102
118
140
0 (s)
1 (s)
2 (s)
3 (s)
4 (s)
5 (s)
6 (s)
7 (s)

a.


LAD

b.


LCX

c.

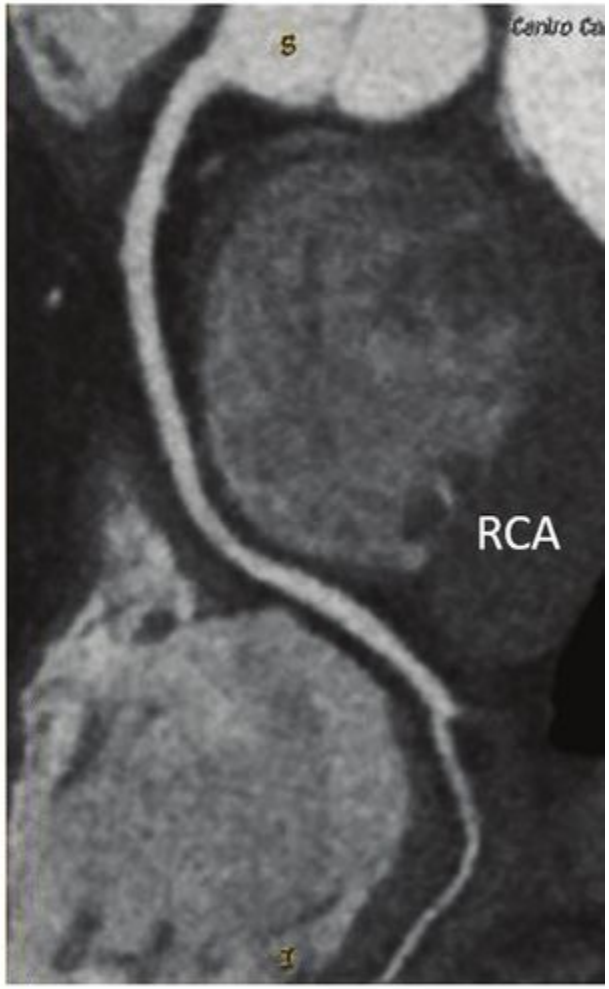
RCA

d.


Page: 1 of 1
IM: 1

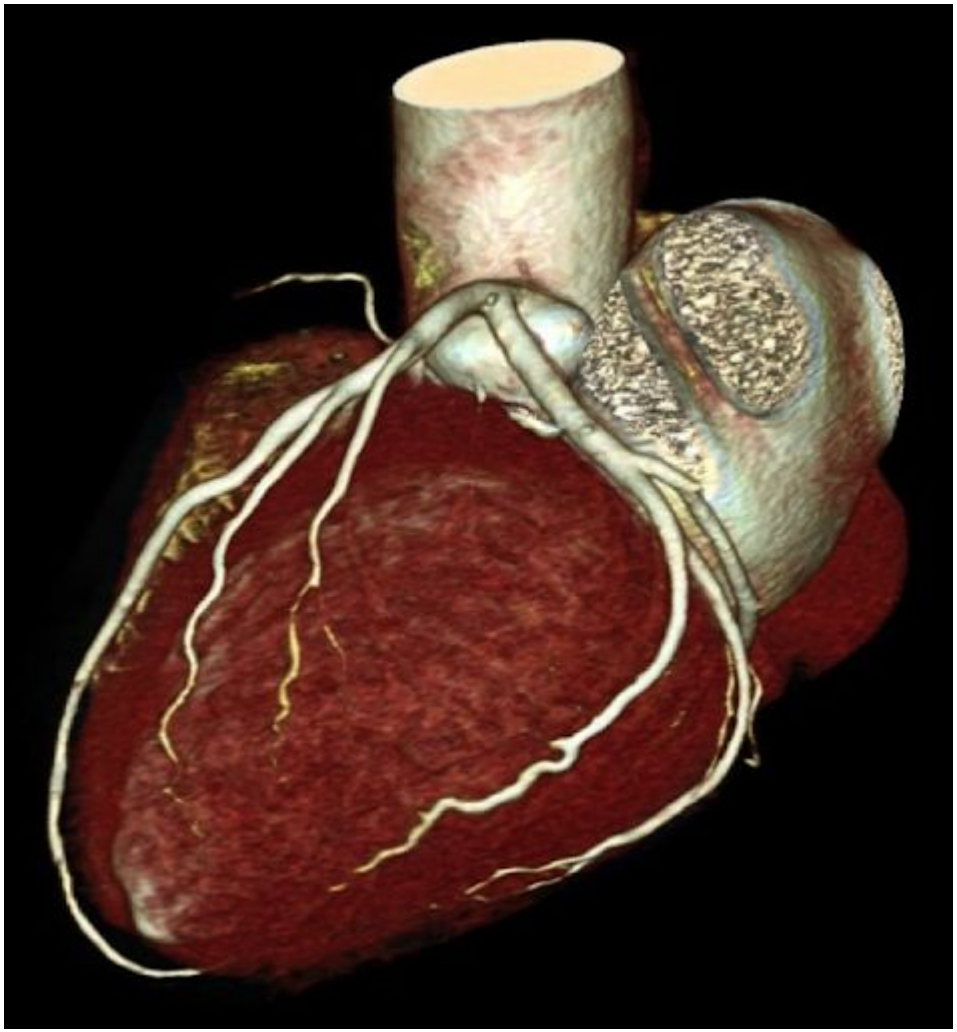

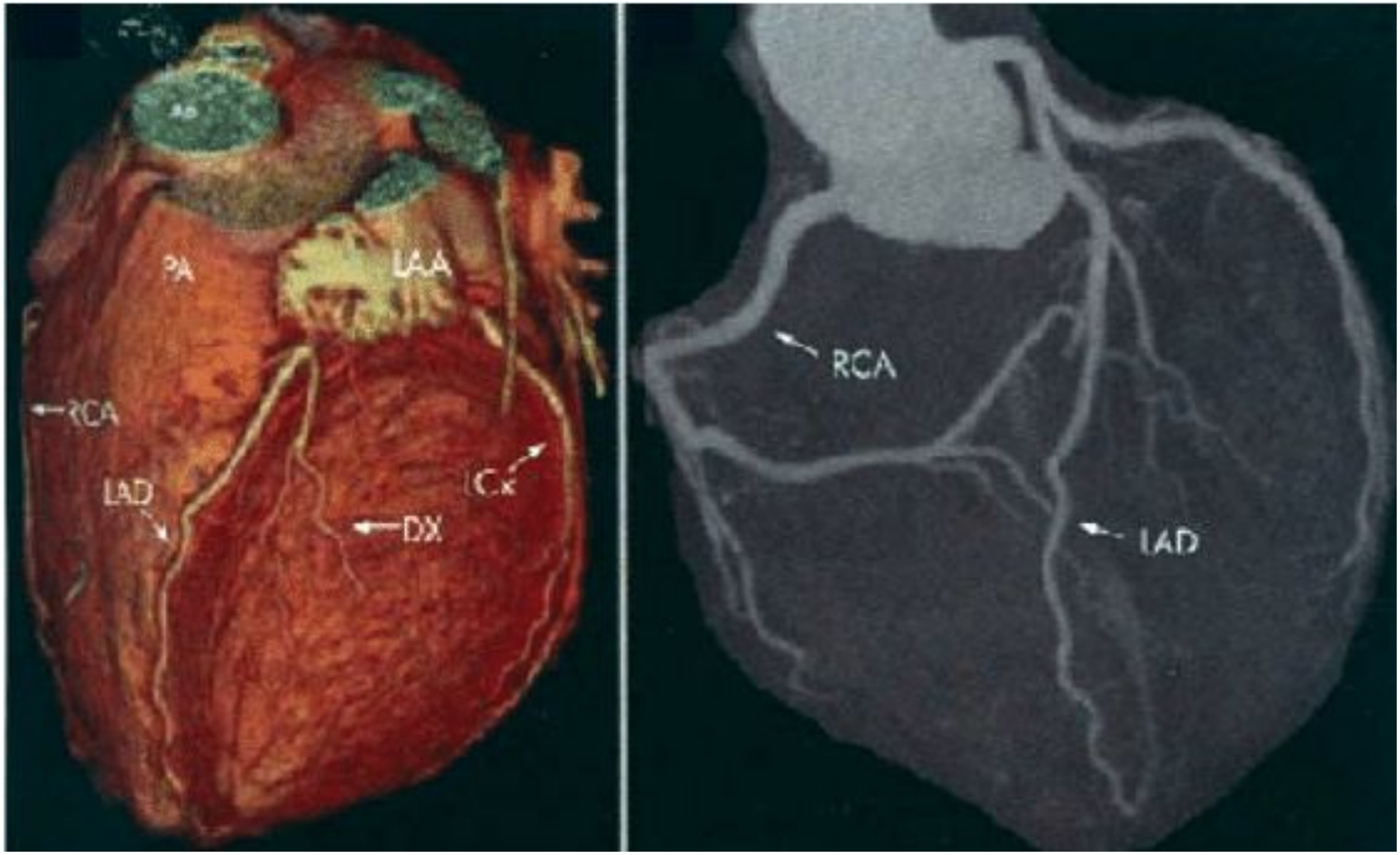
PA
LAA
RCA
LAD
Cx
DX
RCA
LAD

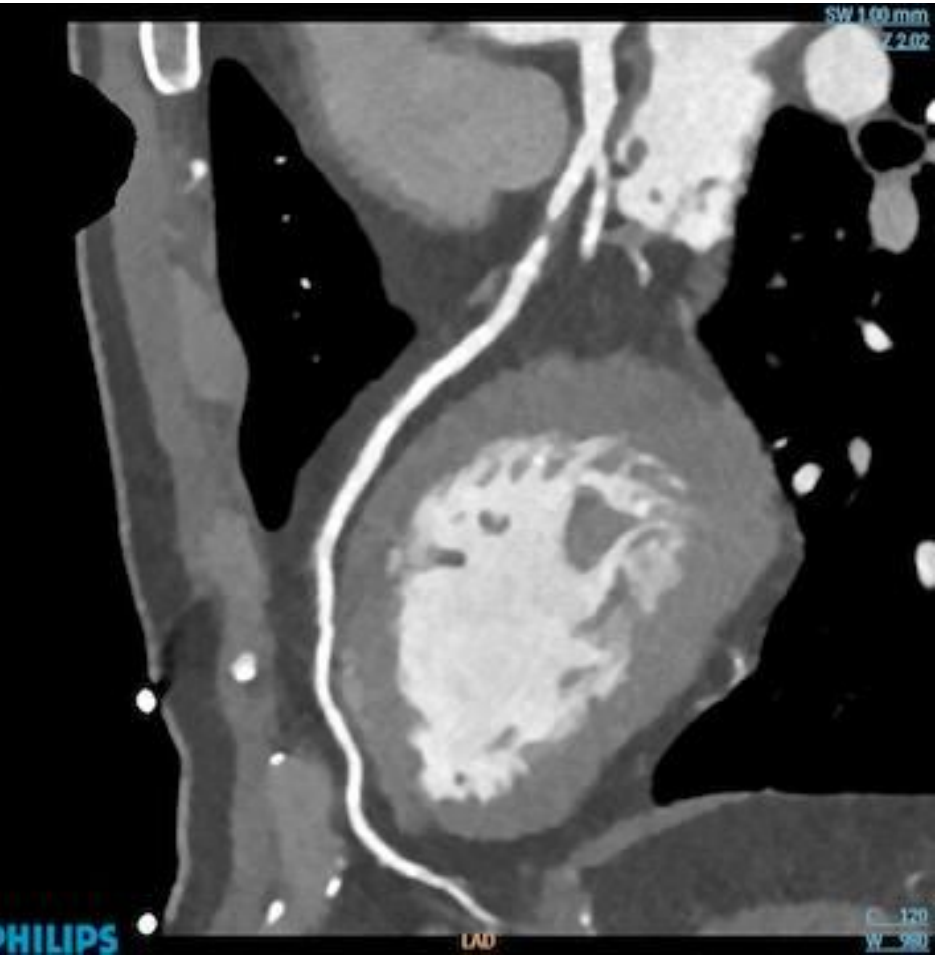
SW 1.00 mm
Z 2.02
PHILIPS
LAD
C 120
W 360

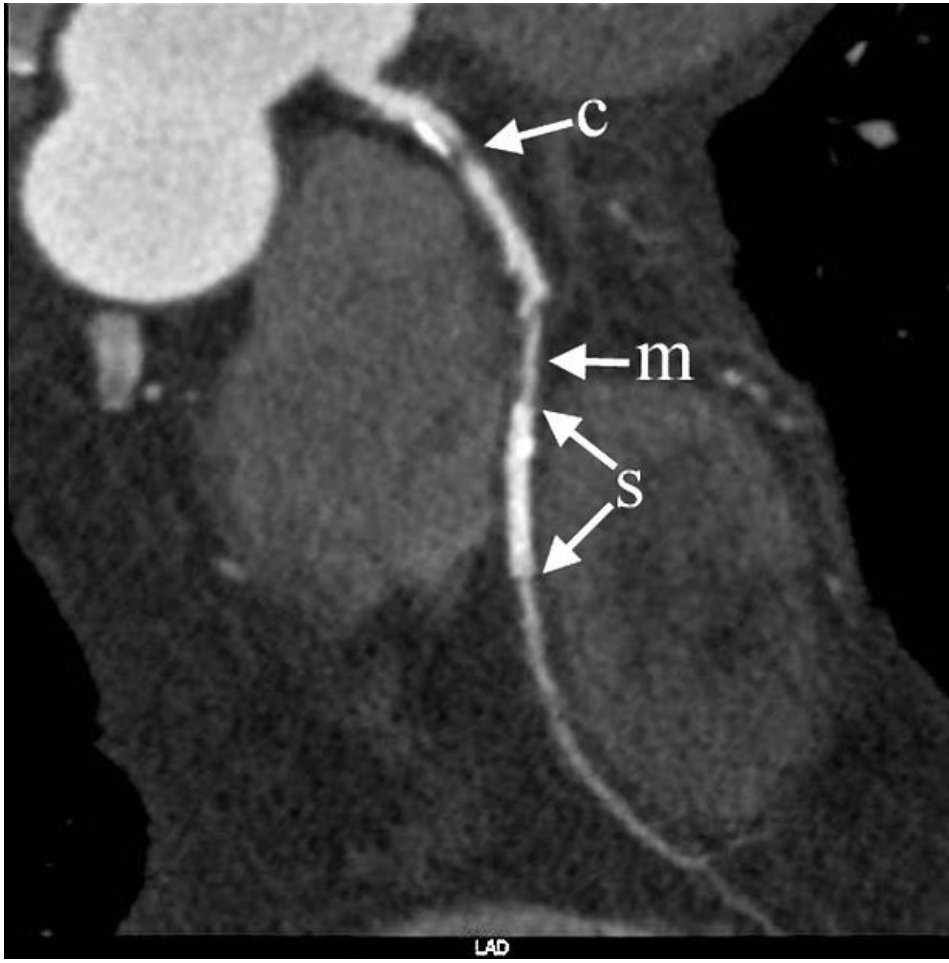
c
m
s
LAD

MYOCRDAIL ENHANCEMENT AND VIABILITY ASSESSMENT

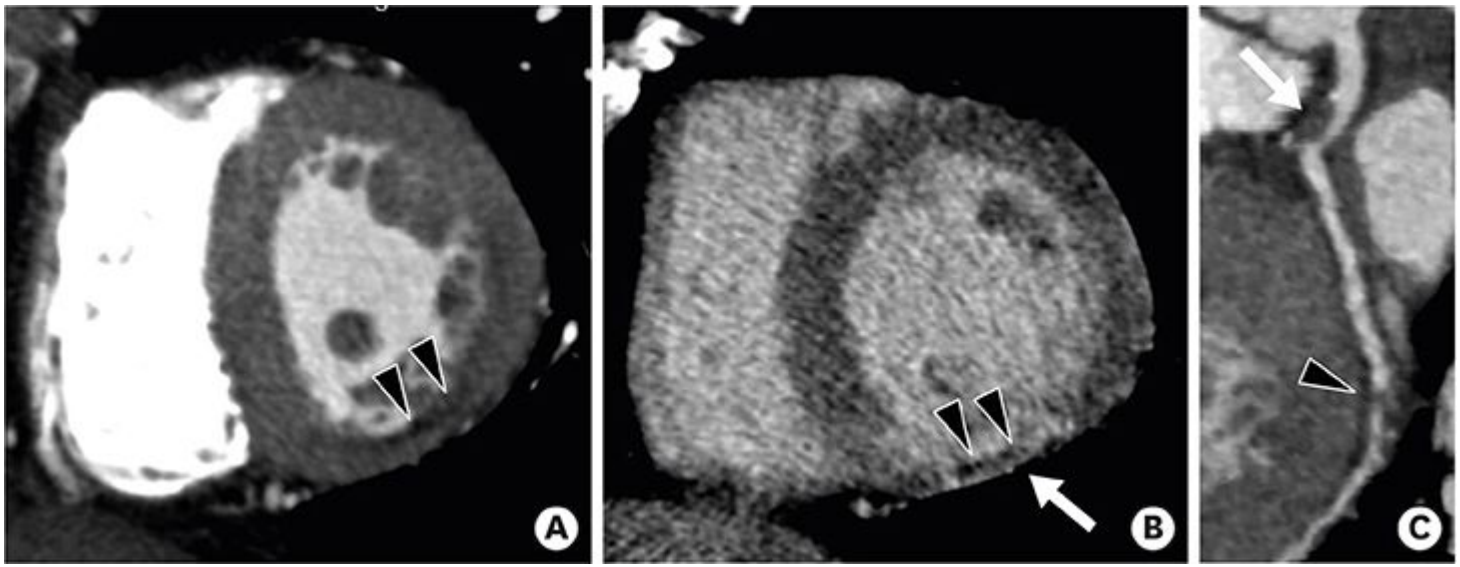

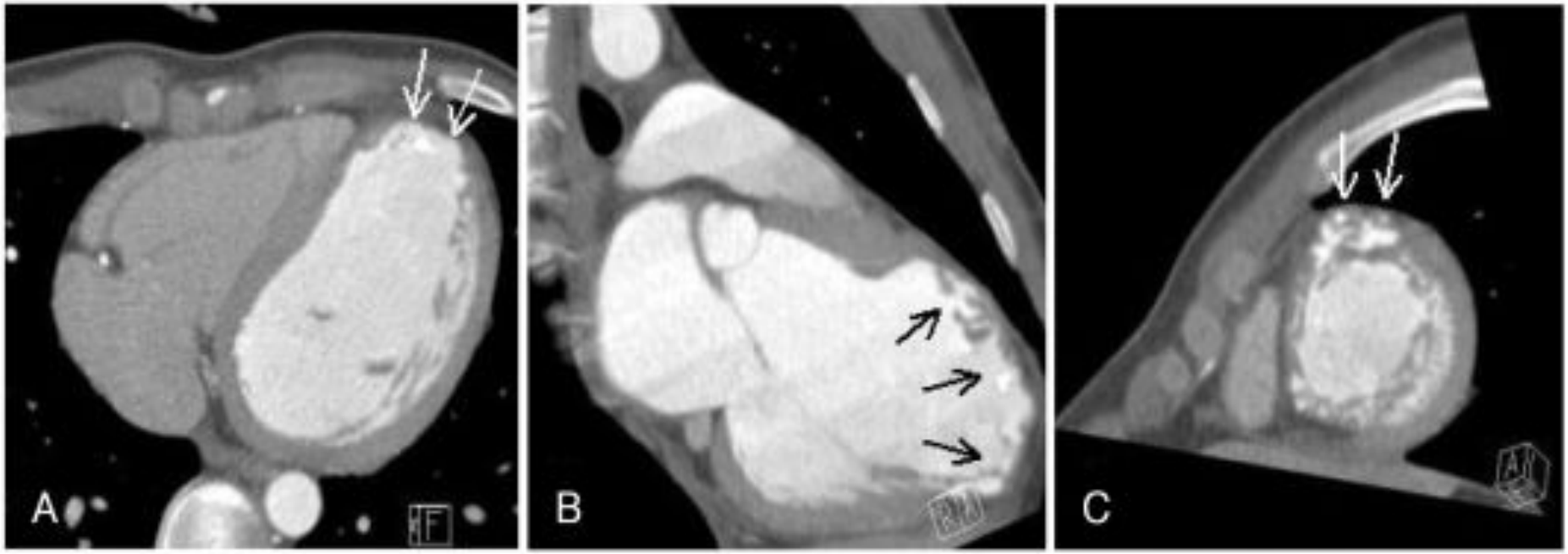
A
B
C

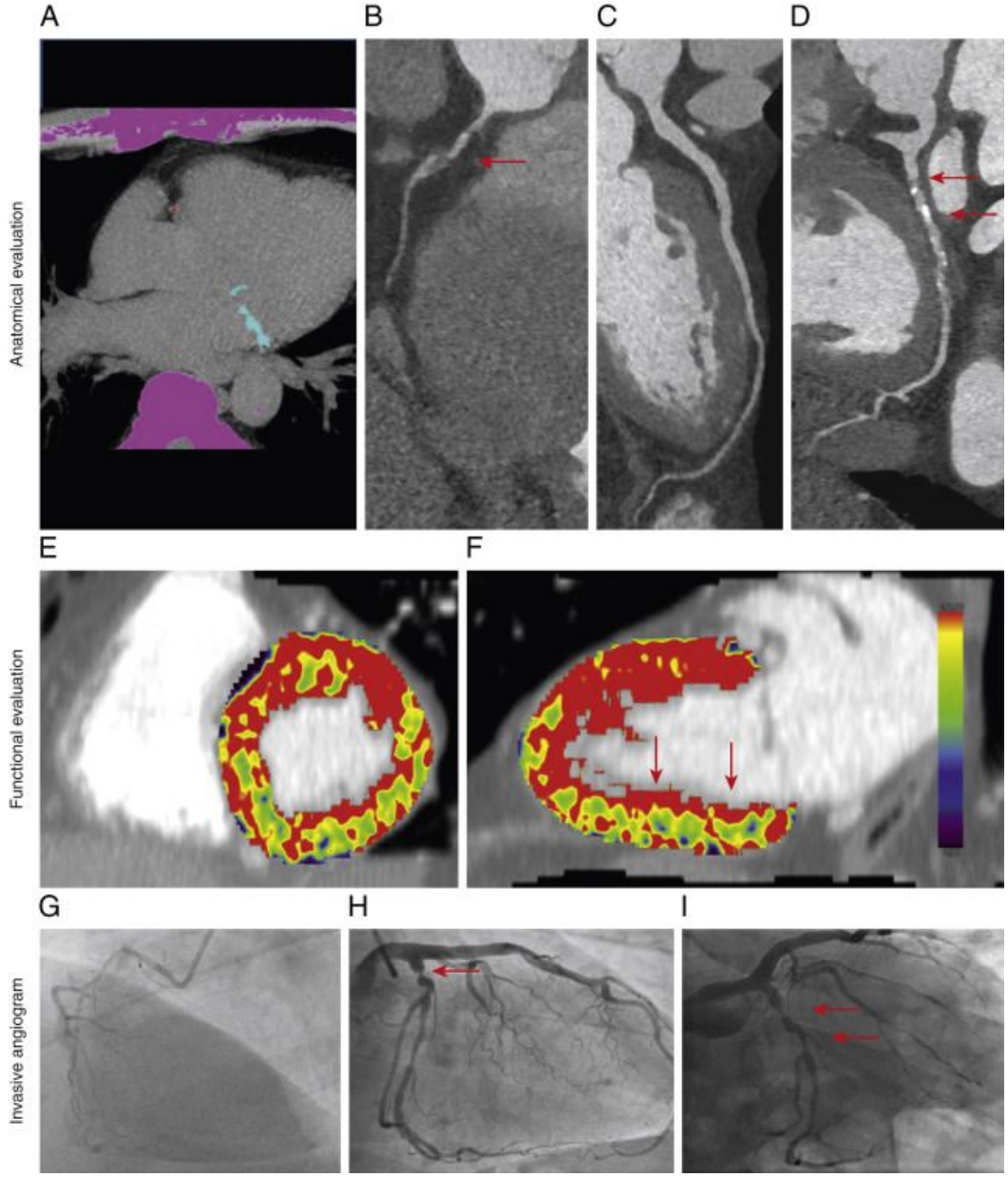
A
B
C
D
Anatomical evaluation
E
F
Functional evaluation
G
H
I
Invasive angiogram

Cardiac CT functional assessment

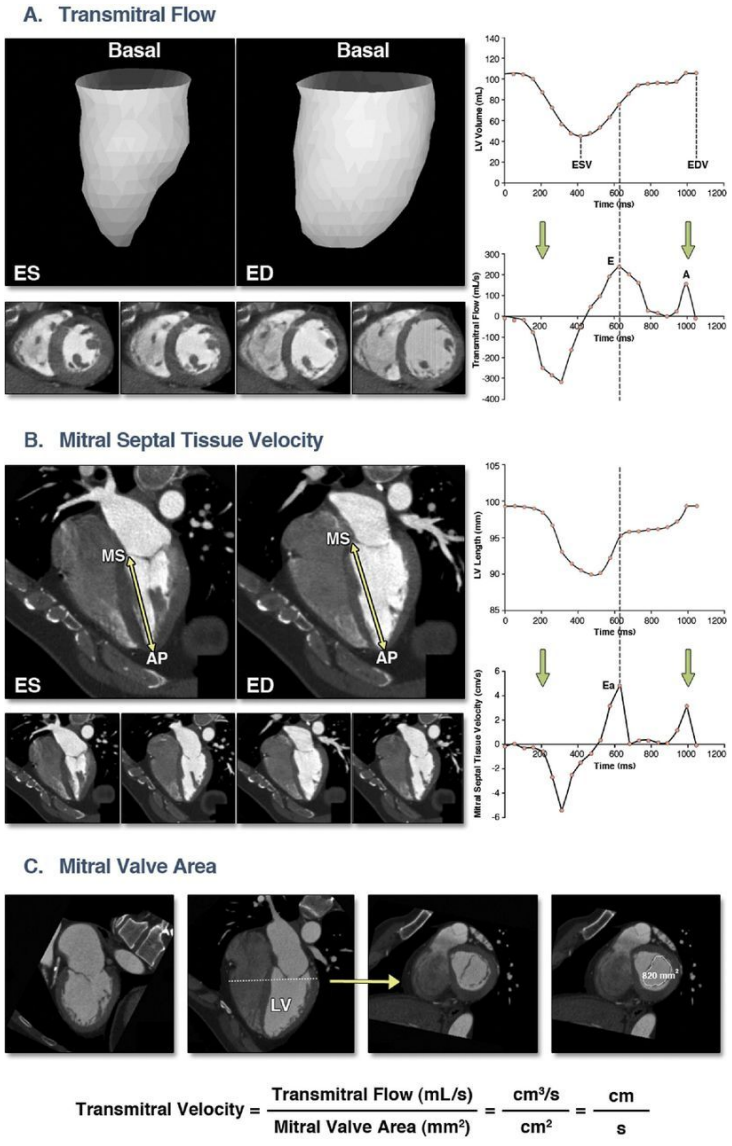

$$\text{Transmitral Velocity} = \frac{\text{Transmitral Flow (mL/s)}}{\text{Mitral Valve Area (mm}^2\text{)}} = \frac{\text{cm}^3/\text{s}}{\text{cm}^2} = \frac{\text{cm}}{\text{s}}$$

LV apex thrombus



Myxoma LT atrium (most common location)



Cardiac MRI.

- Patient cooperation (long study).
- ECG & respiratory gating .
- Specialized technician and physician(skill demanding).

Cardiac MRI used for:

- Muscle viability , masses, thrombus , contractility .
- Functional assessment .
- Used to assess complex cardiac congenital anomaly.
- Coronary vessels.

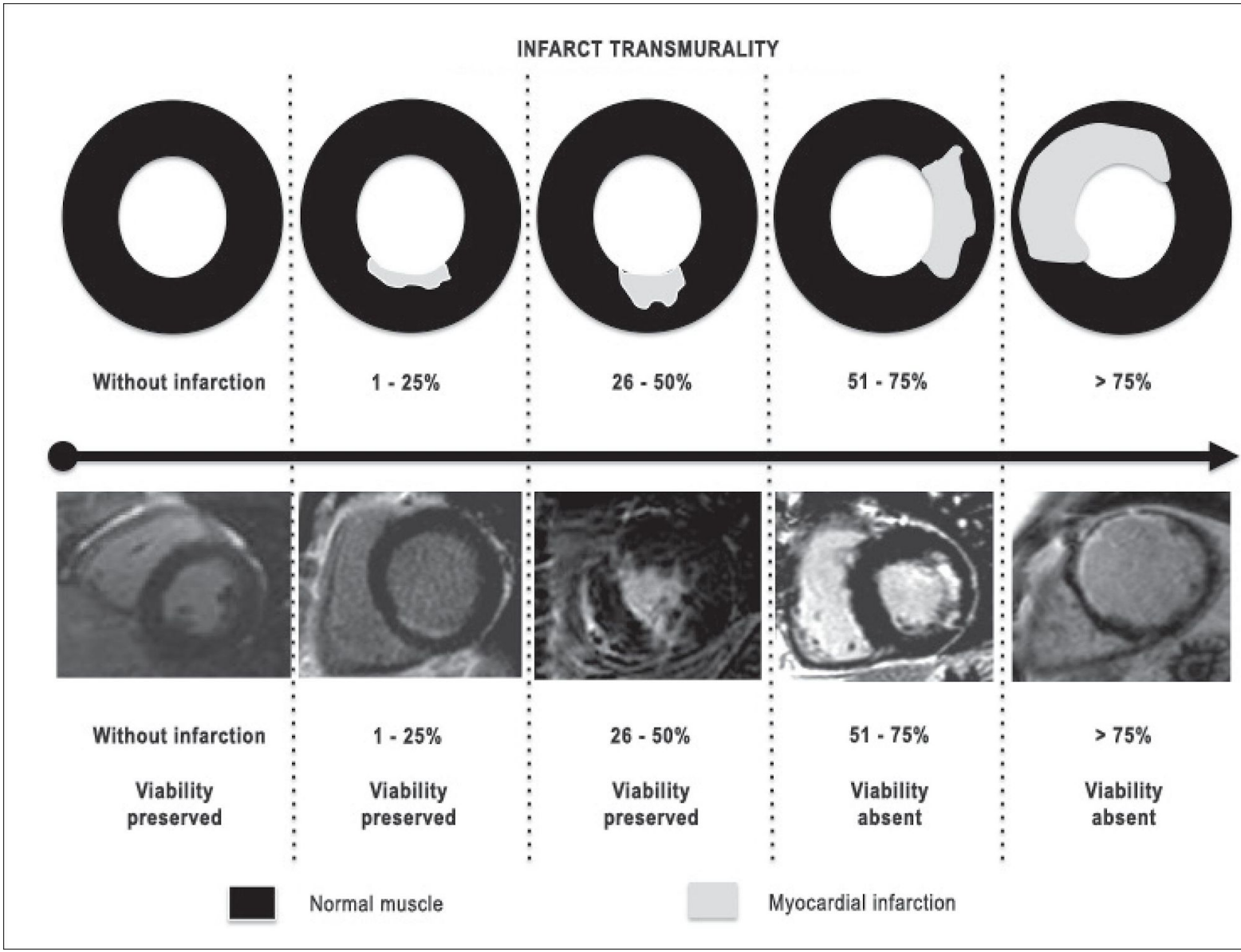
INFARCT TRANSMURALITY
Without infarction
1 - 25%
26 - 50%
51 - 75%
> 75%
Without infarction
1 - 25%
26 - 50%
51 - 75%
> 75%
Viability preserved
Viability preserved
Viability preserved
Viability absent
Viability absent
Normal muscle
Myocardial infarction

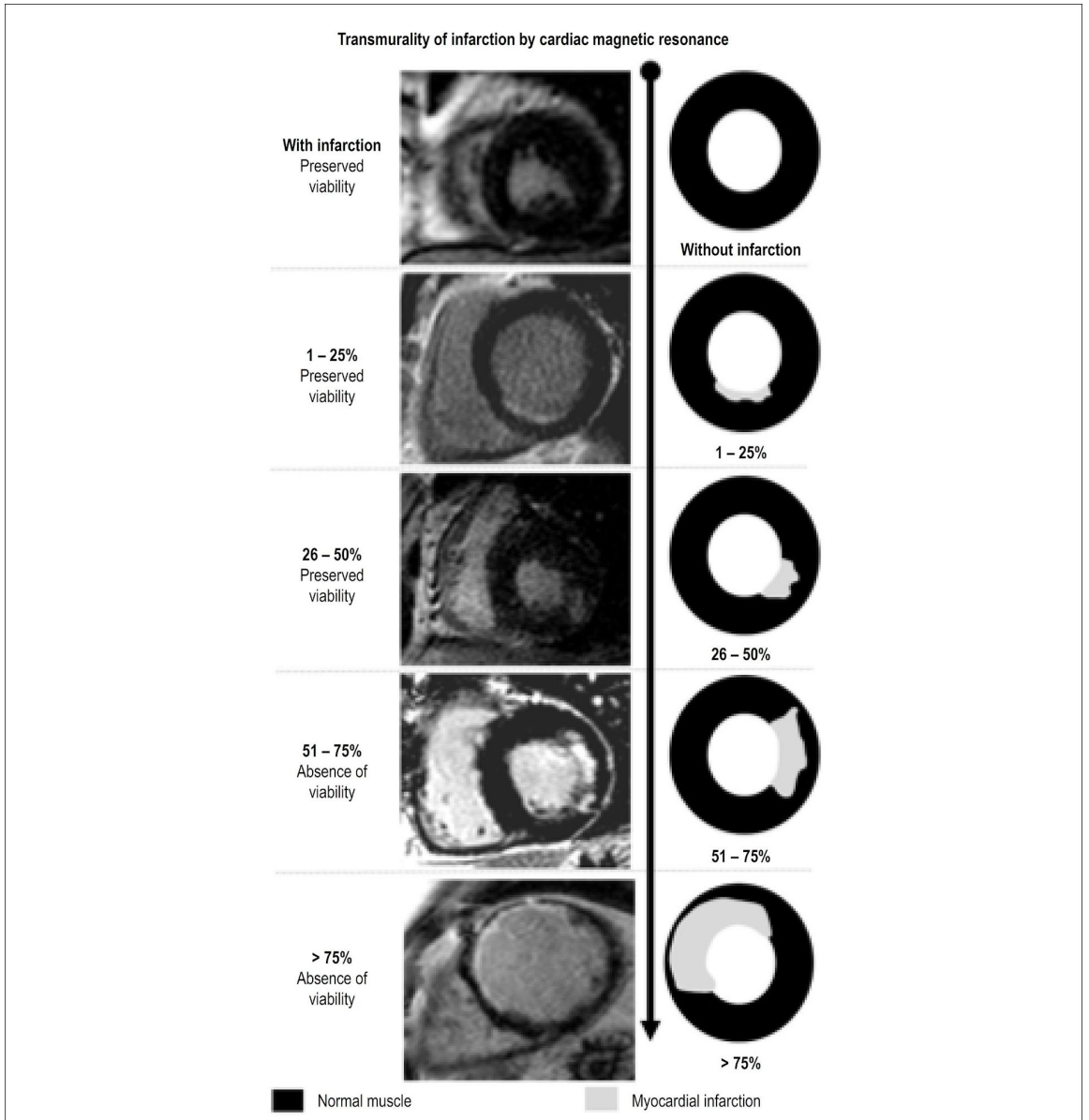
Transmurality of infarction by cardiac magnetic resonance
With infarction
Preserved
viability
Without infarction
1 – 25%
Preserved
viability
1 – 25%
26 – 50%
Preserved
viability
26 – 50%
51 – 75%
Absence of
viability
51 – 75%
> 75%
Absence of
viability
> 75%
Normal muscle
Myocardial infarction

F1. Myocardial Mass in Hypertrophic vs. Normal Left Ventricles

Papillary muscles included in myocardial mass calculation

+	+	+	-	-	-

Hypertrophic cardiomyopathy

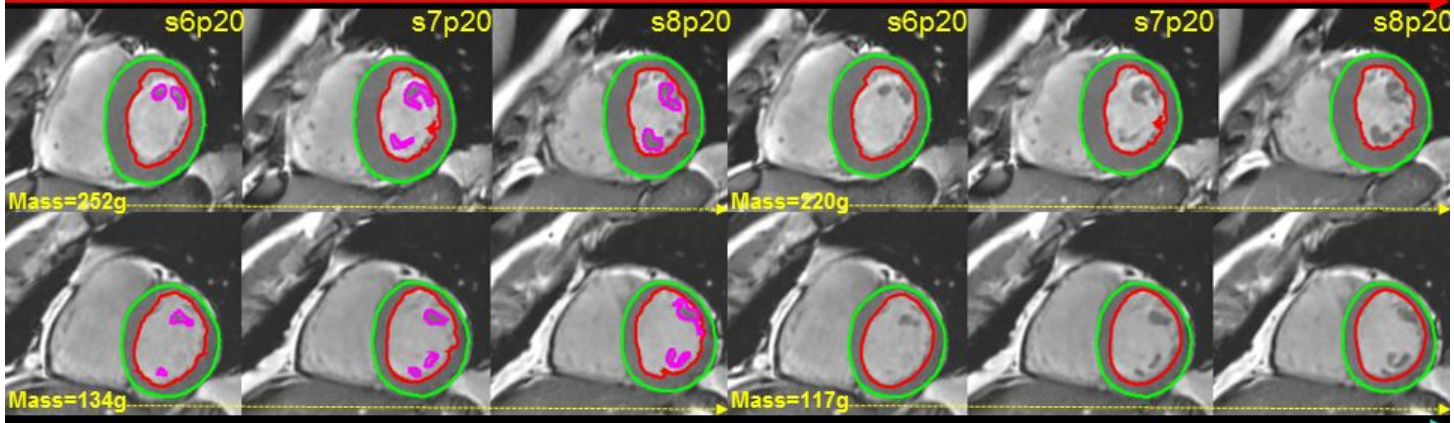

Normal

P=Phase. S=Slice.

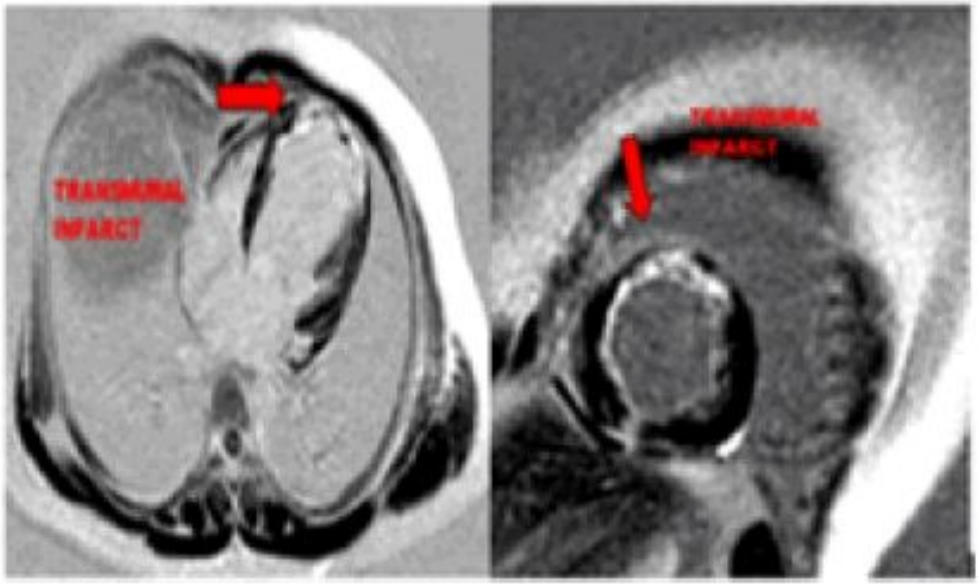

Figure 2a: Cardiac MRI short and horizontal axis showing transmural infarct (arrows) involving the apical, apical anterior, antero-septal segments.

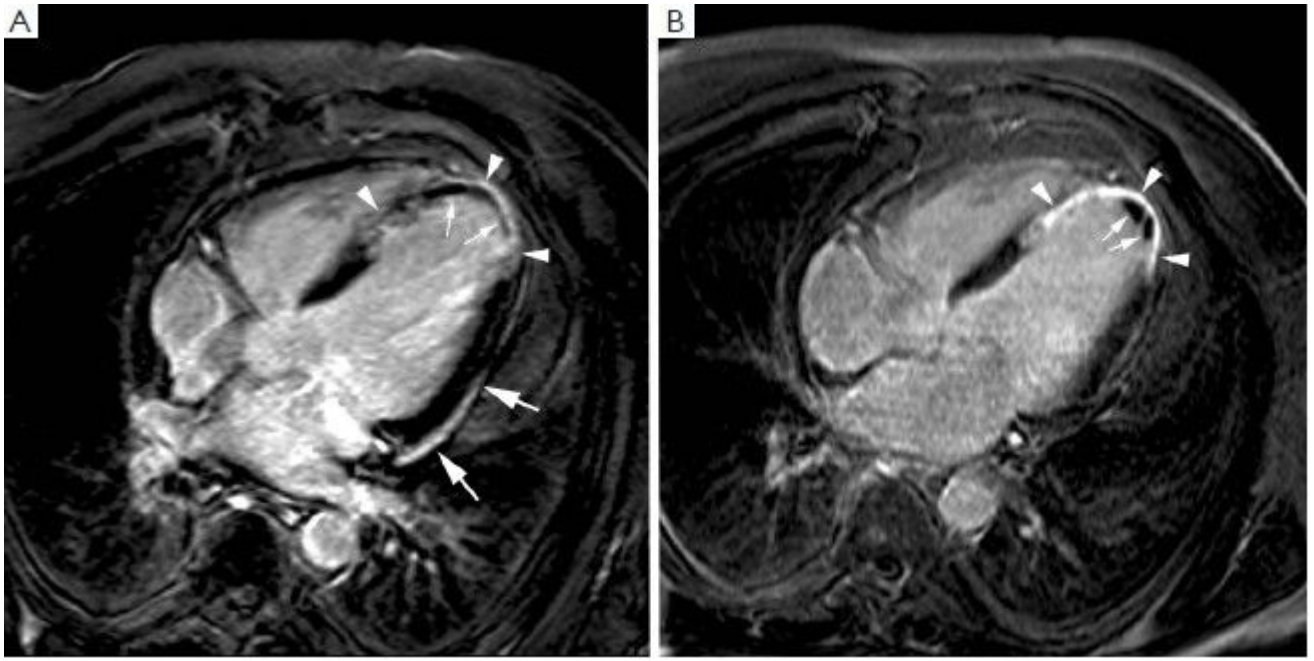

Late gadolinium imaging in horizontal image plane at 1 week (A) and 4 months (B) after the acute event. At 1 week, presence of diffuse enhancement of the apical part of the ventricular septum and LV apex (arrowheads, A) with large area of microvascular obstruction (small arrows, A). Note the presence of some pericardial enhancement over the laterobasal part of the LV (arrows, A). At 4 month follow-up, the infarct has thinned and strongly enhances (arrowheads, B). Note the presence of a small mural thrombus in LV apex (arrows, B)

LV ventricle apex thrombus

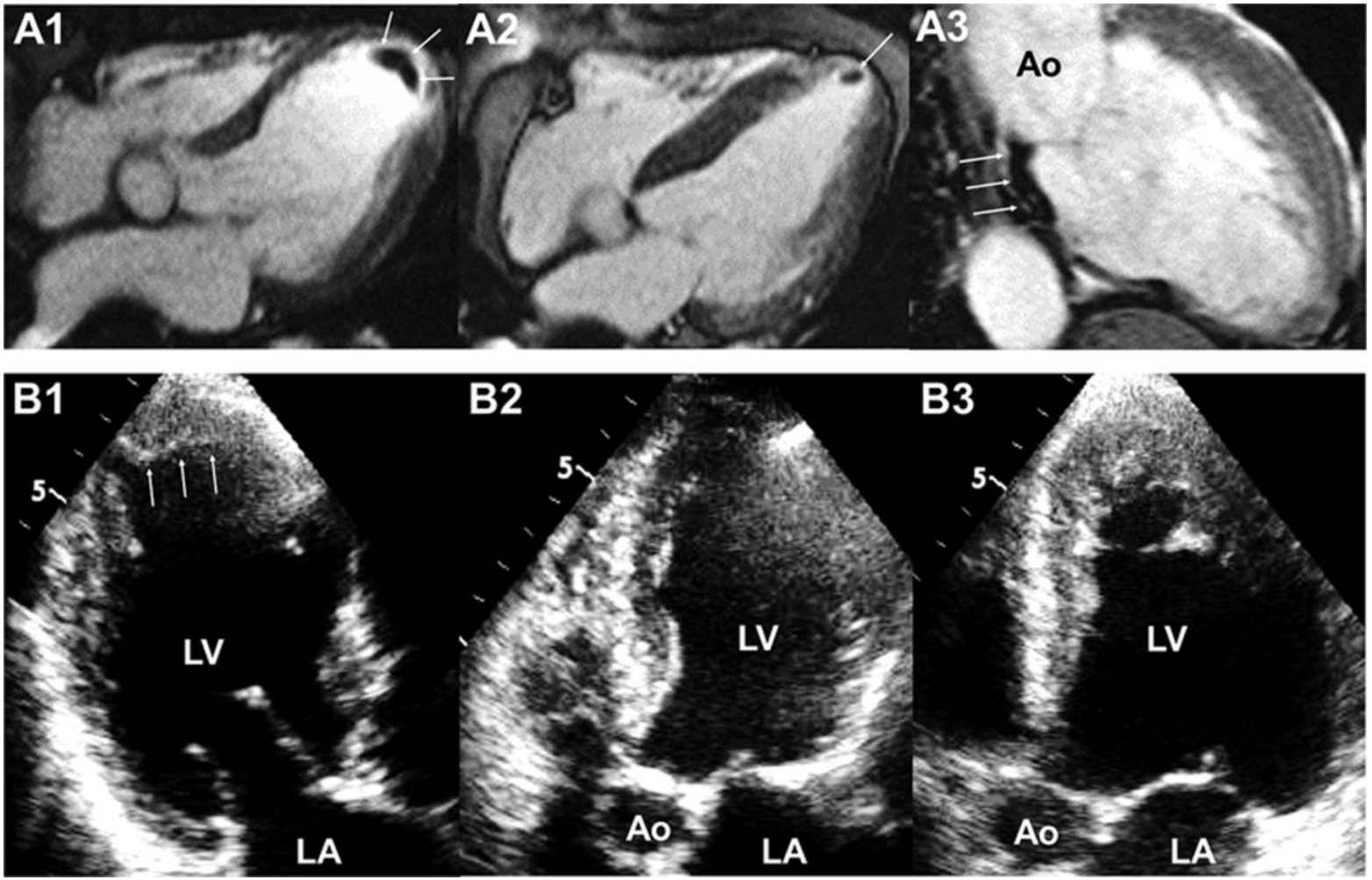

Myxoma at RT atrium bulging inside the RT ventricle.

