CARDIAC IMAGING
X-RAY

DR. MOHAMAD MATAR

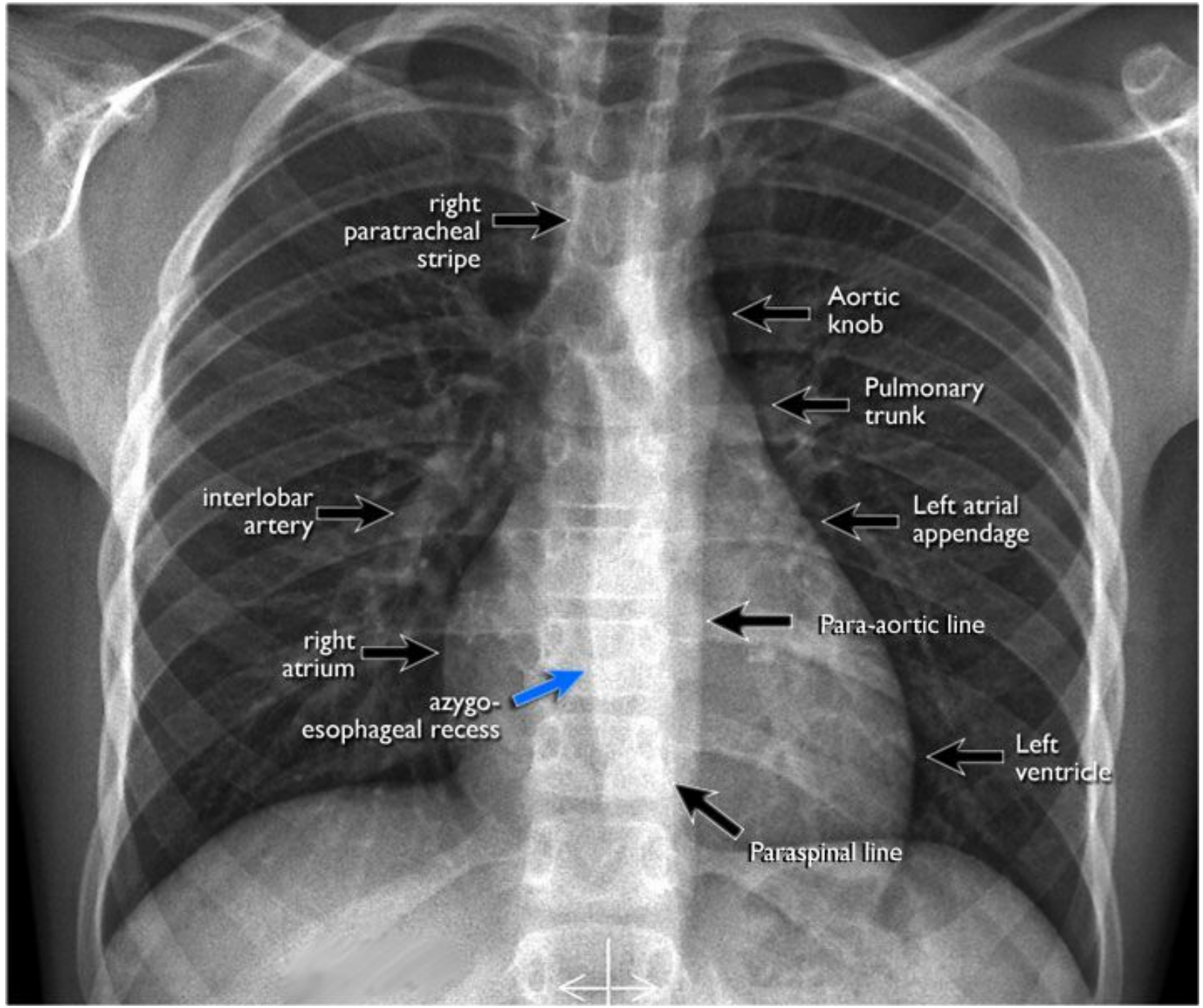
right paratracheal stripe
Aortic knob
Pulmonary trunk
interlobar artery
Left atrial appendage
Para-aortic line
right atrium
azygo-esophageal recess
Left ventricle
Paraspinal line

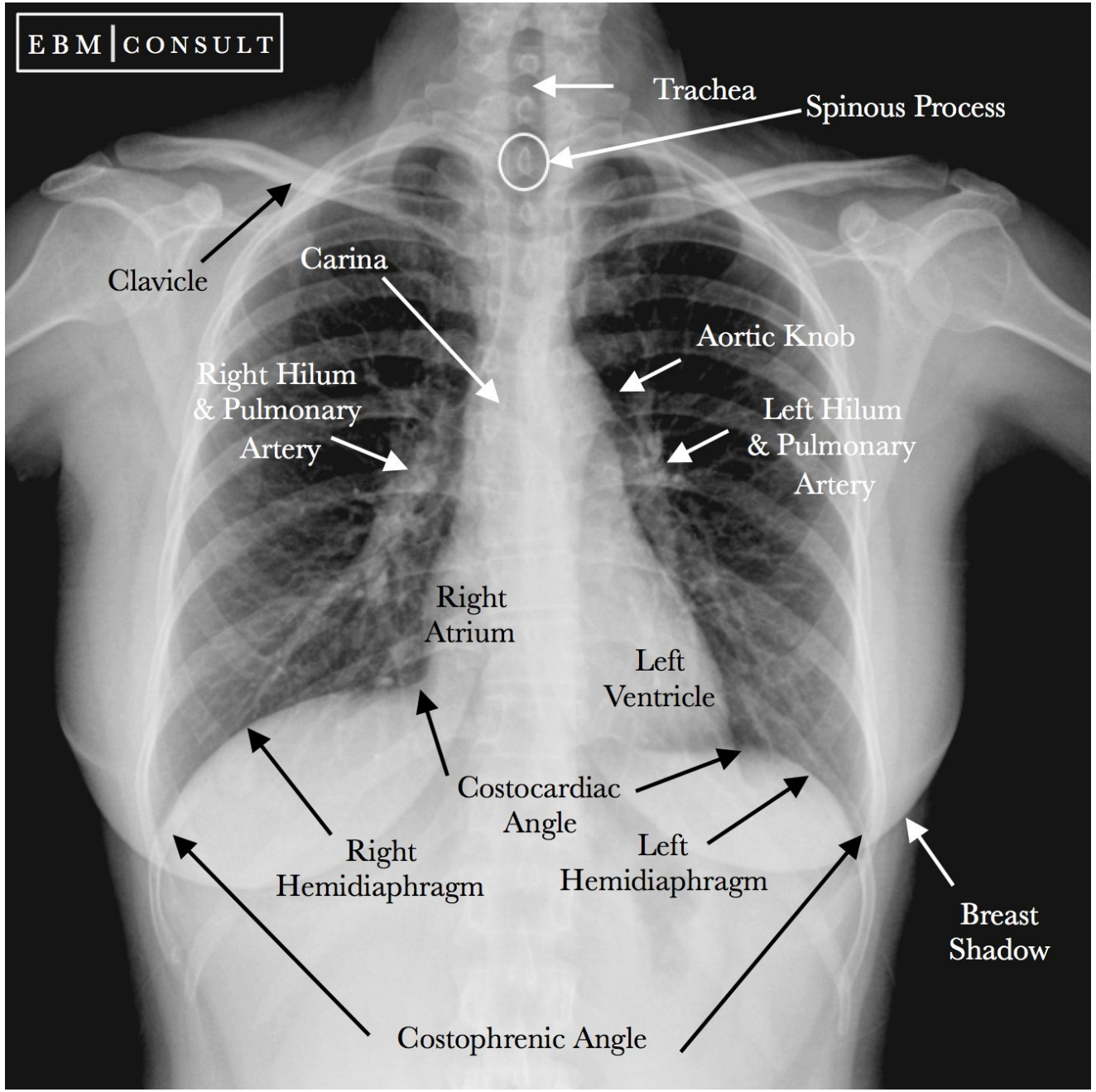
EBM | CONSULT
Trachea
Spinous Process
Clavicle
Carina
Aortic Knob
Right Hilum & Pulmonary Artery
Left Hilum & Pulmonary Artery
Right Atrium
Left Ventricle
Costocardiac Angle
Right Hemidiaphragm
Left Hemidiaphragm
Breast Shadow
Costophrenic Angle

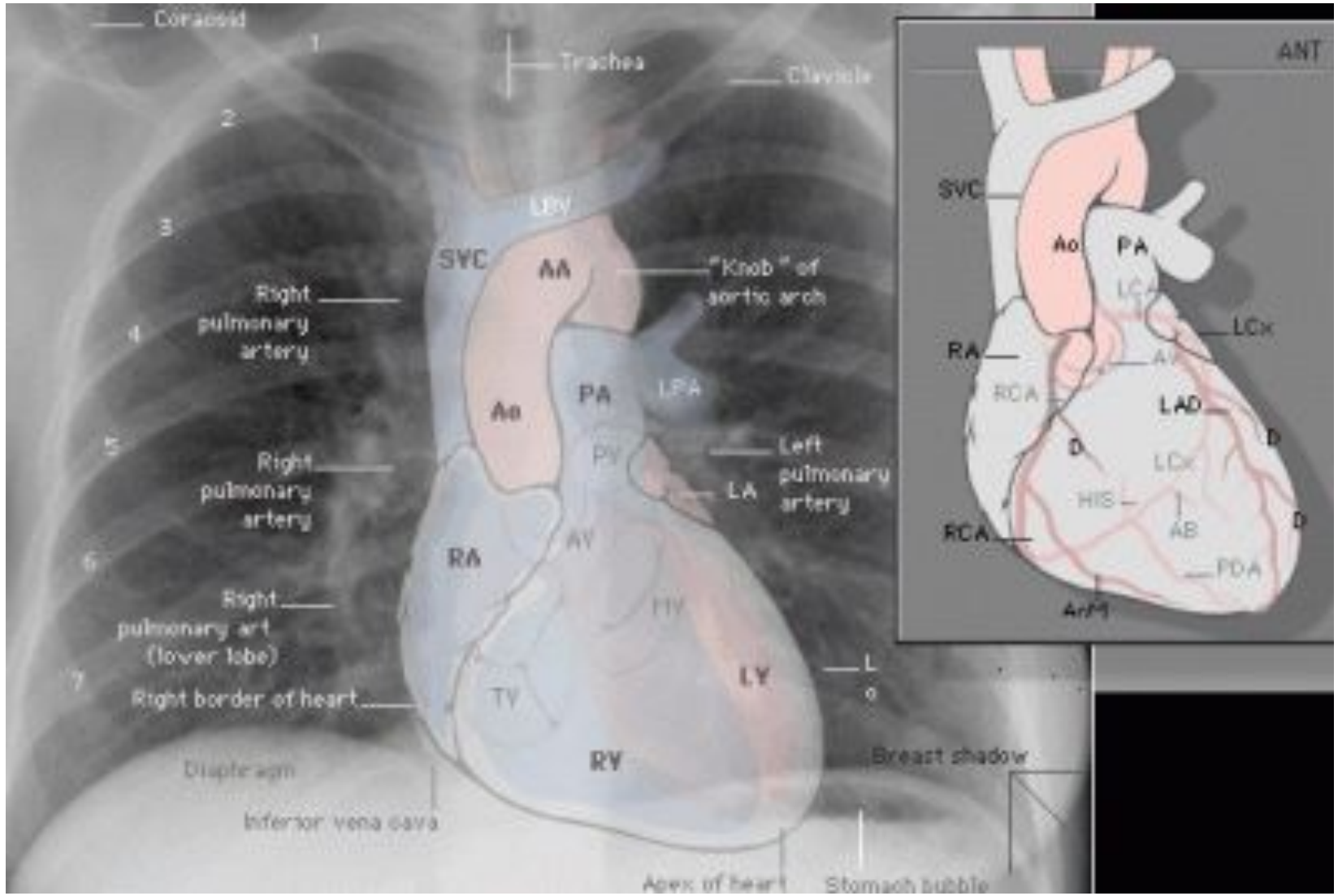
Coracoid
1
2
3
4
5
6
7
Trachea
Clavicle
LBV
SVC
AA
"Knob" of aortic arch
Right pulmonary artery
Ao
PA
LPA
Right pulmonary artery
PV
Left pulmonary artery
LA
RA
AV
Right pulmonary art (lower lobe)
RV
Right border of heart
TV
LV
L
o
Diaphragm
Inferior vena cava
Apex of heart
Breast shadow
Stomach bubble
ANT
SVC
Ao
PA
LCA
LCx
RA
RCA
LAD
D
D
LCx
HIS
AB
D
RCA
PDA
Aorta

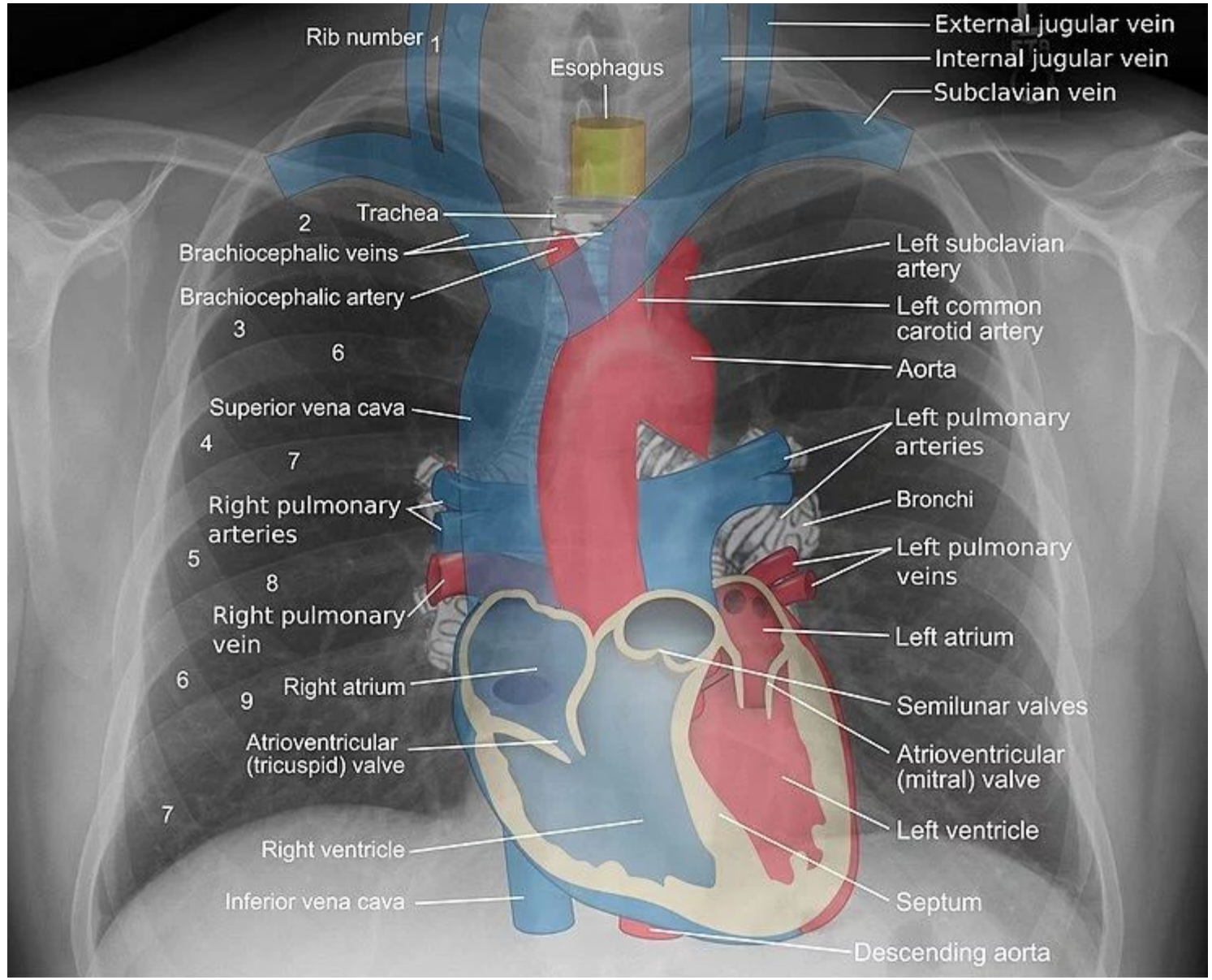
Rib number 1
Esophagus
External jugular vein
Internal jugular vein
Subclavian vein
2
Trachea
Brachiocephalic veins
Brachiocephalic artery
Left subclavian artery
Left common carotid artery
3
6
Aorta
Superior vena cava
Left pulmonary arteries
4
7
Right pulmonary arteries
Bronchi
5
Left pulmonary veins
8
Right pulmonary vein
Left atrium
6
9
Right atrium
Semilunar valves
Atrioventricular (tricuspid) valve
Atrioventricular (mitral) valve
7
Left ventricle
Right ventricle
Septum
Inferior vena cava
Descending aorta

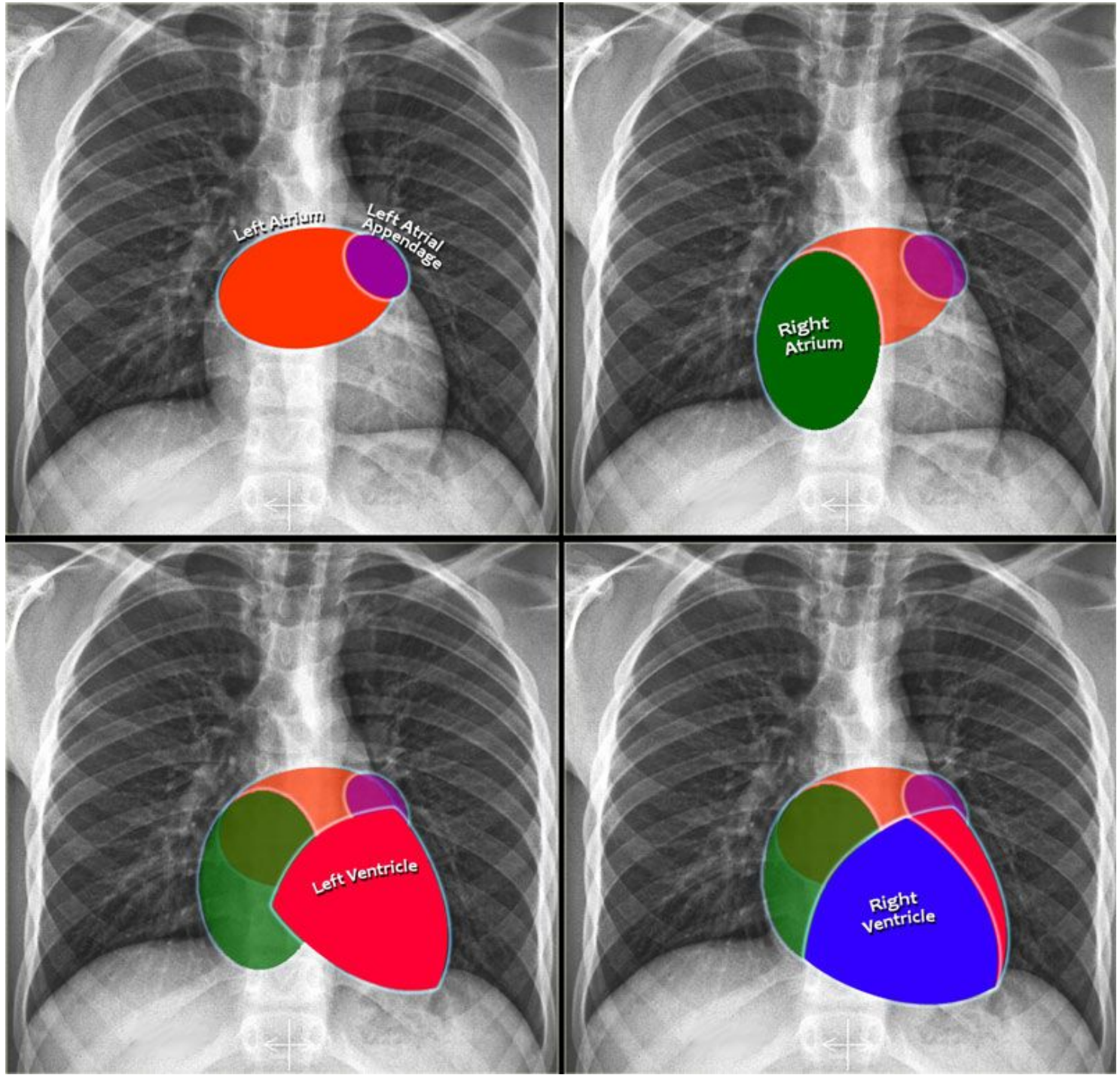
Left Atrium
Left Atrial Appendage
Right Atrium
Left Ventricle
Right Ventricle

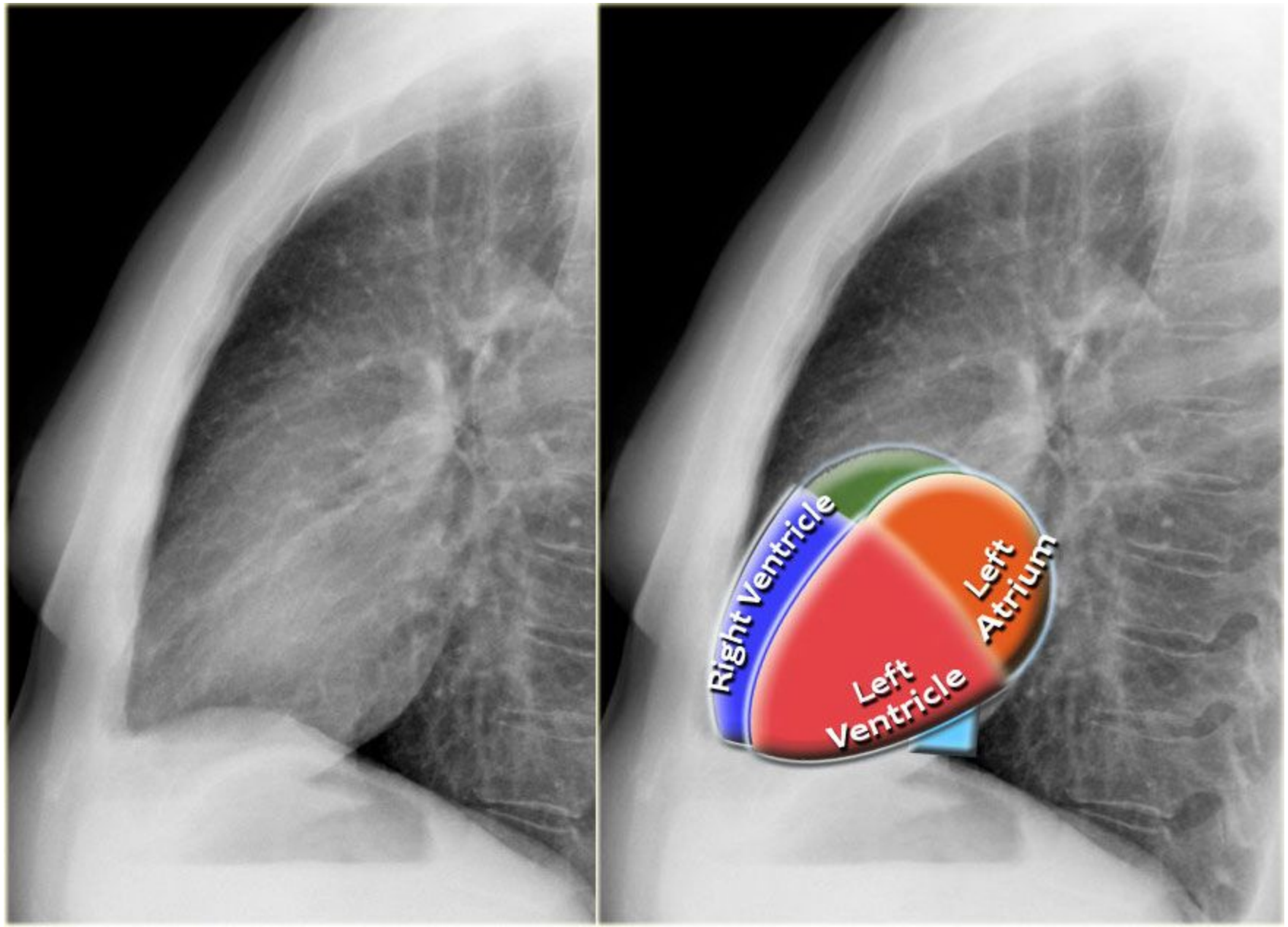
Right Ventricle
Left Atrium
Left Ventricle

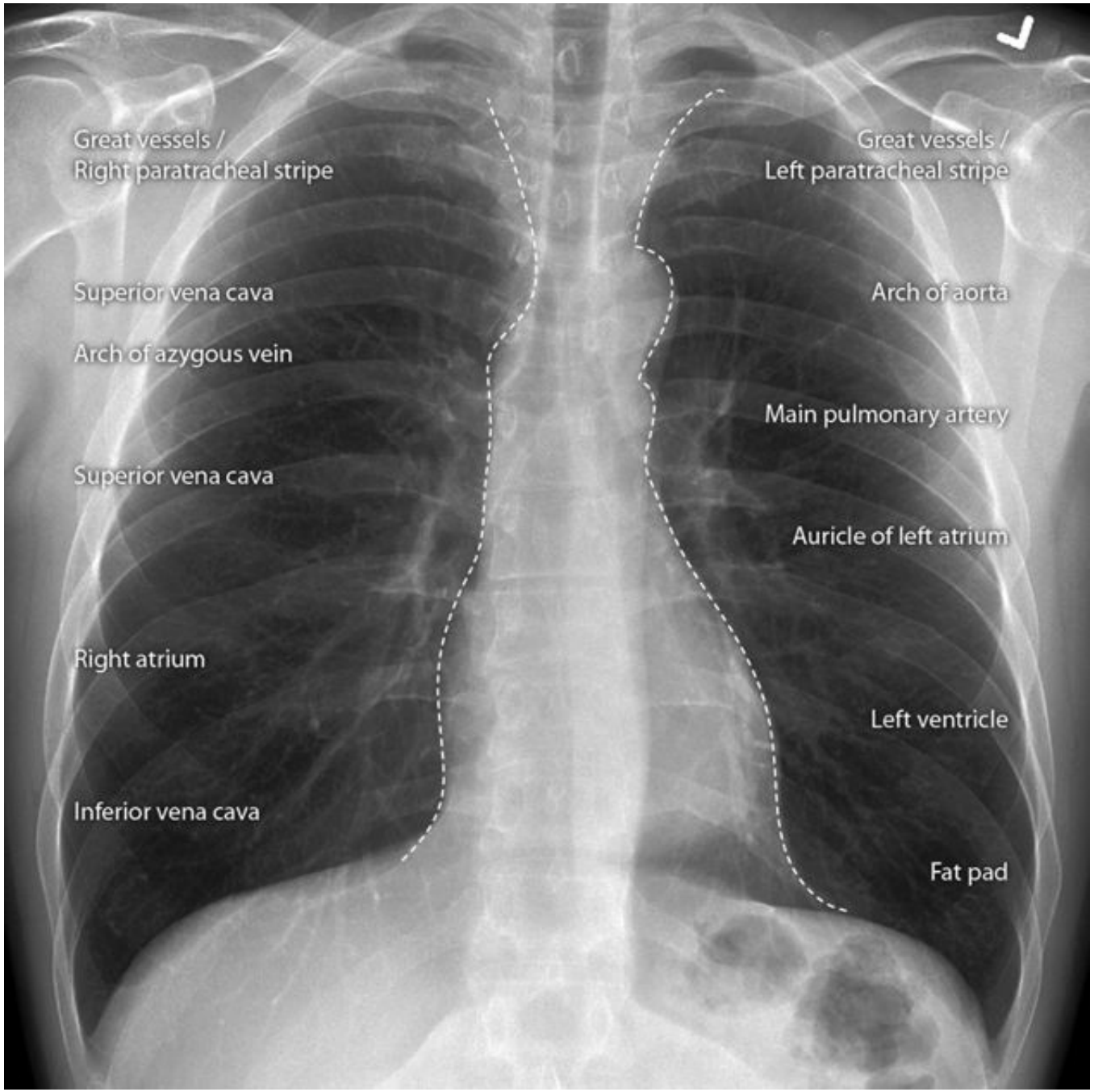
Great vessels /
Right paratracheal stripe
Superior vena cava
Arch of azygous vein
Superior vena cava
Right atrium
Inferior vena cava
Great vessels /
Left paratracheal stripe
Arch of aorta
Main pulmonary artery
Auricle of left atrium
Left ventricle
Fat pad

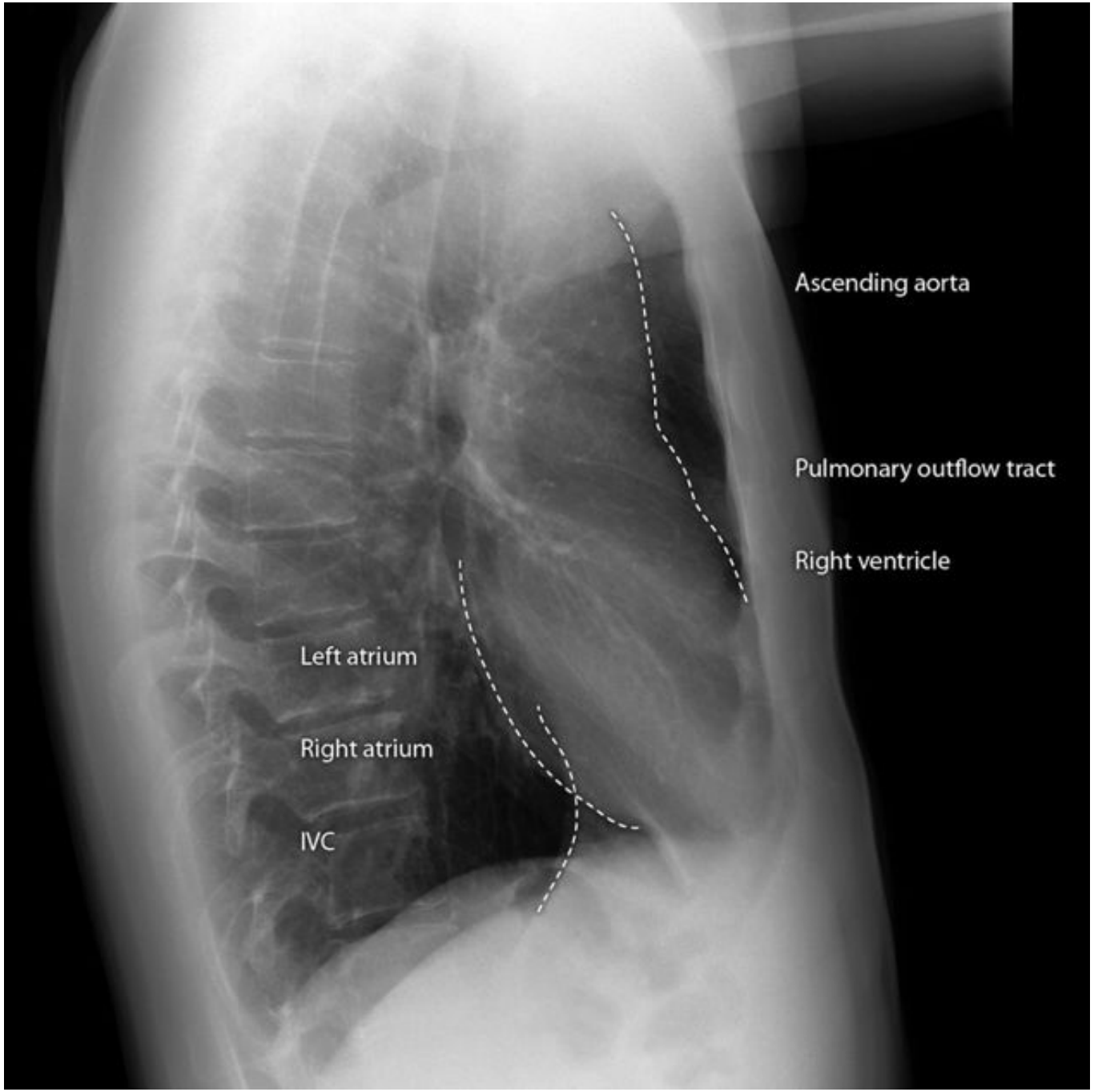
Ascending aorta
Pulmonary outflow tract
Right ventricle
Left atrium
Right atrium
IVC

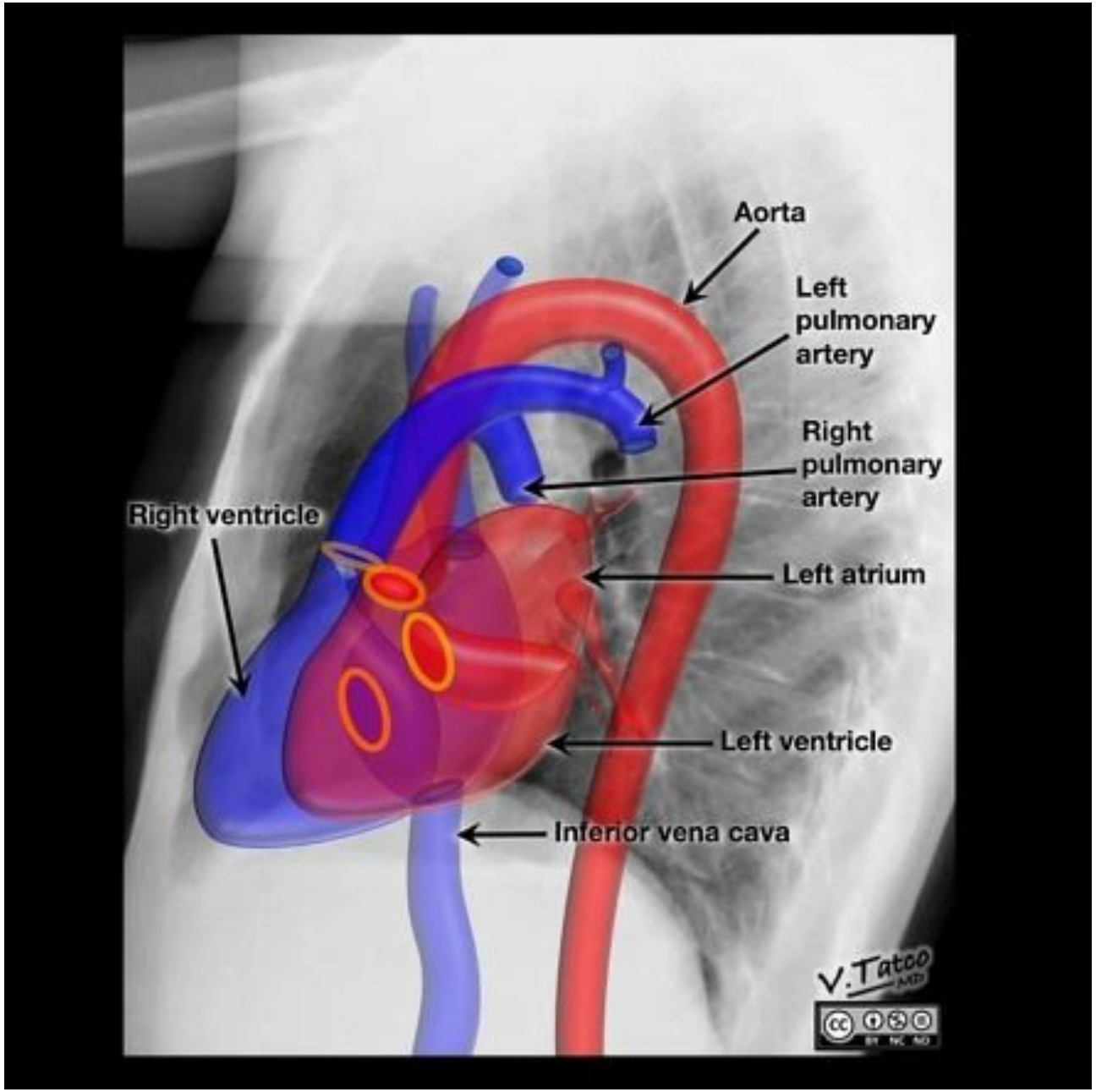
Aorta
Left pulmonary artery
Right pulmonary artery
Right ventricle
Left atrium
Left ventricle
Inferior vena cava
V.Tatoo MD

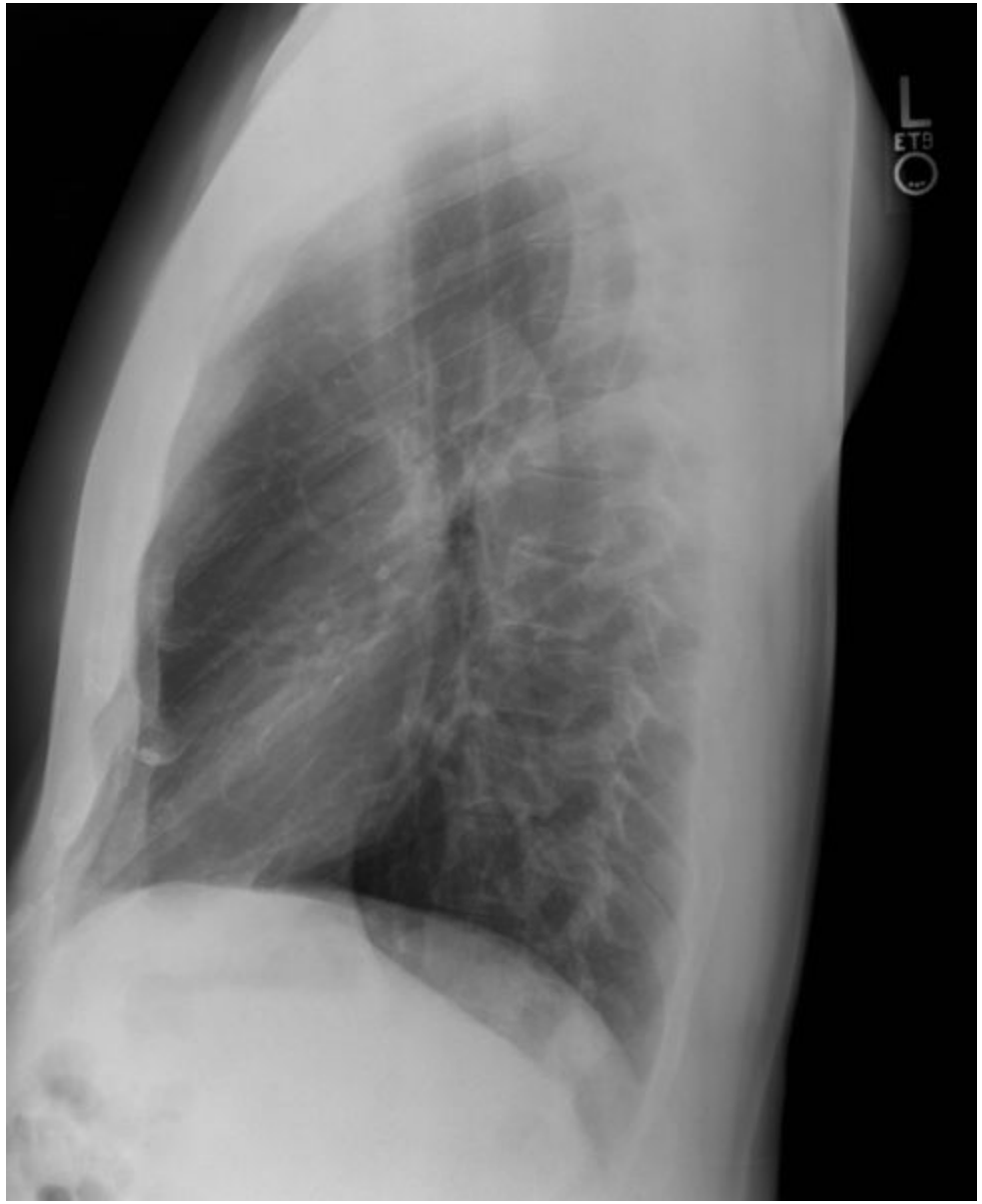
L

CARDIOMEGALY

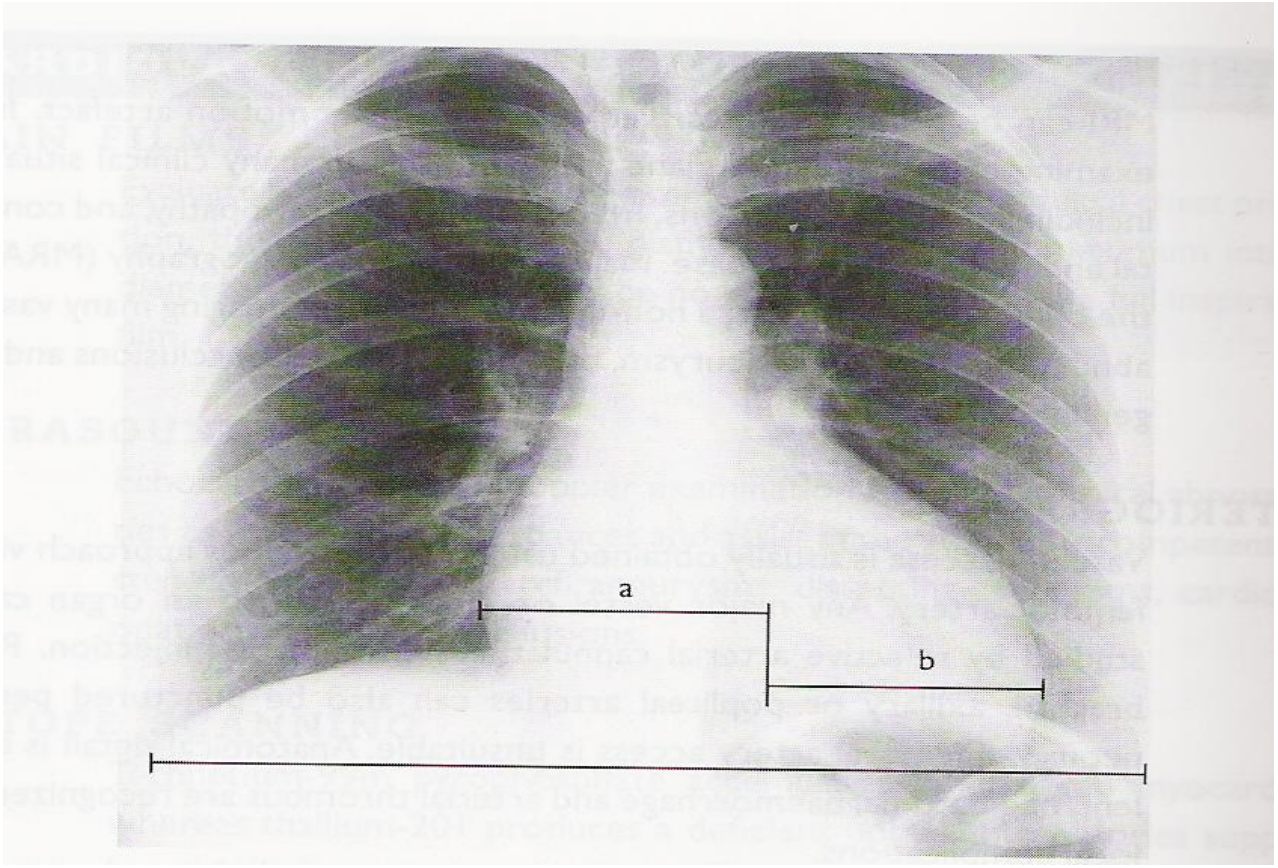

LT ATRIUM ENLARGEMENT

Causes

- acquired
  - mitral stenosis
  - mitral regurgitation
  - left ventricular failure
  - left atrial myxoma
- congenital
  - ventricular septal defect (VSD)
  - patent ductus arteriosus (PDA)

Direct visualisation of the enlarged atrium includes:

Double density sign

when the right side of the left atrium pushes into the adjacent lung, and becomes visible superimposed or even beyond the normal right heart border (known as atrial escape)

a similar appearance can be caused by the right superior pulmonary vein in patients without atrial enlargement .

oblique measurement : of greater than 7cm measured from mid point of left main bronchus to the right border of the left atrium (this requires a double density sign of course)

this is thought to be the most reliable sign on chest radiography

convex left atria appendage:

normally the left heart border just below the pulmonary outflow track should be flat or slightly concave

Indirect signs include:

- splaying of the carina, with increase of the tracheal bifurcation angle to over 90 degrees
    - This refers to both the inter-bronchial angle (i.e angle formed by the central axis of the left and right main bronchi) and the subcarinal angle.
    - Both are inaccurate and dependent on radiographer technique, inspiration and body habitus .
    - The mean and range of both measurements vary widely in normal individuals.
        - interbronchial angle: normal mean 67-77° (with a range 34-109°)
        - subcarinal angle: normal mean 62-73° (range 34-90°)
- posterior displacement of the left main stem bronchus on lateral radiograph
    - right and left bronchi therefore do not overlap, but rather form an upside down 'V', sometimes referred to as the walking man sign [5]
- superior displacement of the left main stem bronchus on frontal view
- posterior displacement of a barium filled esophagus or nasogastric tube

Carinal angle

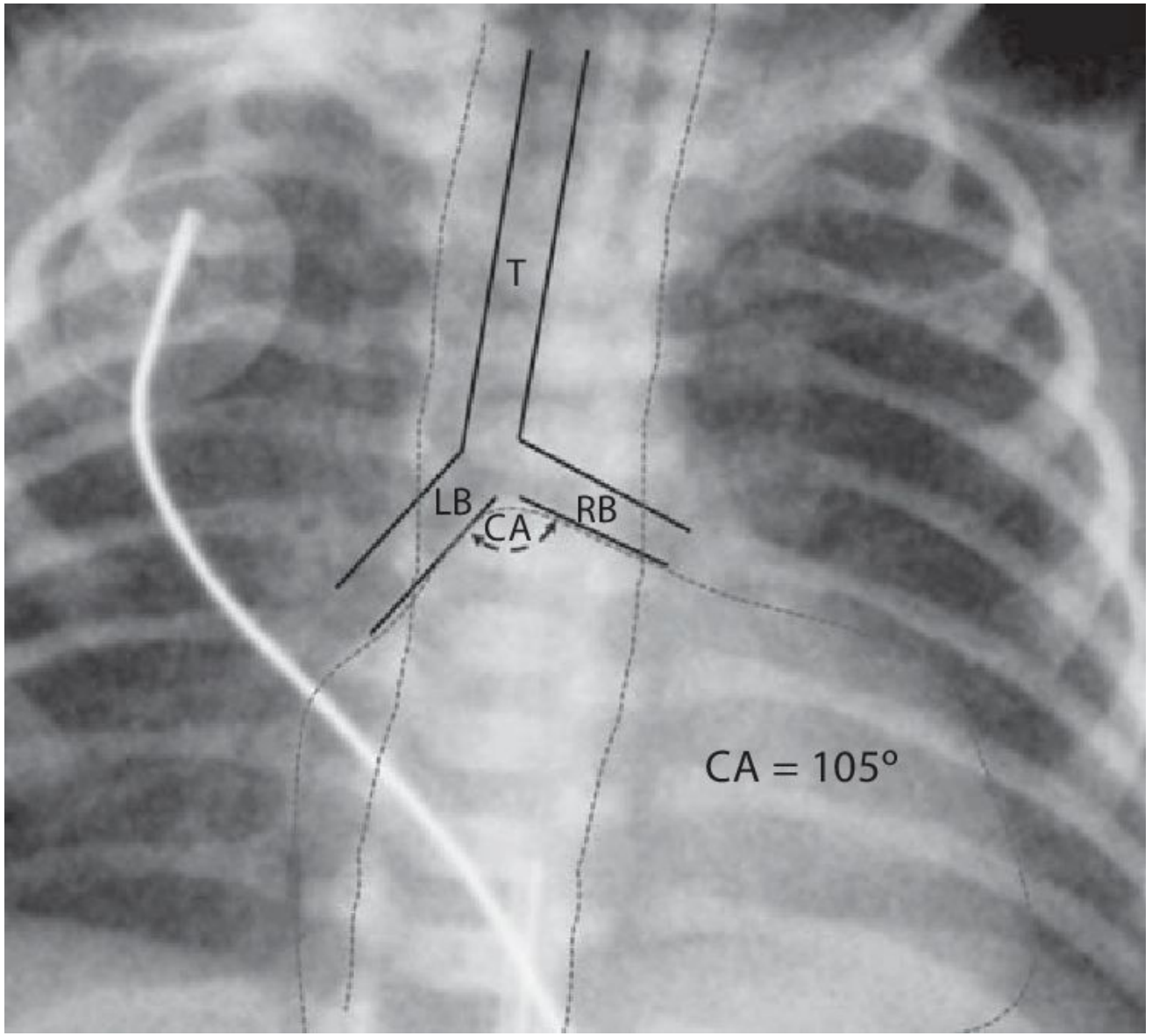

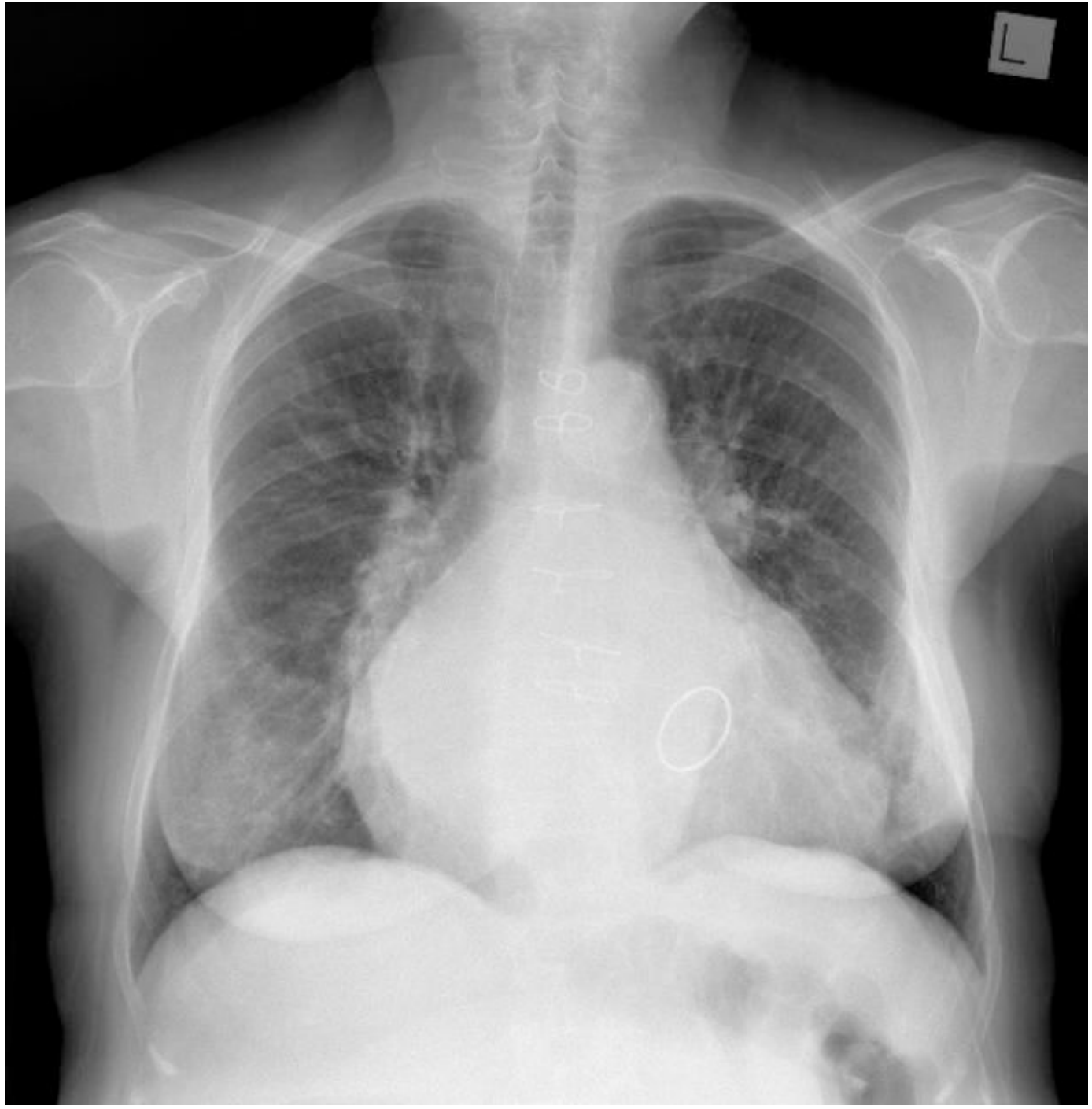
L

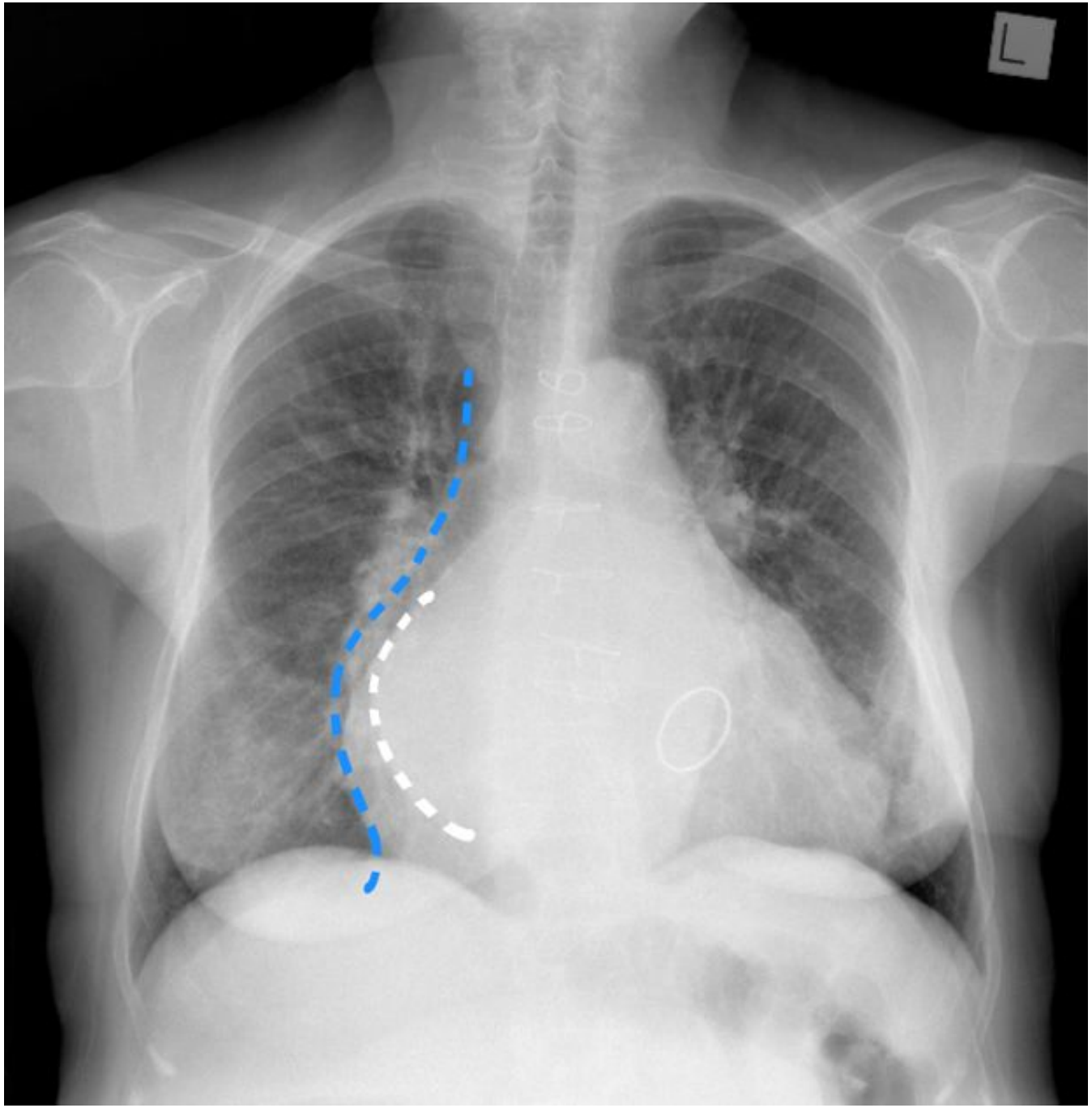
L

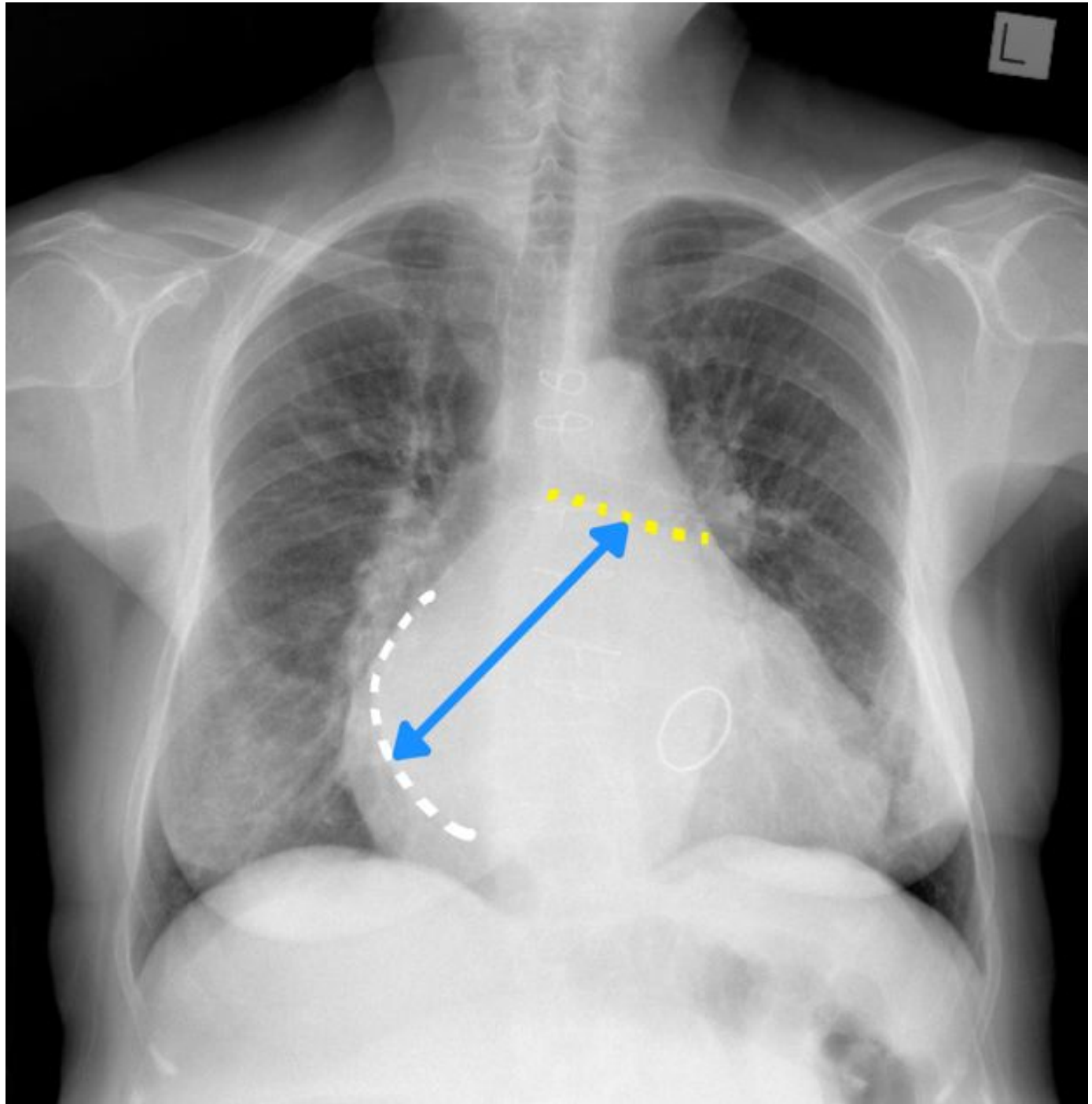
L

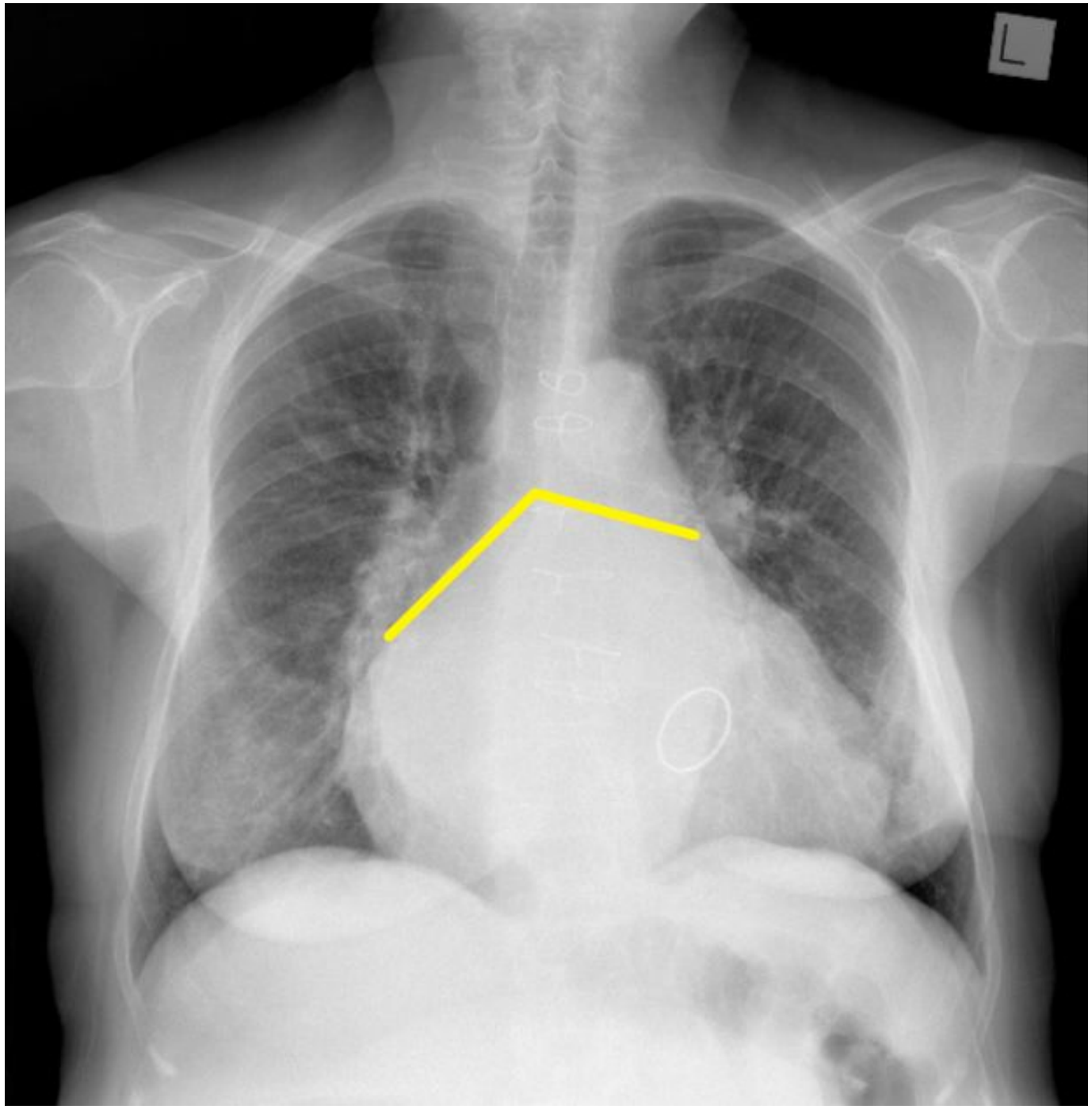
L


L

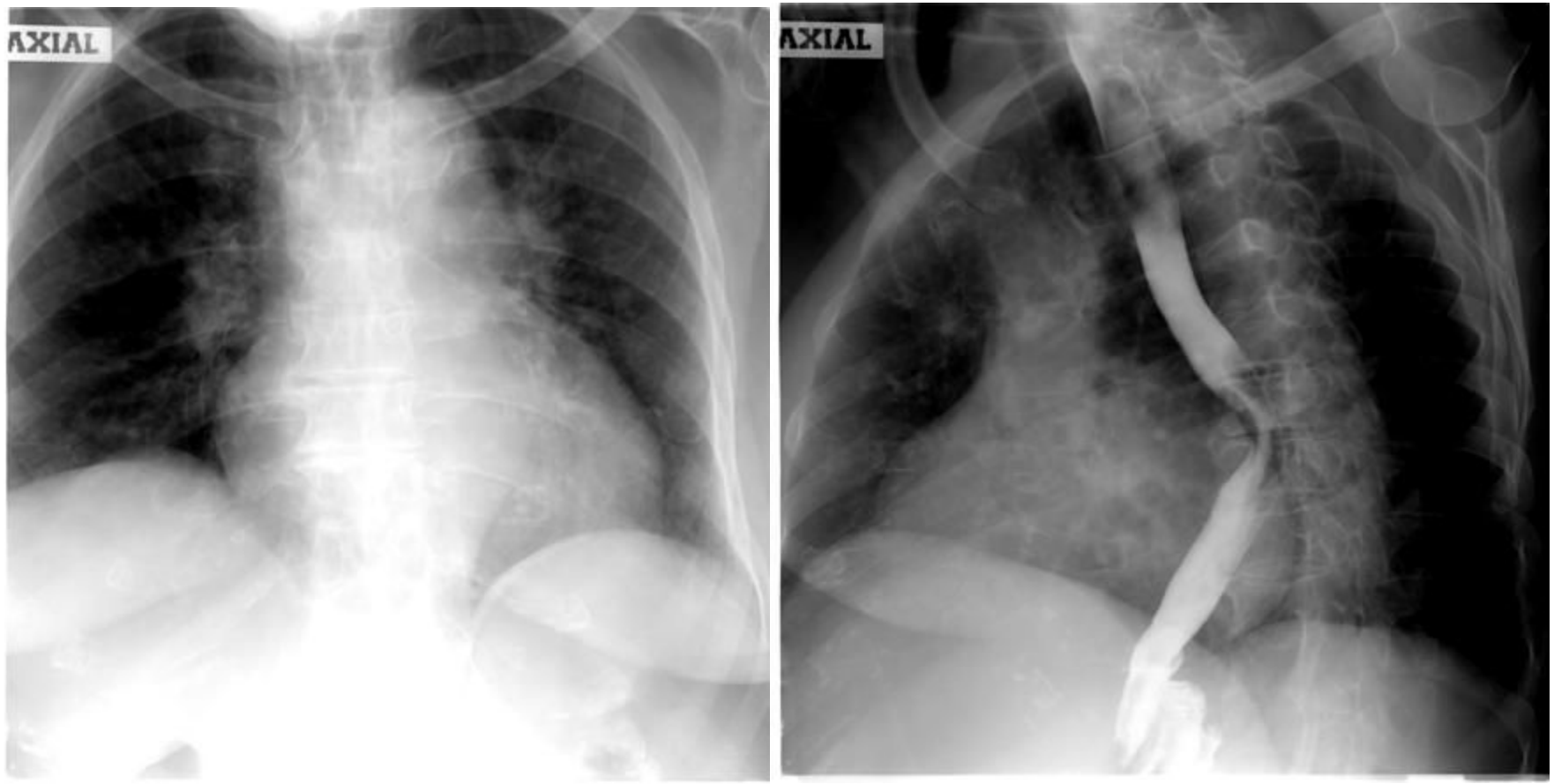
AXIAL
AXIAL

LT ATRIAUM

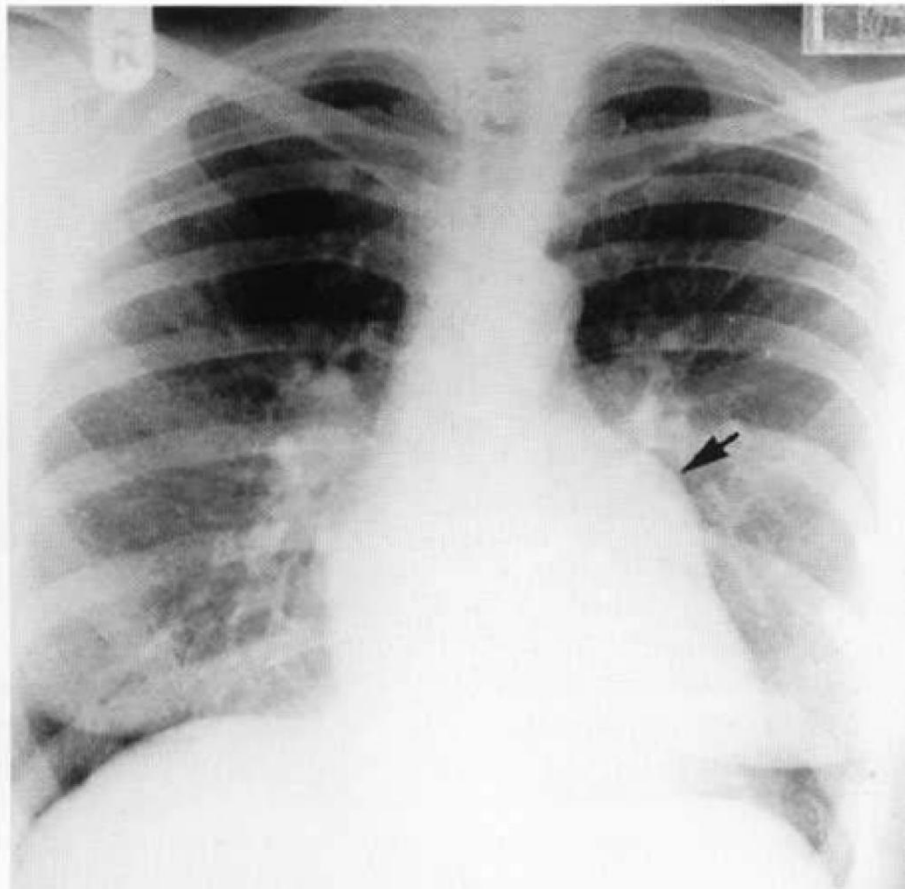

- Double density sign
- Carinal angle >90.
- Oblique measurement >7cm.
- Convex LT atrial appendage.

RT atrium

- RT heart boarder enlargement.
- Enlarged shadow of IVC & SVC .

Causes

- raised right ventricular pressures
  - pulmonary arterial hypertension
  - cor pulmonale
- valvular disease
  - tricuspid regurgitation
  - tricuspid stenosis
  - Ebstein's anomaly
- atrial septal defect (ASD)
- atrial fibrillation (AF)
- dilated cardiomyopathy

Radiographic features

- enlarged, globular heart
- narrow vascular pedicle
- gross enlargement of the right atrial shadow, i.e. increased convexity in the lower half of the right cardiac border

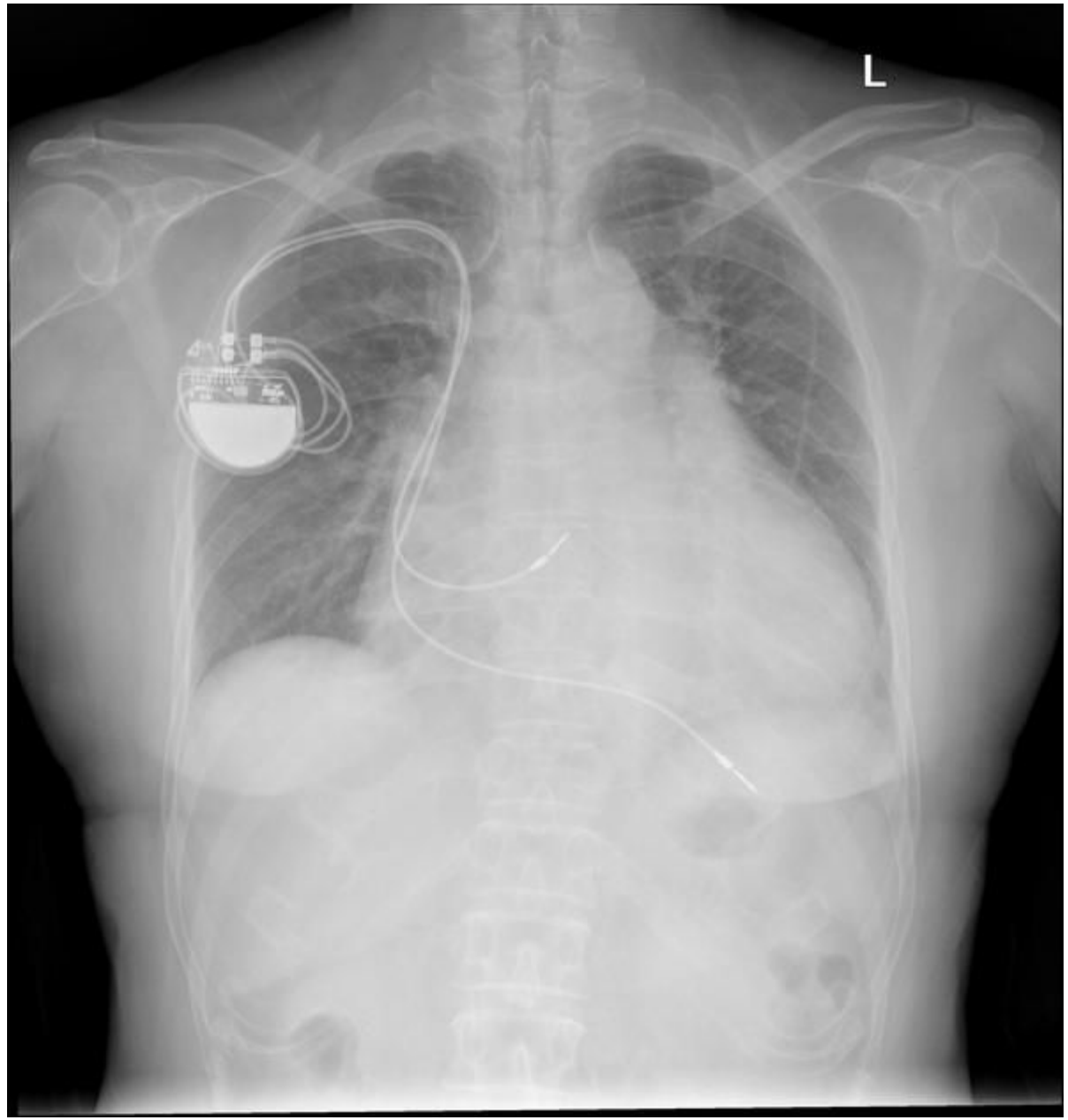
L

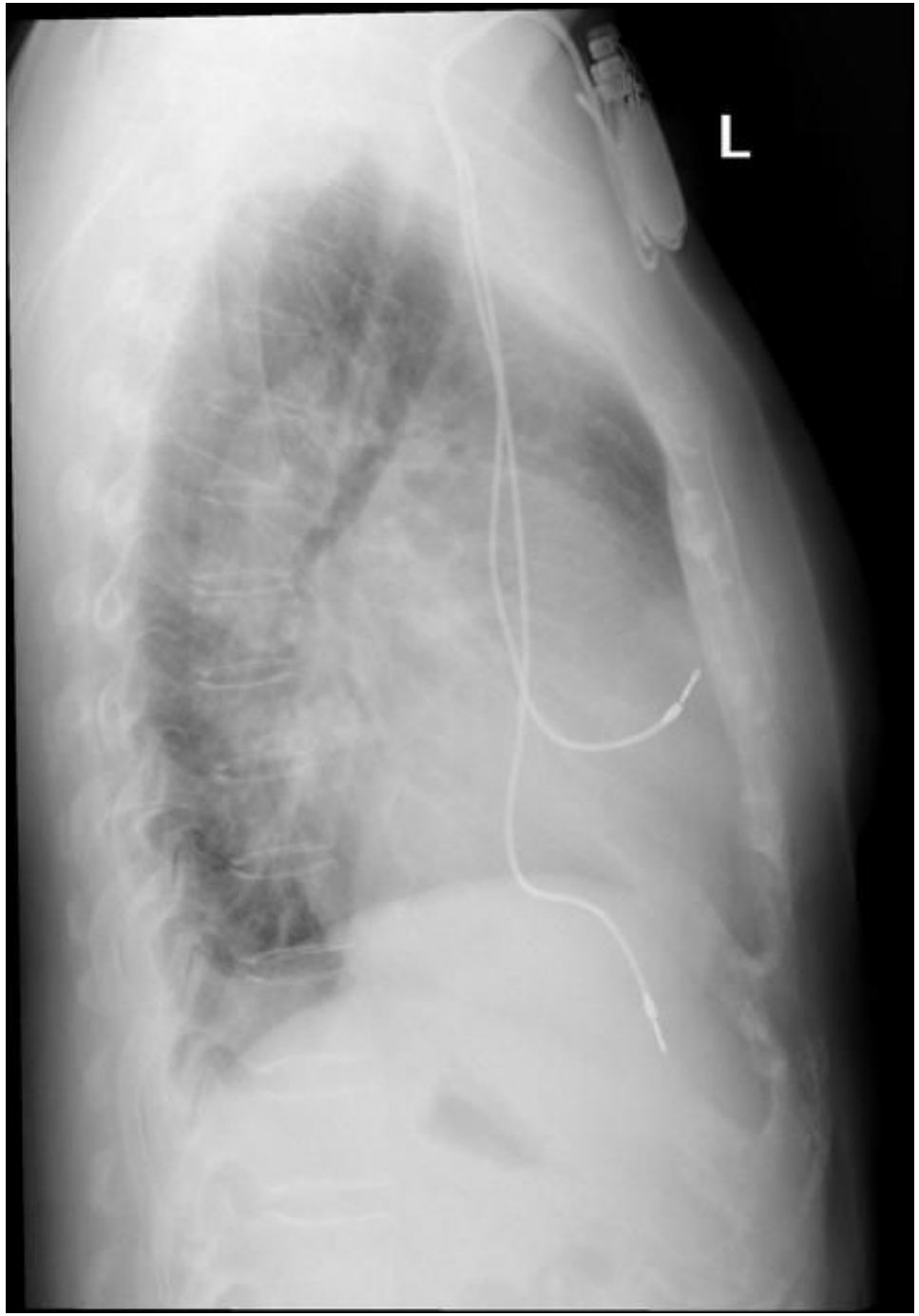
L



Fig. 17. Marked right atrial dilatation and right ventricular dilatation due to severe tricuspid regurgitation related to traumatic injury of the tricuspid valve

LT Ventricle Hypertrphy

- LVH itself is not a disease, it is usually a marker for disease involving the heart.
- Disease processes that can cause LVH include any disease that increases the afterload that the heart has to contract against, and some primary diseases of the muscle of the heart.

- **Left ventricular enlargement** can be the result of a number of condition, including:

- pressure overload
  - hypertension
  - aortic stenosis
- volume overload
  - aortic regurgitation
  - mitral regurgitation
- wall abnormalities
  - left ventricular aneurysm
  - hypertrophic cardiomyopathy

- Bulge in the LT heart boarder, down ward and lateral displacement of the cardiac apex.
- Rounded apex.
- Posterior displacement of heart in lateral x ray.
- Late signs:
    - LT atrial enlargement
    - Pulmonary congestion.
    - Prominent aortic arch.

LT VENTRICLE



Left ventricular aneurysm

Hover over image to show findings

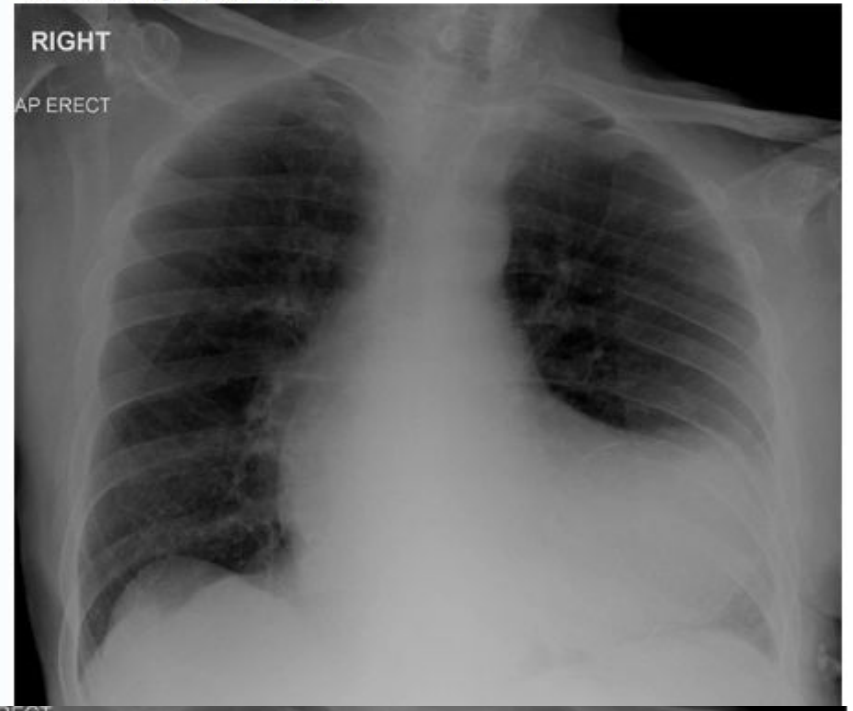

Left ventricular aneurysm

- AP erect chest x-ray
- Heart clearly enlarged despite the AP view
- Bulging left heart border
- Circular rim of calcification (arrowheads)

Clinical information

- Previous myocardial infarction

Diagnosis

- Left ventricular aneurysm - an uncommon complication of myocardial infarction

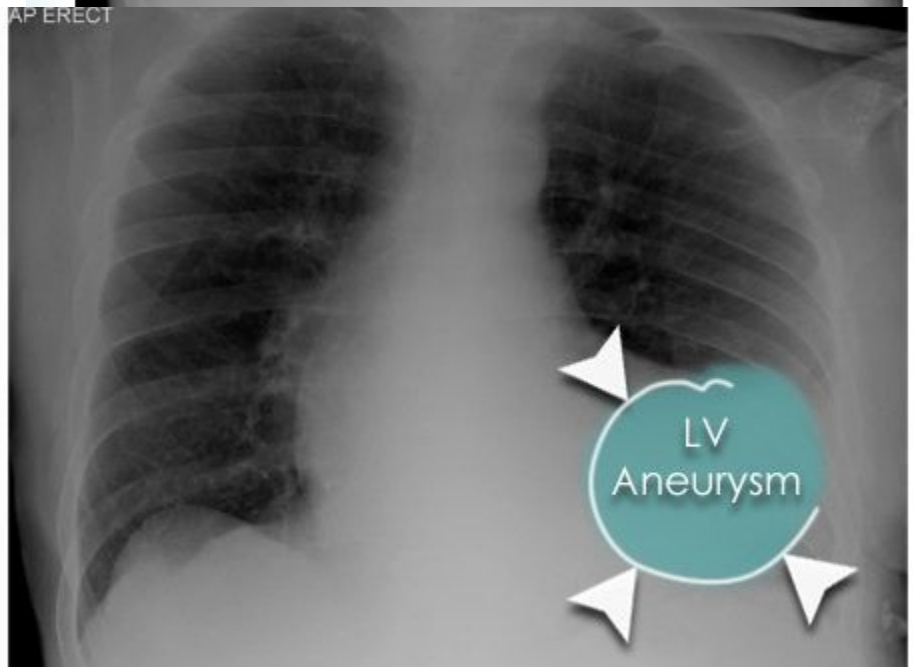

- Heart clearly enlarged despite the AP view
- Bulging left heart border
- Circular rim of calcification (arrowheads)

Clinical information

- Previous myocardial infarction

Diagnosis

- Left ventricular aneurysm - an uncommon complication of myocardial infarction

RT Ventricle Enlargement.

- AP view:
  - Up ward elevation of cardiac apex.
  - Transverse position of the heart.

- Lateral view demonstrates:
  - filling of the retrosternal space
  - rotation of the heart posteriorly

Right ventricular enlargement can be the result of a number of conditions, including :

- pulmonary valve stenosis
- pulmonary artery hypertension
- atrial septal defect
- tricuspid regurgitation
- dilated cardiomyopathy
- ASD
- VSD
- anomalous pulmonary venous drainage
- High altitude
- Cardiac fibrosis
- Chronic obstructive pulmonary disease (COPD)
- Athletic heart syndrome

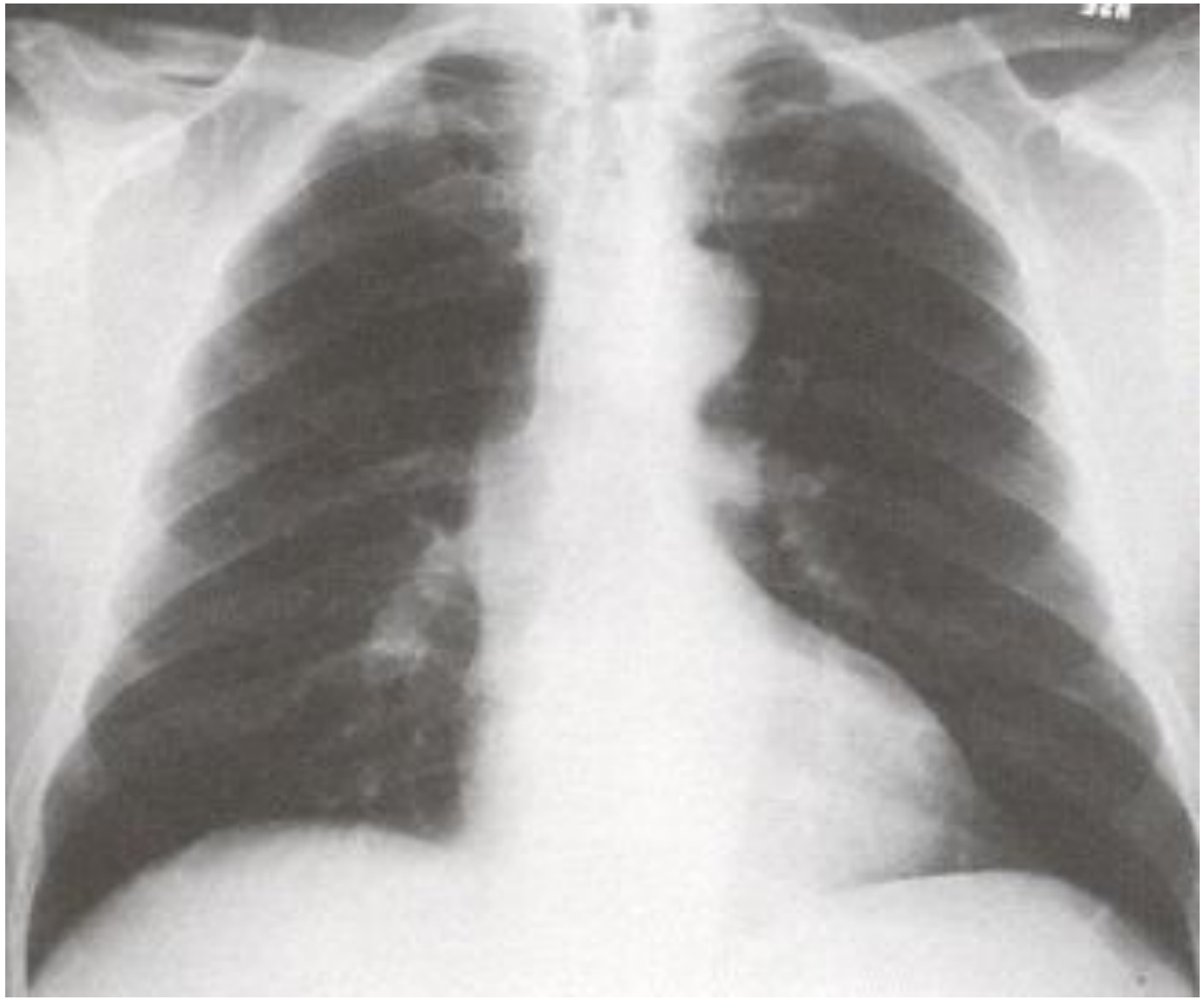

RT VENTRICLE (PS)



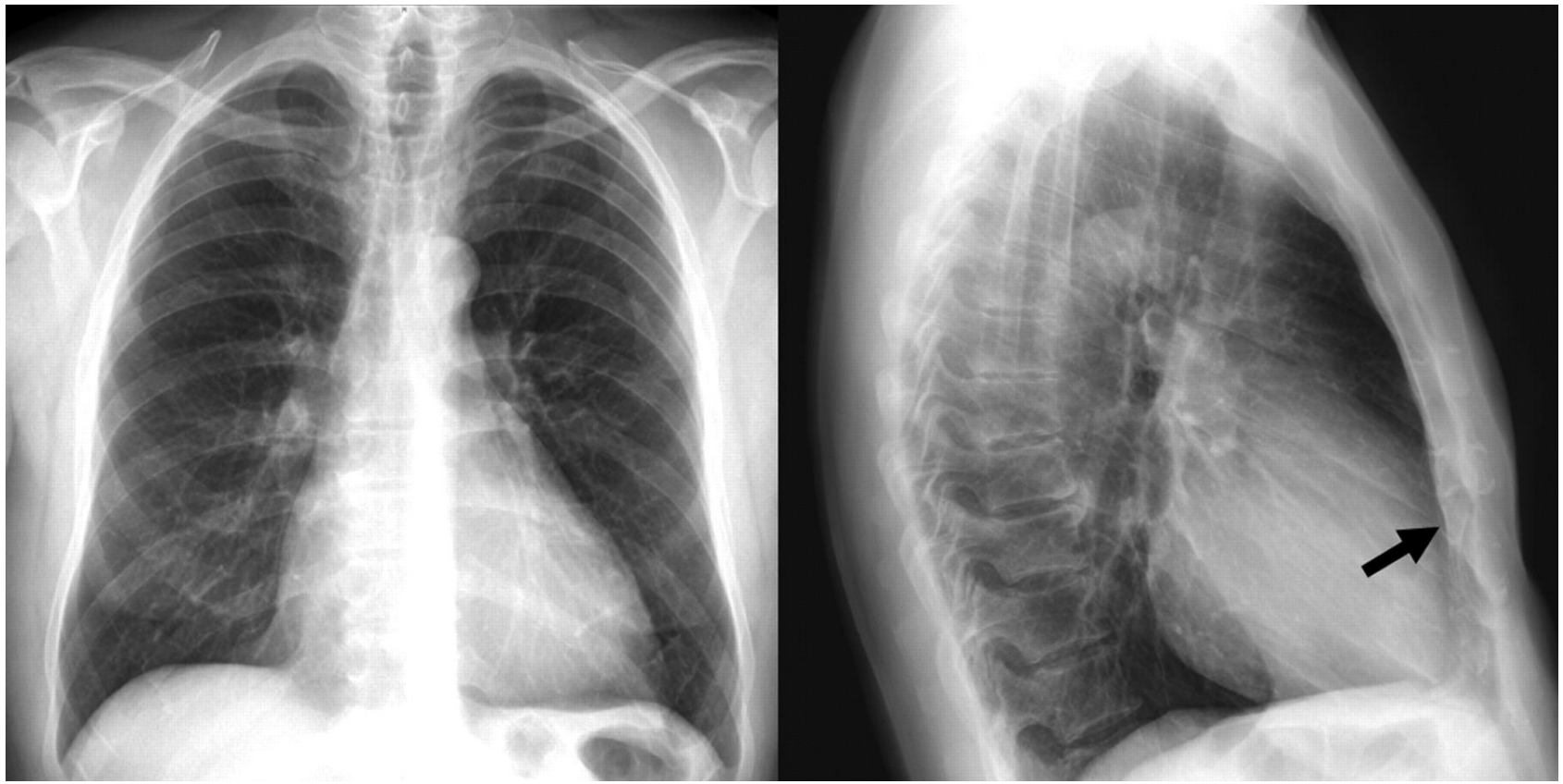

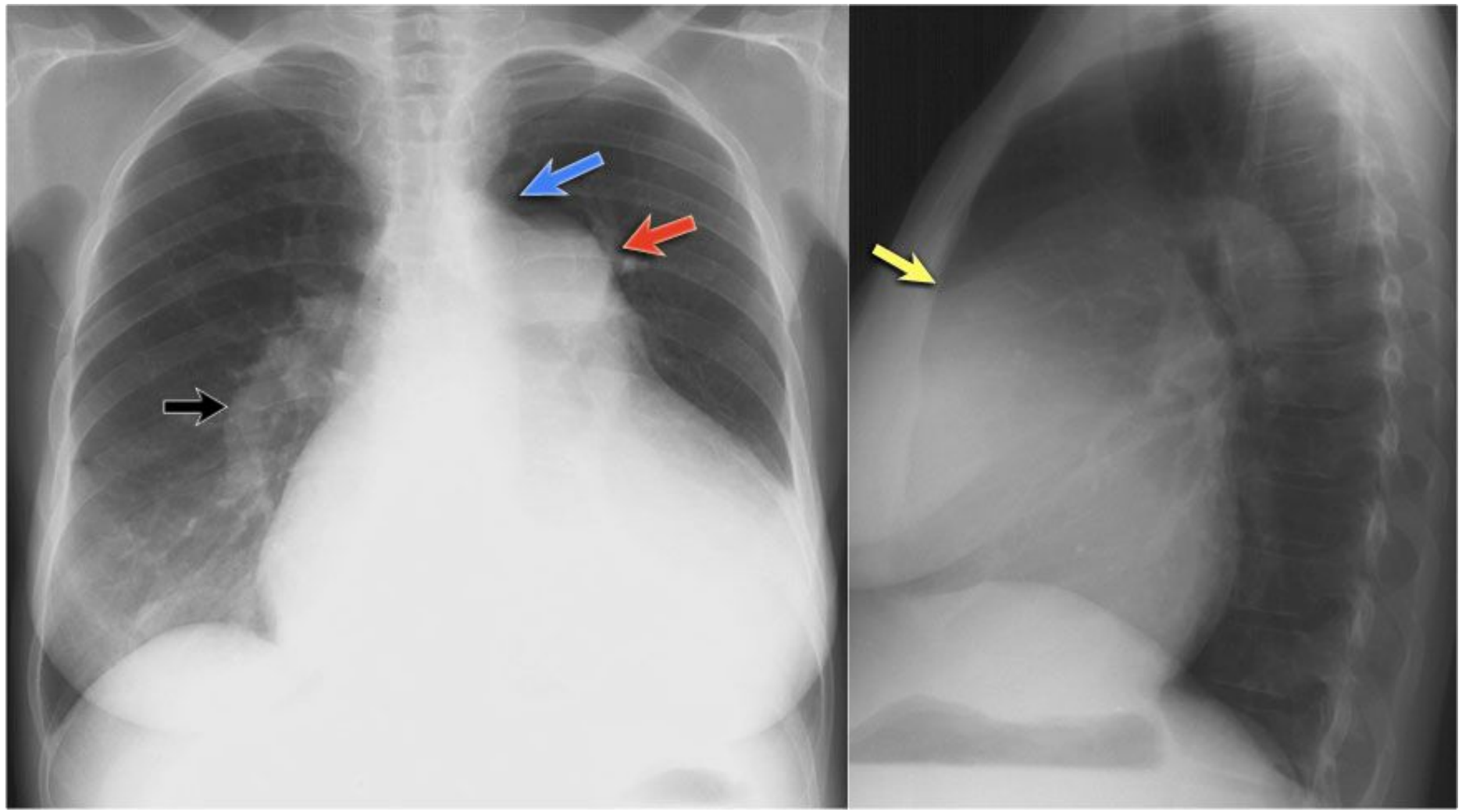

RT

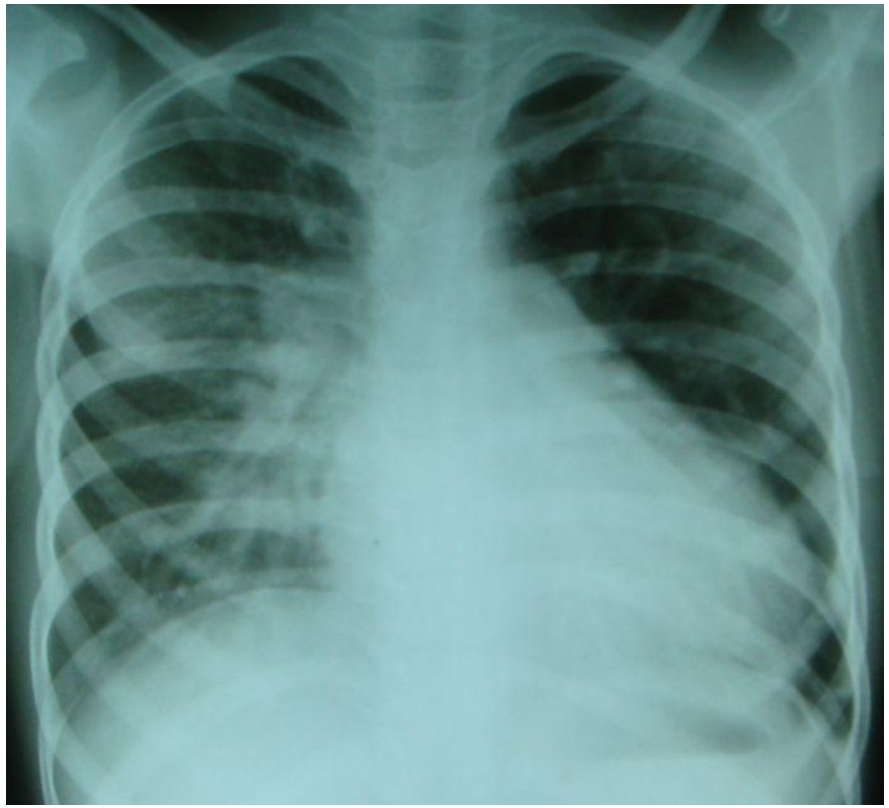

Congenital abnormality , primary RT ventricle enlargement

