CARDIOVASCUALR IMAGING III

DR. MOHAMAD MATAR

Eisenmenger Syndrome



Eisenmenger Syndrome

- Long standing increased pulmonary flow and pressure. Usually due to LT to RT shunt.
- Hypertrophied small vessels,, lead to increased resistance to pulmonary flow.
- Dilated main pulmonary artery, while decrease in pulmonary vascular marking.

PULOMONARY HT

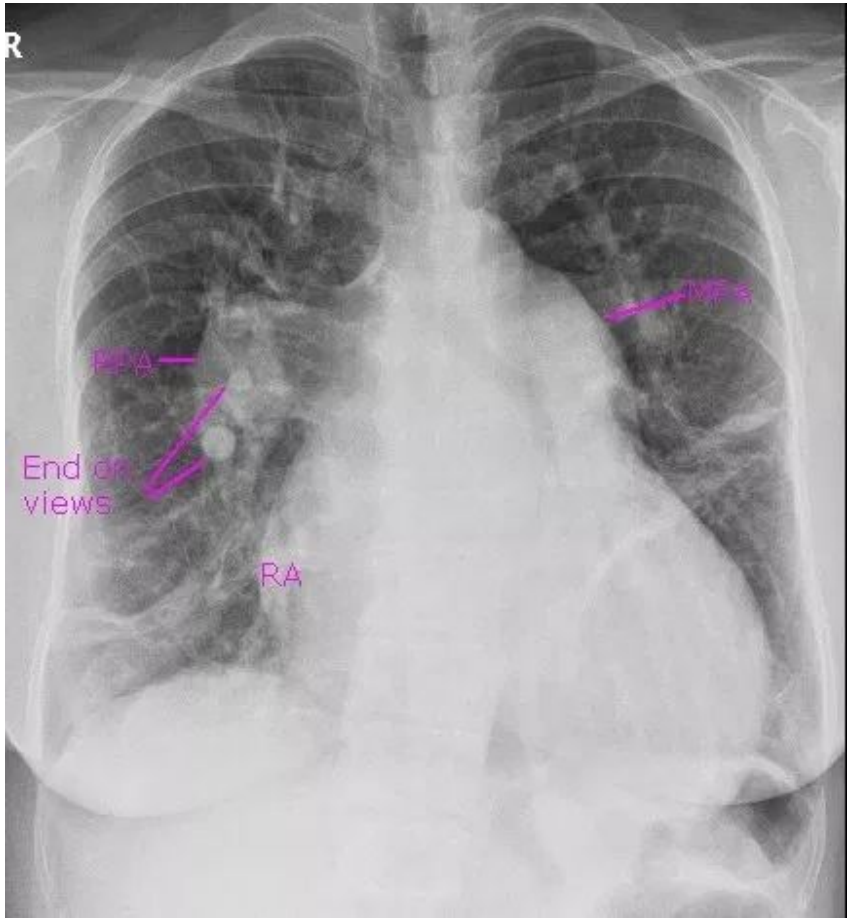

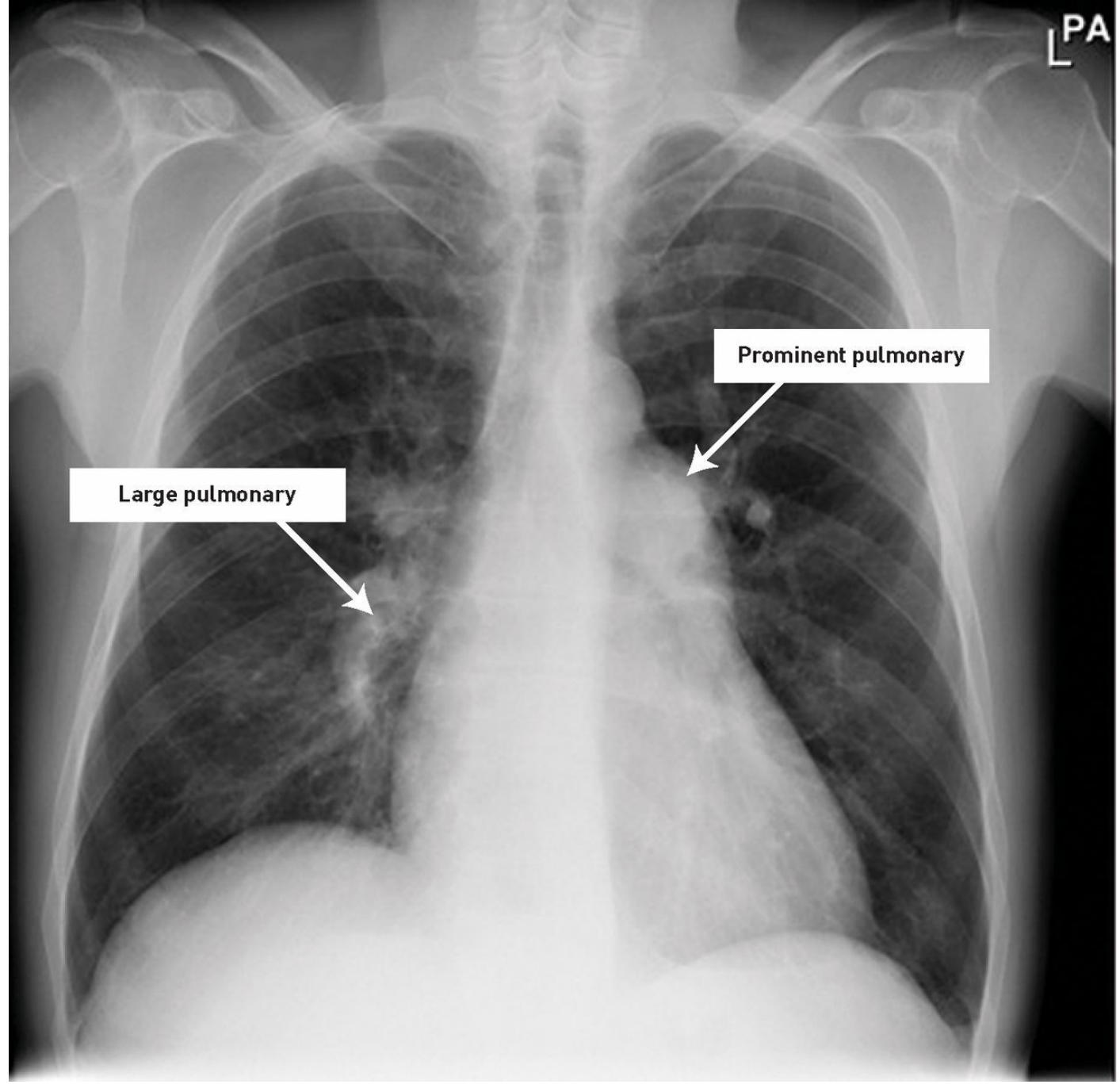
PA
Prominent pulmonary
Large pulmonary

PULMONARY HYPERTENTION

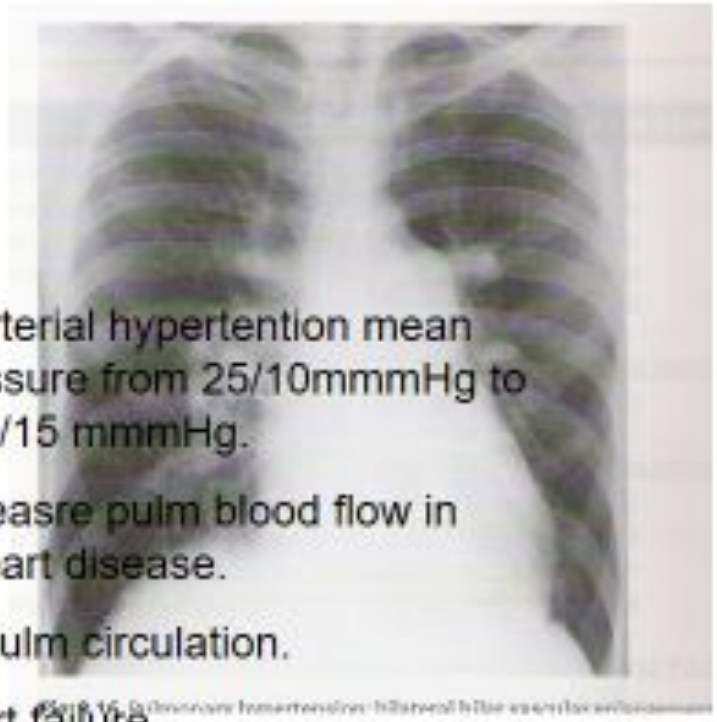

Pulmonary arterial hypertention mean increase pressure from 25/10mmmHg to more than 30/15 mmmHg.

Causes: increasre pulm blood flow in congenital heart disease.

Obstructive pulm circulation.

Left side heart failure.

Radiological signs enlarged cardiac size, dilated pulmonary hilar vs.

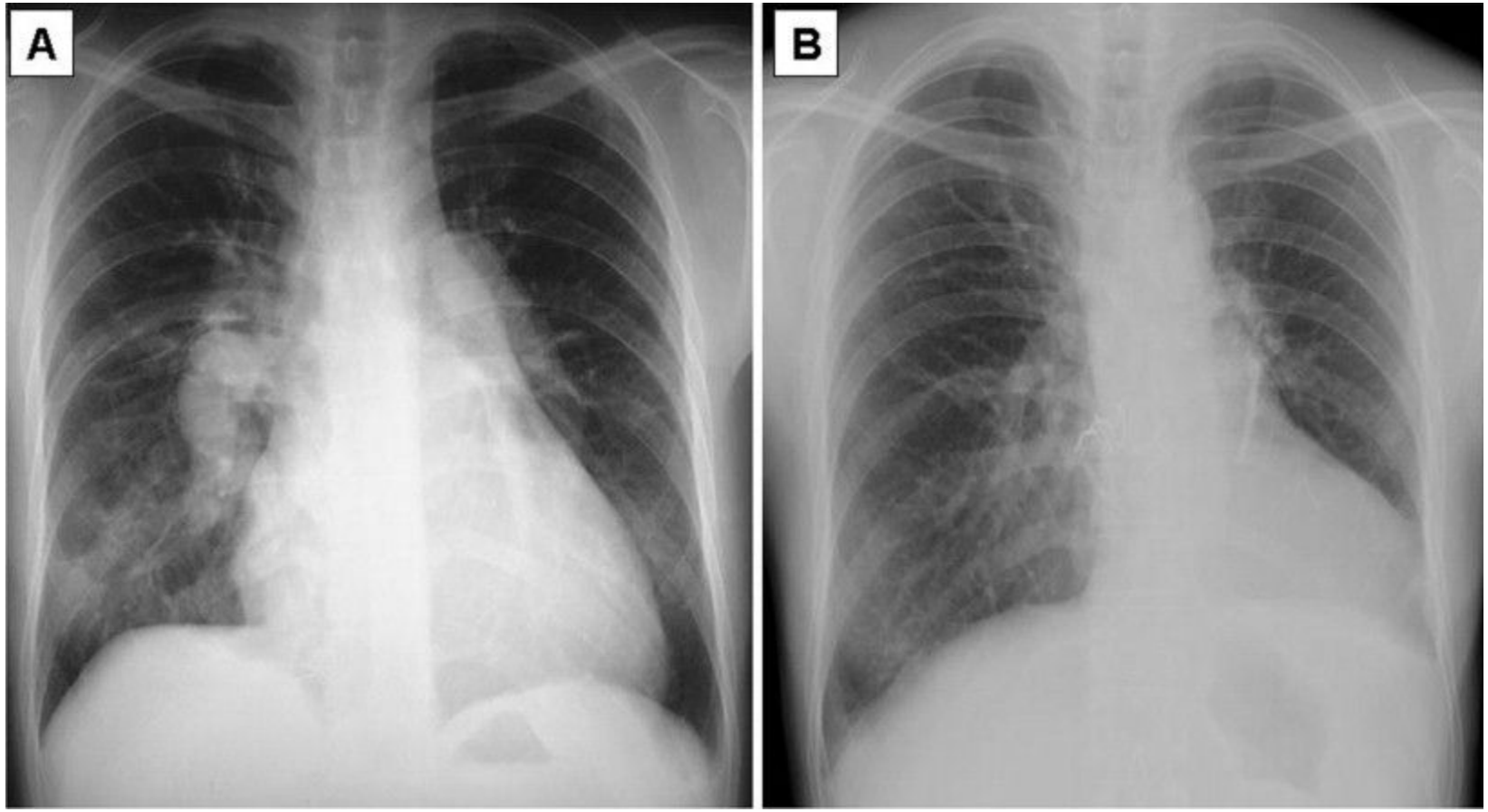
A
B

PERICARDIAL EFFUSION

1-IMAGING, plain film, U/S, CT &

2-CAUSES:

Infection, infarction, myxodema, malignancy, bronchal and edias tumor invasion, collagen vascul disease and rheumatoid.

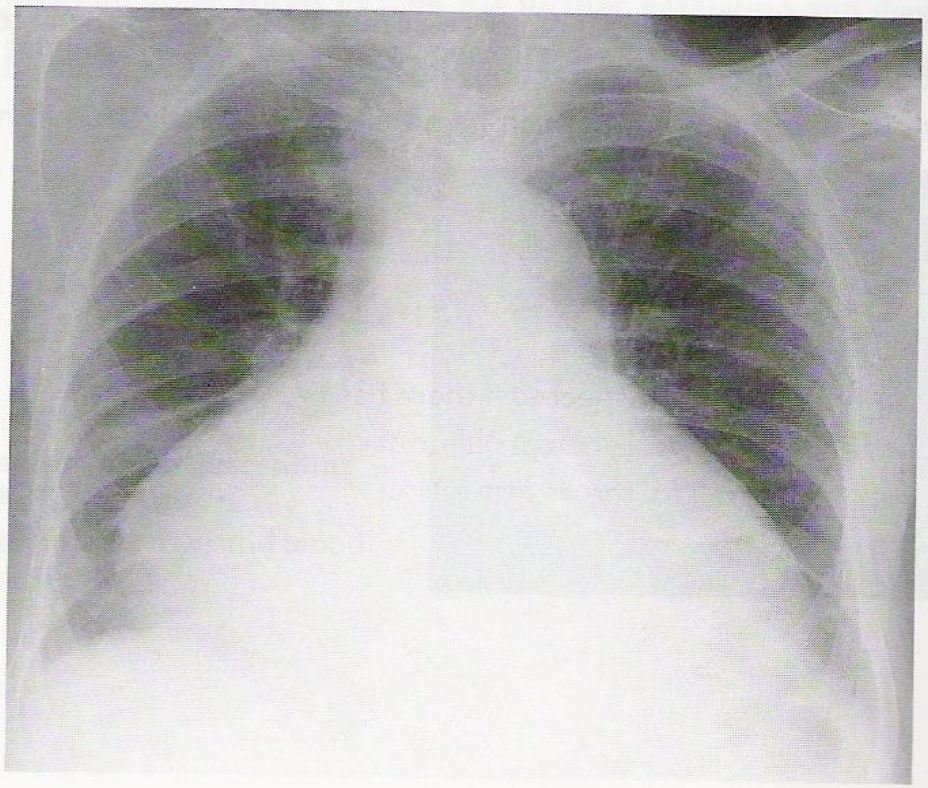

Fig. 3.3 Pericardial effusion: large globular shaped cardiac shadow with

CARDIAC FAILURE

RADIOLOGICAL FEATURES

1. Cardiac enlargement,
2. Upper lobe vascular prominent.
3. Pleural effusion.
4. Interstitial edema.
5. Alveolar pulmonary edema.

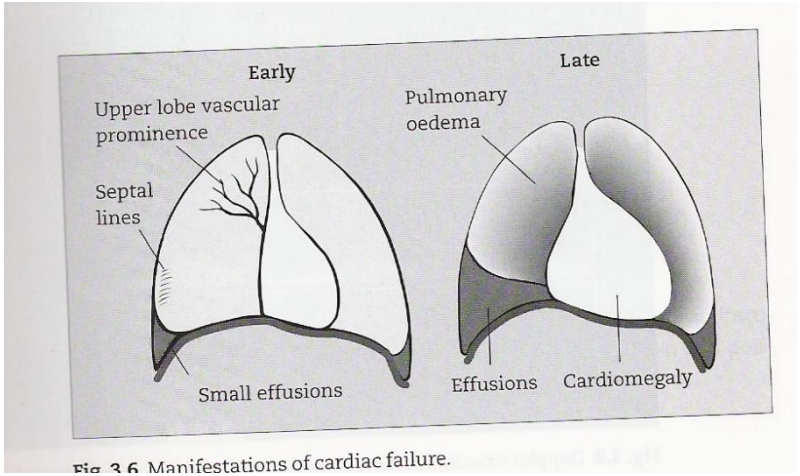

Fig. 3.6 Manifestations of cardiac failure.

Signs of heart failure

Hover over image to show findings

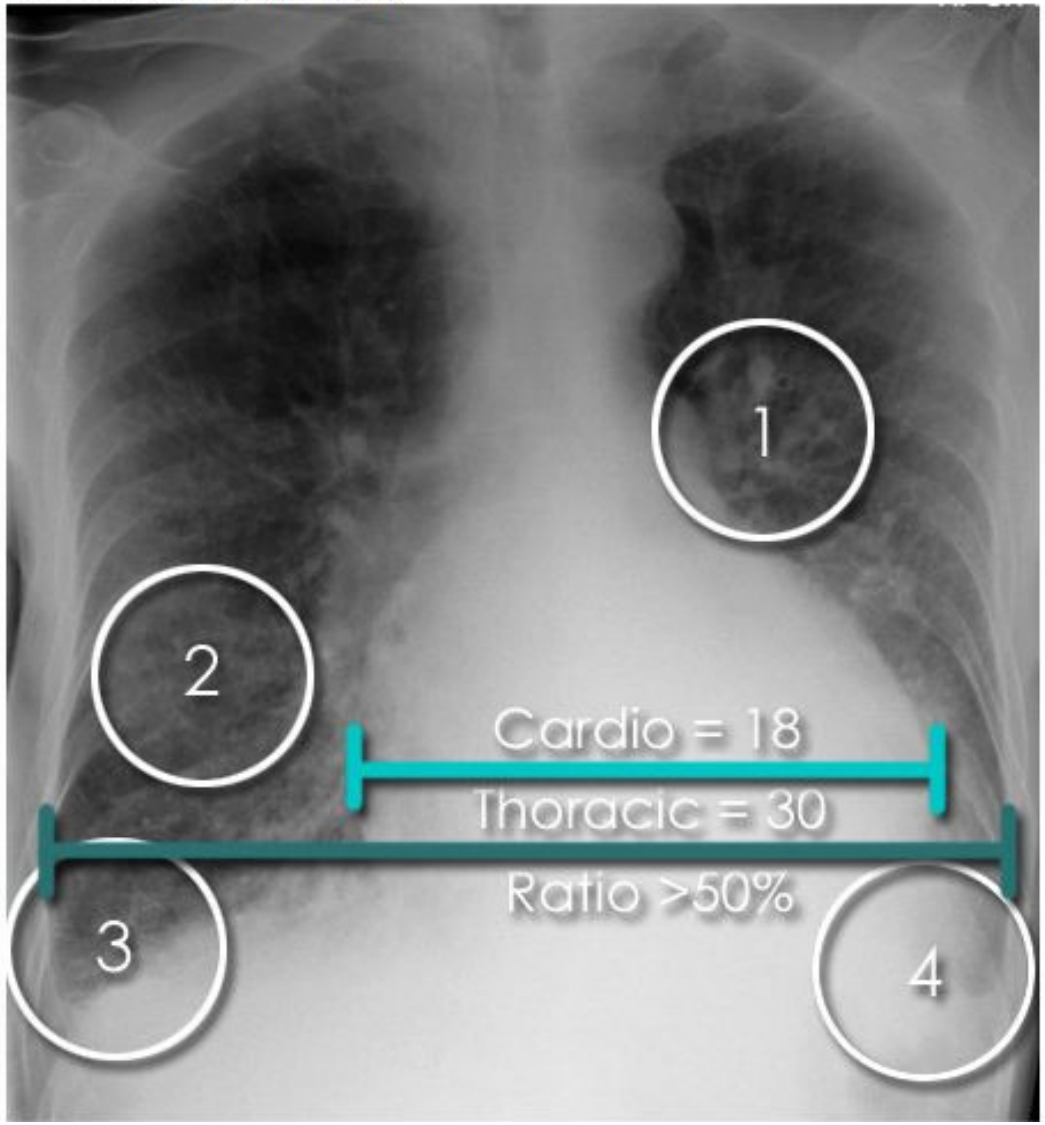

Signs of heart failure

- Cardiomegaly CTR = 18/30
- Upper zone vessel enlargement (1) - a sign of pulmonary venous hypertension
- Pulmonary oedema (2) - bilateral increased lung markings (classically peri-hilar and shaped like bats wings - more widespread in this case)
- Septal (Kerley B) lines (3) - See next picture
- Pleural effusions (4)

Clinical information

- Worsening exercise tolerance
- Chronic uncontrolled hypertension
- Rapid onset of shortness of breath
- Atrial fibrillation

Diagnosis

- Left ventricular failure with pulmonary oedema

Septal (Kerley B) lines

Septal lines, also known as Kerley B lines, are due to fluid accumulating between the secondary lobules of the lungs. They are an elusive sign, but once spotted, pulmonary oedema is almost always the cause, especially in a patient with a cardiac history.

Septal lines (Kerley B lines)

Hover over image to show findings

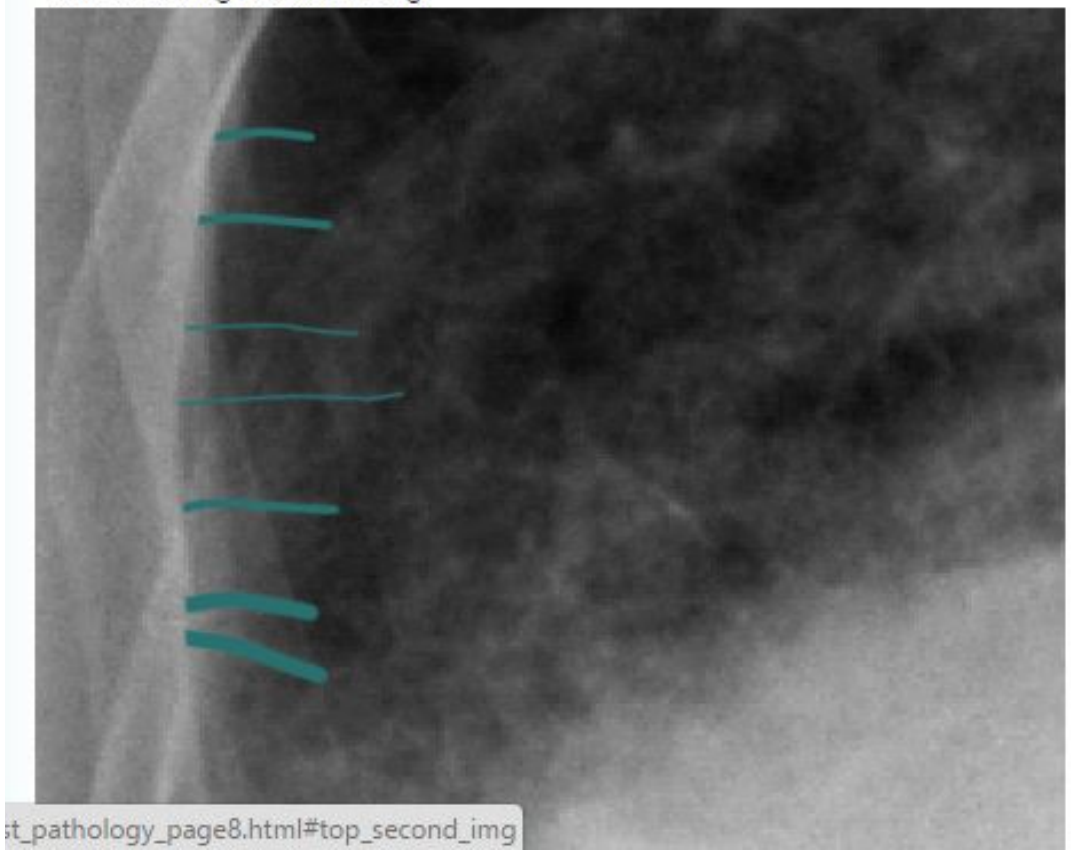

st_pathology_page8.html#top_second_img

Septal lines (Kerley B lines)

- Costophrenic angle (detail of above image)
- Horizontal lines reaching the lung edge

Diagnosis

- Septal lines - a specific sign of pulmonary oedema

Differential diagnosis

- Occasionally conditions that cause lymphatic obstruction may cause septal lines - such as sarcoidosis or lymphangitis carcinomatosa

luid leaks
nto interstitium
& alveoli
PULMONARY
EDEMA &
SIONS
KERLEY B
LINES

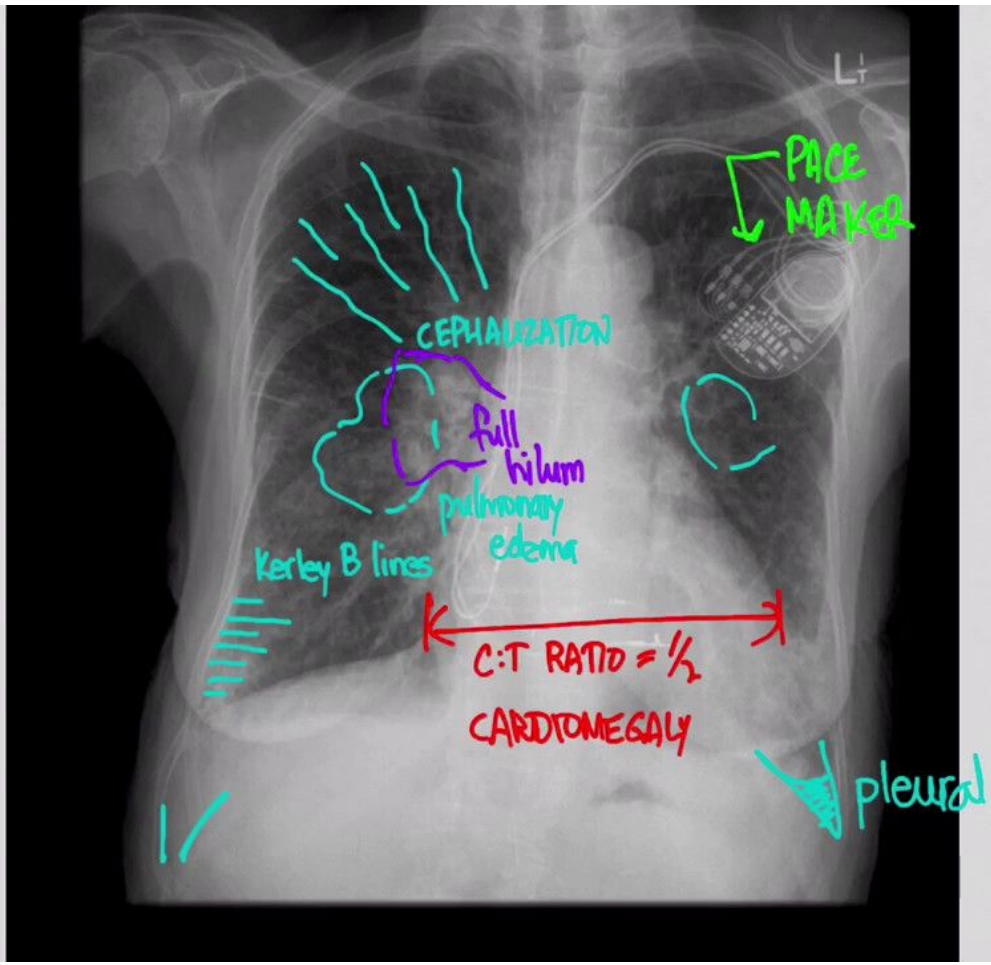



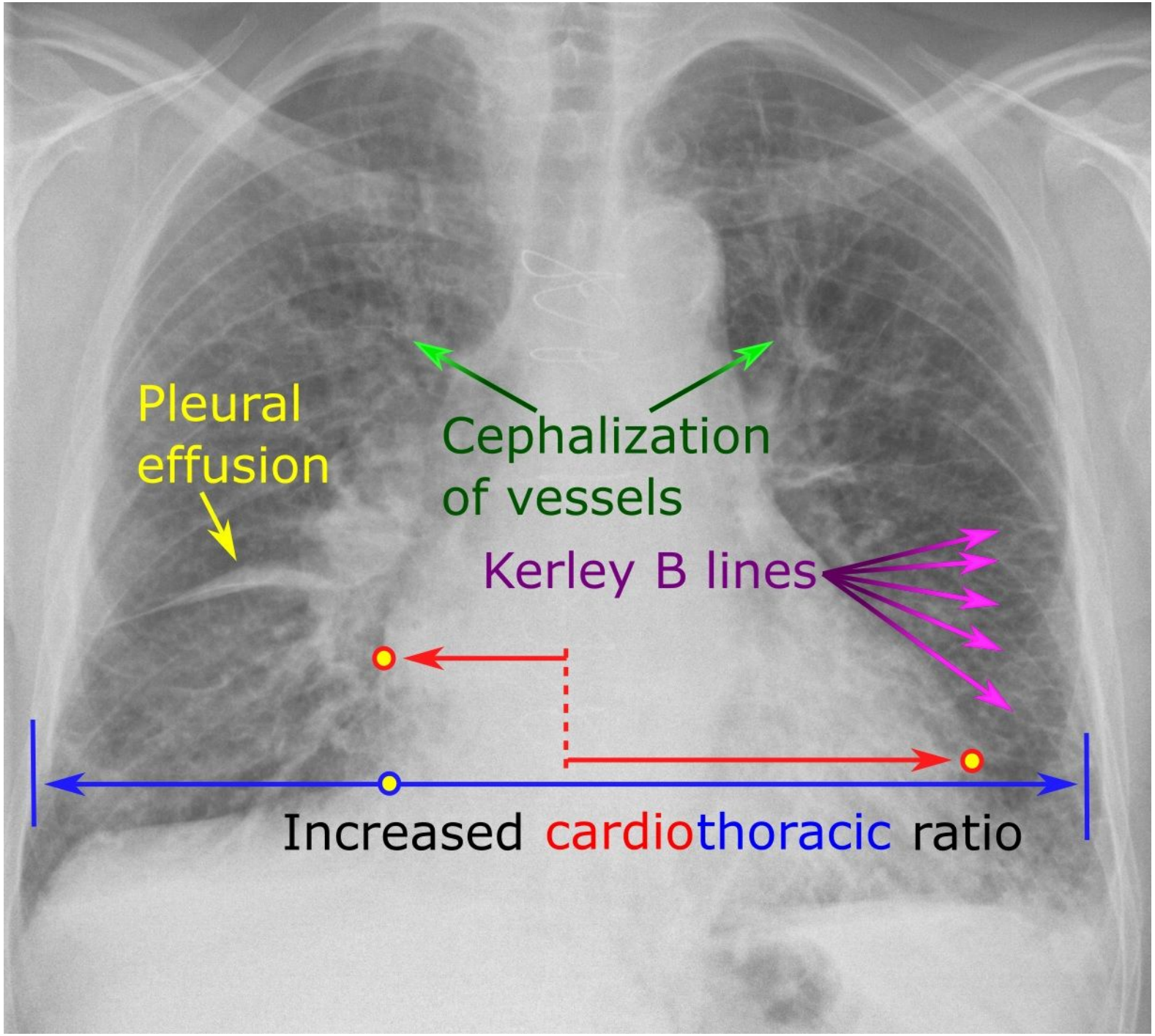
Pleural effusion
Cephalization of vessels
Kerley B lines
Increased cardiothoracic ratio

CARDIAC FAILURE

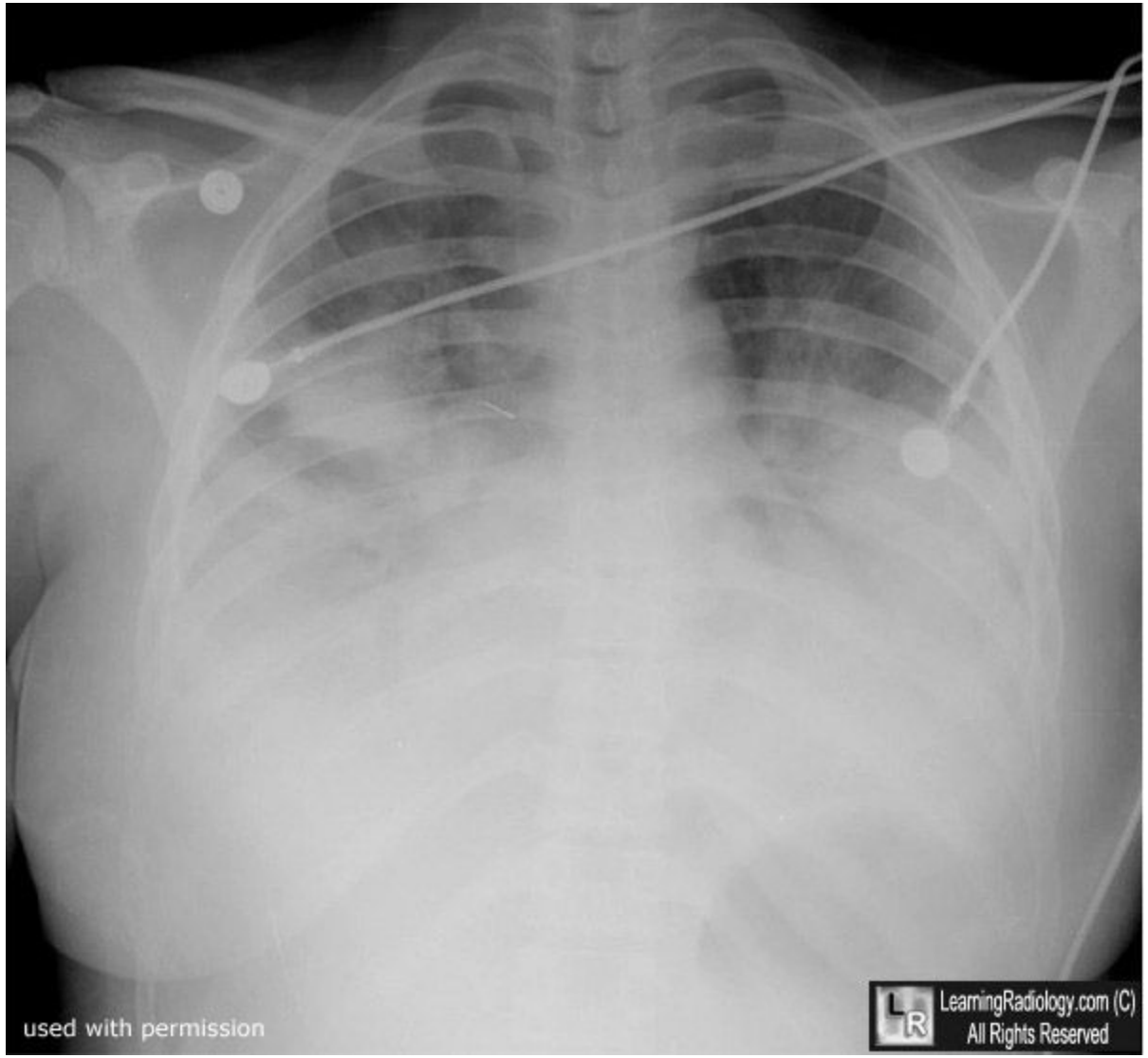

TUBES&CATHETERS

.Endotracheal tube

.Central line

.Swan-Ganz catheter

.Naso-gastric tube

.Pacing wire

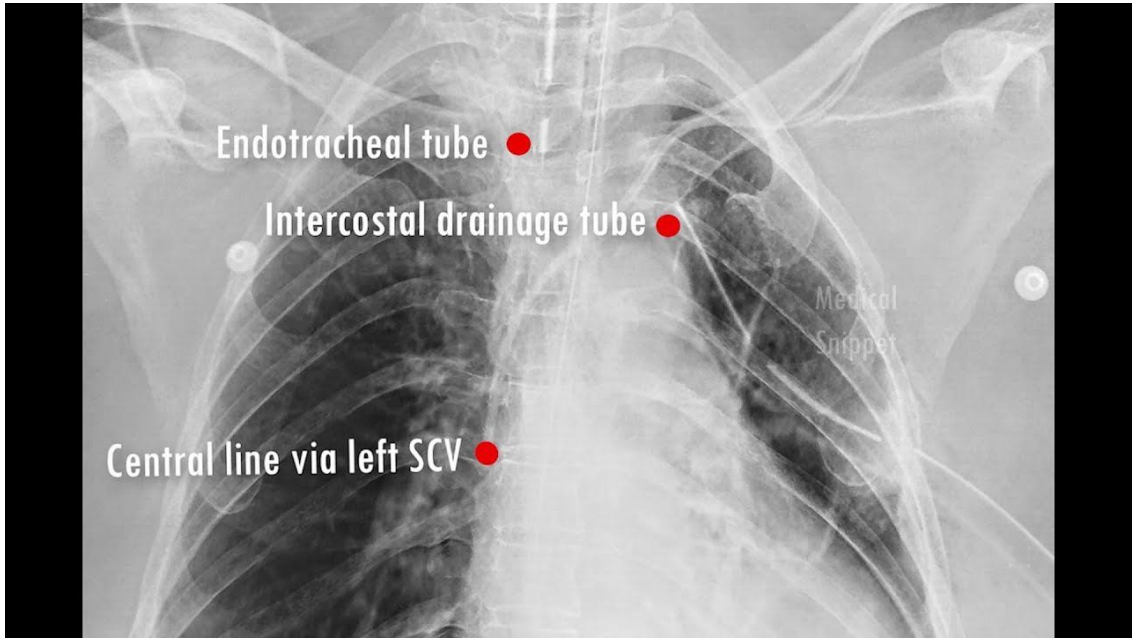

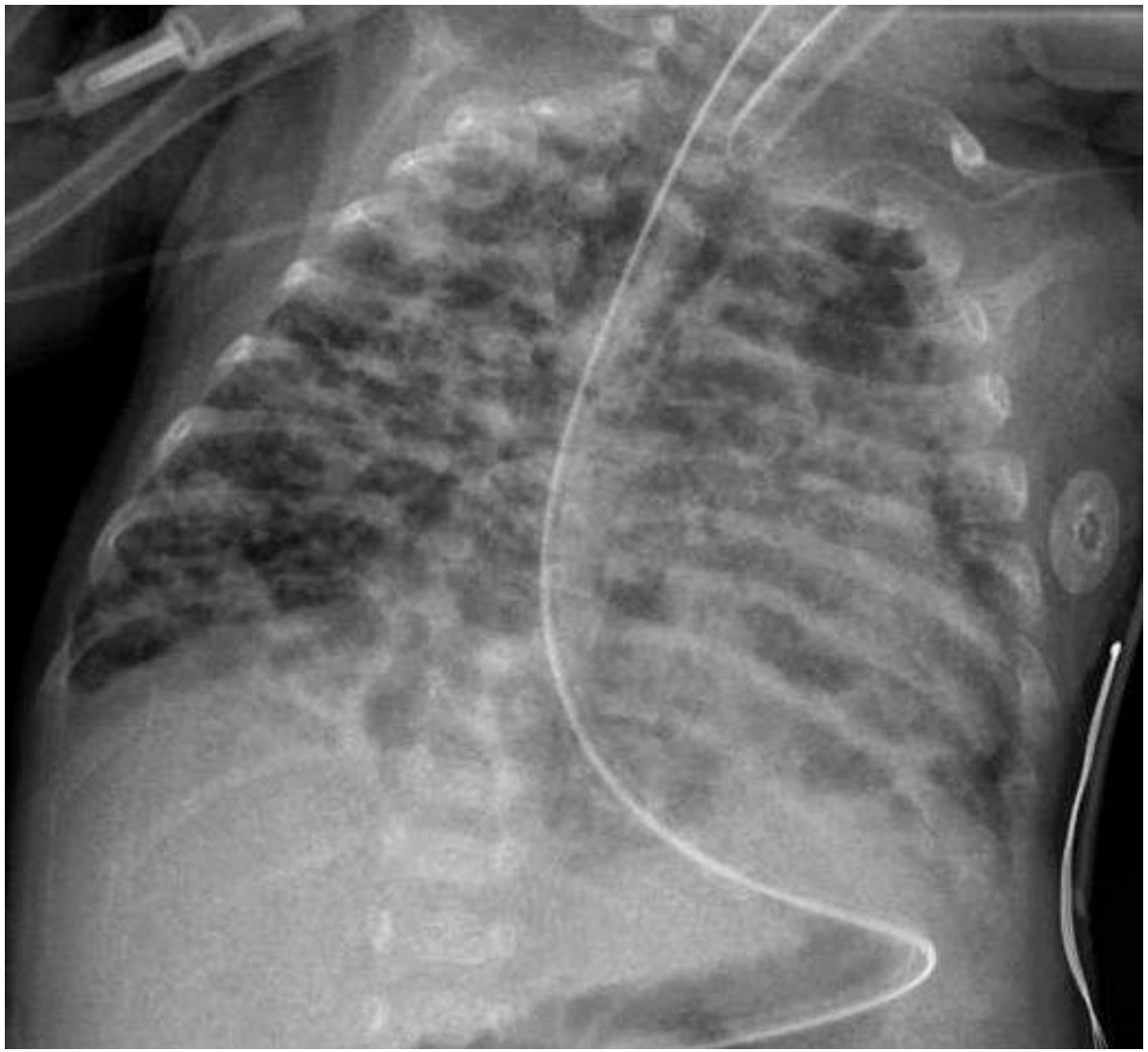

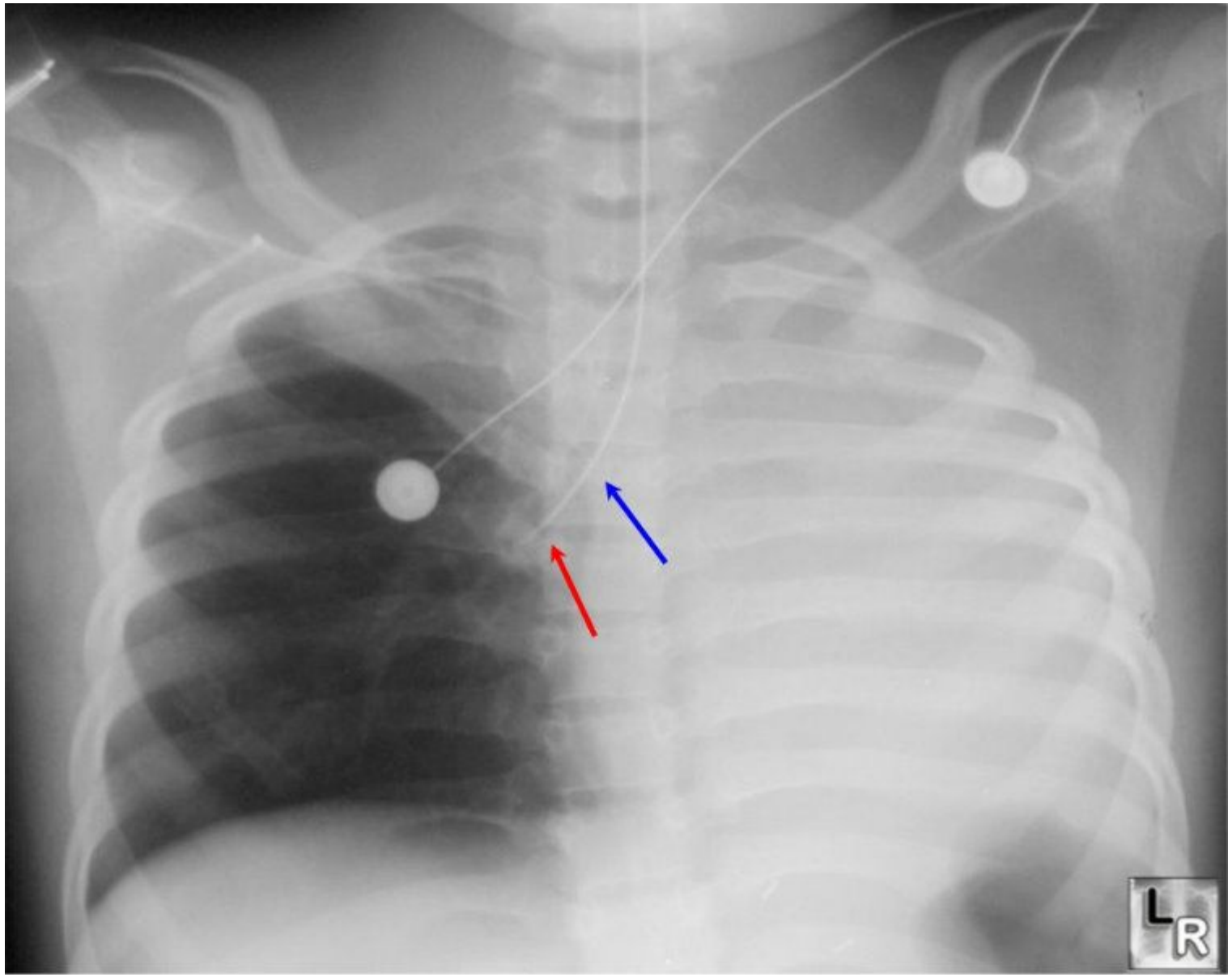
L
R

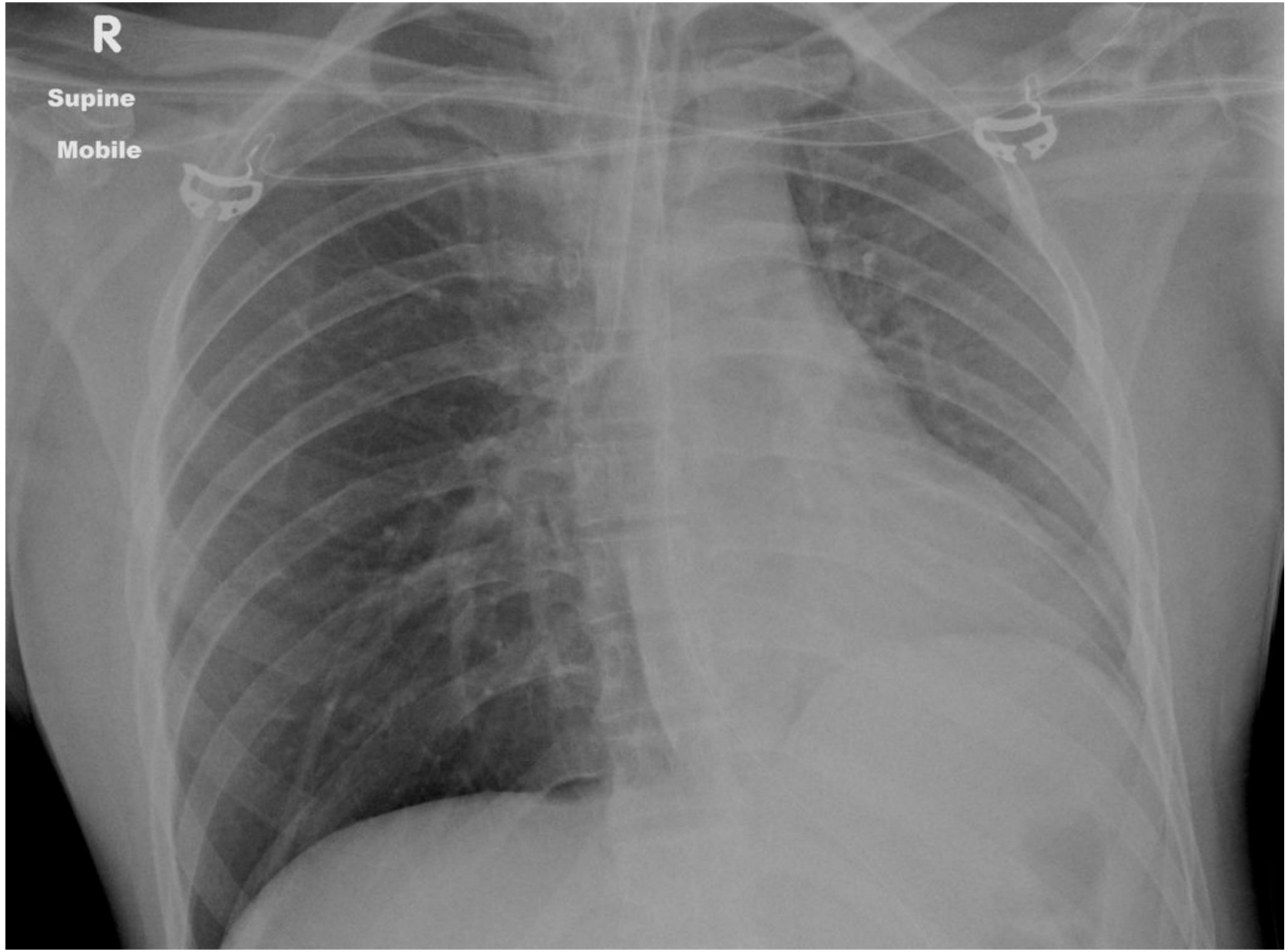
R
Supine
Mobile

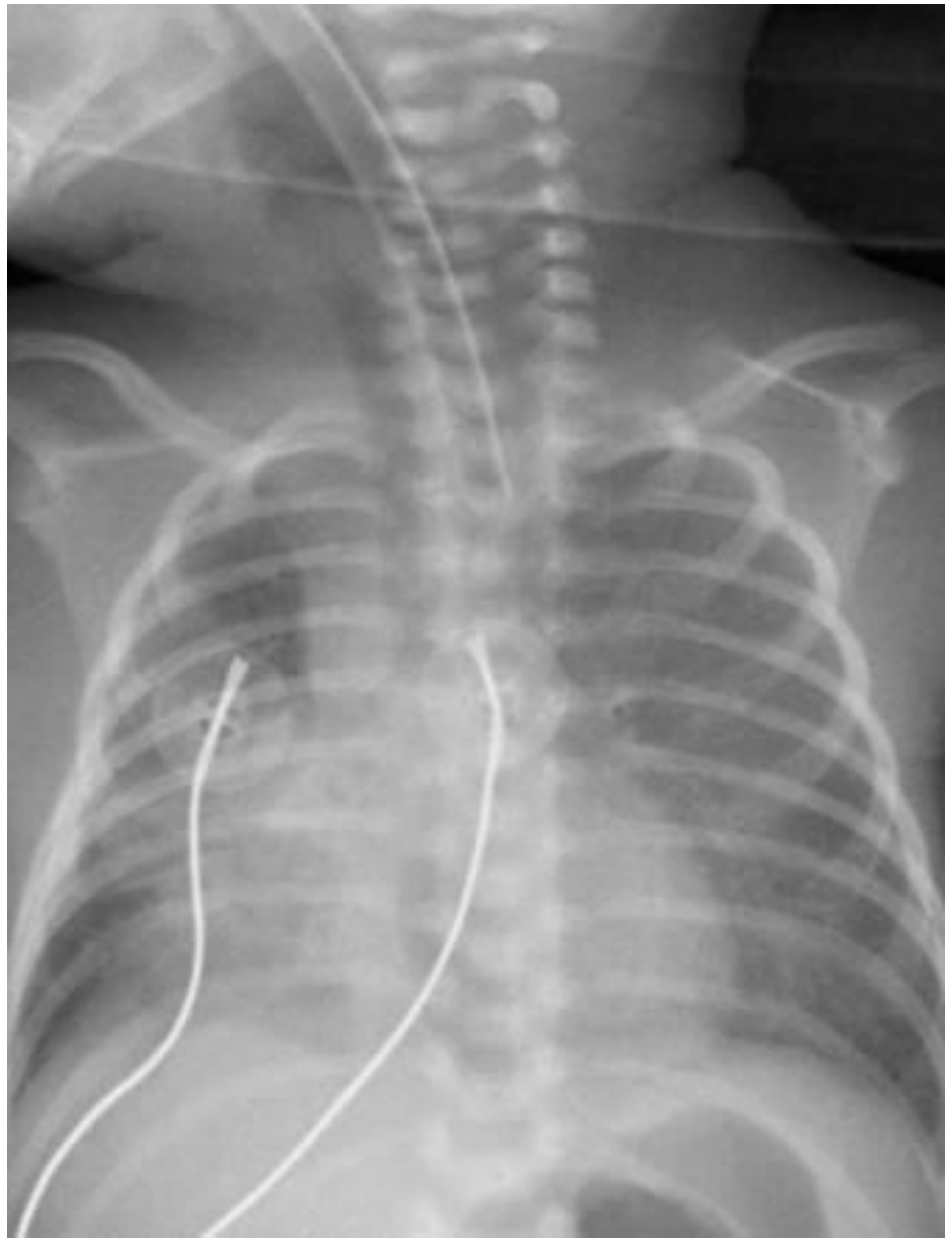

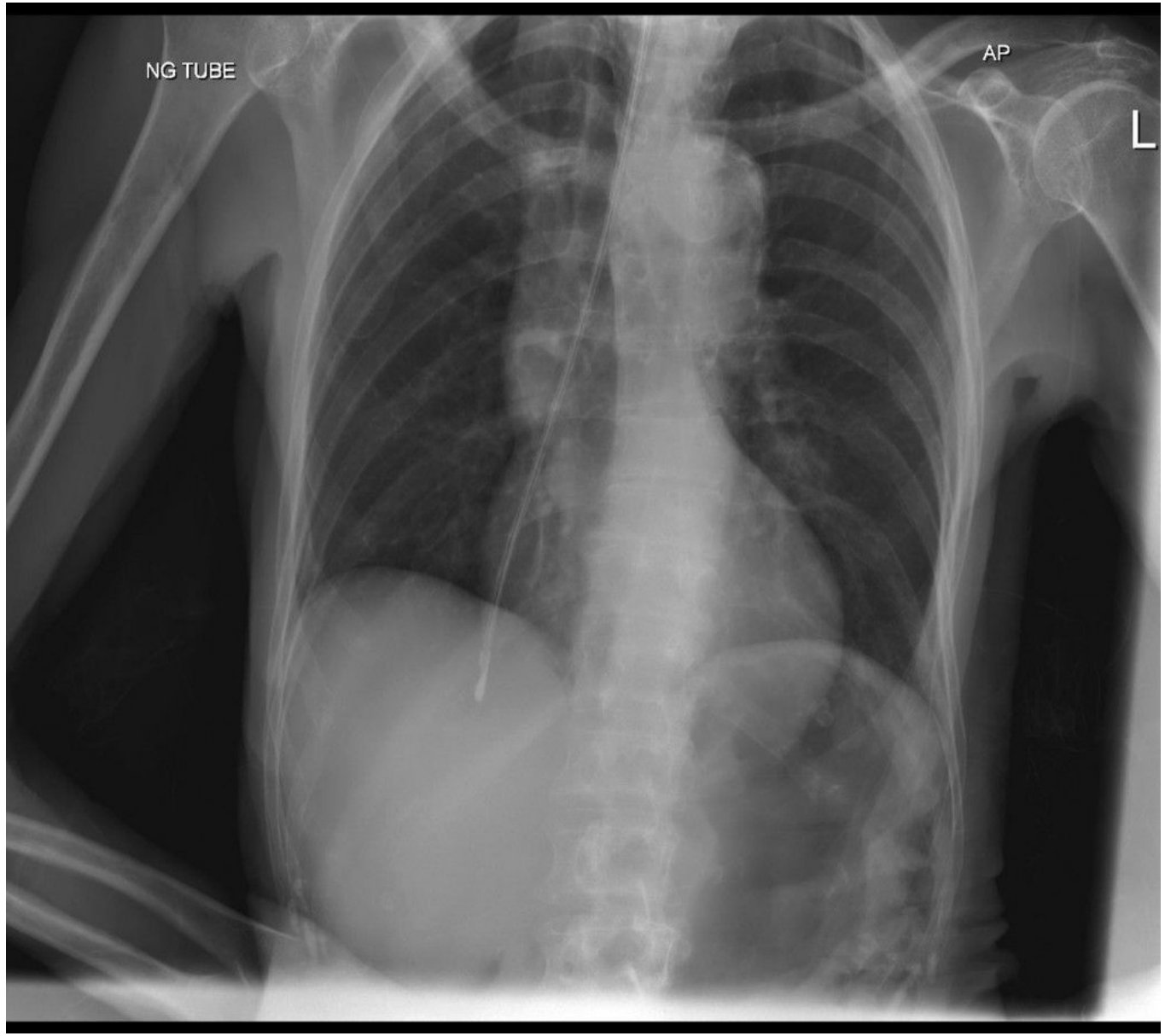
NG TUBE
AP
L

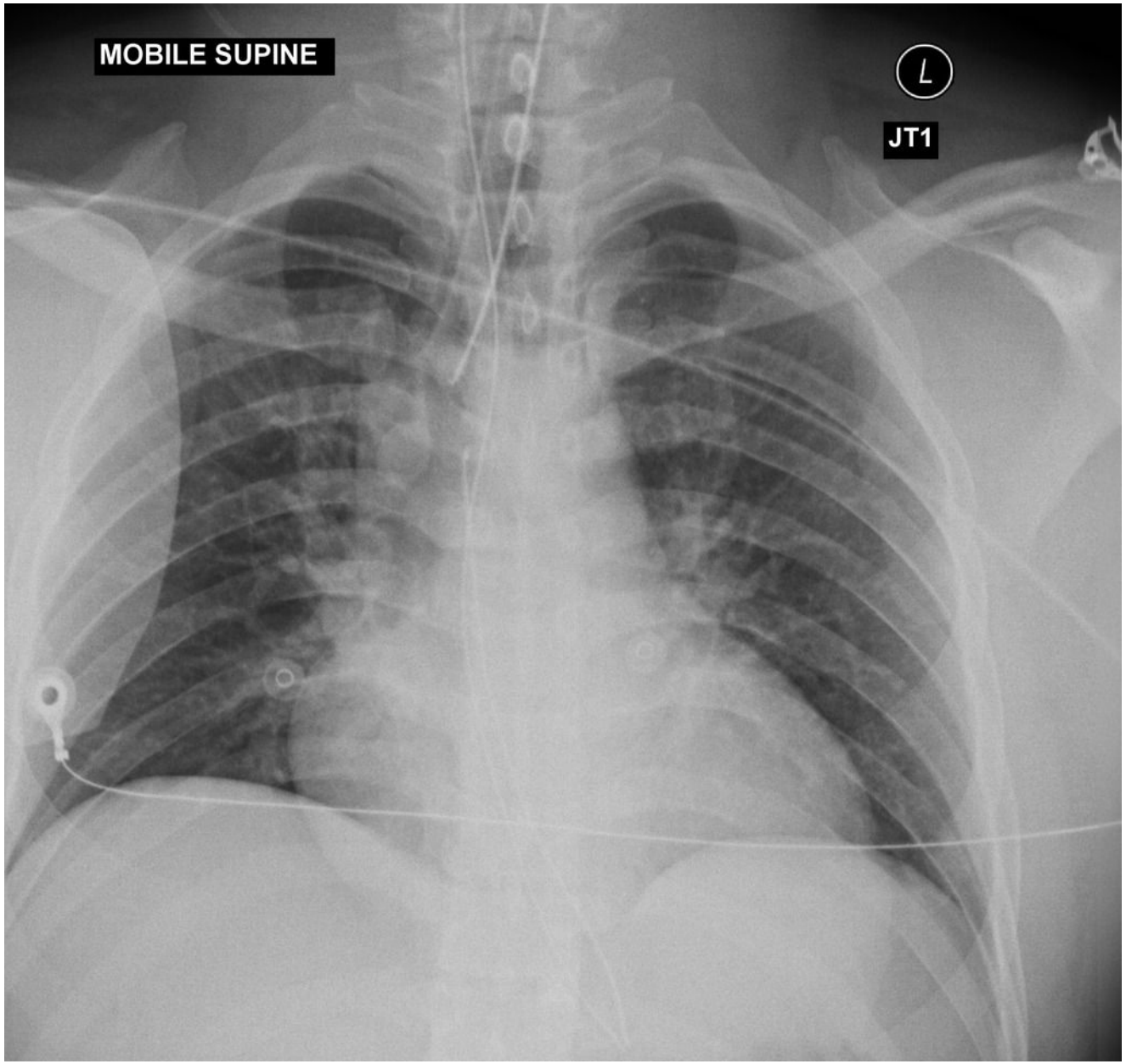
MOBILE SUPINE
L
JT1


L

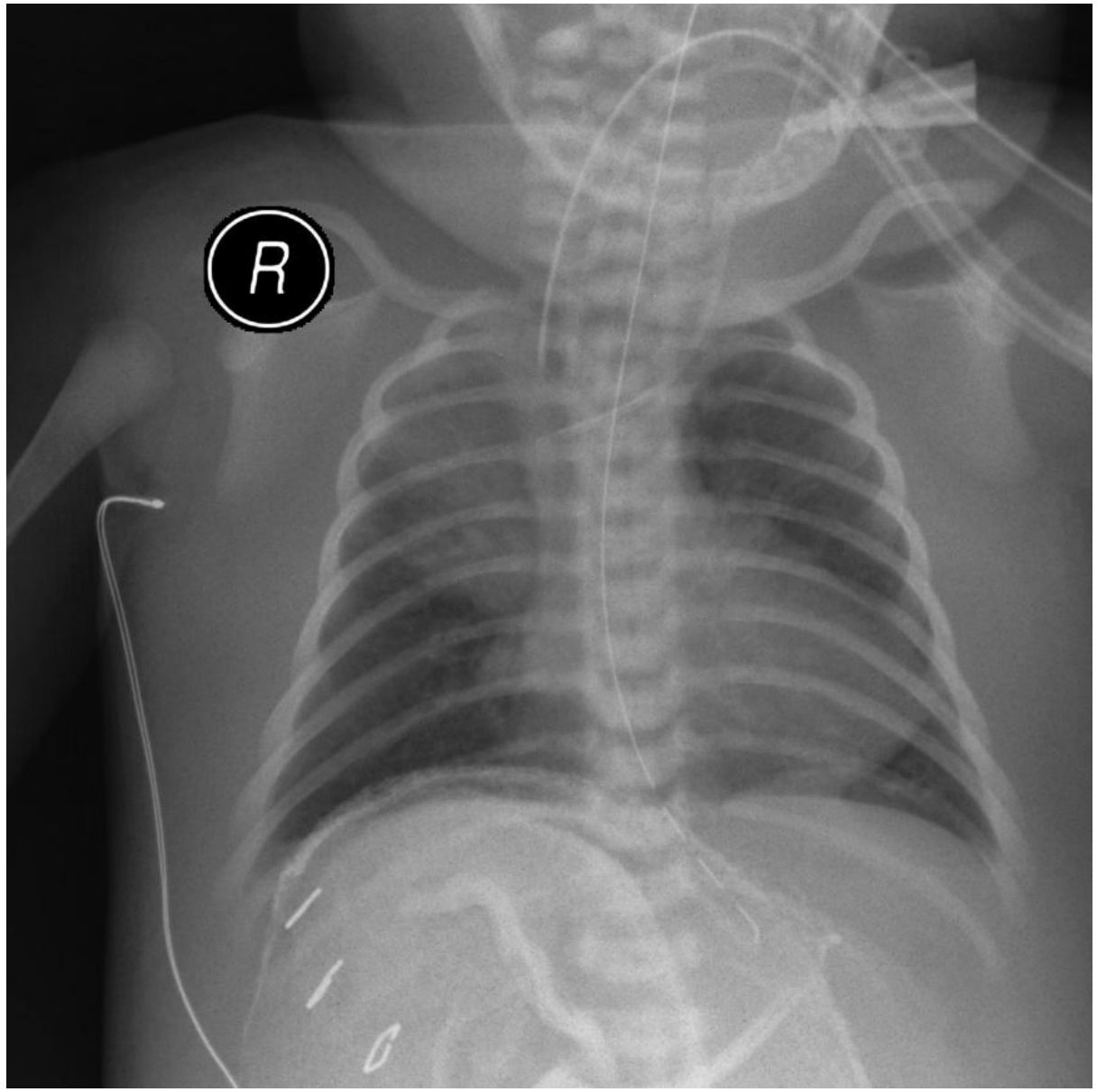
R

DVT

Site LL.

PPF: post surgery, contraceptive use, prolonged bed rest & hypercoagulability.

PRESENTATION: calf pain, swelling,.

IMAGING MODALITIES: U/S, Venogram.

COMPLICATIONS: pulmonary embolus.

TREATMENT

US diagnostic criteria of DVT

Direct signs	Indirect signs
• Intramural thrombus	• Loss of phasicity:
• Incompressibility +++	Proximal thrombosis
• ↑ in vein diameter	Venous compression
• No flow in pulsed Doppler	• Loss of augmentation:
• No flow in color Doppler	Distal thrombosis

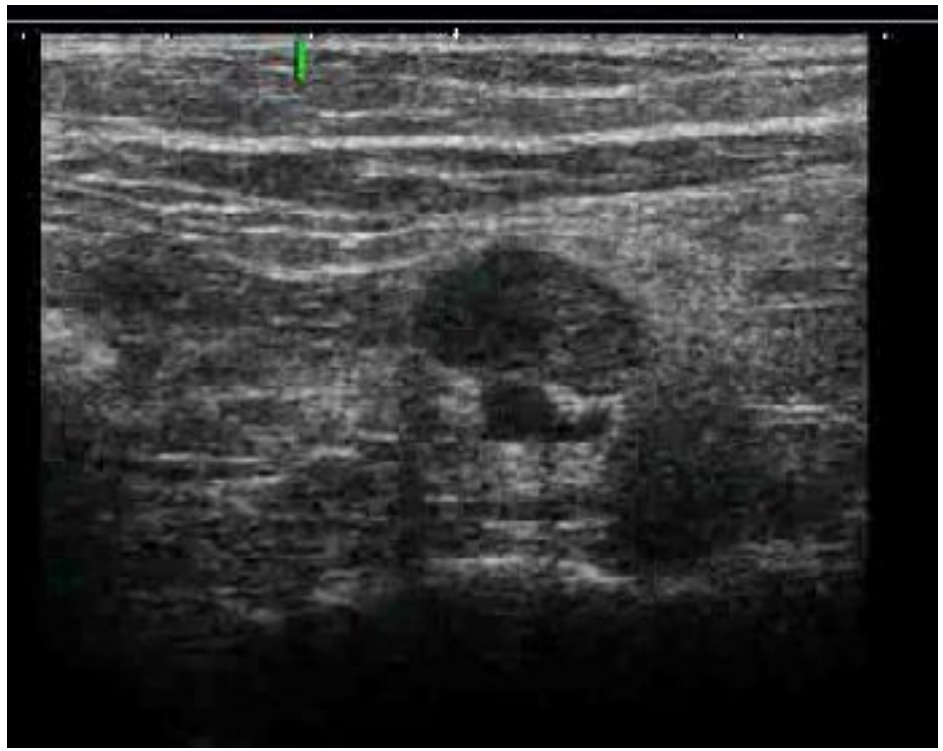



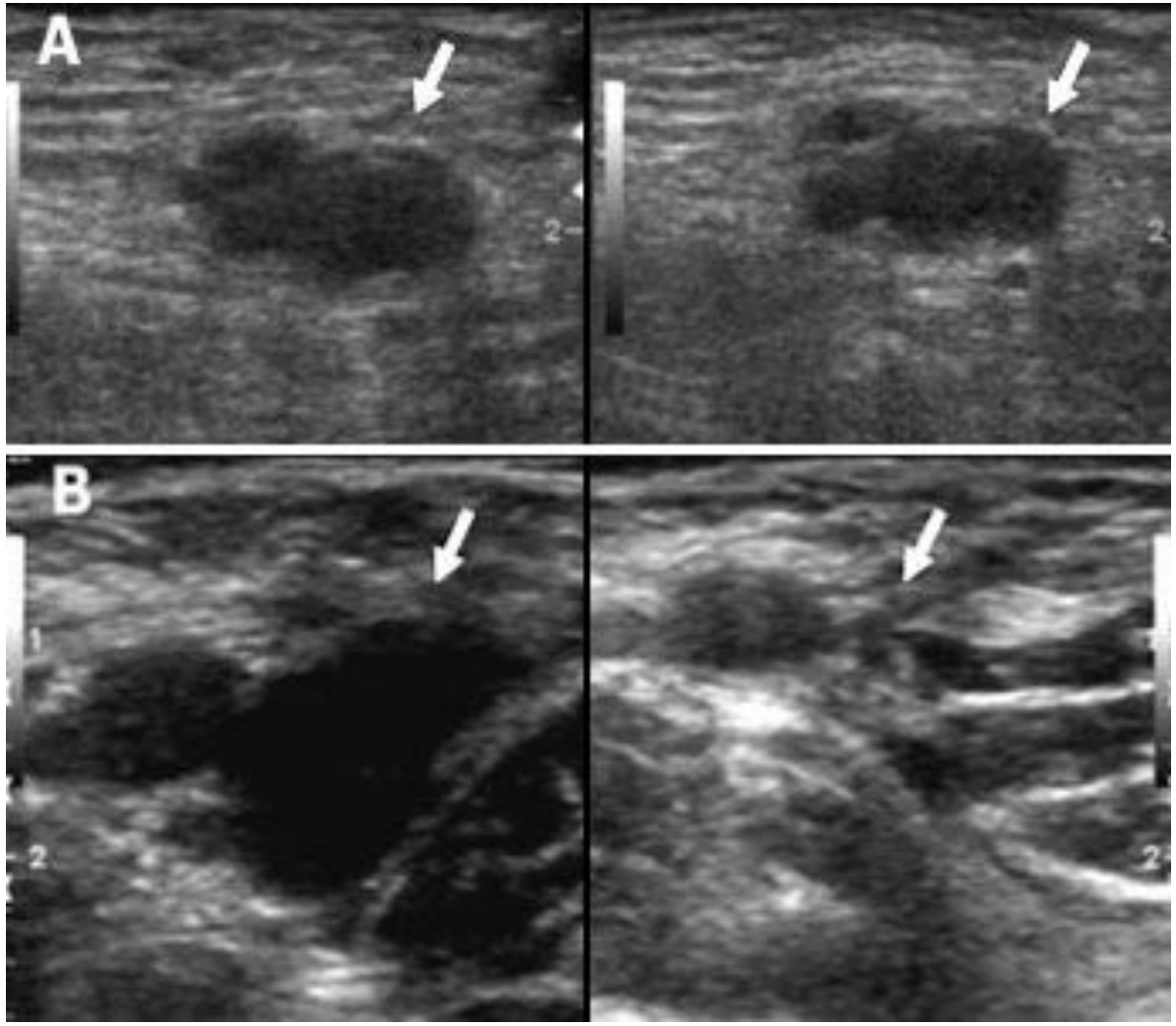
A
B

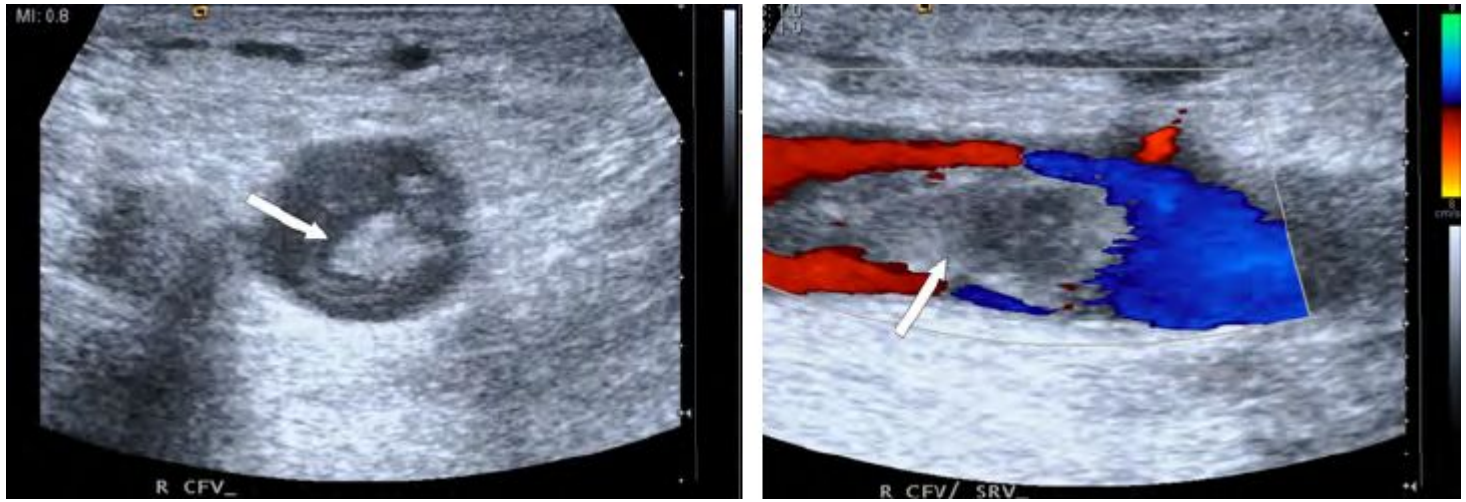
MI: 0.8
R CFV_
R CFV/ SRV_

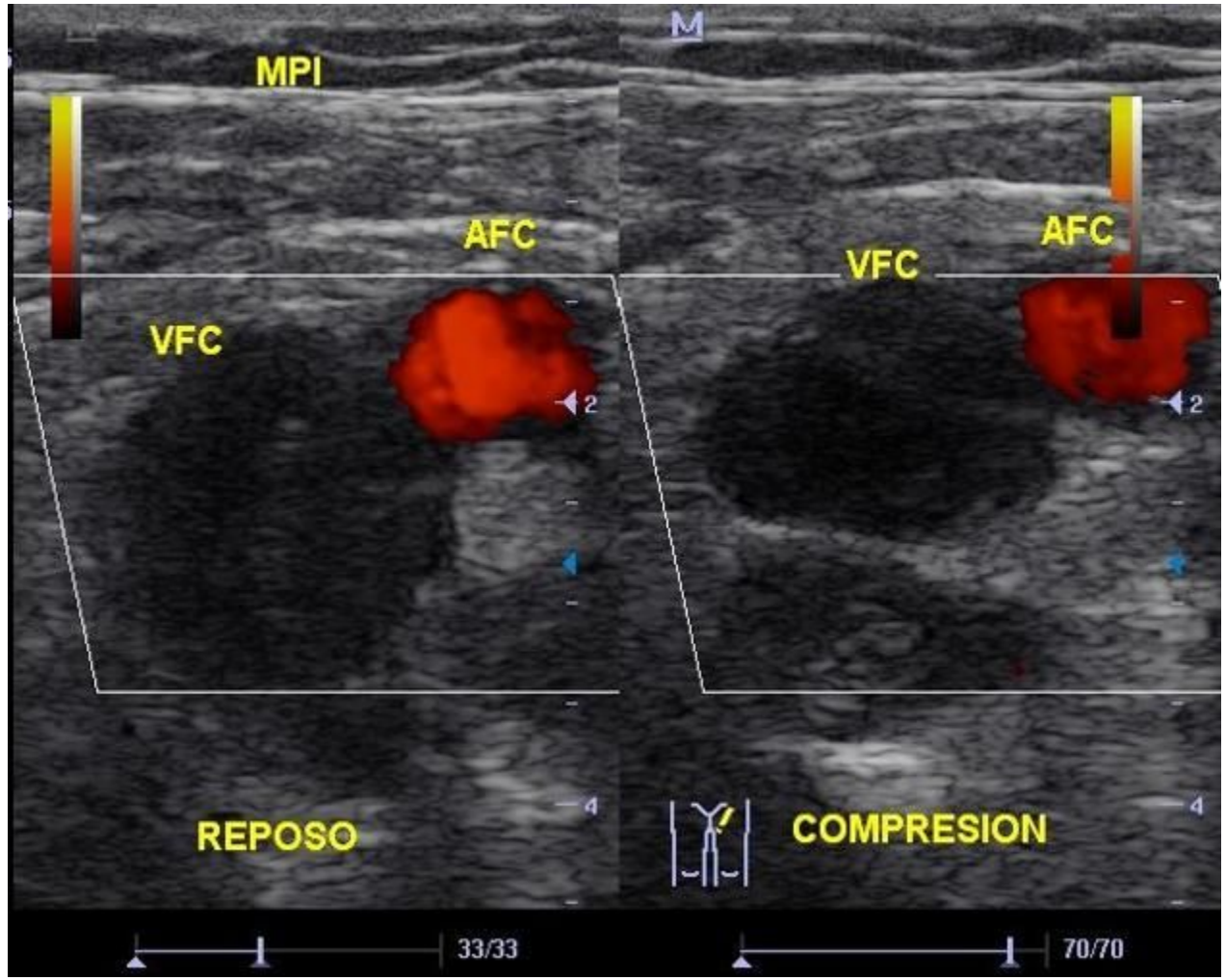
MPI
AFC
VFC
REPOSO
M
AFC
VFC
COMPRESION
33/33
70/70

DVT

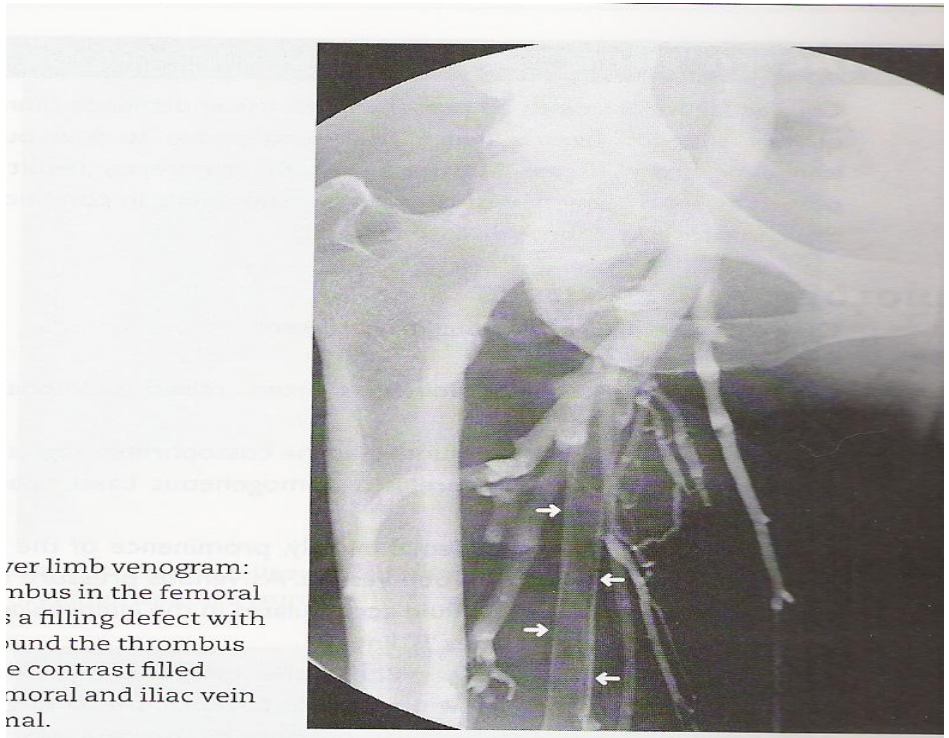

ver limb venogram:
nbus in the femoral
s a filling defect with
ound the thrombus
e contrast filled
moral and iliac vein
nal.

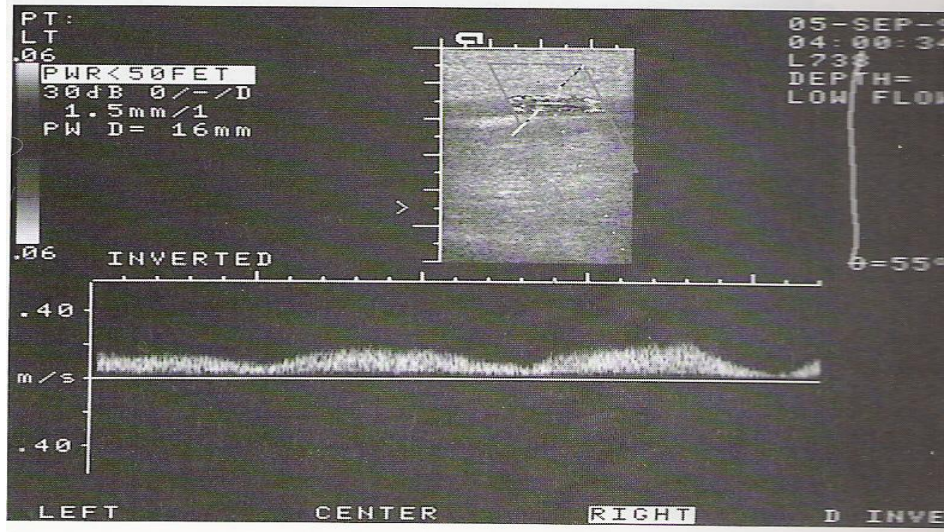

Fig. 3.8 Doppler examination of the femoral vein with a normal Doppler

IVC OBSTRUCTION



PULMONARY EMBOLISM

TYPES OF EMBOLISM: fat embolism, septic embolism, amniotic fluid embolism

RADIOLOGICAL FEATURES:

Small pleural effusion.

Basal lung collapse.

COMPLICATIONS : infarction, pulmonary hypertention.

Investigation: isotope scan , CT pulm. angiography

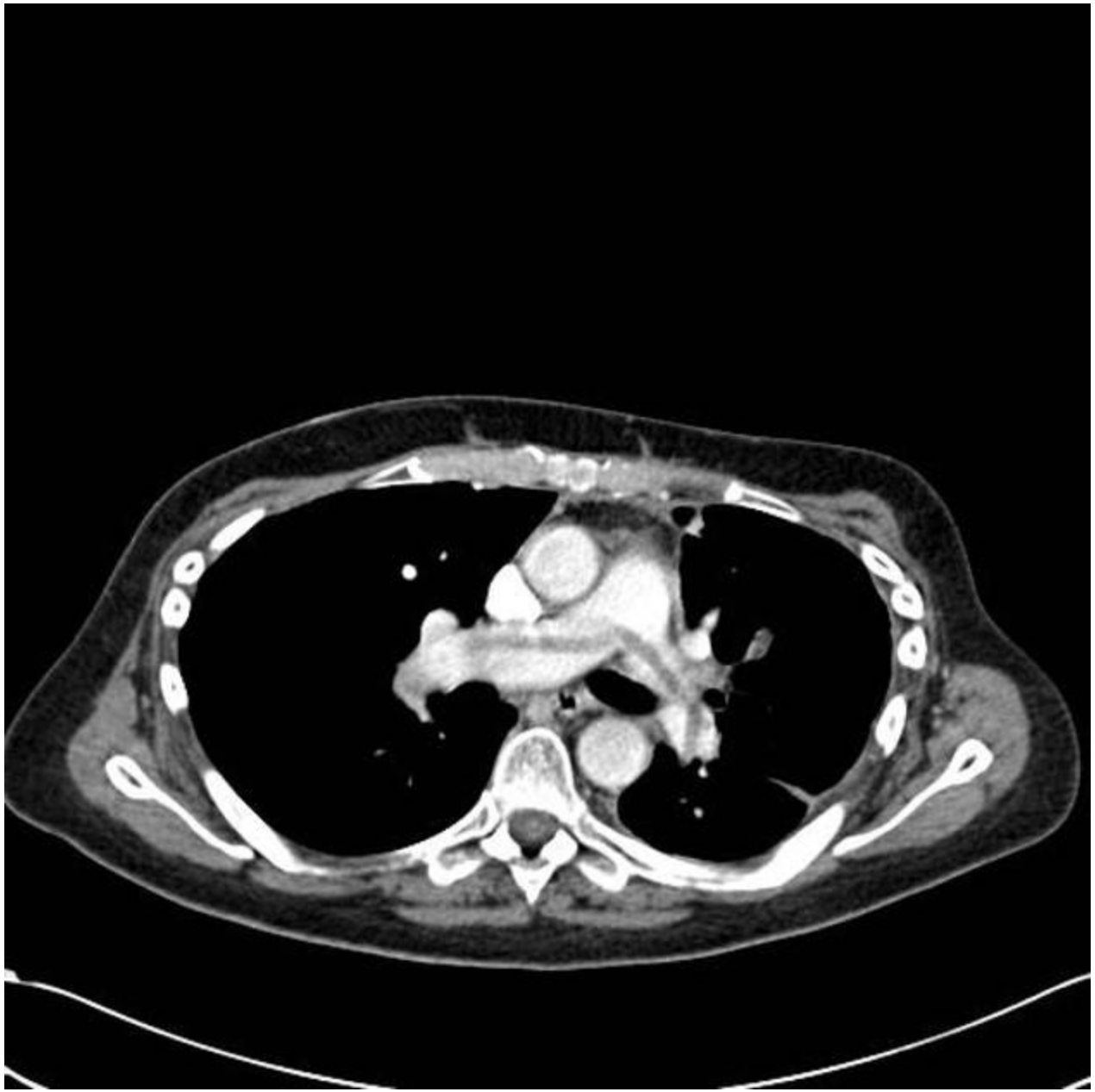



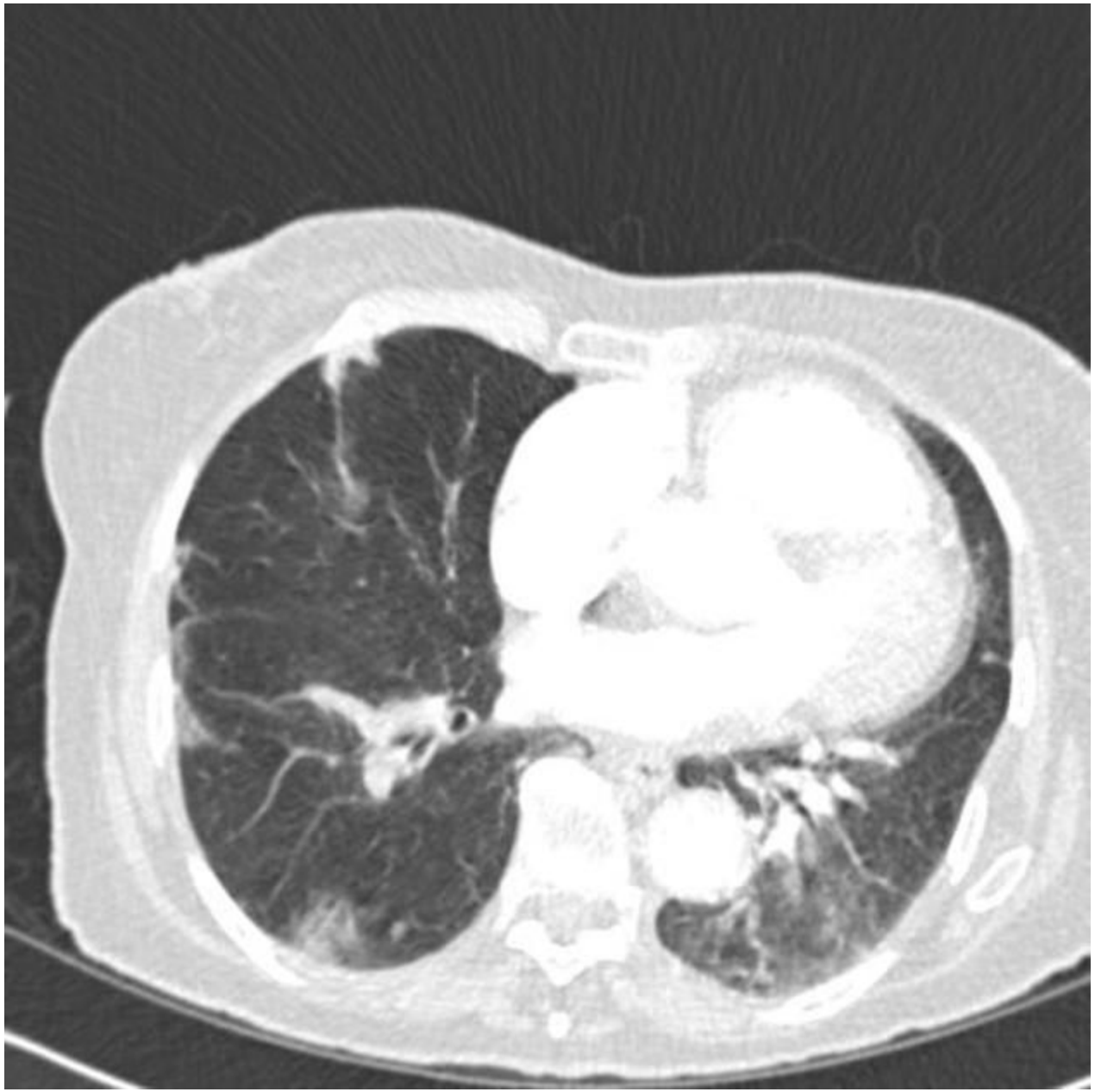

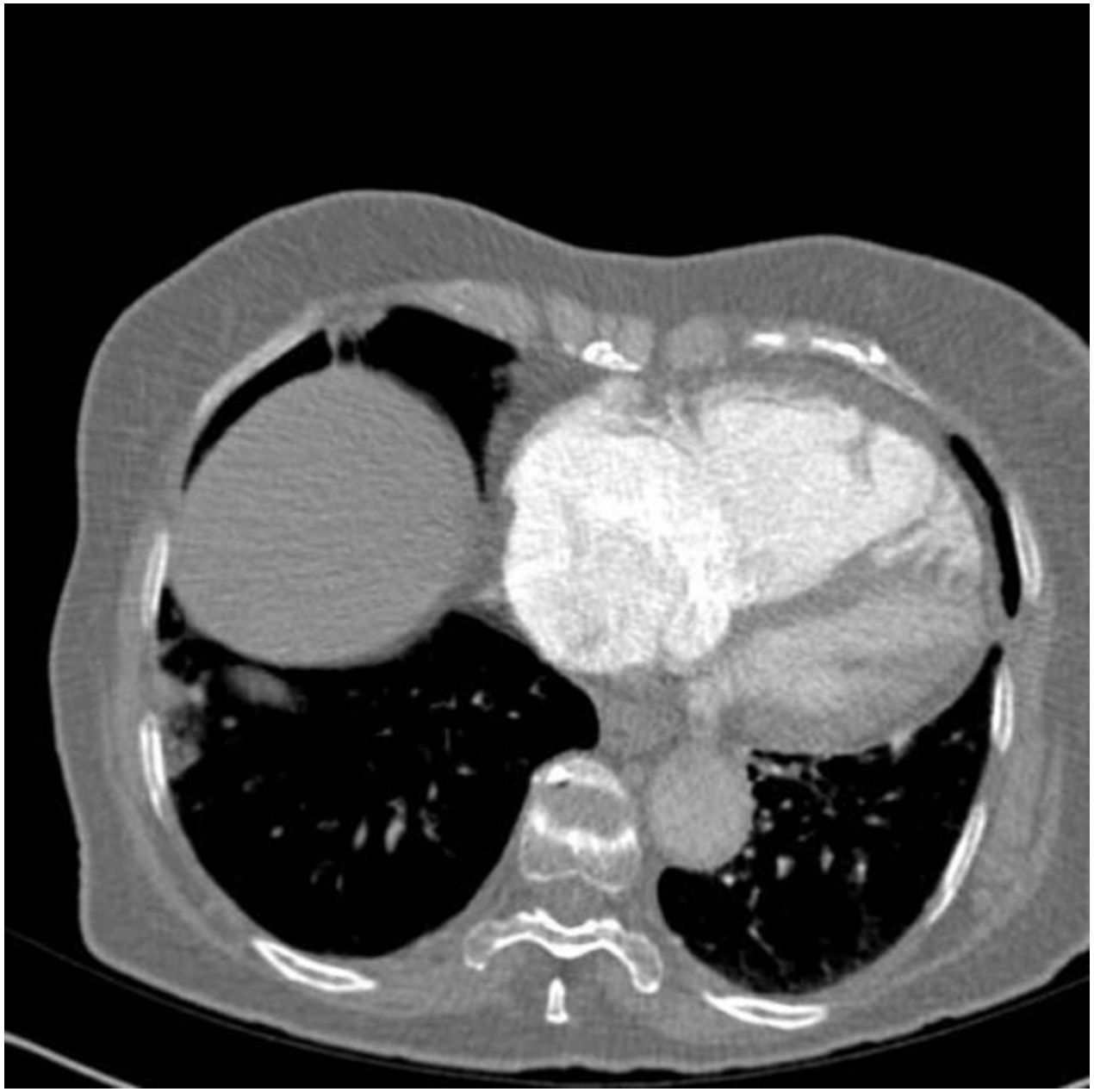

PULMONARY EMBOLISM(V/QSCAN)

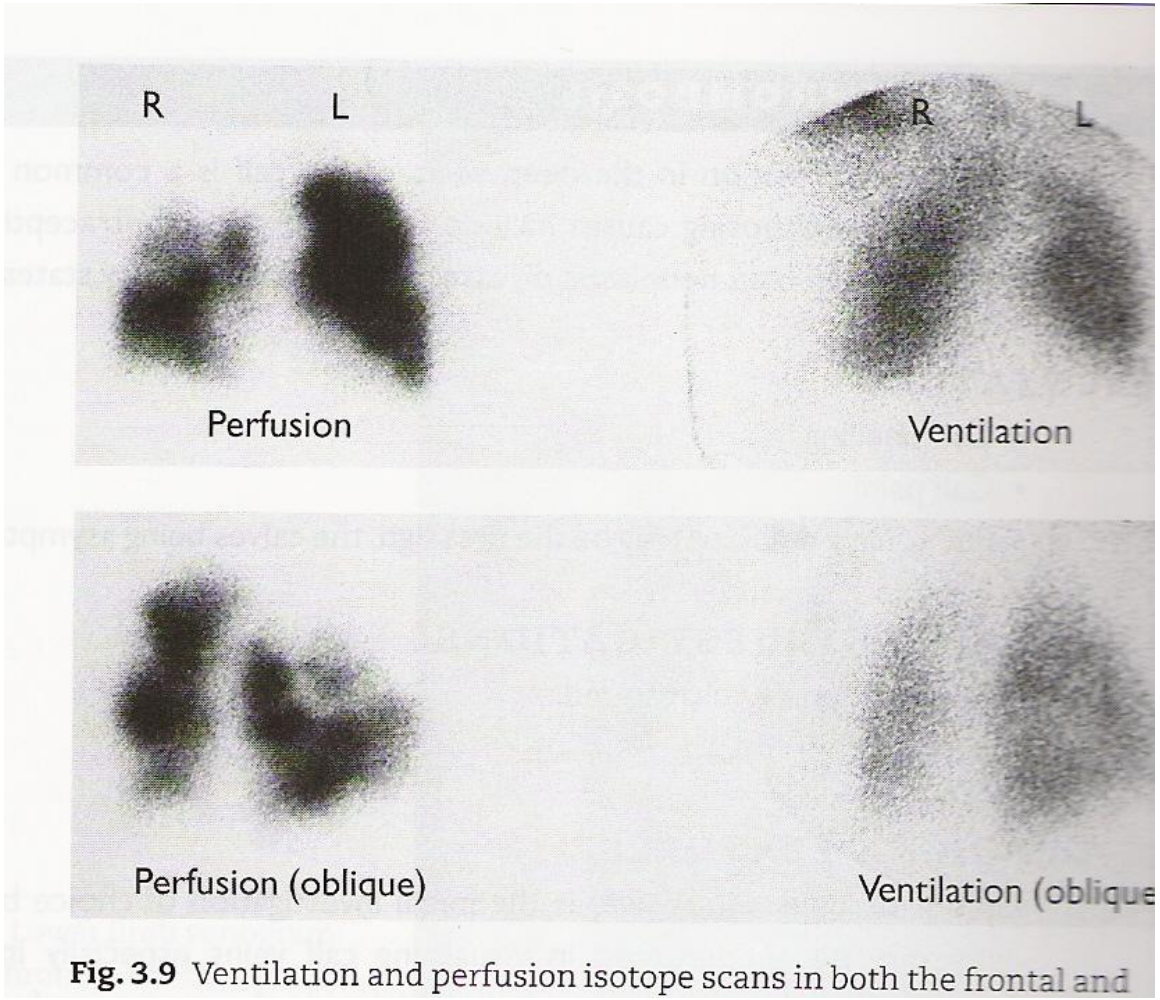

Fig. 3.9 Ventilation and perfusion isotope scans in both the frontal and

PULMONARY EMBOLISM(ANGIO)

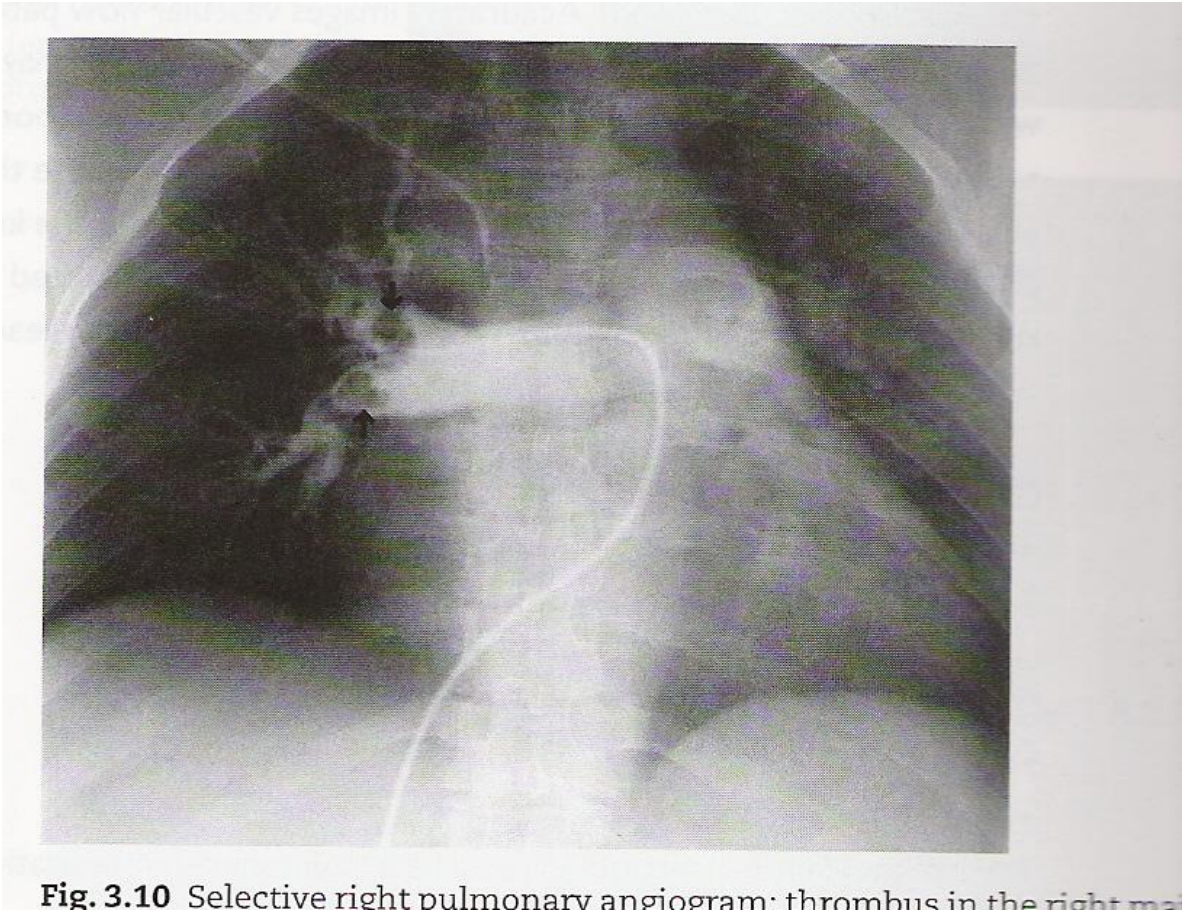

Fig. 3.10 Selective right pulmonary angiogram: thrombus in the right ma

AORTIC ANEURYSM

TYPES: traumatic, congenital, inflammatory, dissecting, degenerative.

IMAGING MODALITIES:

- Plain abdominal or chest films.
- U/S.
- CT & MRI.
- ARTERIOGRAPHY.

AORTIC ANEURYSM(PLAIN FILM)

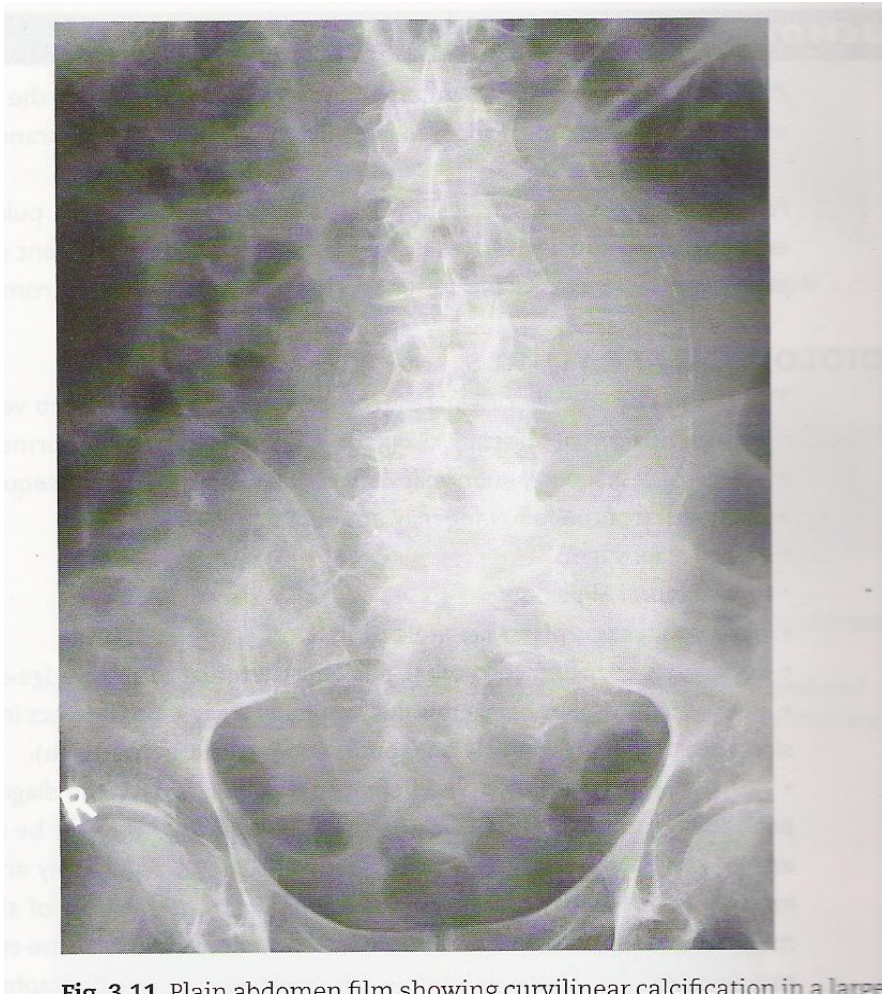

Fig. 3.11 Plain abdomen film showing curvilinear calcification in a large

AORTIC ANEURYSM(CT)

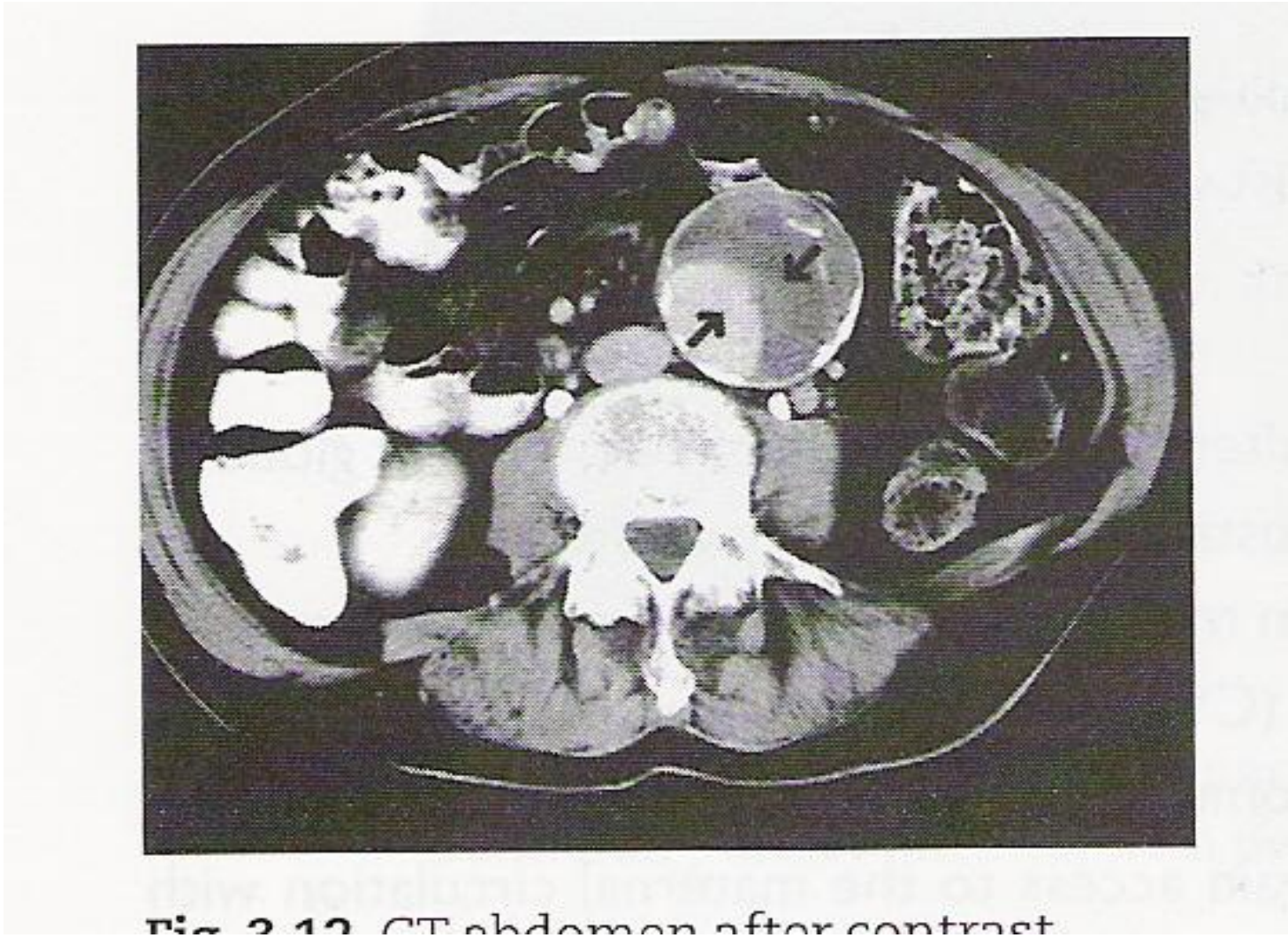

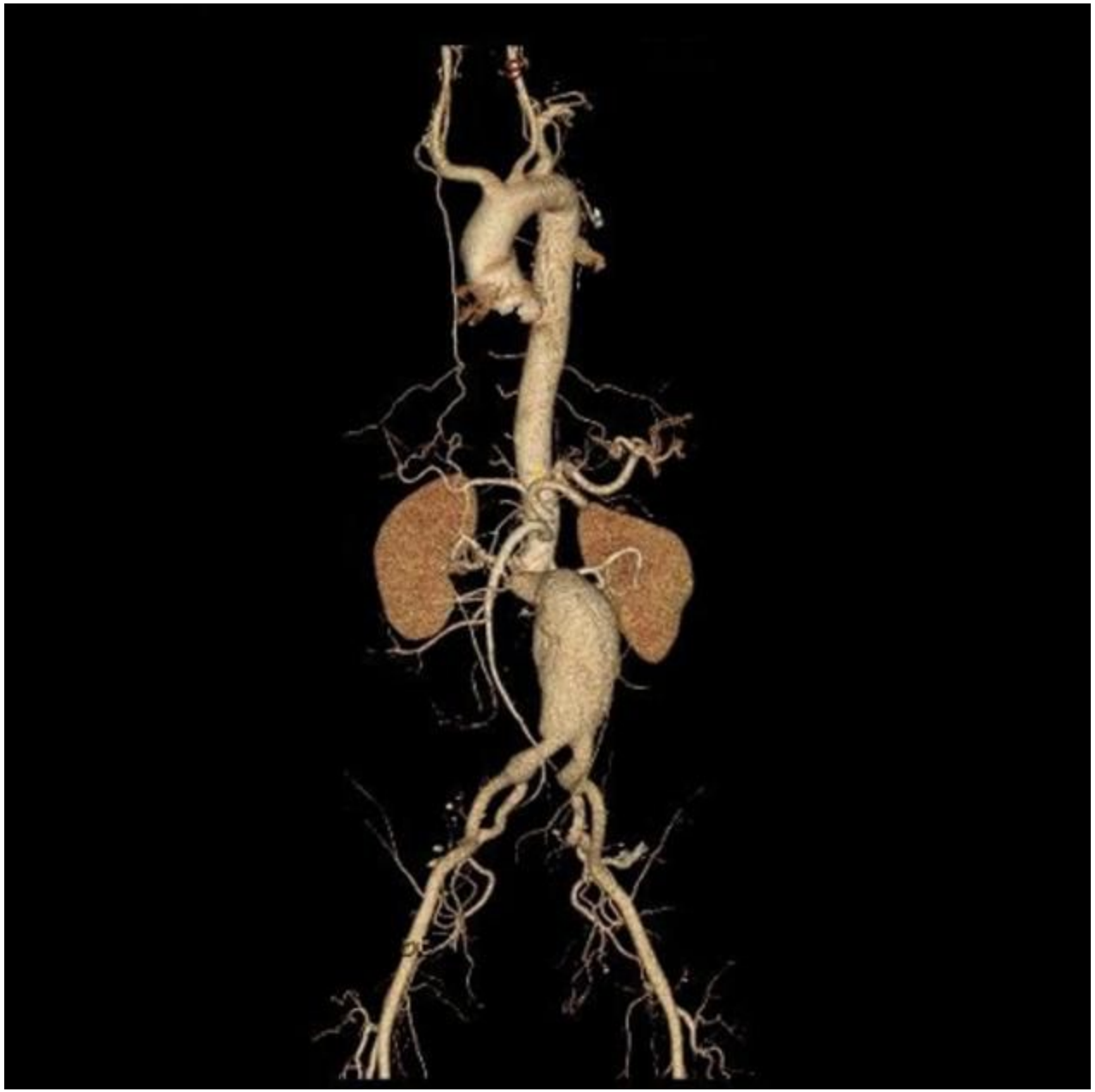


Warning: Not for diagnostic use

AORTIC ANEURYSM(US)



PERIPHERAL VASCULAR DISEASE

ARTERIAL INSUFFICIENCY. More in .LL, or arterial embolus

C/P: pain calves increase by exercise. Cold limb and ulceration

Radioogical tools: Doppler .u/s. arteriography



Fig. 3.14 Arteriogram: occluded segment in the right femoral artery.

ARTERIAL EMBOLUS

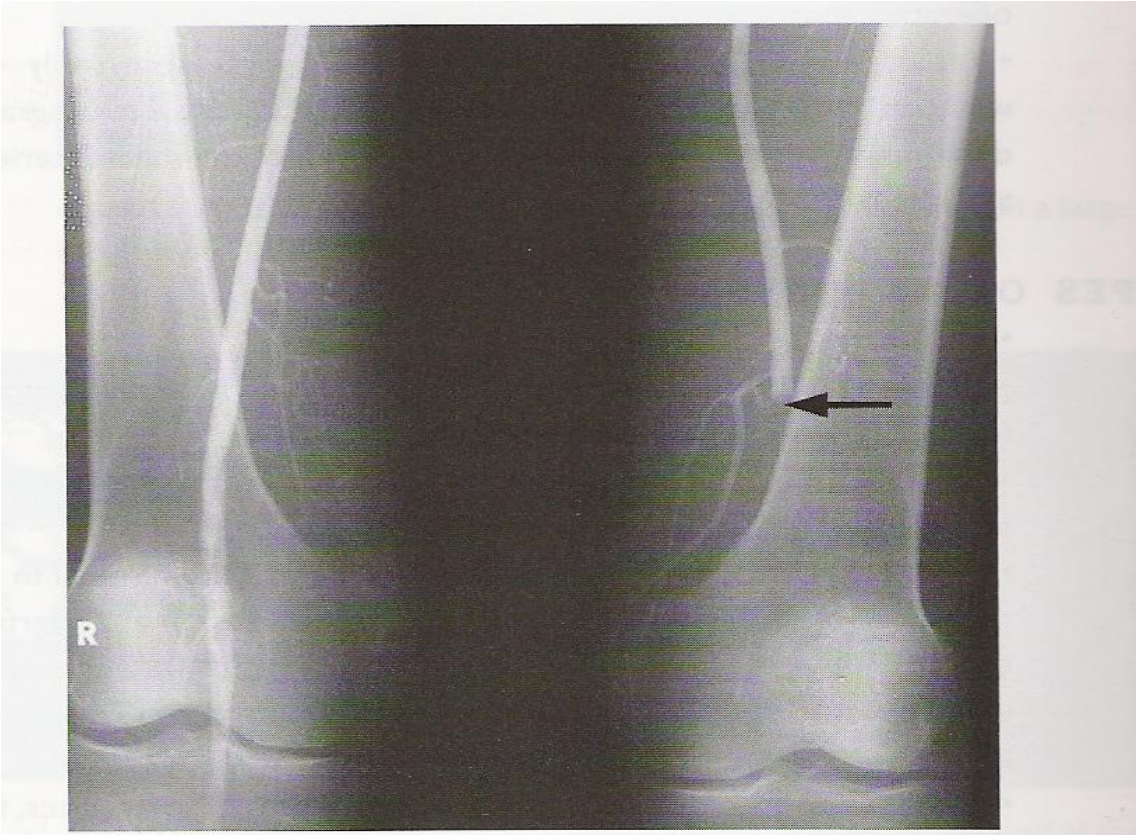

Fig. 3.15 Femoral embolus: sharp contrast cut off in the left femoral art

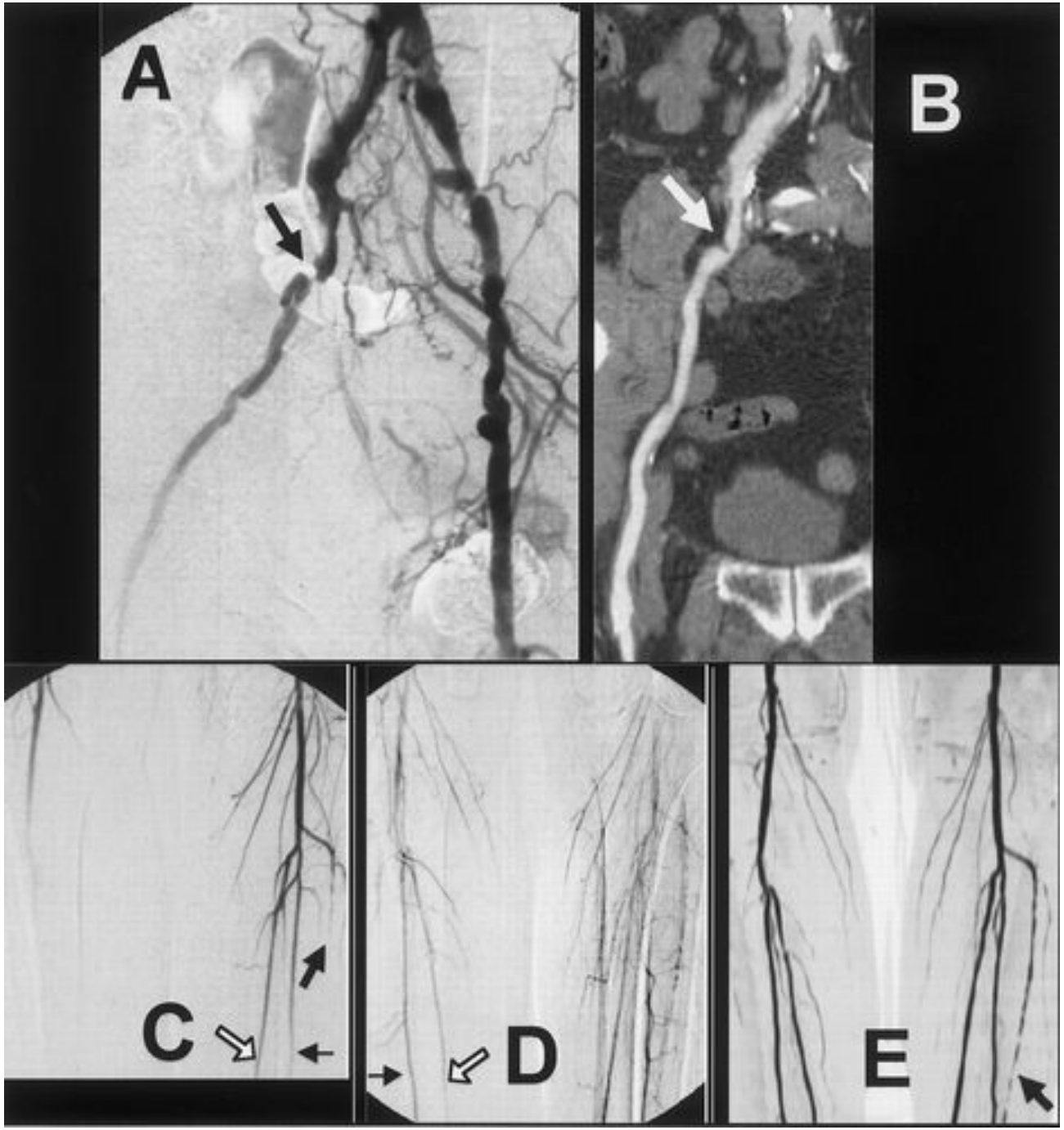
A
B
C
D
E

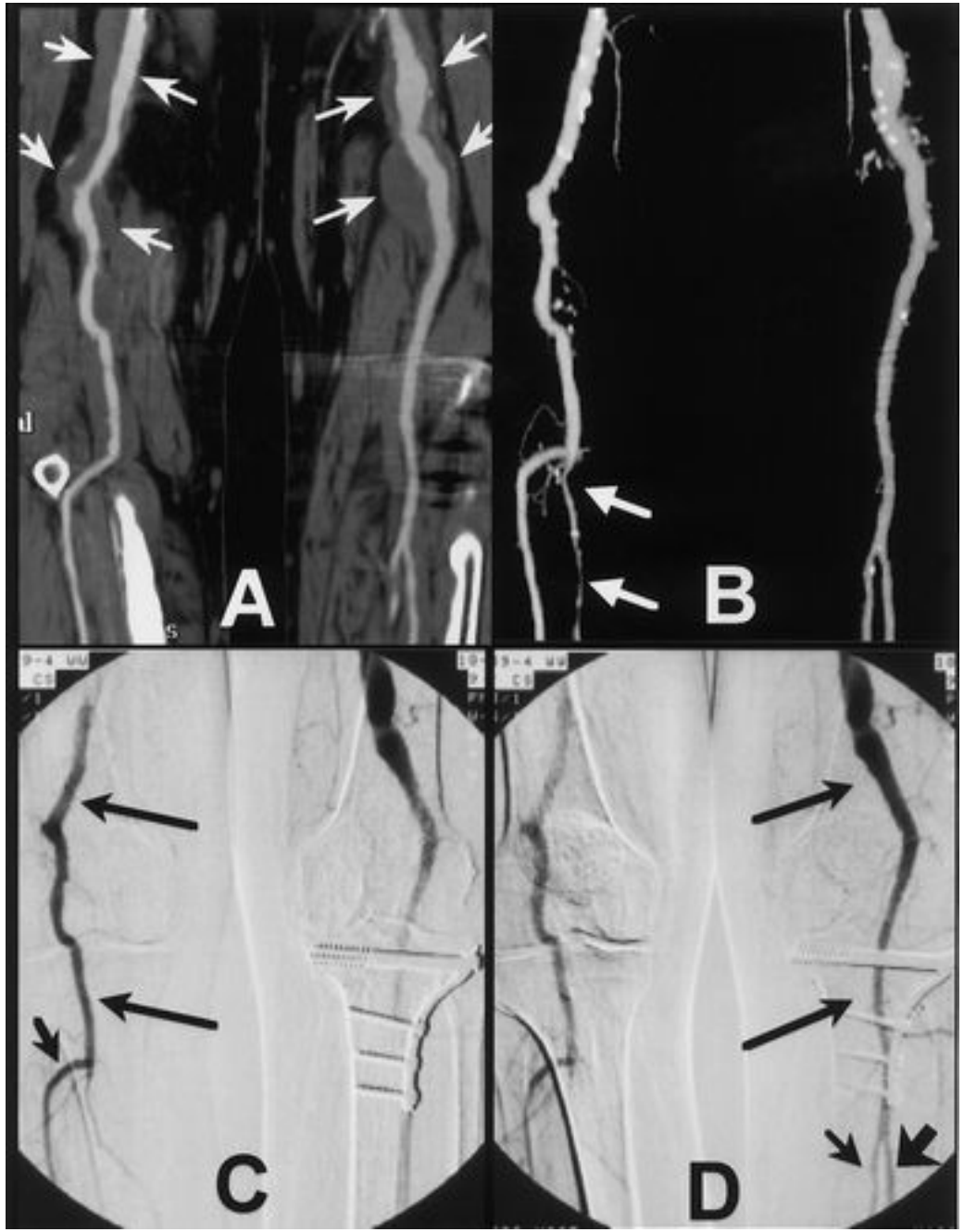
A
B
C
D

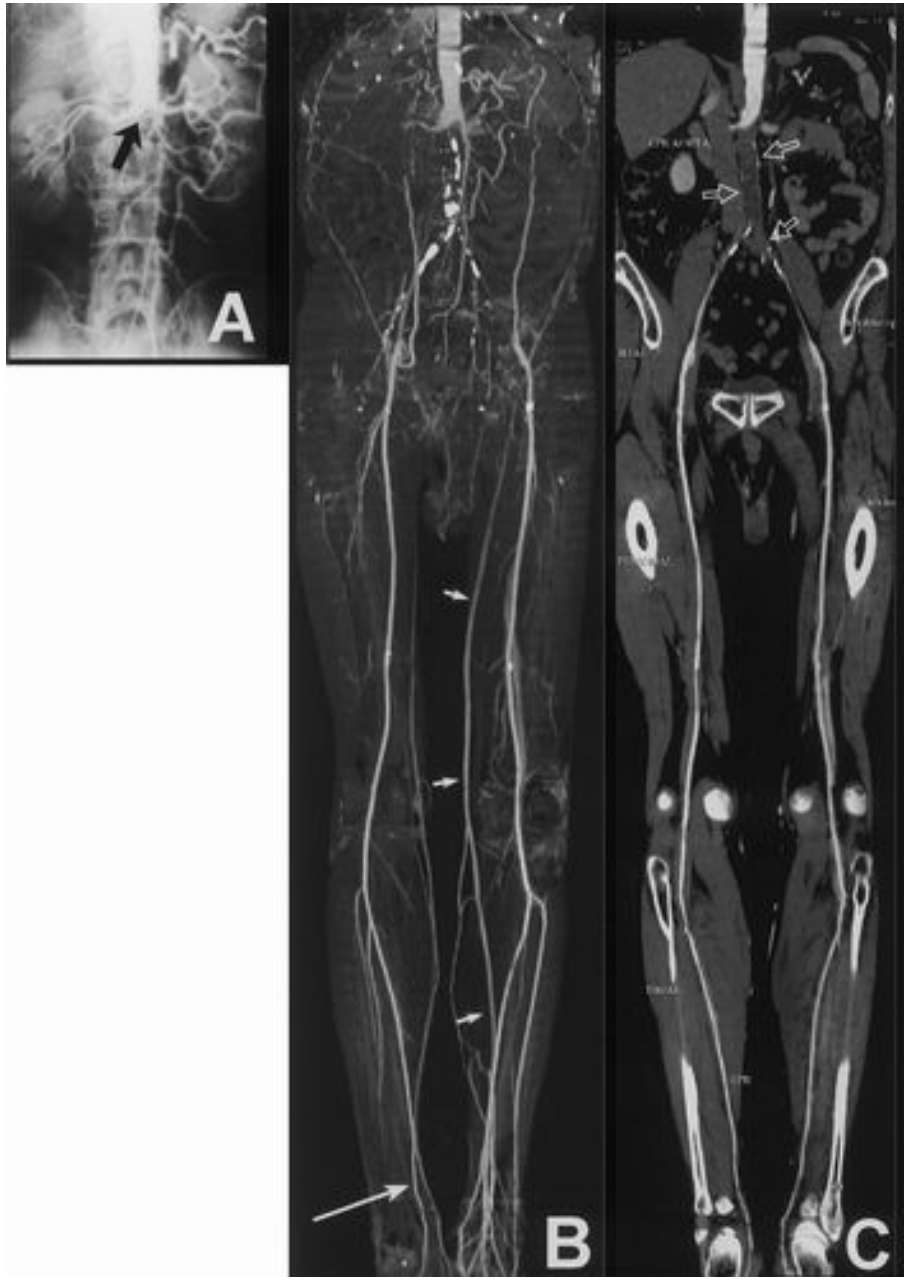
A
B
C

MRA



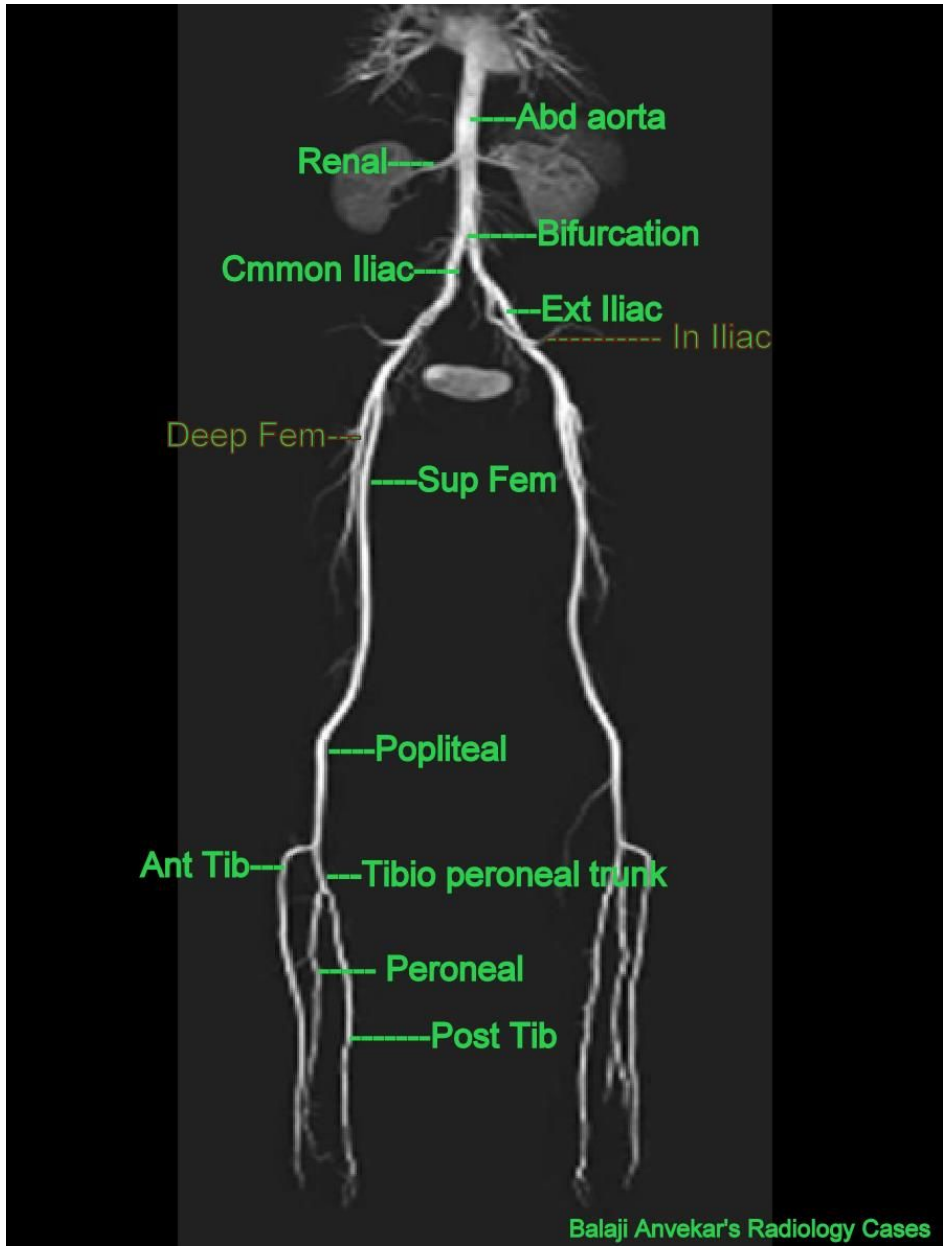
---Abd aorta
Renal----
-----Bifurcation
Cmmon Iliac----
---Ext Iliac
---------- In Iliac
Deep Fem---
----Sup Fem
----Popliteal
Ant Tib---
---Tibio peroneal trunk
---- Peroneal
-------Post Tib
Balaji Anvekar's Radiology Cases

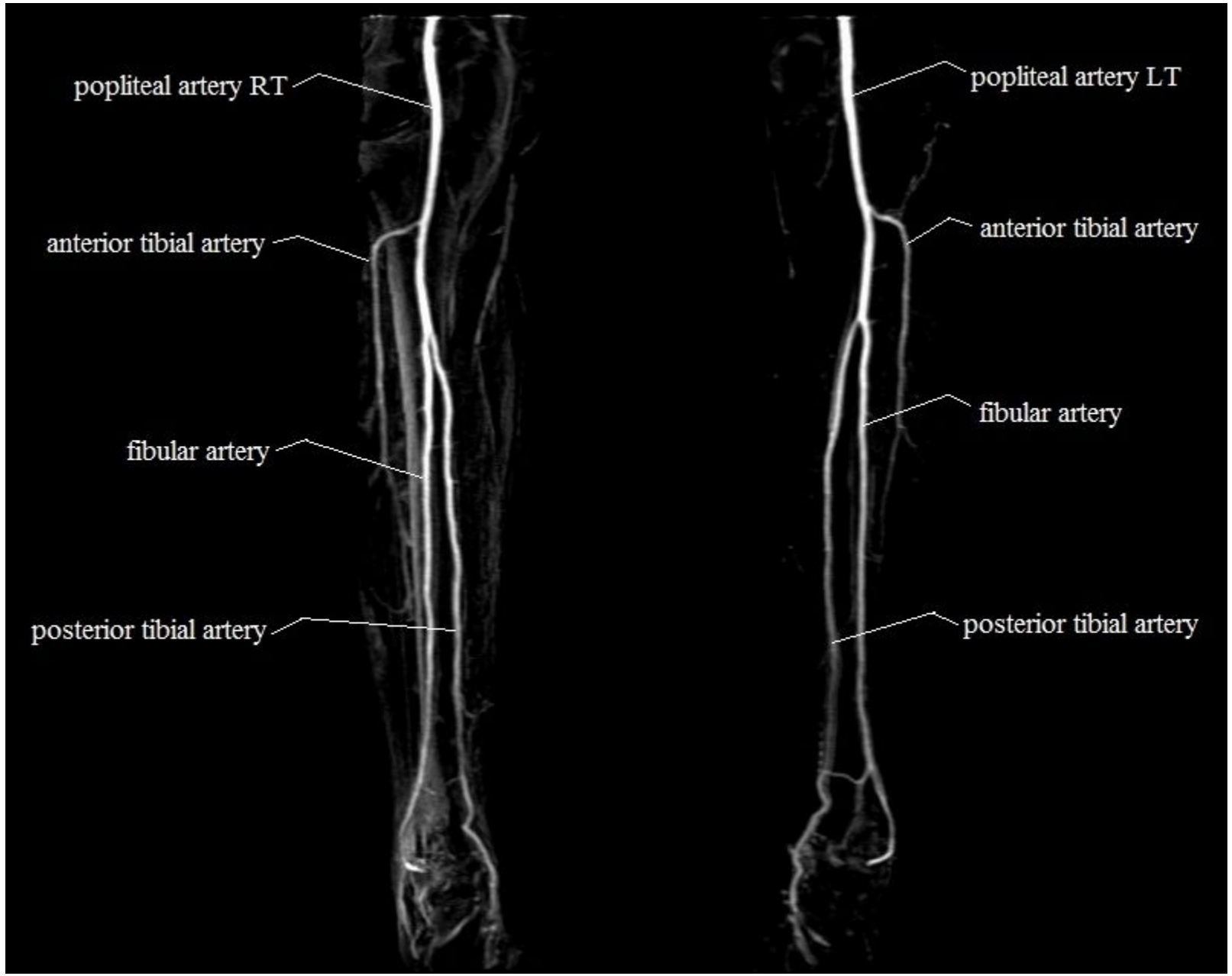
popliteal artery RT
anterior tibial artery
fibular artery
posterior tibial artery
popliteal artery LT
anterior tibial artery
fibular artery
posterior tibial artery

THANKS FOR LISTENING