MUSCULO-SKELTAL SYSTEM I

DR MOHAMAD MATAR

IMAGING MODALITIES

- X-ray
- US
- CT
- MRI
- ISOTOPE SCAN
- PET SCAN

Ultrasound

- Not available at all institutions
- Reproducible in trained hands
- Excellent for superficial soft tissue elements including tendons and muscle
- Patient friendly
- Small to moderate expense

Ultrasound

- Routine exam room equipped with adequate imaging devices
- Superficial gel (standard or aseptic) application with touch with transducer
- Usually static exam of architecture +/- vascularity assessment
- Potential for dynamic imaging







Ultrasound

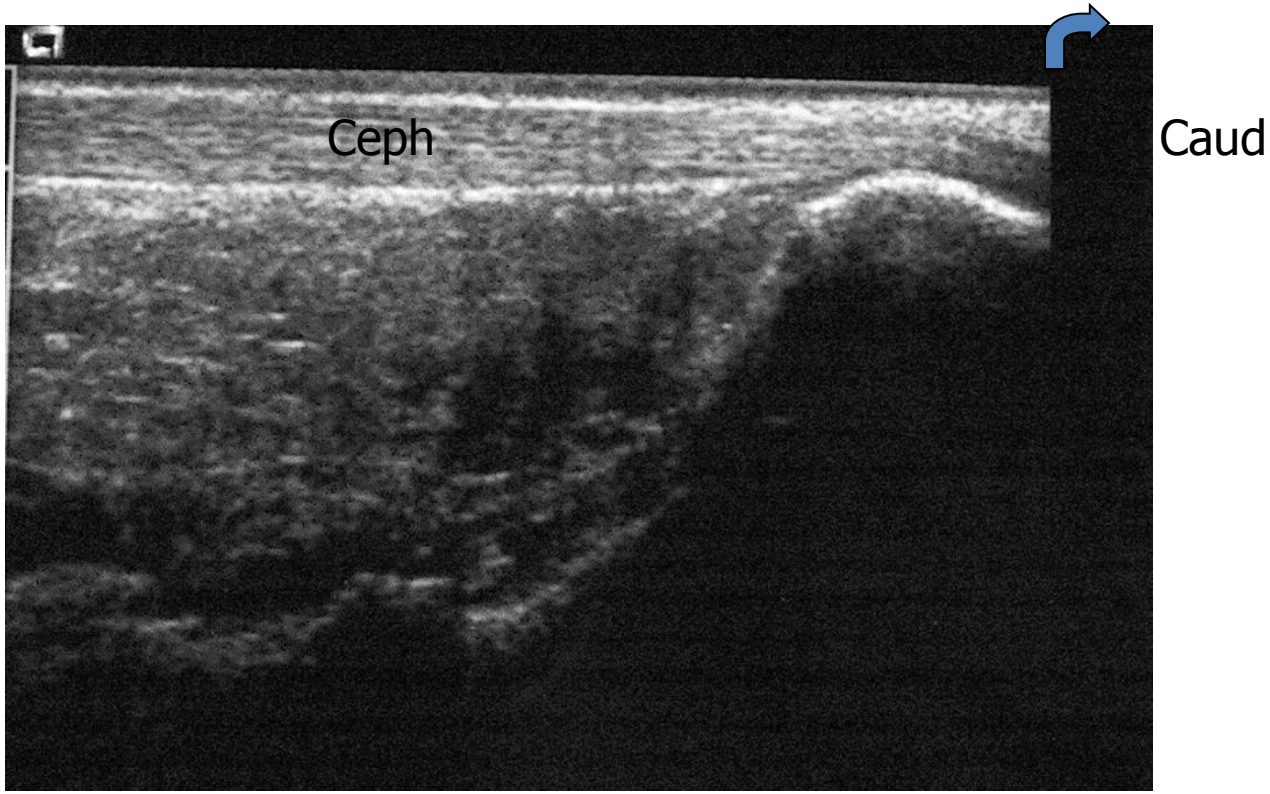

Cephalad

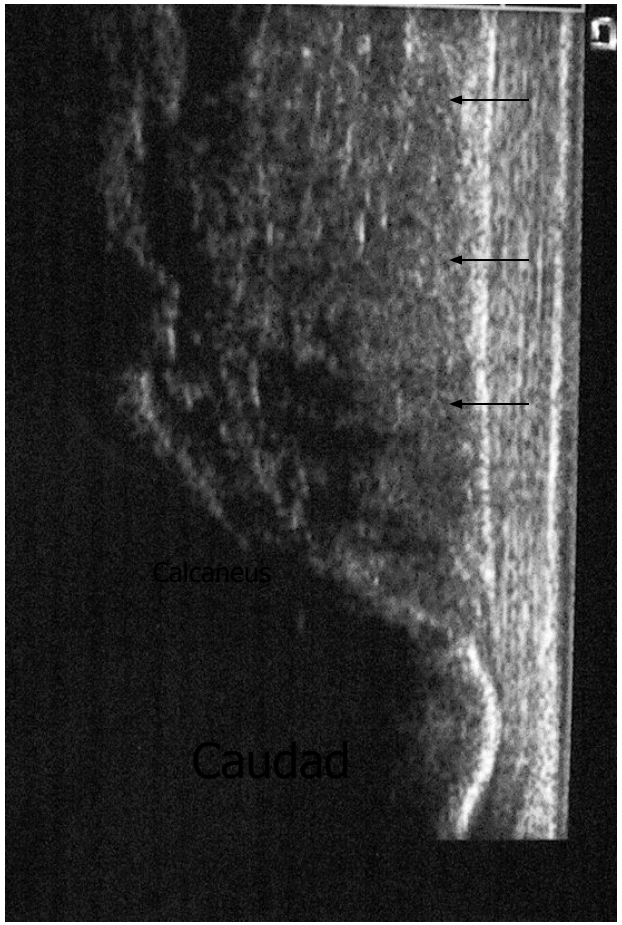

Ultrasound – Achilles Tendon

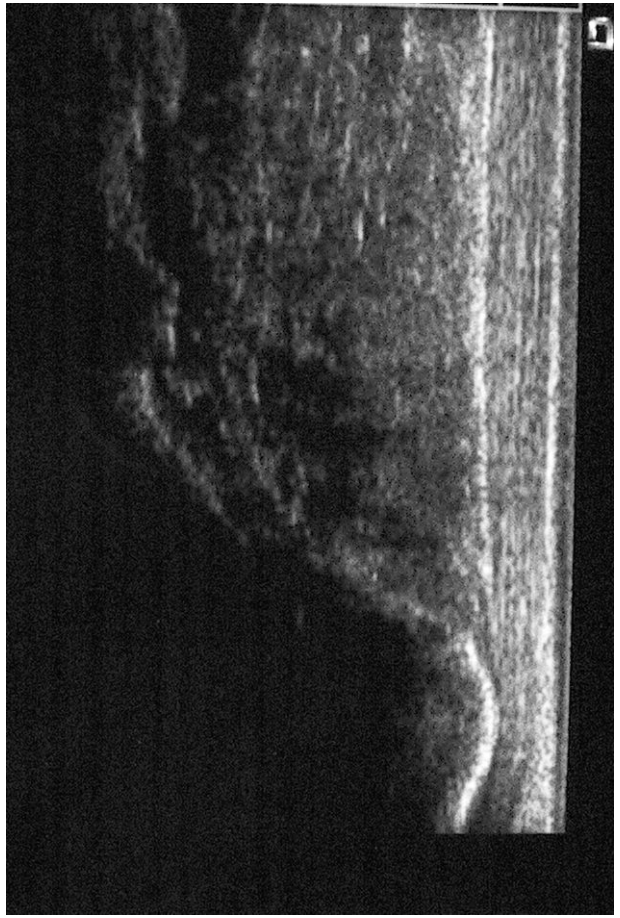

Intrasubstance tear

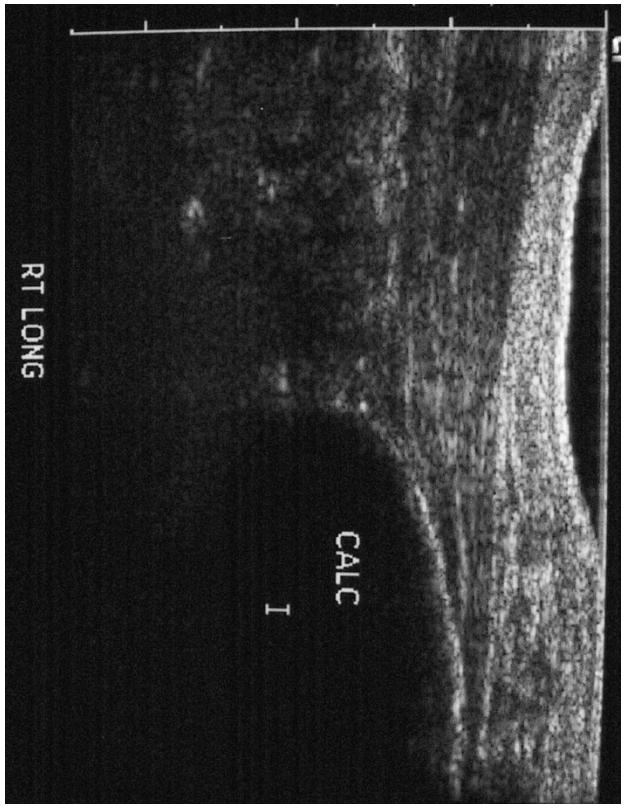

Ultrasound – Patellar tendon

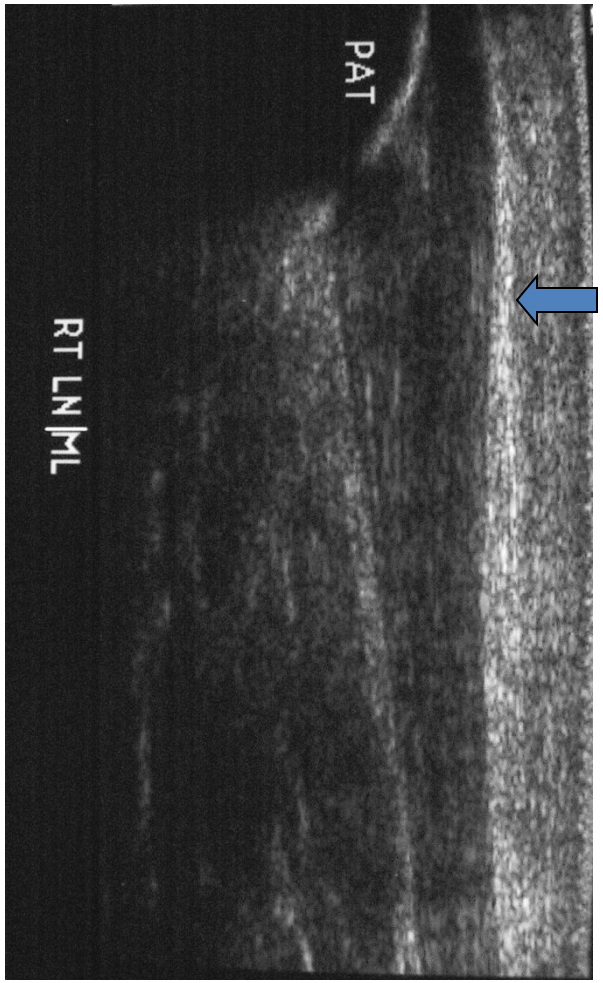

Proximal patellar – tendonitis

Jumper's Knee

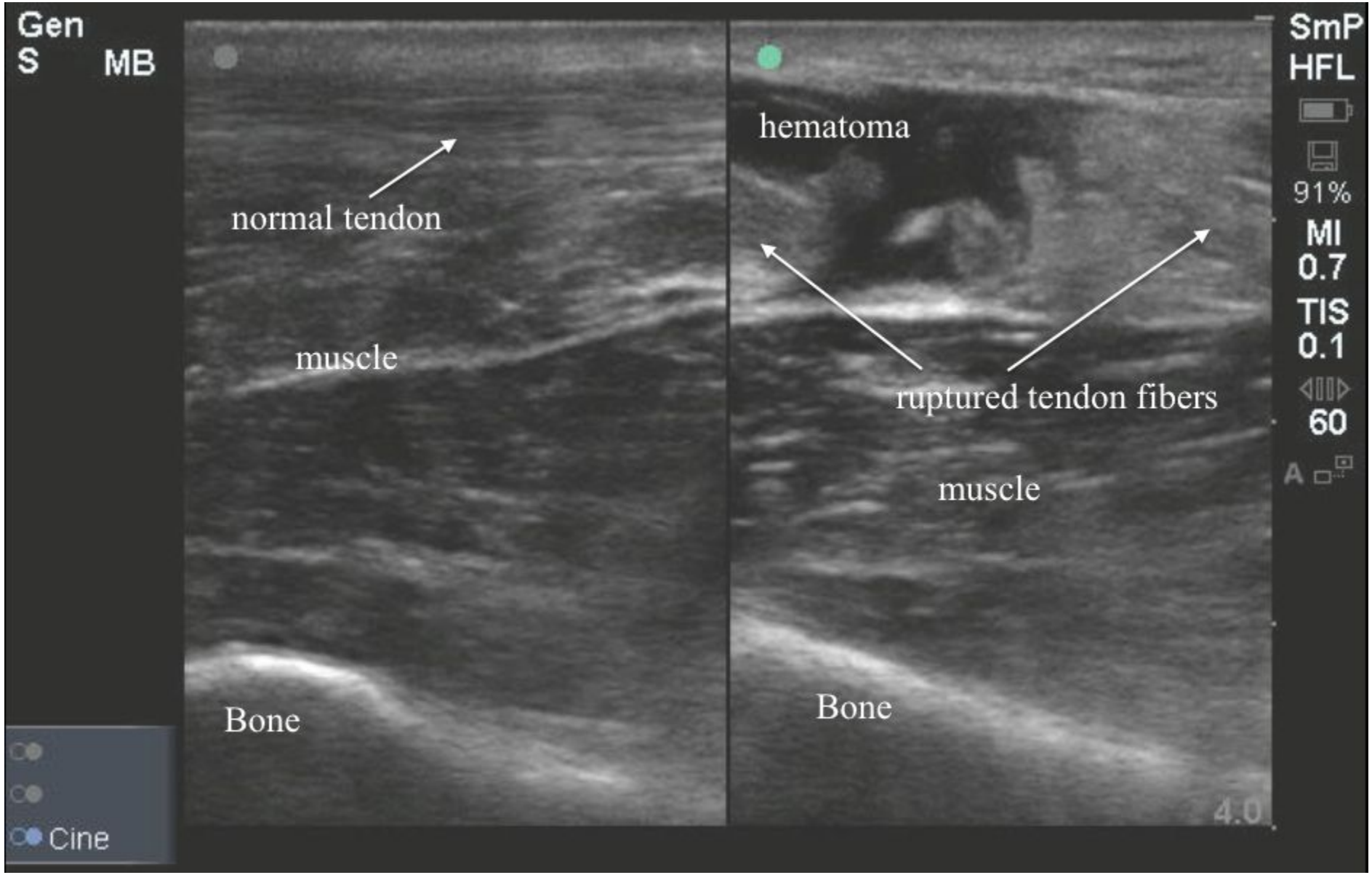
Gen
S MB
normal tendon
muscle
Bone
hematoma
ruptured tendon fibers
muscle
Bone
4.0
SmP
HFL
91%
MI
0.7
TIS
0.1
60
A
Cine


CI 45Hz
RV
2D
56%
C 58
P Moy
Rés
SE
3.5

Joint effusion

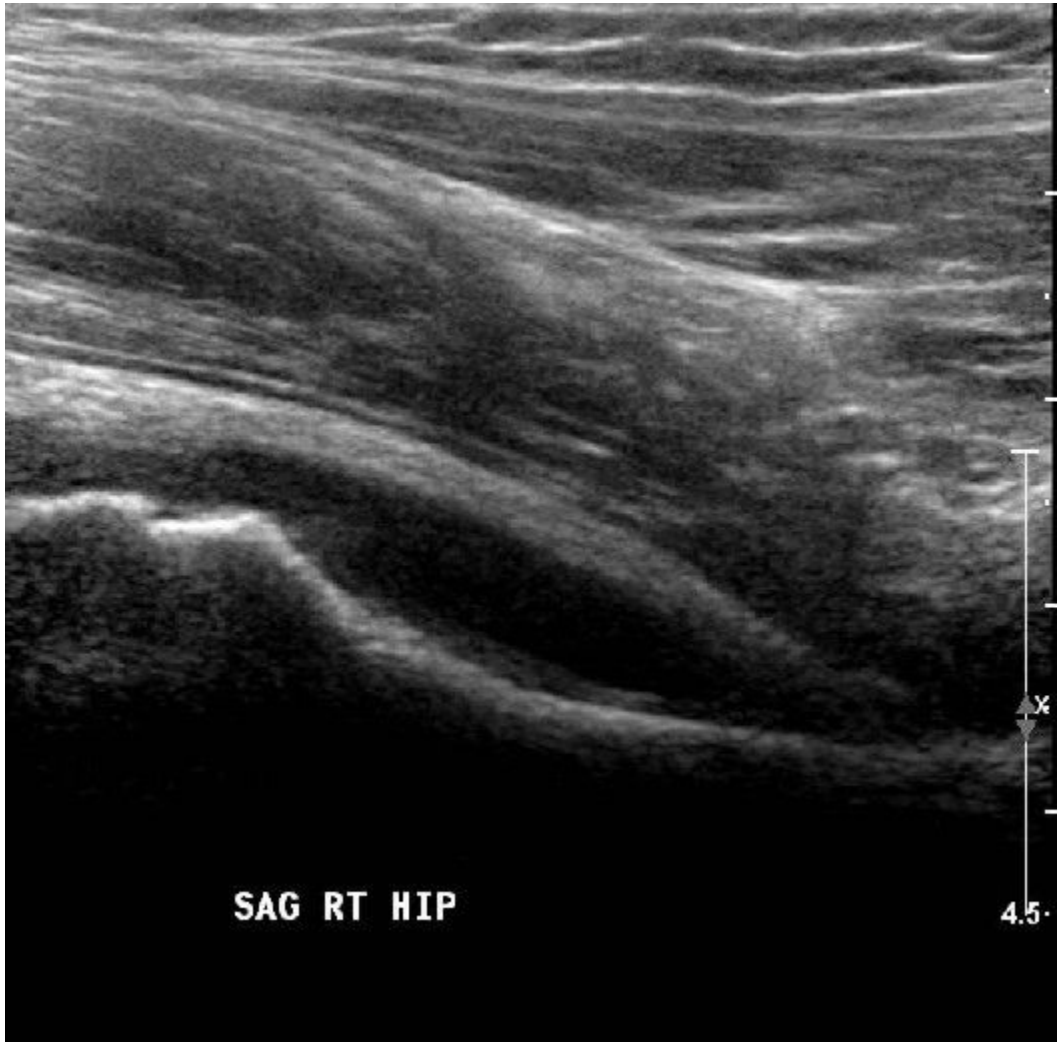

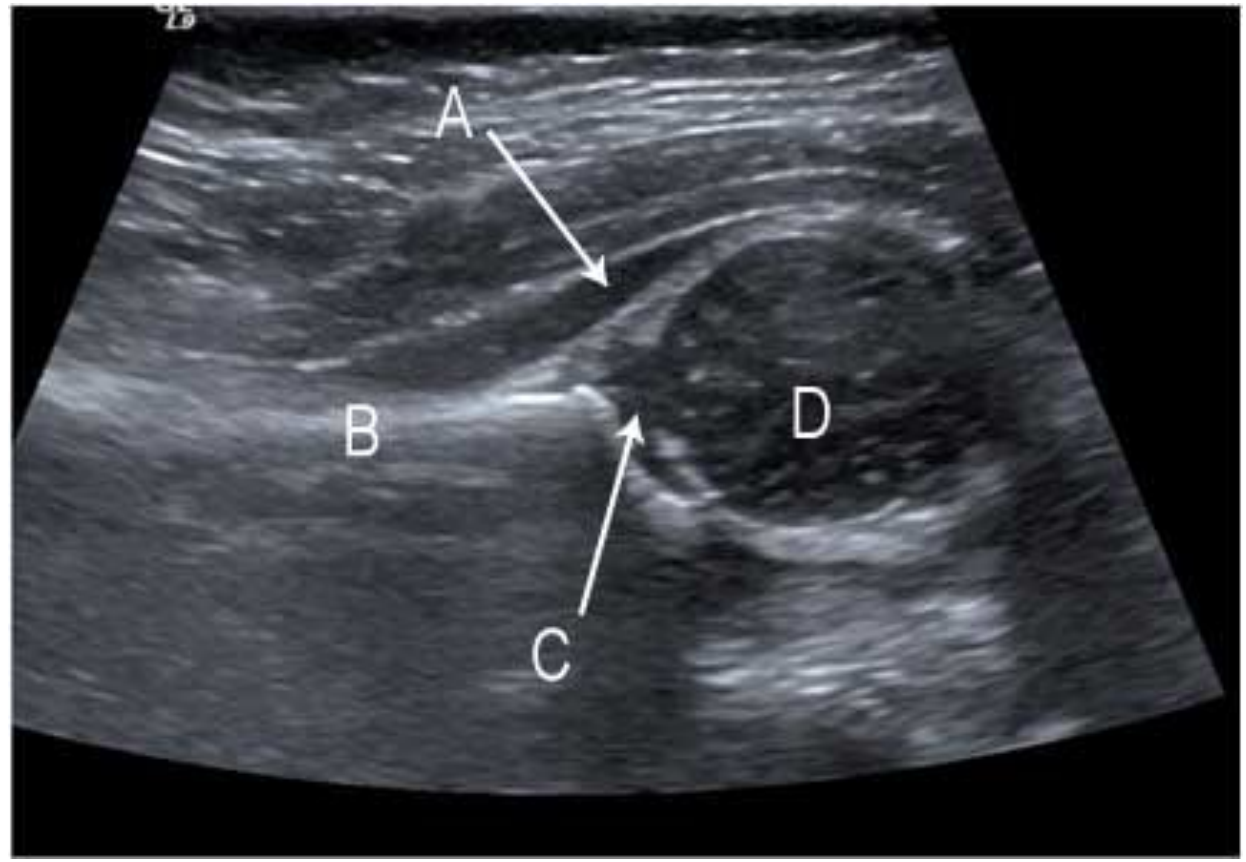
A
B
C
D

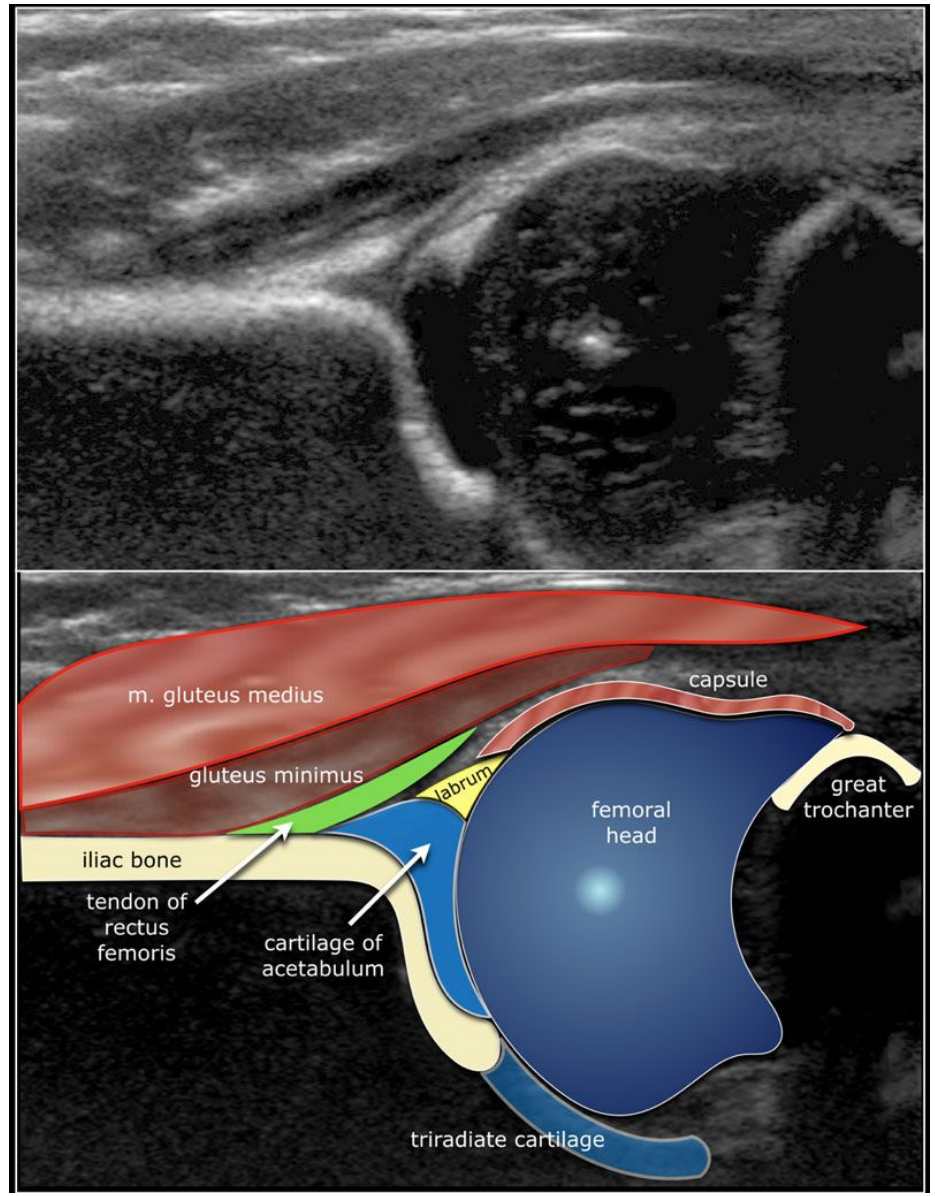
m. gluteus medius
gluteus minimus
labrum
capsule
great trochanter
femoral head
iliac bone
tendon of rectus femoris
cartilage of acetabulum
triradiate cartilage


VF8-3
PAEDHIP
42 dB
7.3 MHz
DR 60 dB
Edge 1
Persist 4
R/S 3
Map B
Tint 1
27 fps
LT HIP CORONAL
Fr239
4.5 cm
Page: 9 of 16
P 100% MI 0.48
IM: 9

Computed Tomography (CT)

- Widely available
- Reproducible, although variety of techniques
- Excellent bone assessment
- Occasionally useful for soft tissue assessment
- Patient friendly
- Moderate expense
- Interventional options

Computed Tomography

- Usually supine axial exam, with some alternative positioning options
- Can develop reformatted images after exam for alternative views
- Imaging time in seconds, rarely minutes
- Usually without IV or oral contrast



CT - Fractures

Scaphoid fracture



CT - Dislocation





Lis Franc Fx/Dislocation

CT – Bony anomalies

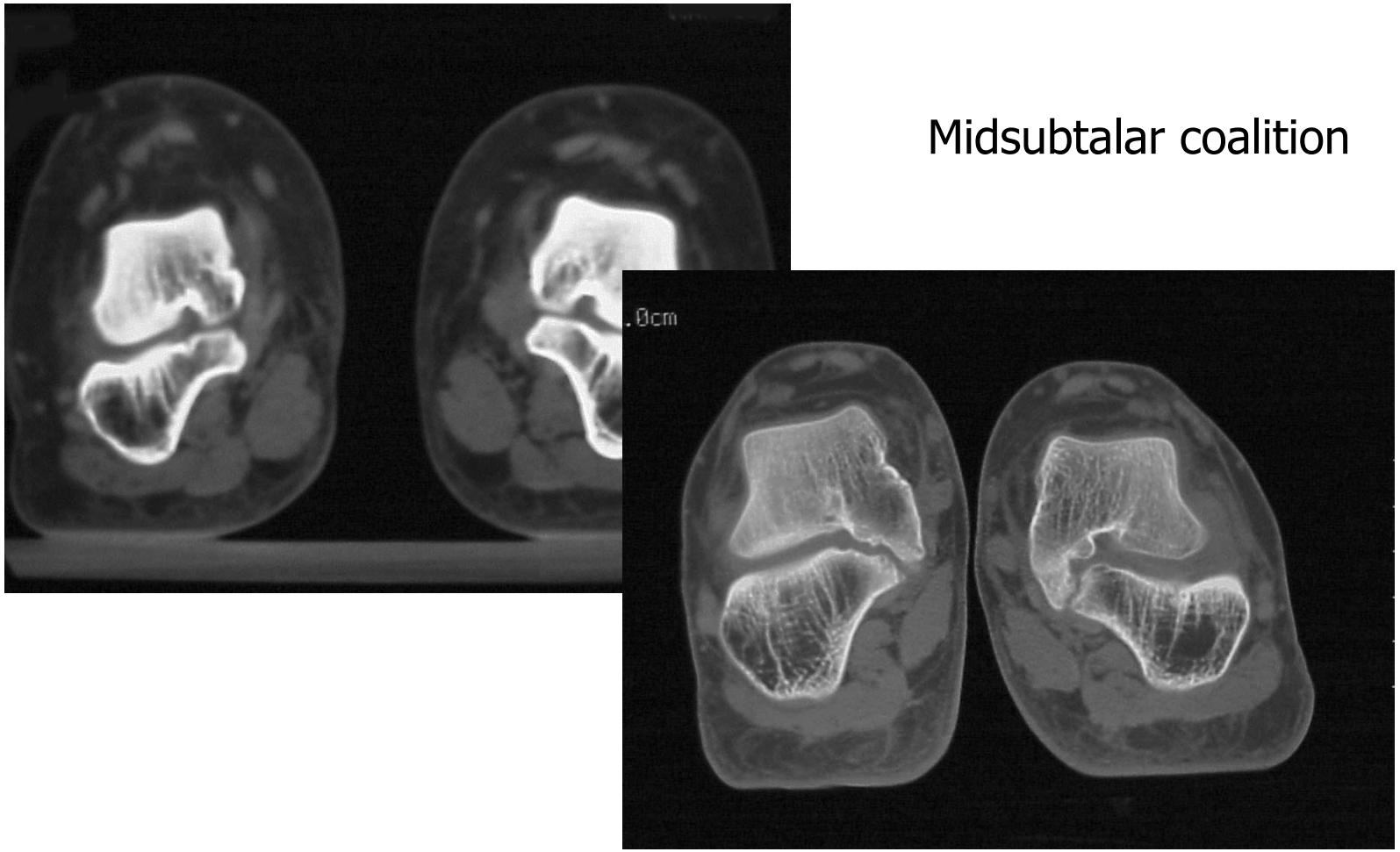

Midsubtalar coalition





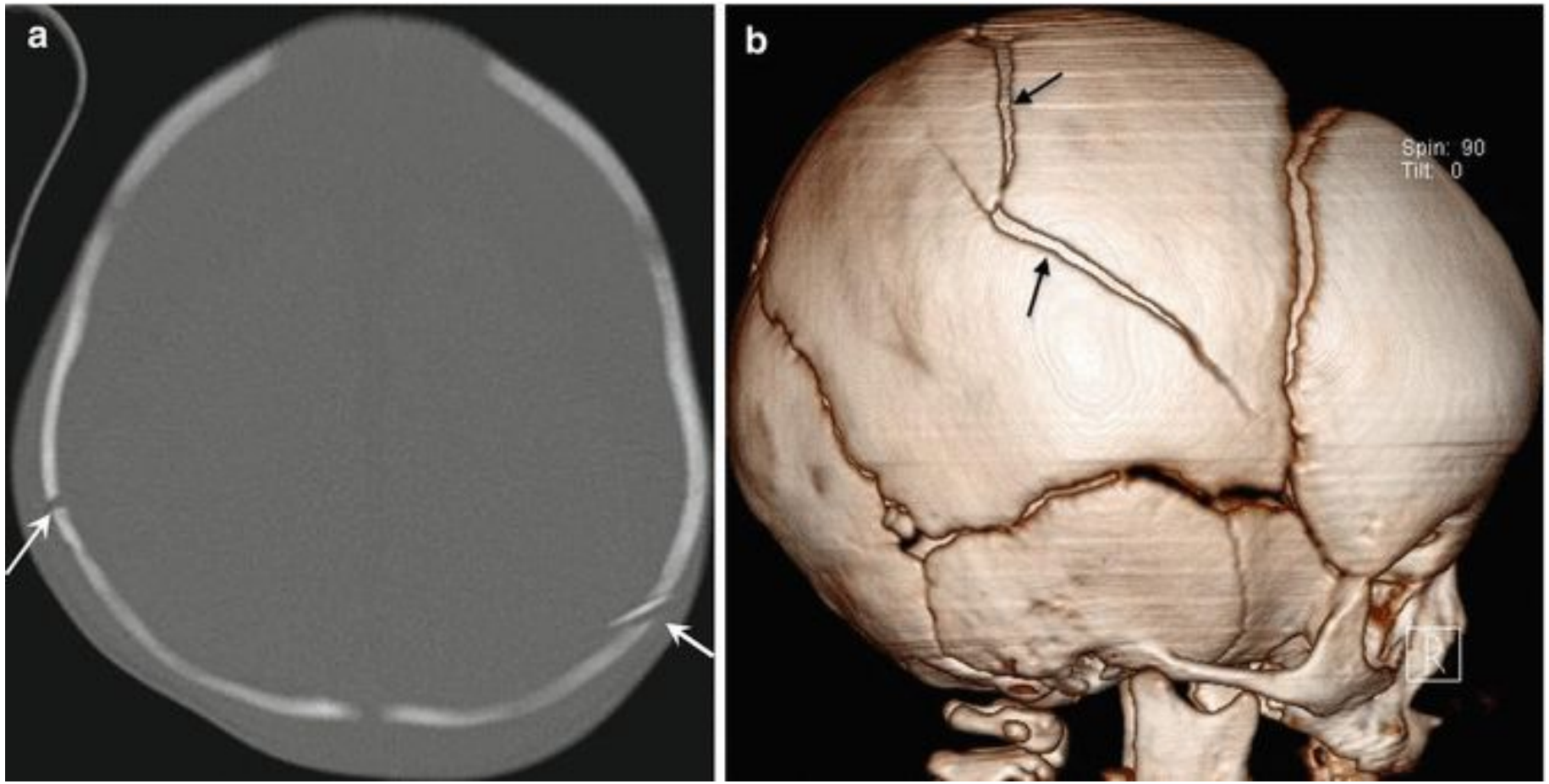
a
b
Spin: 90
Tilt: 0
R



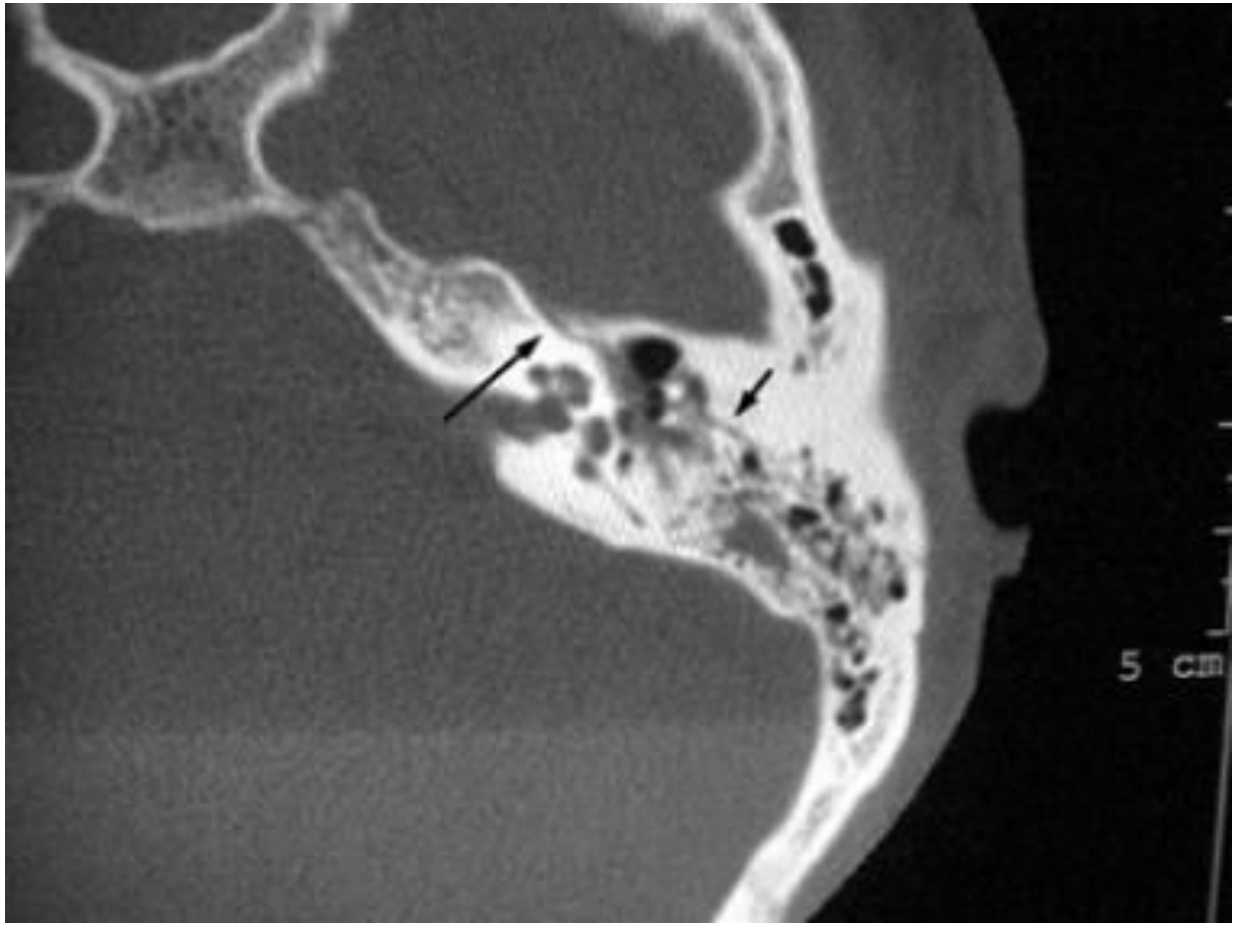
5 cm

Magnetic Resonance Imaging

- Widely available, but non-standardized imaging techniques
- Reproducible
- Excellent for soft tissue pathology
- Good-excellent for bone pathology
- NOT patient friendly
- Large expense

MRI – Absolute Contraindications

- Cardiac Pacemakers
- Electronic stimulators
- Metallic foreign bodies in the orbit
- Body habitus beyond limits of physical unit

MRI - Relative Contraindications

- Penile prostheses
- Cardiac valves
- Berry aneurysm clips
- Retained bullet fragments
- Claustrophobia

MRI

- Usually performed with patient supine
- Multiplanar imaging obtained without changing position
- One exam = one body part
- Average exam time 45 minutes; most patients can’t last >2 hours
- **Strict** guidelines for sedation
- Optional contrast – Rad usually decides for body imaging



OPEN

CLOSED





MRI – Trauma

Osteochondritis dissecans

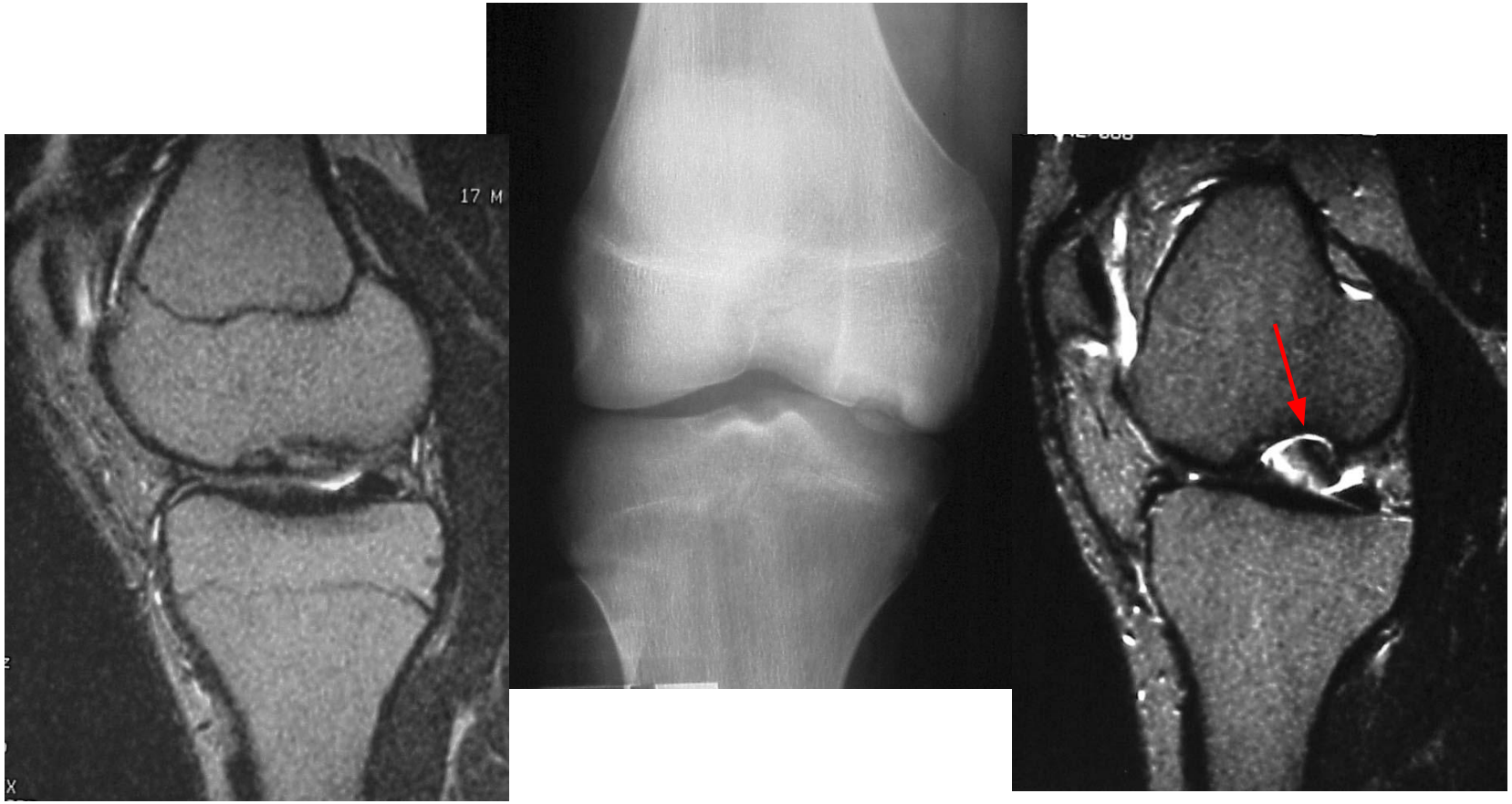

MRI – Trauma

Femoral Neck Fracture

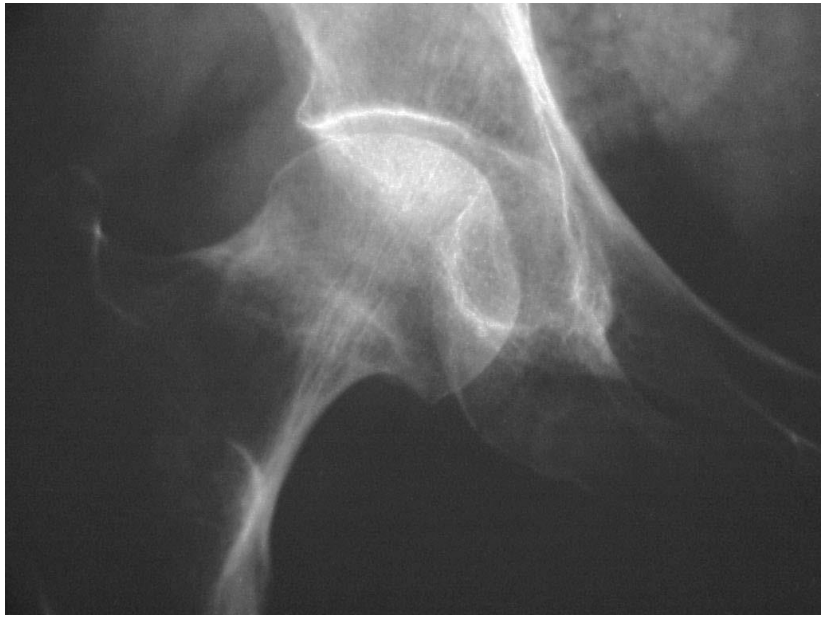

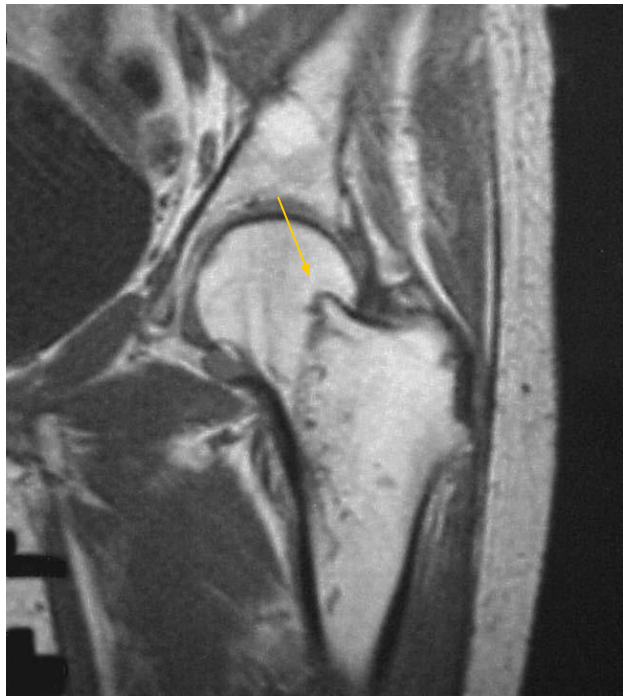

MRI - Trauma

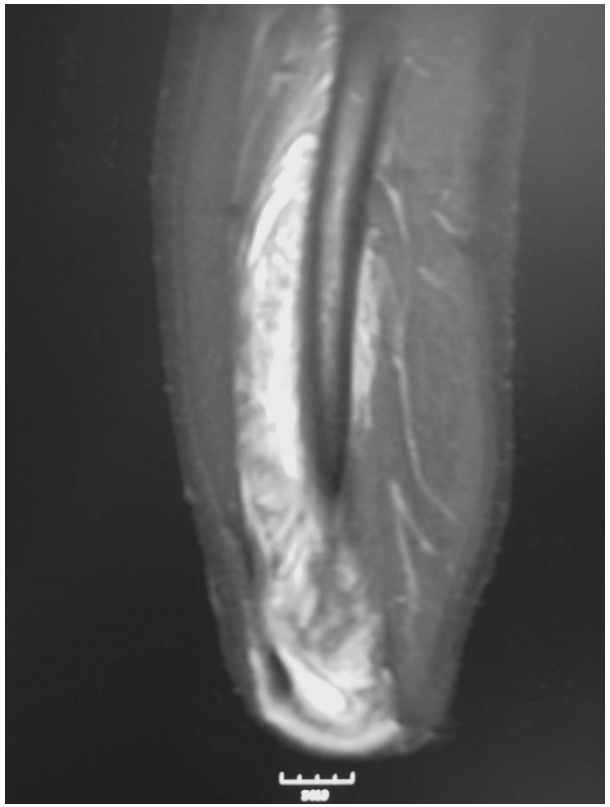

Tear vastus medialis

MRI – Internal Derangement

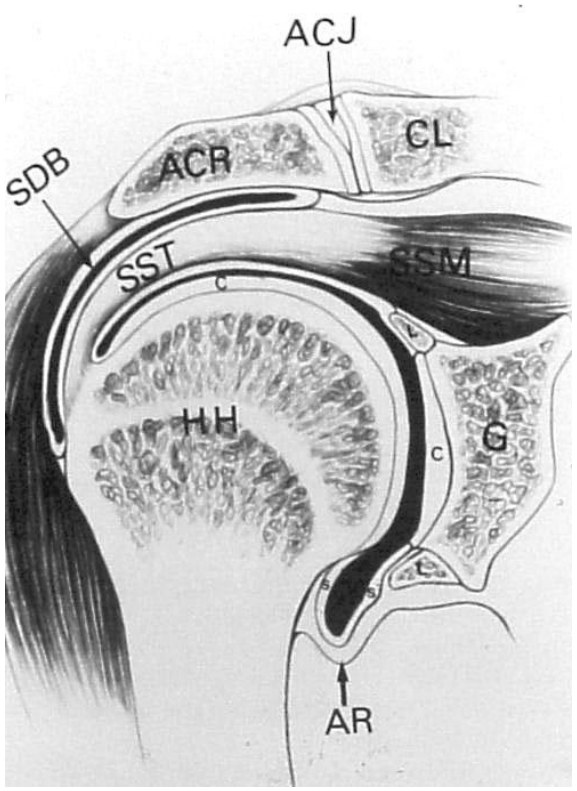



MRI – Internal Derangement

Supraspinatus tear= Full thickness, Fu



Coronal PD

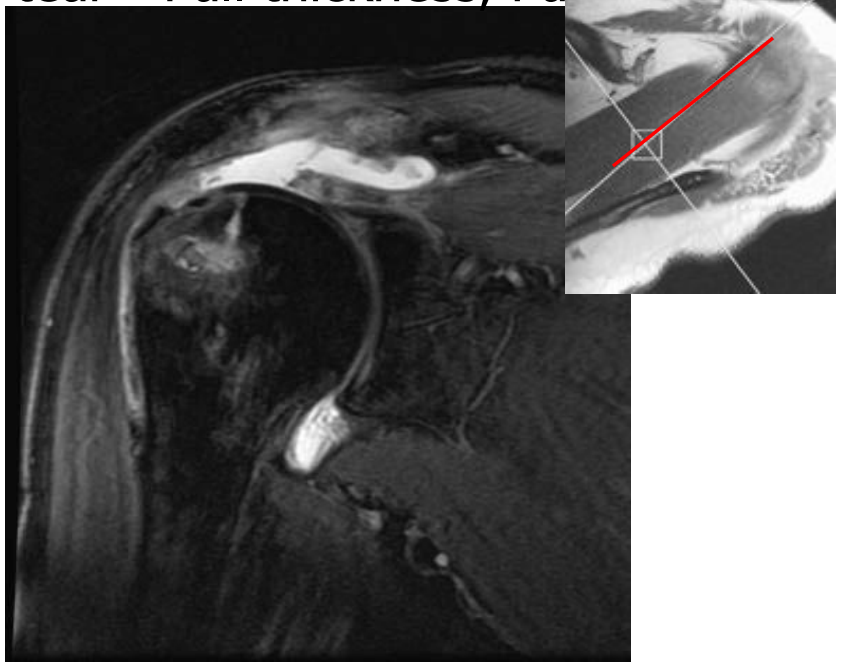

Coronal T2

MRI – Internal Derangement



Sagittal NL

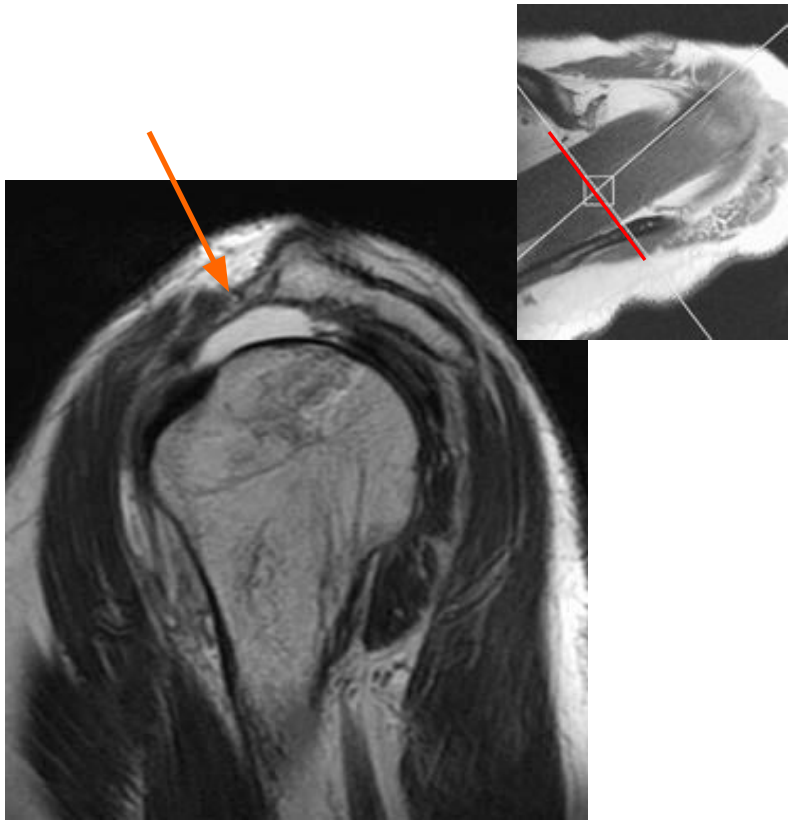

Sagittal FT, FW Supra

MRI – Internal Derangement

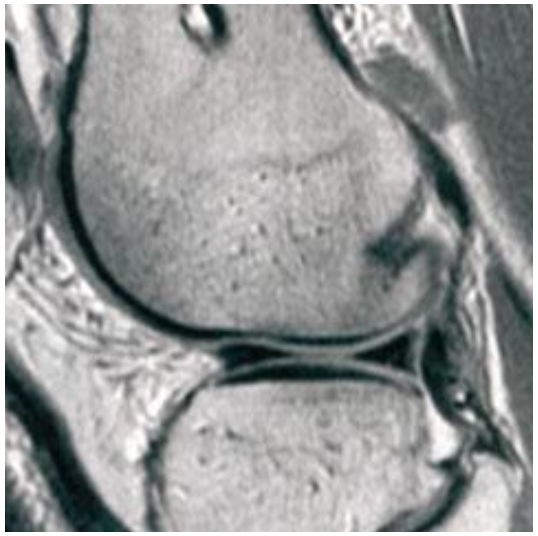

Sagittal, Meniscus NL

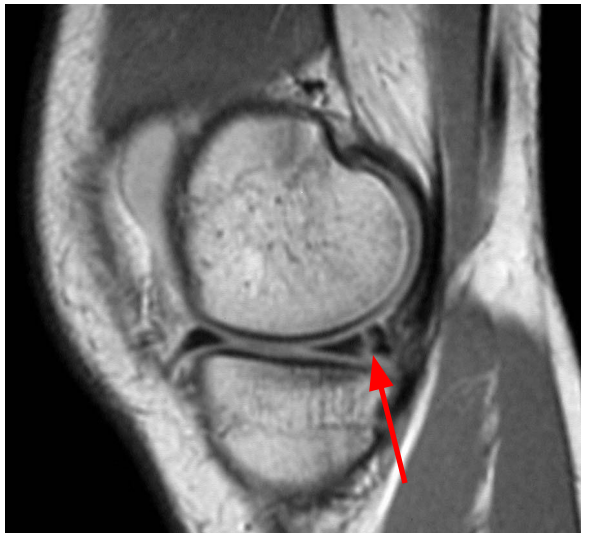

Posterior Horn Tear

MRI – Internal Derangement

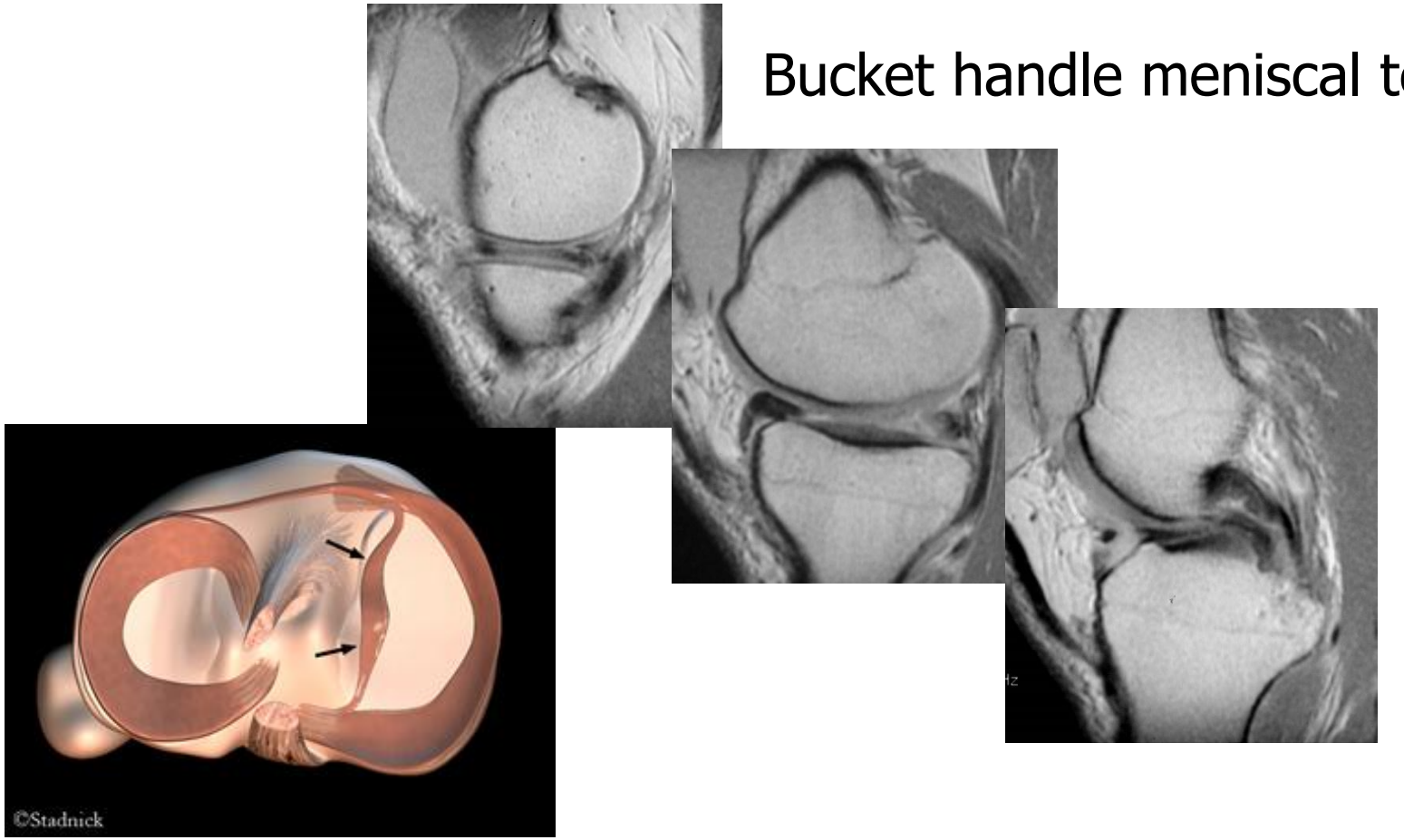

Bucket handle meniscal tear

MRI – Internal Derangement



Sagittal – Intact ACL ⬆

Torn ACL ➡



Malignant Hibrous Histocytoma

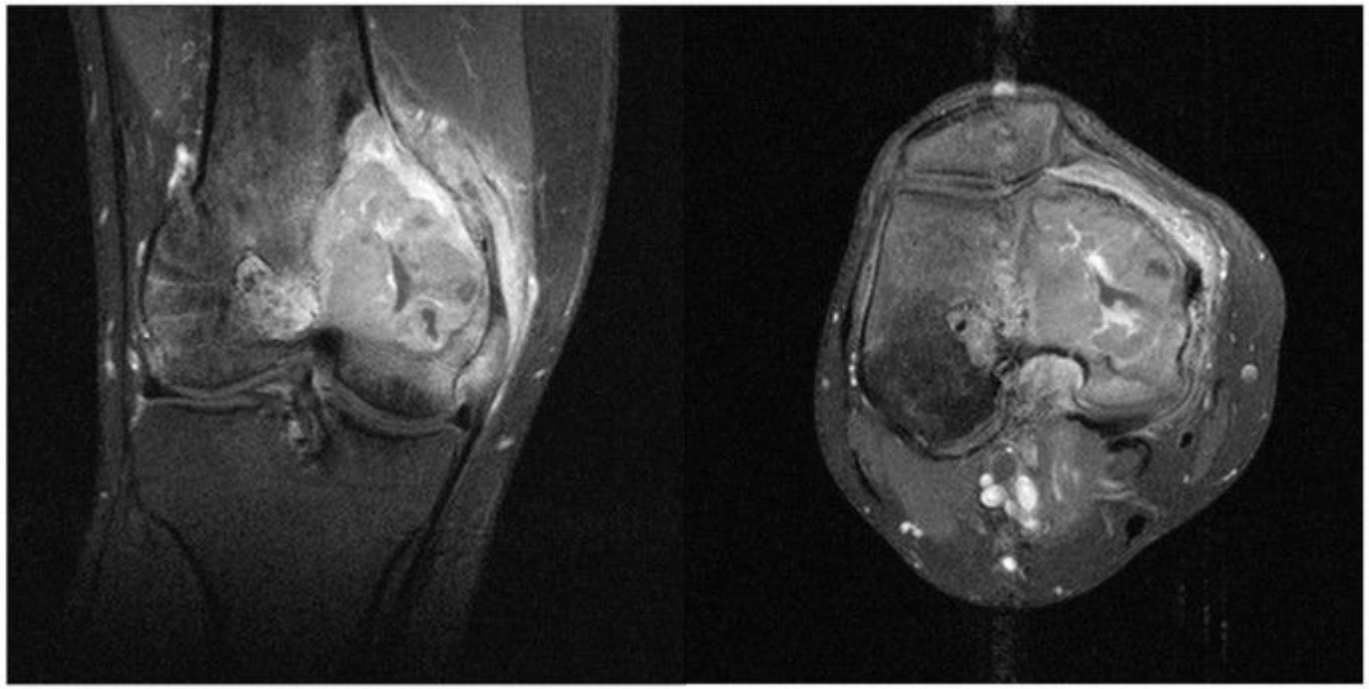

Giant cell tumor

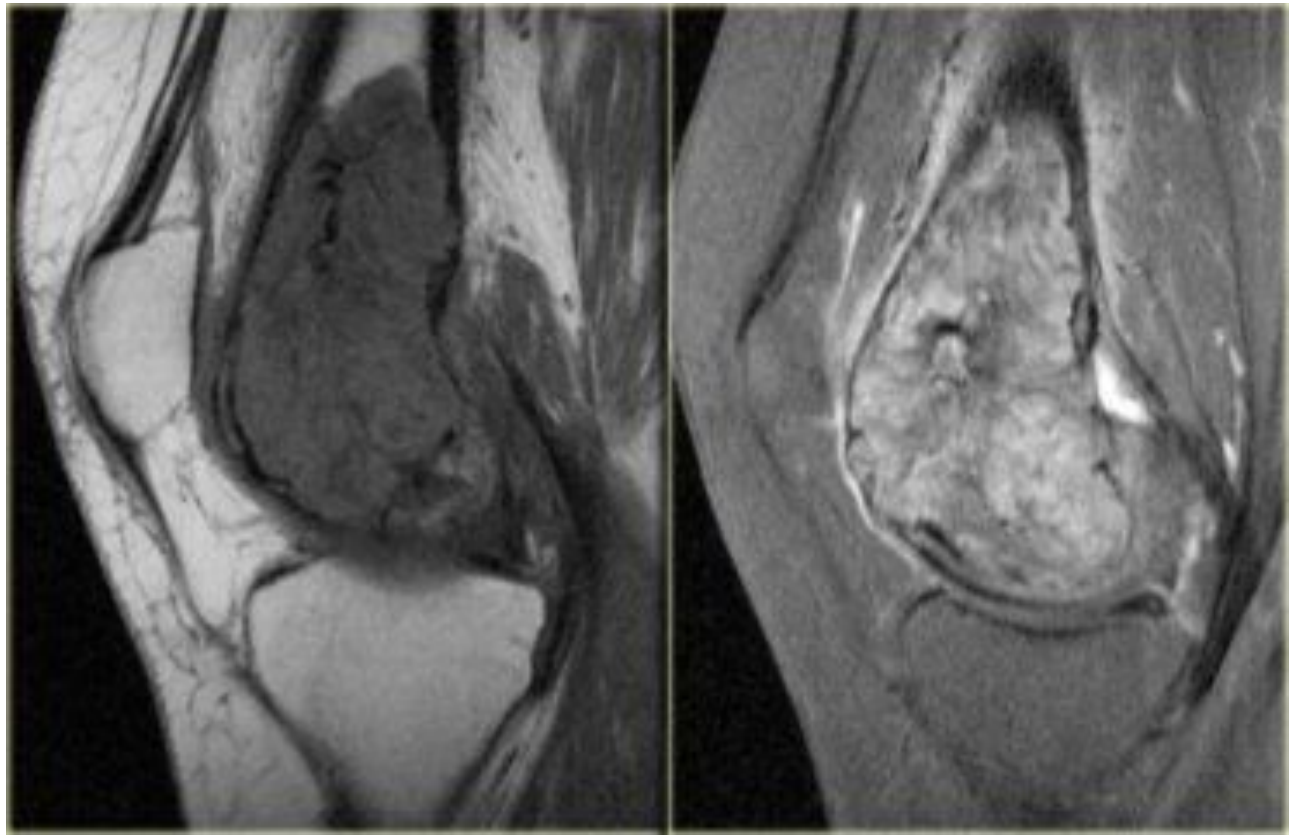

Brodie abscess

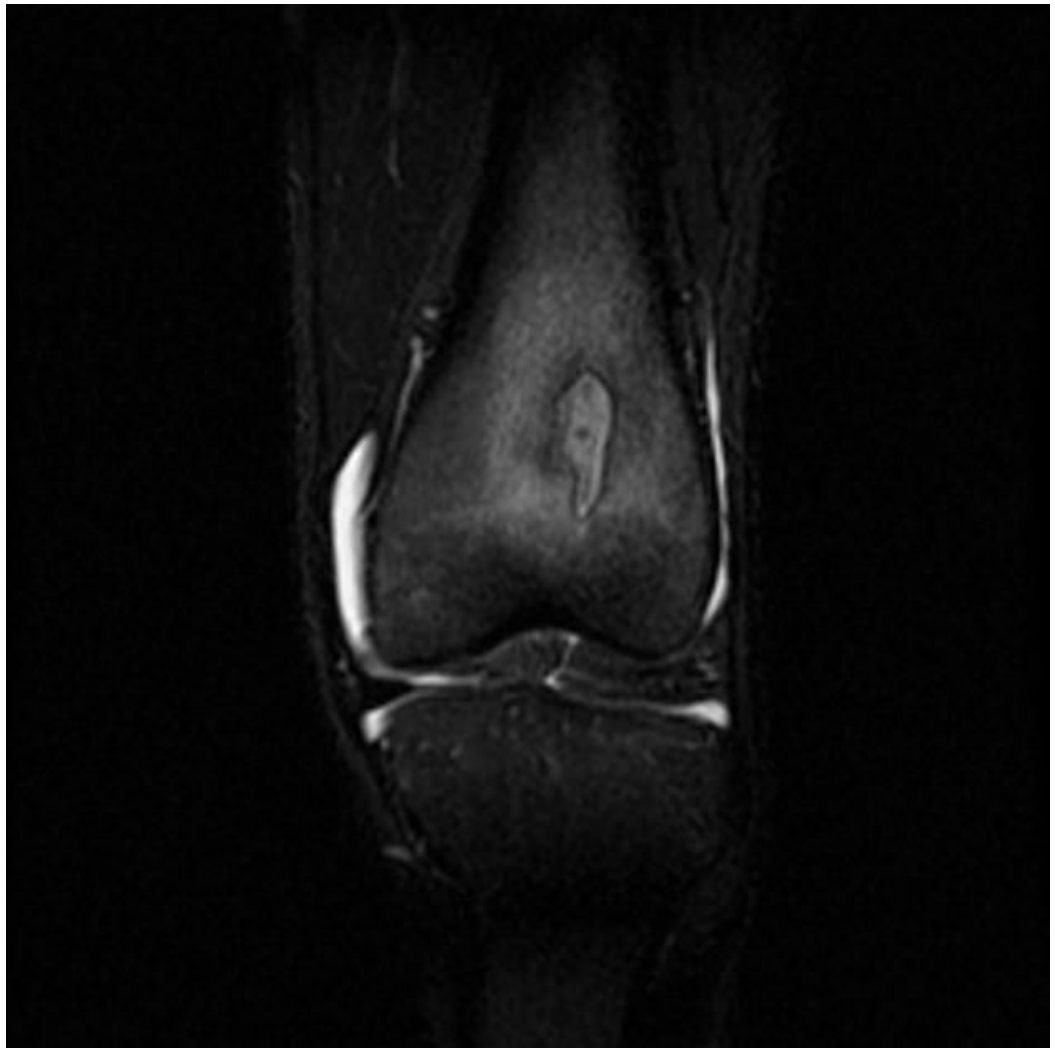



Nuclear Scintigraphy

- Most common = Bone Scan
- Very sensitive for skeletal pathology
- Mildly sensitive for soft tissue pathology
- Usually nonspecific as an isolated test
- Mostly patient friendly; no significant environmental exposure

Small-moderate expense •

Nuclear Scintigraphy

- Excellent for specific pathologies
  - Osteomyelitis
  - Metastases – Not Multiple myeloma
  - Occult fracture
- Reasonably reassuring
  - Normal is usually normal

Nuclear scintigraphy – Bone Scan

- IV injection radioisotope (Tc-99m) bound to phosphate +/- dynamic imaging
- Approx 3 hour delay
- Delayed static imaging with a superficial detector

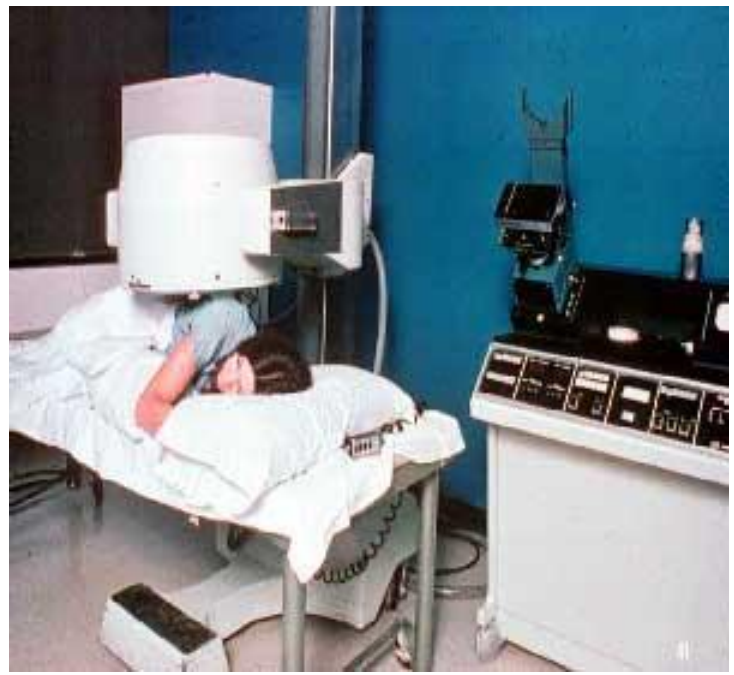

Nuclear Scintigraphy – Bone Scan

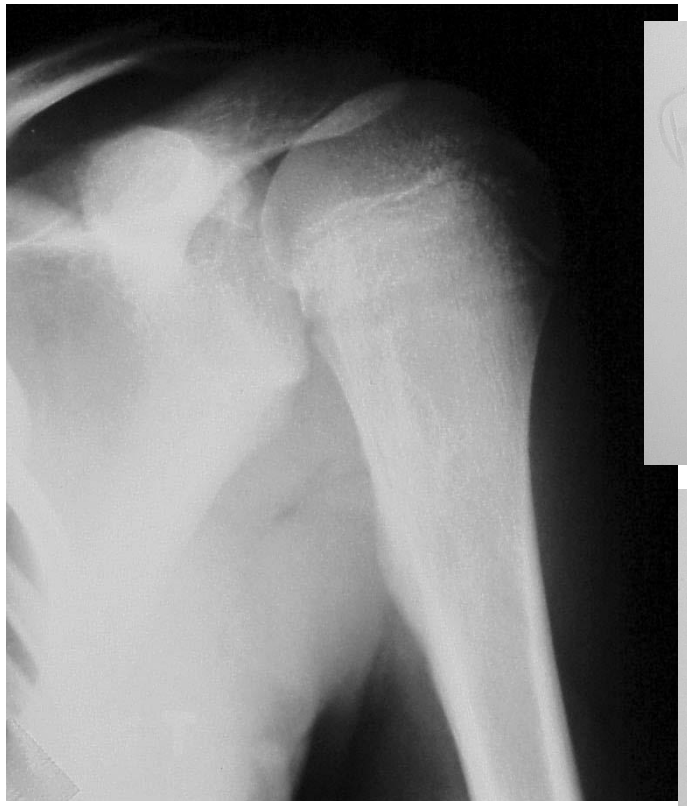

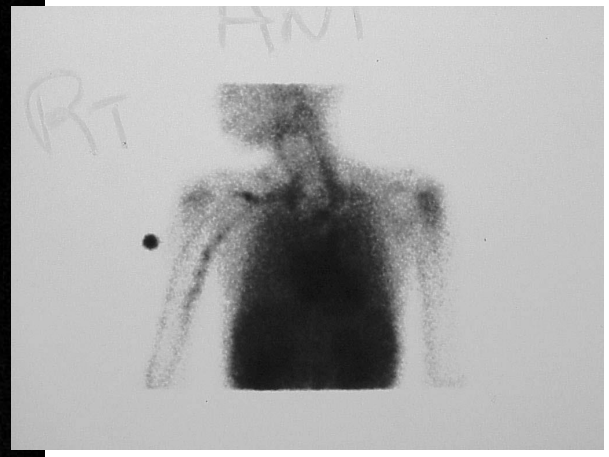

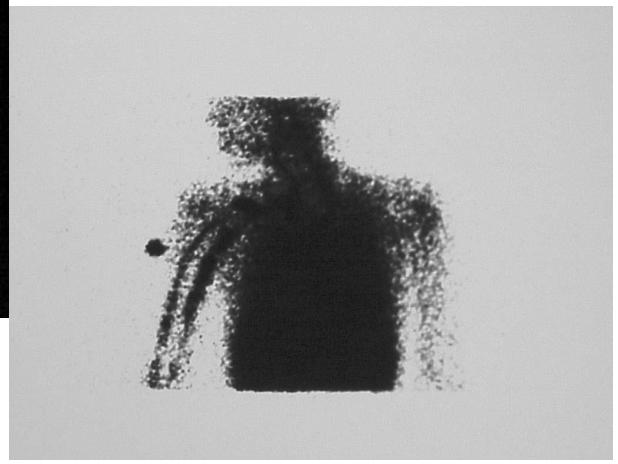

Osteomyelitis

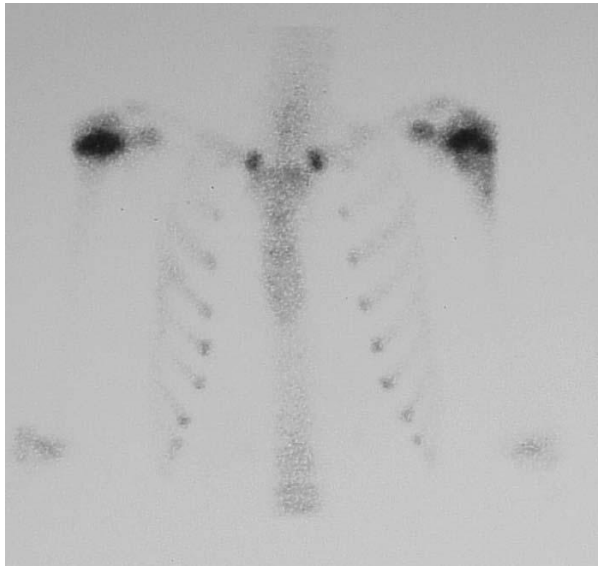

Nuclear Scintigraphy



2nd MT stress fracture

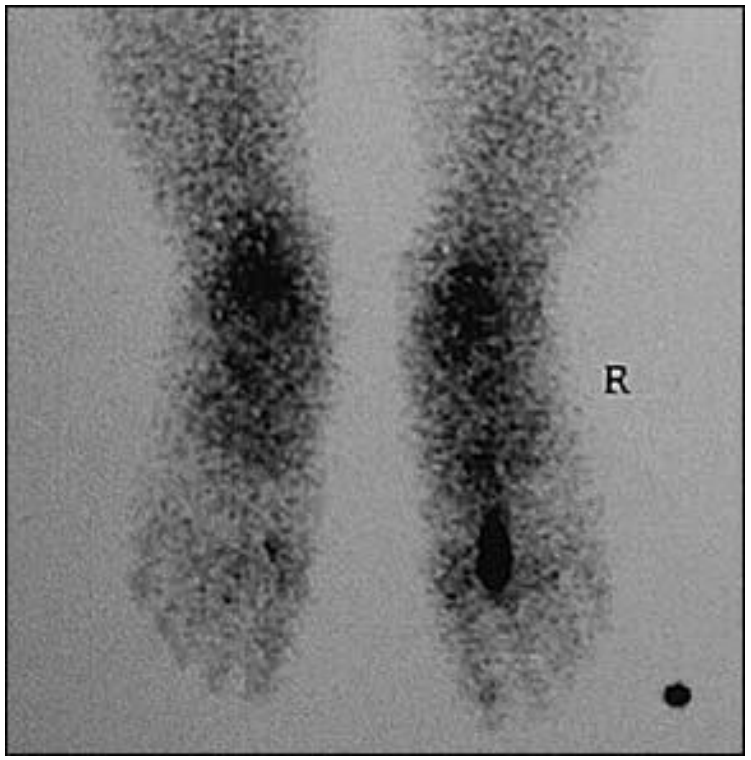



PET SCAN

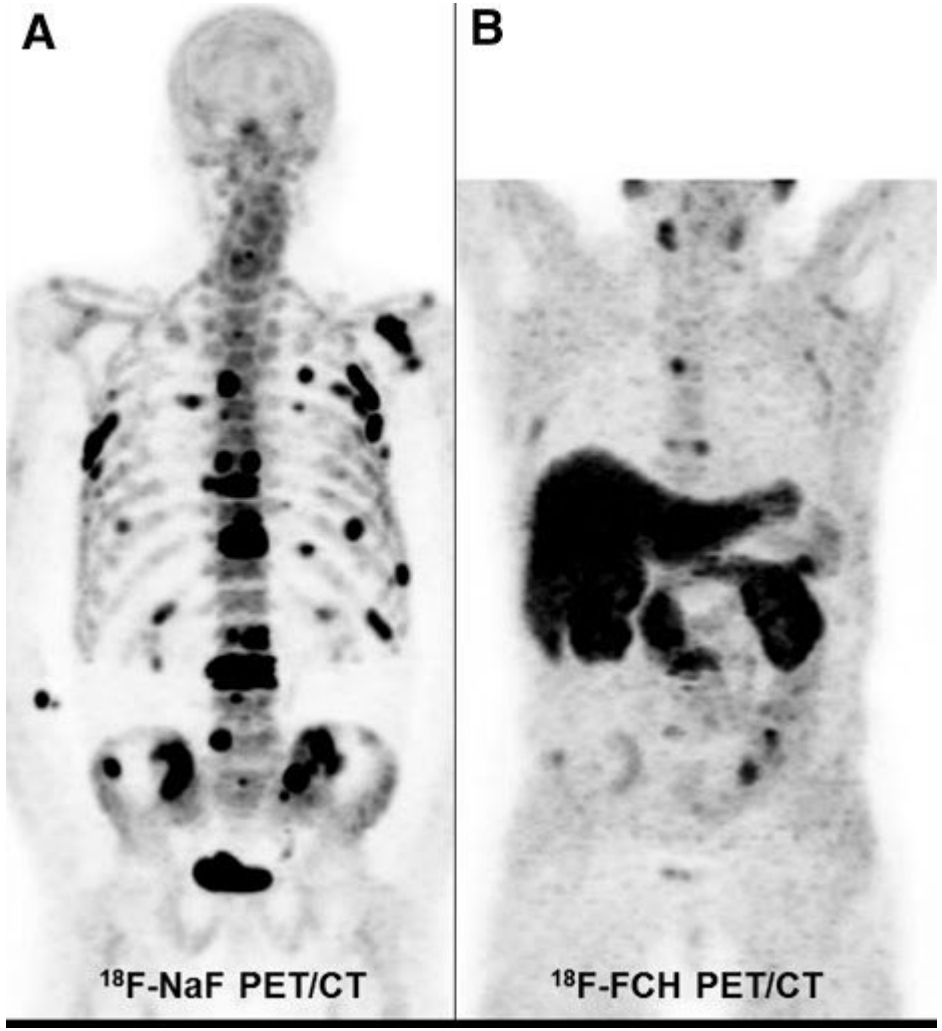

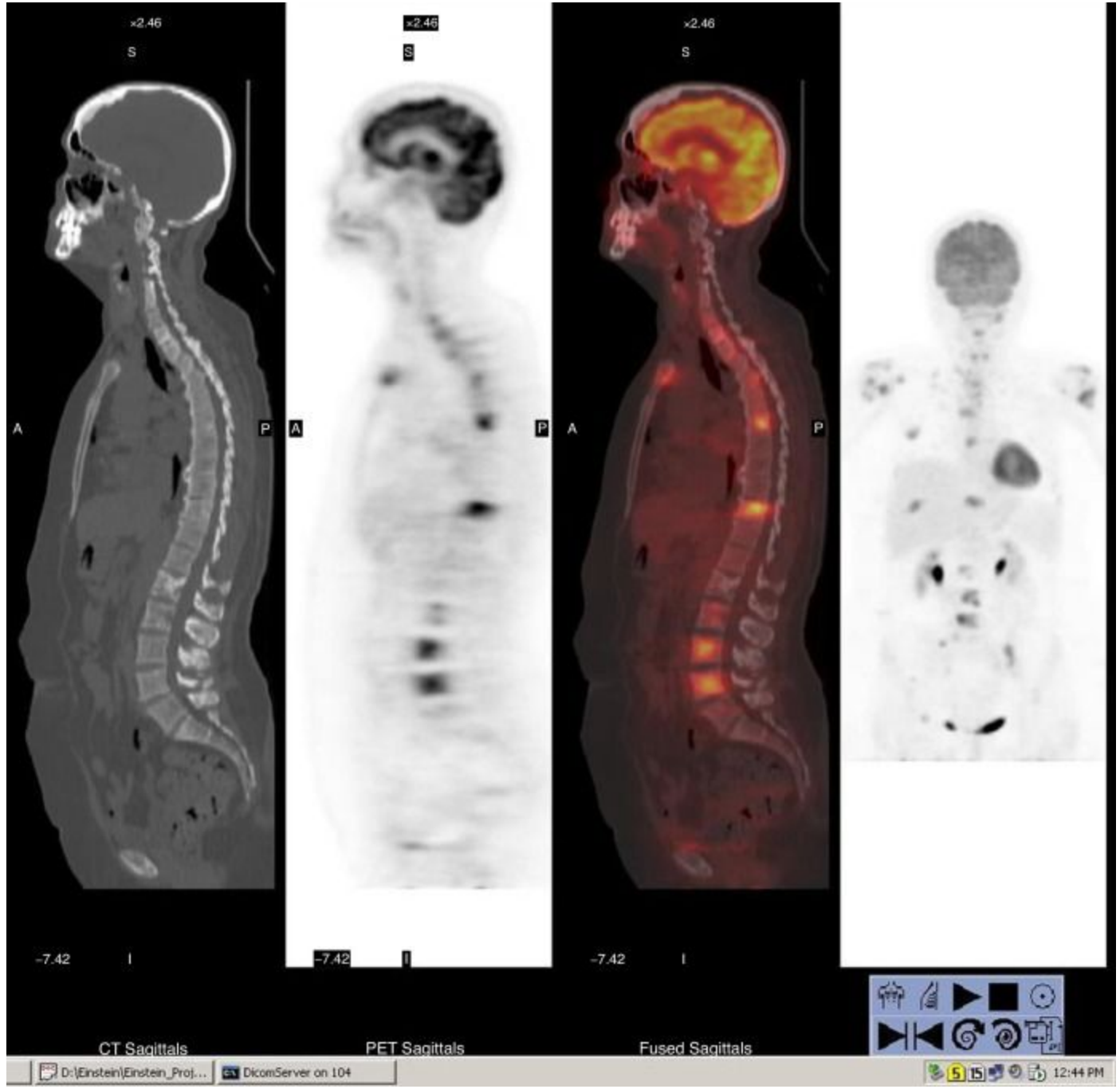
×2.46
S
A
P
-7.42
I
CT Sagittals
PET Sagittals
Fused Sagittals
D:\Einstein\Einstein_Proj...
DicomServer on 104
12:44 PM

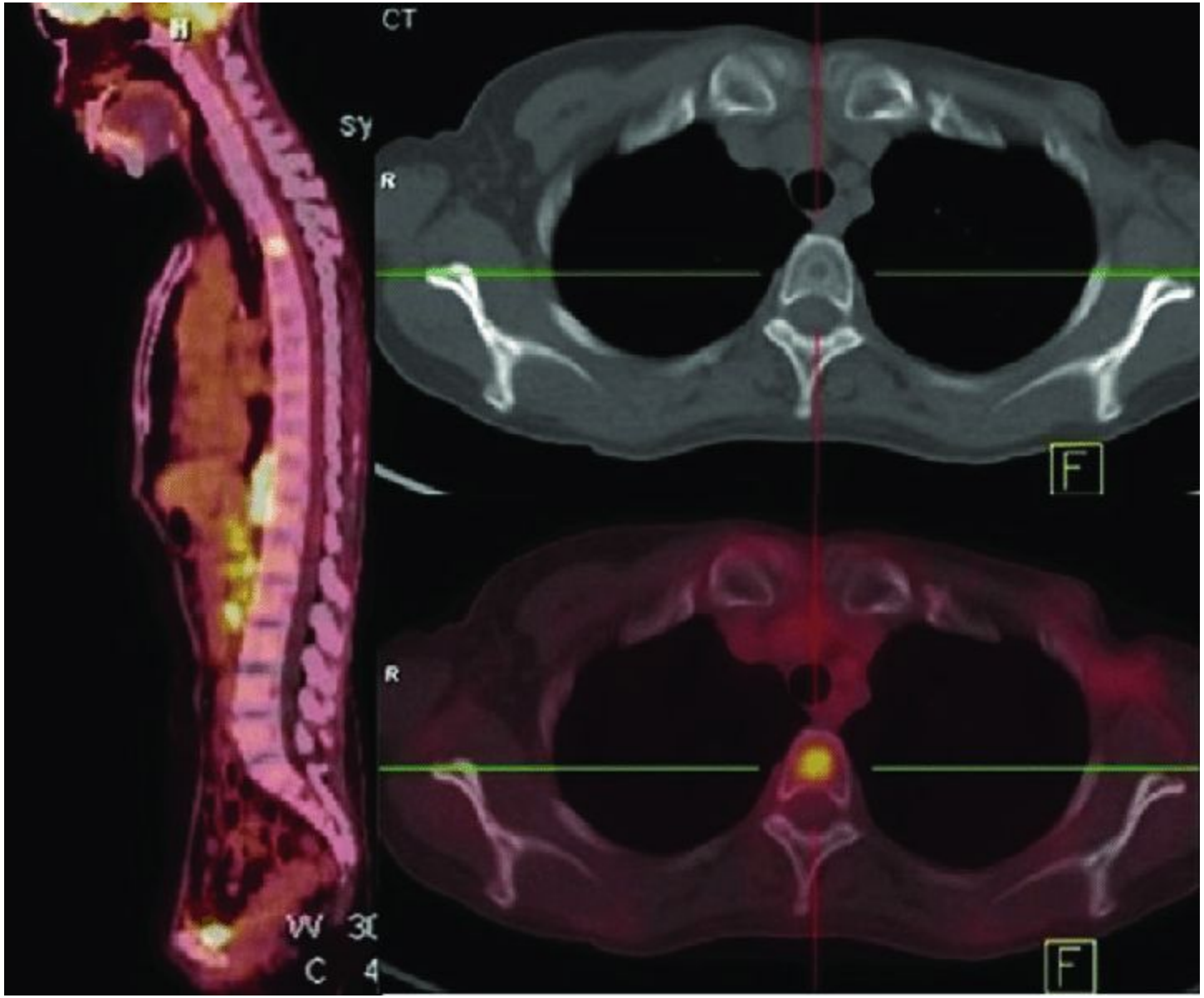
H
CT
Sy
R
F
R
F
W 3[
C 4

THANKS FOR LISENING