1. Twenty-four hours after undergoing surgical repair of an abdominal aortic aneurysm, a 77-year-old man has the onset of mild confusion. His urine output has been 10 mL/h over the past 3 hours. He is diaphoretic. He is oriented to person but not to place or time. His temperature is 38.2°C (100.8°F), pulse is 110/min, respirations are 20/min, and blood pressure is 80/60 mm Hg. The upper and lower extremities are cold and clammy. Pulmonary artery catheterization shows a pulmonary capillary wedge pressure of 23 mm Hg (N=5–16). Which of the following is the most likely explanation for these findings?

- A) Inadequate volume replacement
- B) Intra-abdominal hemorrhage
- C) Myocardial infarction
- D) Pulmonary embolism
- E) Sepsis

https://t.me/USMLENBME2CK

2. A 57-year-old man comes to the physician because of a 3-month history of five to six loose stools daily and a 7.3-kg (16-lb) weight loss. He notes that he had two to three bowel movements daily for 3 weeks following a 10-day course of tetracycline 2 months ago. He underwent antrectomy with Billroth II reconstruction for a perforated gastric ulcer 1 year ago. He has not had any changes in his diet. He has osteoarthritis of the hips treated with ibuprofen. He is 185 cm (6 ft 1 in) tall and weighs 72 kg (160 lb); BMI is 21 kg/m^2. Examination shows excess skinfolds over the abdomen. The abdomen is scaphoid with a well-healed surgical scar. Which of the following is the most likely cause of this patient's diarrhea?

A) Bacterial overgrowth
B) Bile reflux
C) COX-2 inhibition
D) Dumping syndrome
E) Efferent loop obstruction

https://t.me/USMLENBME2CK

3. A 32-year-old man is brought to the emergency department 30 minutes after a head-on motor vehicle collision in which he was the restrained driver. On arrival, he is in severe respiratory distress. Breath sounds are decreased over the left hemithorax. There is crepitant swelling over the face, neck, and hemithorax. An x-ray of the chest shows extensive subcutaneous air and a left pneumothorax. After proper placement of a left chest tube, the patient has a persistent large air leak. Which of the following is the most likely diagnosis?

A) Esophageal injury
B) Open pneumothorax
C) Ruptured bronchus
D) Tension pneumothorax

https://t.me/USMLENBME2CK

4. A previously healthy 52-year-old man comes to the physician because of a 3-month history of light-headedness and hunger in the late evening before dinner and after strenuous exercise. His symptoms improve if he eats or drinks something sweet. Two weeks ago, he fell to the ground nearly unconscious while running with some friends in the late afternoon; his symptoms improved by drinking fruit punch. His only medication is one aspirin tablet each morning. He does not smoke cigarettes or use illicit drugs and drinks one or two glasses of wine each evening. He is an emergency medical technician. His father has type 2 diabetes mellitus. The patient is 183 cm (6 ft) tall and weighs 77 kg (170 lb); BMI is 23 kg/m^2. His pulse is 60/min, and blood pressure is 105/60 mm Hg. Examination shows no other abnormalities. He is given a meal and then given nothing orally. Seven hours later when he develops similar symptoms, his serum glucose concentration is 25 mg/dL, and serum insulin and C-peptide concentrations are increased. Which of the following is the most likely diagnosis?

A) Adrenal insufficiency
B) Cushing syndrome
C) Exogenous production of insulin-like growth factor
D) Insulinoma
E) Pituitary insufficiency
F) Reactive hypoglycemia
G) Surreptitious self-administration of insulin
H) Type 1 diabetes mellitus

https://t.me/USMLENBME2CK

5. A 25-year-old woman comes to the physician 48 hours after the onset of sharp pain in the upper outer quadrant of the right breast. The pain has been gradually resolving. Examination shows a 2-cm tender area in the upper outer quadrant of the right breast; there is no associated mass. Which of the following is the most appropriate next step in management?

A) Reassurance
B) Mammography
C) MRI of the breast
D) Antibiotic therapy
E) Biopsy of the tender area

6. A 16-year-old girl is brought to the emergency department after being stabbed in the anterior neck 30 minutes ago. A large hematoma is evident and is pulsatile at the level of the thyroid cartilage. As the physician watches, the hematoma expands. Which of the following is the most appropriate initial step in management?

A) Barium esophagography to rule out esophageal injury
B) Endotracheal intubation
C) Esophagoscopy to rule out esophageal injury
D) Indirect laryngoscopy to determine vocal cord injury
E) Tracheostomy

https://t.me/USMLENBME2CK

7. A 57-year-old woman comes to the physician because of a 3-month history of cough. She says that the cough has increased in frequency during the past 4 weeks and that she coughed up blood-tinged sputum once. She has not had any other symptoms. She has no history of serious illness and takes no medications. She has smoked one pack of cigarettes daily for 40 years. She is 160 cm (5 ft 3 in) tall and weighs 66 kg (145 lb); BMI is 26 kg/m^2. Coarse rhonchi are heard over the right lung base. A chest x-ray shows a 3-cm mass near the hilum of the right lung. A biopsy specimen of the mass obtained via bronchoscopy shows non-small cell carcinoma of the right main stem bronchus. Mediastinoscopy and PET scan show no metastatic disease. Preoperative testing shows:

FEV_1 for the left lung	600 mL
Maximum voluntary ventilation (MVV)	50% of predicted
Diffusion capacity of the lung for carbon monoxide (DLCO)	50% of predicted

Arterial blood gas analysis on room air shows:

Pco_2	44 mm Hg
Po_2	75 mm Hg

Which of the following parameters is likely to be most useful in assessing this patient's postoperative risk for pneumonectomy?

A) Arterial blood Pco_2
B) Arterial blood Po_2
C) DLCO
D) FEV_1
E) MVV

https://t.me/USMLENBME2CK

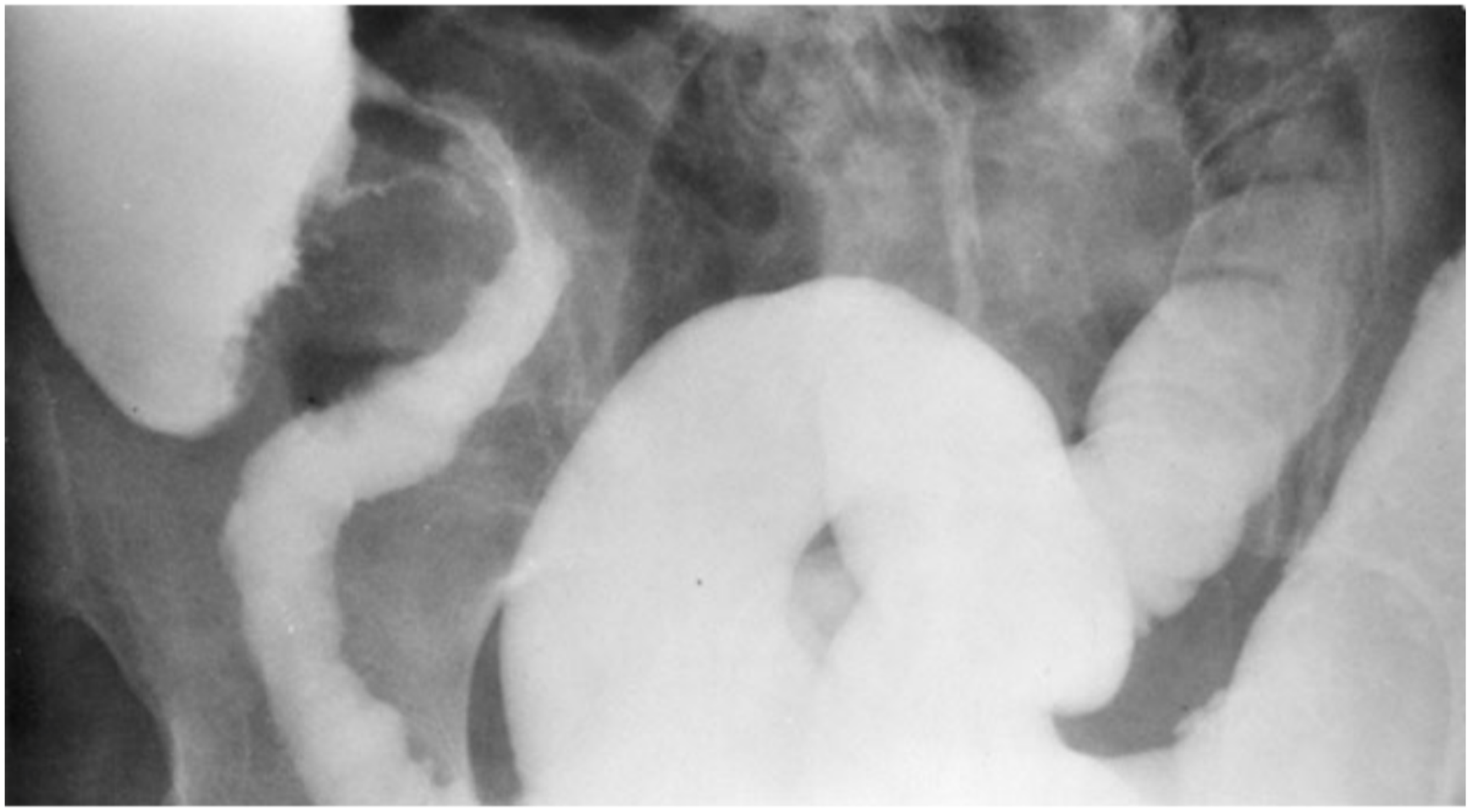

8. A 26-year-old woman has worsening, intermittent abdominal cramps. She has a history of intermittent diarrhea and a 5-kg (11-lb) weight loss. Examination shows moderate generalized abdominal tenderness, hyperactive bowel sounds, and no involuntary guarding. There is pronounced tenderness and a mass in the right lower quadrant. The barium enema examination is shown. Which of the following is the most likely diagnosis?

- A) Amebic enteritis
- B) Crohn disease
- C) Leiomyosarcoma
- D) Necrotizing enterocolitis
- E) Recurrent intussusception

https://t.me/USMLENBME2CK

9. A 57-year-old man comes to the physician because of a 3-month history of increasing pain in his calves when he walks more than one-half mile. The pain resolves after 5 minutes of rest, and he can again walk one-half mile before the pain returns. He has smoked one pack of cigarettes daily for 40 years. He has a 10-year history of hypertension well controlled with hydrochlorothiazide and atenolol. His temperature is 37°C (98.6°F), pulse is 84/min, respirations are 12/min, and blood pressure is 140/85 mm Hg. Popliteal, dorsalis pedis, and posterior tibialis pulses are slightly decreased; femoral pulses are normal. Measurement of ankle brachial indices shows a ratio of 0.8 (N>1). In addition to recommending smoking cessation, which of the following is the most appropriate next step in management?

- A) Recommend a walking program
- B) CT scan of the lumbar spine
- C) MRI of the calf
- D) Aspirin therapy
- E) Aortic angiography

https://t.me/USMLENBME2CK

10. A 77-year-old man is brought to the emergency department by his family because of intermittent confusion during the past 5 days. His family says that he was more confused this morning. He has a long-standing history of alcoholism. During the past 6 days, his family has forced him to decrease his daily alcohol intake. He does not go to a physician regularly but has been treated for hypertension in the past. He currently takes no medications. He appears unkempt and mildly lethargic. His pulse is 80/min, and blood pressure is 166/92 mm Hg. Physical examination shows no other abnormalities. His Mini-Mental State Examination score is 27/30. Laboratory studies show:

Hematocrit	38%
Mean corpuscular volume	104 μm^3
Leukocyte count	6200/mm^3
Platelet count	155,000/mm^3
Serum	
Na^+	131 mEq/L
K^+	3.8 mEq/L
Cl^-	95 mEq/L
HCO_3^-	25 mEq/L
Urea nitrogen	10 mg/dL
Creatinine	1.3 mg/dL

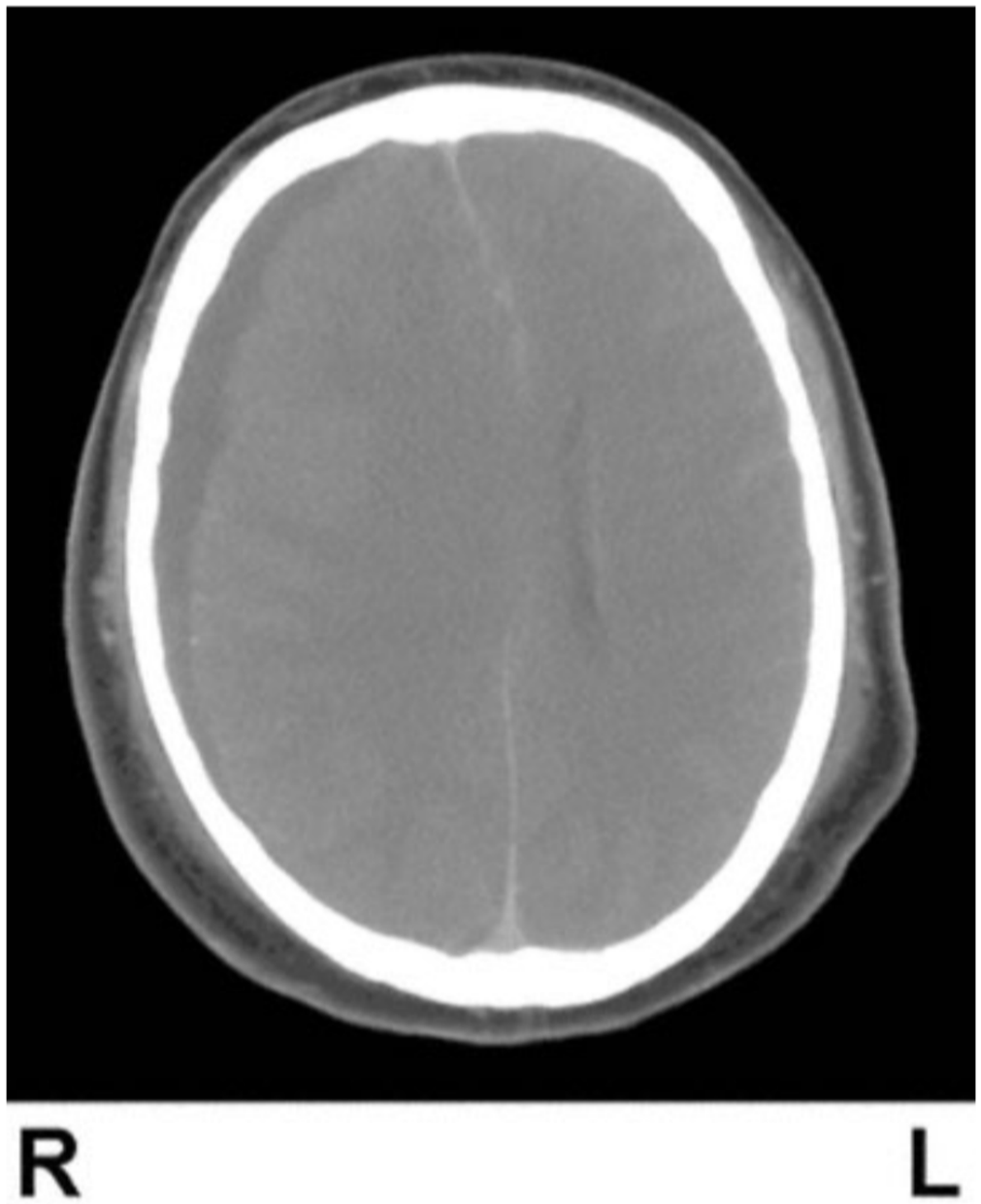

A CT scan of the head is shown. Which of the following is the most appropriate next step in management?

- A) Anticonvulsant therapy
- B) Benzodiazepine therapy
- C) Intravenous magnesium sulfate therapy
- D) Lumbar puncture
- E) Craniotomy

https://t.me/USMLENBME2CK

11. Six hours after sigmoid colectomy and colostomy for perforated diverticulitis, a 62-year-old woman has had a total postoperative urine output of 65 mL through a Foley catheter. Preoperatively, the patient had a serum urea nitrogen concentration of 45 mg/dL and a serum creatinine concentration of 2 mg/dL. She has been receiving 0.45% saline at 90 mL/h since the operation. She is 157 cm (5 ft 2 in) tall and weighs 60 kg (132 lb); BMI is 24 kg/m^2. Her pulse is 95/min, and blood pressure is 130/90 mm Hg. Her serum electrolyte concentrations are within the reference range, and urine specific gravity is 1.028. Which of the following is the most appropriate next step in management?

- A) Measurement of creatinine clearance
- B) Intravenous pyelography
- C) Renal perfusion scan
- D) Rapid administration of 500 mL of 0.9% saline
- E) Administration of intravenous fluids to replace insensible fluid losses only
- F) Administration of intravenous fluids to replace urine output only

https://t.me/USMLENBME2CK

12. A 65-year-old man has frequent premature ventricular contractions (PVCs) in the recovery room following elective repair of an inguinal hernia under spinal anesthesia. Examination shows a complete T3–4 spinal motor and sensory block. Pulse oximetry shows an oxygen saturation of 95%, unchanged from during the operation. Arterial blood gas analysis shows:

pH	7.25
Pco_2	55 mm Hg
Po_2	75 mm Hg

An ECG shows normal sinus rhythm with nonspecific changes and frequent PVCs. Which of the following is the most likely cause?

- A) Fluid overload
- B) Intraoperative myocardial infarction
- C) Metabolic acidosis
- D) Total sympathetic blockade
- E) Ventilatory insufficiency

13. A 52-year-old man comes to the physician because he has had a 14-kg (30-lb) weight loss during the past 6 months. He has noticed oily, floating stools during the past 2 months. He received the diagnosis of acute pancreatitis 2 years ago and has had 1- to 3-hour episodes of severe abdominal pain since then. Current medications include oxycodone. His mother has type 2 diabetes mellitus, and his father died of alcoholic cirrhosis. The patient has smoked one pack of cigarettes daily for 30 years. He has alcoholism but has been abstinent for the past 2 years. He is 173 cm (5 ft 8 in) tall and weighs 59 kg (130 lb); BMI is 20 kg/m^2. His pulse is 100/min, and blood pressure is 120/80 mm Hg. The abdomen is scaphoid with mild diffuse tenderness. The liver edge is firm and is palpated 2 cm below the right costal margin. Laboratory studies show:

Hematocrit	32%
Mean corpuscular volume	83 μm^3
Leukocyte count	10,300/mm^3
Platelet count	302,000/mm^3
Serum	
Na^+	139 mEq/L
K^+	3.5 mEq/L
Cl^-	108 mEq/L
HCO_3^-	19 mEq/L
Urea nitrogen	22 mg/dL
Glucose	164 mg/dL
Creatinine	1.1 mg/dL
Alkaline phosphatase	120 U/L
AST	23 U/L
ALT	29 U/L
Amylase	90 U/L
Ferritin	250 ng/mL
Lipase	43 U/L (N=14–280)

Which of the following is the most likely explanation for these findings?

- A) Bacterial overgrowth
- B) Celiac disease
- C) Cystic fibrosis
- D) Hemochromatosis
- E) Pancreatic insufficiency
- F) Type 2 diabetes mellitus

https://t.me/USMLENBME2CK

14. A 72-year-old man comes to the physician because of a 4-month history of progressive hearing loss and ringing in his right ear and unsteadiness when walking. He has a history of hypercholesterolemia, myocardial infarction, and mitral valve prolapse. He sustained a cerebral infarction 3 years ago. Medications are atorvastatin and 81-mg aspirin. His temperature is 37°C (98.6°F), pulse is 72/min, respirations are 13/min, and blood pressure is 130/82 mm Hg. Physical examination shows decreased movement of the right side of the face. Weber test localizes to the left ear. Rinne test shows air conduction is greater than bone conduction bilaterally. Muscle strength is 5/5 throughout. Deep tendon reflexes and coordination are normal. Sensation to temperature is decreased over the right side of the face. His gait is unsteady. An MRI of the brain is most likely to show which of the following?

- A) Acoustic neuroma (vestibular schwannoma)
- B) Basilar artery thrombosis
- C) Cholesteatoma
- D) Pontine hematoma
- E) Temporal lobe mass

https://t.me/USMLENBME2CK

The response options for the next **2** items are the same. Select one answer for each item in the set.

For each patient with a bleeding disorder, select the most likely diagnosis.

- A) Anticardiolipin antibodies
- B) Antithrombin III deficiency
- C) Fibrinogen abnormality
- D) Hemophilia
- E) Thrombasthenia
- F) Thrombocytopenia
- G) Thrombocytosis
- H) von Willebrand disease

15. A 64-year-old man is undergoing an elective surgical repair of an abdominal aortic aneurysm. During the operation, a retroaortic renal vein is lacerated, and the patient subsequently loses a large amount of blood. In addition to 4 L of blood retained by the cell-saver autotransfusion device, 22 units of packed red blood cells are replaced. The patient is hemodynamically stable, but blood is oozing from every surface in the operative field and from the intravenous and arterial catheter sites.

https://t.me/USMLENBME2CK

For each patient with a bleeding disorder, select the most likely diagnosis.

A) Anticardiolipin antibodies
B) Antithrombin III deficiency
C) Fibrinogen abnormality
D) Hemophilia
E) Thrombasthenia
F) Thrombocytopenia
G) Thrombocytosis
H) von Willebrand disease

16. A 22-year-old man comes to the emergency department because of a swollen, painful, and slightly plethoric right lower extremity. He has had two episodes of superficial thrombophlebitis of the right lower extremity; the first episode occurred 30 months ago and the second episode occurred 18 months ago. Venous duplex scan confirms deep venous thrombosis involving the infrapopliteal veins.

https://t.me/USMLENBME2CK

17. A previously healthy 52-year-old woman comes to the physician for a follow-up examination 1 month after she received the diagnosis of hypertension. She currently takes no medications. Her temperature is 37.6°C (99.7°F), pulse is 105/min, respirations are 18/min, and blood pressure is 165/95 mm Hg. Examination shows a 1-cm mass in the right lobe of the thyroid gland. The remainder of the examination shows no abnormalities. Ultrasonography of the thyroid gland shows a solid mass. A radionuclide scan of the thyroid gland shows increased uptake in the region of the mass. This patient is most likely to have which of the following findings?

- A) Decreased serum thyroid-stimulating hormone (TSH) concentration and increased triiodothyronine (T_3) and thyroxine (T_4) concentrations
- B) Increased serum TSH concentration and decreased T_3 and T_4 concentrations
- C) Presence of thyroid-stimulating immunoglobulins
- D) TSH-mediated increase in iodide uptake by the follicular cells
- E) TSH-mediated increase in the iodination of thyroglobulin
- F) TSH-mediated increase in thyroglobulin production by the follicular cells

https://t.me/USMLENBME2CK

18. A 55-year-old man is brought to the emergency department 1 hour after the onset of vomiting and severe substernal pain radiating to the back; his symptoms began after he ate a large meal. On arrival, he is diaphoretic. His blood pressure is 90/70 mm Hg. Serum amylase activity is normal. ECG and x-rays of the abdomen are normal. An x-ray of the chest shows blunting of the left costophrenic angle. Esophagography with contrast medium shows extravasation into the mediastinum and the left pleural cavity. Intravenous fluids and antibiotics are begun. Which of the following is the most appropriate next step in management?

- A) Esophagoscopy
- B) Exploratory celiotomy
- C) Exploratory thoracotomy
- D) CT scan of the chest
- E) Tube thoracostomy

https://t.me/USMLENBME2CK

19. Three hours after undergoing an uncomplicated tonsillectomy for obstructive sleep apnea, an obese 10-year-old boy's temperature increases to 40.5°C (104.9°F). His pulse is 130/min, respirations are 30/min with deep breathing, and blood pressure is 90/60 mm Hg. Blood pressure obtained perioperatively was 105/70 mm Hg. The skin is mottled. The tonsillar bed is intact, and there is no excessive bleeding. The thyroid gland is not enlarged. Bilateral basilar crackles are heard. The precordium is hyperdynamic with no rubs or gallops. The extremities are cool, and there is generalized muscle rigidity. Laboratory studies show:

Prothrombin time	17 sec (INR=1.5)
Partial thromboplastin time	48 sec
Urine	
Blood	2+
Protein	2+
RBC/WBC	none
Organisms	none

An ECG shows nonspecific ST-segment changes. Which of the following is the most likely diagnosis?

A) Malignant hyperthermia
B) Myocardial infarction
C) Myocarditis
D) Sepsis
E) Thyroid storm

https://t.me/USMLENBME2CK

20. A 67-year-old man with long-standing hypertension comes for a follow-up examination. He has angina pectoris and mild chronic obstructive pulmonary disease. Medications include nitroglycerin and an albuterol inhaler. He has smoked two packs of cigarettes daily for 48 years. He is 183 cm (6 ft) tall and weighs 70 kg (154 lb); BMI is 21 kg/m^2. His pulse is 72/min, respirations are 14/min, and blood pressure is 165/105 mm Hg. Examination shows no other abnormalities. Serum studies show a urea nitrogen concentration of 36 mg/dL and a creatinine concentration of 1.9 mg/dL. Renal ultrasonography shows a 14-cm left kidney and a 7-cm right kidney. Which of the following is the most likely cause of this patient's hypertension and renal atrophy?

- A) Chronic glomerulonephritis
- B) Chronic interstitial nephritis
- C) Chronic vesicoureteral reflux
- D) Fibromuscular dysplasia of the renal artery
- E) Renal artery stenosis

21. A 28-year-old woman comes to the physician because of fatigue, increasing breast size and tenderness, and increased urinary frequency over the past 8 weeks. She has also had slight intermittent cramping in the midline. She is uncertain when her last menstrual period occurred. She is 152 cm (5 ft) tall and weighs 85 kg (187 lb); BMI is 37 kg/m^2. Ultrasonography shows a viable pregnancy high in the uterus consistent with an 8-week gestation. Two weeks later, she has severe right-sided abdominal pain associated with right shoulder pain. Ultrasonography of the pelvis shows a viable pregnancy in the right cornual area of the uterus. Immediately after the ultrasonography, the patient's vital signs become unstable with a pulse of 140/min, respirations of 20/min, and blood pressure of 90/40 mm Hg. Which of the following is the most likely diagnosis?

- A) Adenomyosis
- B) Corpus luteum cyst
- C) Ectopic pregnancy
- D) Endometrioma
- E) Endometriosis
- F) Follicular cyst
- G) Leiomyomata uteri
- H) Pelvic inflammatory disease
- I) Ruptured ovarian cyst
- J) Spontaneous abortion

https://t.me/USMLENBME2CK

22. A 51-year-old surgeon comes to the physician because of neck pain and not being able to hold a pair of forceps in her left hand. She also has numbness over her ring and little fingers. Physical examination shows weakness of all intrinsic hand muscles, but there is no loss of reflexes. Which of the following nerve roots is most likely to be involved?

- A) C4
- B) C5
- C) C6
- D) C7
- E) C8

23. A 37-year-old woman comes to the emergency department 12 hours after the onset of abdominal pain, nausea, and decreased appetite. The pain is localized to the right lower quadrant of the abdomen. Her last menstrual period was 2 weeks ago. Her temperature is 38°C (100.4°F). The abdomen is tender to palpation in the right lower quadrant. Pelvic examination shows no purulent discharge and no cervical motion tenderness. Her leukocyte count is 13,500/mm^3. Urinalysis shows several WBC/hpf. Which of the following is the most appropriate next step in management?

A) Colon contrast studies
B) Upper gastrointestinal series with small bowel follow-through
C) Intravenous pyelography
D) Culdocentesis
E) Appendectomy

https://t.me/USMLENBME2CK

24. A previously healthy 67-year-old man comes to the physician because of intermittent gross hematuria, fever, and fatigue over the past 2 months; he has had a 4.5-kg (10-lb) weight loss during this period. Examination, including the prostate, shows no abnormalities. Laboratory studies show:

Serum	
Ca^{2+}	12.2 mg/dL
Urea nitrogen	15 mg/dL
Creatinine	1.3 mg/dL
Phosphorus	1.9 mg/dL
Urine	
Blood	2+
Protein	negative
RBC	30/hpf
WBC	none

Which of the following is the most likely diagnosis?

A) Diabetic nephropathy
B) Goodpasture syndrome
C) Lupus nephritis
D) Polyarteritis nodosa
E) Polycystic kidney disease
F) Poststreptococcal glomerulonephritis
G) Renal cell carcinoma
H) Urinary tract infection
I) Wegener granulomatosis

https://t.me/USMLENBME2CK

25. A 20-year-old man comes to the emergency department 1 day after the onset of fever and severe pain at the base of the spine between the gluteal folds. His temperature is 38.3°C (101°F). There is tender fullness with slight erythema between the gluteal folds over the coccyx. Which of the following is the most likely diagnosis?

A) Anal fissure
B) Cellulitis
C) Fistula in ano
D) Perirectal abscess
E) Pilonidal abscess

https://t.me/USMLENBME2CK

26. A 60-year-old woman has had dysphagia for 3 months. She has a 10-year history of heartburn. Examination shows no abnormalities. Barium swallow shows a 2-cm tapered distal esophageal stricture with moderate dilation of the proximal esophagus. Which of the following is the most appropriate initial step in management?

A) Hydrostatic balloon dilatation
B) Endoscopic placement of a Silastic feeding tube
C) Esophagoscopy and biopsy
D) Antireflux operation
E) Esophageal resection

https://t.me/USMLENBME2CK

27. A 37-year-old woman comes to the physician because of a 3-week history of progressive shortness of breath on exertion. She has a 3-year history of hypertension. Medications are lisinopril and 81-mg aspirin. Her temperature is 37°C (98.6°F), pulse is 90/min, respirations are 14/min, and blood pressure is 140/70 mm Hg. Crackles are heard at both lung bases. On cardiac examination, there is an opening snap that introduces a grade 2/6, diastolic rumbling murmur; the murmur is heard best at the apex and continues up to S_1. Which of the following is the most likely diagnosis?

- A) Aortic regurgitation
- B) Aortic stenosis
- C) Atrial septal defect
- D) Hypertrophic obstructive cardiomyopathy
- E) Mitral regurgitation
- F) Mitral stenosis
- G) Pulmonic stenosis
- H) Ventricular septal defect

https://t.me/USMLENBME2CK

28. A previously healthy 82-year-old man comes to the physician 12 hours after the onset of left groin pain, nausea, and vomiting. His temperature is 39°C (102.2°F), pulse is 110/min, and blood pressure is 90/60 mm Hg. Examination shows a 5-cm, firm, tender, inguinal mass. His leukocyte count is 16,000/mm^3 with a shift to the left. Which of the following is the most likely diagnosis?

A) Colon diverticulitis
B) Femoral artery aneurysm
C) Inguinal lymphadenitis
D) Strangulated inguinal hernia
E) Testicular torsion

https://t.me/USMLENBME2CK

29. A 52-year-old woman comes for a routine health maintenance examination. She has been receiving tamoxifen therapy for breast cancer prophylaxis for 3 years because of her family history of breast cancer. Examination shows a palpable 3-cm left ovary. The remainder of the examination shows no abnormalities. Which of the following is the most appropriate next step in diagnosis?

A) Measurement of serum estradiol concentration
B) X-rays of the abdomen
C) Barium enema
D) Pelvic ultrasonography
E) Laparoscopy

https://t.me/USMLENBME2CK

30. A 52-year-old man comes to the physician because of a 3-day history of upper abdominal pain and bloating and a 1-day history of nausea and vomiting. Bismuth preparations and antacids have not relieved the nausea and vomiting. He has a history of a duodenal ulcer treated with omeprazole. He currently takes no prescription medications. His pulse is 90/min and regular, and blood pressure is 130/88 mm Hg. Cardiopulmonary examination shows no abnormalities. The abdomen is distended with borborygmi in the epigastric area and a succussion splash. There is no rebound tenderness or guarding. Which of the following is the most likely explanation for these findings?

- A) Gastric mucosal irritation due to an enterovirus infection
- B) Mucosal action of ingested heat-stable enterotoxins
- C) Perforation of a duodenal diverticulum
- D) Scarring and fibrosis of a duodenal ulcer crater
- E) Thrombosis of the superior mesenteric artery

https://t.me/USMLENBME2CK

31. A 46-year-old woman with immune thrombocytopenic purpura has been treated with prednisone (100 mg daily) and immune globulin for 6 weeks without relief. Her platelet count is 20,000/mm^3. Bleeding time is prolonged, clot retraction is poor, and platelet life span is shortened. A bone marrow biopsy specimen shows a near-normal level of megakaryocytes. Which of the following is the most appropriate next step in management?

A) Aspirin therapy
B) Increase prednisone to 200 mg daily
C) Doxorubicin therapy
D) Granulocyte-macrophage colony-stimulating factor therapy
E) Splenectomy

https://t.me/USMLENBME2CK

32. Two days after undergoing an aortic valve replacement for aortic stenosis, a 72-year-old woman develops ventricular fibrillation secondary to hypokalemia. The patient is a Jehovah's Witness, and she and her family were adamant during preoperative consultation that no blood products be administered under any circumstances. Her hematocrit is 18%. Following successful resuscitation, she has severe abdominal pain. Her temperature is 38°C (100.4°F), pulse is 100/min, and blood pressure is 100/70 mm Hg. She is being mechanically ventilated. Abdominal examination shows rebound tenderness; bowel sounds are absent. Her hematocrit is 15%, and leukocyte count is 17,000/mm^3. Intravenous antibiotic therapy is begun. Which of the following is the most appropriate next step?

- A) Sign a do-not-resuscitate order
- B) Administration of erythropoietin, intravenously
- C) Administration of iron, intramuscularly
- D) Transfusion of packed red blood cells
- E) Exploratory laparotomy

https://t.me/USMLENBME2CK

33. A 47-year-old woman undergoes open reduction and internal fixation of a midshaft fracture of the left humerus sustained in a motor vehicle collision. Postoperatively, ketorolac is added to the regimen because of poor pain control with morphine via patient-controlled pump. After her pain control has improved, the morphine is stopped, and the ketorolac is continued as the sole analgesic agent. Two days later, the patient has a decreased urine output. Her temperature is 37°C (98.6°F), pulse is 80/min, respirations are 12/min, and blood pressure is 120/80 mm Hg. Examination of the left upper extremity shows a well-healing surgical incision. Her serum creatinine concentration has increased from 0.7 mg/dL preoperatively to 3.4 mg/dL. Which of the following is the most likely underlying mechanism of the acute renal failure?

- A) Hypovolemia
- B) Inappropriate secretion of ADH (vasopressin)
- C) Increased production of angiotensin II
- D) Inhibited synthesis of prostacyclin
- E) Tubuloglomerular feedback

https://t.me/USMLENBME2CK

34. An asymptomatic 26-year-old woman comes to the physician for a preemployment examination. Physical examination shows no abnormalities. An x-ray of the chest is shown. Which of the following is the most likely diagnosis?

- A) Bronchogenic carcinoma
- B) Sarcoidosis
- C) Thymoma
- D) Tuberculosis
- E) Wegener granulomatosis



35. During a routine physical examination, a 6-year-old boy has a continuous murmur over the pulmonary area, a loud S_2, and bounding peripheral pulses. Which of the following is the most likely diagnosis?

- A) Aortic stenosis
- B) Atrial septal defect
- C) Coarctation of the aorta
- D) Patent ductus arteriosus
- E) Pulmonary stenosis

https://t.me/USMLENBME2CK

36. Eight hours after undergoing transurethral prostate resection, a 62-year-old man has a hemoglobin concentration of 7.5 g/dL. A transfusion of heterologous packed red blood cells is begun. Two hours later, he develops chills and fever. He has received 200 mL of the transfusion. His temperature is 39°C (102.2°F), pulse is 120/min, respirations are 18/min, and blood pressure is 120/70 mm Hg. Which of the following is the most likely explanation for these findings?

A) ABO incompatibility
B) Bacterial overgrowth in transfused blood
C) Intravenous catheter infection
D) Preformed antibodies to leukocyte antigens
E) Rh incompatibility

https://t.me/USMLENBME2CK

37. A 19-year-old man comes to the emergency department because of severe generalized abdominal pain for 12 hours. He has had increasing episodes of diarrhea for 6 weeks and bloody diarrhea for 4 days. He has had no bowel movements since the onset of abdominal pain. He appears pale and ill. His temperature is 38.9°C (102°F), and pulse is 144/min. Abdominal examination shows diffuse tenderness with hypoactive bowel sounds. Rectal examination shows bloody stool. An x-ray of the abdomen shows a transverse colon 8 cm in diameter but no free air. Which of the following is the most likely diagnosis?

- A) Angiodysplasia of the colon
- B) Antibiotic-associated colitis
- C) Arteriovenous malformation of the colon
- D) Diverticulitis
- E) Ischemic colitis
- F) Pseudomembranous colitis
- G) Rectal carcinoid
- H) Ulcerative colitis
- I) Volvulus of the colon

https://t.me/USMLENBME2CK

38. A 32-year-old woman comes to the emergency department because of a 10-hour history of increasingly severe, constant pain in her abdomen. She has nausea but has not vomited. She has systemic lupus erythematosus well controlled with prednisone. She takes no other medications. Her temperature is 38°C (100.4°F), pulse is 110/min, respirations are 16/min, and blood pressure is 115/65 mm Hg. Examination shows no scleral icterus. The abdomen is soft and tender to palpation over the right upper quadrant; there is mild guarding without rebound. Laboratory studies show:

Hemoglobin	14 g/dL
Leukocyte count	12,000/mm^3
Segmented neutrophils	75%
Bands	10%
Lymphocytes	15%

Results of liver function tests are within the reference ranges. Abdominal ultrasonography shows a distended gallbladder with a thickened wall and a gallstone lodged in the neck of the gallbladder. Following administration of cefazolin and an intravenous infusion of lactated Ringer solution, the patient is taken to the operating room for laparoscopic cholecystectomy. On induction with propofol, her blood pressure abruptly decreases to 60/40 mm Hg and remains constant despite administration of an additional 500-mL bolus of lactated Ringer solution. Which of the following is the most appropriate next step in pharmacotherapy?

A) Administer diphenhydramine
B) Administer dopamine
C) Administer gentamicin
D) Administer hydrocortisone
E) Decrease the dose of propofol

https://t.me/USMLENBME2CK

39. A 26-year-old woman with chronic alcoholism comes to the emergency department because of hematemesis four times during the past 2 hours. She vomited small amounts of clear material before vomiting blood and blood clots. She appears unkempt and tremulous. Her pulse is 124/min, and blood pressure is 92/68 mm Hg. Examination shows dry, blood-caked oral mucous membranes. There are no skin signs of chronic hepatic disease. The liver and spleen are not palpable; there is no evidence of ascites or peripheral edema. Which of the following is the most appropriate next step in management?

- A) Measurement of arterial blood gases
- B) Intravenous administration of fluids
- C) Intravenous infusion of ADH (vasopressin)
- D) Insertion of a nasogastric tube
- E) Upper gastroduodenal endoscopy

https://t.me/USMLENBME2CK

40. An 11-month-old girl is brought to the emergency department 1 hour after the onset of fever and passing purple, jelly-like stools. During the past 7 hours, she has had episodes of drawing up her knees and crying. She does not appear to be in distress or dehydrated. Her temperature is 37.8°C (100°F), pulse is 110/min, respirations are 16/min, and blood pressure is 100/50 mm Hg. An elongated mass is palpated in the right upper abdominal quadrant. Which of the following is the most appropriate next step in management?

A) Contrast enema
B) Upper gastrointestinal studies with small bowel follow-through
C) CT scan of the abdomen
D) HIDA scan
E) Colonoscopy

https://t.me/USMLENBME2CK

41. A 3-week-old female newborn is brought to the physician because of an 18-day history of increasingly yellow skin and eyes. She was born at term to a 24-year-old woman, gravida 2, para 2, following an uncomplicated pregnancy and delivery; her weight at birth was 3175 g (7 lb). She is exclusively breast-fed. Today, she weighs 3345 g (7 lb 6 oz). Physical examination shows scleral icterus and generalized jaundice. The remainder of the examination shows no abnormalities. Her serum total bilirubin concentration is 15 mg/dL with a direct component of 13 mg/dL. Which of the following is the most likely diagnosis?

- A) ABO incompatibility
- B) Biliary atresia
- C) Breast milk jaundice
- D) Gilbert syndrome
- E) Hereditary spherocytosis
- F) Physiologic jaundice

https://t.me/USMLENBME2CK

42. A 22-year-old man is brought to the emergency department 1 hour after being involved in a motor vehicle collision. On arrival, his pulse is 120/min, and blood pressure is 100/70 mm Hg. He has multiple facial lacerations. Which of the following imaging studies is best used to screen for cervical trauma?

- A) CT scan
- B) Lateral x-ray
- C) MRI
- D) Myelography
- E) Tomography

https://t.me/USMLENBME2CK

43. Ten days after admission to the hospital, a 22-year-old man with acute leukemia has the onset of pain and edema of the right upper extremity. He completed a 7-day course of induction chemotherapy 3 days ago. On admission, he received sodium bicarbonate and allopurinol and underwent placement of a right atrial catheter. His pulse is 80/min, and blood pressure is 126/78 mm Hg. The right upper extremity is approximately 1.5 times larger in circumference than the left upper extremity. Venous duplex ultrasonography of the right upper extremity shows occlusion of the right axillary and subclavian veins. Which of the following is the most likely cause of the patient's symptoms?

- A) Adverse effect of chemotherapeutic agents
- B) Arterial embolism
- C) Cellulitis
- D) Cervical rib syndrome
- E) Complication of the right atrial catheter

https://t.me/USMLENBME2CK

44. A previously healthy 27-year-old woman is brought to the emergency department immediately after she sustained a single gunshot wound to the right mid thigh. She is alert and oriented to person, place, and time. She says she has pain in her right thigh. Her pulse is 100/min, respirations are 24/min, and blood pressure is 120/80 mm Hg. Examination shows a single entry wound in the right mid thigh with swelling. The right popliteal, posterior tibial, and dorsalis pedis pulses are absent. Administration of oxygen and intravenous 0.9% saline is begun. An x-ray of the right lower extremity shows a comminuted fracture of the femur. After reduction and immobilization of the fracture, which of the following is the most appropriate next step in management?

- A) Measurement of the ankle brachial indices
- B) Duplex ultrasonography of the right lower extremity
- C) CT scan of the pelvis
- D) MRI of the right thigh
- E) Surgical exploration of the right femoral artery

https://t.me/USMLENBME2CK

45. A 52-year-old man is brought to the emergency department because of respiratory distress after hitting his chest on the steering wheel in a motor vehicle collision. On arrival, his pulse is 110/min, respirations are 32/min, and blood pressure is 110/80 mm Hg. There is tenderness to palpation over the 3rd, 4th, and 5th ribs. X-rays show fractures of these ribs both anteriorly and laterally and an infiltrate in an underlying area suggestive of alveolar and interstitial edema. Which of the following is the most likely diagnosis?

- A) Cardiac tamponade
- B) Hemothorax
- C) Open pneumothorax
- D) Pulmonary contusion
- E) Tension pneumothorax
- F) Traumatic diaphragmatic hernia

46. A previously healthy 62-year-old man comes to the physician 2 days after an episode of blindness in the right eye that lasted 5 to 10 minutes. He has no history of similar episodes or other neurologic symptoms. He has type 2 diabetes mellitus treated with an oral hypoglycemic agent. His pulse is 75/min, respirations are 12/min, and blood pressure is 150/90 mm Hg. Examination shows intact motor and sensory function. The visual fields are full to confrontation. Results of funduscopic examination are shown. Which of the following is the most likely underlying cause of these findings?

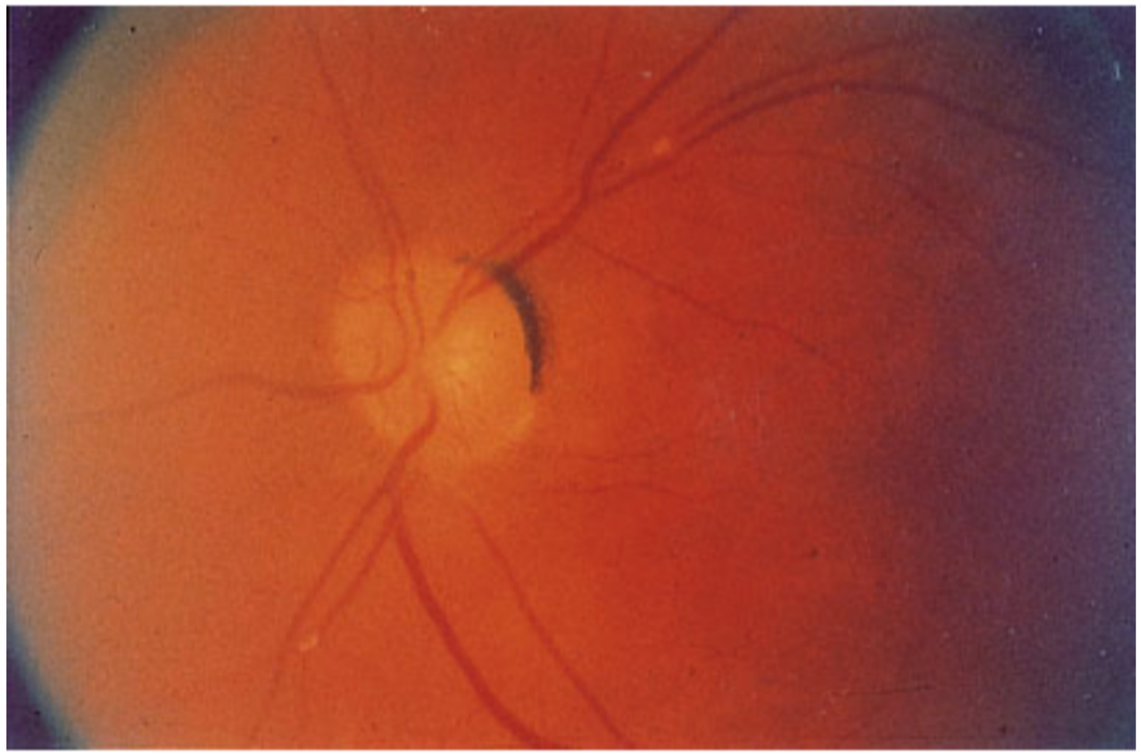

- A) Cardiomyopathy
- B) Carotid stenosis
- C) Cataract
- D) Diabetic retinopathy
- E) Glaucoma

https://t.me/USMLENBME2CK

47. A 42-year-old woman is brought to the emergency department 17 minutes after being involved in a motor vehicle collision. She has abdominal and left flank pain. She is hemodynamically stable. There is tenderness over the left flank but no external marks. Urinalysis shows gross blood. Which of the following is the most appropriate next step in management?

A) Renal blood flow scan
B) CT scan of the abdomen and kidneys
C) Arteriography
D) Peritoneal lavage
E) Exploratory operation

https://t.me/USMLENBME2CK

48. A 52-year-old man comes to the physician because of a 4-month history of loose, foul-smelling stools; during this period, he has had a 6.3-kg (14-lb) weight loss despite a good appetite. He also has had urinary frequency and urgency for 5 weeks. He has not had fever, chills, nausea, or vomiting. He has a 10-year history of recurrent alcoholic pancreatitis that has required hospitalization once or twice each year because of severe abdominal pain. He has not been hospitalized since he abstained from drinking alcohol 2 years ago, but he has had chronic, mild midepigastric pain since that time. During his last hospitalization 2 years ago, an x-ray of the abdomen showed calcifications in the pancreas. He is 175 cm (5 ft 9 in) tall and weighs 69 kg (153 lb); BMI is 23 kg/m^2. Examination shows temporal wasting. Cardiopulmonary examination shows no abnormalities. Abdominal examination shows midepigastric tenderness with no masses or hepatosplenomegaly; bowel sounds are normal. There is no peripheral edema. Laboratory studies show:

Hematocrit	39%
Mean corpuscular volume	84 μm^3
Leukocyte count	9000/mm^3
Segmented neutrophils	73%
Lymphocytes	18%
Monocytes	9%
Platelet count	230,000/mm^3
Serum	
Urea nitrogen	17 mg/dL
Glucose	280 mg/dL
Creatinine	1.2 mg/dL
Protein, total	5.8 g/dL
Albumin	2.7 g/dL

In addition to pancreatic enzyme replacement therapy, which of the following is most likely to decrease long-term morbidity in this patient?

A) High-fiber diet
B) Lactose-free diet
C) Nutritional supplementation
D) Insulin therapy
E) Sulfonylurea therapy

https://t.me/USMLENBME2CK

49. A 52-year-old woman comes to the physician because of a 1-year history of progressive difficulty swallowing, intermittent vomiting of undigested food, and a cough that is more severe at night. During the past 6 months, she has had an 8-kg (17-lb) weight loss. She has not had pain with swallowing or difficulty speaking. She has no history of serious illness and takes no medications. She states that she has had some anxiety during the past 6 months because of fear of losing her job. She does not smoke cigarettes or drink alcohol. Her temperature is 37°C (98.6°F), pulse is 80/min, respirations are 18/min, and blood pressure is 120/84 mm Hg. Examination shows no palpable neck masses. The trachea is midline, and there is no thyromegaly. Cardiopulmonary and abdominal examinations show no abnormalities. A chest x-ray shows an air-fluid level in the posterior mediastinum at the level of the cardiac silhouette. Manometry shows normal lower esophageal sphincter pressure and absent lower esophageal sphincter relaxation with swallowing. Which of the following is the most likely diagnosis?

- A) Achalasia
- B) Diffuse esophageal spasm
- C) Globus hystericus
- D) Hiatal hernia
- E) Systemic sclerosis (scleroderma)

50. A 24-year-old woman comes to the emergency department because of diffuse pain after she fell asleep for 4 hours while sunbathing at a tropical resort. Examination shows diffuse erythema and exquisite tenderness over 48% of her body. Which of the following is the most appropriate next step in management?

A) Observation
B) Application of porcine xenografting
C) Calcium gluconate therapy
D) Topical silver sulfadiazine therapy
E) Excision and skin grafting

https://t.me/USMLENBME2CK