RADIOLOGY IMAGING MODALITIES

Dr Marwan Matar

Consultant Radiologist

European Gaza Hospital

Radiology the eye of medicine

Radiology has a central role in
the initial diagnosis as well as subsequent
management of patients.

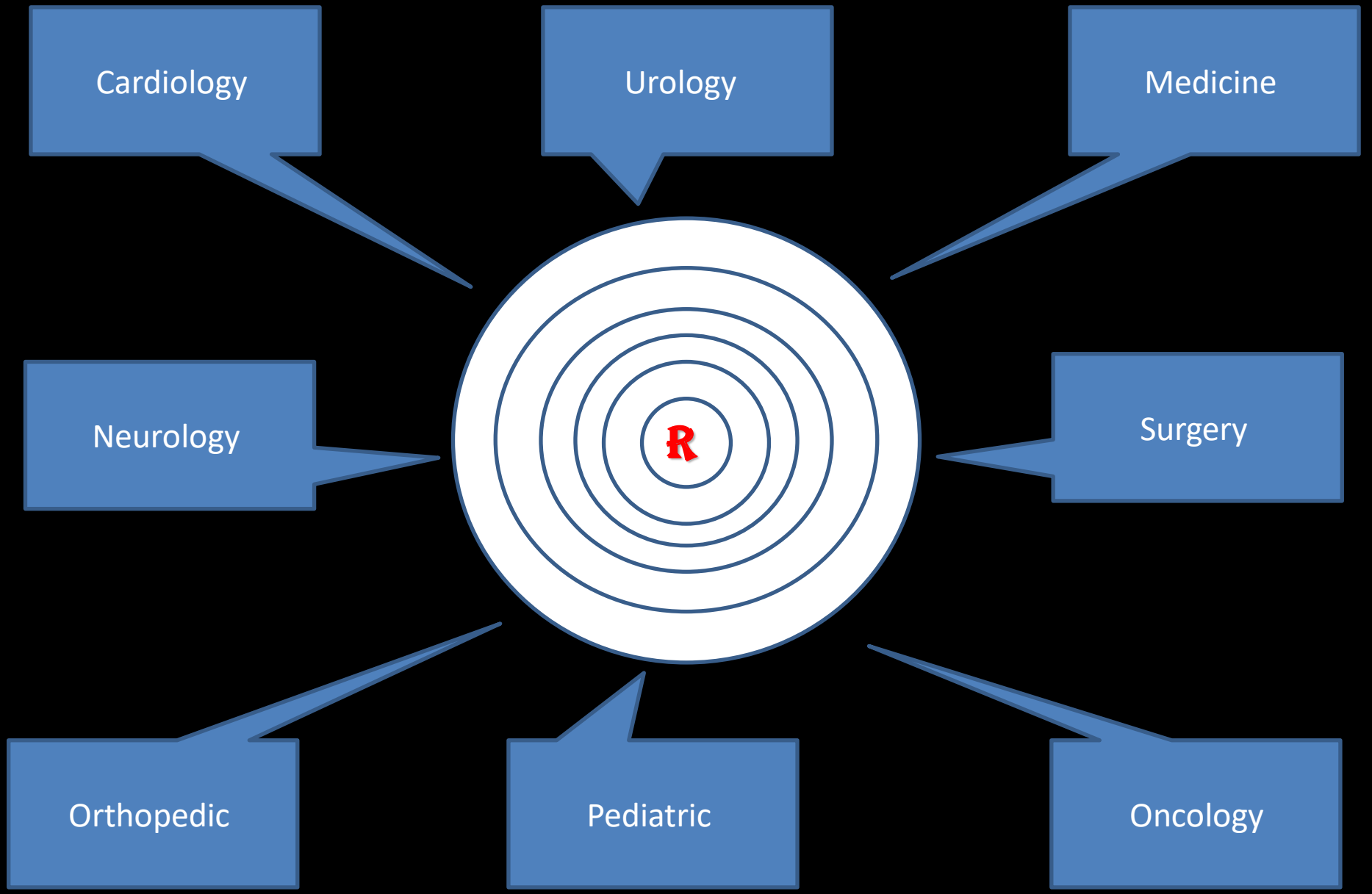
Cardiology
Urology
Medicine
Neurology
℞
Surgery
Orthopedic
Pediatric
Oncology

MODULES

1. Head & Neck
2. MSK
3. GIT
4. Genito-Urinary & OB
5. Respiratory
6. Cardio- Vascular
7. Pediatric

- Plain X-Ray
- Flouroscopy
- US
- CT
- MRI
- Intervention
- Nuclear medicine













Projectional radiography

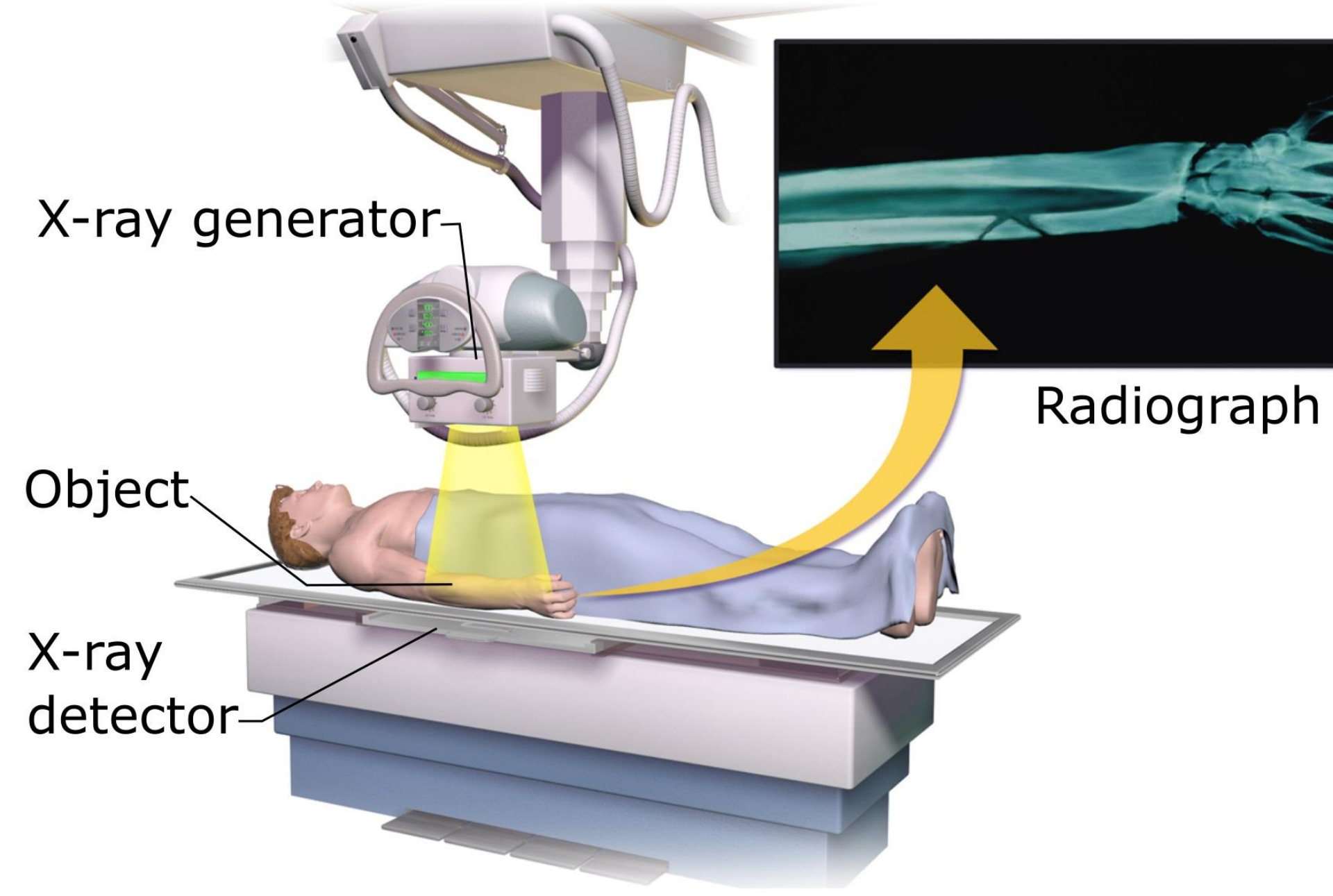

Conventional X-ray

1. Chest

2. Abdomen

3. Skeletal system







DIGITAL X-RAY

The principal advantages of digital radiography are:

- ● Significant reduction in radiation exposure
- ● Digital enhancement ensures all images are of an adequate quality
- ● Transfer of images out of the radiology department to other sites
- ● Elimination of storage problems associated with conventional films
- ● No hard copy films
- ● Rapid retrieval of previous images and reports for comparison
- ● Ease of availability of examinations to clinicians

FLOUROSCOPY/SCREENING

The principles :



- ● Fluoroscopy is the term used when a continuous low - power X - ray beam is passed through the patient to produce a dynamic image that can be viewed on a monitor.
- Many different procedures, such as barium studies of the gastrointestinal tract, arteriography and interventional procedures

FLOUROSCOPY/SCREENING



FLOUROSCOPY/SCREENING

- ● GIT system (Barium swallow , meal, follow through and enema) .
- Genito- Urinary tract (MCUG, Urethrography, HSG and Intervention).





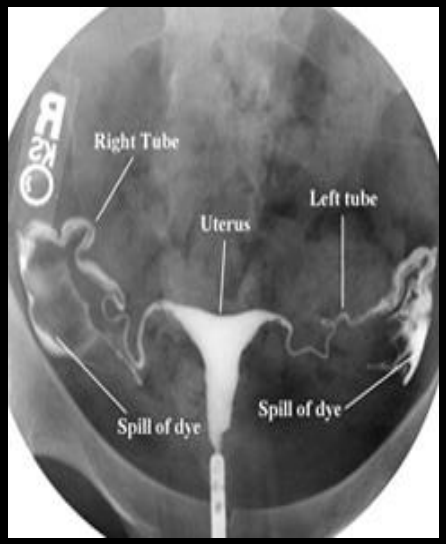





ULTRASOUND

- Definition:
- Ultrasound defined as **sound** that is too **high** in frequency for **humans** to hear.

- A diagnostic technique in which high-frequency sound waves penetrate the body and produce multiple echoes; these echo patterns can be viewed as an image on a computer screen.

- Frequency ranges used in medical Ultrasound imaging are 2 - 15 MHz

ULTRASOUND

- كانت أولى مساعي البحث في الموجات الصوتية منذ عام ١٨٢٢ عندما سعى عالم الفيزياء السويسري **(دانيل كولادين)** لحساب سرعة الصوت عن طريق جرسه المائي في مياه بحيرة **(جنيفا)** . والتي مهدت لوضع (نظرية الصوت) في عام ١٨٧٧ بجهود العالم **(لورد ريليه)** والتي شرحت الأساسيات الفيزيائية لموجات الصوت وانتقاله وارتداده . وتوالت الأبحاث حتى كان تصميم وإنشاء أول نظام(Sonar) Sound Navigation & Ranging عامل في الولايات المتحدة عام ١٩١٤ على يد العالم فسندن لأغراض الملاحة البحرية ولتحديد أماكن المار ينز الألماني في الحرب العالمية الأولى

ولم توظف الموجات فوق الصوتية لخدمة الأغراض الطبية حتى بداية الأربعينات على يد دكتور الأعصاب والطبيب النفسي النمساوي **(كارل ثيودو)** والذي يعتبر أول طبيب استخدم الموجات فوق الصوتية في التشخيص الطبي وقد واجه في ذلك صعوبات بسبب امتصاص عظام الجمجمة لمعظم طاقة الموجات فوق الصوتية.

ULTRASOUND

- Non invasive.
- Reliable
- Non expensive.
- No Radiation

❑ **Requirements:**

- Fasting 4-6hours.
- No bowel preparation.
- No CM



COMMON TERMINOLOGY (US)

- ****The beginner needs to be familiar with a few commonly used terms:**

  - **Image Interpretation:**

- **Anechoic / Echo lucent** - Complete absence of returning sound waves, area is black .
- **Hypo echoic** - Structure has very few echoes and appears darker than surrounding tissue .
- **Hyper echoic / Echogenic** - Opposite of hypo echoic, structure appears brighter than surrounding tissue

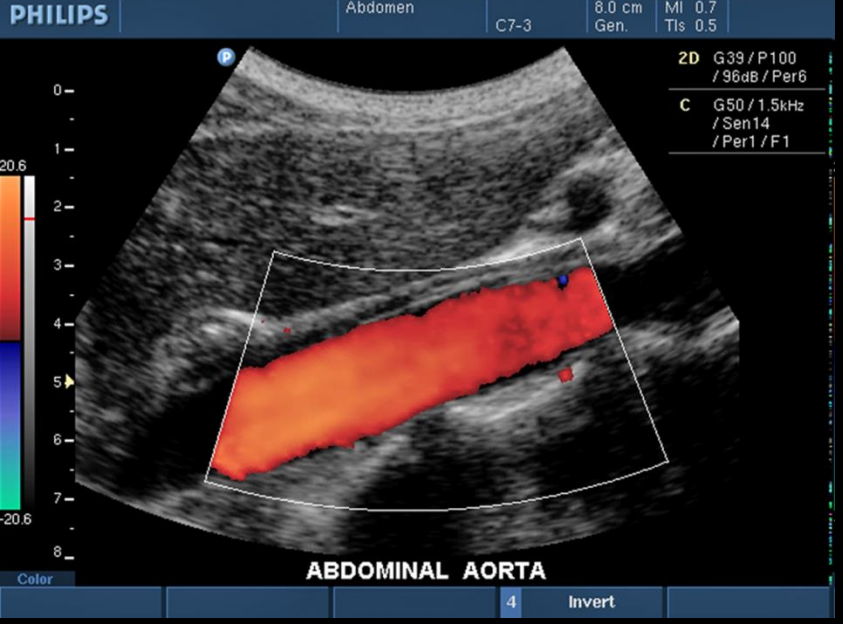
PHILIPS
Abdomen
C7-3
8.0 cm
Gen.
MI 0.7
TIs 0.5
2D G39 / P100
/ 96dB / Per6
C G50 / 1.5kHz
/ Sen14
/ Per1 / F1
20.6
-20.6
Color
4 Invert
ABDOMINAL AORTA

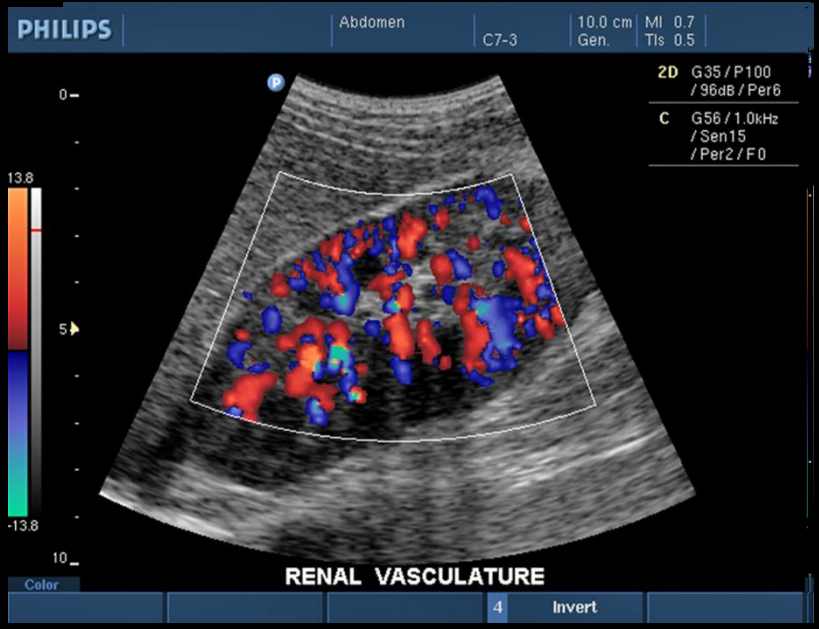
PHILIPS
Abdomen
C7-3
10.0 cm
Gen.
MI 0.7
TIs 0.5
2D G35 / P100
/ 96dB / Per6
C G56 / 1.0kHz
/ Sen15
/ Per2 / F0
13.8
-13.8
Color
4 Invert
RENAL VASCULATURE


PHILIPS
C7-3
9.5 cm
HRes.
MI 0.9
TIs 0.2
2D G55 / P100
/ 100dB / Per6
Zoom 1.96 ~ 9.46 cm
2D
UMBILICAL CORD



COMPUTED TOMOGRAPHY (CT)

Diagnostic Value :

- To assess equivocal plan X-Ray findings and ultrasound is not successful .
- Staging of body neoplasm.
- Metastatic workup of malignancies .
- Assessment of post traumatic complication .
- Diagnosis of vascular pathology .

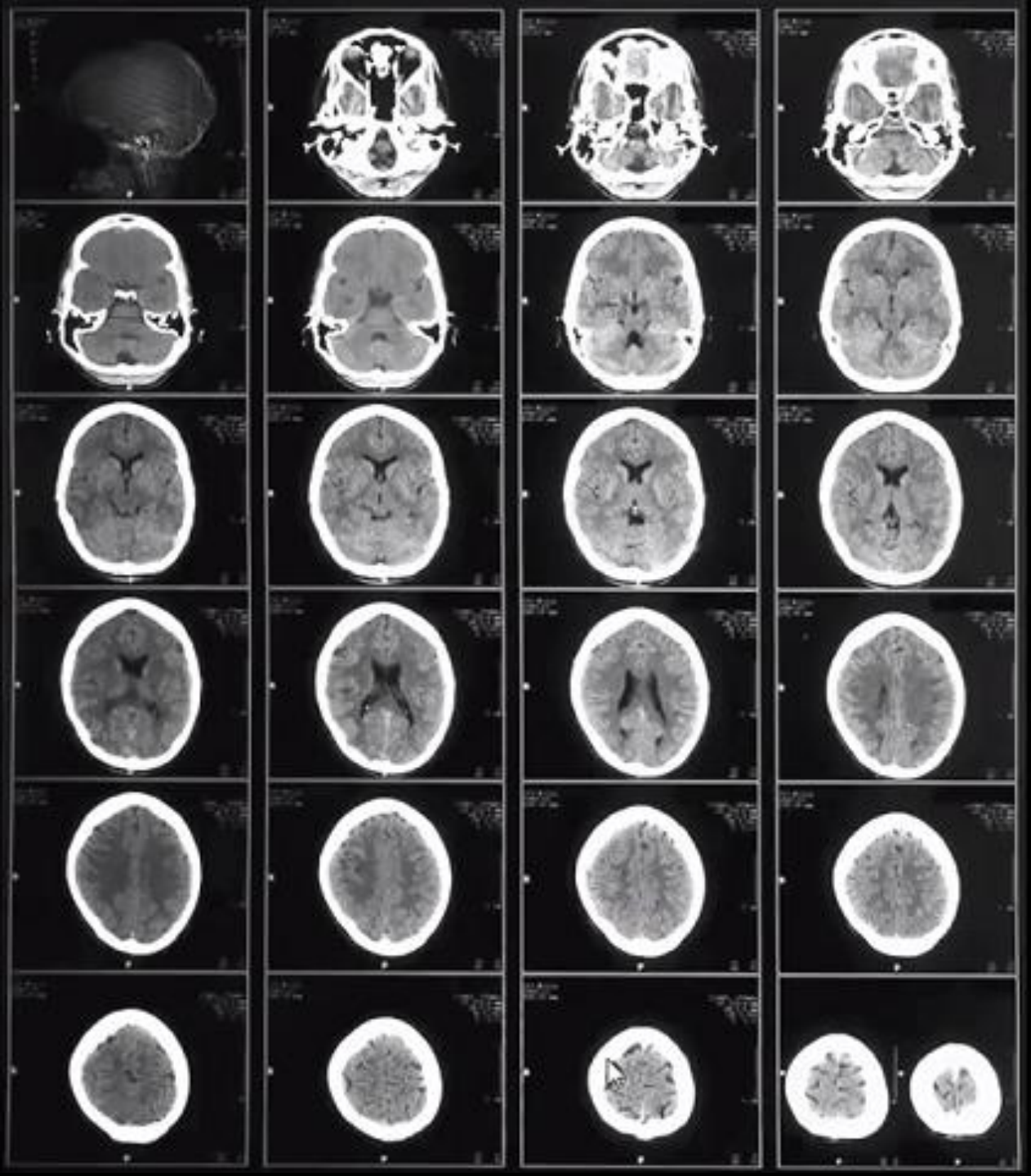

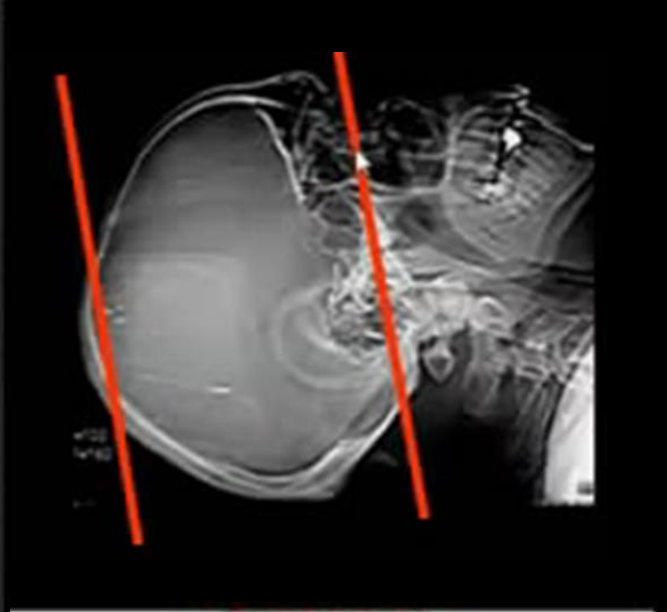

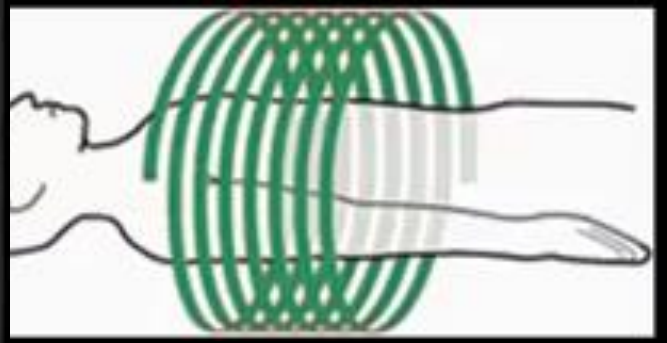

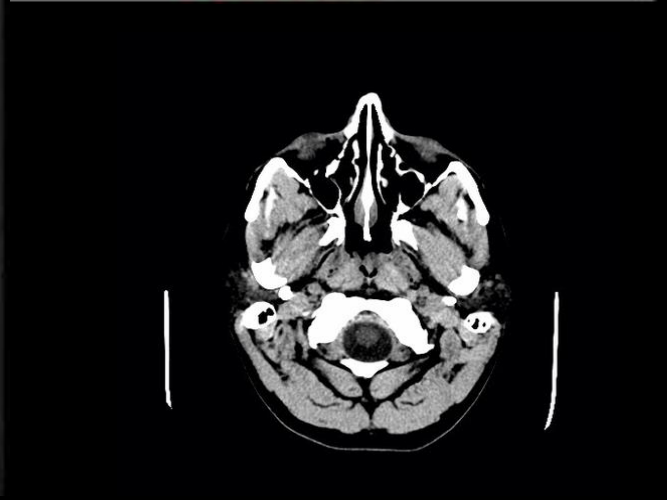

Multidetector CT 1999

- **Advantages**

4,8,16,32,64, 128-- 640

- 8 times faster than spiral CT
- CT chest in 4 seconds (very rapid scanning)
- Non invasive vascular imaging .
- Vertical reconstruction -Achieving high quality 2D and 3D reconstructed images
- Virtual endoscopy .

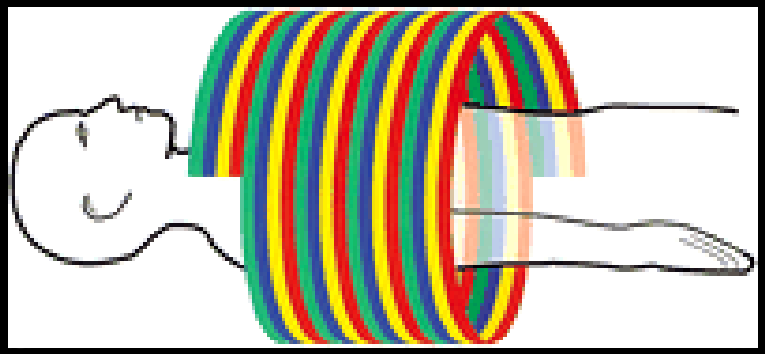



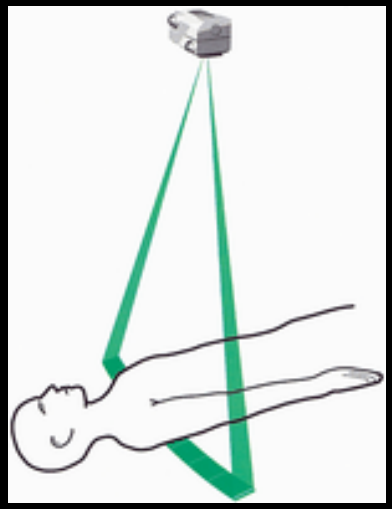

Normal pul



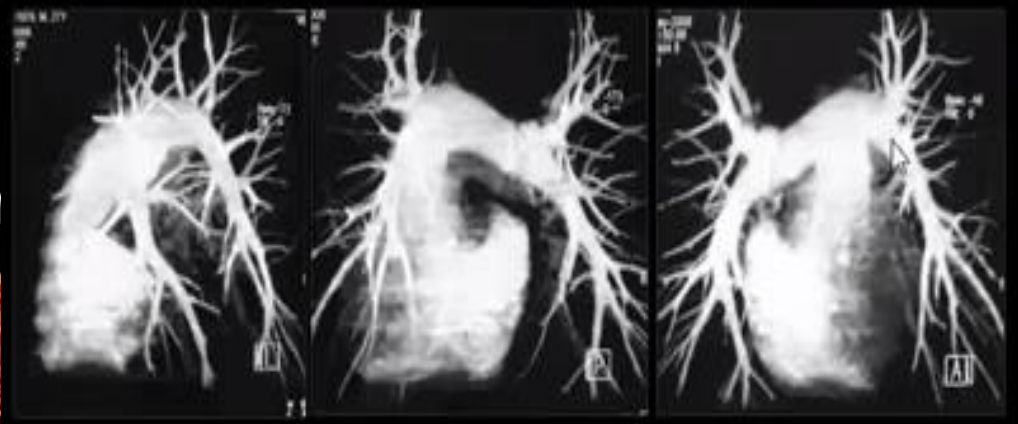



CT coronary angiography



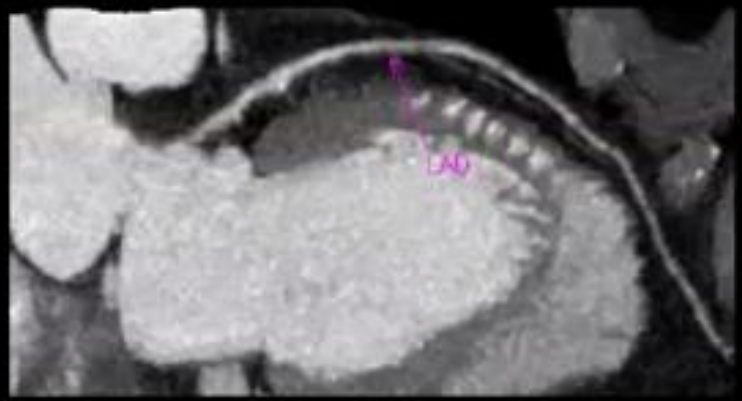

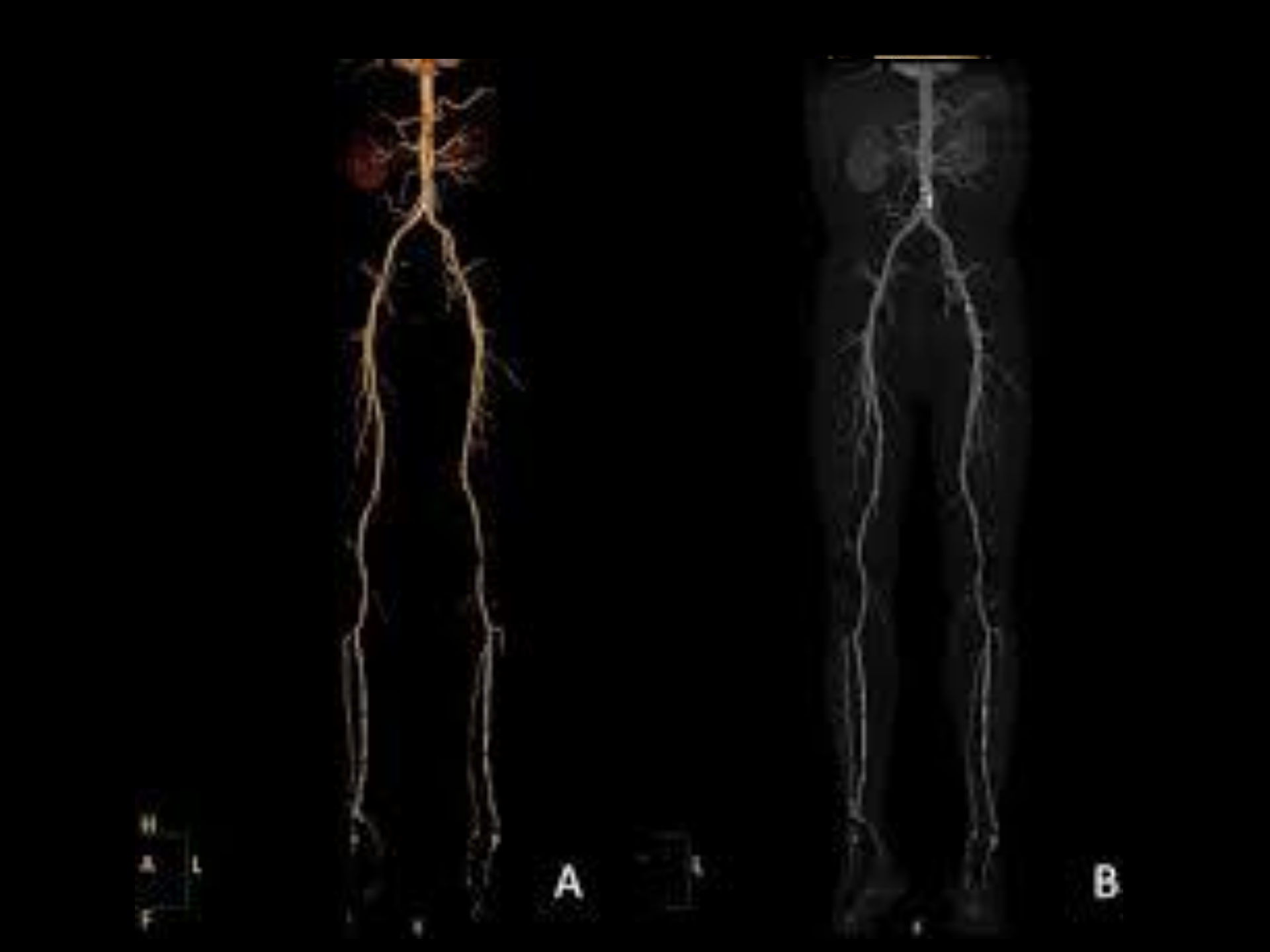
A
B

COMMON TERMINOLOGY (CT)

- **The beginner needs to be familiar with a few commonly used terms:

HU CT density

- **Hyperdens:** Bright .
- **Hypodens:** Dark
- **Isodens :** Gray

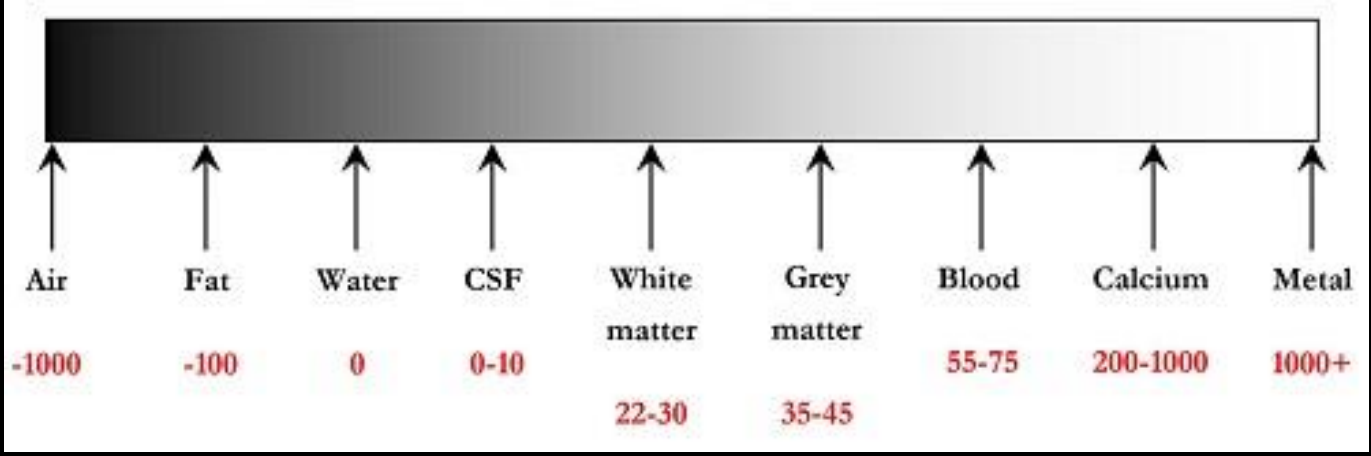

Hypodens •

Hyperdense

Isodense



Ischemic Infarction

Hg Infarction

Sub acute SDH

Magnetic Resonance Imaging (MRI)

Images are created by the interaction between the external magnet in the machine and the internal magnet in the human body



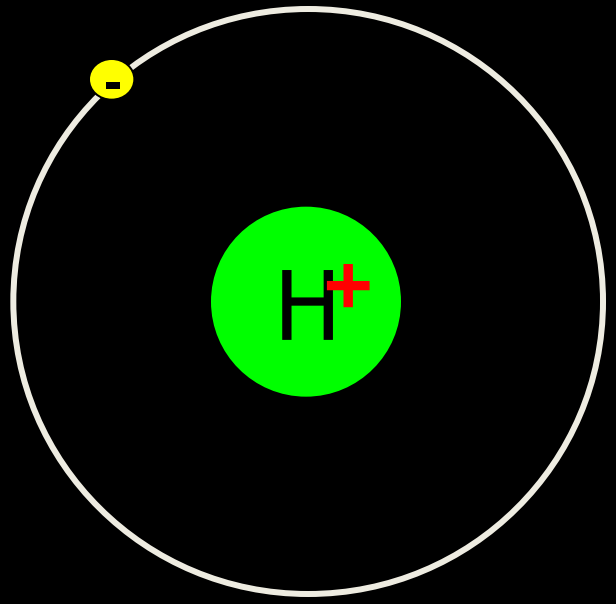

Water represents 75-80% of the human body

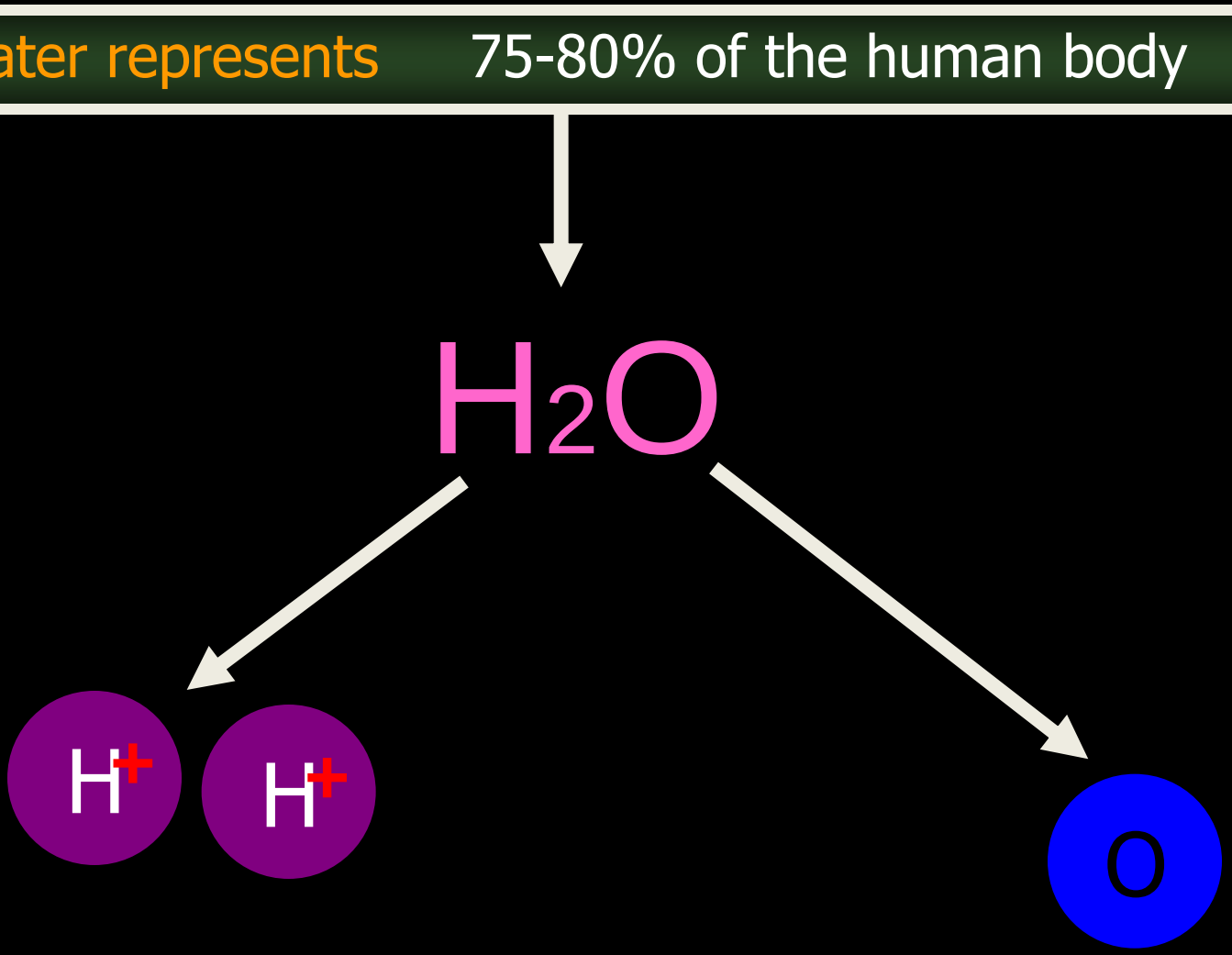

MR Imaging

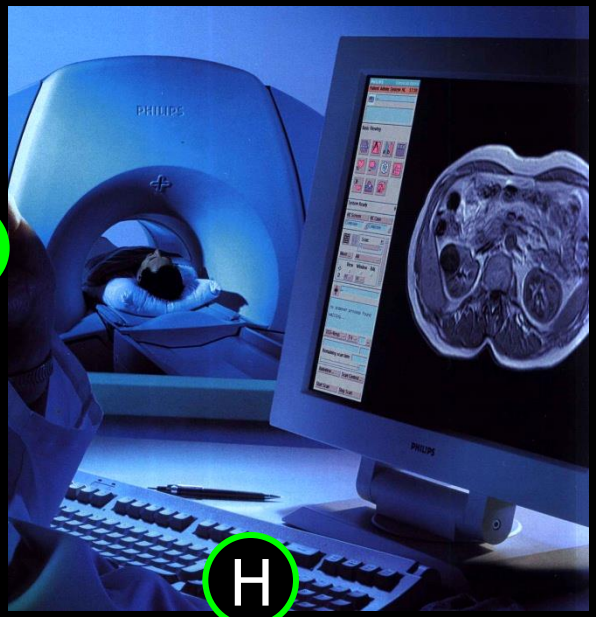

MR Imaging

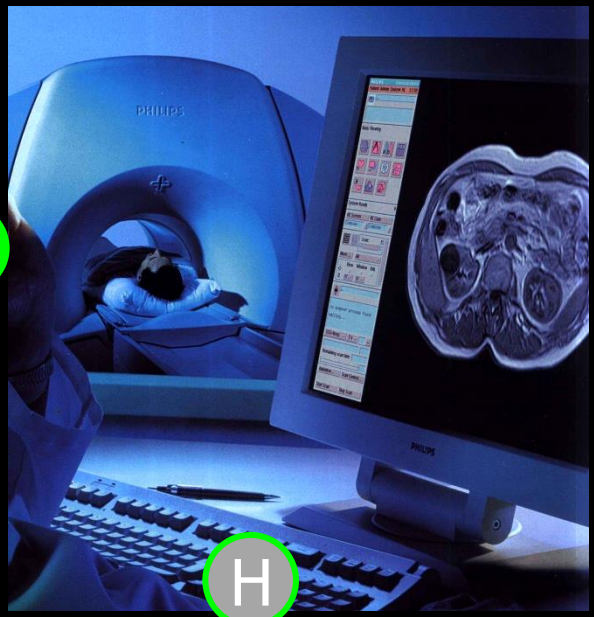

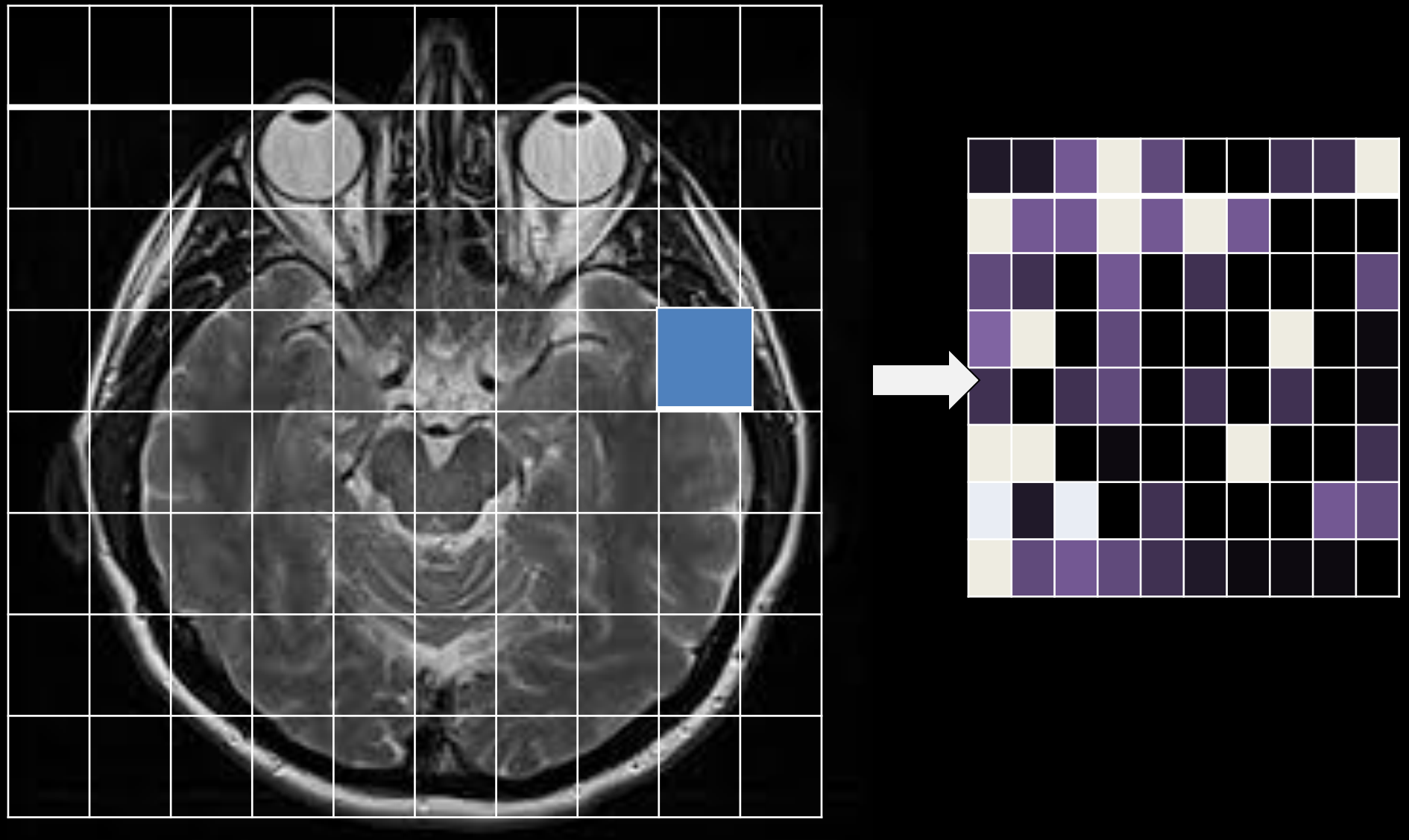

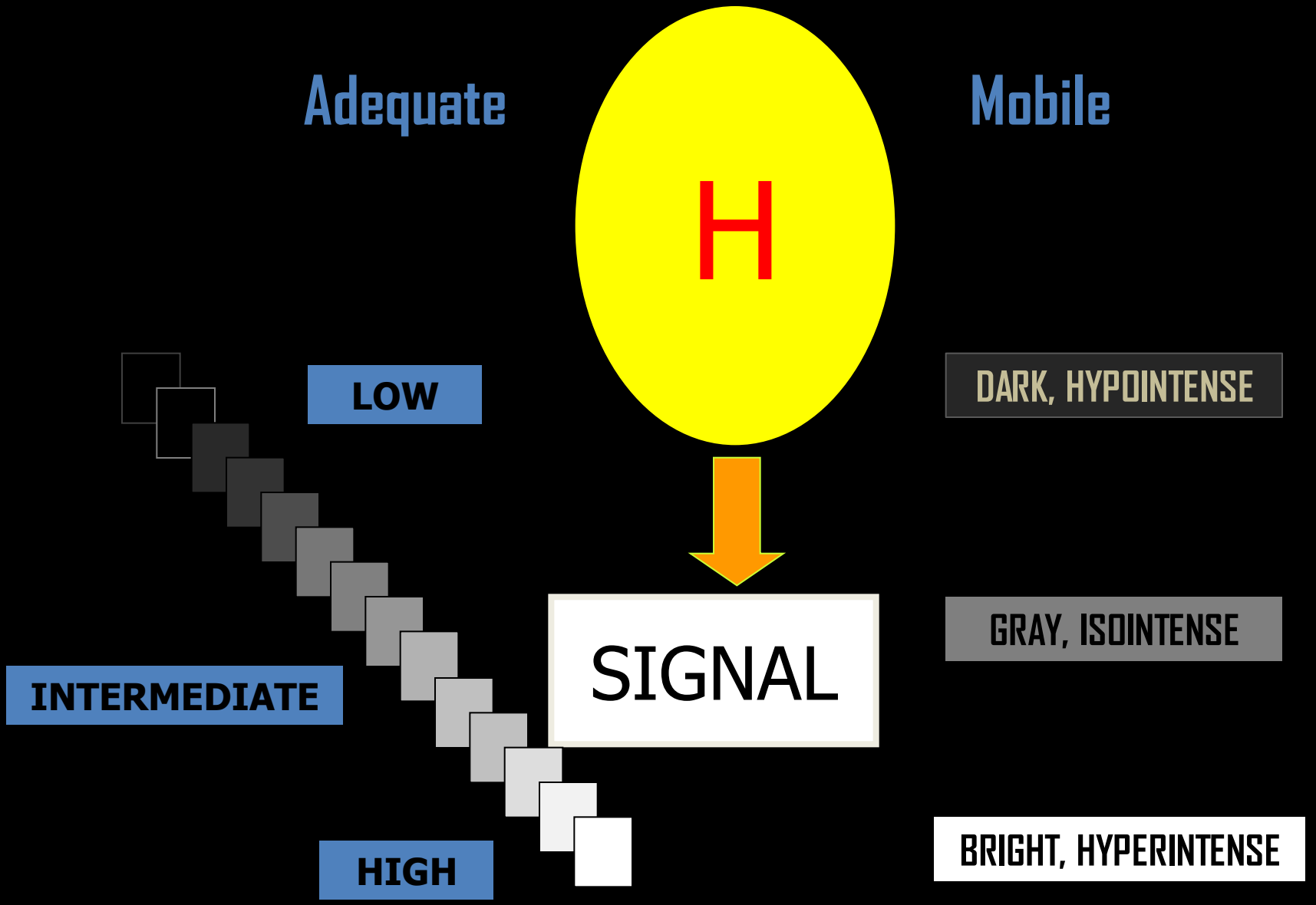
Adequate
Mobile
H
LOW
DARK, HYPOINTENSE
SIGNAL
INTERMEDIATE
GRAY, ISOINTENSE
HIGH
BRIGHT, HYPERINTENSE

Sequences

T1 FLAIR T2

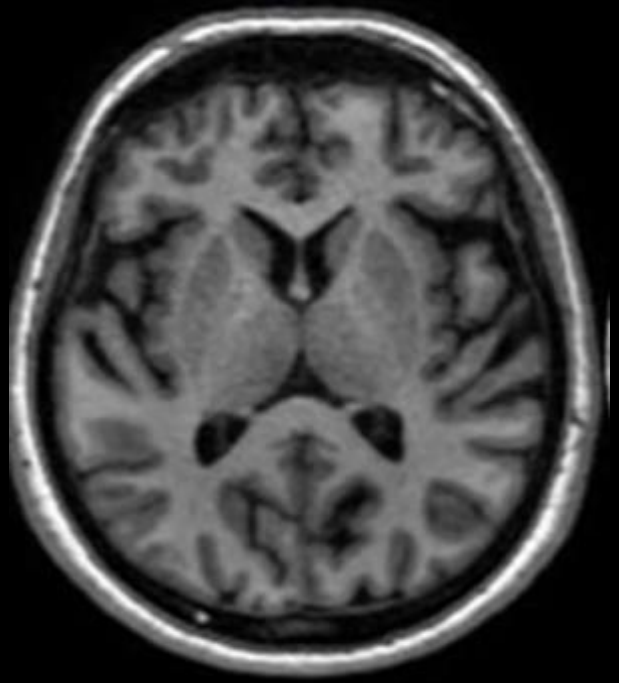

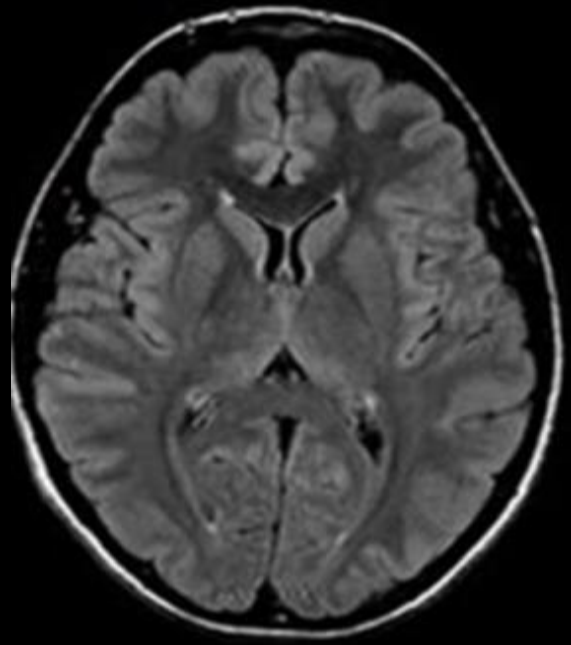

Planes

Axial

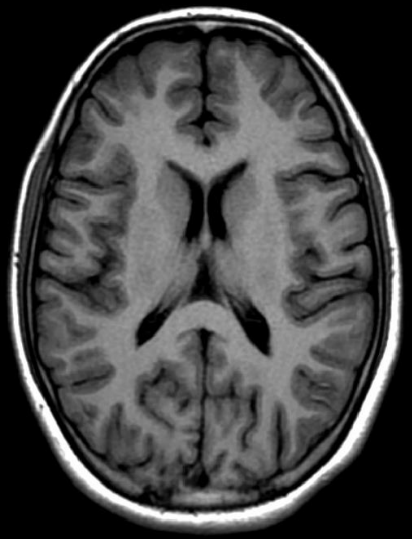

T1

T2

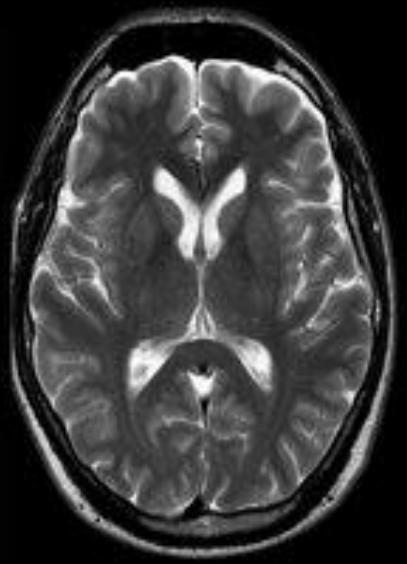

Planes

Sagittal



T1

T2

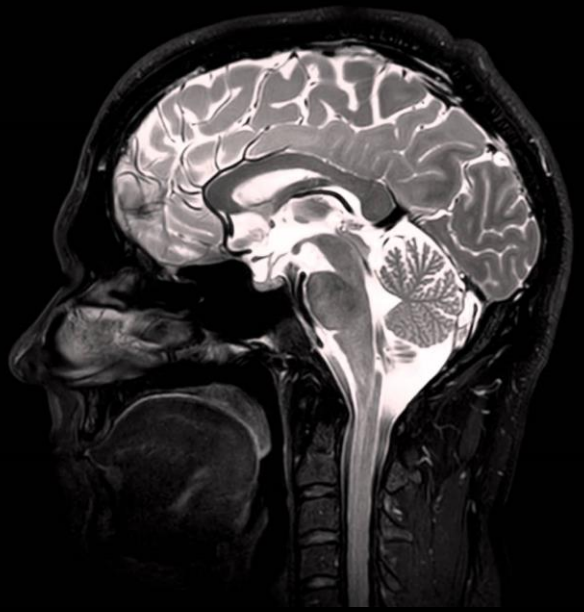

Planes

Coronal

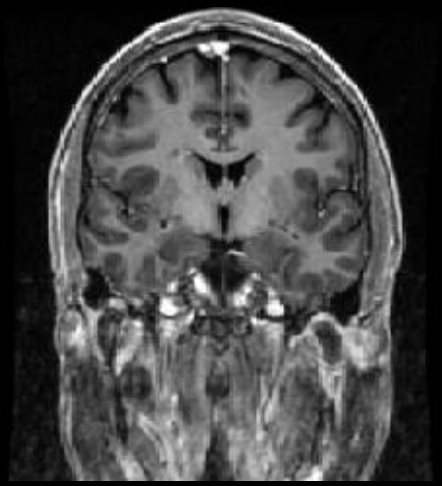

T1

T2

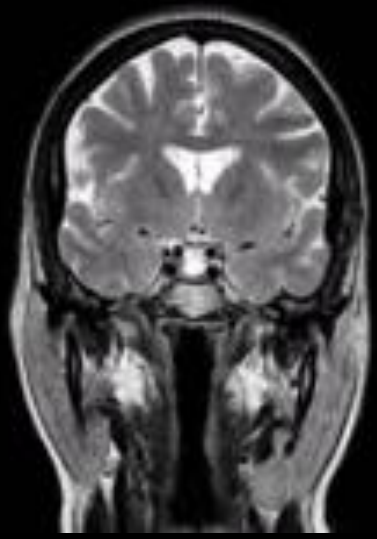

MAGNETIC RESONANCE IMAGING (MRI)

Advantages

- Can image in any plane – axial, sagittal or coronal.
- Non - ionizing and hence believed to be safe to use.
- No bony artefacts due to lack of signal from bone.
- Excellent anatomical detail, especially of soft tissues.
- Visualizes blood vessels without contrast: magnetic resonance angiography (MRA).
- Intravenous contrast utilized much less frequently than CT.

MAGNETIC RESONANCE IMAGING (MRI)

Disadvantages

- High operating costs.
- Poor images of lung fields.
- Inability to show calcification with accuracy.
- Fresh blood in recent haemorrhage not as well visualized as by CT.
- MRI more difficult to tolerate with examination times longer than CT.

Contra-indications to MRI

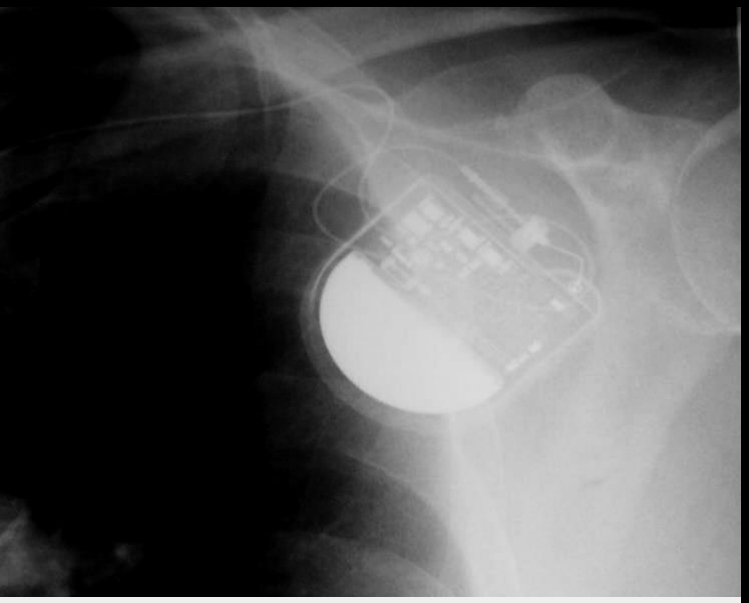

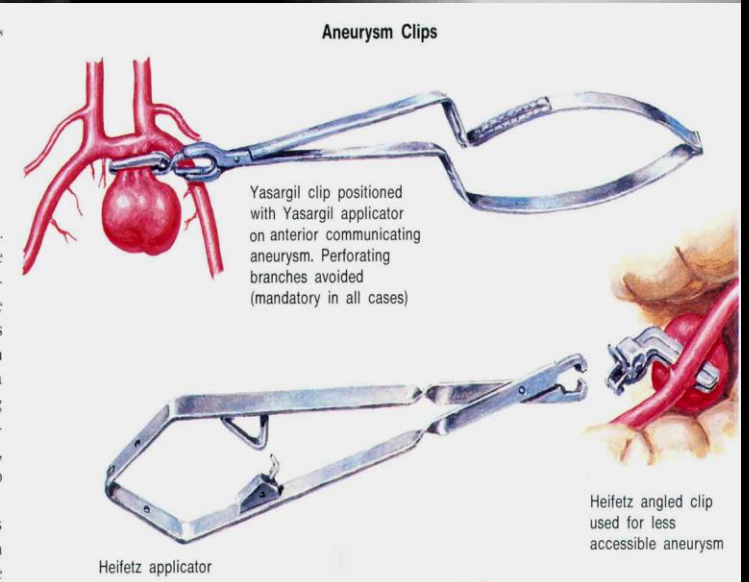

- Cardiac pace maker
- Chochlear (inner ear) implants
- Intra-cranial aneurysmal clipping
- Swan-Ganz catheter with thermodilution tips
- Implanted neuro stimulators
- Metal or unidentifiable FB in the eyes
- Shrapnel near a vital organ .

NUCLEAR MEDICINE

- physiological imaging modality
- **Its avaluable diagnostic tool and** medical specialty that uses radioactive tracers (substances) to assess body functions and to diagnose and treat disease .
  - it records radiation emitting from within the body rather than radiation that is generated by external sources like X-rays

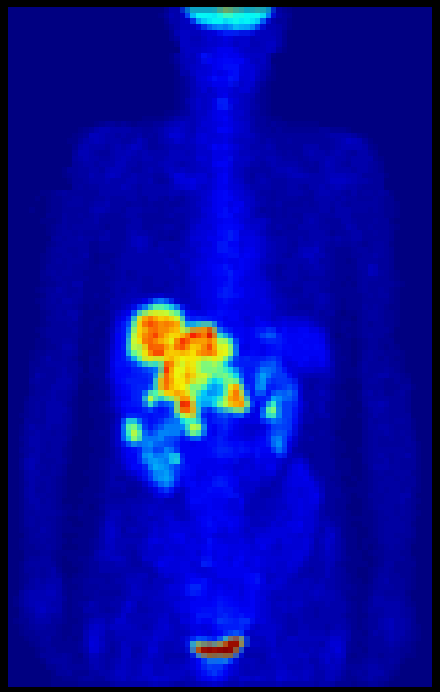

NUCLEAR MEDICINE

- Single photon emission computed tomography (SPECT) and positron emission tomography (PET) scans are the two most common imaging modalities in nuclear medicine

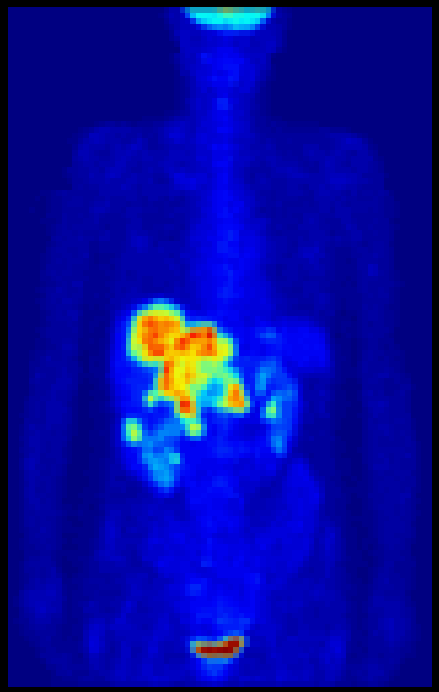



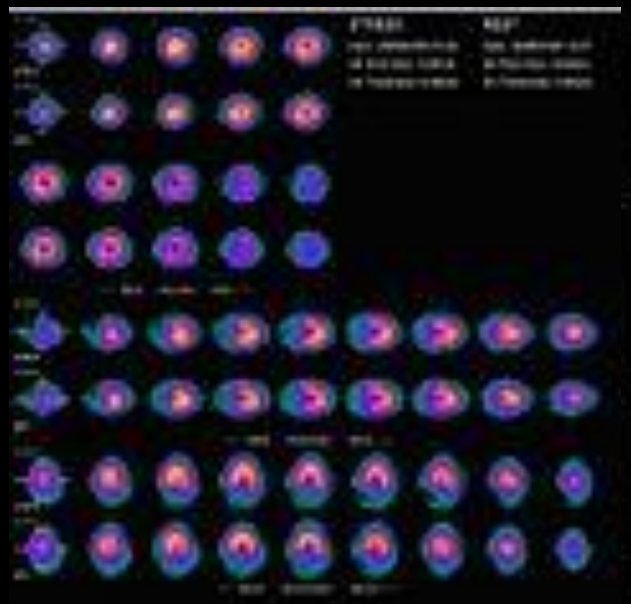

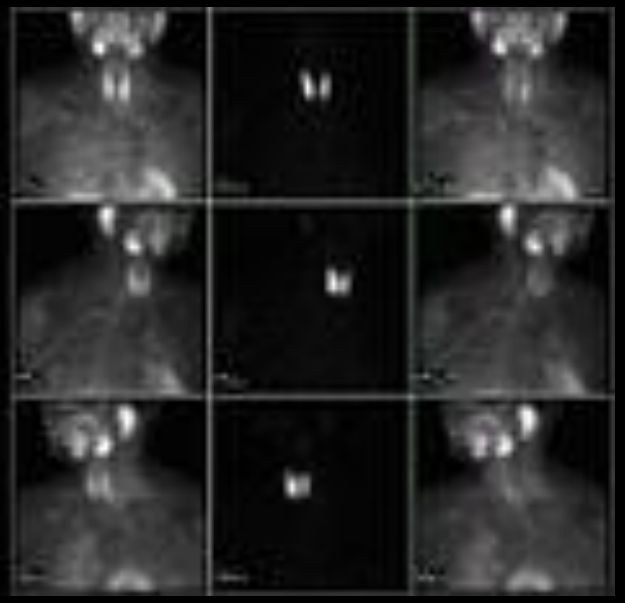



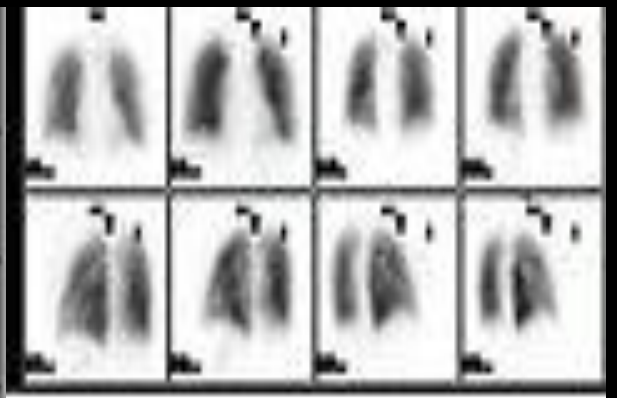

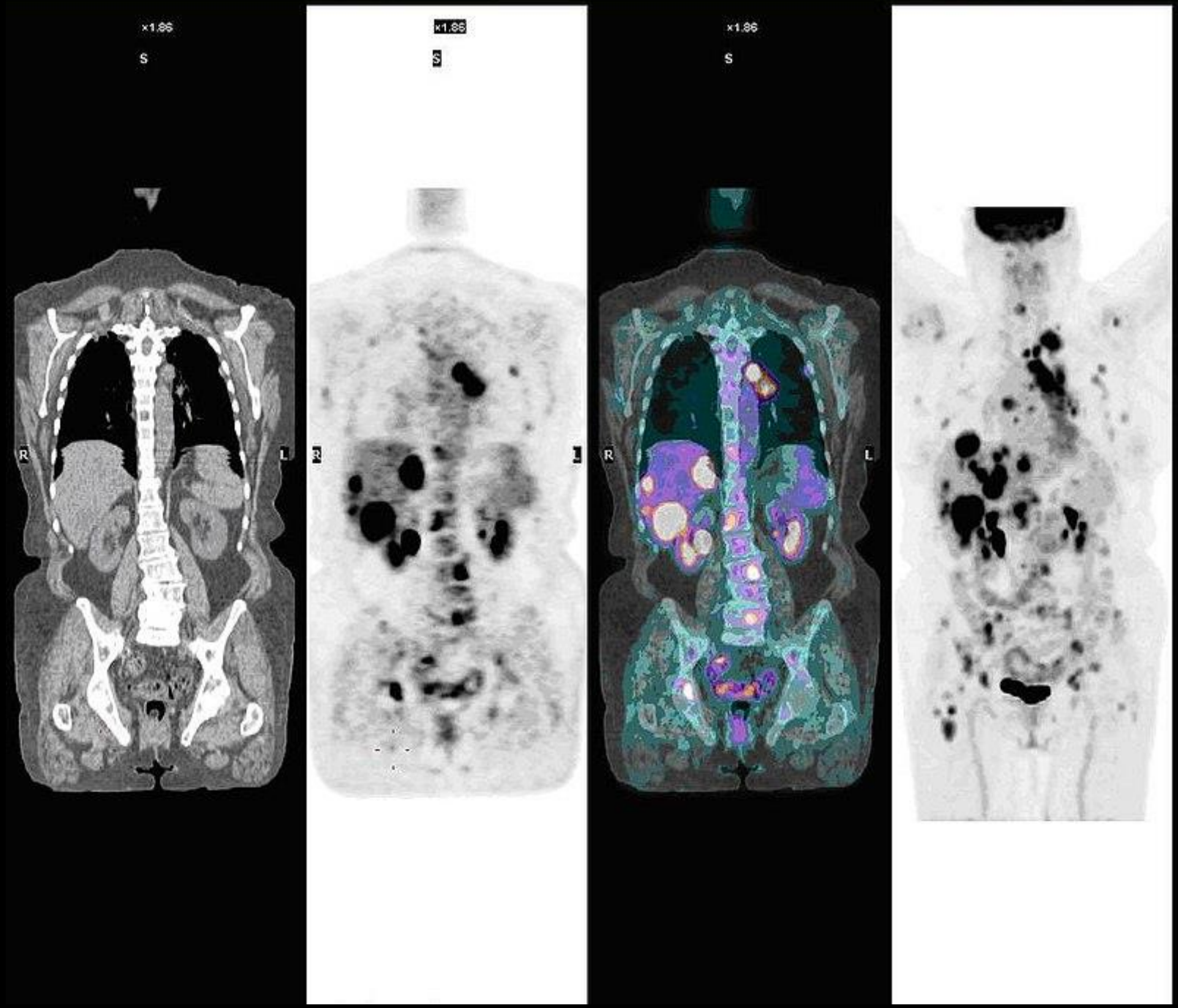
×1.86
S
R
L
×1.86
S
R
L
×1.86
S
R
L

Interventional Radiology

RADIOLOGY THE EYE OF MEDICINE

THANK YOU