URINARY TRACT PATHOLOGY

Dr Marwan Matar

Consultant Radiologist

European Gaza Hospital

Imaging Modality

- Plain X-Ray
- Flouroscopy
- US
- CT
- MRI
- Intervention
- Nuclear medicine











Plane UT (KUB)

Diagnostic value:

- Radio-opaque calculi.
- Calcification
- Gas pattern.
- Organomegaly.
- Bone abnormalities.

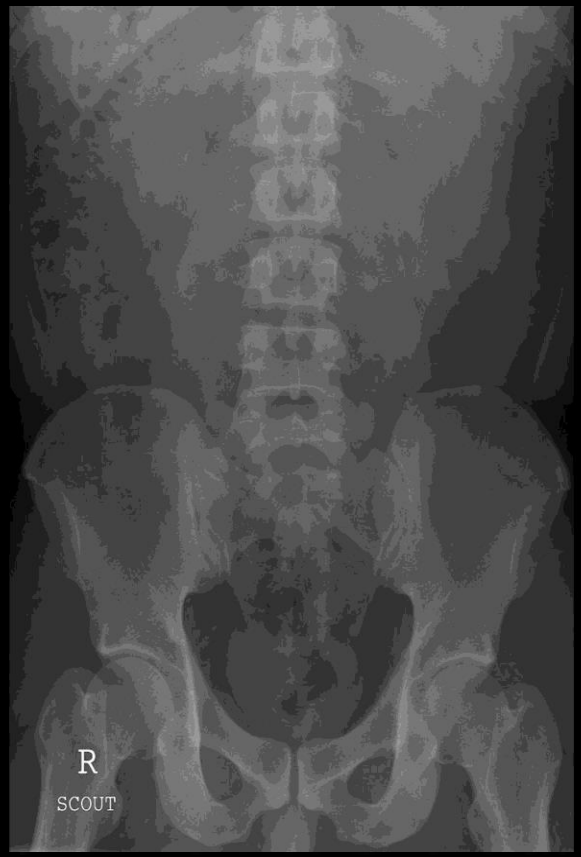

Intravenous Urography (IVU) (IVP)

- **Diagnostic value:**
  - Show the renal function.
  - UT obstruction.
  - Renal and bladder masses
  - Congenital anomalies.
- **Contraindication in patient with:**
  - Renal impairment.
  - Hypersensitive to CM.
  - Pregnancy.



Voiding Cystourethrogram (VCUG)

❑ Indication :

- ➢ Diagnosis /assessment of the urethral stricture.
- ➢ Suspected urethral trauma



❑ Contraindication :

- ➢ UTI
- ➢ Recent Urethral instrumentation (1week).

CT Urinary Tract (CTUT)

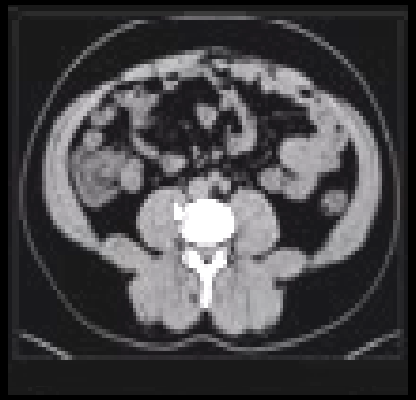





CT UT with IV contrast

- CT remains the single most effective modality for diagnosis and staging RCC with accuracy appreciating 90%

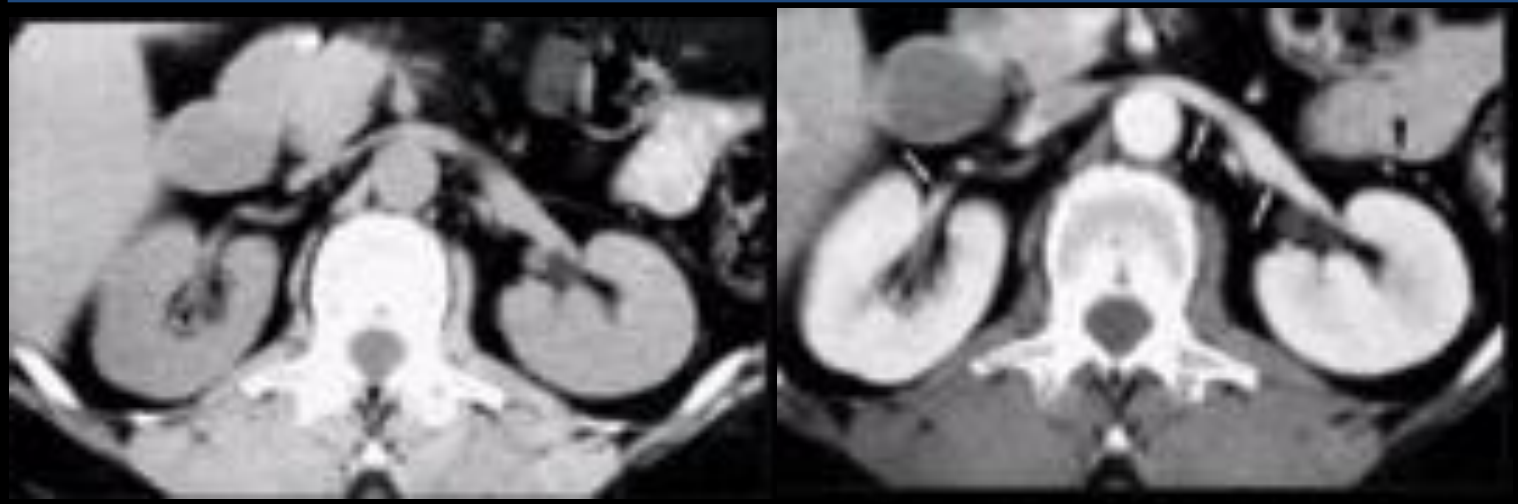

Pre contrast

Post contrast

CT UT with IV contrast

- Dynamic scan.
- CT renal angiography and CT urography

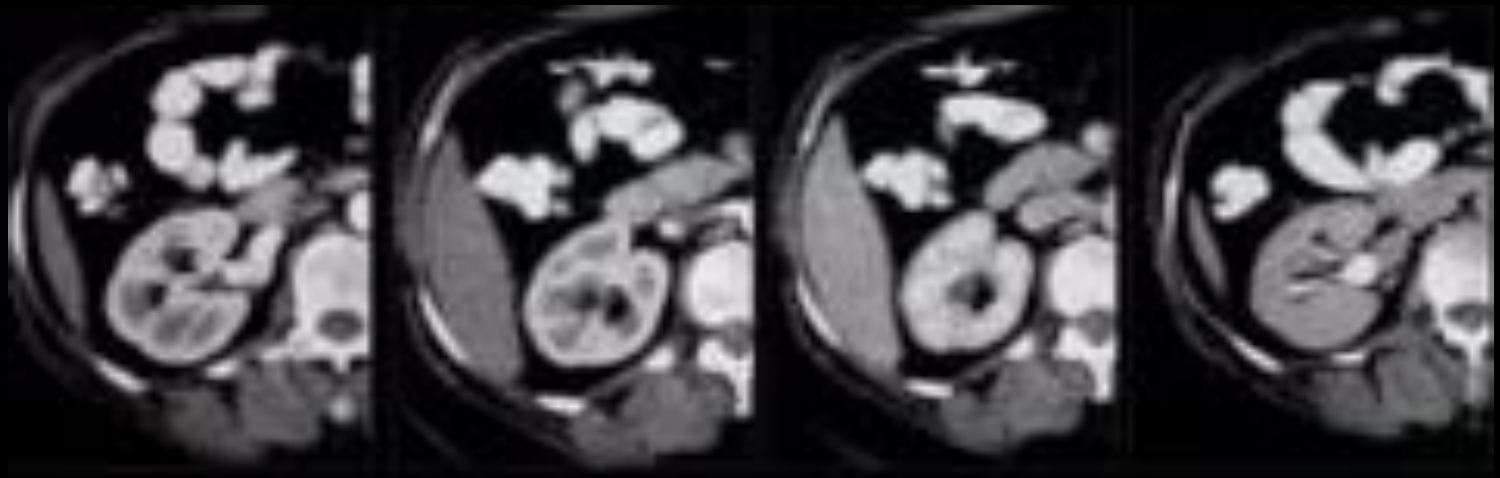





MR Urography (MRU)





Items for evaluation

- Congenital anomalies.
- Stone disease.
- Renal masses.
- Renal infection.

Congenital anomalies

1. Fetal lobulation.
2. Horseshoe kidney
3. PUJ
4. Hypoplasia or hyperplasia
5. Absent one kidney.
6. Duplex kidney and ureter.
7. Malrotation.
8. Ectopic kidney

- Shape
- Size
- Number
- Position

Fetal lobulation (normal variation)





Horseshoe kidney









PUJ obstruction







Congenital PUJ obstruction



Renal agenesis

CT Urography shows normal left kidney , but the RT kidney is not seen any where along the path of ascent course or pelvic



Renal Duplication

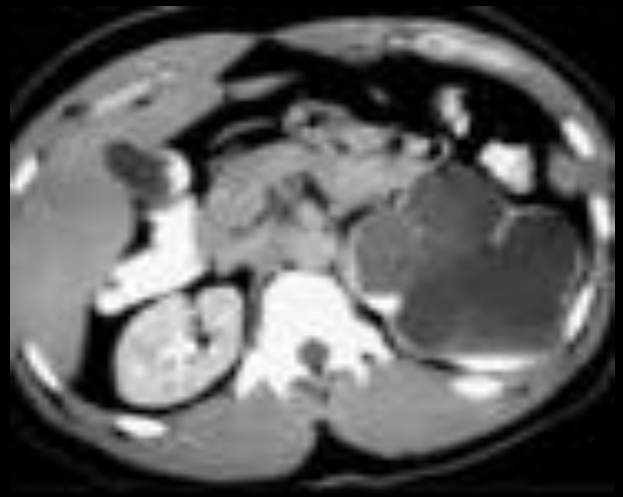

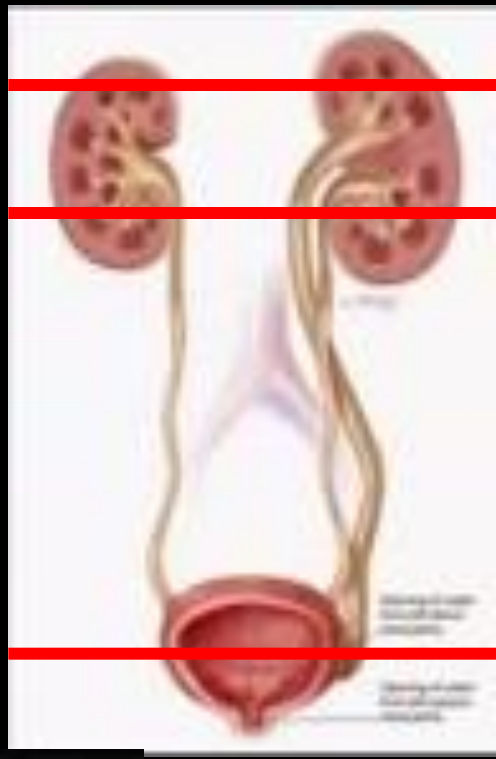

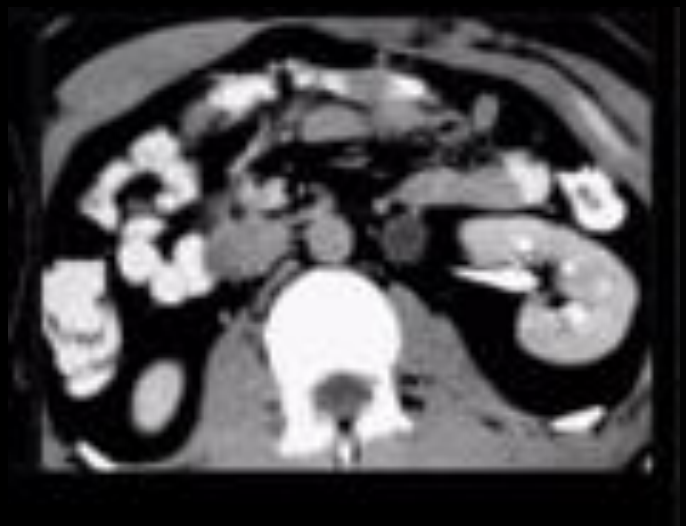



Duplex ureter

- The RT superior moiety is obstructed , its ureter may be ectopic and enters the bladder urethra or vagina more inferiorly than the normally placed inferior ureter moiety.
- The superior ureter may associated with a uretrocele and more likely obstructed.
- The inferior ureter may associated with reflux nephropathy and scaring.



Malrotation





Ectopic Pelvic Kidney





Bilateral Ectopic Pelvic Kidney

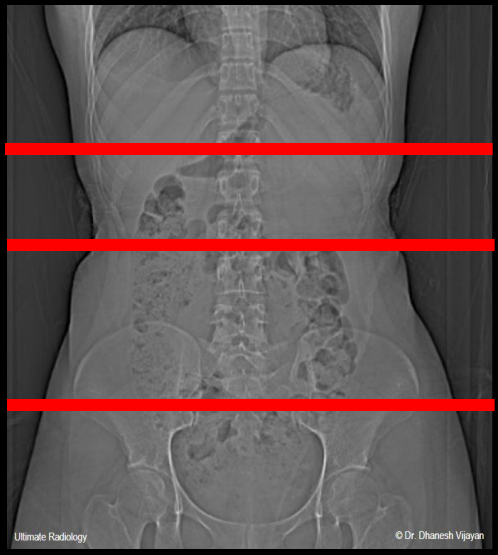



Cross Ectopia

- The left kidney is crossed below the RT kidney, but normal insertion of its ureter to UB



Items for evaluation

- Congenital anomalies.
- Stone disease. → Radio-opaque stones / Radiolocent stones
- Renal masses.
- Renal infection.

Distal uretric stone U/S



Radio~ opaque renal stones





Radio~lucent renal stones





Distal uretric calculus

Flank pain and fever



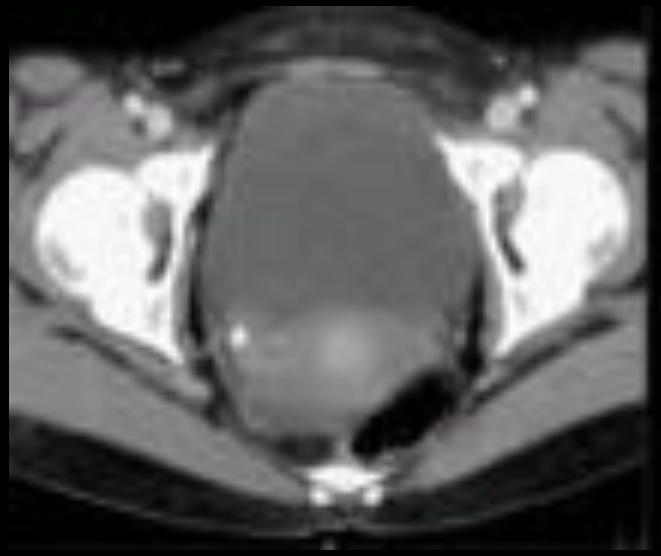

- CT scan shows swollen RT kidney with dilated pelvis.
- Stone in lower RT ureter which mostly causes the hydronephrosis and predispose to infection

Items for evaluation

- Congenital anomalies.
- Stone disease.
- Renal masses.
- Renal infection.

Simple renal cyst,

Atypical renal cyst.

Polycystic renal disease.

Renal cell carcinoma.

Nephroblastoma.

Transational cell carcinoma.

Renal lymphoma.

Renal metastasis.

Multicystic nephroma.

Oncocytoma.

angiomylipoma

Renal masses

- Cystic
- Solid
- Mixed



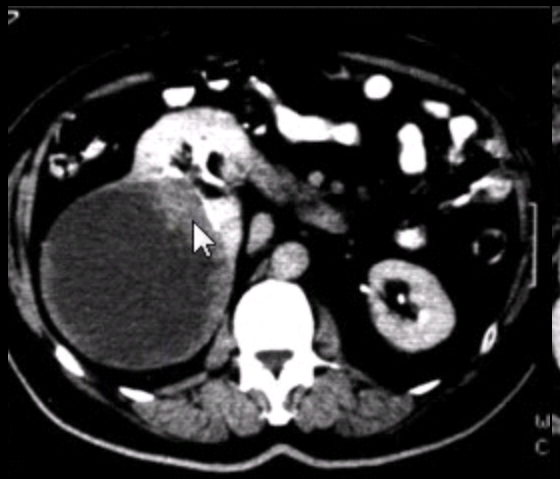





Simple renal cyst

- Very common
- Unknown cause.
- Typical cyst criteria.

Yes

1. Smooth sharp margin.
2. Paper thin wall
3. clear water contents.

No

1. Septation.
2. Calcification.
3. Mural nodules enhancement.



Atypical renal cyst

- Thick margin
- Abnormal contents
- Septations, calcifications
- Mural nodules [Consider solid lesion? Neoplasm]

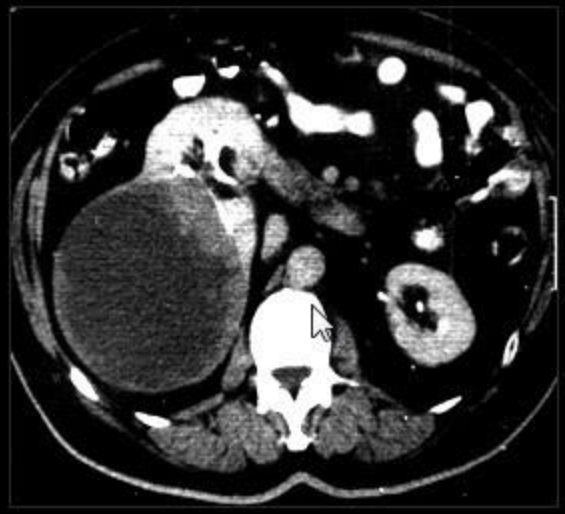

Atypical renal cyst

- Thick margin
- Abnormal contents
- Septations, calcifications
- Mural nodules [**Consider solid lesion? Neoplasm**]

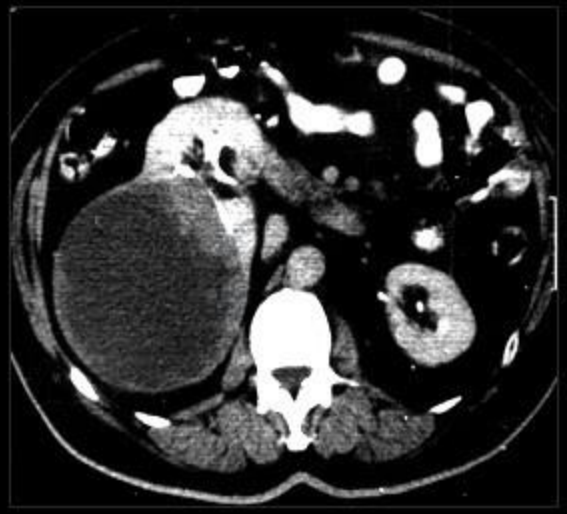

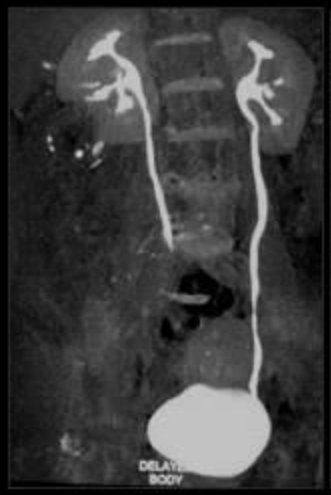





Atypical renal cyst

- Thick margin
- Abnormal contents
- Septations, calcifications
- Mural nodules [Consider solid lesion? Neoplasm]

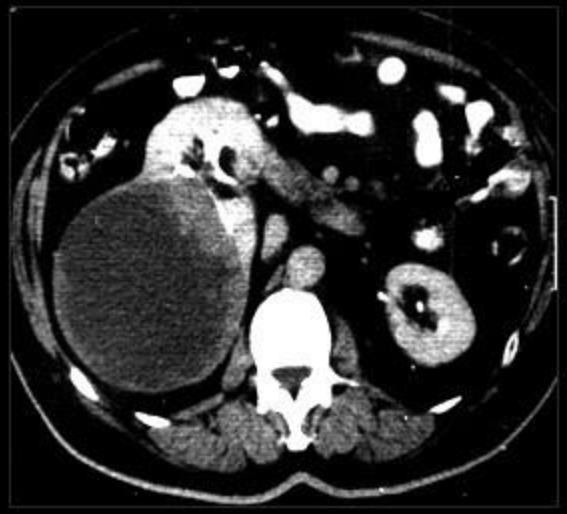

Pathologically proved RCC

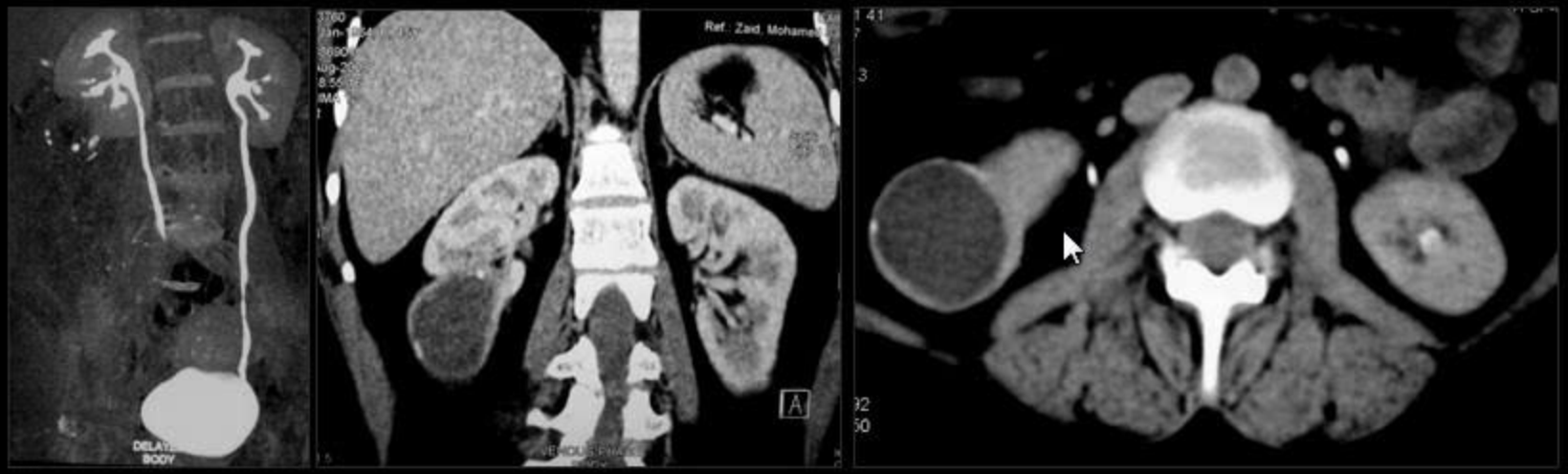

Poly cystic renal disease

Infantile type

- Bilateral large kidneys
- Numerous cysts [few mms in diameter]
- Poor renal function
- Death usually after birth
- Other cysts in liver, spleen, pancreas





Non contrast CT shows **polycystic kidneys** with progression after 6 years

Poly cystic renal disease

Adult type

- Multiple cysts of variable sizes
- Bilateral large kidneys
- Preserved renal function with splayed calyces
- Renal failure and hypertension [4th decade]
- Hepatic and pancreatic cysts in 1/3 of cases

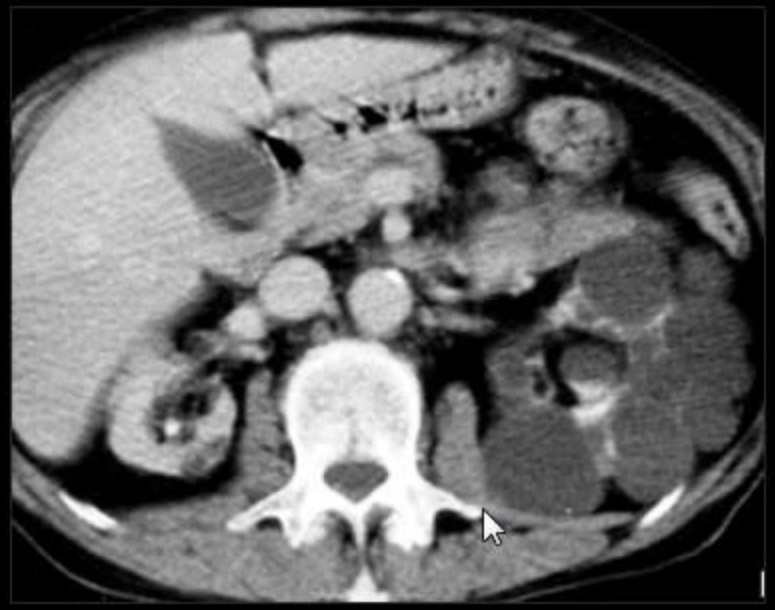

polycystic kidneys
with asymmetrical involvement



Autosomal dominant polycystic kidney disease.

[A 30-year-old man with positive family history]

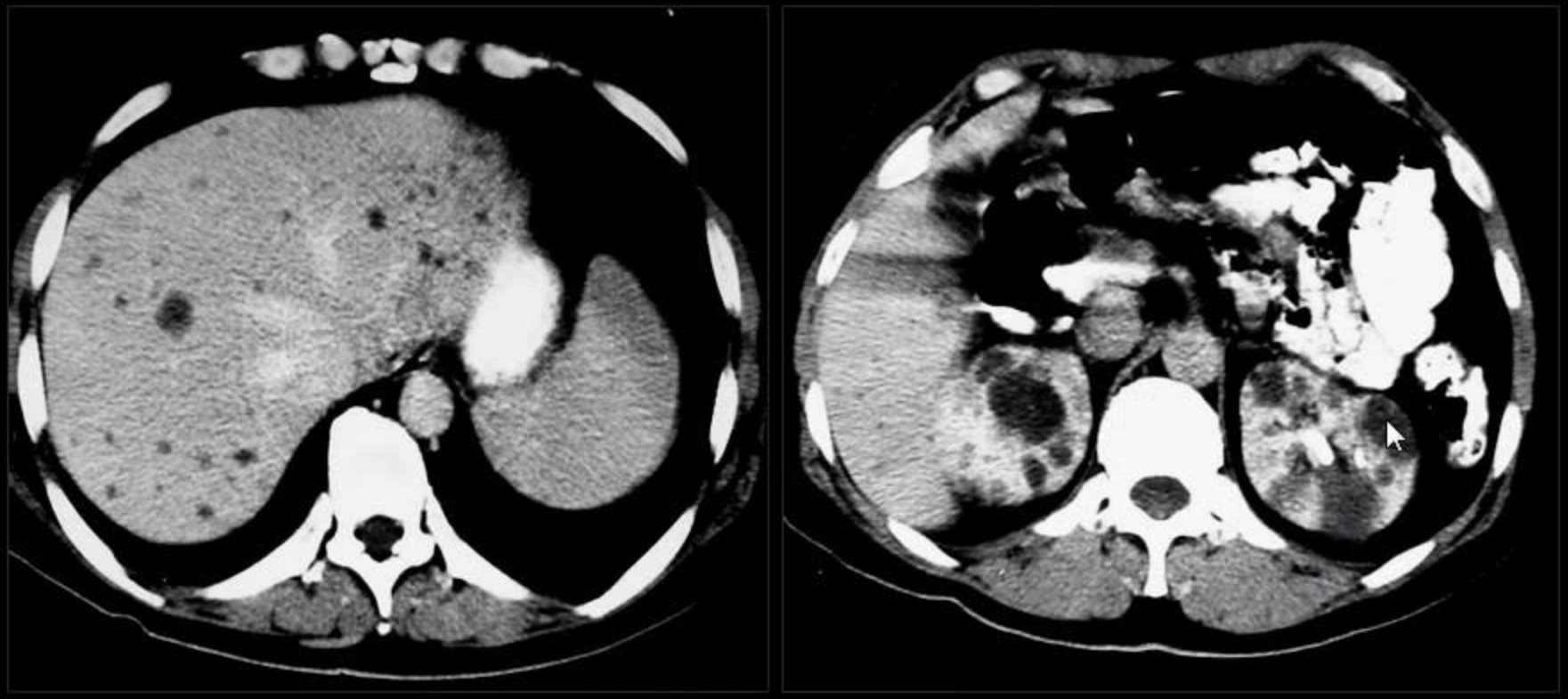

Autosomal dominant polycystic kidney disease

Multiple renal cysts

- Few cysts
- No family history of polycystic disease
- No hypertension or renal failure

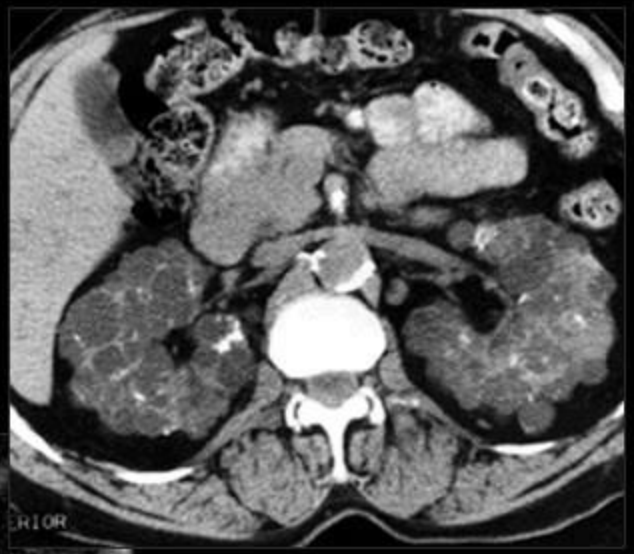





Renal Cell Carcinoma RCC

- RCC represents about 90% of all renal tumors in adults
- The classical clinical triad of hematuria, abdominal mass, and pain is an uncommon presentation of RCC and in fact late one.
- Micro- hematuria may exist but hematuria can be absent in up to 40% of cases 24-50% of surgical treated RCC are incidentally discovered.



RCC imaging modality CT

- Enhancing mass
- Contour deformity.
- Matrix calcification

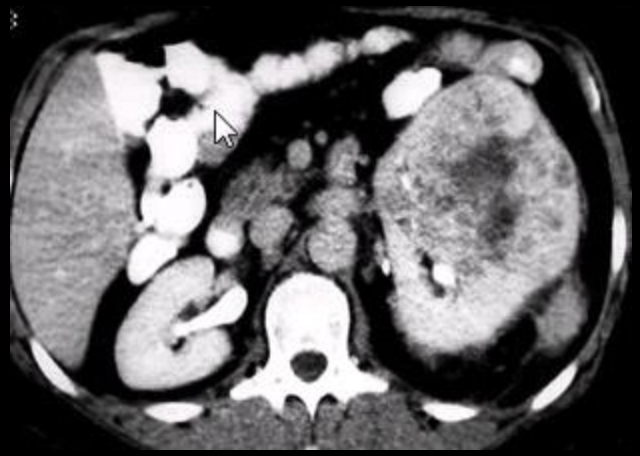





Imaging interpretation should include:

- Evaluation of tumor size, & shape.
- Peri nephric invasion .
- Tumor vascular (CT angiography).
- LNs enlargement.
- Vascular invasion:

1. IVC invasion .
2. Renal vein invasion

- Local or distant metastatic spread.

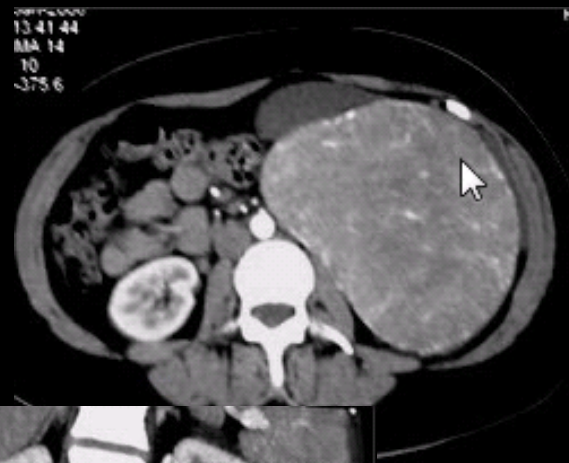



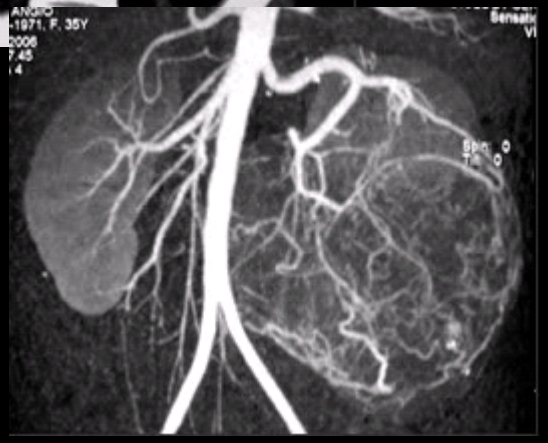

Stage III b, c

venous tumor spread

- Extension into the IVC 4-10% dictates the surgical approach (abdominal, thoraco- abdomen, cardiopulmonary bypass).

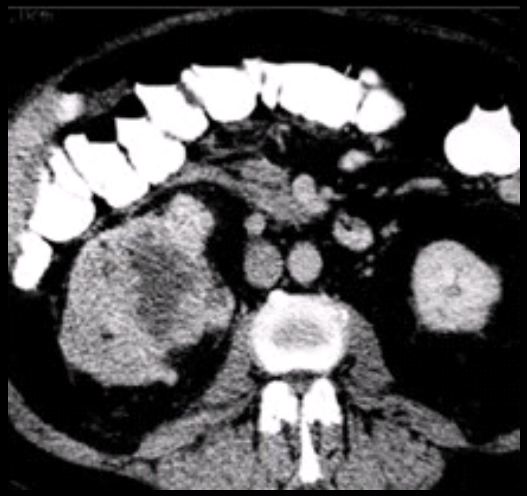

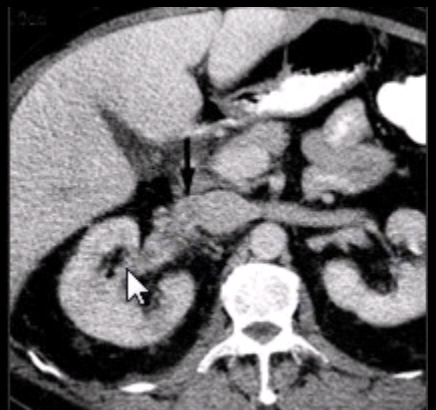



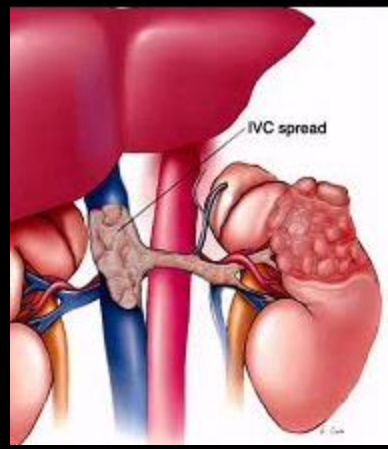

Stage IV a

- Extension outside the Gerotas facia with invasion of the adjacent structures.



Stage IV b

Supra – diaphragmatic IVC.

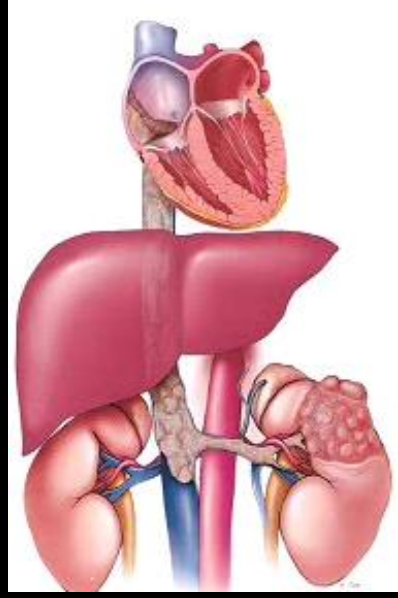

- Extension into IVC 4-10%.
- Dictates the surgical approach.
- (abdominal, thoraco- abdomine, cardiopulmonary by pass).





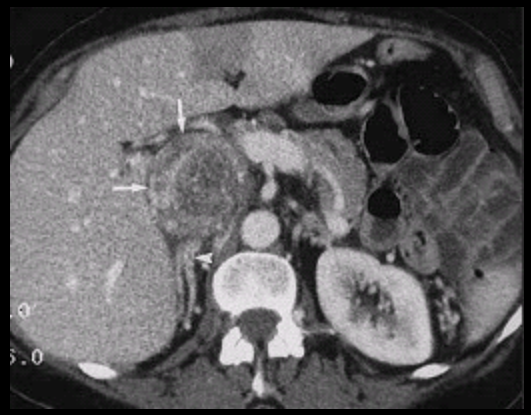

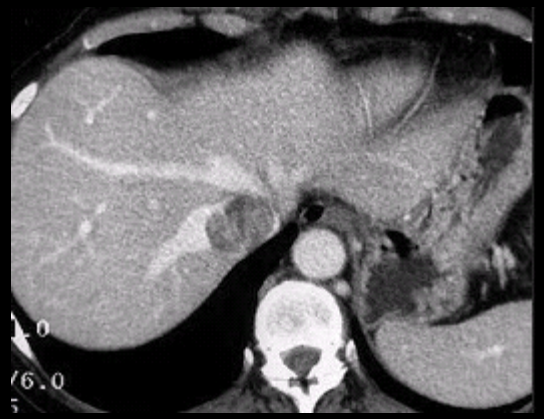

Cystic Renal cell carcinoma

- Large cystic mass with mural nodules and appear vascular in CT angiography

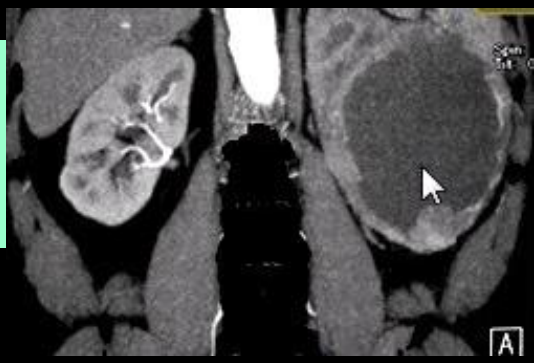

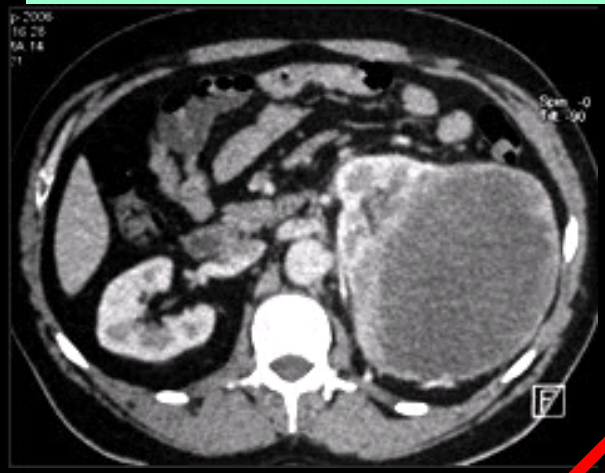



Calcification

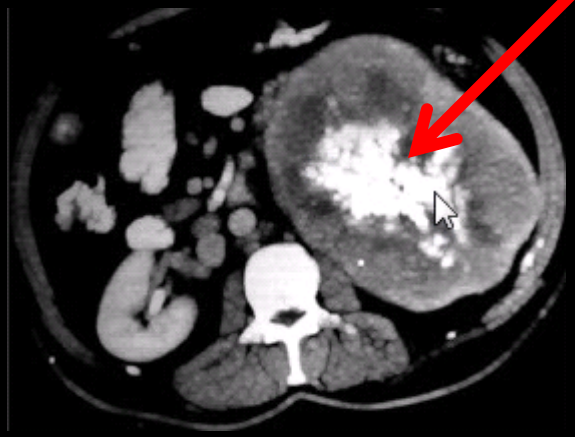

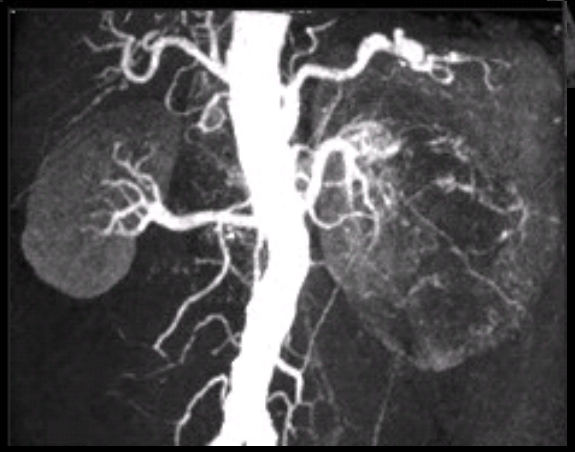

Nephroblastoma (Wilms tumor)

- Wilms tumor in the most common primary malignant renal tumor of the childhood.
- Represents about 7% of all childhood cancer.
- The mean age at diagnosis is 3.5 y.
- Abdominal mass with pain, fever, and hematuria.
- About 10% of the cases have metastasis at presentation.
- Bilateral tumors occur in 5-10%.



Nephroblastoma

M 6Y

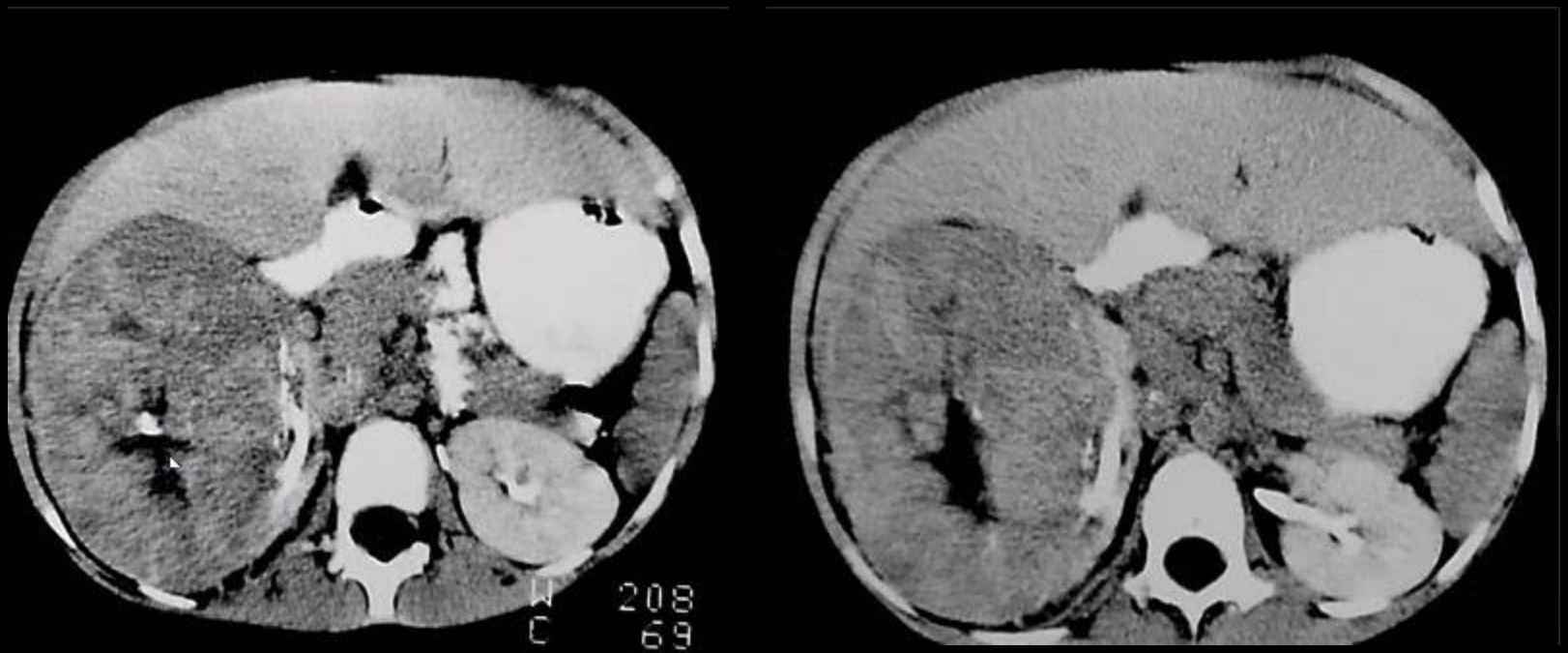

Transitional cell carcinoma

- The most common tumor of the renal pelvis
- Multiple lesions in about 30% of cases.
- M:F = 4:1 above 60ys.
- Diagnosed by IVP, CTU, MRU.
- Filling defect in the pelvis.

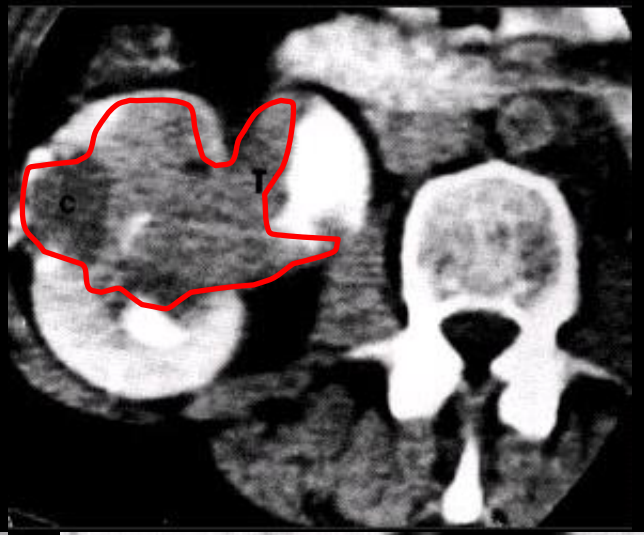

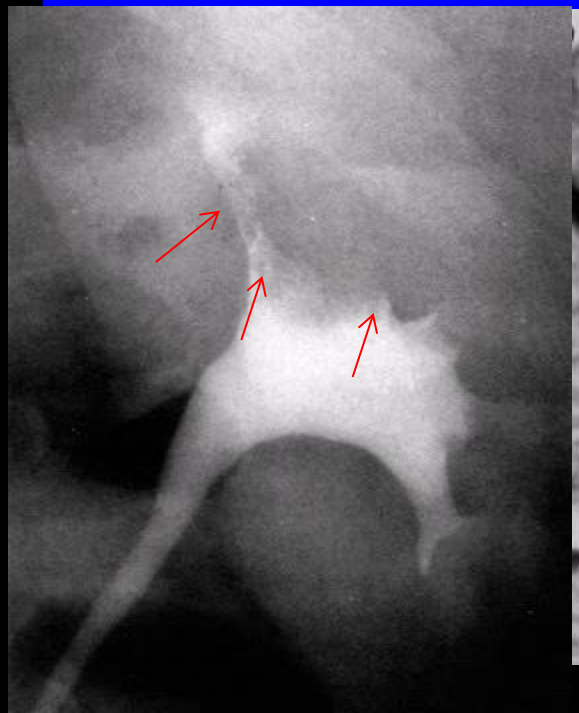





Renal pelvic filling defect

- Non opaque stone.
- Blood clots.
- Polyps.
- Hypertrophied renal papilla.
- Vascular impression.
- Inflammatory conditions.



TCC

Oncocytoma

- Differentiation from RCC is difficult
- Helpful diagnostic criteria
  - Homogenous solid lesion
  - Sharply hypodense star- shaped scar 33%
  - Large size may reach 4kg

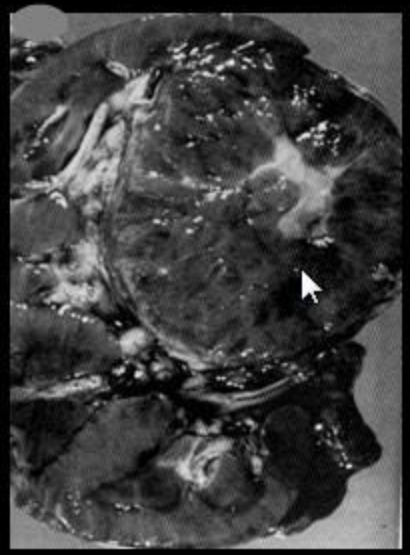





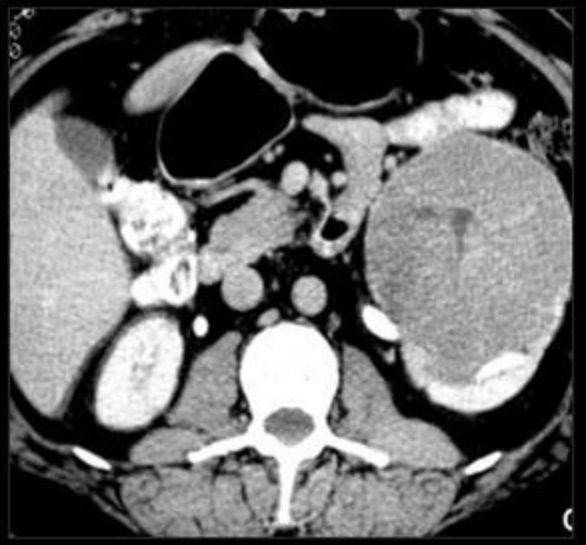

Fat containing Renal masses

- Angiomyolipoma
- Simple lipoma
- Teratoma
- Liposarcoma
- Xanthogranulomatous pyelonephritis



Renal Infection

- Renal and perirenal abscess
- Renal tuberculosis
- Emphysematous pyelonephritis
- Xanthogranulomatous pyelonephritis
- Renal hydatid cyst



Common manifestation in acute renal conditions

- Swollen kidney.
- Poor renal function.
- Dirty perinephric fat.
- Acute bilateral.
- Pylonephritis , CM enhancemened CT scan demonstrates patchy striated nephrograms

F 34Y



Pylonephritis , CM enhancemened CT scan demonstrates patchy striated nephrograms

Renal abscess



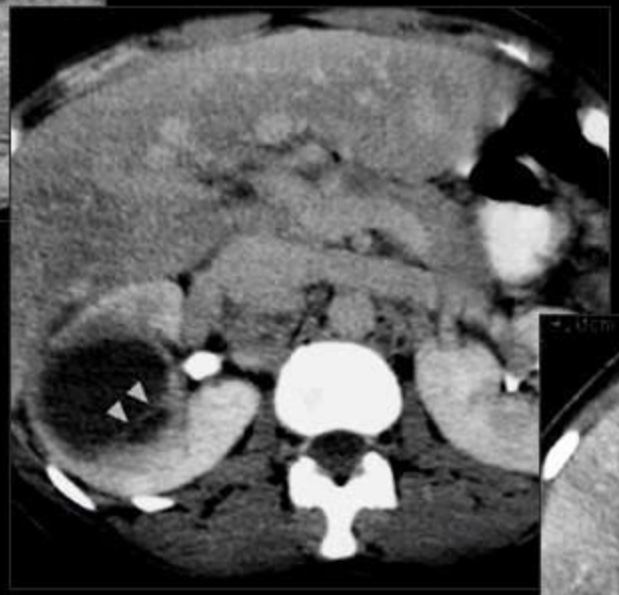

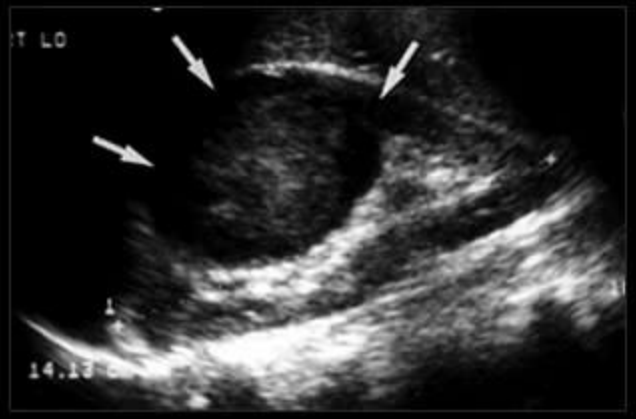

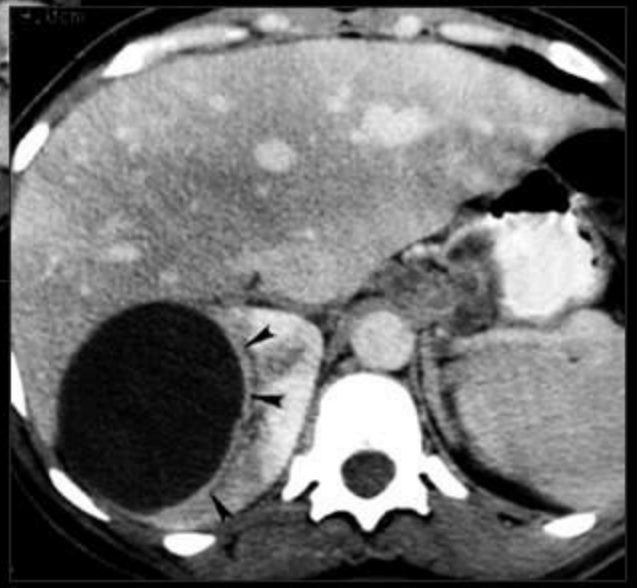

Renal hydatid cyst



F 62Y

Renal hydatid cyst



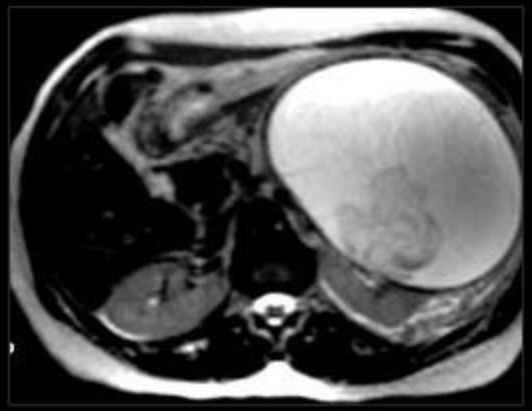

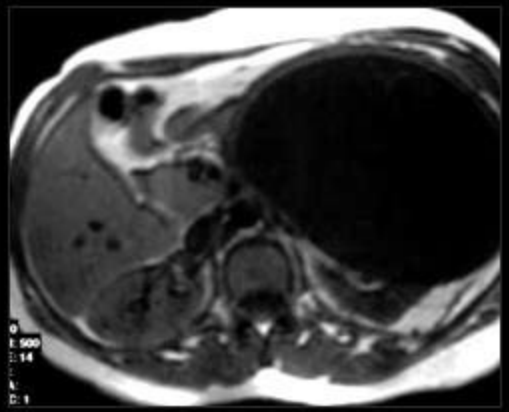



Patient with renal colic

Start by PUT & US

Inconclusive

CT urinary tract

Site & size of calculi

Back pressure effects

IVU to look for renal function

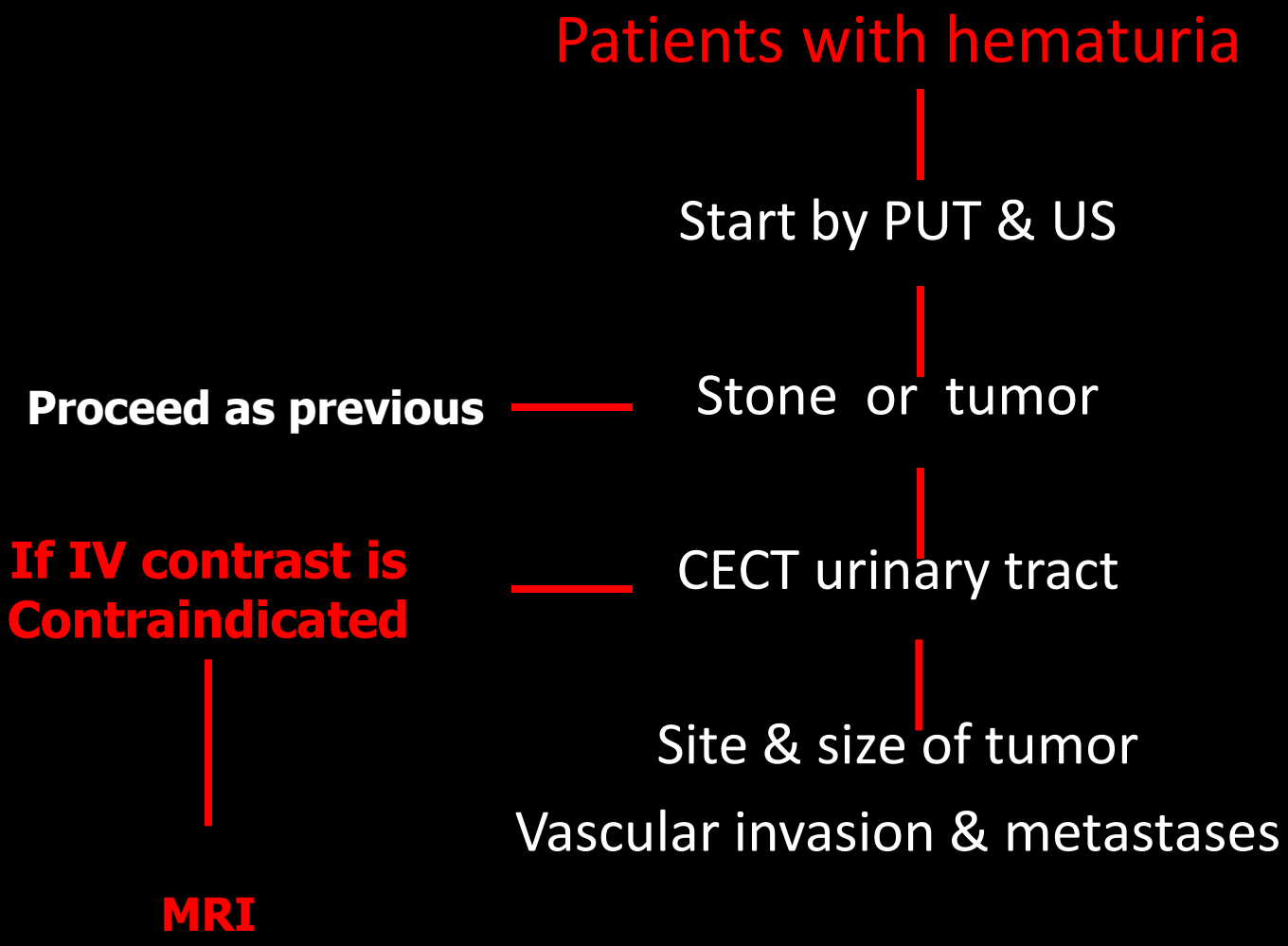
Patients with hematuria
Start by PUT & US
Stone or tumor
Proceed as previous
CECT urinary tract
If IV contrast is Contraindicated
Site & size of tumor
Vascular invasion & metastases
MRI

استراحة

