Common Carotid Artery:

Origin: Rt: Brachiocephalic artery, Lt: Aortic arch [has no branches]

Surface marking: Sternoclavicular joint; Tubercle of lateral process of C6 (chassaignac's tubercle)

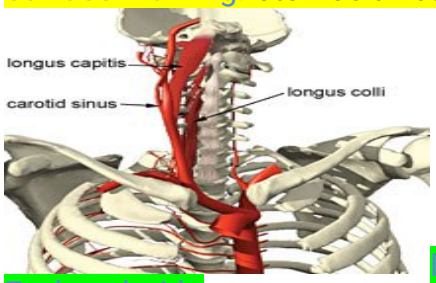

Bifurcation level: Greater cornu of the hyoid

Enclosed with

Carotid sheath which contains also vagus nerve & internal jugular vein

Internal Jugular vein is located lateral & posterior to the carotid artery

Vagus Nerve: in between

Covered by: Sternocledomastoid muscle; Infrahyoid muscles

Relation:

Anteriomedially: Thyroid gland; Larynx; Trachea; Inferior constrictor muscle

Posteriorly: Longus colli & capitus, Cervical sympathetic trunk, Anterior tubercle of C4-7 vertebrae, Veterbral artery

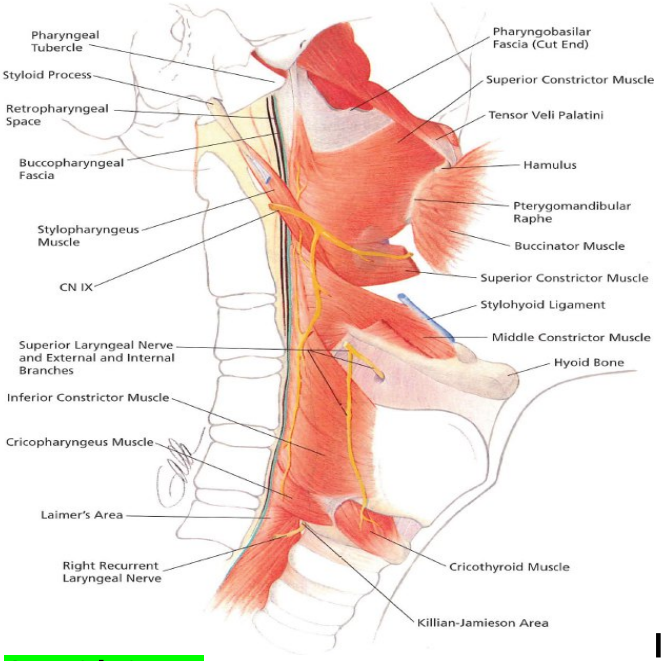

Internal and External Carotid artery:

Carotid sinus:

Dilation at point of division the vessels

may be confined to origin of **internal** carotid artery

histologically, the media is thinner & adventitia thicker

stretch receptors are innervated by **glossopharyngeal nerve** and they are the main baroreceptors

Carotid Body

located **deep** to the bifurcation

reddish-brown in color, measures 6*3mm

features glomus cells containing dopamine

innervated by **glossopharyngeal nerve**

Internal Carotid artery

The internal carotid artery enters the skull base:

Medial to: Glenoid fossa, Styloid process, Stylomastoid foramen

Posterior to: Sphenoid sinus

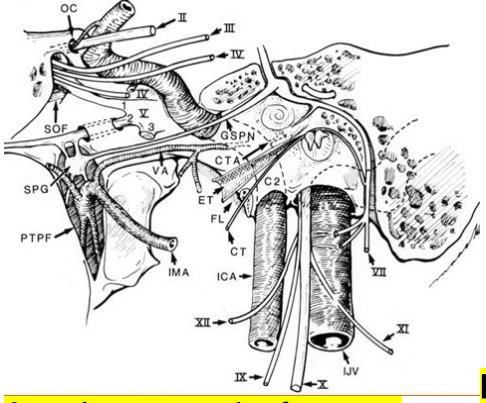

Posteriomedial to: Eustachian tube

Anterior to: jugular foramen

becomes encased in the petrous portion of the temporal bone, positioned:

Posterior to the ET & sphenoid spine

Medial to Glenoid fossa

Anterior to styloid process

The **spine** of the sphenoid bone is the **most** consistent and **reliable** extracranial landmark for locating **ICA** where it enters the petrous portion of the temporal bone

Vertical segment: anterior to the hypotympanum, Gives caritotympanic branches to the middle ear cavity

Horizontal segment

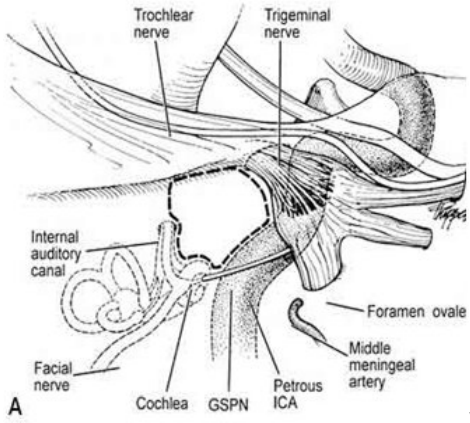

when it passes medially to the osseous eustachian tube then artery bends in an anteromedial direction to form the horizontal segment.

It runs under the gasserian ganglion and separated from it by thin bony plate

It is not uncommon for the osseous eustachian tube to be dehiscent where it is in contact with the internal carotid artery.

The GSPN is the most reliable intracranial landmark for the petrous portion of the internal carotid artery

The course of the GSPN is directly above and in the same direction as the horizontal portion of the petrous portion of the internal carotid artery.

2nd Vertical segment:

turns vertically across the foramen lacerum to pass alongside the lateral wall of the sphenoidal sinus & medial wall of the cavernous sinus.

The impression of the internal carotid artery within the lateral wall of the sinus usually can be seen with endoscopy.

The internal carotid artery traverses the cavernous venous sinus just before entering the intracranial space

Branches of external carotid artery

External carotid branches in sequence: [SALFO PIS]

1. Superior thyroid a
2. Ascending pharyngeal a
3. Lingual a
4. Facial a
5. Occipital a

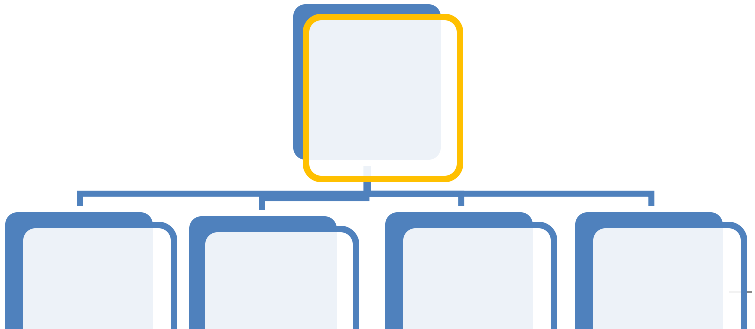

6. Posterior auricular a
7. Internal Maxillary a
8. Superficial temporal a

1-5 branches in the carotid triangle
the terminal branch of carotid artery at the level of mandibular condyle branch into mandibular & temporal

Superior thyroid

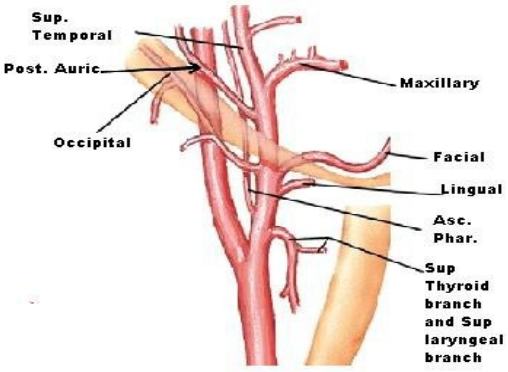

Located in the **muscular** triangle + **carotid** triangle
Supplies the area between the **thyroid** and **hyoid** bone
Arise **below** the hyoid bone



Ascending pharyngeal

The ascending pharyngeal artery is the **smallest** branch given off from the external carotid artery.
It arises from the **back** part of that artery about one-half of an inch above the bifurcation of the common carotid artery.
It ascends between the internal carotid artery and the side of the pharynx and beneath the stylopharyngeus muscle and the glossopharyngeal nerve to the **base** of the skull.
They also **communicate** through canals with the **ascending palatine artery** from the anterior facial arteries off of the external carotid
It is divided into:

Pharyngeal trunk (**extracranial**):
- Superior pharyngeal artery
- Middle pharyngeal artery
- Inferior pharyngeal artery
- Eustachian tube artery

Inferior tympanic artery (via inferior ty

Neurocranial trunk (**Intracranial**):
- Cival branch
- Jugular branch (via dorello's canal):
- Hypoglossal branch (via hypoglossa

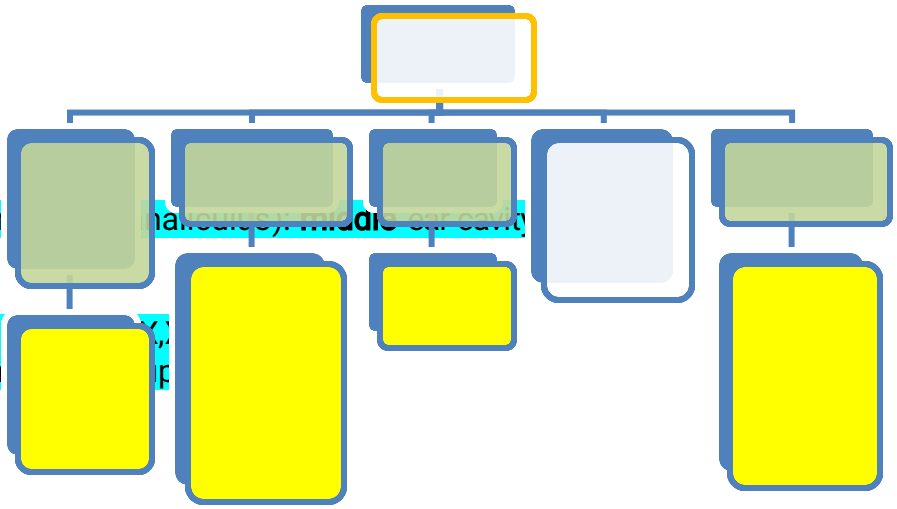

Lingual artery

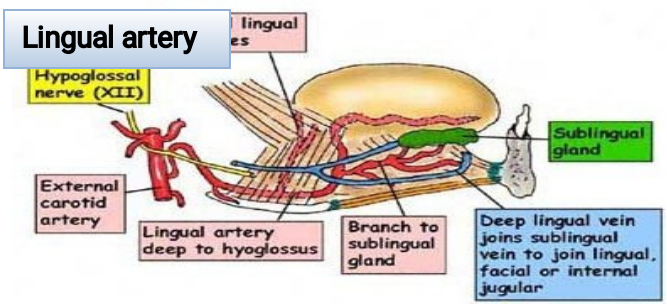

The lingual artery arises from the external carotid artery opposite the tip of the **greater cornu** of the hyoid bone.

1st part of the artery:

lies in the **carotid triangle**

Superficial to the middle constrictor of the pharynx.

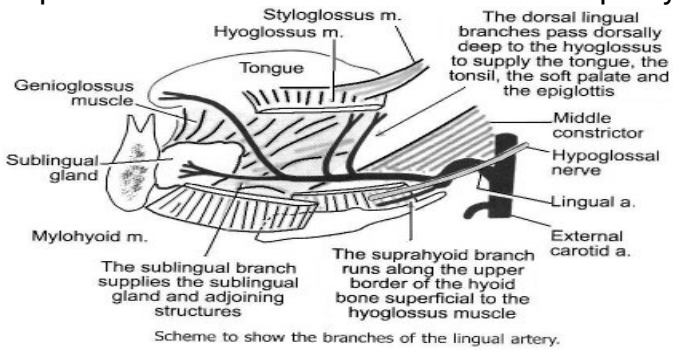

Scheme to show the branches of the lingual artery.

It forms a characteristic **upward** loop which is crossed by the hypoglossal nerve.

The lingual loop permits free movements of the hyoid.

2nd part of the artery:

lies between the **hyoglossus muscle** & **middle constrictor**

hypoglossus muscle which separates it from the hypoglossal nerve.

Dorsalis branch arise from this part

3rd/deep part/arteria profunda linguae:

run upwards along the **anterior** margin of the hyoglossus;

Forward to the tip of the tongue.

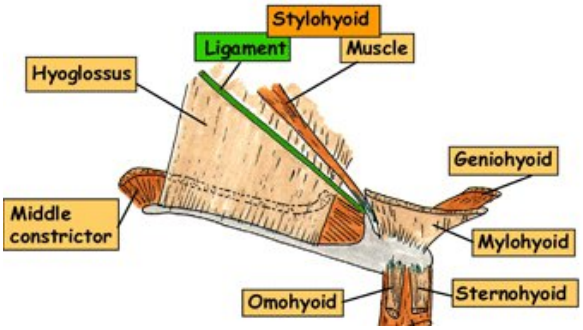

Lies between the genioglossus muscle & **mylohyoid** muscle.

Branches: deep lingual + sublingual artery

So middle constrictor+ genioglossus are **deep** to the lingual artery

Hypoglossus + mylohyoid are **superficial** to the lingual artery

Glossopharyngeal nerve lies **medial** to the **lingual artery**

Note that the lingual nerve is deep to the hypoglossal nerve

Terminal branch of the lingual artery is the deep lingual artery

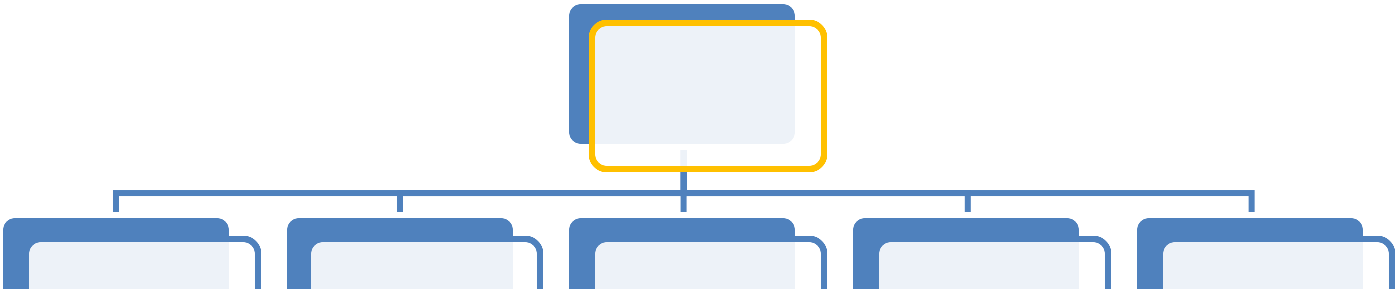

Facial artery

Pathway of the facial artery

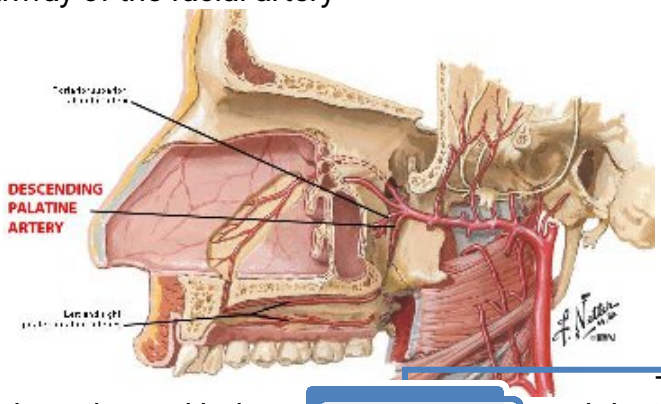

The external carotid: medial t ... ible: over the submandibular s ... ound the inferior border of the mandibl ... l side: anterior to the masse ... s upward medially along the lateral sid ... terminates at the medial cantilus of the eye

Re ... ns

As ... artery

I branch of the facial artery

... gap betwe ... e ... c

... tyloglossu

... perior cons

Lies superficial to the stylogossus muscle

Occipital

al artery arises from the external carotid artery **opposite** the facial artery

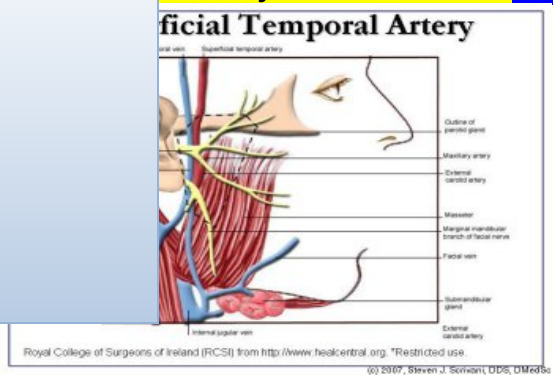

It is covered by the posterior belly of the Digastricus and the Stylohyoideus, and the hypoglossal nerve winds around it from behind forward

Branches

Sternocleidomastoid branches
Auricular branch
Mastoid branch
Descending branches
Occipital branches

Posterior Auricular

The **posterior auricular artery** arises from the external carotid artery, **above** the Digastric muscle and Stylohyoid muscle, **opposite** the **apex** of the styloid process
The posterior auricular artery supplies blood to the scalp **posterior to the auricle** and to the auricle **itself.**
Branches: stylomastoid branch which becomes the **posterior tympanic artery** which gives **2 branches:**
1- **stapedius branch**
2- **mastoid branch**

Superficial temporal

Its pulse is palpable superior to the zygomatic arch, **anterior** and **superior** to the tragus.

Internal maxillary artery

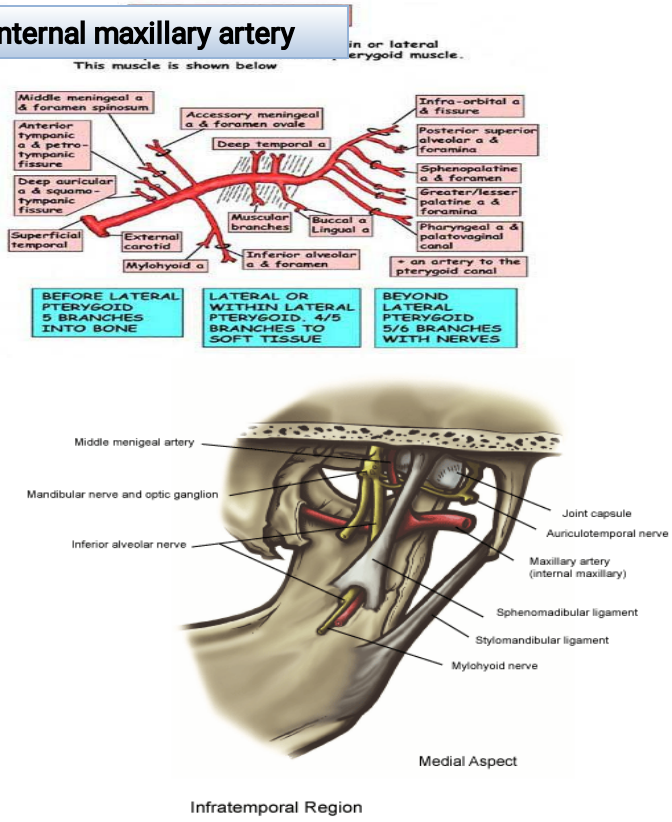

Infratemporal Region

It passes forward either lateral **or** medial to the pterygoid muscles
If it takes the medial course, the artery then turns laterally again to emerge between the 2 heads of the muscle
The artery is divided into **3** divisions by the **lateral pterygoid muscle** with 5 branches coming from each part:
Mandibular part: to bone
Pterygoid part: to soft tissue
Pterygopalatine part: with the nerves

The maxillary artery enters the Infratemporal fossa between the sphenomandibular* ligament & the neck of mandible inferior & parallel to Auriculotemporal branch
Then goes to the Pterygopalatine fossa via the Pterygomaxillary Fissure
* **Sphenomandibular ligament**: extends from the sphenoid **spine** to the **angle** of the mandible

Table 32.7 Branches of the maxillary artery

Part	Artery		Distribution
Mandibular part	① Inferior alveolar a.		Mandible, teeth, gingiva
	② Anterior tympanic a.		Tympanic cavity
	③ Deep auricular a.		Temporomandibular joint, external auditory canal
	④ Middle meningeal a.		Calvaria, dura, anterior and middle cranial fossae
Pterygoid part	⑤ Masseteric a.		Masseter muscle
	⑥ Deep temporal aa.		Temporalis muscle
	⑦ Pterygoid branches		Pterygoid muscles
	⑧ Buccal a.		Buccal mucosa
Pterygopalatine part	⑨ Descending palatine a.	Greater palatine a.	Hard palate
		Lesser palatine a.	Soft palate, palatine tonsil, pharyngeal wall
	⑩ Posterosuperior alveolar a.		Maxillary molars, maxillary sinus, gingiva
	⑪ Infraorbital a.		Maxillary alveoli
	⑫ A. of pterygoid canal		
	⑬ Sphenopalatine a.	Lateral posterior nasal aa.	Lateral wall of nasal cavity, choanae
		Posterior septal branches	Nasal septum

Copyrighted materi

The **1st** part of the maxillary artery gives off 5 branches to **bones**:

1. **Deep auricular a:** Supply the external auditory canal
2. **Anterior tympanic:** Supply the middle ear cavity
3. **Middle Meningeal a:**
   Passes between the sphenomandibular ligament & lateral pterygoid muscle
   Between the **2 roots** of Auriculotemporal nerve
   Give branch to:
   1- superior tympanic artery which goes with lesser petrosal nerve through superior tympanic canaliculus
   2- superficial petrosal a which goes with greater petrosal N through the facial hiatus
1. **Inferior alveolar artery :**
   Passes down 2 join the inferior alveolar nerve 2 enter the Mandibular foramen
   Give mylohyoid artery before the entry into the Mandibular foramen
1. **Accessory Meningeal a**

The **2nd** part of the maxillary artery gives off **5** branches to the **soft tissue (muscles of mastication)**:

1. **Anterior Deep** Temporalis muscle: run deep to the Temporalis fascia and superficial to the skull
2. **Posterior Deep** Temporalis muscle
3. **Masseteric** : masseter muscles
4. **Lateral & medial pterygoid muscles**
5. **Buccal artery & lingual artery**

The **3rd** part of the artery:
Moves through the **Pterygomaxillary fissure** from the Infratemporal fossa into the Pterygopalatine fossa

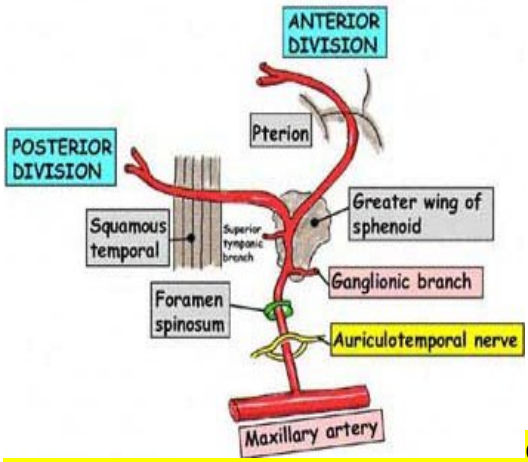

gives the 5 branches within the Pterygopalatine fossa **except** the **superior posterior alveolar branch** which branch in the Infratemporal fossa

branches **go with Nerves**

1. **Posterior superior alveolar artery:**
   - The only branch that does not divide in the Pterygopalatine fossa
   - Goes through the posterior superior alveolar foramen
   - Give supply to : gum, molar, premolar, maxillary sinus
1. **Infra-orbital artery:**
   - **terminal** branch of the maxillary artery
   - Goes through the infratemporal **fissure**
   - supply the floor of the orbit & lateral aspect of the nose
1. **Sphenopalatine artery**
   - goes through the sphenopalatine foramen
   - emerge in the nose posterior to the posterior end of the middle turbinate
   - gives intranasally the following branches:
     1) **posterior superior lateral nasal branches** : supply the posterior superior part of the **lateral** wall of the nasal cavity
     2) **posterior superior septal/medial branch**:
        - supply the posterior superior part of the **septum**
        - continues ant along the septum to enter the hard palate via incisive canal
1. **Descending palatine artery:**
   - go through the palatine canal
   - divide into Greater & lesser palatine artery and emerge from the greater & lesser palatine foramen
   a. 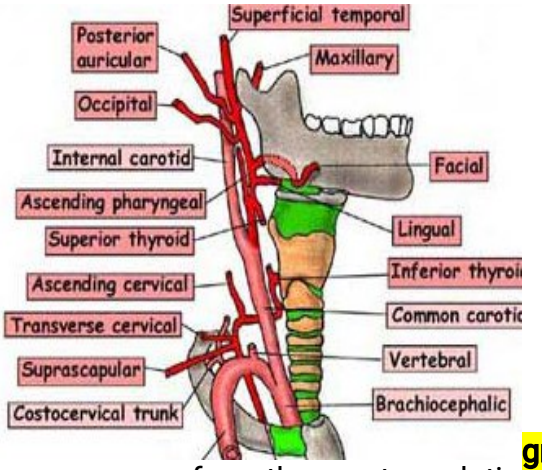

greater palatine artery:
      - emerge from the greater palatine artery
      - pass anterior to the incisive foramen
      - supply the hard palate gingival, mucosa, glands
      - anastamose with sphenopalatine artery at the incisive canal
   a. **lesser palatine artery supply:** soft palate, tonsil
1. **Vidian artery**
   - goes through the vidian/pterygoid **canal** to supply the vidian nerve

supply the auditory tube + sphenoid sinus

1. **Pharyngeal Artery**
   Goes through palatovaginal **Canal**
   Supply the auditory tube + **Nasopharynx**

Note:

The **maxillary artery** after it gives the **infra-orbital artery** & **posterior superior alveolar artery** is enters the **pterygomandibular fissure**
The name of the maxillary artery after it enters the pterygomandibular artery is **sphenoplatine** artery

Subclavian artery

Scalinus anterior muscle divides the **Subclavian artery** into **3** divisions
Each Subclavian artery:
enters the neck behind the sternoclavicular joint
ends by becoming the axillary artery
origin:
left side: aortic arch
right side: brachiocephalic trunk
branches:
First Part:
Vertebral artery
Thyrocervical trunk:
- Inferior thyroid artery
- Transverse cervical artery
- **Suprascapular** artery

Internal thoracic artery
Second Part:
Costocervical trunk
Dorsal scapular artery

Relations: From anterior to Posterior:
Subclavian **vein**: **anteroir** scalenous muscle: Subclavian **artery**: brachial **plexus**: **middle** scalenous muscle
Vagus nerve + Phrenic nerve lies between the **1st part of the Subclavian artery & Subclavian vein**
Phrenic nerve is then becomes **superficial to** scalenus **anterior**
The subclavian artery gives rise to the thyrocervical trunk. The transverse cervical and suprascapular arteries usually course **laterally** over the surface of the **phrenic** nerve. This relation allows identification of these structures

Vertebral Artery Triangle : an important triangle extending from the **root** of the neck
Borders:
scalenus **anterior** muscle

longus colli muscle
superior aspect of the 1st part of the subclavian artery
(Pre)Vertebral Fascia surrounds this area.

Contents of the triangle of the vertebral artery:
Vertebral artery (from the first division of the Subclavian artery) and vein ascend to the **apex** of triangle and enter the foramen transversarium of **C6**.