SMALL INTESTINE

Duodenum

- The duodenum is a C-shaped tube, about (25 cm) long, that joins the stomach to the jejunum.
- It is important because it receives the openings of the bile and pancreatic ducts.
- The duodenum curves around the head of the pancreas.

*Pancreatic and bile duct open posteromedial aspect of 2nd part of duodenum just below the middle.

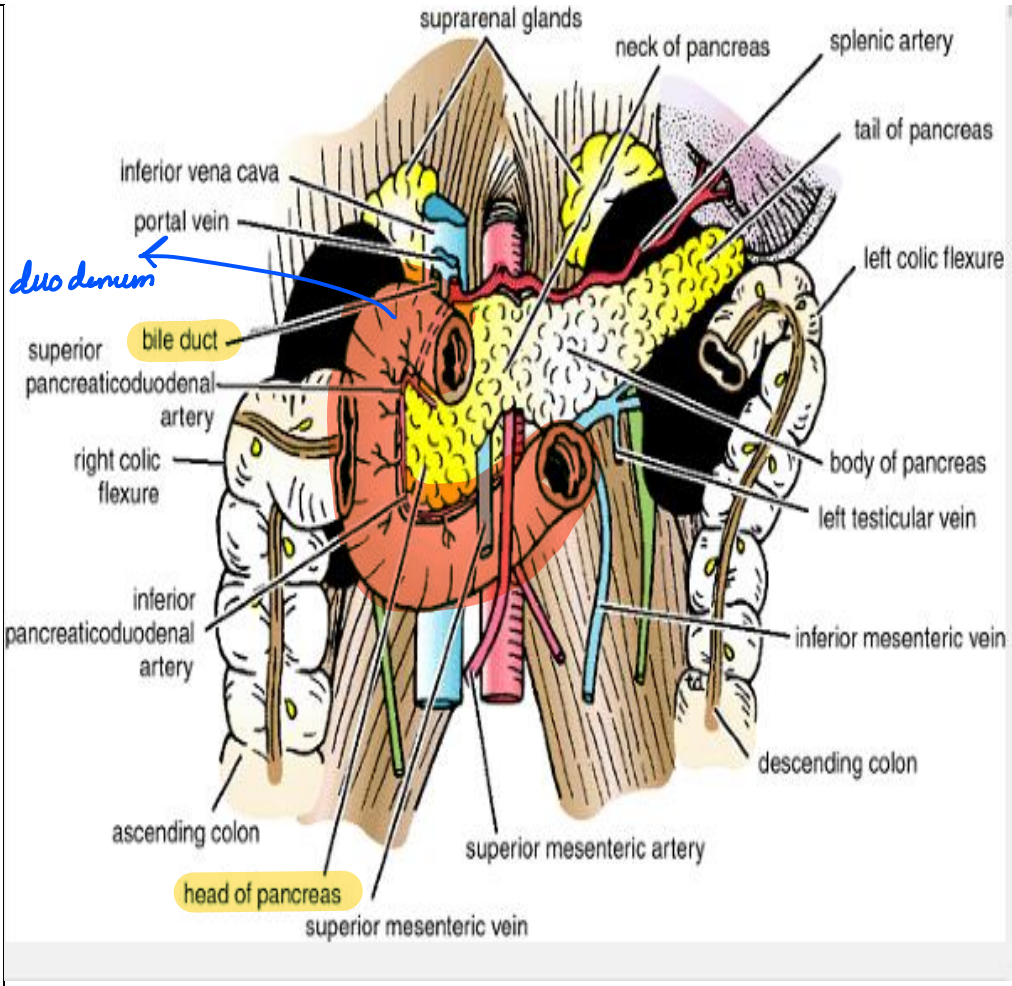

Duodenum

small intestine / stomach زي

- The first inch of the duodenum resembles the stomach in that it is ***Intraperitoneal*** covered on its anterior and posterior surfaces with peritoneum the lesser sac lies behind this short segment. ***Duodenal cap*** → 1st inch of duodenum

ورا peritoneum ولا تتحرك Fixed وتتعرض للـ trauma، أسهل من intraperitoneum ← لأنها بتتحرك ← تهرب

→ 9 inch

- The remainder of the duodenum is ***Retro-Peritoneal***, being only partially covered by peritoneum.

* Duodenum 4 parts:

1st → 2 inch
2nd → 3 inch
3rd → 4 inch
4th → 1 inch

→ * usually duodenal ulcer lies in the 1st inch of the 1st part of duodenum
↓
duodenal cap

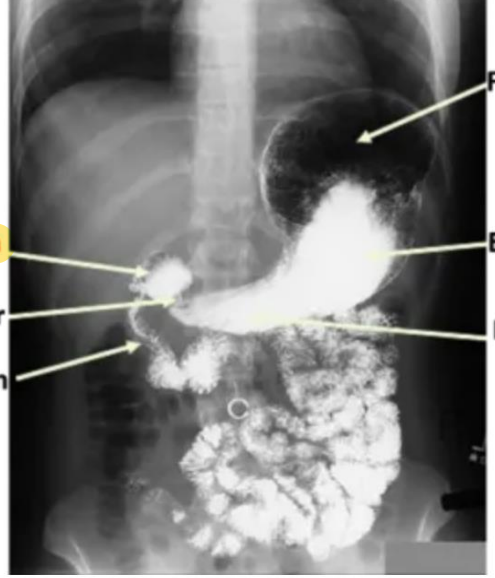

زمان كانوا من صورة الأشعة
هاد يطلعوا على
duodenal cap

لو شكلها زي cap
↓
يعني normal
مش ulcer

لو شكلها deformed
مش زي cap
↓
يعني فيها ulcer

* ولكن الآن بطلوا يعتمدوا
صورة الصبغة ويعملوا
Gastroscope.

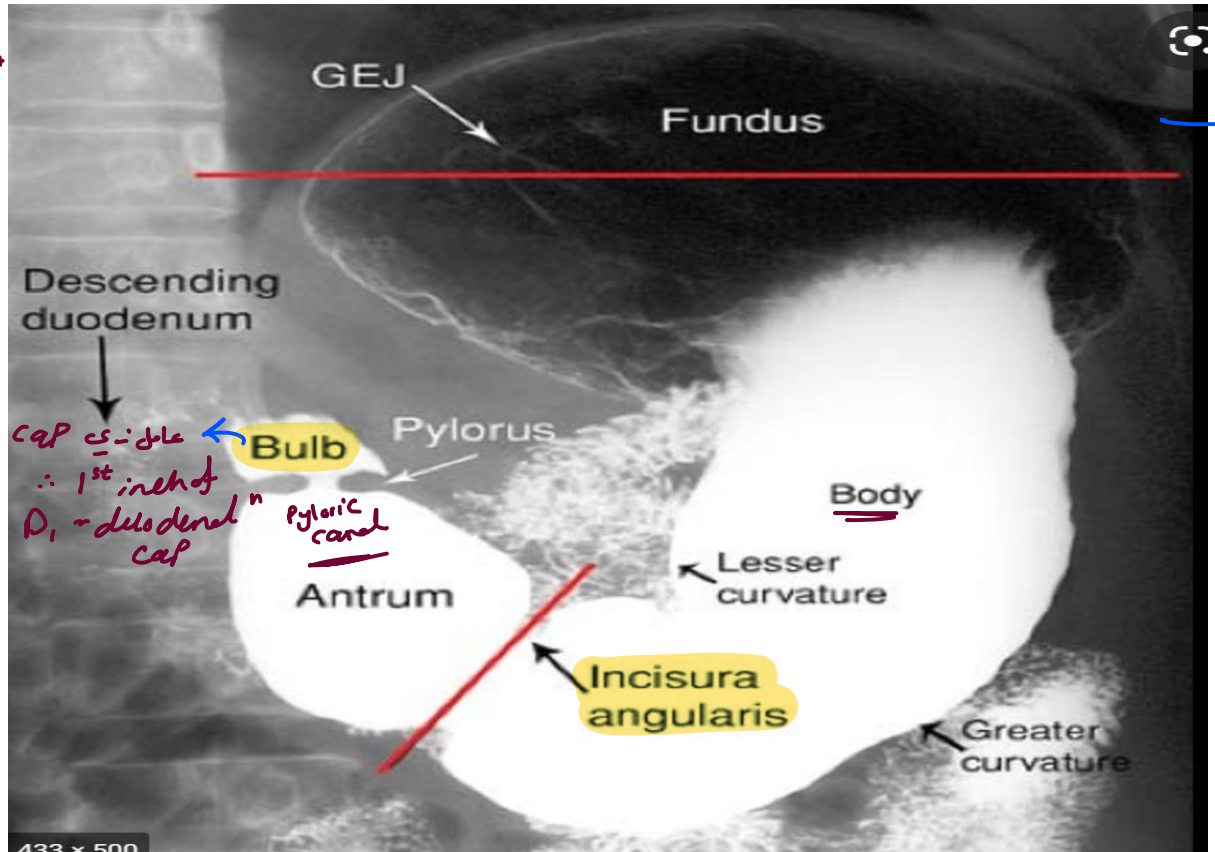

عامل زي cap
∴ 1st inch of
D_1 = duodenal cap

صبغة في Stomach

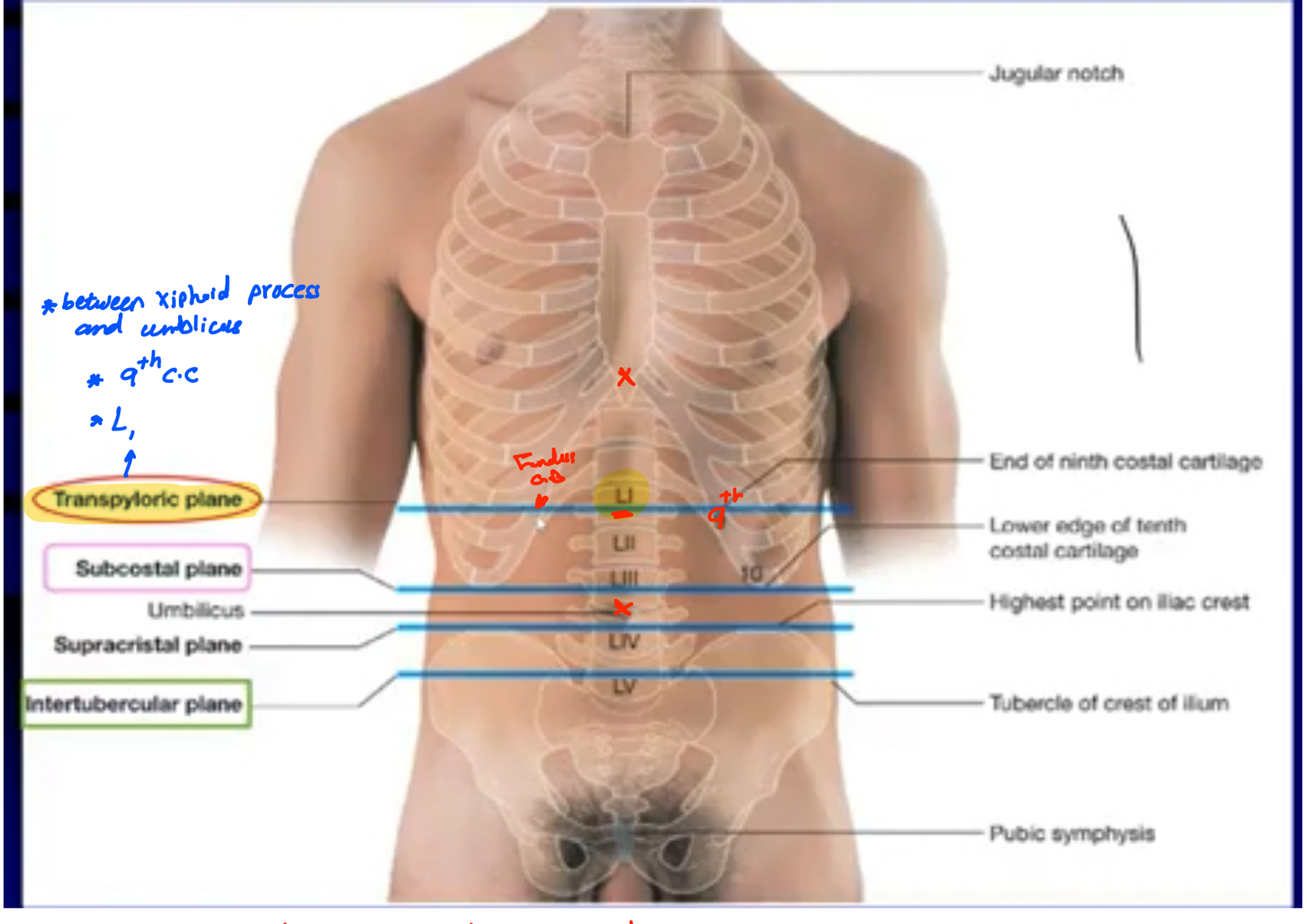

* between xiphoid process and umbilicus
* 9th c.c
* L_1

* structures lies in Transpyloric plane:

1. Fundus of gall bladder
2. Pylorus
3. junction between D_1. D_2.

Parts of the Duodenum

- **The Duodenum is situated in the Epigastric and Umbilical regions and, for purposes of description, is divided into four parts.**

First Part of the Duodenum

- **The first part of the duodenum is *(2 inch)* long and begins at the pylorus and runs upward and backward on the right side of the L1.**
- **It thus lies on the Trans-Pyloric plane L1.**

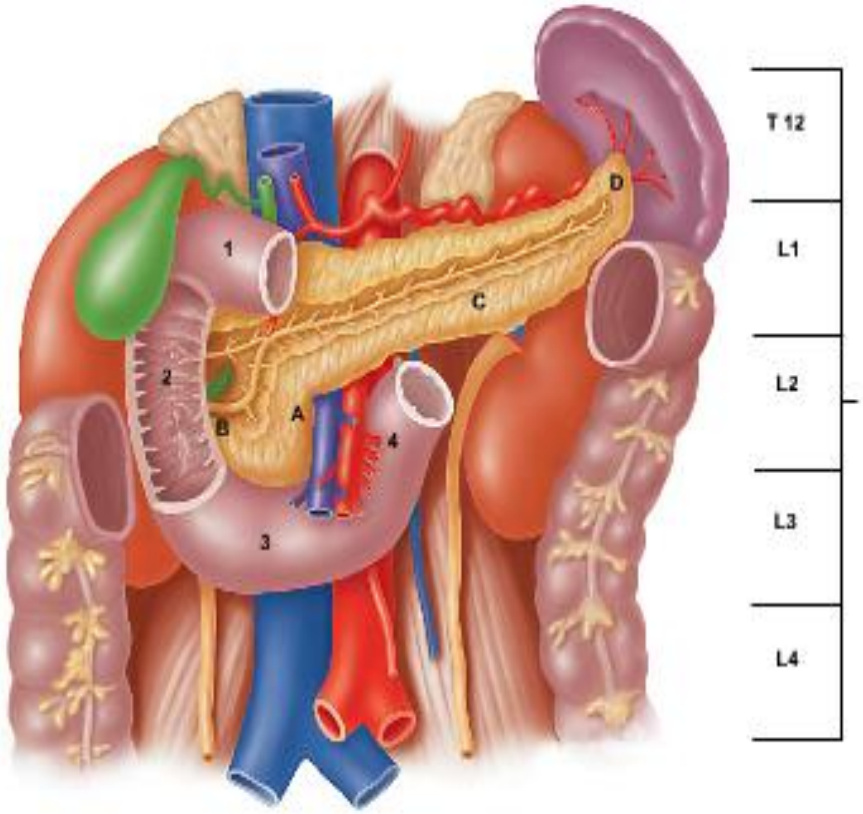

Parts of the Duodenum

The *relations* of the first part are:

- ***Anteriorly:*** The quadrate lobe of the liver and the ***Gall Bladder.***
- ***Posteriorly:*** The lesser sac (first inch only), the gastro duodenal artery, the bile duct and portal vein, and the inferior vena cava. + Rt. kidney
- ***Superiorly:*** The entrance into the lesser sac (the Epiploic Foramen). Winslow Foramen
- ***Inferiorly:*** The head of the pancreas.

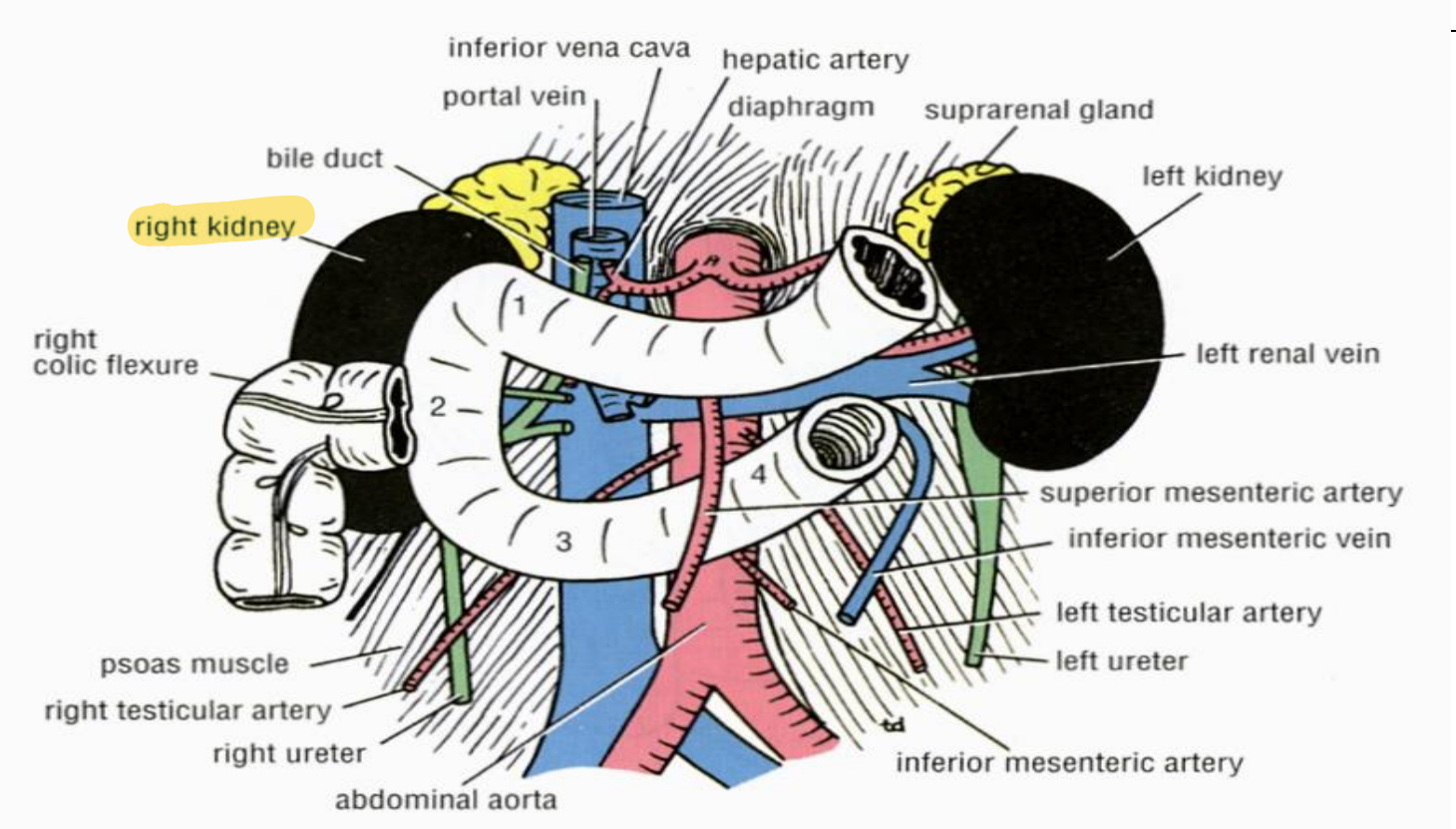

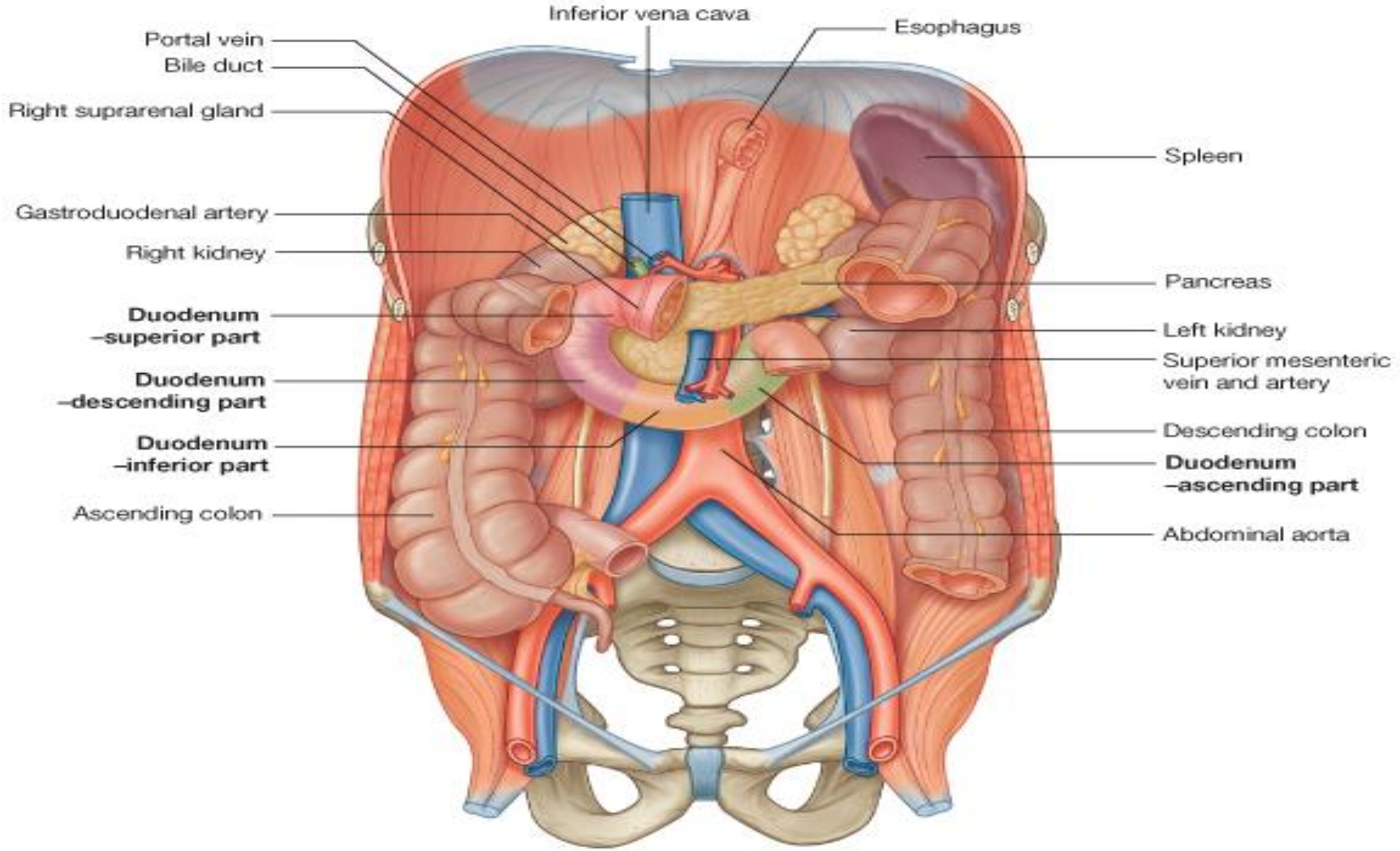
Inferior vena cava
Esophagus
Portal vein
Bile duct
Right suprarenal gland
Spleen
Gastroduodenal artery
Right kidney
Pancreas
Duodenum –superior part
Left kidney
Superior mesenteric vein and artery
Duodenum –descending part
Descending colon
Duodenum –inferior part
Duodenum –ascending part
Ascending colon
Abdominal aorta

Relations of 1st Part of Duodenum

Anterior: Liver, Gall bladder

Posterior: Bile duct, Portal vein
Gastroduodenal artery
Behind all these IVC

* بالتالي القرحة لو كانت من ورا وعملت erosion متضغط على gastroduodenal artery ، بصير sever bleeding.

* سؤال مشهور بالجراحة
لو شخص بنتقدم عنده قرحة في الاثنى عشر ماصو Seroded artery
gastroduodenal artery

Relations of 2nd Part of Duodenum

Anterior: Liver, Transverse colon, Coils of jejunum

Posterior: Right kidney, Inferior vena cava
Right psoas major

* branch of common hepatic artery

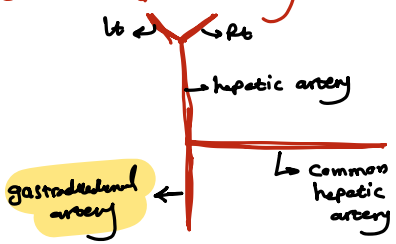

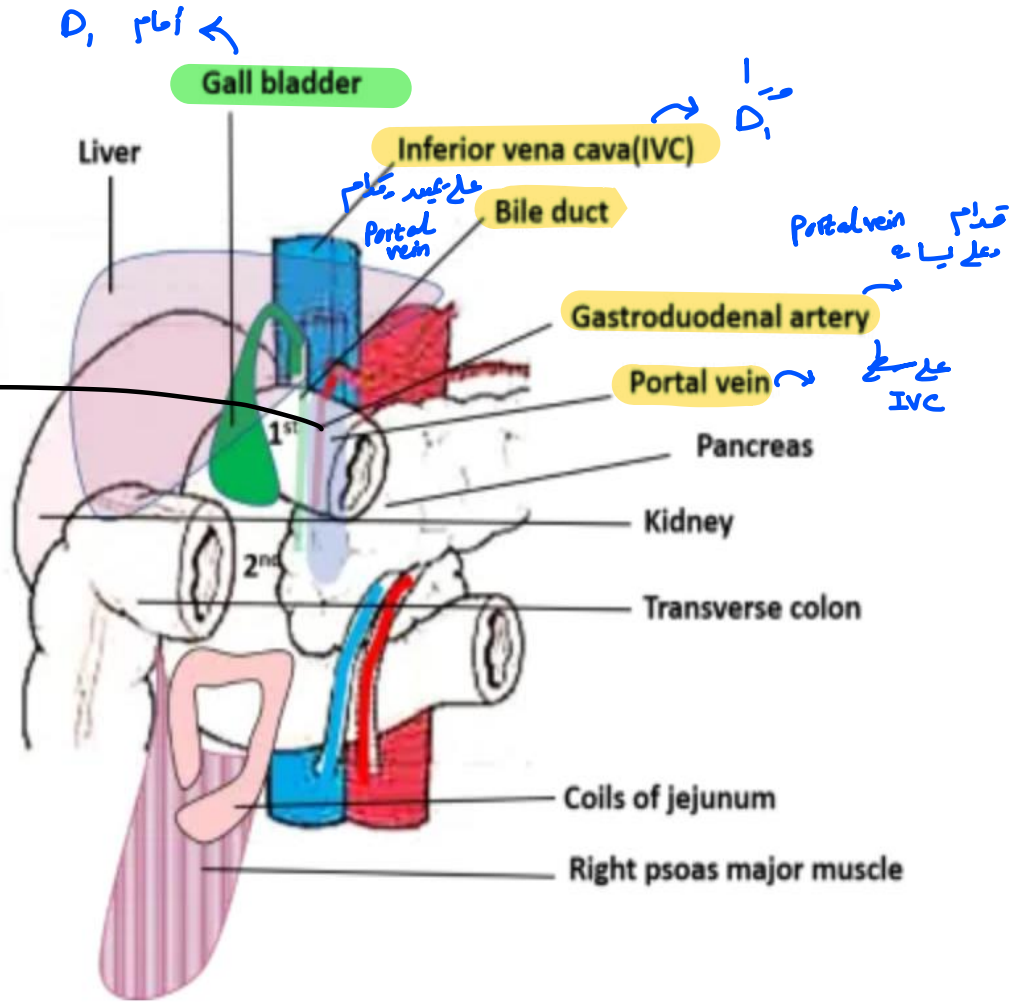

Parts of the Duodenum

Second Part of the Duodenum

* lies in c. curved duodenum

- The second part o the duodenum is 3 inch long and runs vertically downward in front of the hilum of the right kidney on the right side of the L2,3.
- About halfway down its medial border, the bile duct and the main pancreatic duct pierce the duodenal wall.

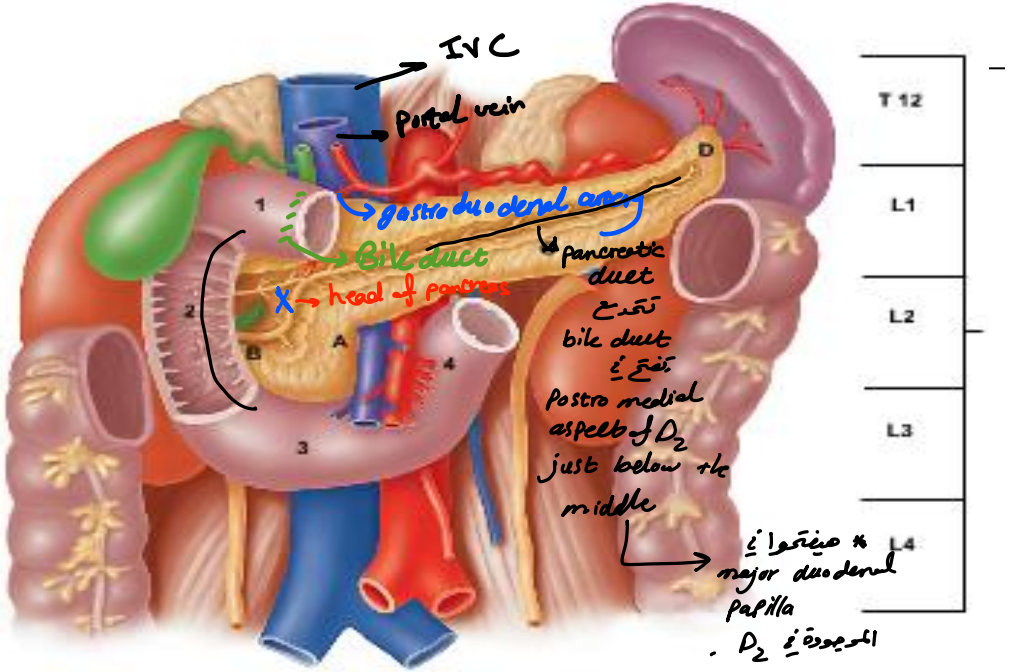

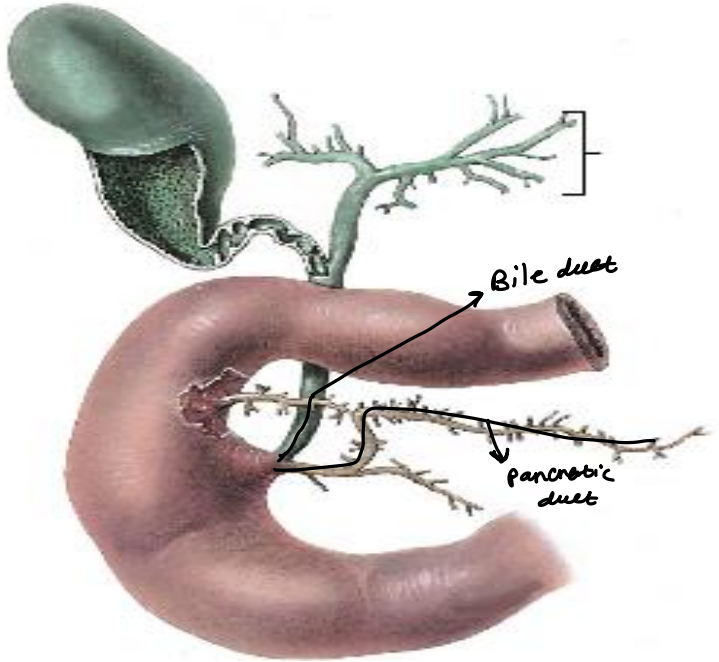

Parts of the Duodenum

- **They unite to form the ampulla that opens on the summit of the major duodenal papilla.**
- ***The Accessory Pancreatic Duct of Santorini*, if present, opens into the duodenum a 1 cm higher up on the minor duodenal papilla.** or above the main pancreatic duct.

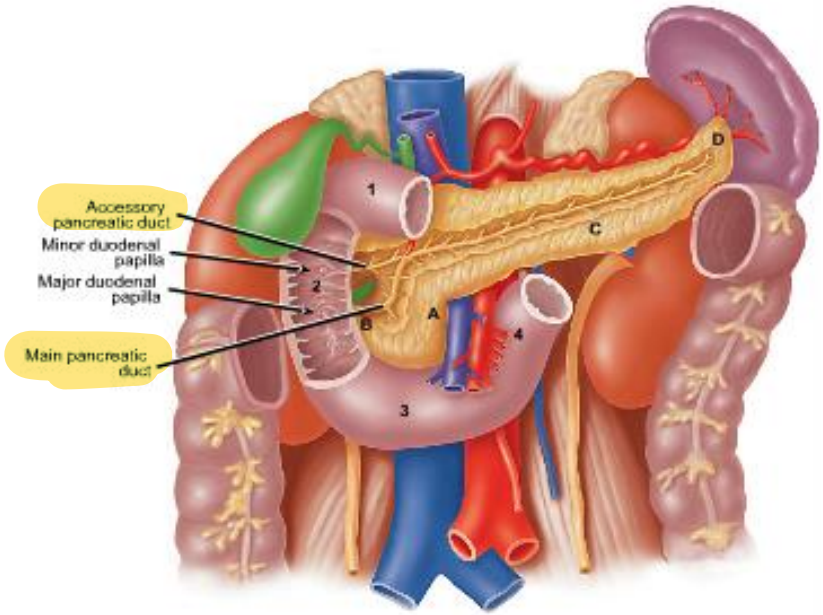

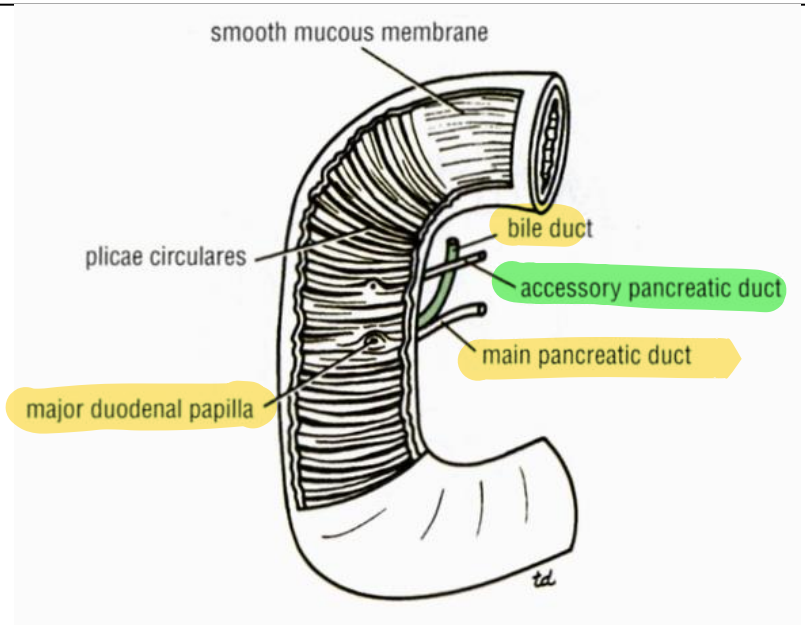

* pancreatic duct ماشية من tail لتحت في body , neck , عرضها (1 mm)
لكن في head بتنزل لتحت , عرضها (3 mm)

* pancreatic duct very Fine duct

* لذلك زمان كانوا يفكروا pancreas مصمت (نش فيه duct)
لأن عرضها 1mm

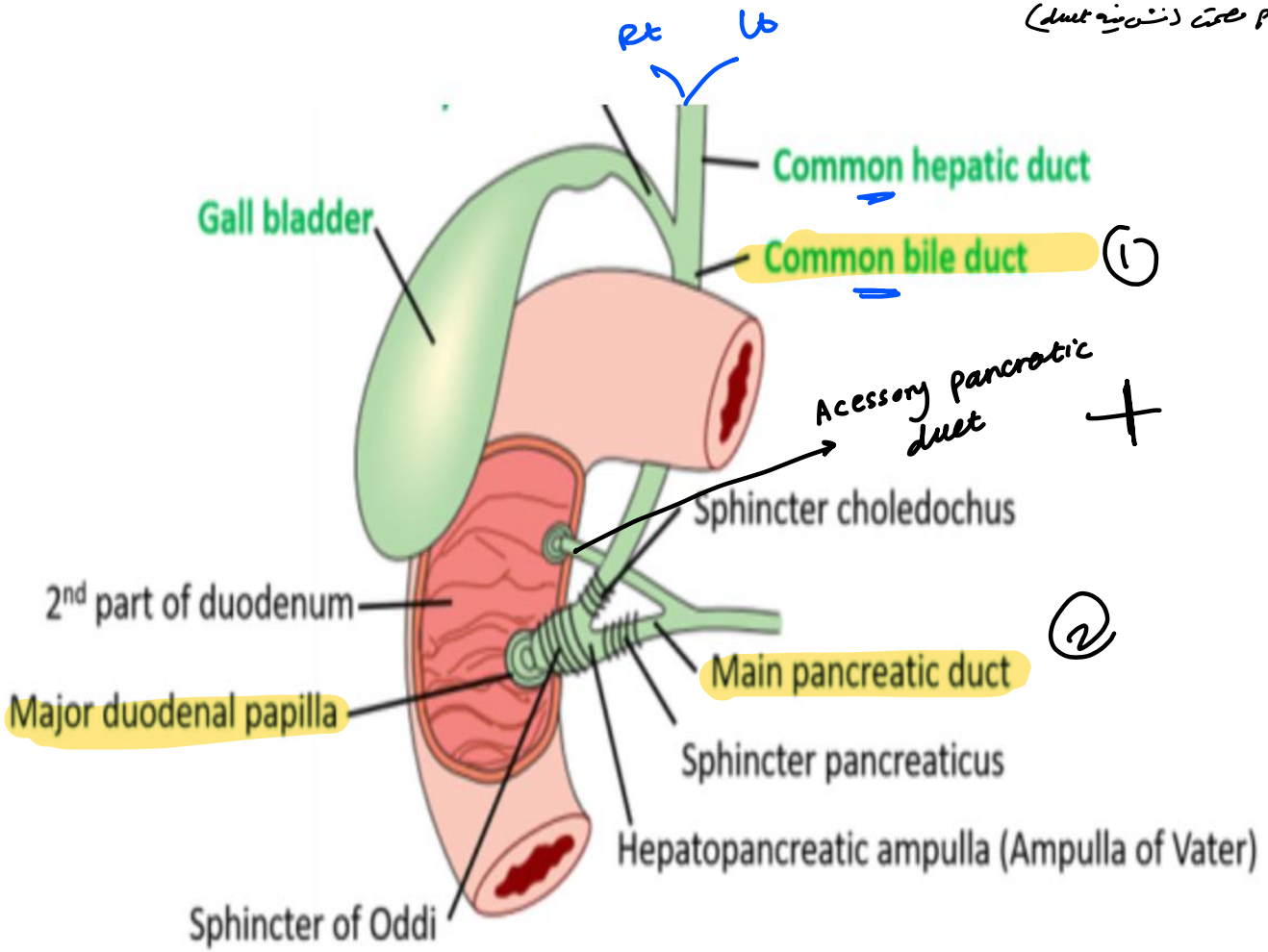

Parts of the Duodenum

The *relations* of the second part are:

- ***Anteriorly:*** **The fundus of the gallbladder and the right lobe of the liver, the transverse colon, and the coils of the small intestine.**
- ***Posteriorly:*** **The hilum of the right kidney and the right ureter.**
- ***Laterally:*** **The ascending colon, the right colic flexure, and the right lobe of the liver.**
- ***Medially:*** **The head of the pancreas, the bile duct, and the main pancreatic duct.**

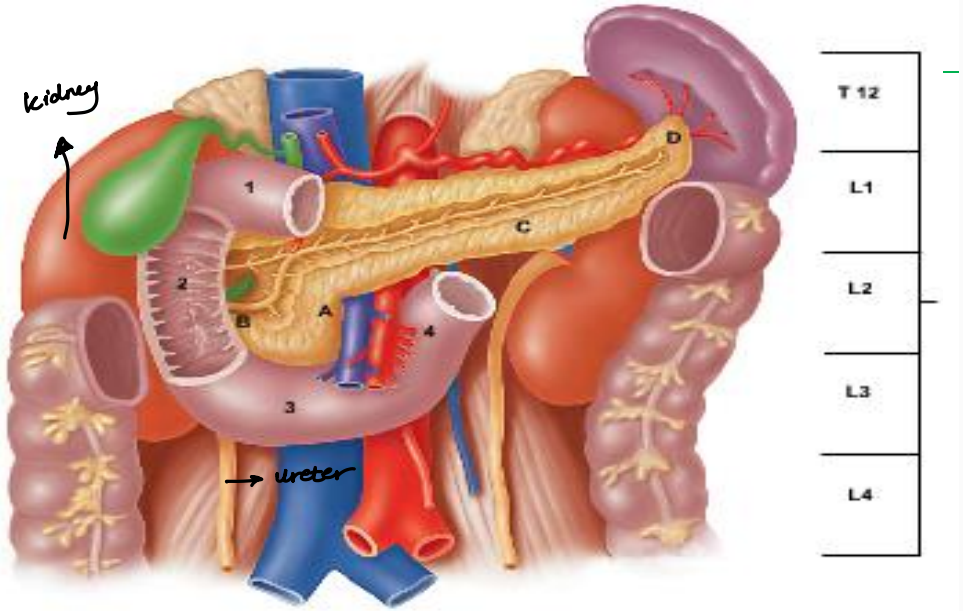

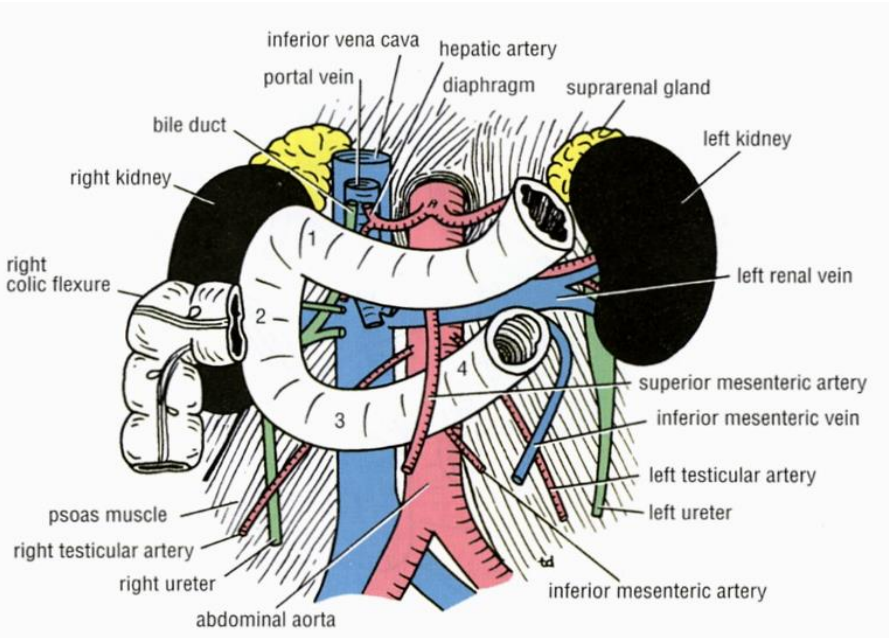

Parts of the Duodenum

Third Part of the Duodenum ⟹ L_3

ماشي بالعرض

- **The third part of the duodenum is *(4 inch)* long and runs horizontally to the left on the Subcostal plane, passing in front of the vertebral column and following the lower margin of the head of the pancreas.**

inf. mesenteric vein → lt side of inf. mesenteric artery
sup. mesenteric vein → Rt. side of sup. mesenteric artery

D_3 → قدامه → sup. mesenteric artery.
D_3 → وراه → inf. " "

* مش مهم كثير زي D_1, D_2 بقطع horizontally
① Rt ureter
② Rt. psoas muscle
③ IVC
④ Aorta

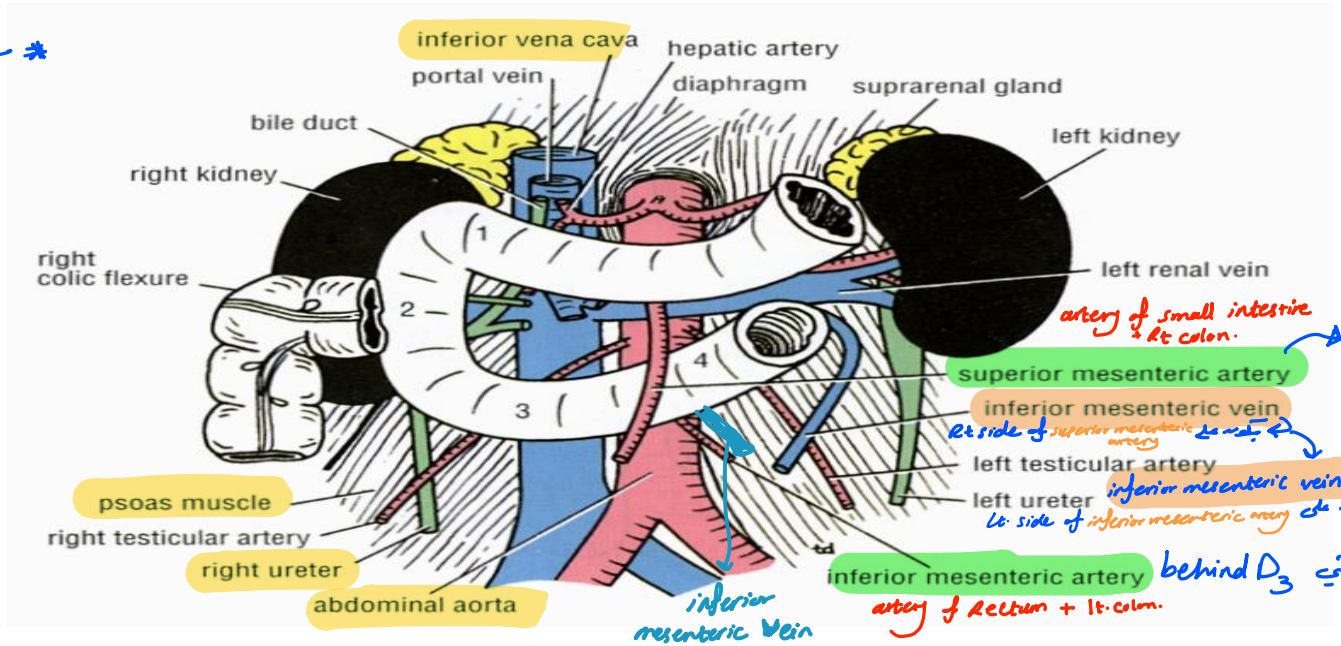

artery of small intestine + Rt colon.
infront of D_3 * بمشي
Rt side of superior mesenteric artery بكون على
inferior mesenteric vein تكتب
Lt. side of inferior mesenteric artery بكون على
inferior mesenteric vein
behind D_3 * بمشي
artery of Rectum + lt. colon.

Parts of the Duodenum

The *relations* of this part are:

- ***Anteriorly:*** **The root of the mesentery of the small intestine, the superior mesenteric vessels contained within it, and coils of jejunum.**
- ***Posteriorly:*** **The right ureter, the right psoas muscle, the inferior vena cava, and the aorta , IMA.**
- ***Superiorly:*** **The head of the pancreas.**
- ***inferiorly:*** **Coils of jejunum.** small intestine

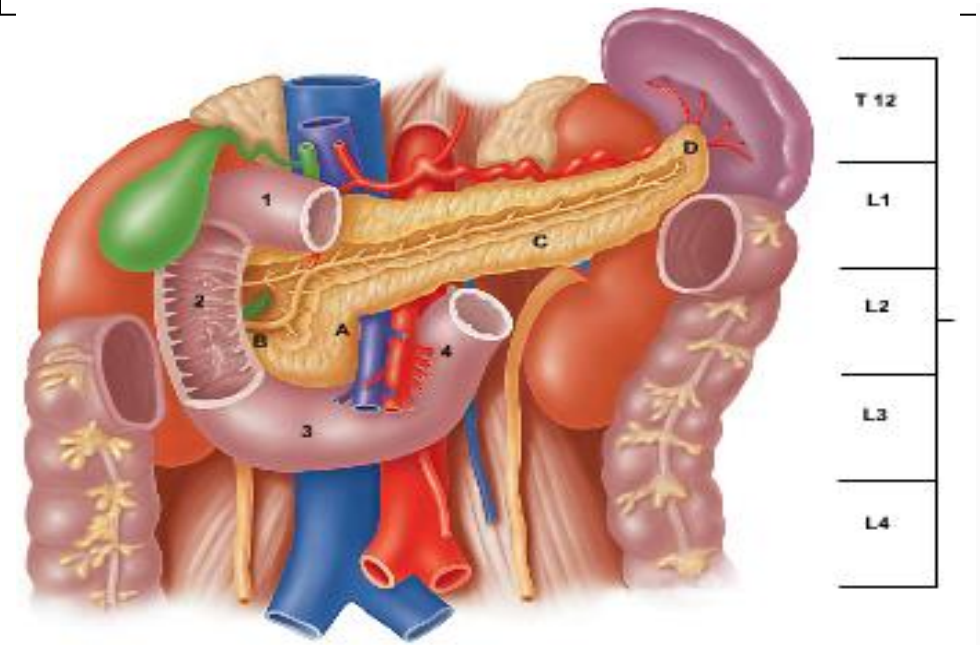

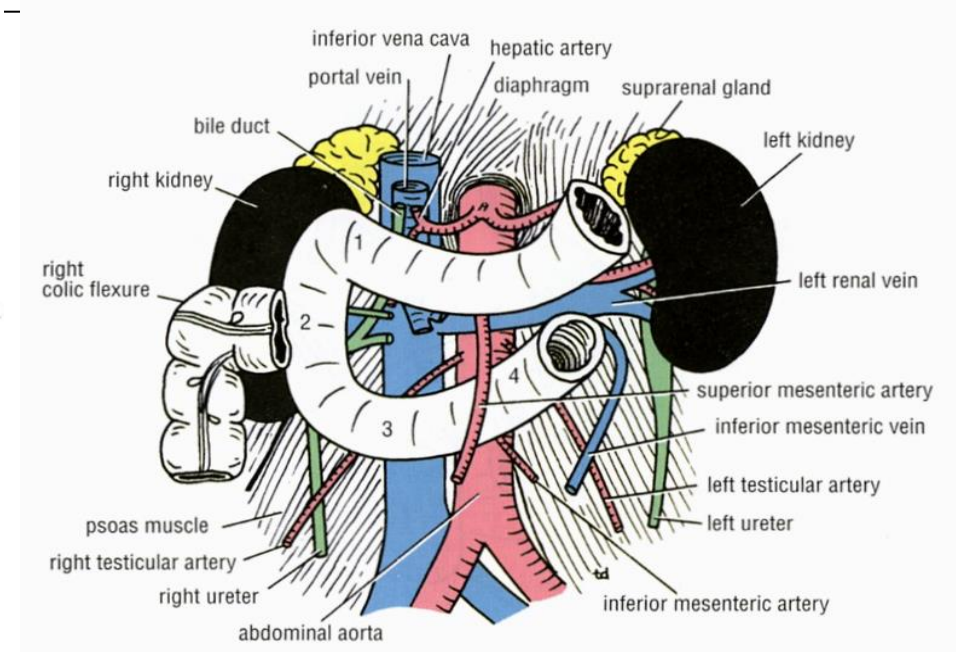

Parts of the Duodenum

Fourth Part of the Duodenum

- The fourth part of the duodenum is 1 inch. long and runs upward and to the left to the duodenojejunal flexure.
- The flexure is held in position by a peritoneal fold, the ligament of Treitz, which is attached to the right crus of the diaphragm.

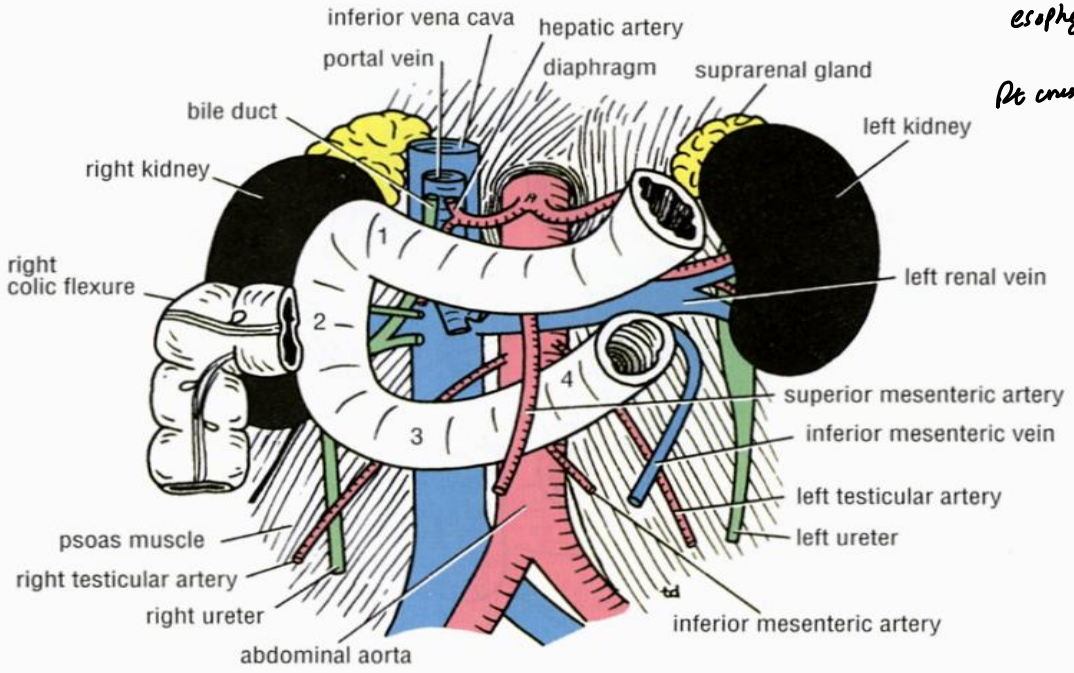

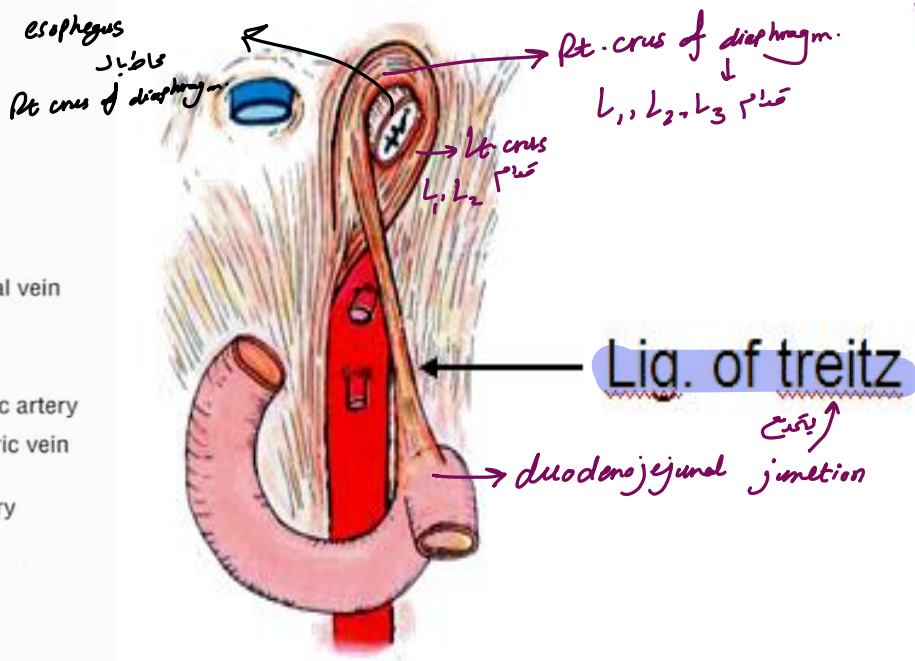

Parts of the Duodenum

The *relations* of this part are:

- **Anteriorly: The beginning of the root of the mesentery and coils of jejunum.**
- **Posteriorly: The left margin of the aorta and the medial border of lie left psoas muscle.**

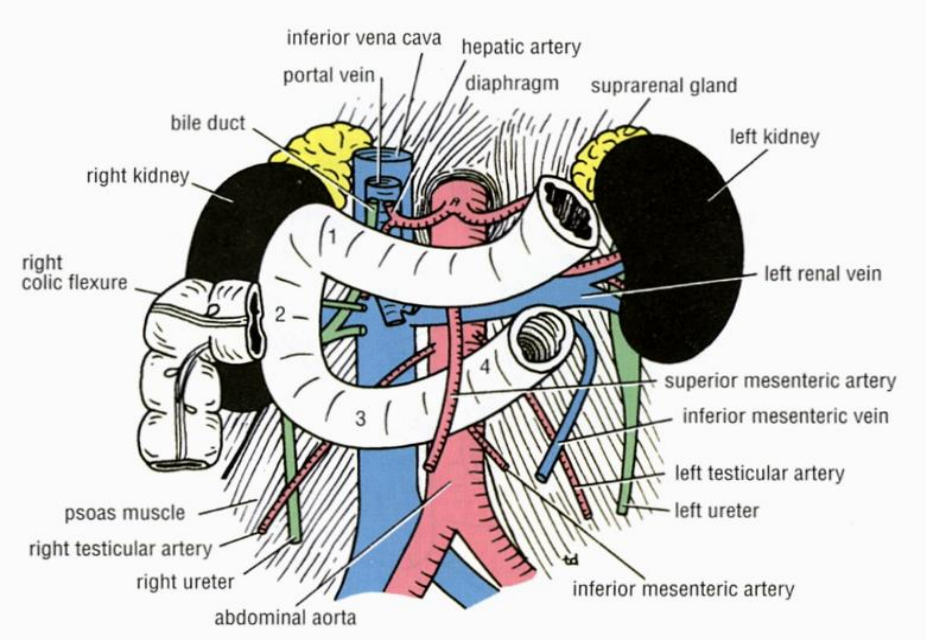

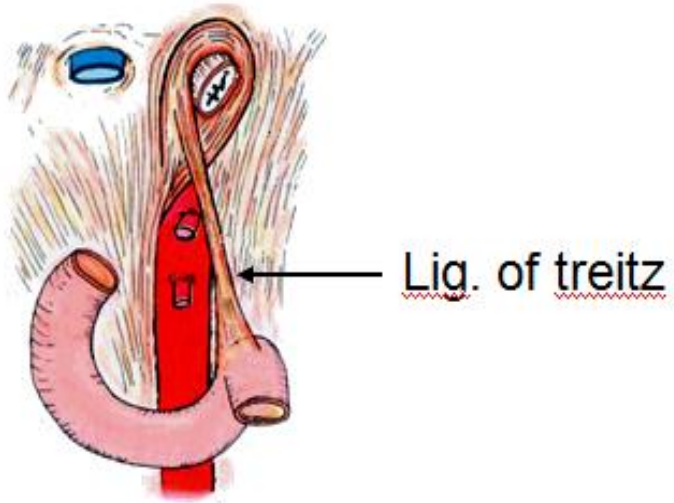

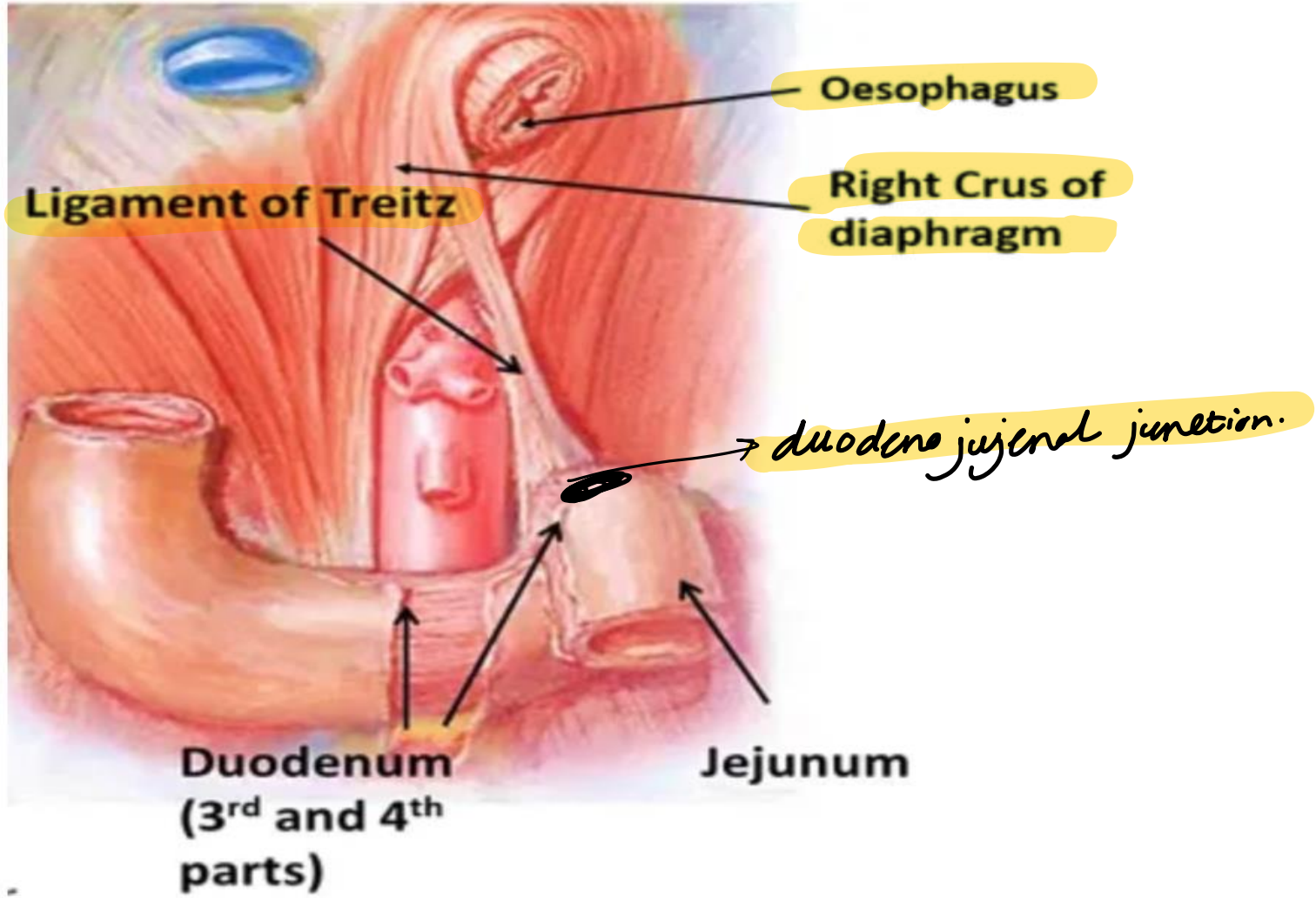
Oesophagus
Right Crus of diaphragm
Ligament of Treitz
duodeno jujenal junction.
Duodenum (3rd and 4th parts)
Jejunum

Duodenum

- The mucous membrane of the duodenum is Thick.
- In the first part of the duodenum it is Smooth.
- In the remainder of the duodenum it is thrown into numerous circular folds called the ***Plicae Circulares***.

- At the site where the bile duct and the main pancreatic duct pierce the medial wall of the second part is a small, rounded elevation called the ***major duodenal papilla.***
  - The accessory pancreatic duct, if present, opens into the duodenum on a smaller papilla about (1.9 cm) above the major duodenal papilla.

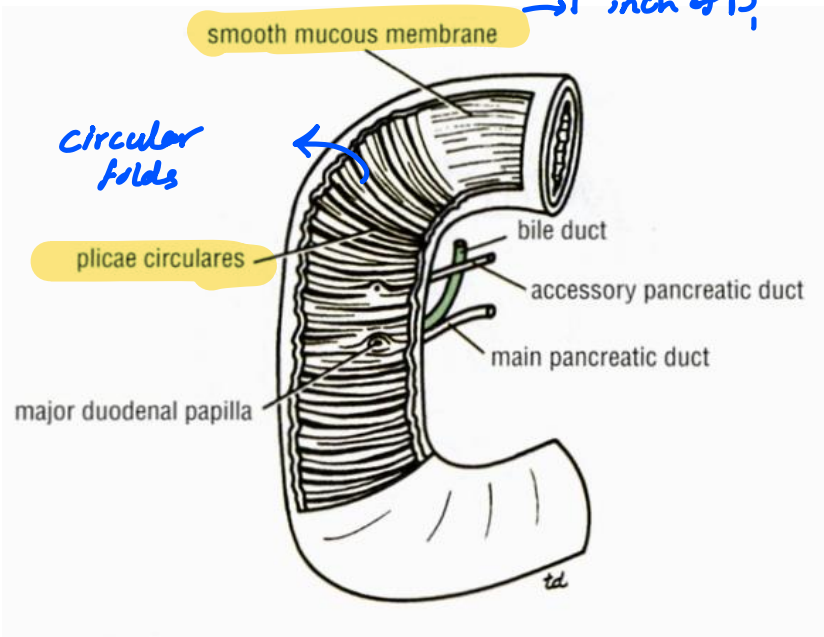

Blood Supply of Duodenum + Head of pancreas

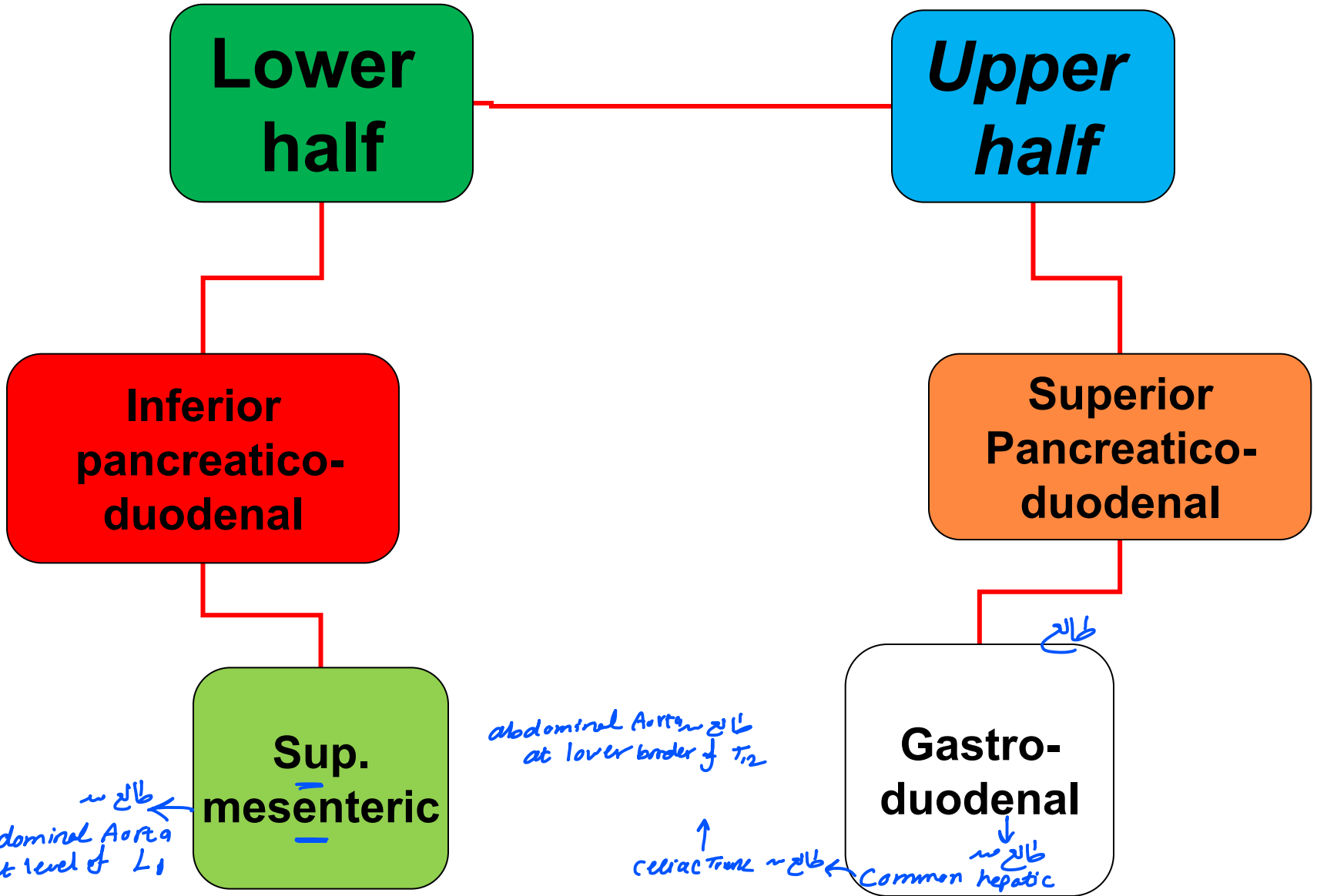

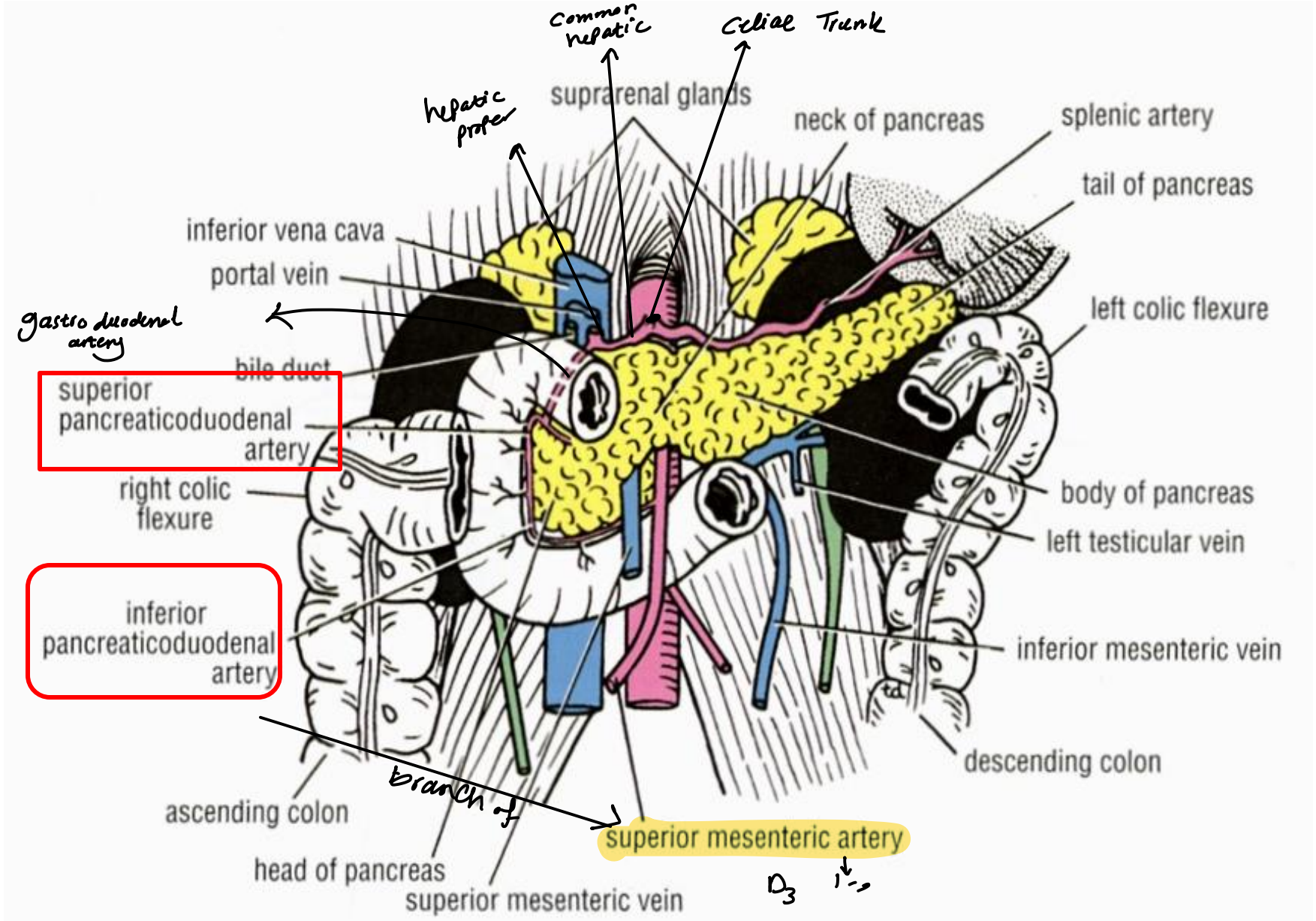
common hepatic
Celiac Trunk
hepatic proper
suprarenal glands
neck of pancreas
splenic artery
tail of pancreas
inferior vena cava
portal vein
gastro duodenal artery
left colic flexure
bile duct
superior pancreaticoduodenal artery
right colic flexure
body of pancreas
left testicular vein
inferior pancreaticoduodenal artery
inferior mesenteric vein
descending colon
branch of
ascending colon
superior mesenteric artery
head of pancreas
superior mesenteric vein
D3

DUODENAL ULCER

- As the stomach empties its contents into the duodenum, the acid chyme is squirted against the Antrolateral wall of the first part of the duodenum.
- This thought to be an important factor in the production of a duodenal ulcer at this site.
- An ulcer of the anterior wall of the first inch of the duodenum may *Perforate* into the upper part of the greater sac, above the transverse colon.



* if Duodenal ulcer is posterior ⟹ erode the gastroduodenal artery ⟶ sever hematesis

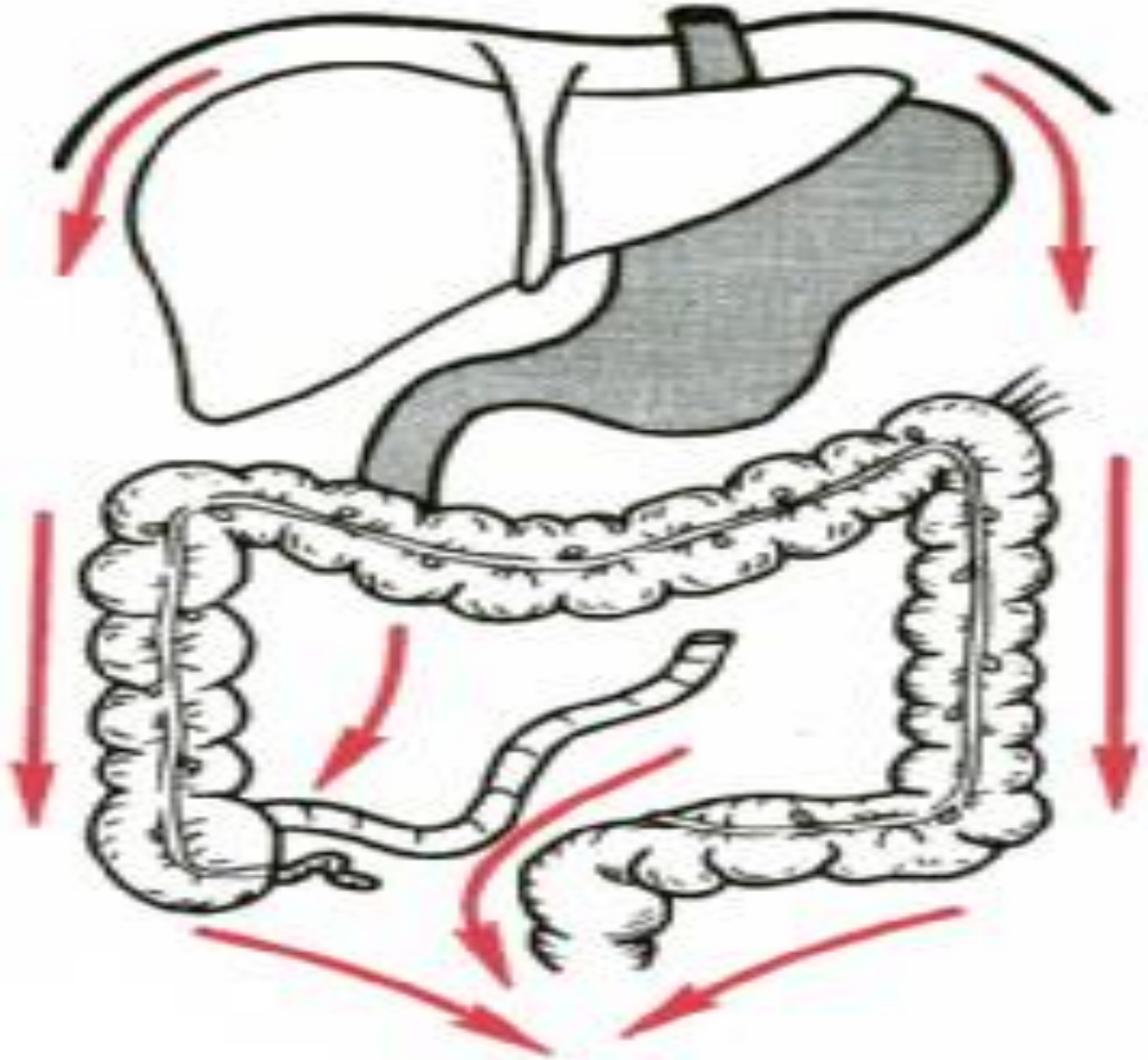

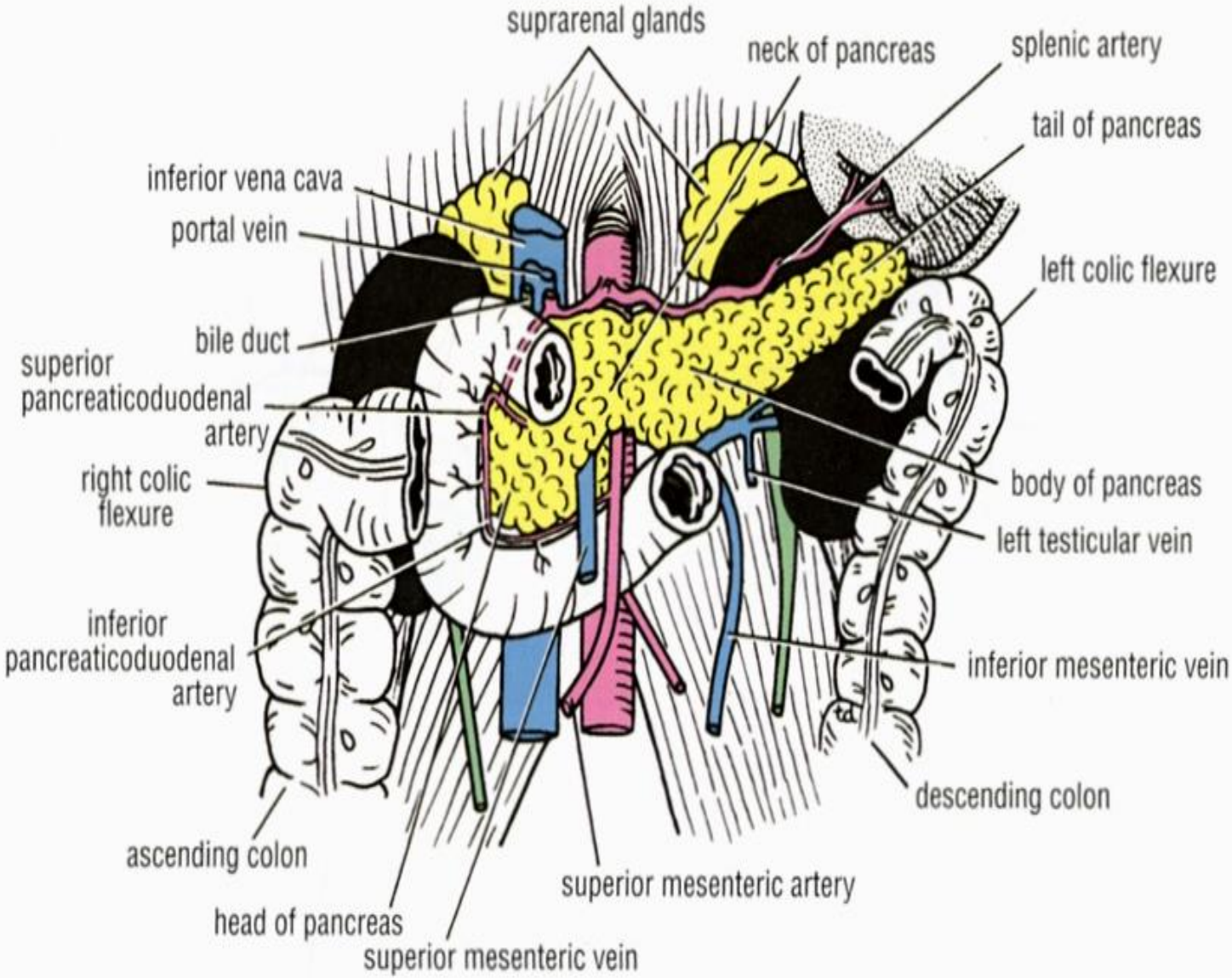
suprarenal glands
neck of pancreas
splenic artery
tail of pancreas
inferior vena cava
portal vein
left colic flexure
bile duct
superior pancreaticoduodenal artery
right colic flexure
body of pancreas
left testicular vein
inferior pancreaticoduodenal artery
inferior mesenteric vein
descending colon
ascending colon
superior mesenteric artery
head of pancreas
superior mesenteric vein

IMPORTANT DUODENAL RELATIONS

*Povert syndrome : لو الحصوة دخلت duodenum وكانت كبيرة وعلقت فيها
ما نزلت على small intestine بالتالي انسد طريق الأكل
بالتالي ح يستفرغ الأكل.

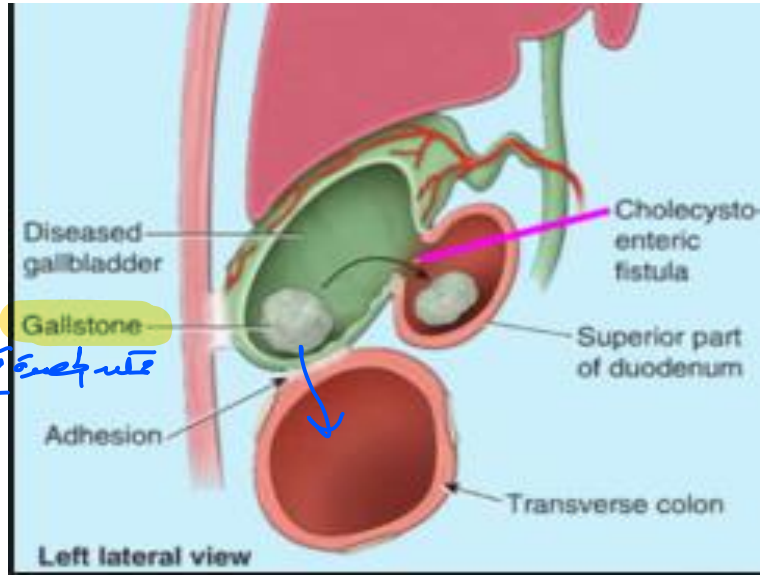

- The relation to the duodenum of the gallbladder, the transverse colon, and the right kidney should be remembered.

infront of duodenum

ممكن الحصوة تنزل على colon لكن هاد نادر

- Cases have been reported in which a large gallstone ulcerated through the gallbladder wall into the duodenum. Gall stone ileus

هو أن gall bladder اللي قدام duodenum عملت perforation إلها
الحصوة نزلت في duodenum ومشت في كل small intestine ووصلت
آخرها. علقت عند ileosecal valve وعملت intestinal obstruction

- Operations on the colon and right kidney have resulted in damage to the duodenum.

