Abdominal Vasculature:

Arterial supply

Abdominal Aorta

avge diameter : 2,8 cm

The main bld. Supply to the abdomen comes from:

Abdominal Aorta → continuation of descending Aorta. → in diaphragm

- **Starts** in aortic hiatus opposite to Lower border of ***T12***
- **Descend** infront of upper 4 lumbar vertebrae, slightly curved to Lt.
- **Ends** opposite to ***L3-L4 disc*** **2cm below and to left of umbilicus** by dividing into: ***2 Common Iliac Arteries***

short artries ends by dividing to → extend iliac / internal iliac → artery of Pelvis organs.

To its Rt lie IVC,cisterna chyli, azygos v

→ Starts one vertebra below it's end L4-L5 As continuation of 2 common iliac veins.

To its lt lie Lt sympathetic trunk.

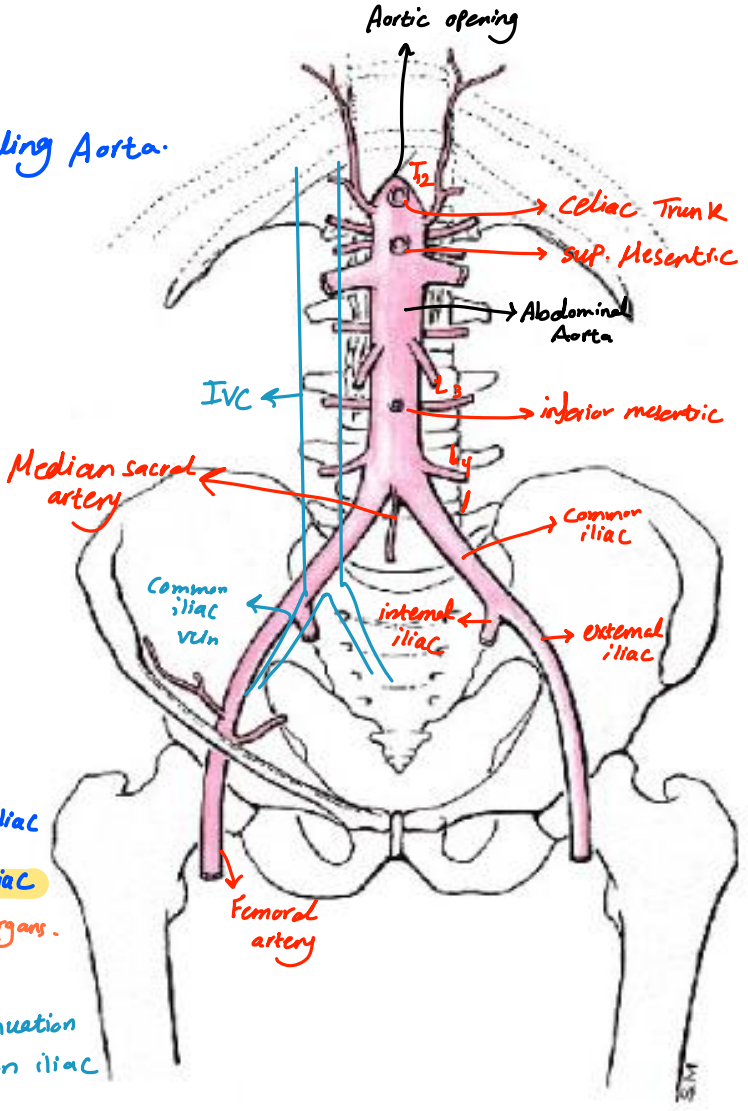

Branches of Abd. Aorta

Abd. Wall branches:

5 lumbar Arteries (each side)

1st lumbar = inf. phrenic artery

Abd. Cavity branches: (Visceral)

3 Anterior

3 lateral

3 Terminations

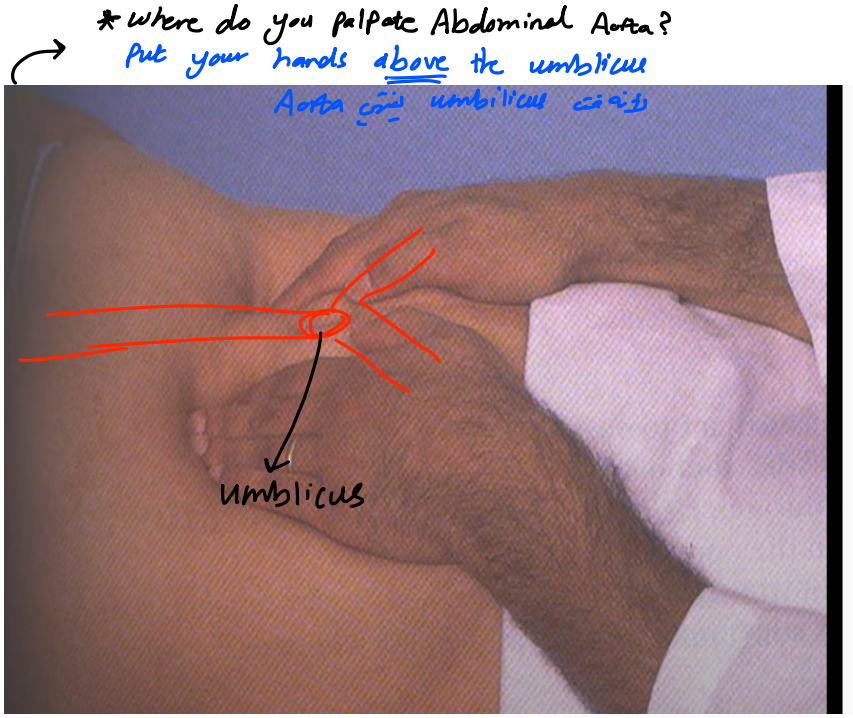

3 anterior: Single

- Celiac trunk T12
- Sup. Mesenteric L1
- Inf. Mesenteric L3

3 lateral: Paired

- Suprarenal
- Renal L2
- Gonadal (testicular or ovarian)

3 Terminations:

2 common iliac A (L4)

Median sacral a. single

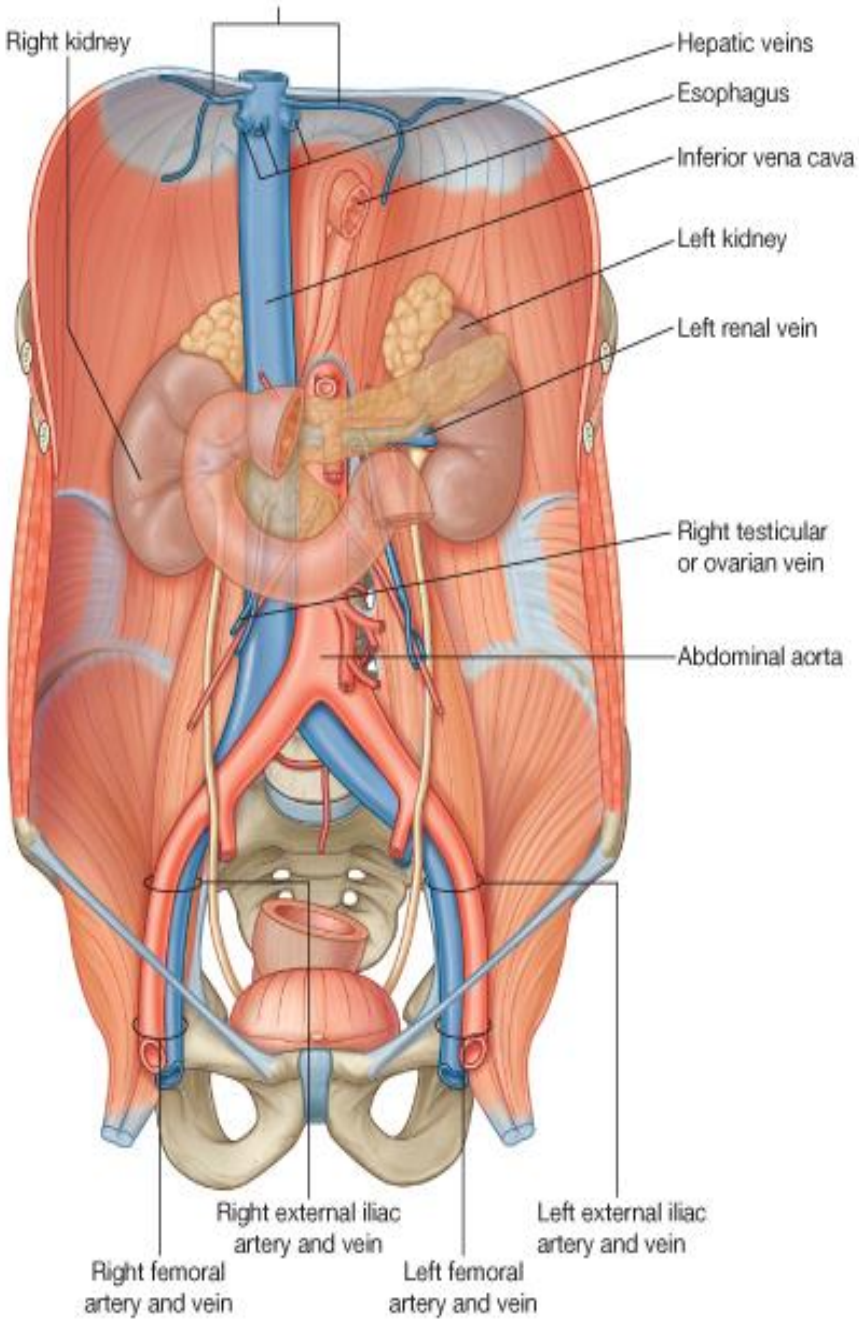

Abdominal Aorta

Common iliac arteries

just below and to the left of umbilicus

- 5 cm long ,Begin at Lt side of L3-L4 disc
- End at level of L5-S1 at sacral promontory, infront of sacro-iliac joint by dividing into.
- External iliac artery: Run along brim of pelvis on medial border of psoas muscle, then infront of muscle ,below inguinal lig to become Femoral artery.
- Internal iliac artery: Run backward,downward,on pos wall of pelvis, between ureter infront,IIV behind
- At upper part of greater sciatic foramen it divide to ant , pos branch

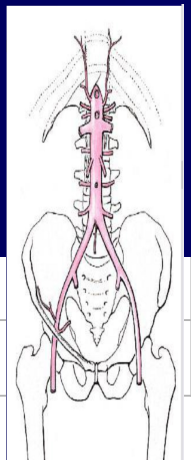

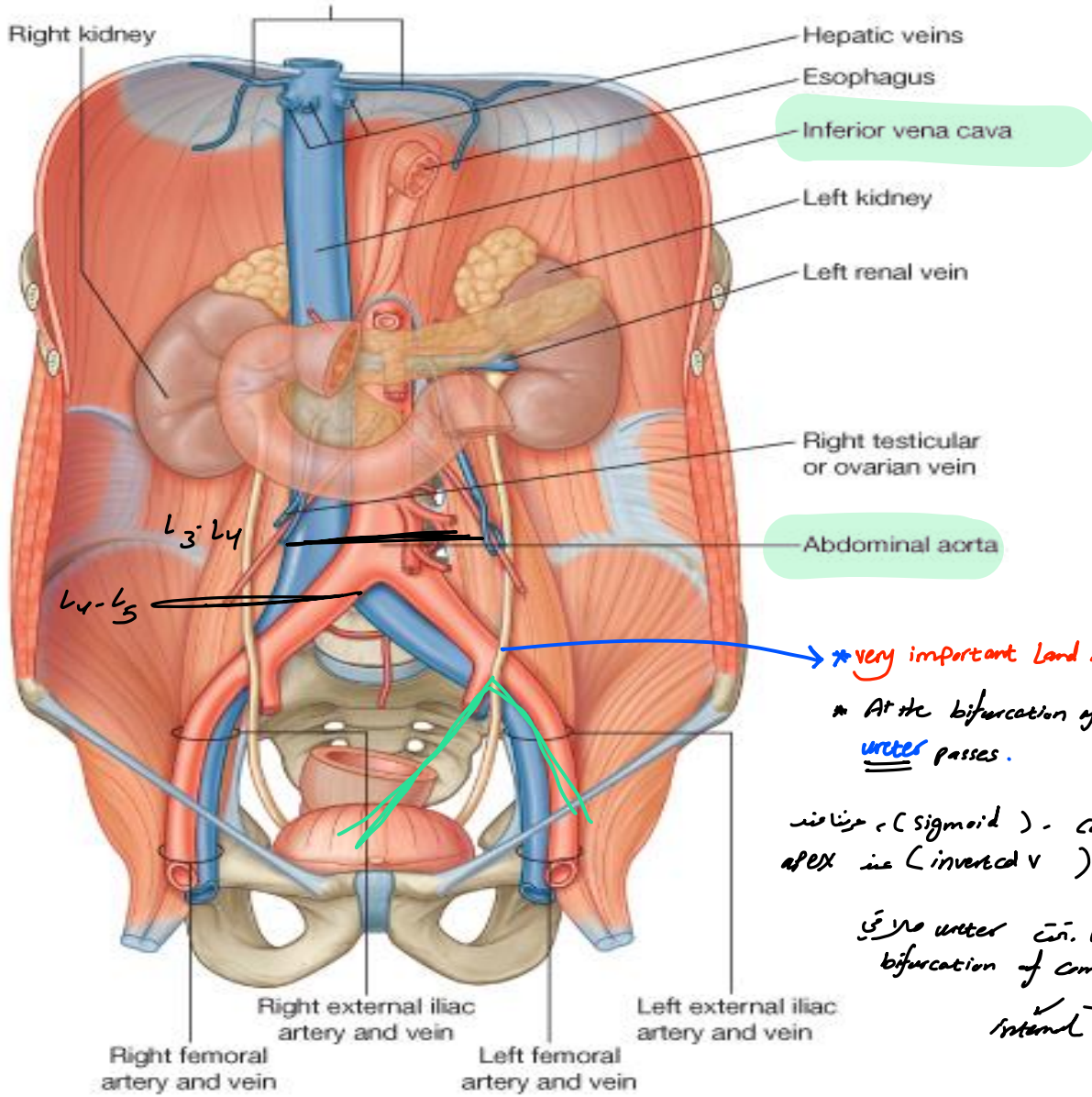

* very important Land mark:

* At the bifurcation of common iliac artery ureter passes.

* فلما بعمل cancer colon ، (sigmoid) ، عرفنا عند apex عند (inverted V) sigmoid meso colon (pelvic meso colon)

ملاقي ureter تحت ملاقي ureter bifurcation of common iliac artery.

internal → external

Celiac Trunk → 1st branch of celiac Trunk.

lower border

At level of *T12* just beneath the hiatus

Very short 1 cm

Divides into 3 branches:

Lt.: Splenic A. (largest)

↳ tortious.

Rt.: Common hepatic a.

Sup.: Left gastric a.

pass on **(lesser curvature superiorly)**

أصغر واحد في celiac Trunk لكنه أكبر blood supply للـ Stomach [5]

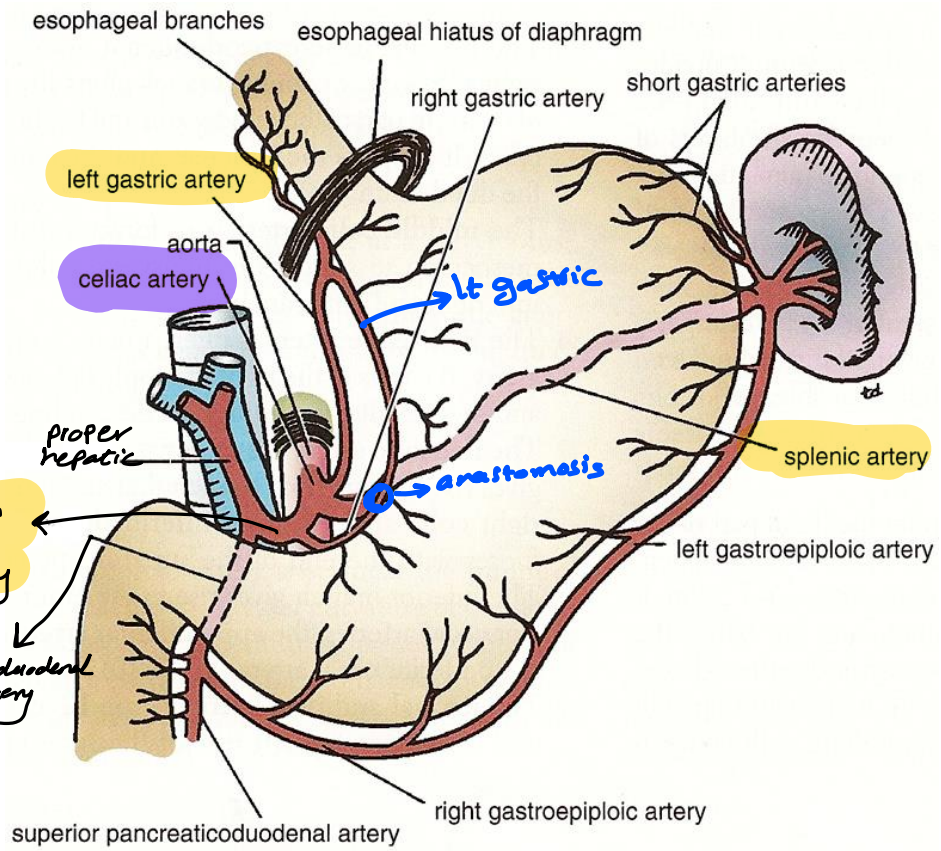

Splenic Artery → stomach bed مدخن

Largest branch of *Celiac Trunk*

Pass Post. to the stomach & Sup. to pancreas at upper border, very tortuous course.

① splenic artery ② tail of pancreas موجود فيه

Enters the linorenal ligament to reach the hilum of the spleen, where it divide into 5-6 terminal branches

Branches:

① Pancreatic arteries → Body of pancreas

② Short gastric arteries 5-6 (to the fundus) pass through gastrosplenic lig

③ left gastro-epiploic a. (greater curvature on lf.)

gastro duodenal artery بطلع من Rt كتير

2 ligaments of spleen

linorenal
- splenic artery
- tail of pancreas

gastrosplenic
- Lt. gastroepiploic artery
- Short gastric artries

Splenic Artery

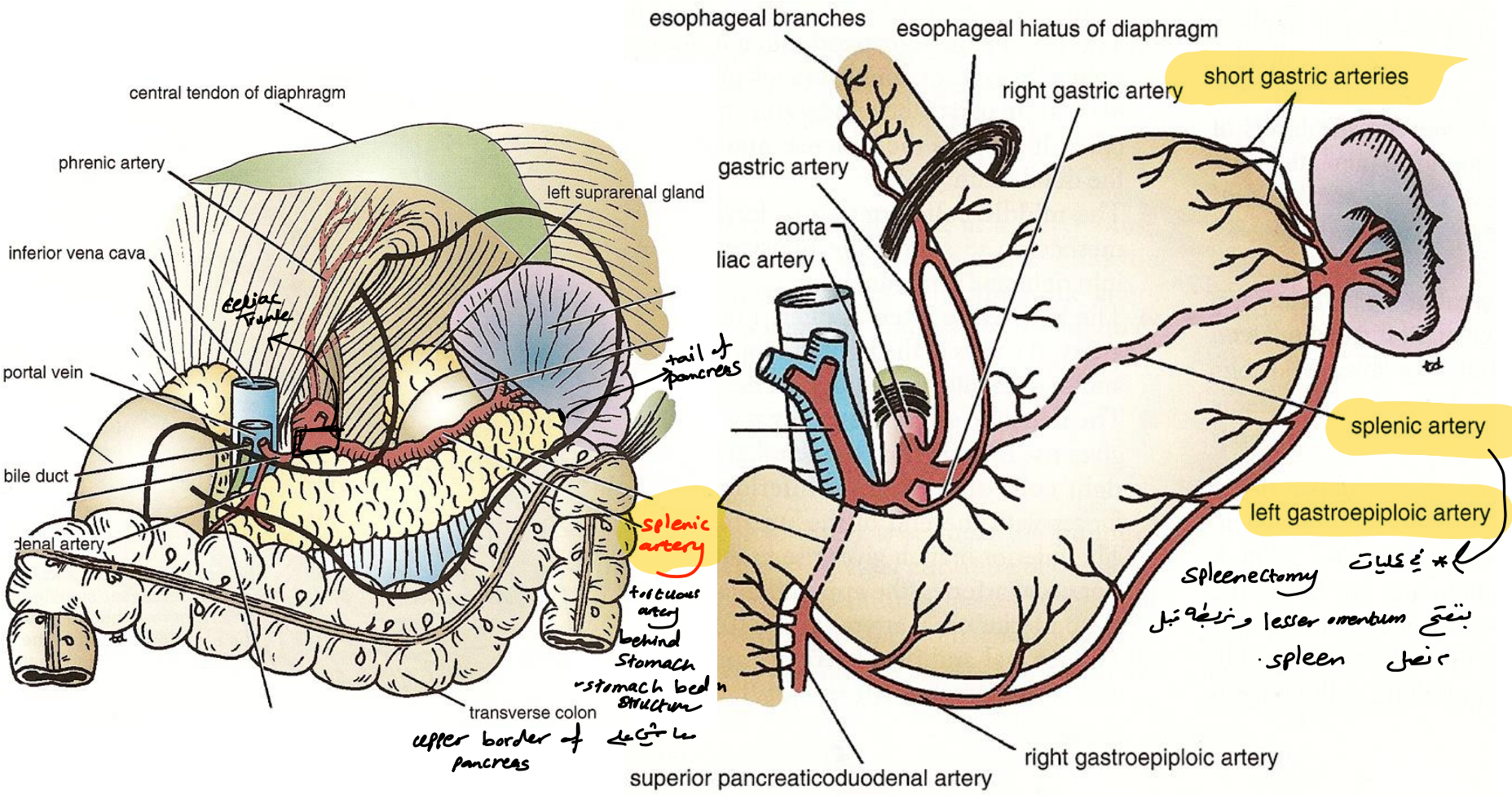

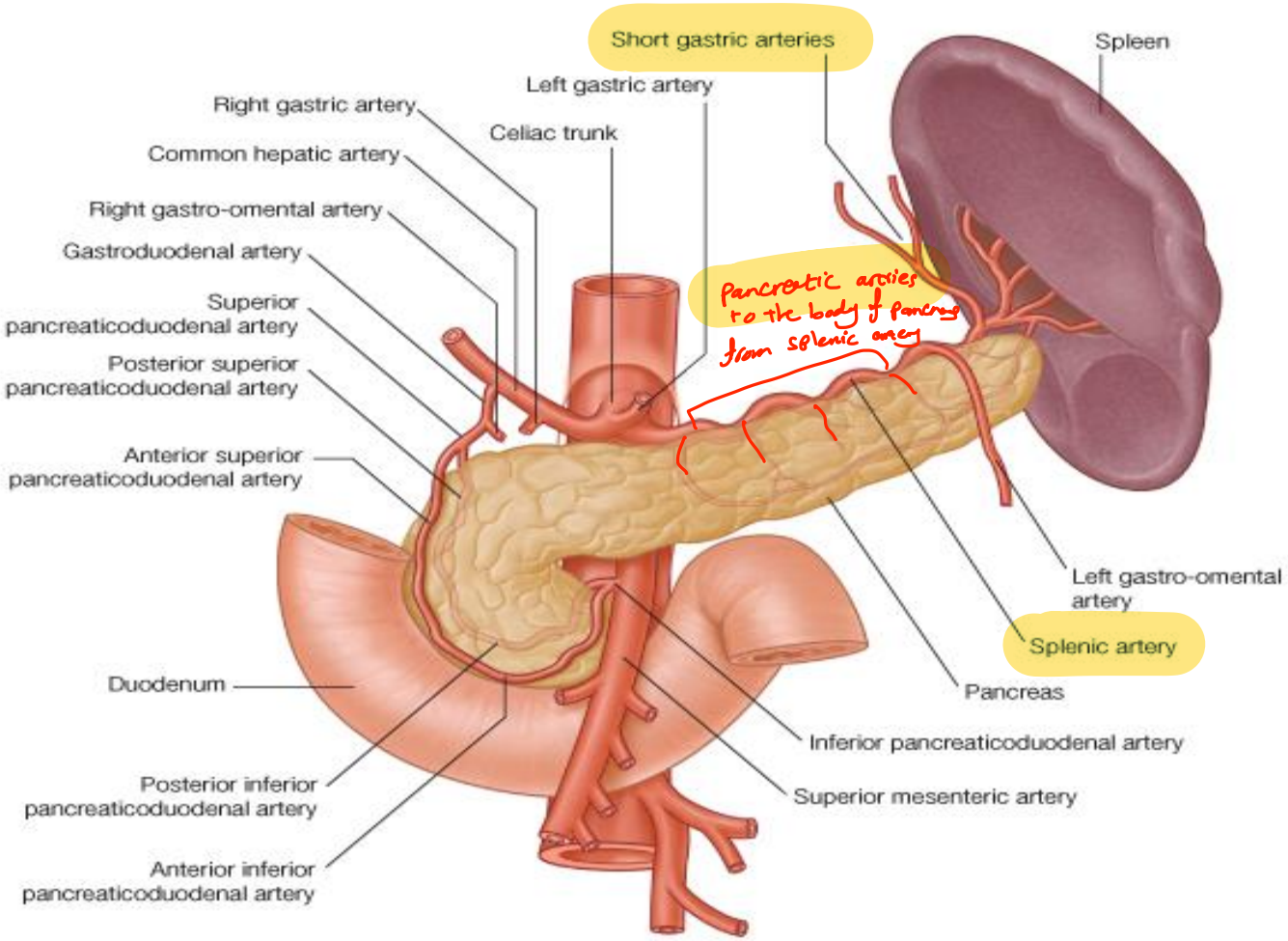
Short gastric arteries
Spleen
Left gastric artery
Right gastric artery
Celiac trunk
Common hepatic artery
Right gastro-omental artery
Gastroduodenal artery
Pancreatic arteries to the body of pancreas from splenic artery
Superior pancreaticoduodenal artery
Posterior superior pancreaticoduodenal artery
Anterior superior pancreaticoduodenal artery
Left gastro-omental artery
Splenic artery
Duodenum
Pancreas
Inferior pancreaticoduodenal artery
Superior mesenteric artery
Posterior inferior pancreaticoduodenal artery
Anterior inferior pancreaticoduodenal artery

Common Hepatic Artery

* لو انقطع Celiac Trunk أو branches 3 نرى
(hepatic - splenic - Lt. gastric)
بنقدر نربطهم.
* بنقدر نربط inf. mesentric artery
* لكن ما بنقدر نربط sup. mesentric artery / vein
لأنه هيصير gangrene to small intestine هيموت الشخص.

Right branch of celiac trunk

Pass in the Rt. Side to the hilum of the liver, infront of portal vein, till it reach upper border of first part of *D1*

It divide like a *T* on its side to at level of L_1

Descending limb: **Gastro-duodenal a**

* إذا كان في ulcer في D_1 ممكن يعمل erosion
لل gastroduodenal a ويصير sever bleeding.

Ascending limb: **Hepatic artery, between to layers of lesser omentum Part of the portal triad**

devide
Rt
Lt

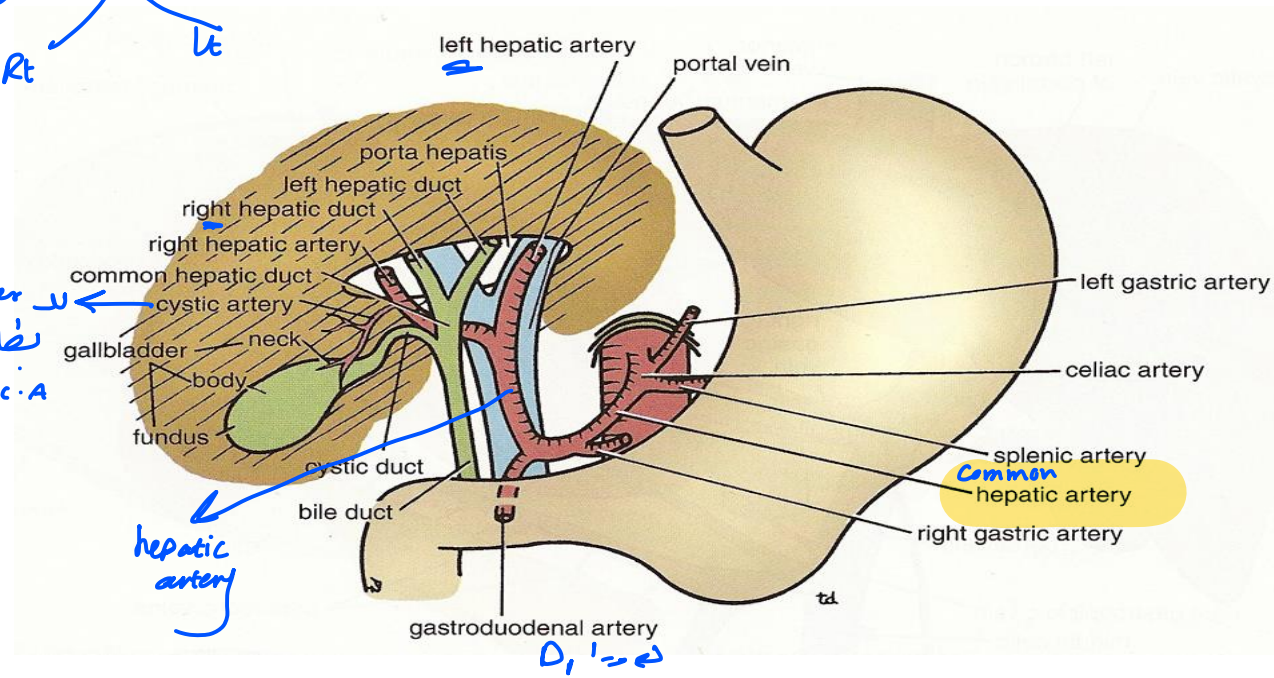

gall blader لل
بطلع من
Rt. hepatic. A

hepatic artery

D_1 لهو

Porta Hepatis

In the middle of visceral surface of the liver.

Contains:

(Portal Triad)

1. **Portal vein *(in)*** behind
2. **Hepatic artery *(in)*** infront, Lt
3. **Bile duct *(out)*** infront, Rt

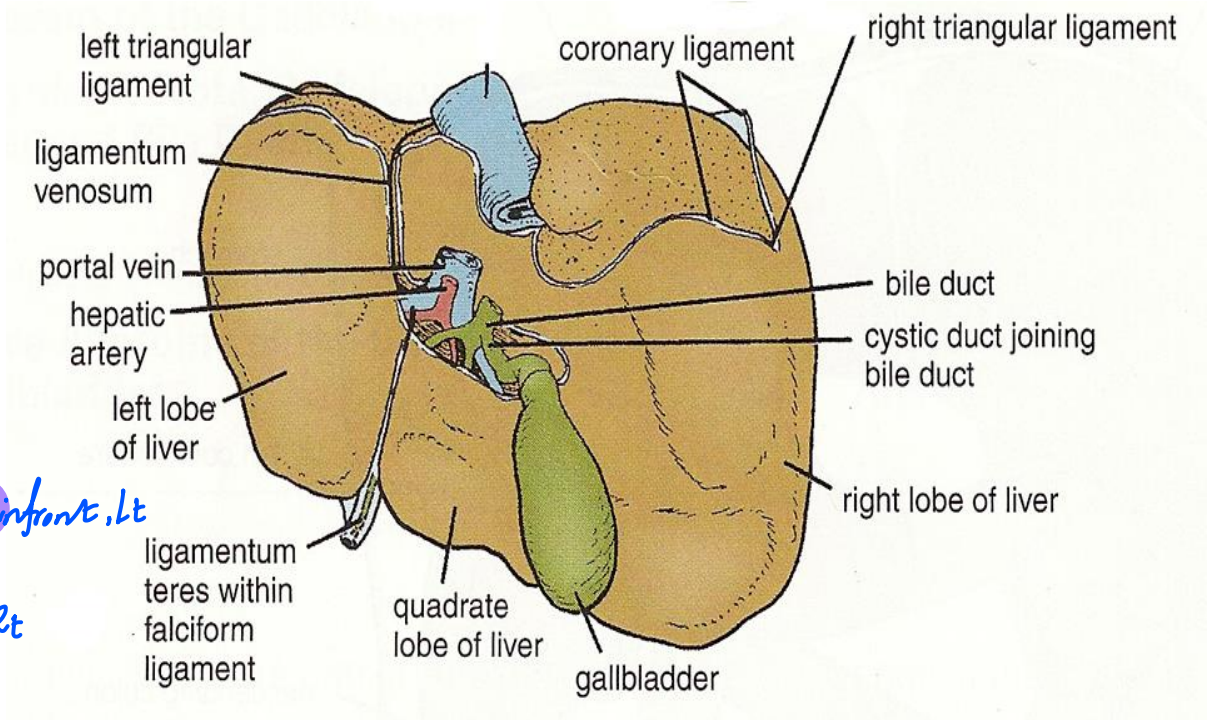

Common Hepatic Artery

Branches:

usually arise from proper hepatic

Rt. Gastric a.: **pass to left**

Gastroduodenal a.:

descends behind duodenum (1st part)

gives: Rt. Gastro-epiploic & sup. Pancreatic duodenal

gastroduodenal artery → branch الى

2 terminations:

Lf. Hepatic a.

Rt. Hepatic a.

artery of gall bladder

Cystic A. comes from Rt. Hepatic a.

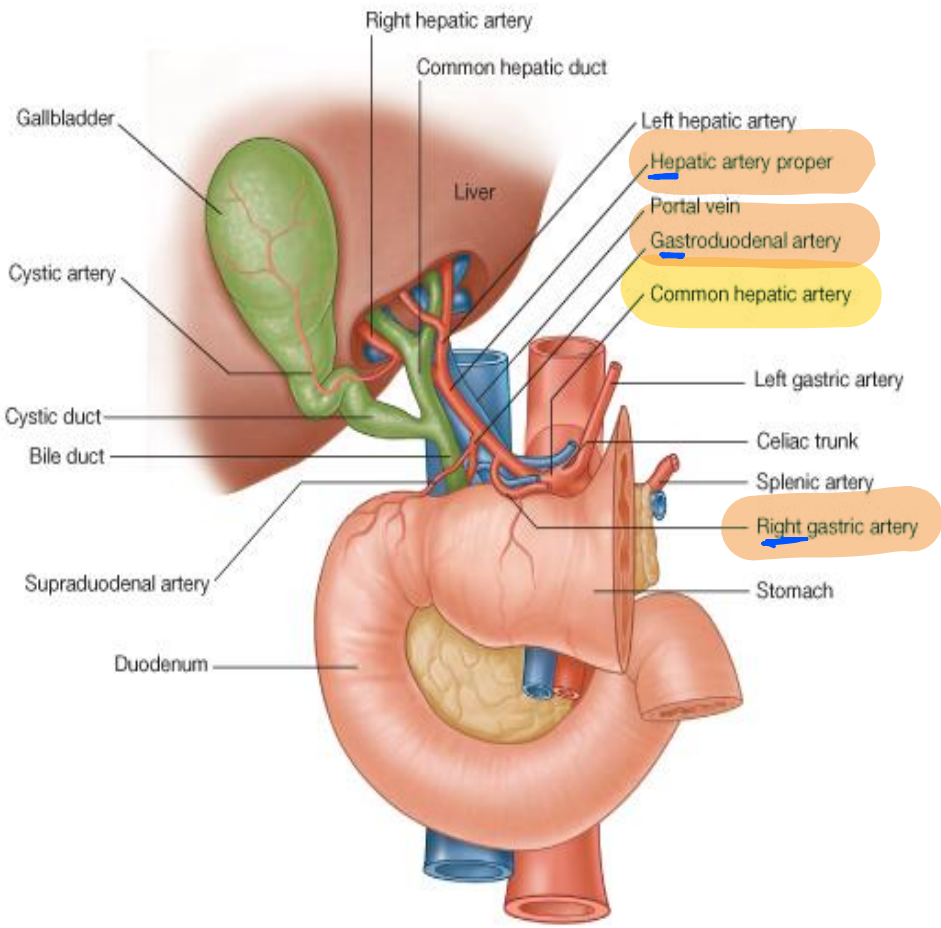

Celiac Trunk Branches (Review)

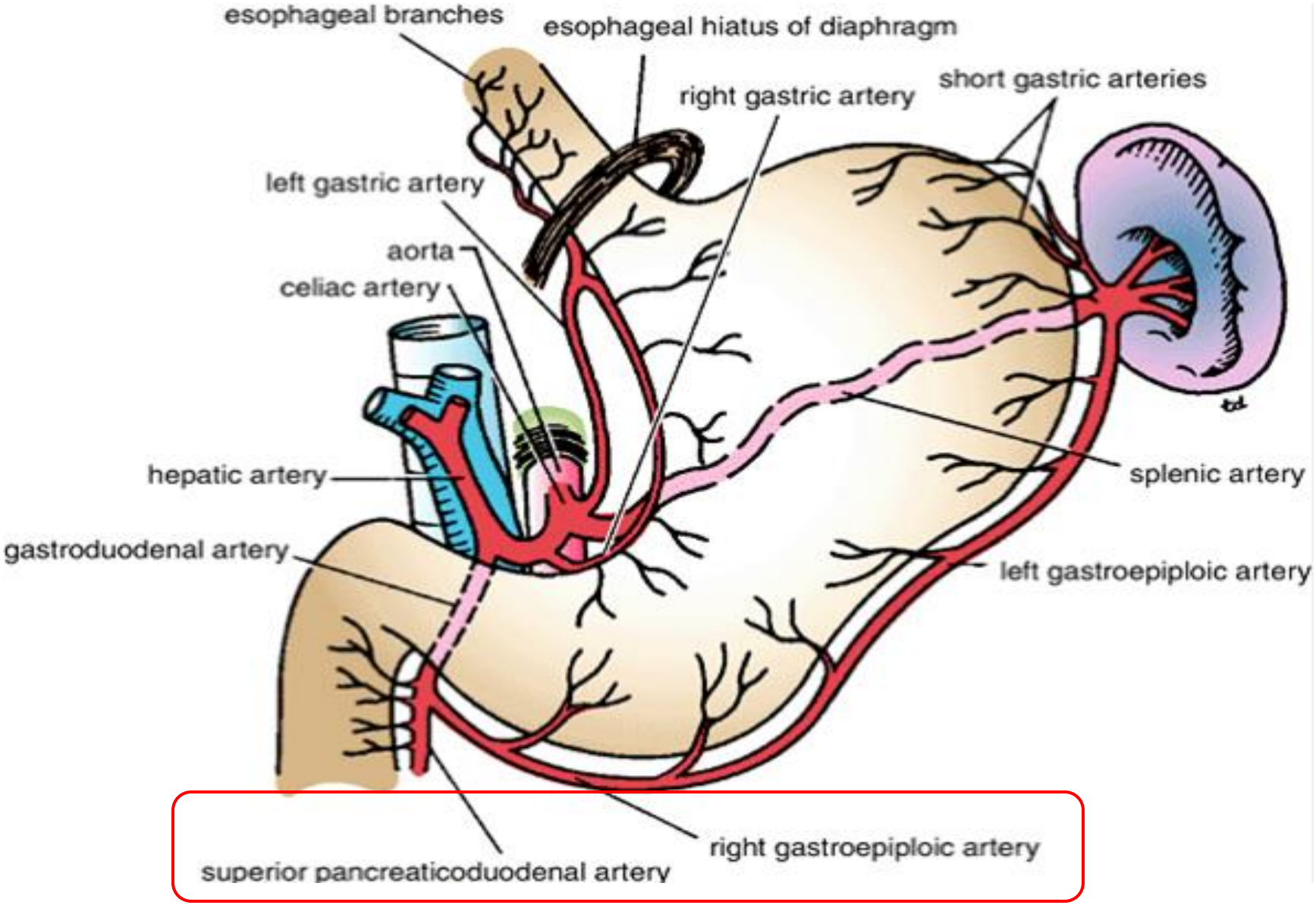

Superior Mesenteric Artery

Arises: * single artery arise From Abdominal Aorta

↳ supply: ① all the small intestine
② cecum
③ ascending colon
④ proximal 2/3 of Transverse colon.

Below celiac trunk & just above the left renal vein, at *L1*, Sup mesenteric vein , lie on the Rt side of artery ,in its concavity

Descends:

post. to *neck of Pancreas*

Ant. to 3rd part of duodenum

Supplies the intestine:

from lower ½ of duodenum

↓

Until proximal 2/3 of transverse colon

End by anatomizing with ileal branches of ileocolic artery

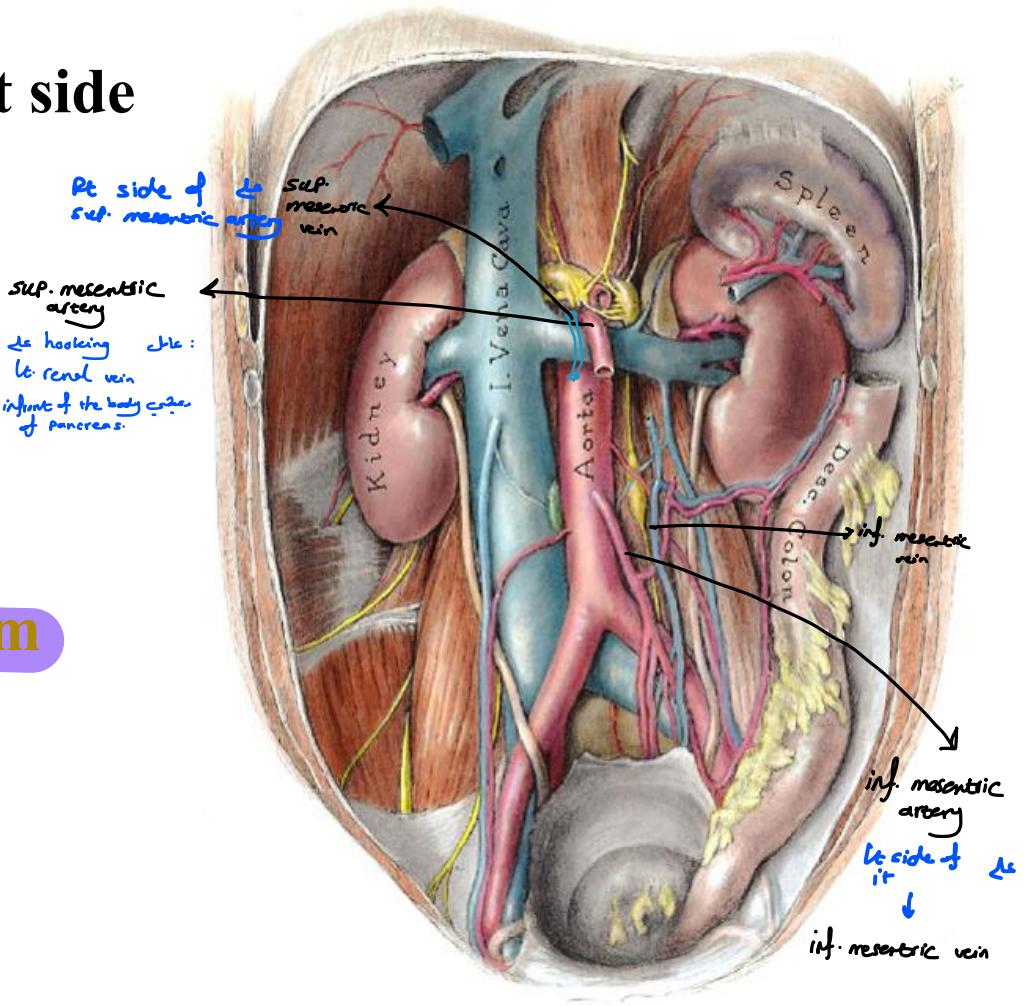

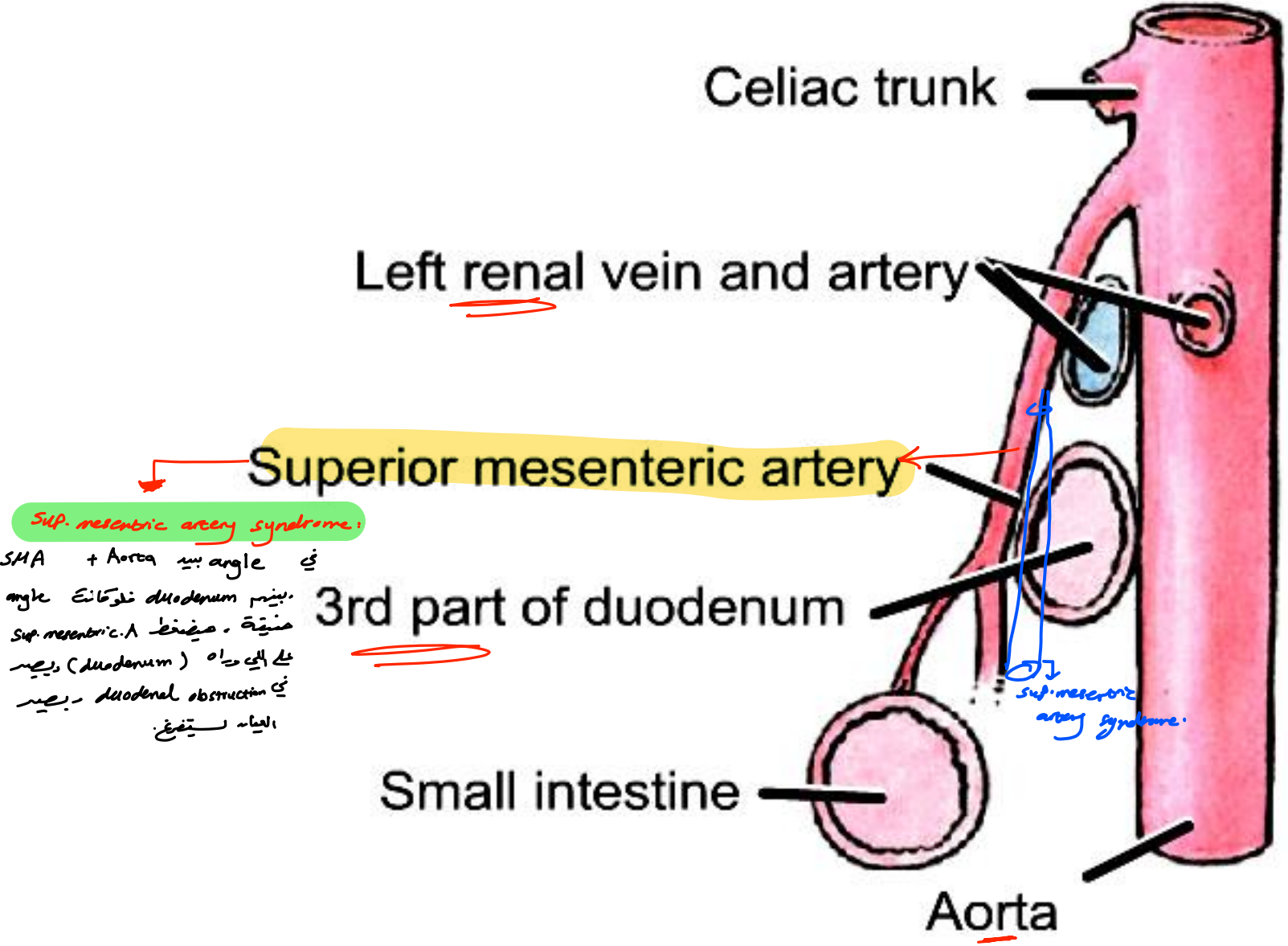

Sup. mesentric artery syndrome:

في SMA + Aorta بين angle
بينهم duodenum فلو كانت angle
ضيقة ، هيضغط Sup. mesentric.A
على اللي وراه (duodenum) ويصير
في duodenal obstruction ويصير
العيان يستفرغ.

Lateral View (from left)

Relations of Superior Mesenteric Artery

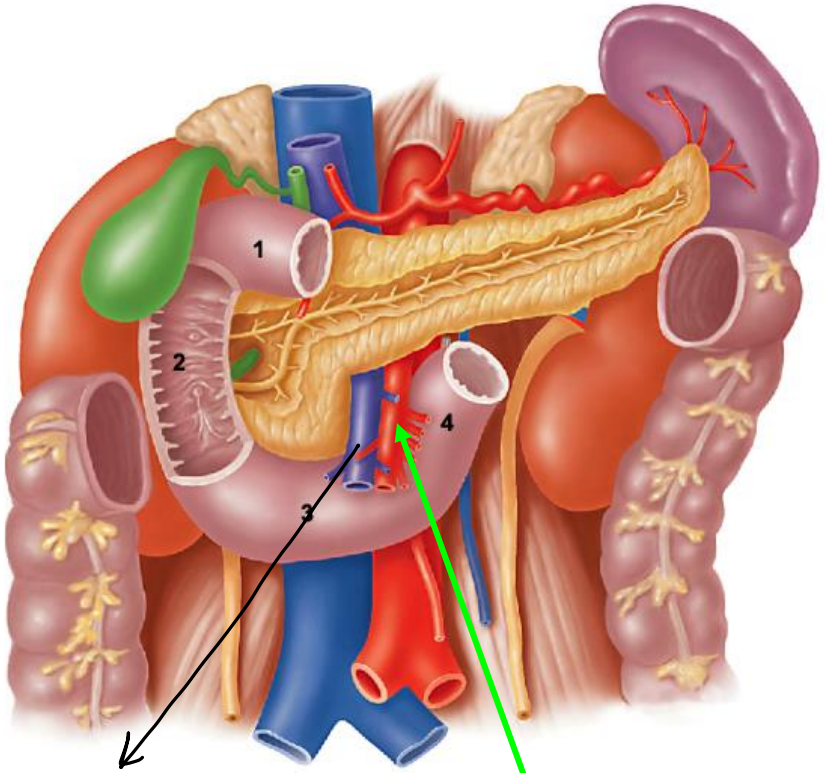

Sup. mesenteric vein
(Rt side of SMA)

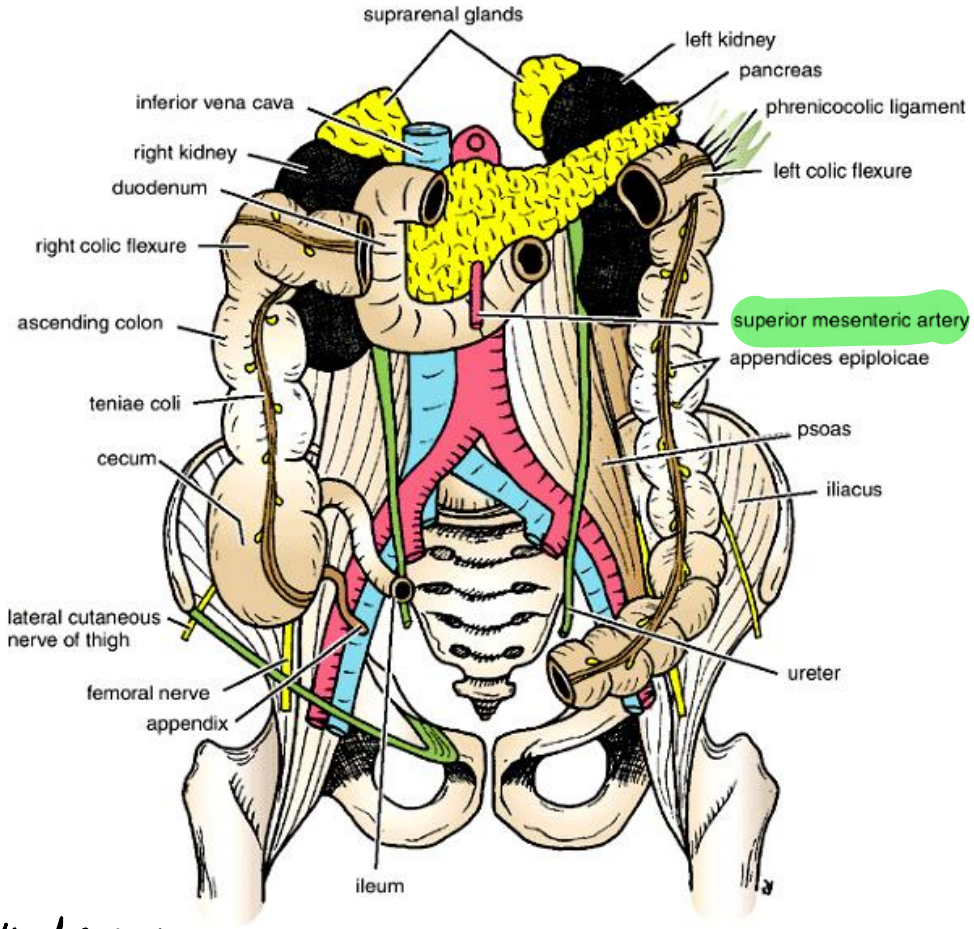

Sup. Mesenteric a. → coiled behind neck of pancreas then infront of 3rd part of duodenum.

Main Branches of Sup. Mesenteric

1. ***Inf. pancreatic duodenal a.***

   Anastomose with sup. Pancreatic duodenal a.

2. ***Jejunal & ileal branches.***

12 or more arise from convex Lt side of SMA

3. ***Ileocolic a.:***

- **Ileal arteries: to terminal ileum**
- **Ant, pos cecal arteries: front, and back of cecum**
- **Appendicular A:descend behind terminal ileum to reach Meso A**
- **Ascending branch:lower1/3 of ascending colon .**

4. ***Right colic a.:***

Supplies the upper2/3 ascending colon, hepatic flexure

5. ***Middle colic a.:***

Supplies proximal 2/3 of transverse colon

Rt hepatic artery may arise from SMA in 25% of people

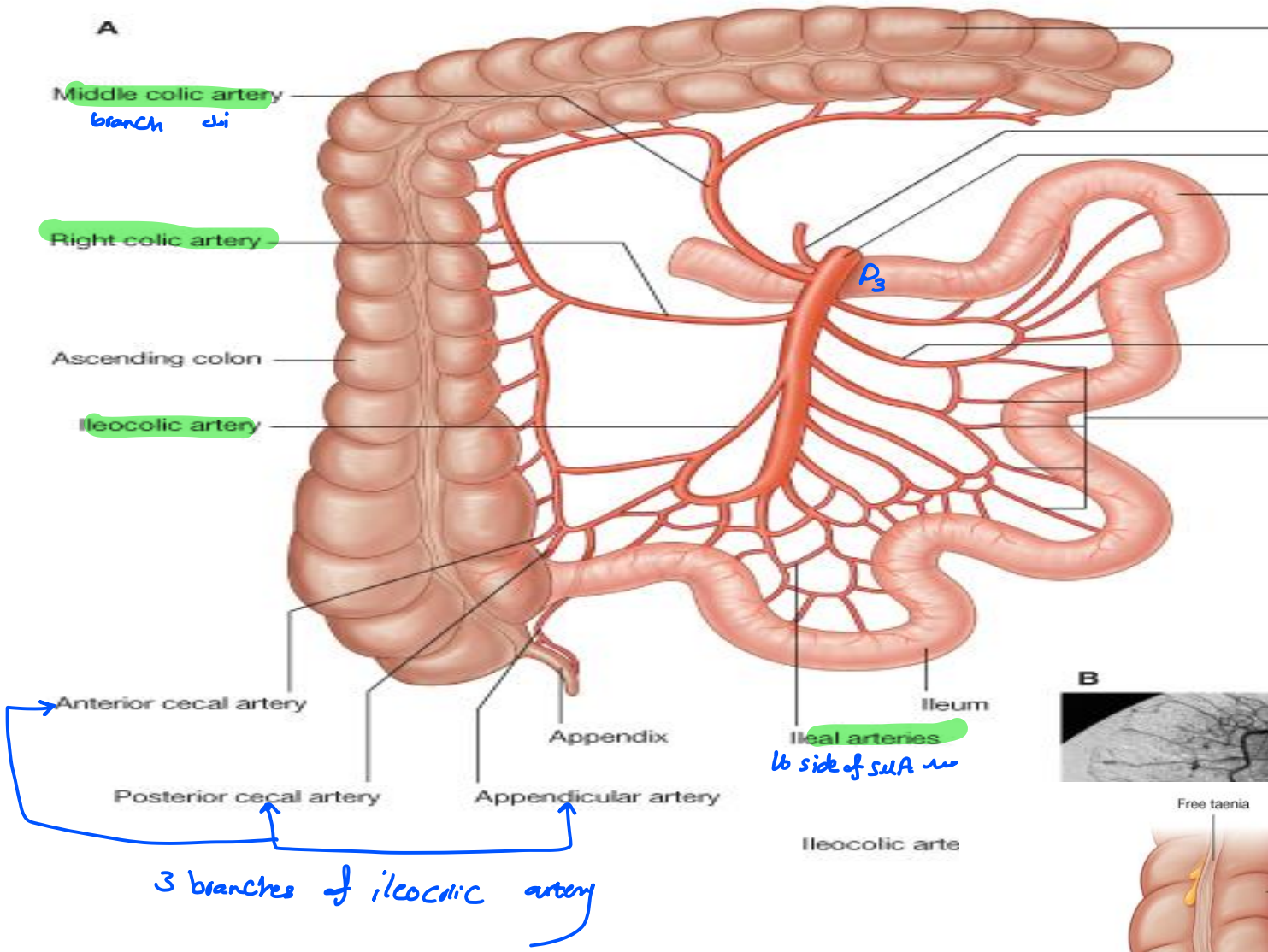
A
Transverse
Middle colic artery
branch of
Inferior pa
Superior mesenteric a
Jejunum
Right colic artery
D3
Jejunal art
lt side of SMA
Ascending colon
Ileocolic artery
Vasa recta
Right co
B
Anterior cecal artery
Ileum
Appendix
Ileal arteries
lt side of SMA
Posterior cecal artery
Appendicular artery
Ileocolic arte
3 branches of ileocolic artery

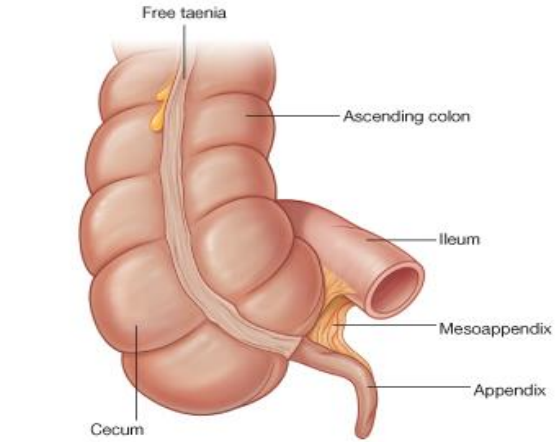
Free taenia
Ascending colon
Ileum
Mesoappendix
Appendix
Cecum

Inferior Mesenteric Artery

Supplies intestine:

From distal 1/3 of transverse colon

↓

Upper ½ of Anal canal

Arise: **from abdominal aorta at level of L3**

Rectum بغذي artery أم

End: **by becoming superior rectal A, which cross lt CIA to enter pelvis**

At its origin lie behind D3

IMV lie on its Lt side

Runs downward to the left.

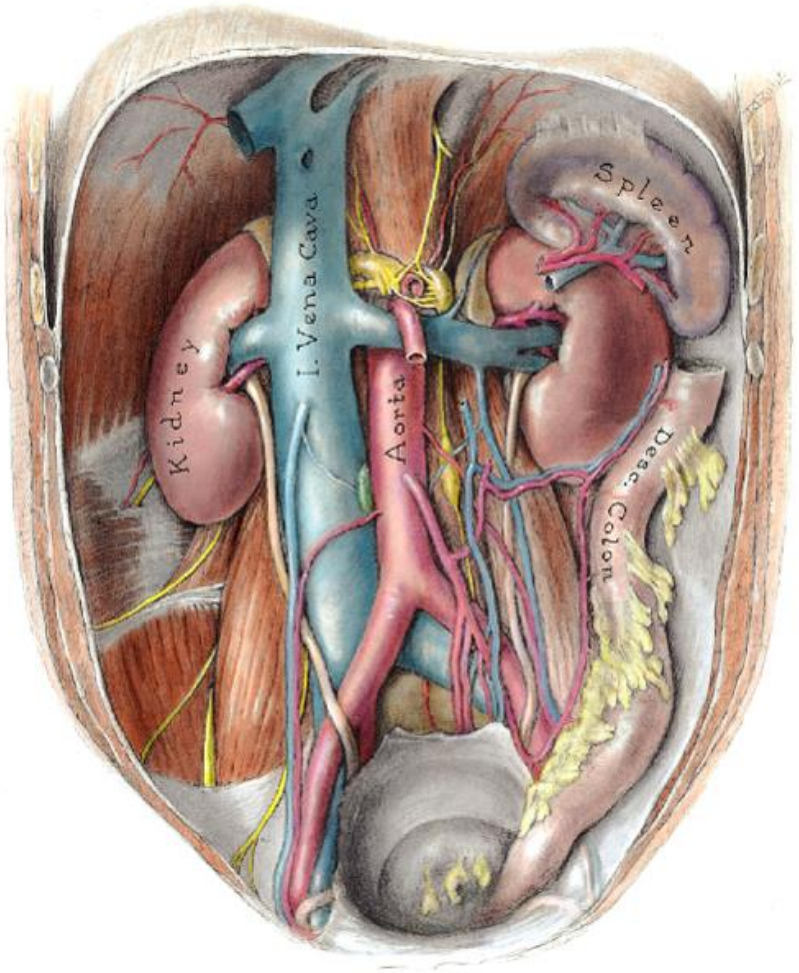

* What is the difference between sup and inf mesentric artery?

* 3rd part of duodenum separate sup mesentric artery infront of it from inferior mesentric artery behind it.

Branches of Inf. mesenteric A

Left Colic:

supplies distal 1/3 of trans. Colon & descending colon

Sigmoid arteries:

3-4 branches

supply sigmoid colon

Superior rectal a.: (continuation of inf. mesenteric artery) Begins at middle of Lt CIA

Enter descending limb of sigmoid mesocon,continue behind rectum and divide into Rt,Lt branches, supply rectum & upper ½ of anal canal,anastomose with M,I rectal arteries (middle, inferior)

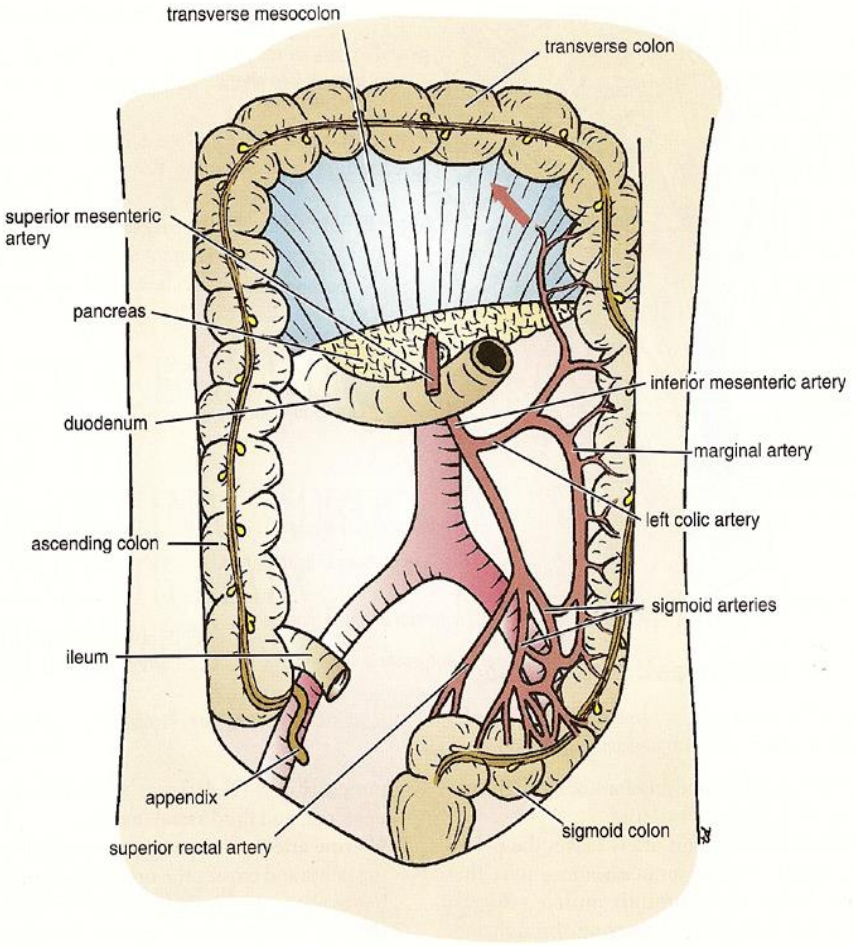

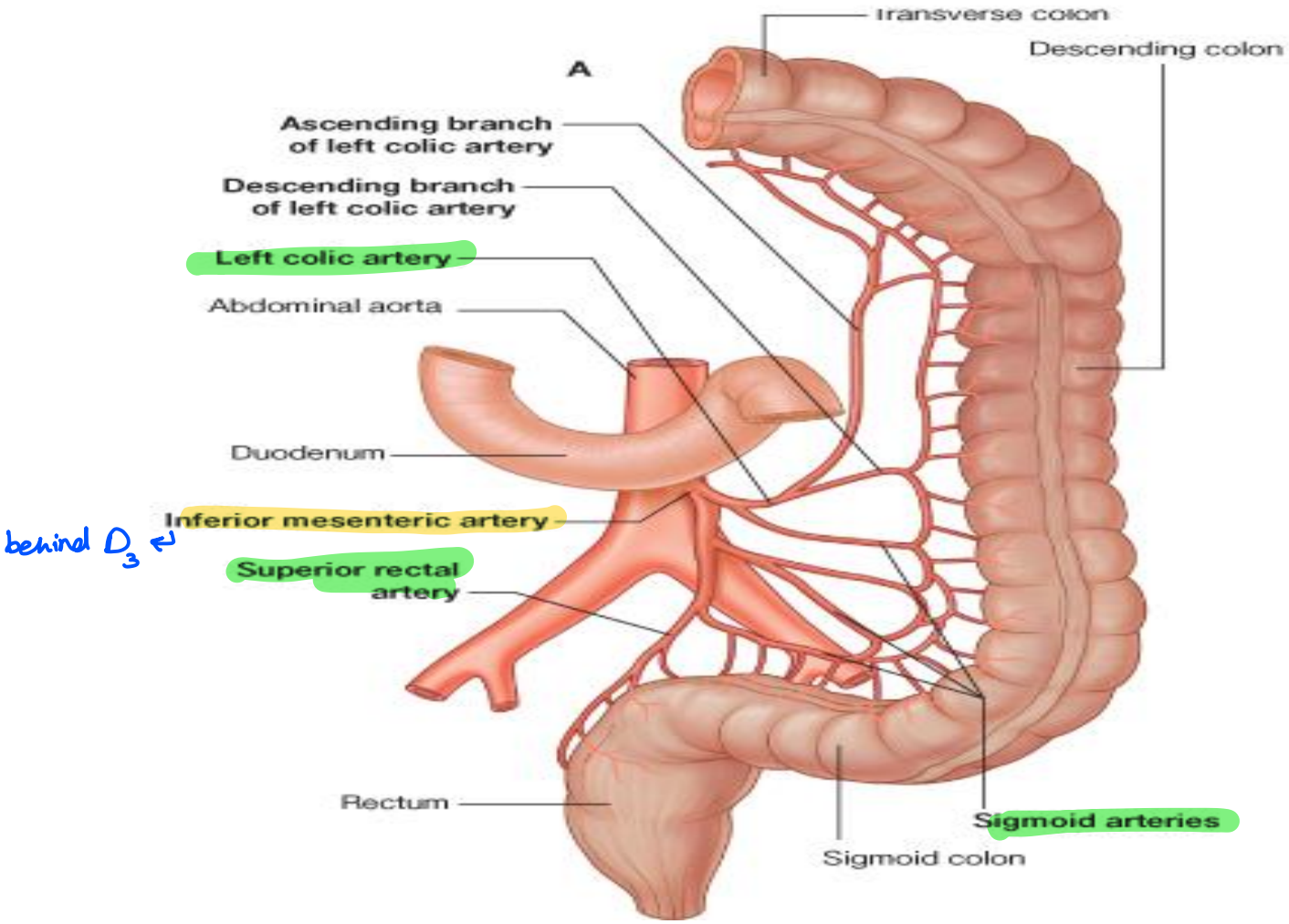
A
Transverse colon
Descending colon
Ascending branch of left colic artery
Descending branch of left colic artery
Left colic artery
Abdominal aorta
Duodenum
Inferior mesenteric artery
behind D3
Superior rectal artery
Rectum
Sigmoid arteries
Sigmoid colon