# Introduction

Brain Tumor

بطلعوا من نفس الـ Tissue أو من meninges

- Primary brain tumors are a diverse group of neoplasms arising from different cells of the central nervous system.
- Approximately one-third of primary brain tumors were malignant.
- 20% of all brain tumors - tumors of childhood.
- **Malignant brain tumors** more frequent in childhood than in adults.

brain tumor عند الاطفال بكون malignant > من عند الـ adult

# Etiology of B

- **Genetic predisposition.**
- **Ionizing radiation.**
- **Viral infections:** Epstein-Barr virus → primary brain lymphoma.
- **Environmental risk factors:** pesticides, chemicals.
- **Possible causative factors include:** allergies, physical, trauma, and certain infections.

# Epidemiology

- **Incidence:** 8-25 per 100,000 persons.
- **Metastasis:** 25% of all brain tumors. → lung cancer خاصة من الـ
- **Race:** whites have a higher incidence of malignant brain tumors compared to **blacks.**
- **Gender:** there is a slight **male** predominance.
- **Age:** a peak incidence of all primary brain tumors around **age 45-50.** * بيجوا بأي عمر عادي
- **Glioblastoma:** rarely occurs before the age of 15.
- **Medulloblastoma:** is uncommon after the age of 20.

بتيجي عند childhood > من Glioblastoma

# Classification of Brain Tumors

1. Primary or secondary (metastatic). → lung, liver
2. Location. prostate, thyroid
3. Tissue of origin → بعد مناخذ Biopsy
4. Grading: microscopic appearance.

* عرض الدكتور Case أول سلايدة ||

← 62y ♀ ، الها اسبوعين

بتقدرش تحكي أسماء ال object (نسيم)

و آخر ٣ ايام صار Rt hand weakness

Rt arm paresis , motor aphasia وعنها

ECG : sinus rhythm normal

X-ray , Blood test normal , ↑ deep tendon reflex

: الحالة زي مملاحظين Prognessive

مش شيء sudden .

عملنا Brain CT //

في mass عاملة Compression على

IF. lateral ventricle ، وفي الـ Cortex

في ( finger like edema)

← suspect tumor

فهنعطي Contrast ، هنلاقي الـ mass

شفطت الـ contrast يبقى

( Brain tumor )

## WHO Classification of Brain Tumors - 2007

1. Tumors of neuroepithelial tissue.
2. Tumors of cranial nerves.
3. Tumors of the meninges.
4. Lymphomas & hematopoietic neoplasms.
5. Germ cell tumors.
6. Tumors of the sellar region. → pitutiary gland tumor
7. Metastatic tumors.

## Classification of Primary Brain Tumors According to Histopathology

- **Astrocytic tumors:** Astrocytoma, Glioblastoma.
- **Oligodendroglial tumors:** Oligodendroglioma.
- **Ependymal tumors:** Ependymoma.
- **Choroid plexus tumors:** Choroid plexus papilloma, choroid plexus carcinoma.
- **Neuronal and mixed neuronal-glial tumor:** Ganglioglioma.
- **Embryonal tumors:** Medulloblastoma.
- **Germ cell tumors:** Germinoma, teratoma.
- **Menigeal tumors:** Meningioma .
- **Tumors of cranial and paraspinal nerves:** Neurinoma or neuroma (Schwannoma), Neurofibroma.
- **Mesenchymal tumors:** Lipoma (→ benign), angiolipoma, liposarcoma (→ maligrant), fibrosarcoma, rhabdomyoma, rhabdomyosarcoma, chondroma, chondrosarcoma, osteoma, osteosarcoma, hemangioma (↓ benign), angiosarcoma (↓ maligrant).

## Glioma

← ال Tumor دة كله malignant
حسب ال more benign فيهم هوا
Grade ①

- Gliomas account for over **80%** of primary CNS malignancies.
- The term "glioma" refers to tumors believed to be derived from glial cells.
- For definitive diagnosis, biopsy needed.
- **Gliomas are grossly devided to:** ✓ حسب Biopsy مسموحا ل
  - ✓ Low grade gliomas.
  - ✓ Intermediate grade.
  - ✓ High grade gliomas (more malignant).

## Meningioma

ورم حميد

- 15% of brain tumors.
- Slow growing tumor, usually benign.
- **Common locations:** parasagital, hemisphers convexity, sphenoid, olfactory groove, sella turcica, cerebello-pontine angle.

✓ احب ♀ y27 للدكتور ب facial hemispasm
involuntary deviation لل face على جهة وحدة طلع السبب
بالآخر / (cerebello-pontine angle meningioma)

Grade 1 → Pilocytic astrocytoma

low grade, well differentiated

Grade 2 → Diffuse astrocytoma

intermediate grade, moderately differenti-

Grade 3 → anaplastic astrocytoma

high grade, Poorly differentia-.

## Large Parasagital Meningioma

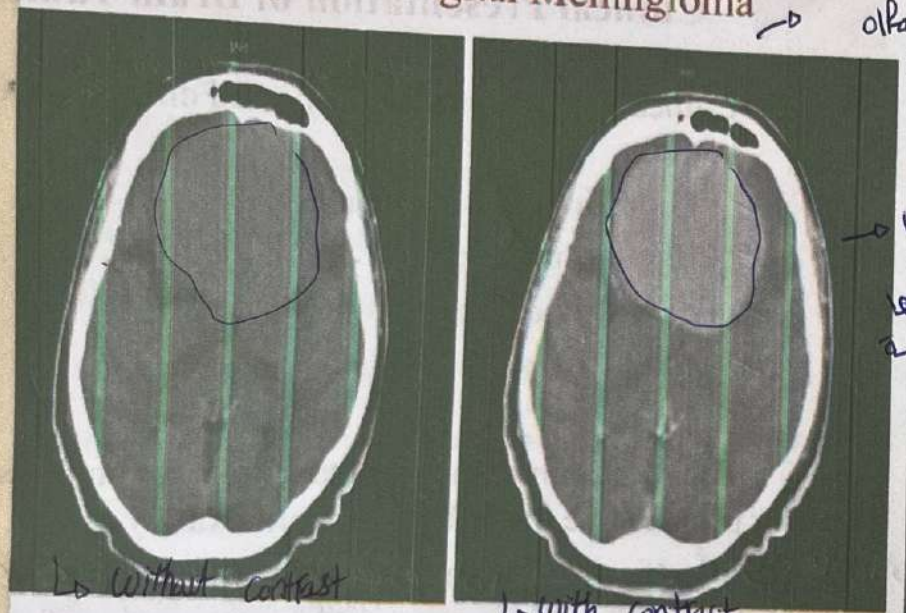


## Metastatic Brain Tumors

"Secondary Brain Tumors"

- **15-30%** of cancer patients develop cerebral metastasis.
- **80%** of metastasis located in cerebral hemispheres.
- **16%** of metastasis located in cerebellum.
- **Median survival** with maximum treatment 8 months.

## Route of Metastatic Spread

- Usually hematogenous.
- Sometimes local extension.

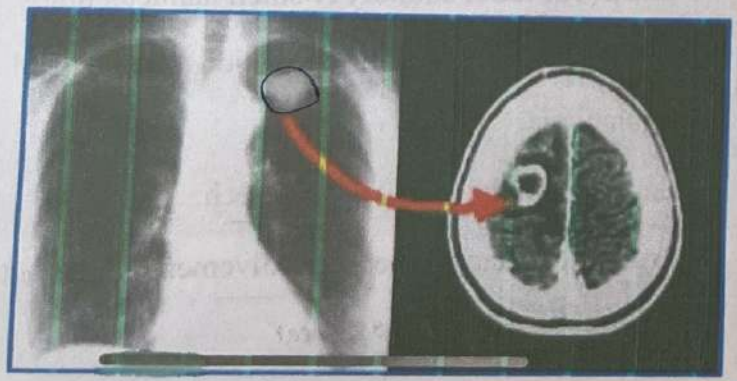

## Brain Metastasis

**Originate from malignant tumors located primarily in other organs:**

- **Lung:** small cell carcinoma → most common
- **Breast:** breast carcinoma.
- **Kidneys:** hypernephroma.
- **Skin:** malignant melanoma.
- **GIT:** colon carcinoma
- **Thyroid gland.**
- **Gynecologic tumors:** ovarian carcinoma.
- **Prostate.**

## Sources of Cerebral Metastasis in Adults

| Primary | % |
|---|---|
| ➢ Lung | 44 % |
| ➢ Breast | 10 % |
| ➢ Kidney | 7 % |
| ➢ GIT | 6 % |
| ➢ Melanoma | 3 % |
| ➢ Undetermined | 10 % |

malignant cell اكثر مكان بيصدر to brain ..

## Clinical Presentation of Brain Tumors

- Clinical presentation depends and differs according to the:
  - ✓ Location of the tumor.
  - ✓ Type of the tumor.
  - ✓ Size of the tumor.
  - ✓ Stage of the tumor.
- The most common presentation of brain tumors is progressive **neurologic deficit, usually motor.**

* ممكن يكون الله شهر شهرين عنده الورم لكن فش أعراض ، فجأة الورم
دة نزف فيجي العيان بأعراض hemorrhagic CVA

## Clinical Presentation Signs & Symptoms

قبلها بيجوا ب

- **Nonfocal or Generalized**
  - Headache,
  - Seizures,
  - Nausea, vomiting,
  - Depressed level of consciousness,
  - Cognitive impairment.
  - Papilloedema

↑ICP

- **Focal Neurologic Deficit**
  - Weakness,
  - Sensory loss,
  - Speech difficulty: dysarthria or aphasia,
  - Hearing dysfunction,
  - Visual dysfunction.

حسب مكان الورم

## Focal Neurologic Deficit

- **Frontal lobe:** hemiparesis, personality changes, expressive aphasia., epilepsy , convulsion , depression
- **Parietal lobe:** contralateral sensory loss, asteriognosis. لقدرش يعرف الاشياء باللمس وهو مغمض
- **Temporal lobe:** auditory & smell hallucinations.
- **Occipital lobe:** visual hallucination, contralateral hemianopia,
- **Cerebellum:** ataxia, slurred speech.
- **Brain stem:** cranial nerve involvement, long tract abnormalities. , loss hear , occular symptom bulbar //

## Diagnostic Procedures

- **Chest X-Ray.**
- **CT:** neck, chest, abdomen, pelvis.
- **Stool analysis:** for occult blood.
- **Mammogram:** in women. → ± Breast Cancer
- **Brain CT:** with and without contrast.
- **Brain MRI:** with and without contrast. → sensitive أكثر
- **Positron Emission Tomography (PET):** for small malignancies detection.
- **Biopsy.**



## Meningioma - CT

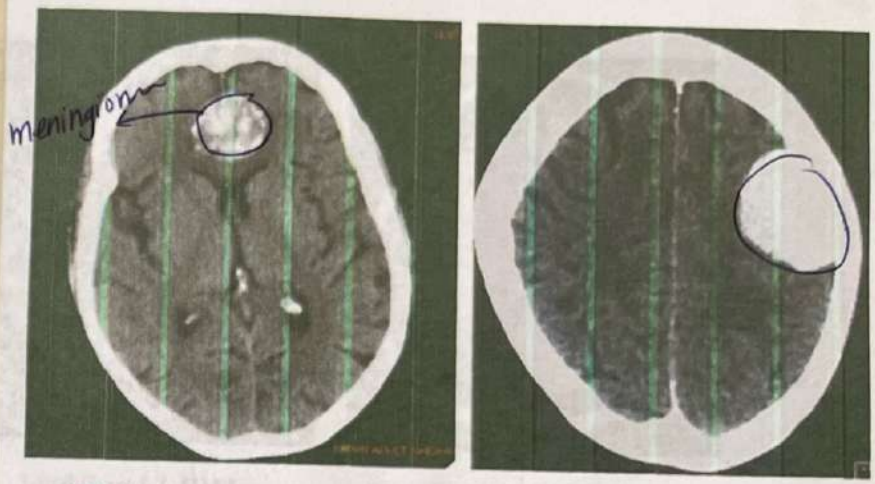


CT without contrast: Calcified Falx Meningioma

CT with contrast: Meningioma Convexity

## Meningioma - MRI

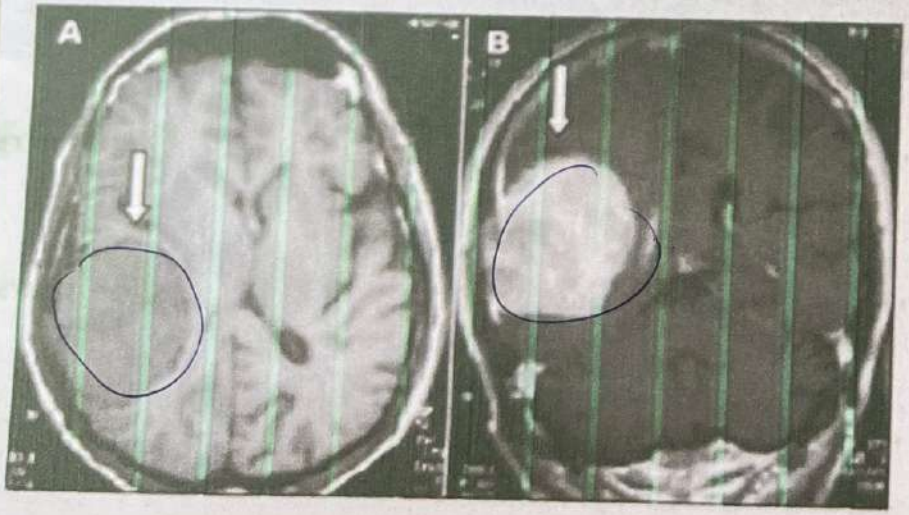


Axial T1 weighted MRI without contrast

Coronal T1 weighted MRI with contrast

## Glioblastoma Grade IV

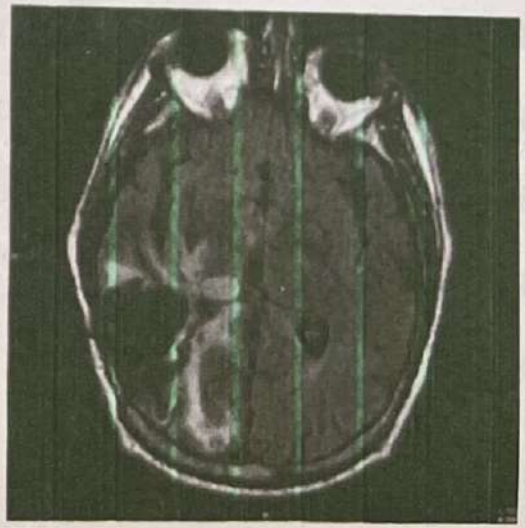

# Astrocytoma

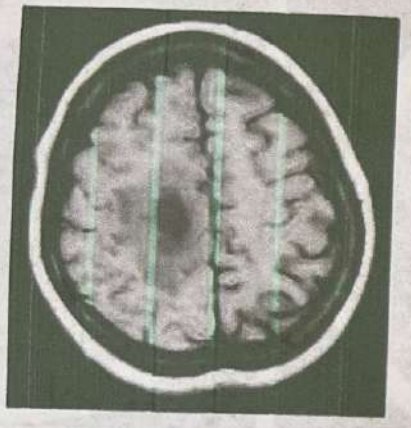

MRI T1 weighted



MRI T2 weighted

حواليها
edema
Vasogenic
[Finger like appearance]

# Management of Malignant Brain Tumors

- Surgery.
- Stereotactic radiosurgery: Gamma Knife Surgery.
- Radiotherapy.
- Chemotherapy.
- Conservative therapy:
  analgesics, steroids, manitol, AED, antiemetics.
  antiepileptic
- Combine therapy.
- Medical rehabilitation and physiotherapy.



Gamma Knife Surgery

# Roles of Radiotherapy in Brain Tumor

- **Incomplete surgery.** ✓ الجراح ما شال كل الورم فنكمل بالاشعاعي
- **Deep brain tumor:** midbrain, pons. ✓ الورم deep مش قادر يوصله الجراح ↳
- **Radiosensitive tumor:** medulloblastoma.
  ↳ تستجيب للاشعاعي
- **Pituitary adenoma.**
- **Palliation:** metastatic lesions.

↳ ↓ growth rate of tumor

↑ survival rate يعيش سنة بدل 8 شهور

# Grade & Median Survival in Astrocytomas

| Grade | Median Survival |
|---|---|
| ❖ Grade- 1: Pilocytic astrocytoma | 8-10 years |
| ❖ Grade- 2: Diffuse astrocytoma | 7-8 years |
| ❖ Grade- 3: Anaplastic astrocytoma | 2-3 years |
| ❖ Grade- 4: Glioblastoma | < 1 year |

# Glioblastoma

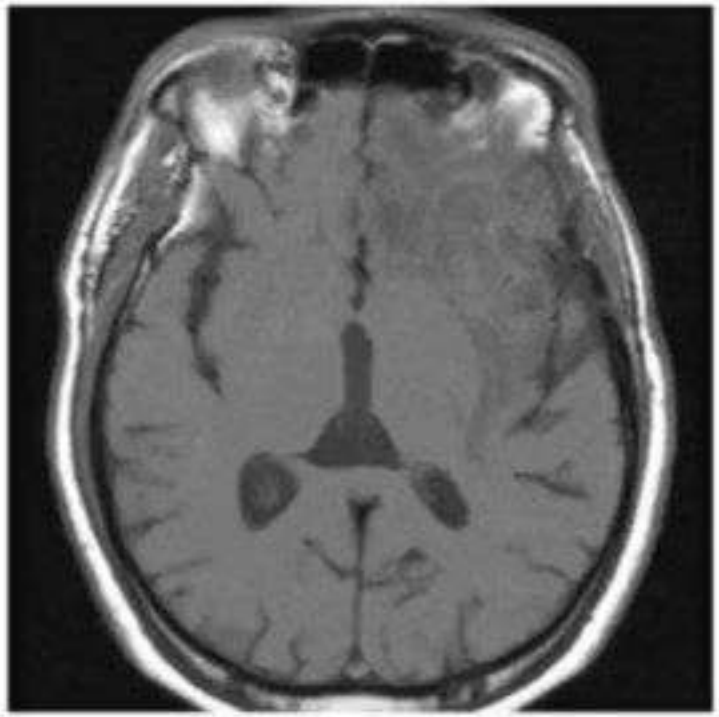

MRI T1 weighted

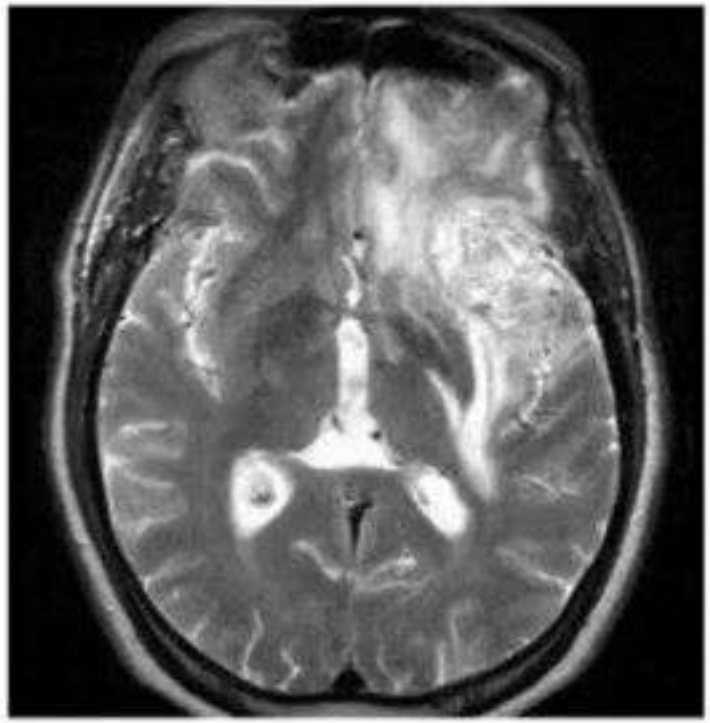

MRI T2 weighted

# MRI: Low Grade Gliomas

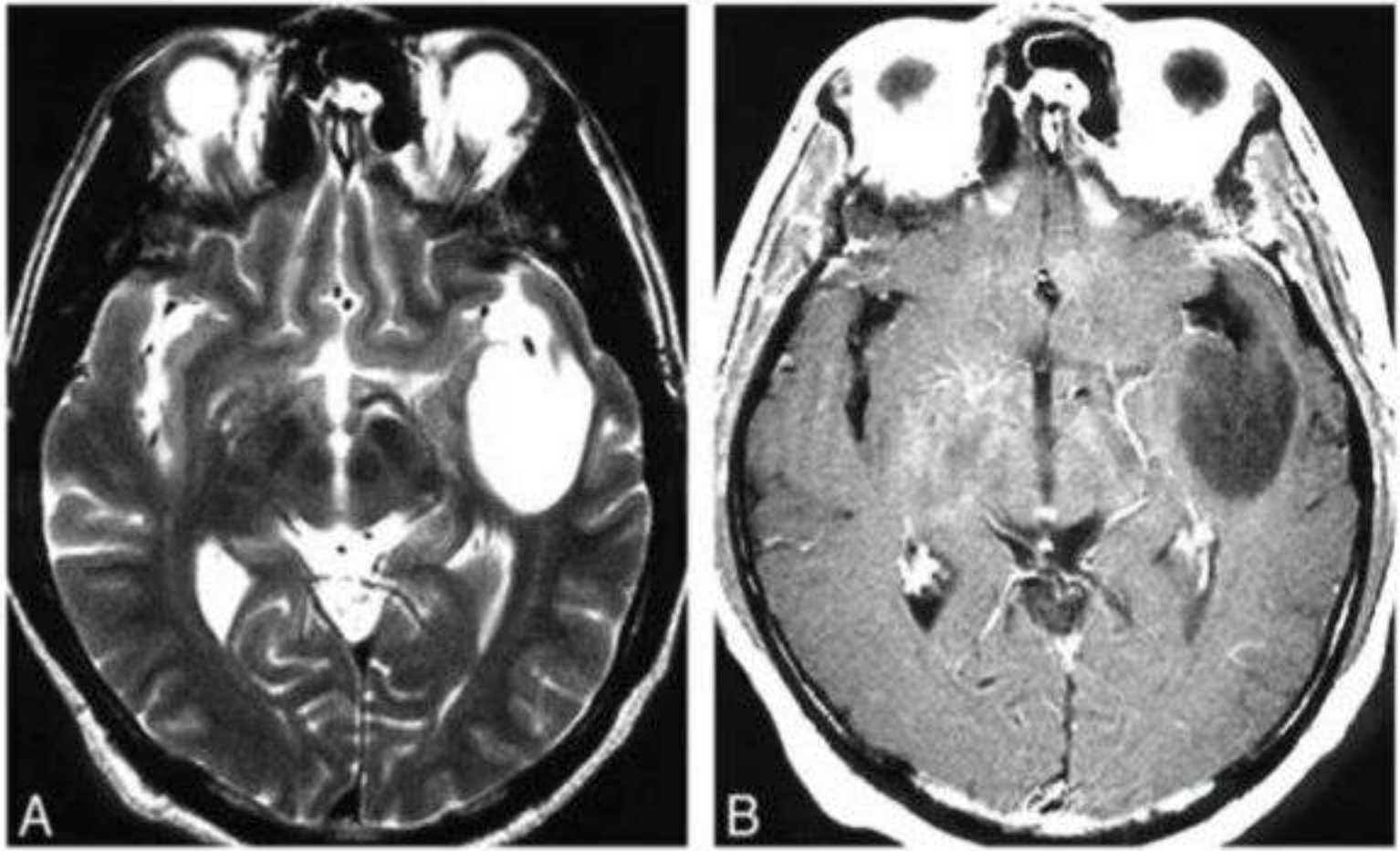

# MRI: High Grade Glioma
# Anaplasic Astrocytoma
# "Grade III"



# MRI: Grade IV Glioma
# High Grade Glioma "Glioblastoma"

