Appendicitis in children

Dr. Elias arteen
FRCSI
Consultant surgeon

* The greater omentum is more developed in children so the seling of perforation better in adult
* In children may have generalized peritonitis so we operate it if there is peritoneal irritation...

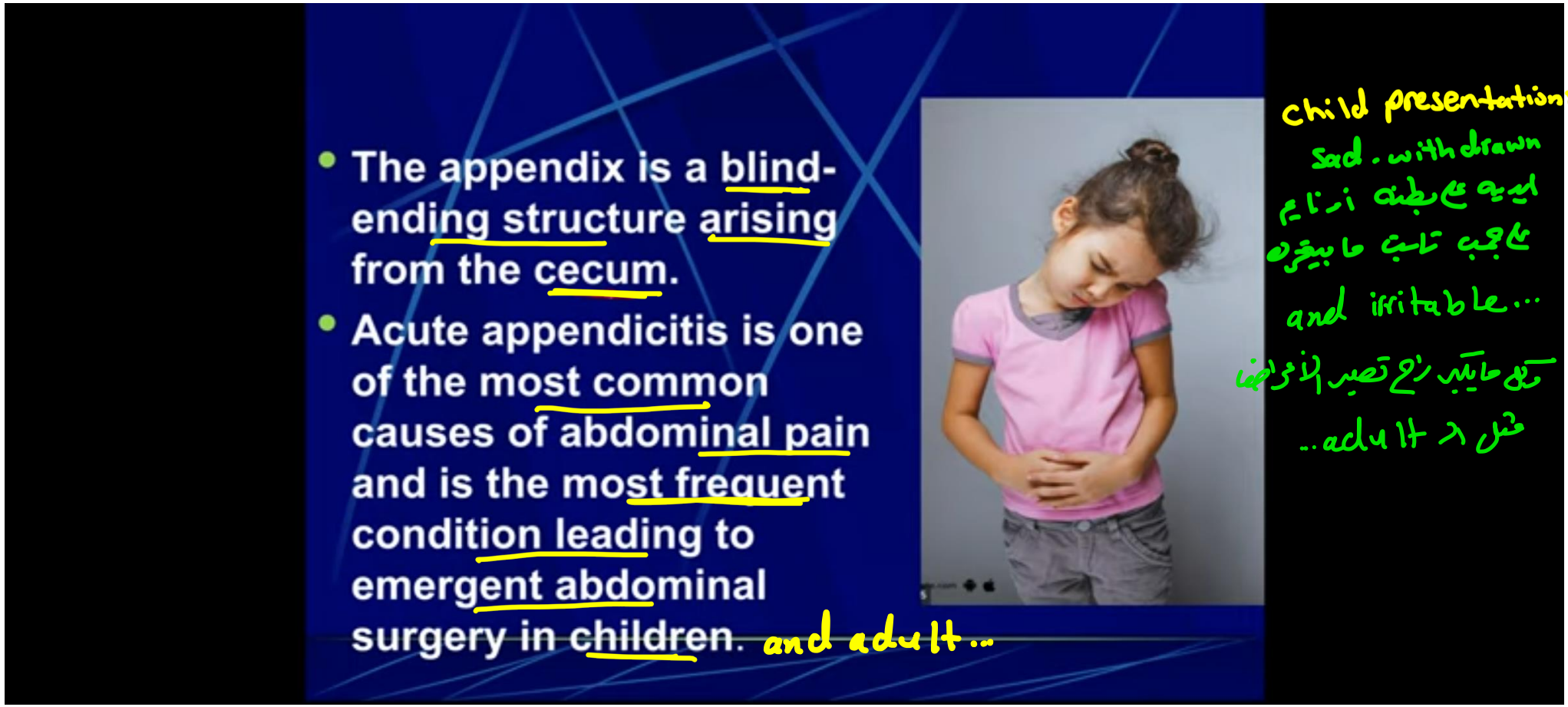

* The appendicitis after 5days not treated by surgery [mass or abcesses ← need drainage.

* perforated appendix :- give them antibiotic then after 6-8 weeks we can operate it...

- usually conservative ++
- more in adult...

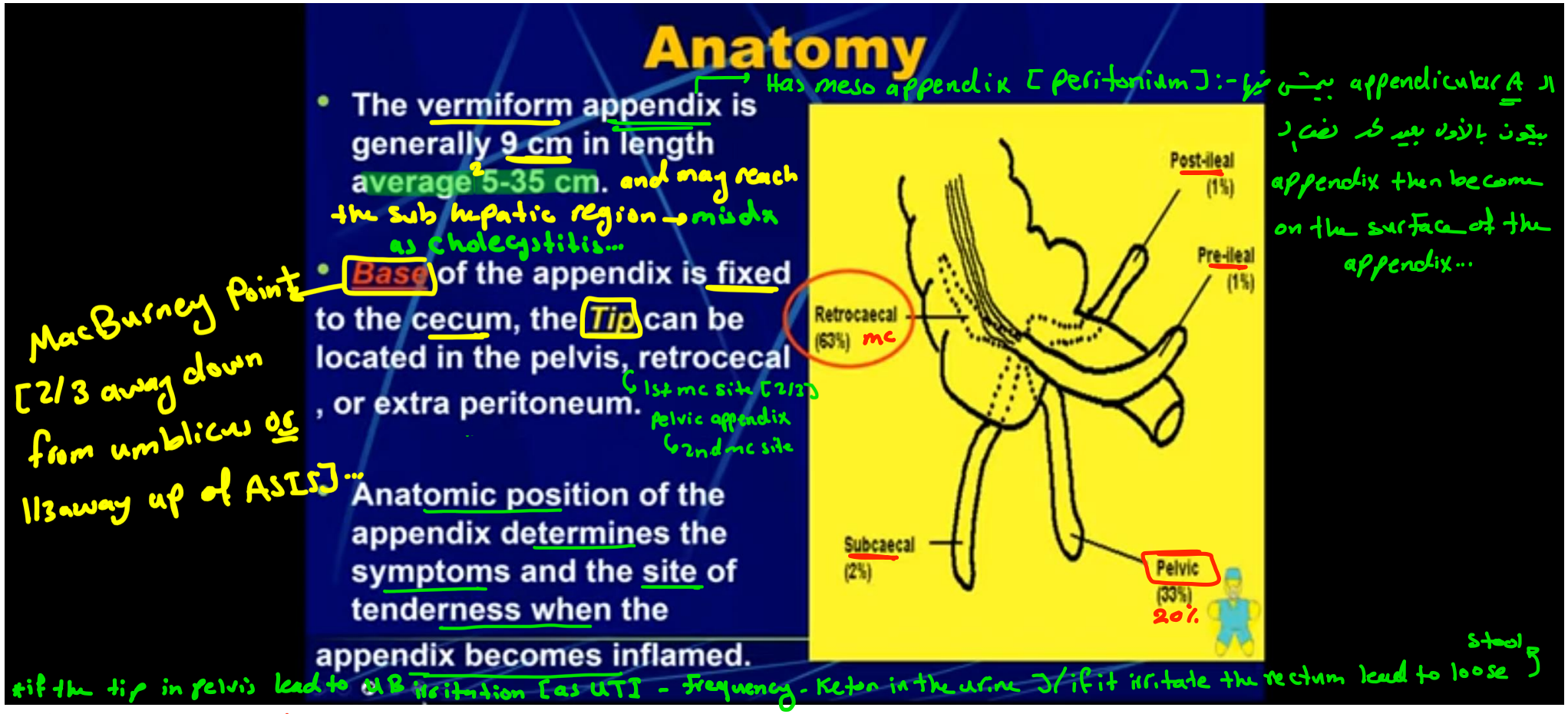

Has meso appendix [peritonium]:- بيخلي appendicular A ال بيكون بالأول بيه كده بعدين appendix then become on the surface of the appendix...

MacBurney Point [2/3 away down from umblicus or 1/3 away up of ASIS]...

and may reach the sub hepatic region → misdx as cholecystitis...

1st mc site [2/3] pelvic appendix
2nd mc site

mc

20%

if the tip in pelvis lead to UB irritation [as UTI - frequency - Keton in the urine] / if it irritate the rectum lead to loose stool

* The retrocecal appendix symptoms mainly → Atypical..
* The pelvis appendix lead to rectum or UB irritation → diarrhea - frequant urination - hematuria [as UTI]

* The retrocecal position of the appendix:- The appendix lie behind the ceccum in 67% of cases...

* The retrocecal appendicitis:- ATypical sign and symptoms may presented by renal colic [diff. them by rebound tenderness]...

* The UTI and gastroentritis :- [mis diagnosis] appendix مشابه للتشخيص ↙

without garding [involuntry]

Has garding [typical for appendix] if it present do surgery

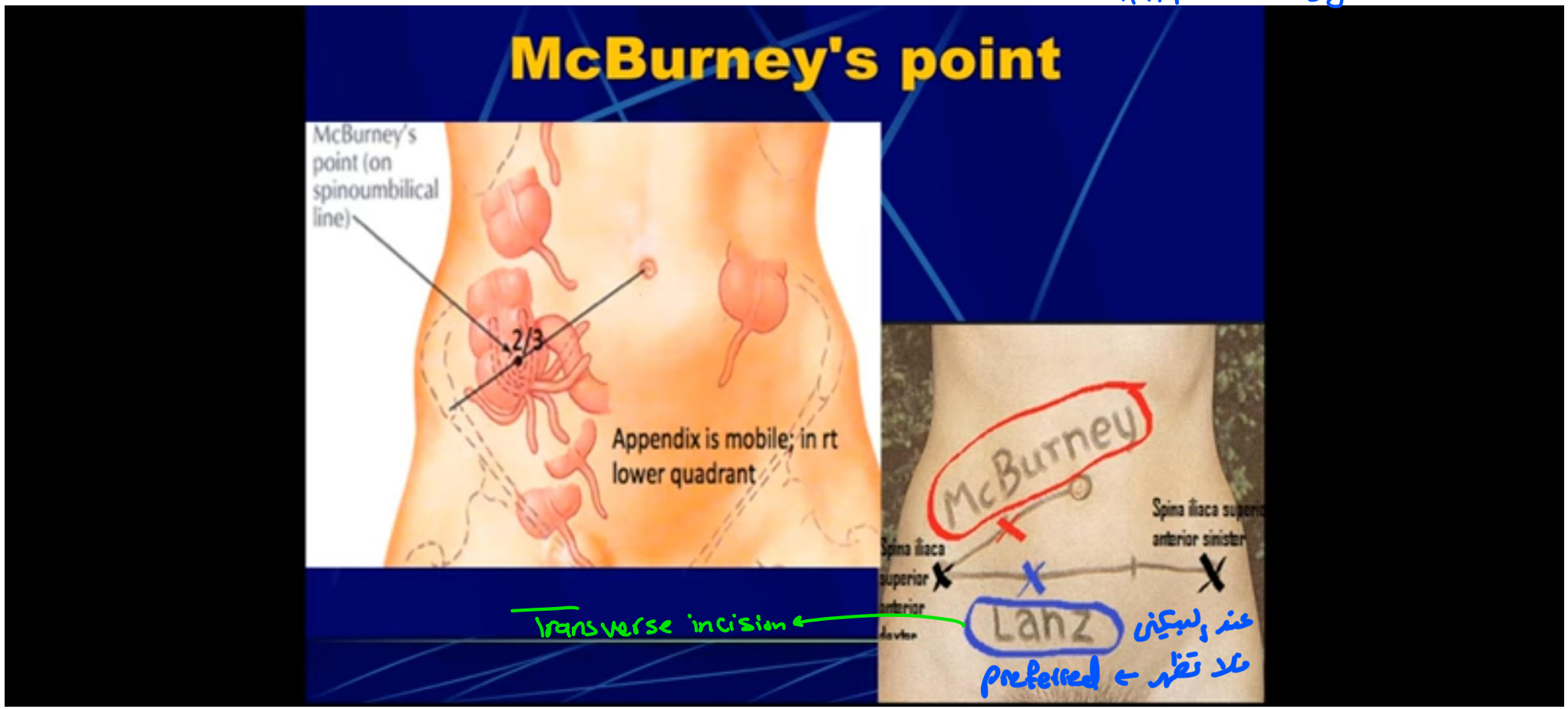

* The First Branch of the SMA is Middle colic A.

* The SMA → ileocolic A (from Rt side) → appendicular A. OR IMA → post devision of caecal A. → appendicular A.

* The proximal 1/2 of appendicular A. far from appendix But the distal 1/2 on the surface of the appendix

↳ patent جيد

↳ may be obstract if there is swollen...

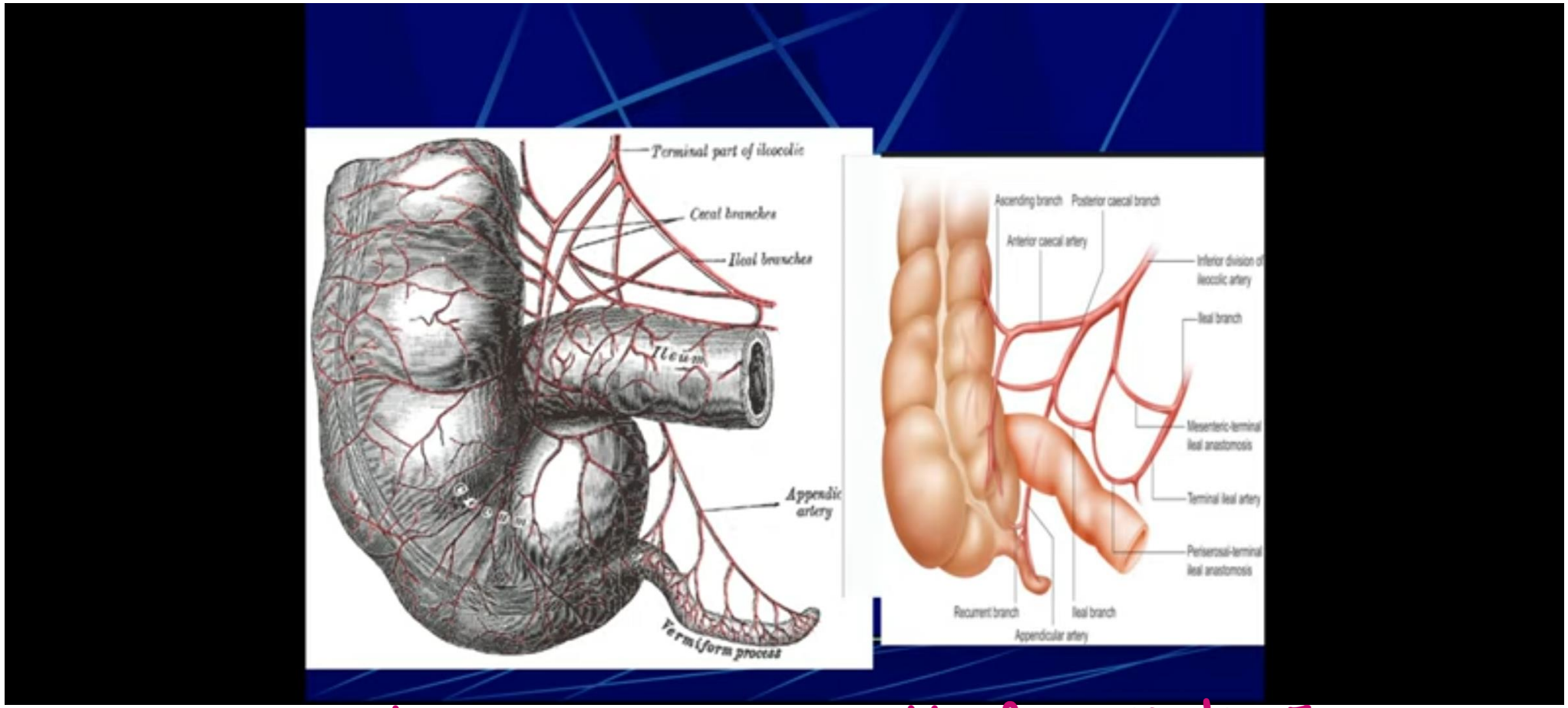

* The perforation of the appendix occur usually at the middle of the appendix [where the appendicular A become at the surface of the appendix... → distally [the appendicular A. away]

* The perforation rarely occur in the Base of the appendix...
Usually Clear...

* The caecum is the 1st part of the colon [length = 6cm]...
↳ From the postromedial aspect of it arise the appendix [below the ileocecal valve by 2 cm] and ampolua of vater...

* The incidence of perforation overall :-
15- 20 %.
But in children depend on the age
كل ما بيبدأ يكبر بزيد نقل النسبة لانه بيبدأ يعبر ... صدرجة بتكون زفت

Epidemiology MCQ

- The incidence between birth and age 4 years is low. (but if it occur there is high risk of perforation...)
- The highest incidence is in 2nd decade of life. [the peak age is 15y/o]
- Overall, 7-9 % of people have their appendix removed during their lifetime. [appendectomy]
- The male-to-female (9% / 7%) ratio is approximately 4:3 . M>F
- Appendicitis is much more common in developed countries. [↑fat - ↑protein - ↓fibers]...
- Appendicitis occurs in all age groups but is rare in infants. ↳dz of young adult ↳[No age is immune of getting appendicitis]

* Befor 2y/o all apendicitis is perforated and below 3y/o there is 80 % of apendicitis is perforated...

* 2/3 of appendicitis in children or adult result from the lymphoid hyperplasia and 1/3 from the Fecolith or other material enter inside the very little at birth then become more ↳ non obstructive appendix lumen... ↳ obstructive

* dilated appendix lead to:- BV [venous] compromize then arterial compromize then gangrine...

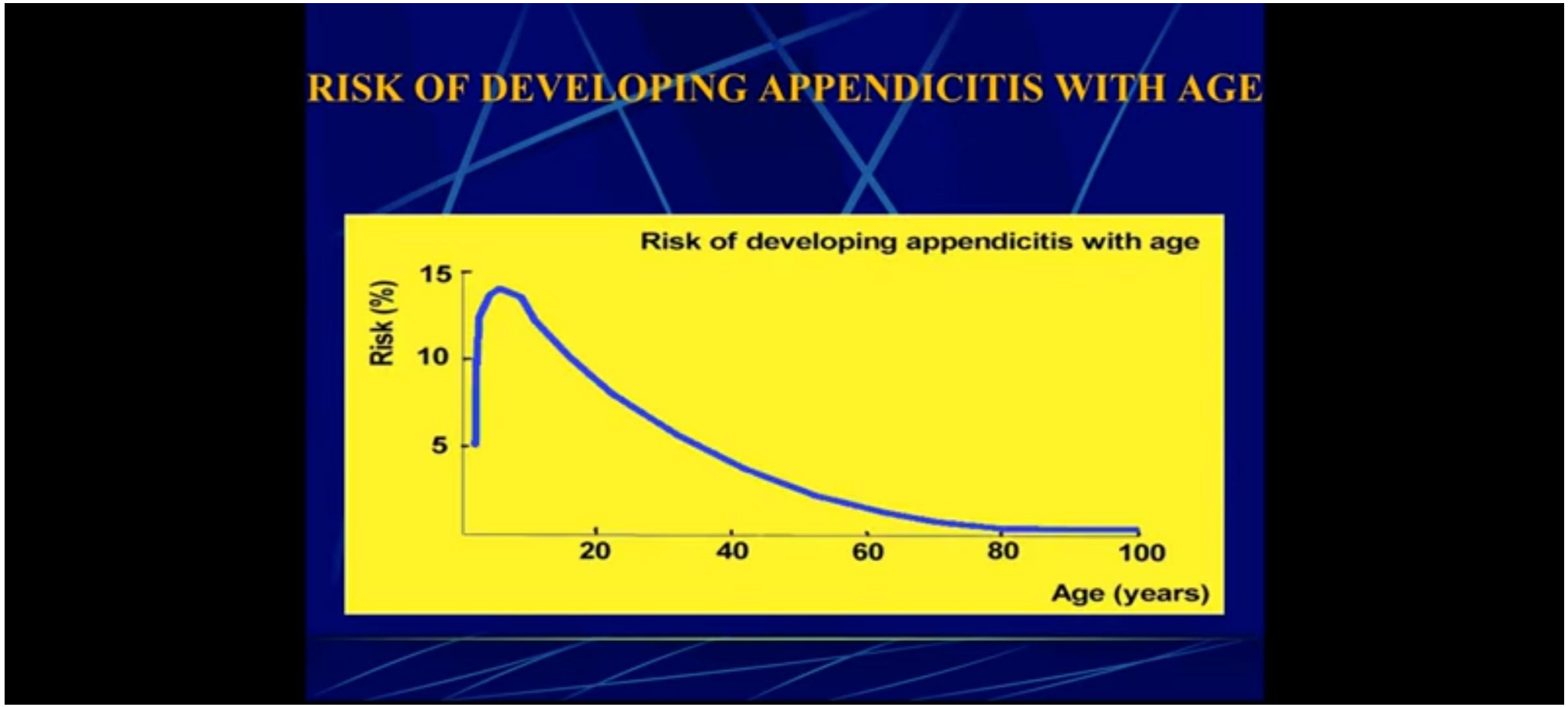

* At birth there is ↓ lymphatic follicle in the submucosa of the appendix + with aging it will increase and may reach 200 at age 10-20 y/o then decreased [at age 30 y/o will decreased 50%]...

* The obstructive appendicitis occur in 1/3 cases in children + the perforation happen faster... [easy quickly]... and destination
the pain more severe

* Non obstructive appendicitis due to inflammation [Ecoli - nonerobic Bacteria]..
  - The pain less obvious
  - May the diameter in US :- 8mm - 1cm ..etc so it more obvious in US ...

so give them antibiotic cover the gram -ve Bacili: and Bacteroid [2nd or 3rd generation cephalosporine or ogmintine]...
as: metranidazole - flagel...

Pathophysiology

① due to hard feces or hypertrophy of the lymphoid follicle in the submucosa..

- Obstruction of lumen, Bacteria Multiply, and the appendix becomes distended distal to obstruction. ② venous congestion..
- The increased intraluminal pressure obstructs venous drainage, and lead to arterial insufficiency the appendix becomes congested and ③ Ischemic. then necrosis then gangrine..
- The combination of bacterial infection and ischemia produce inflammation, which progresses to necrosis and gangrene.
- The progression from non obstruction to ④ perforation usually takes place over 48- 72 hours.
- While perforation was directly related to the duration of symptoms before surgery, the risk was associated more with pre-hospital delay than within-hospital delay.

unlikely occur in hospital

* The surgical site infection more in the open surgery than laproscopic surgery...
  But the pelvic collection more in the laproscopic surgery...

* sudden severe pain - rigid then improved after 2-3hr then peritonitis → localized in adult...
  → generalized in children...

This indicate :- perforated appendix...

* The vesciral pain is paraumblical [has the same dermatome T10]...

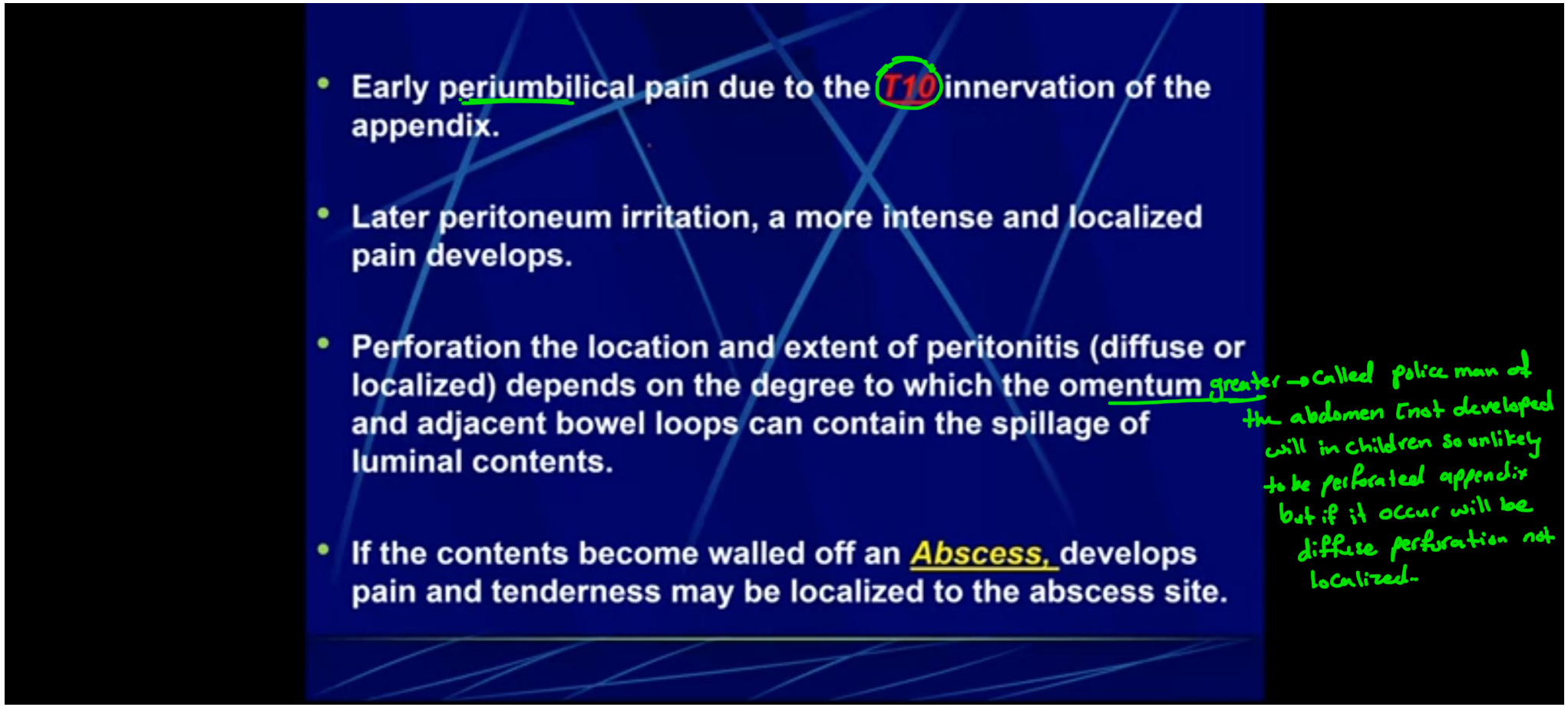

greater → called police man of the abdomen [not developed well in children so unlikely to be perforated appendix but if it occur will be diffuse perforation not localized..

Prognosis

- Generally, the prognosis is excellent. At the time of diagnosis, the rate of appendicular perforation is 20-35%. overall
- The rate of perforation is 80-100% for children younger than 3 years, compared with ~~10-20%~~ 20-30% in children 10-17 years old.
- Children with ruptured appendicitis are at risk for intra-abdominal abscess formation and small bowel obstruction.
- The mortality rate for children with appendicitis is 0.1-1%. and less

is very rare

in children

due to delayed dx: البيبو ما بعرف يشخص التشخيص

كلما كان عمر الطفل أقل راح يزيد perforation الاحتمالية الـ

(1) (2)

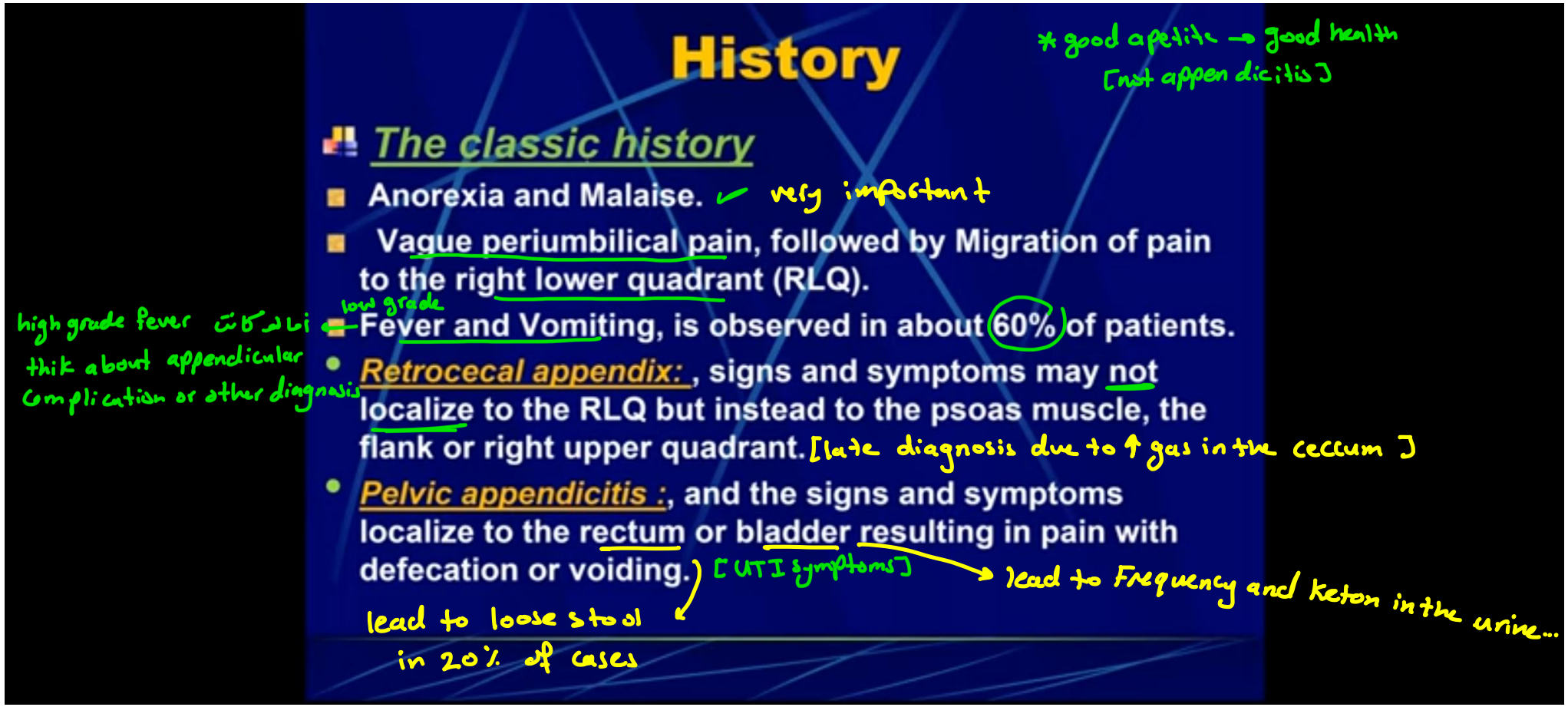
History
* good apetite → good health [not appendicitis]
The classic history
Anorexia and Malaise. ✓ very important
Vague periumbilical pain, followed by Migration of pain to the right lower quadrant (RLQ).
Fever and Vomiting, is observed in about 60% of patients.
low grade
high grade fever تكون لنا
think about appendicular complication or other diagnosis
Retrocecal appendix: , signs and symptoms may not localize to the RLQ but instead to the psoas muscle, the flank or right upper quadrant. [late diagnosis due to ↑ gas in the ceccum]
Pelvic appendicitis :, and the signs and symptoms localize to the rectum or bladder resulting in pain with defecation or voiding.
[UTI symptoms]
lead to Frequency and keton in the urine...
lead to loose stool in 20% of cases

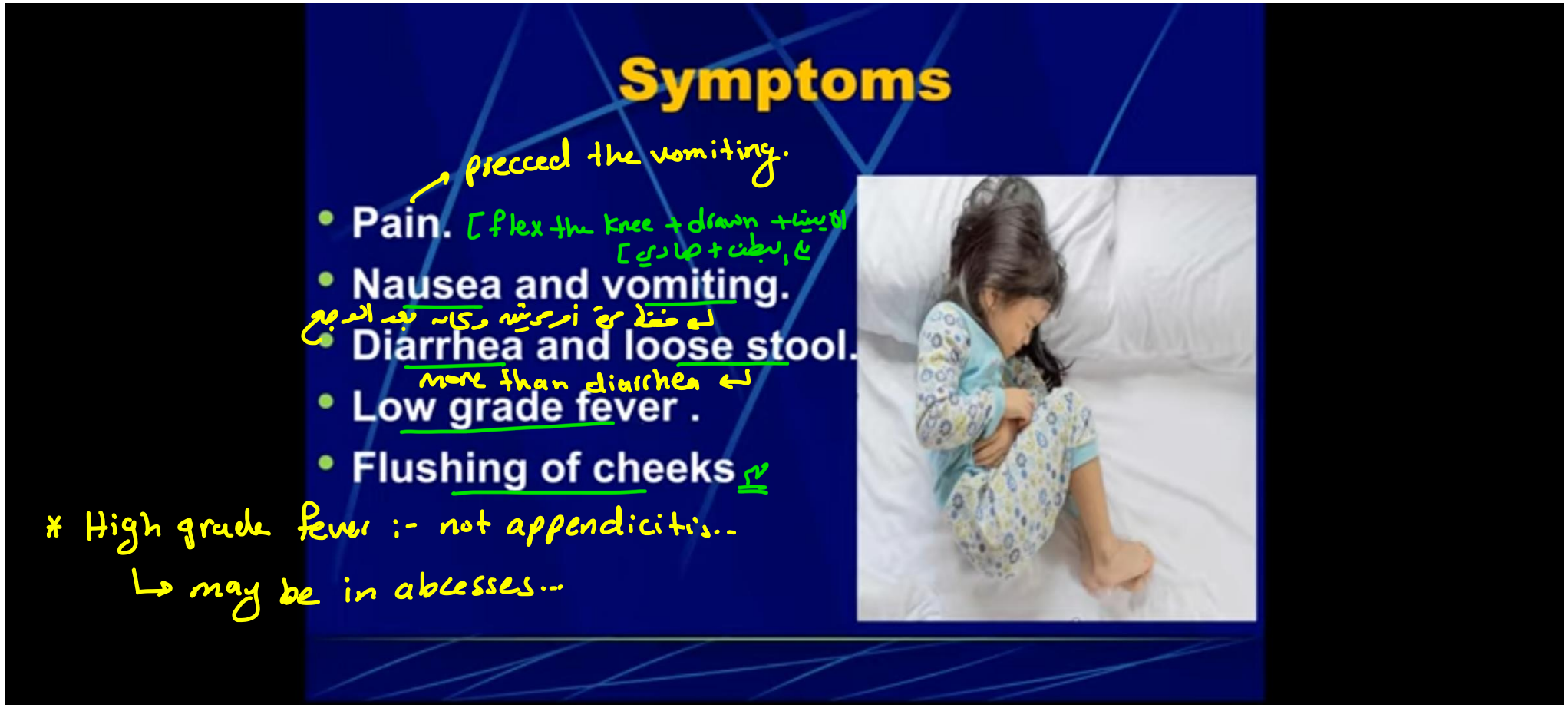

* High grade fever :- not appendicitis..
↳ may be in abcesses...

* 50 % of RIF pain is non specific abdominal pain [no garding - not getting worse]...

* The sensitivity of US in appendix is very hig [in adult]
↳ operator dependent...

* The Fat stranding seen in:- cancer and inflammation...

...accuracy of CT or US ال تقل ~ بسبب ← كل حكا

Physical examination

- The physical examination findings in children may vary depending on age. [↓age → ↑risk of perforation]
- *Irritability is the only sign of appendicitis in a neonate.*
- Older children often seem uncomfortable or Withdrawn. They lie still due to peritoneal irritation. كل ما يتحرك بيزيد الوجع
- Teenaged patients often present in a classic or near-classic fashion.
- Examination of the child requires skill, patience, and warm hands.
- The examination should be thorough and start with areas other than the abdomen. [start away of tender area]
- It is also important to exclude Urinary Tract Infection (UTI) as a cause of abdominal pain. and gastroenteritis...

Abdominal examination

- Full exposure of the abdomen is key.
- Ask child to point with *One Finger* to the site of maximal pain.
- Begin palpation of the abdomen at a *Site Distant* to this, with the most tender area examined last..
- *Distracting Questions* maybe helpful to relieve anxiety during the examination.
- Observing the child's *Facial Expressions* during exam is critical.
- Palpation of the abdomen should be performed with a *Gentle and Light Touch*, searching for involuntary guarding

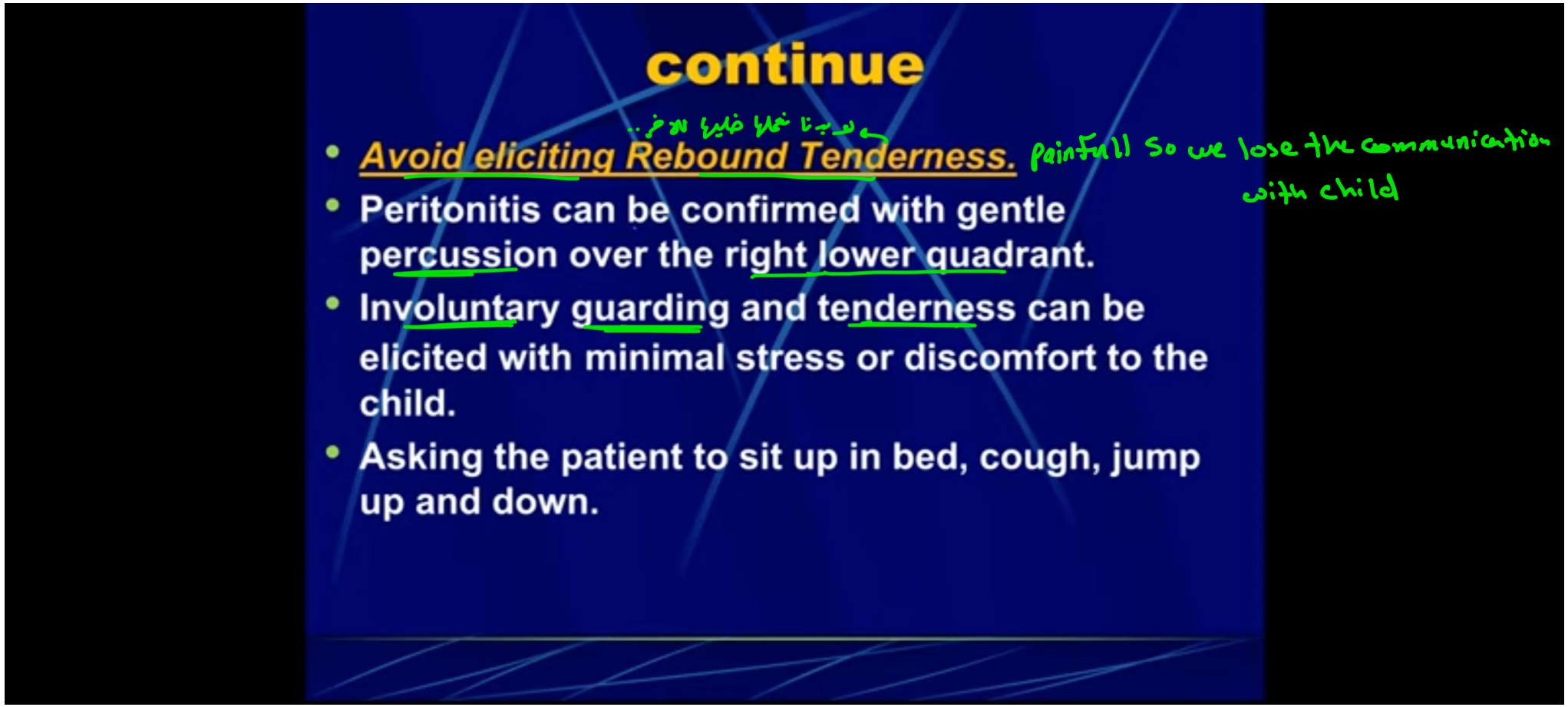
continue
Avoid eliciting Rebound Tenderness.
Peritonitis can be confirmed with gentle percussion over the right lower quadrant.
Involuntary guarding and tenderness can be elicited with minimal stress or discomfort to the child.
Asking the patient to sit up in bed, cough, jump up and down.

Specific signs

- PR exam. (not advisable in children but do it in adult)
- Blumberg sign. (rebound tenderness)
- Rovsing's sign.
- ***Psoas sign.***
- Obturator sign.



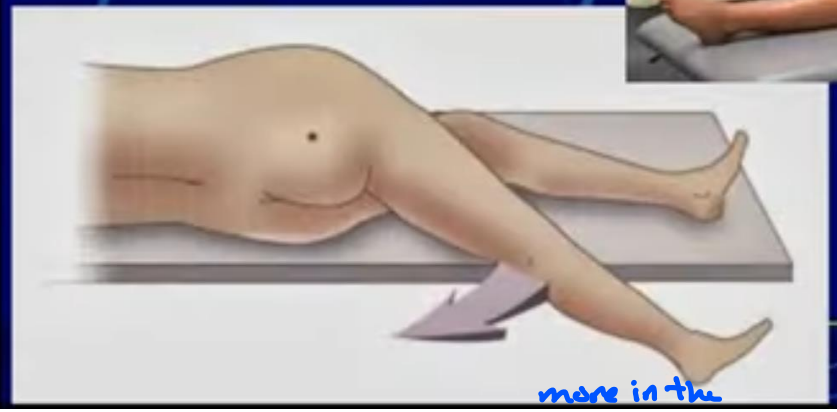

more in the

Blumberg sign

if the pain increase ايبنا تشيل ايدك ← +ve sign

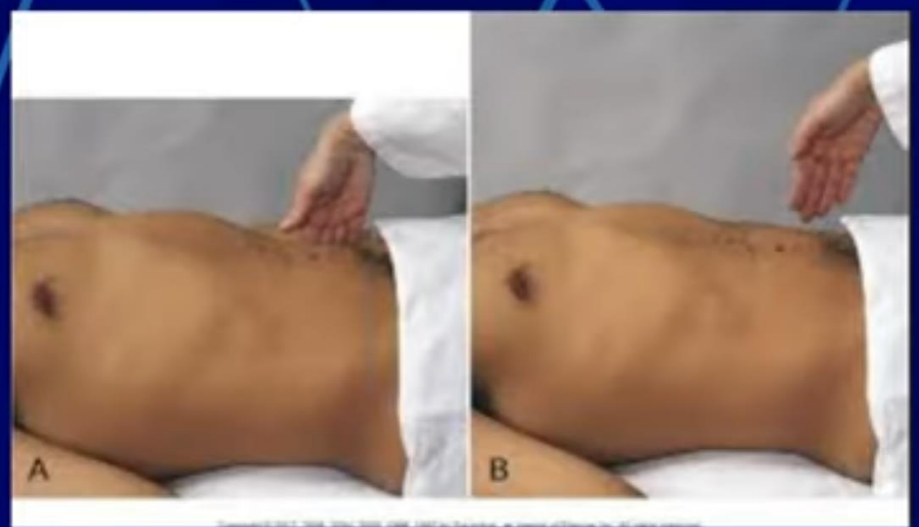

① supine Position
خليه يرفع ال hip لفوق واطول
اضغط انا و لو اتكت تلم جامد
+ve sign. ← pain

② lateral position.
extention of hip ممكن
lead to pain indicate
+ve sign.

irritation of Psoas M.

Psoas sign. done in

supine position — lateral position.

Iliopsoas muscle test. The patient raises the leg from the hip while the examiner pushes downward against it.



CLINICAL FEATURES

PSOA'S SIGN





Psoas sign is right lower-quadrant pain that is produced with the patient extending the hip due to inflammation of the peritoneum overlying the psoas muscles and inflammation of the psoas muscles themselves. Straightening out the leg causes the pain because it stretches the muscles, and flexing the hip into the "fetal position" relieves the pain.

Obturator Sign

irritation of internal O. m. ← Obturator Sign → if we do external rotation of foot → produce pain or internal rotation ↓ +ve sign...

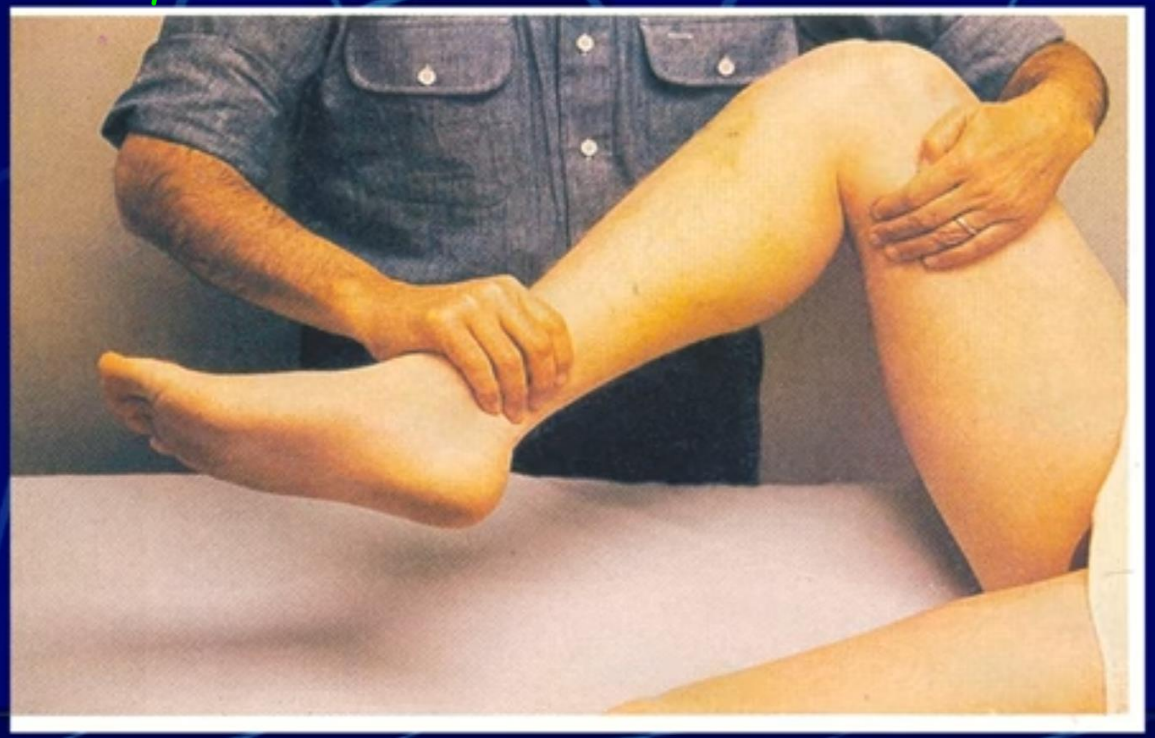

Rovsing's sign. pressure on LIF lead to RIF tenderness [true sign]

ROVSING'S SIGN

- Palpating in the left lower quadrant causes pain in the right lower quadrant

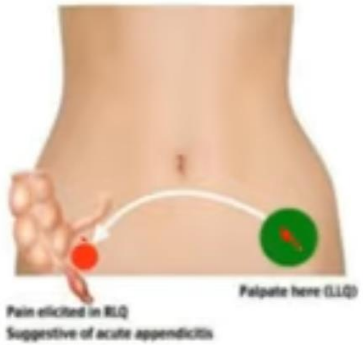

BANGABANDHU SHEIKH MUJIB MEDICAL UNIVERSITY

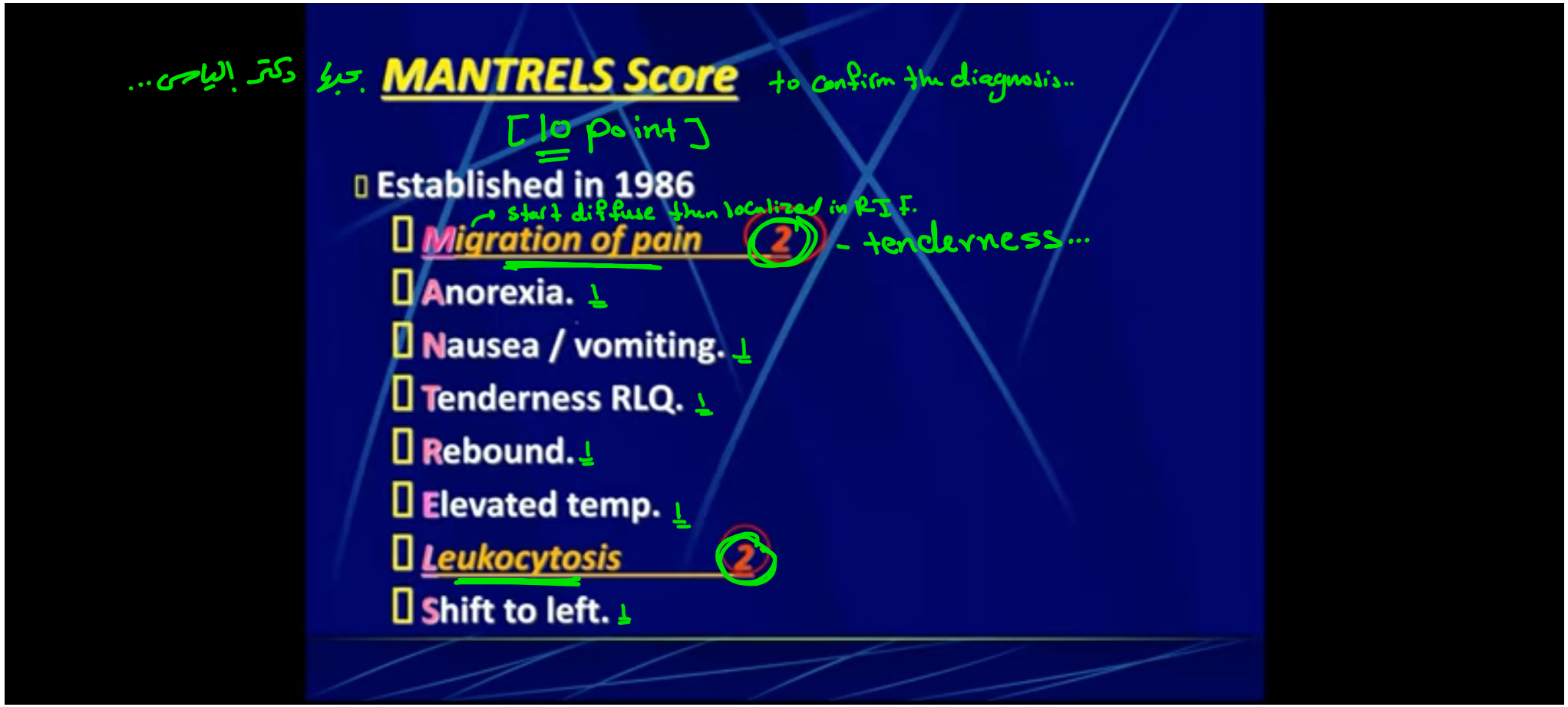
MANTRELS Score
[10 point]
Established in 1986
Migration of pain
Anorexia.
Nausea / vomiting.
Tenderness RLQ.
Rebound.
Elevated temp.
Leukocytosis
Shift to left.

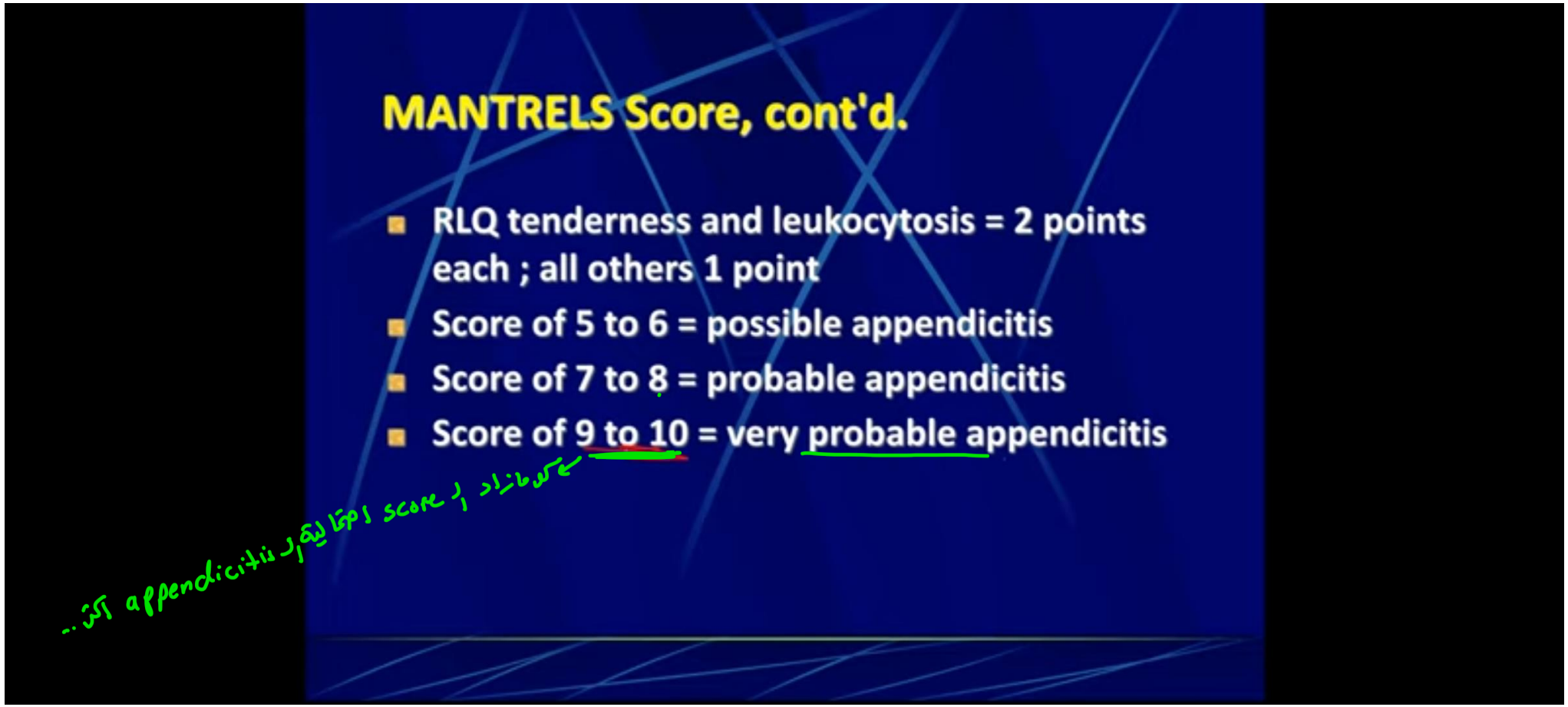
MANTRELS Score, cont'd.
RLQ tenderness and leukocytosis = 2 points each ; all others 1 point
Score of 5 to 6 = possible appendicitis
Score of 7 to 8 = probable appendicitis
Score of 9 to 10 = very probable appendicitis

Alvarado Score



The Alvarado Score

Signs	
Right lower quadrant tenderness	2
Elevated temperature (>99.1 F)	1
Rebound tenderness	1
Symptoms	
Anorexia	1
Nausea or vomiting	1
Migration of pain to right lower quadrant	1
Laboratory Values	
Leukocytosis (>10,000 WBC)	2
Left shift (>75% neutrophils)	1

↳ occurs in 1st day of appendicitis

* if the WBCs > 16000 indicate:- peritonitis or abcesses...

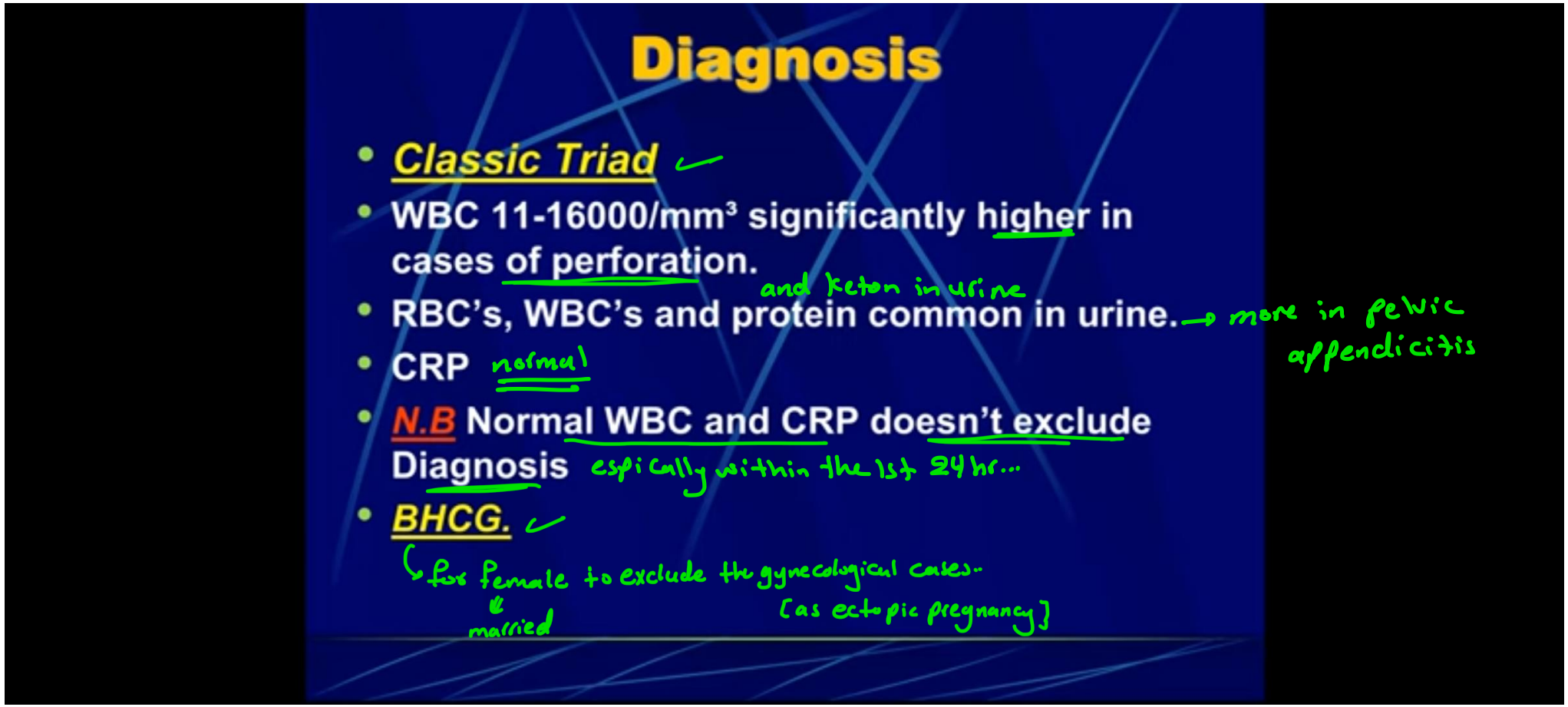

* In children we do US and CT to exclude the gynecological causes...
↳ ↓ sensitive for appendix in children...



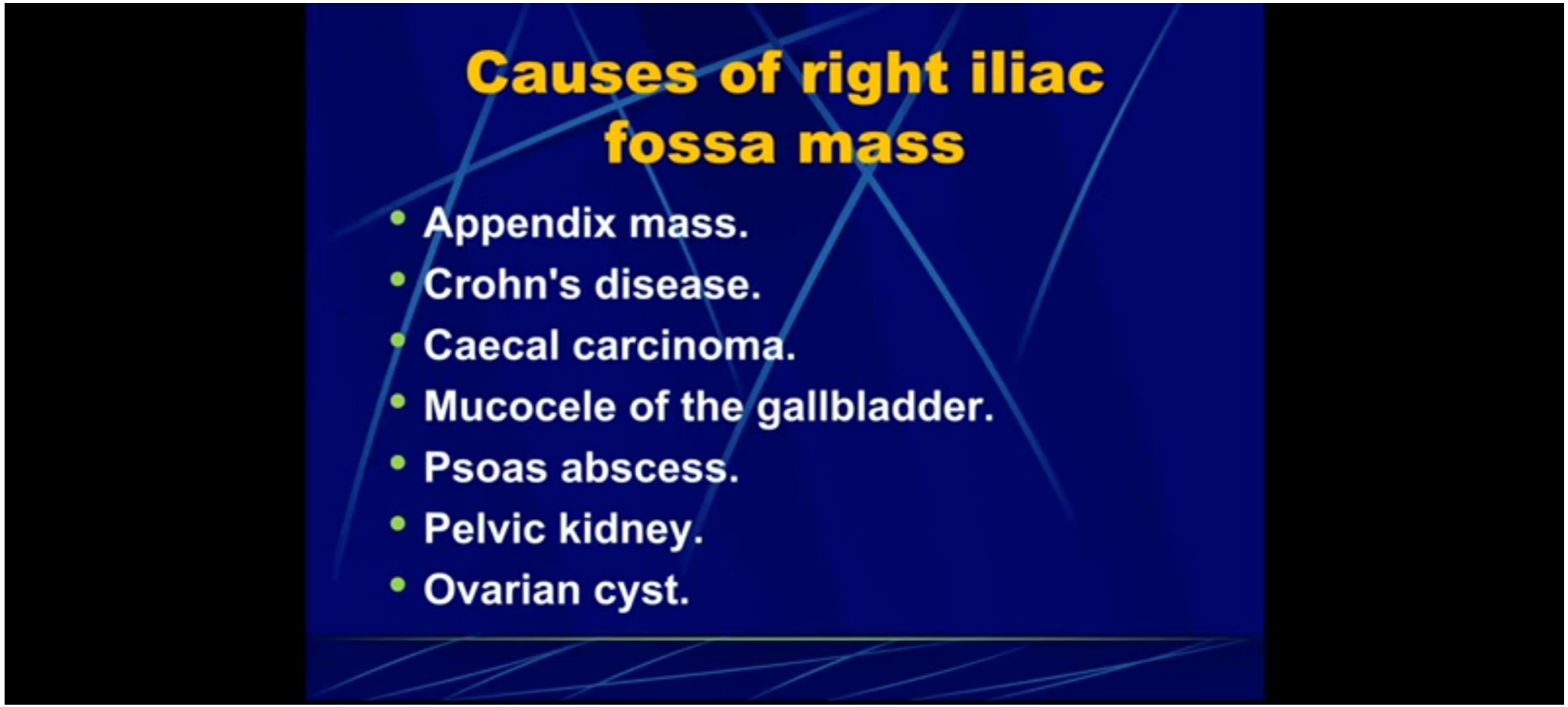
Causes of right iliac fossa mass
Appendix mass.
Crohn's disease.
Caecal carcinoma.
Mucocele of the gallbladder.
Psoas abscess.
Pelvic kidney.
Ovarian cyst.

Abdominal radiology

* we do Plan film abdomen.

- Low sensitivity and specificity. [lateral view]
- Appendicolith specific, but seen in only 10 % [Fecolith]
- May see local air-fluid levels, psoas obliteration, soft tissue mass, gas in appendix : all nonspecific.



in children ← بنعتمد أكتر فيه ع الـ Pure clinical sence

indicate obstruction, appendicitis

or Sentinal gas on Rt I.F...

* No Fat Stranding in Children in US...

US

Appendicitis features

- Appendicular diameter > 6-7 mm (sensitivity 100%, specificity 64%)
- Target sign.
- Non- comprisable.
- Loculated peri-caecal fluid (rupture).
- Appendicolith.
- Absence of gas in appendix lumen.

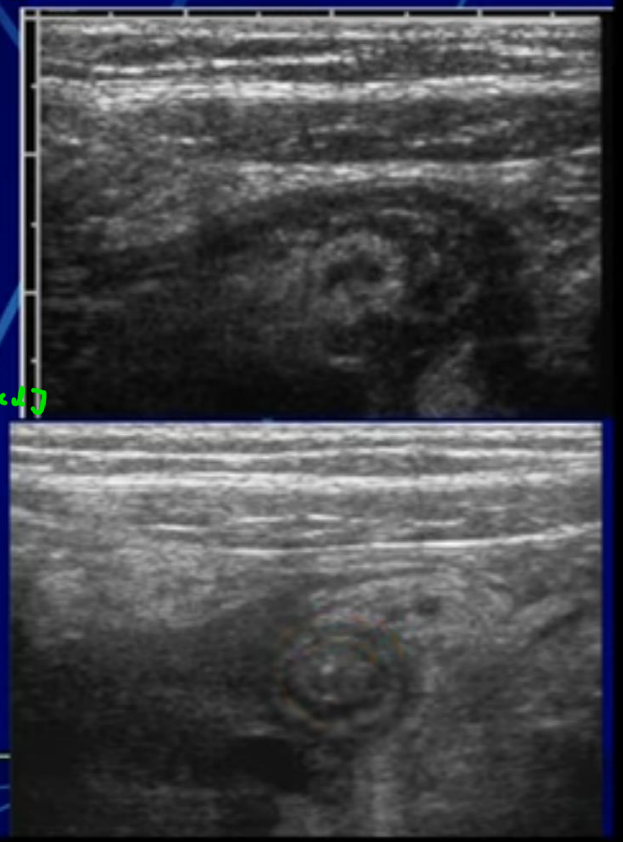



Longitudinal view by ultrasound of enlarged appendix with diameter equal to 13 mm (normal is less than 6 mm).

CT scan

Better than US

لو مختاريه وما

- Accuracy of 93-98% (operator dependant less than US)
- Sensitivity 87-100%
- Specificity 95 -99%

يعني لو طلعت نتيجة بيقول عندك زايدة.

- Enlarged appendix.
- Appendicular wall thickening
- Peri- appendicular fat stranding
- Appendicular wall enhancement

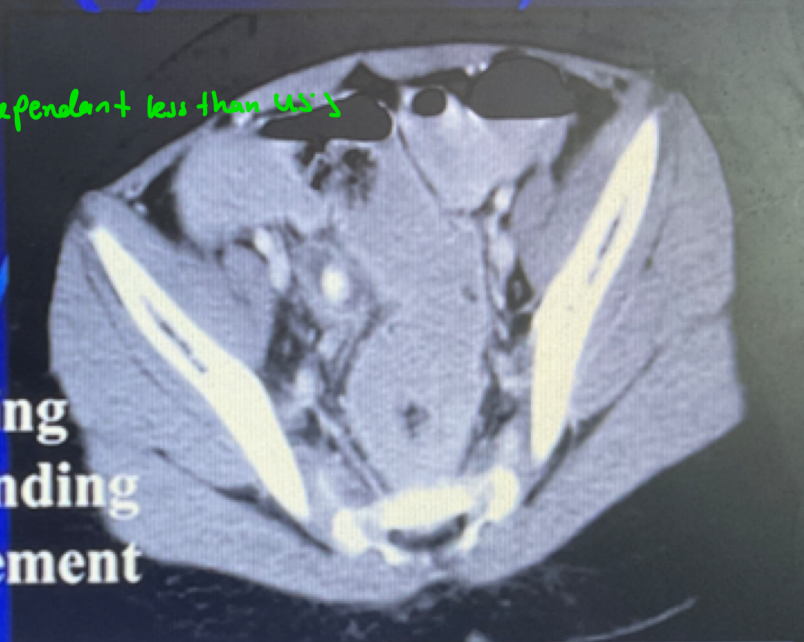

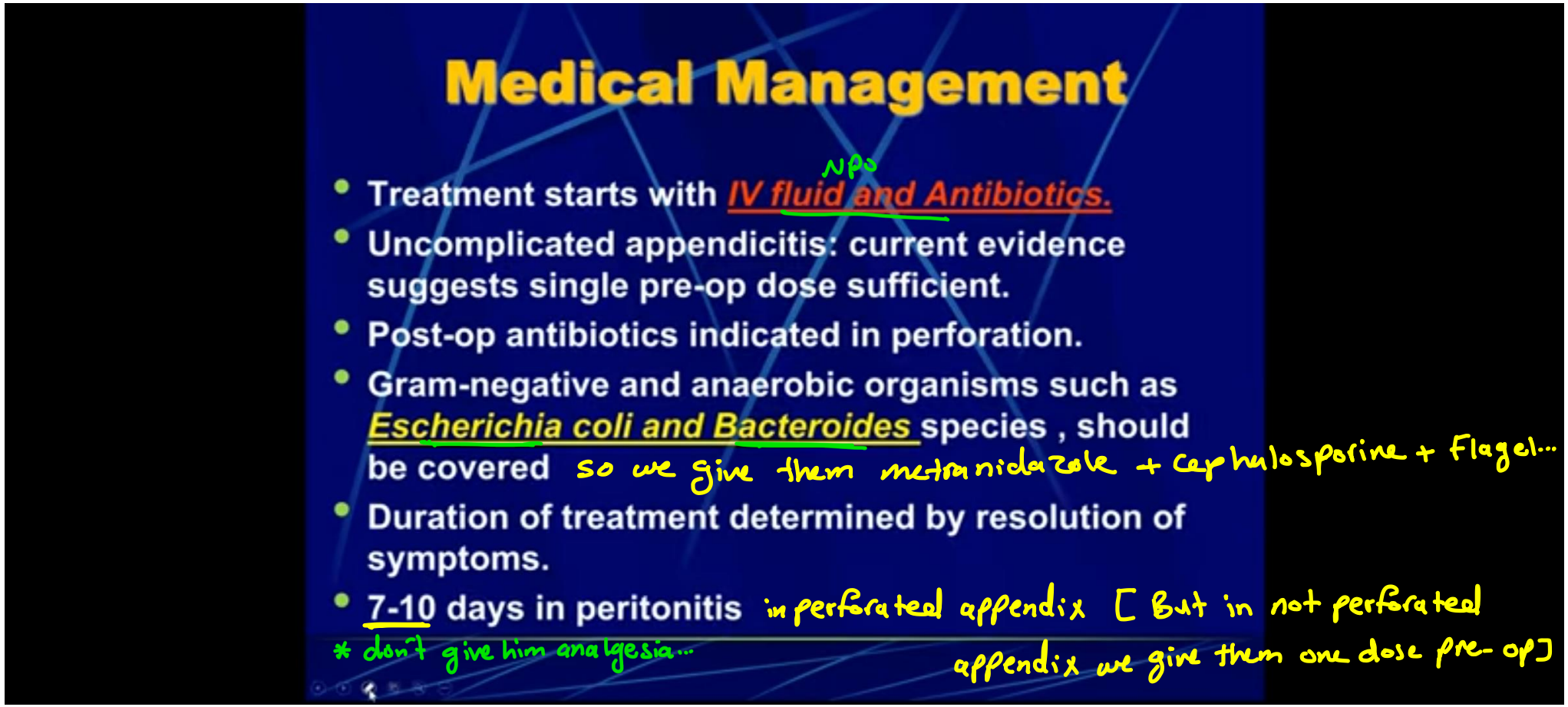

NPO

so we give them metronidazole + cephulosporine + Flagel...

in perforated appendix [But in not perforated appendix we give them one dose pre-op]

* don't give him analgesia...

Antibiotic regimens

- Triple therapy(Ampicillin ,Gentamycin Metronidazole)
- Third generation cephalosporin, and metronidazole
- Early transition to Oral Antibiotics as effective as prolonged IV's .

المستعمل قديماً

المستعمل حالياً

ممكن نبدأ IV وبعديه نكمل oral او الانتيبه نفس الاسبتي حتى حاجة أهم من حاجة ...

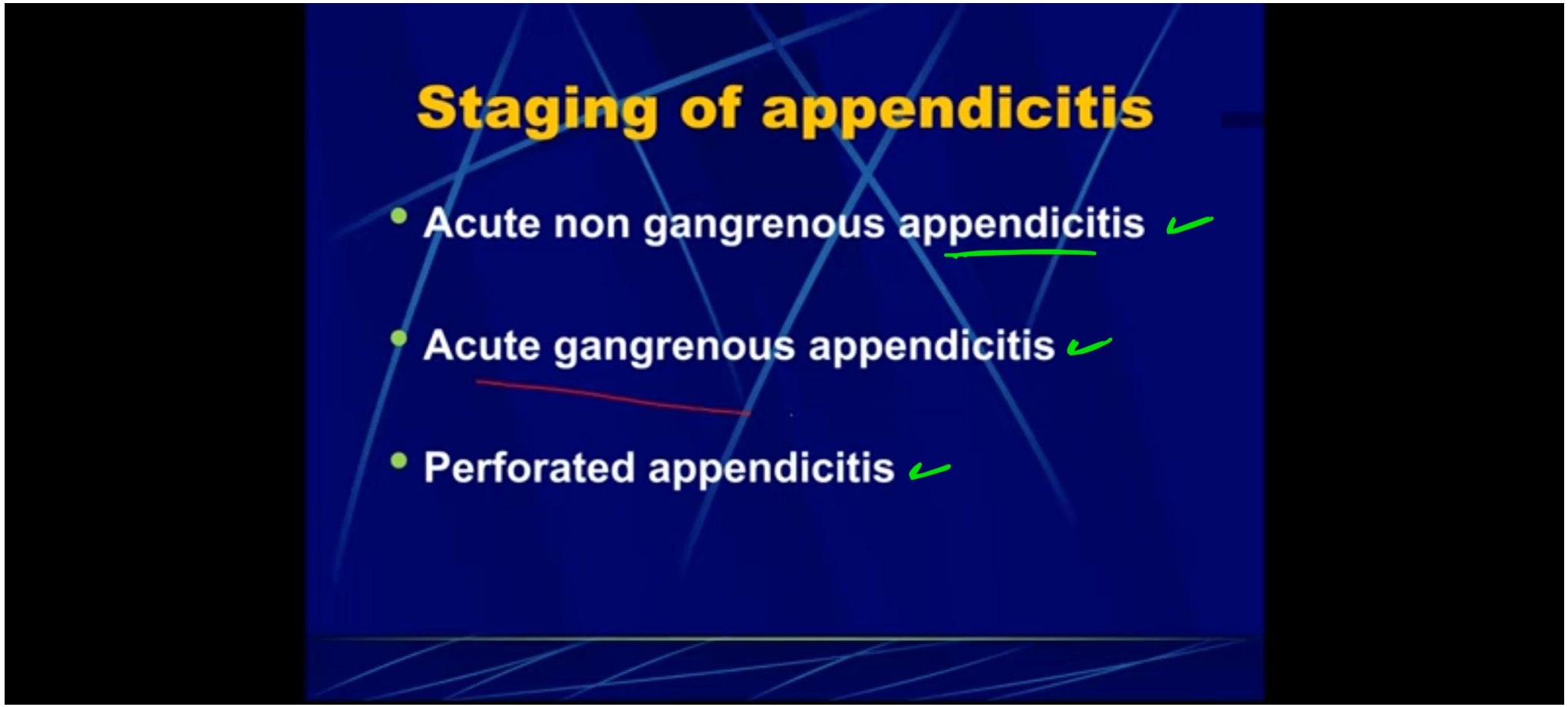
Staging of appendicitis
Acute non gangrenous appendicitis
Acute gangrenous appendicitis
Perforated appendicitis

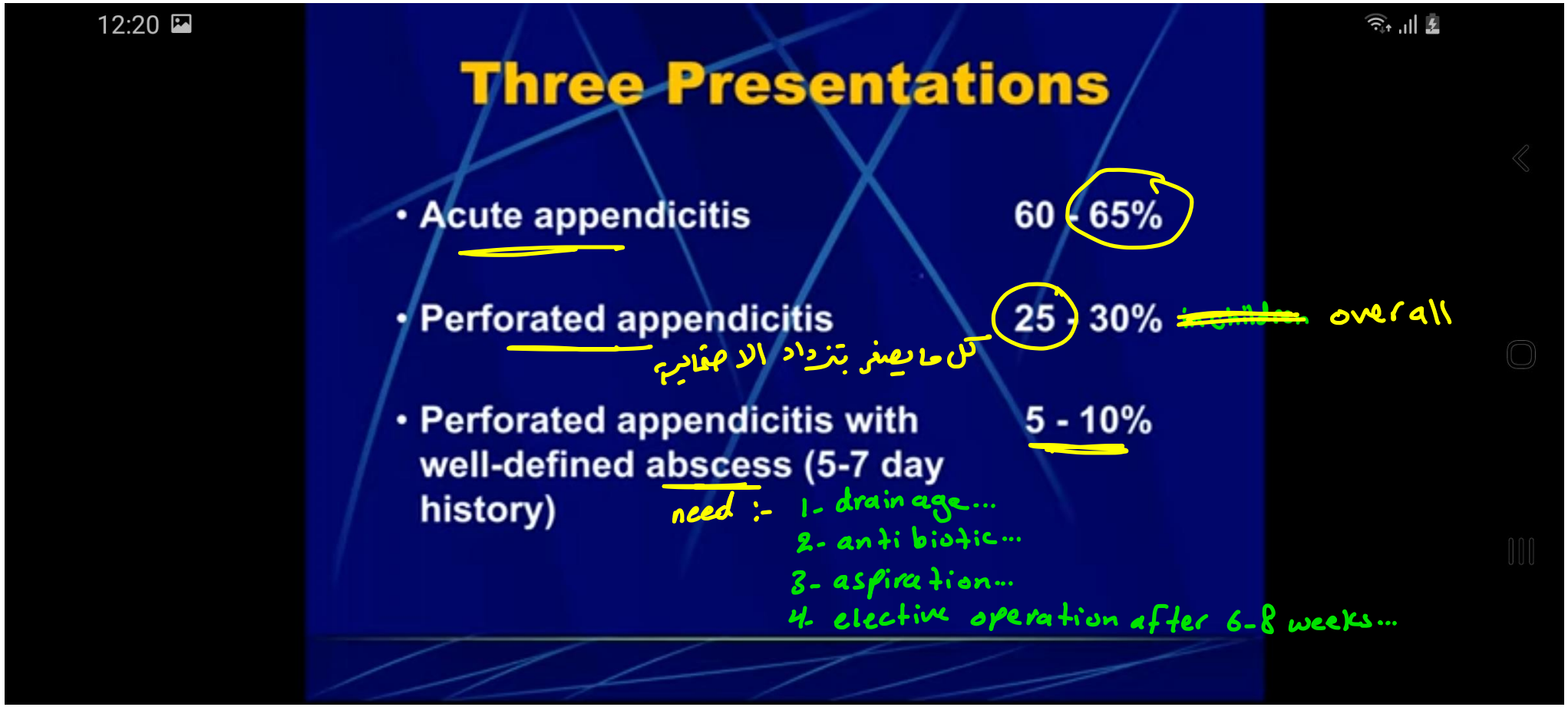
12:20
Three Presentations
• Acute appendicitis 60 - 65%
• Perforated appendicitis 25 - 30%
كل ما يصغر بتزداد الاصابة
overall
• Perforated appendicitis with well-defined abscess (5-7 day history) 5 - 10%
need :-
1- drainage...
2- anti biotic...
3- aspiration...
4- elective operation after 6-8 weeks...

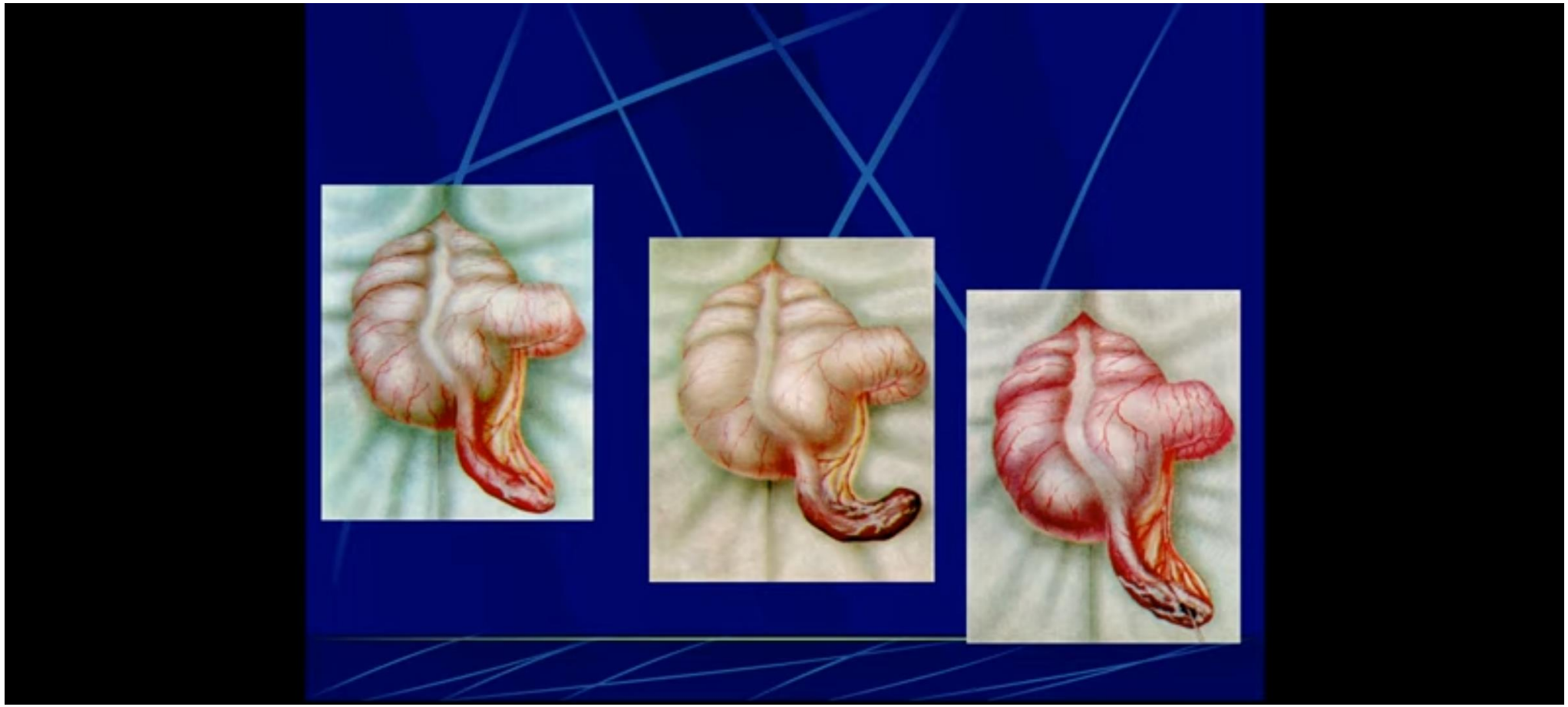

Surgical Management

Acute Appendicitis

→ appendectomy. [as soon as possible within 6hr]...

- Acute appendicitis cured with surgery.
- *Prompt appendectomy is treatment of choice.* (maybe laparotomy.)
- Appendicitis can be treated with Antibiotics alone. + good hydration...
- Antibiotics change from Emergency to Elective.
- Appendectomy in the middle of the night is not justified.

يعني عادي يصير للصبح

Surgical Management
Perforated Appendicitis

- *Appendectomy in the presence of known perforation is Controversial.*
- Antibiotics alone : Antibiotics and interval appendectomy; Appendectomy at presentation
- Recurrent appendicitis(8-14%) short term .
- APSA 86% responders perform interval appendectomy.

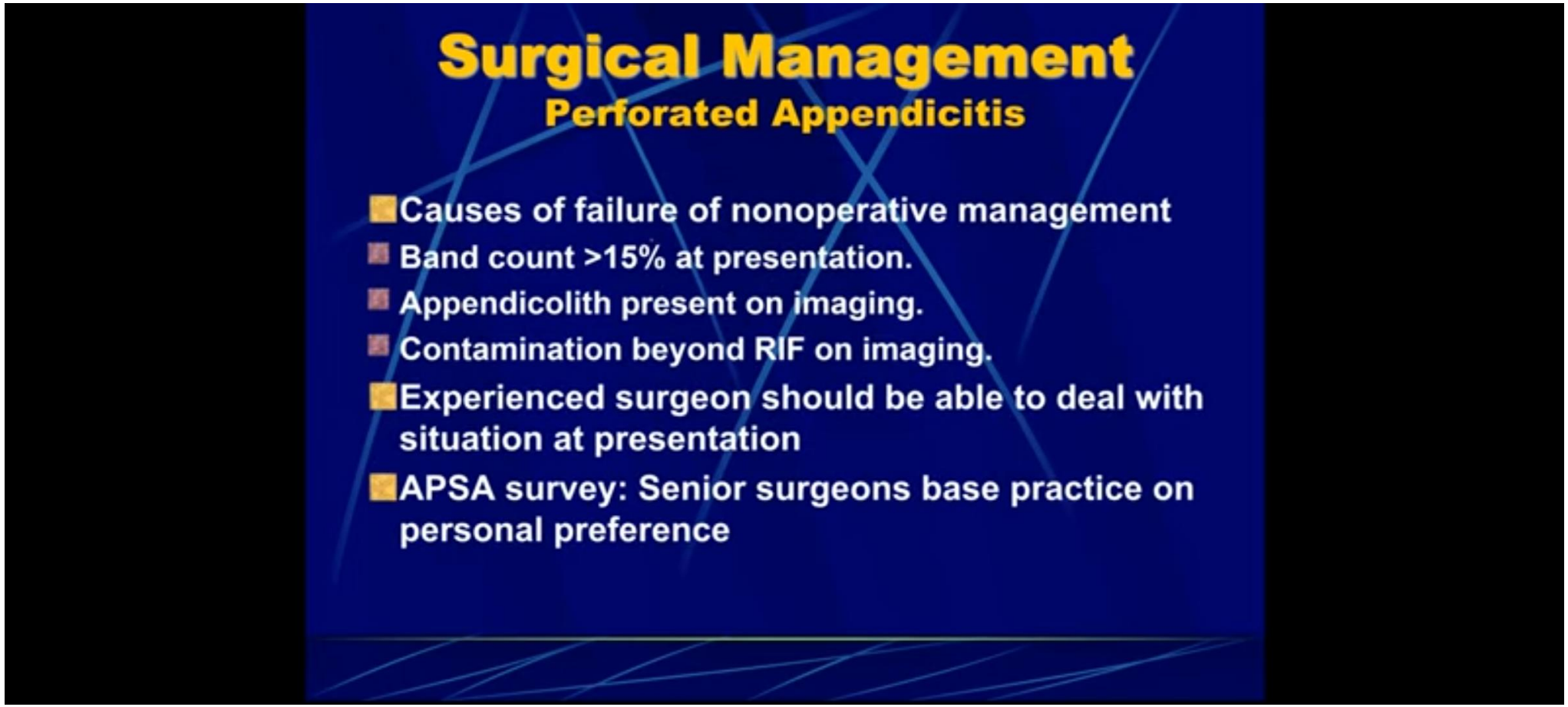
Surgical Management
Perforated Appendicitis
Causes of failure of nonoperative management
Band count >15% at presentation.
Appendicolith present on imaging.
Contamination beyond RIF on imaging.
Experienced surgeon should be able to deal with situation at presentation
APSA survey: Senior surgeons base practice on personal preference

* In appdicular mass don't do appendictomy...
  ↳ need:- conservative-ttt the discharge then operation after 6-8 weeks...

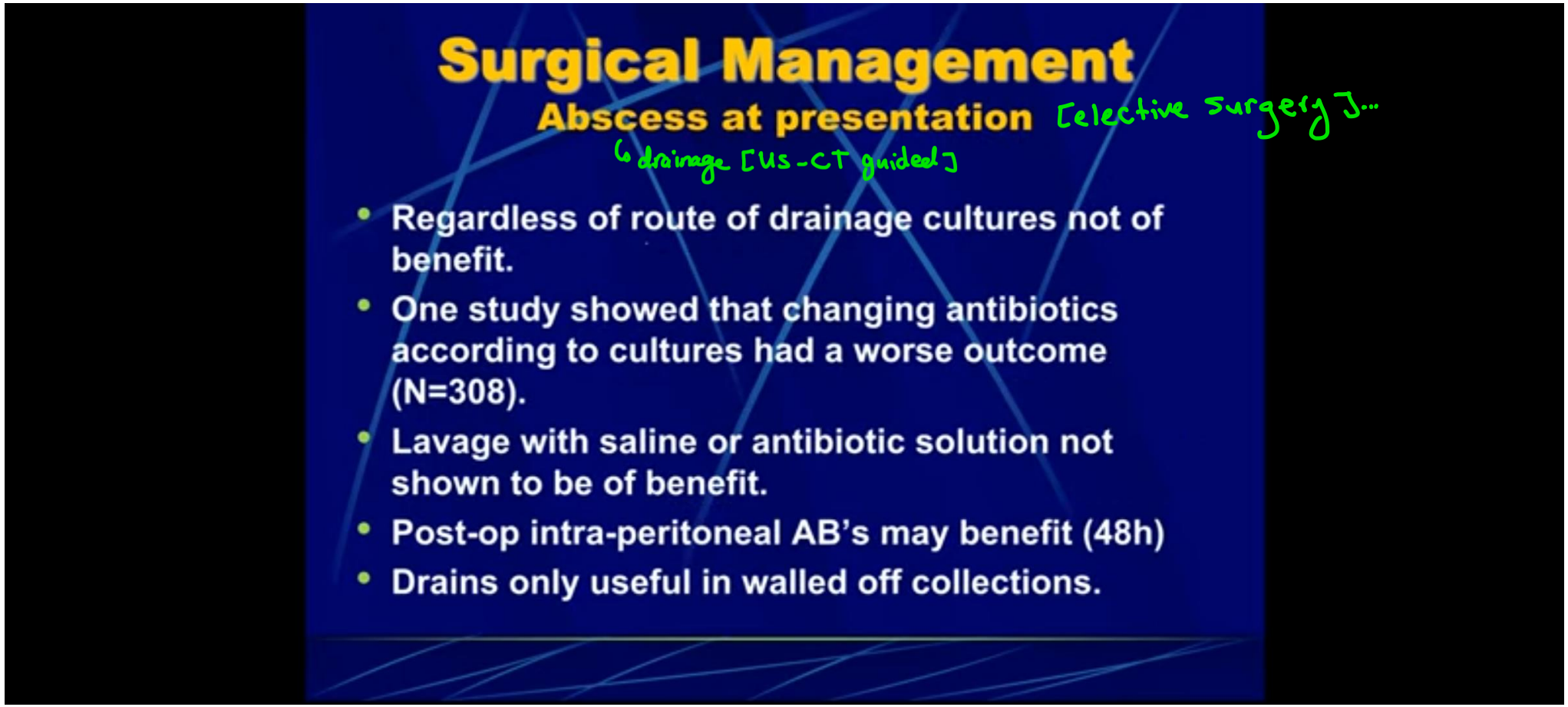

[Elective surgery]...
↳ drainage [US-CT guided]

Surgical Management

Abscess at presentation

- Open surgery high morbidity.
- Percutaneous drainage and interval appendectomy.
- Long course of treatment, cost burden.
- Prospective trial currently in progress comparing early laparoscopic surgery with percutaneous drain and delayed surgery.

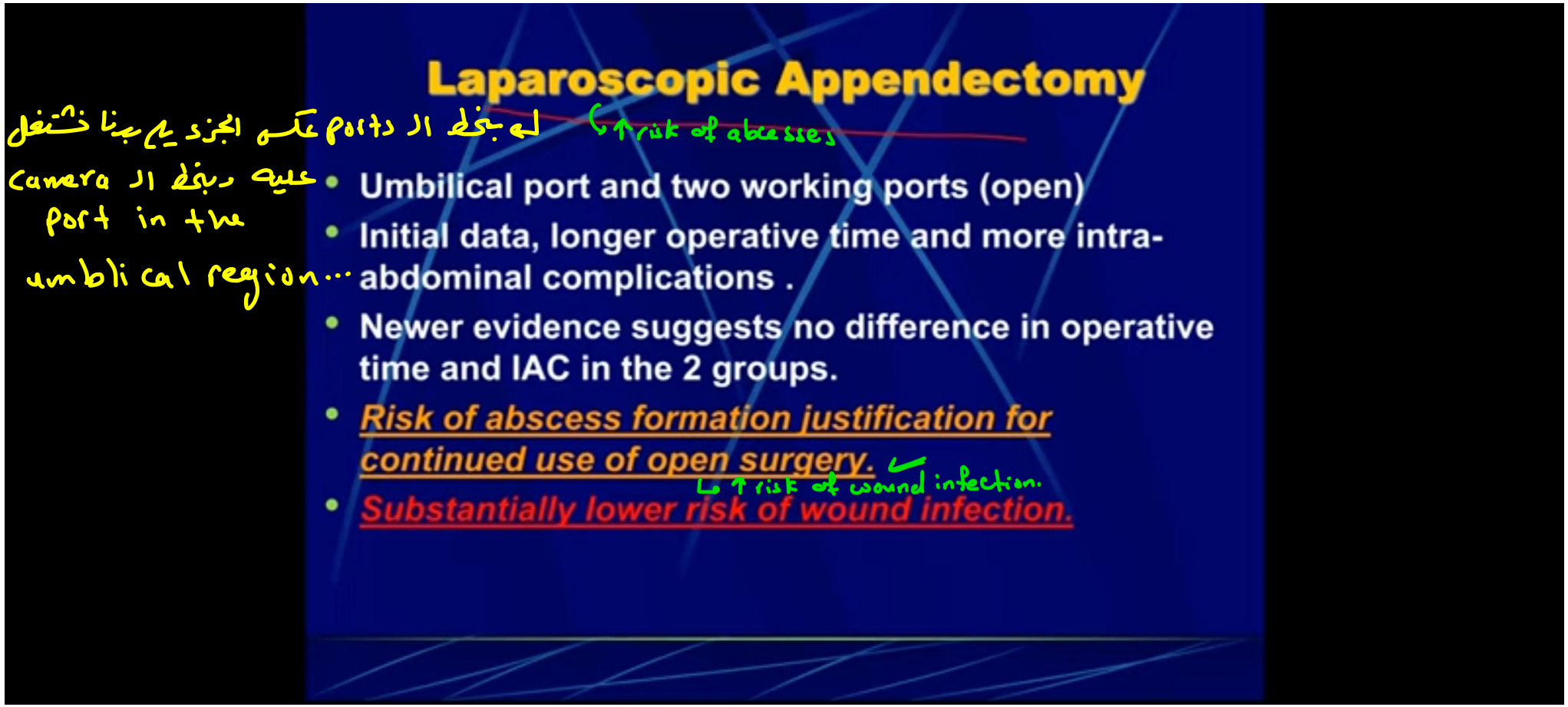
Laparoscopic Appendectomy
Umbilical port and two working ports (open)
Initial data, longer operative time and more intra-abdominal complications .
Newer evidence suggests no difference in operative time and IAC in the 2 groups.
Risk of abscess formation justification for continued use of open surgery.
Substantially lower risk of wound infection.

Laparoscopic Appendectomy

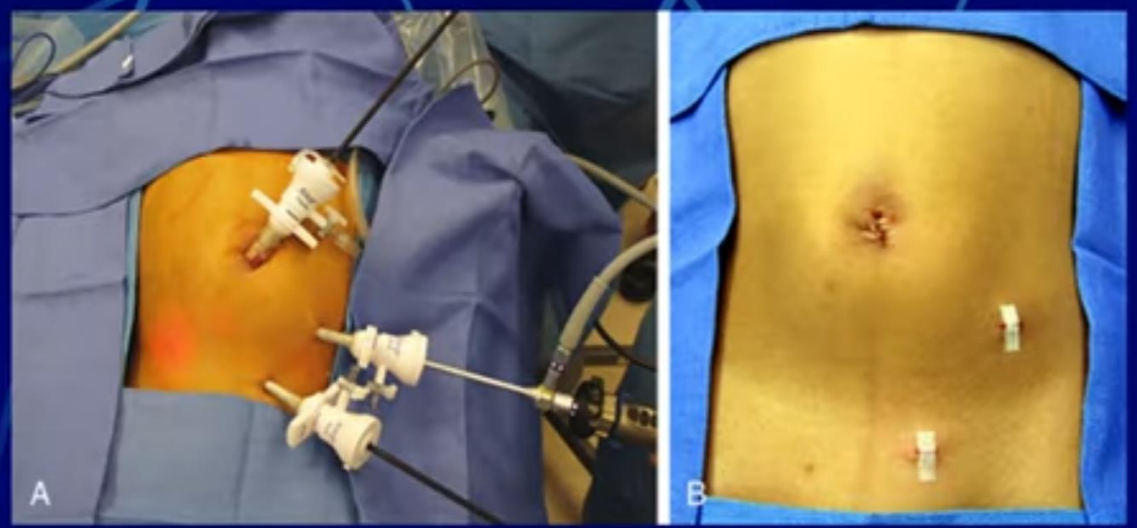

Laparoscopic Appendectomy

Personnel/Port Positions

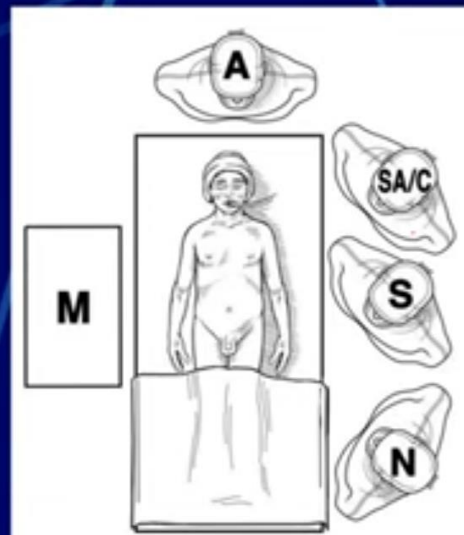



Laparoscopic Appendectomy

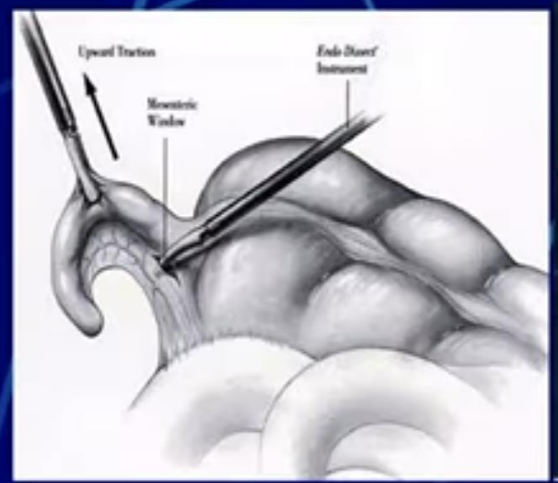



Laparoscopic Appendectomy

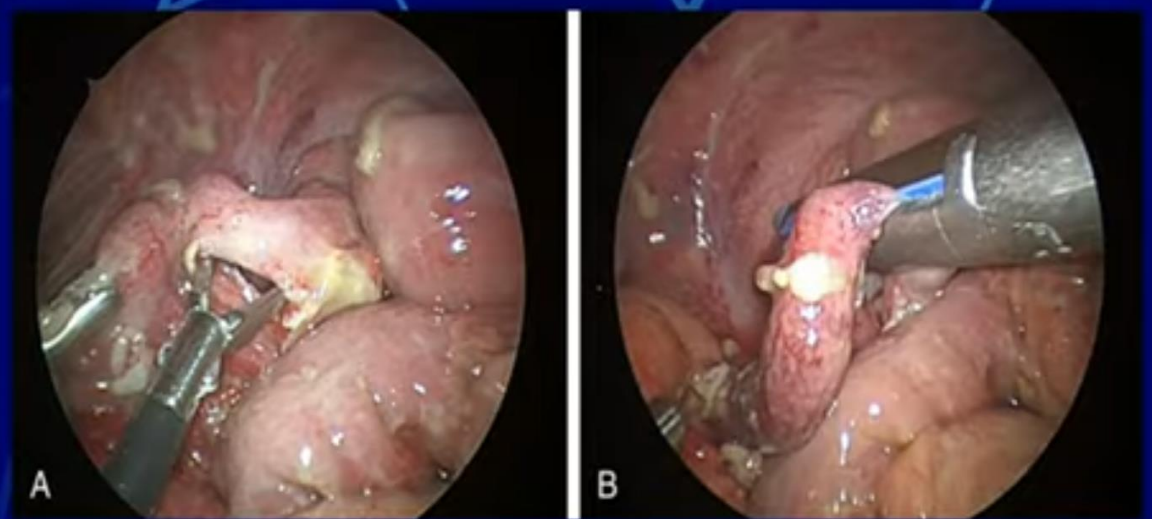

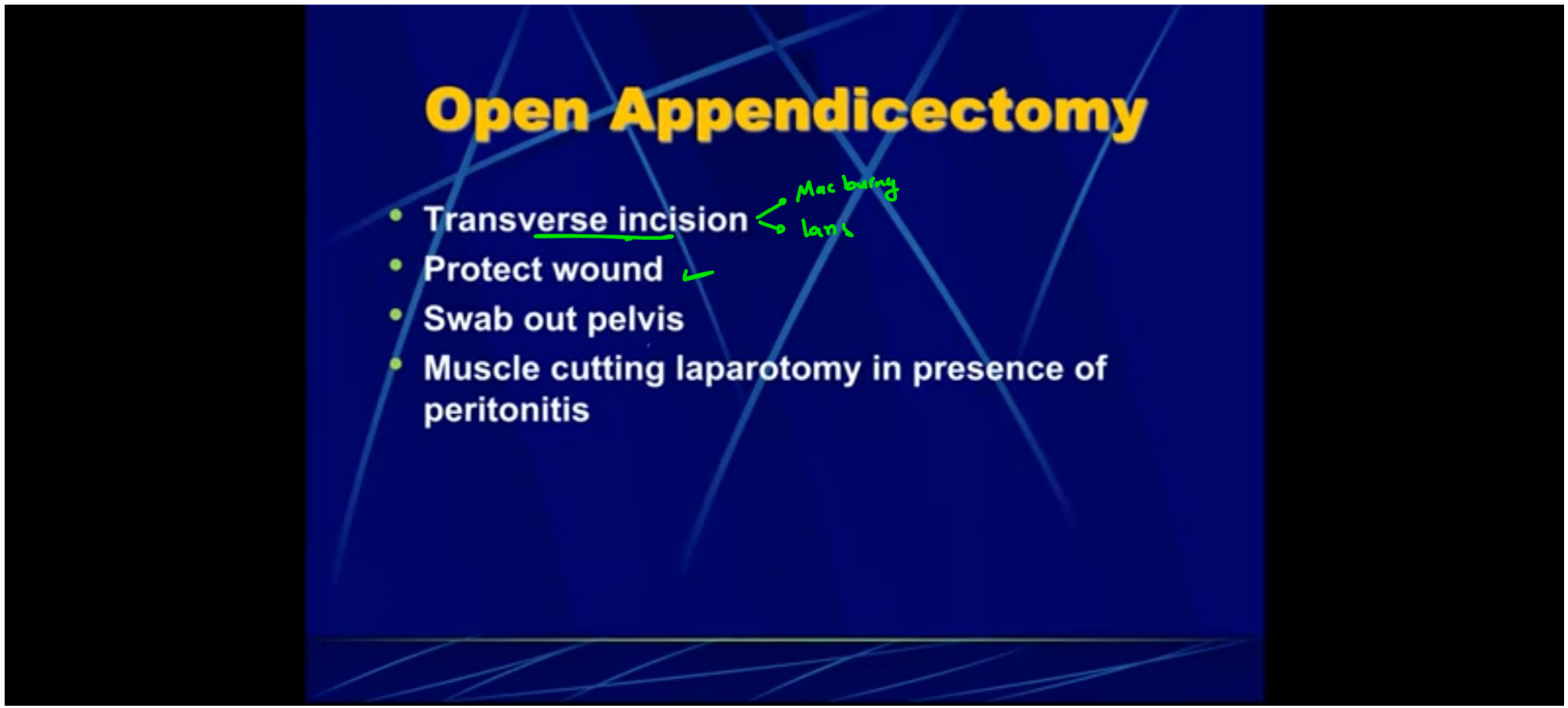
Open Appendicectomy
Transverse incision
Mac burney
lanz
Protect wound
Swab out pelvis
Muscle cutting laparotomy in presence of peritonitis

* The same doctor should do repeat examination for appendicitis...

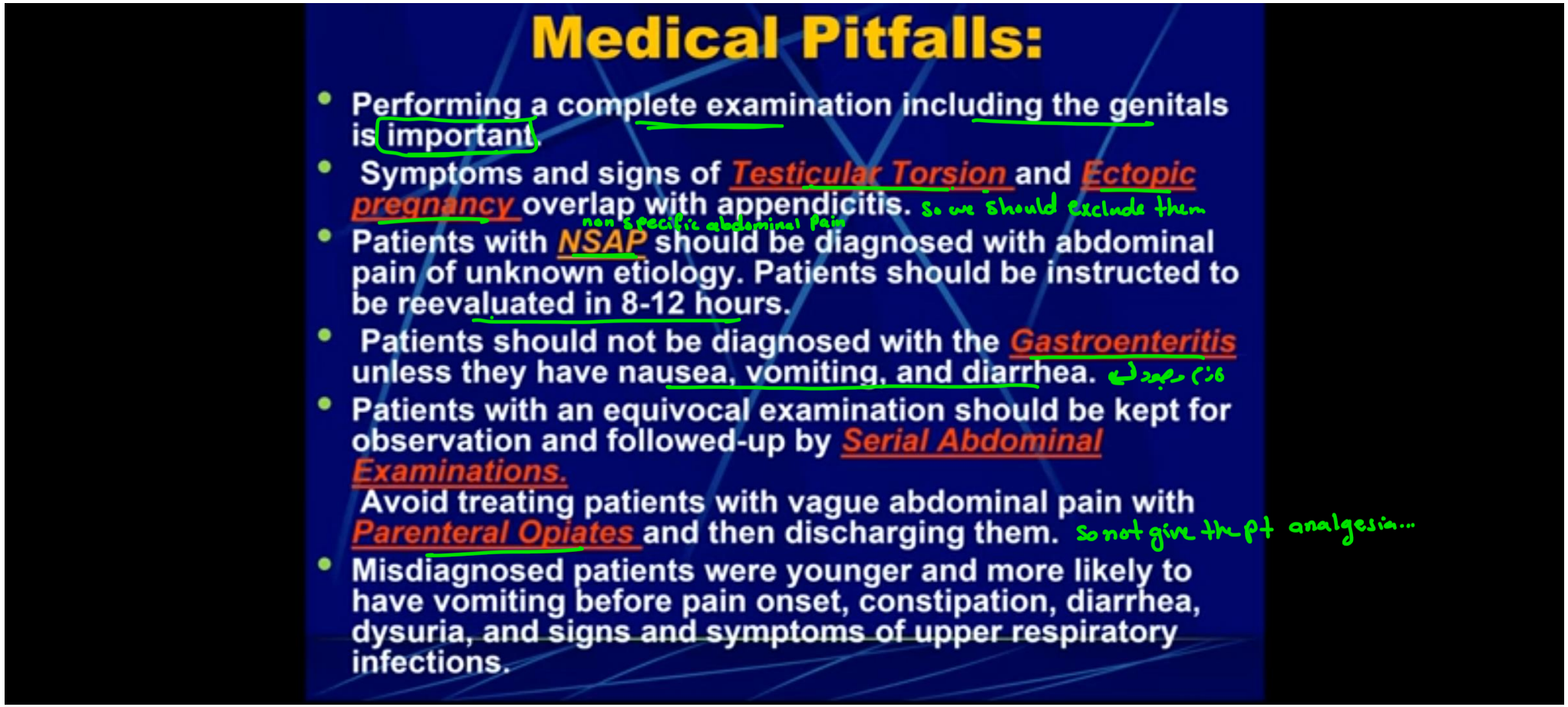


Thank You