* The most neck swelling in children is congenital - inflammatory

But in adult is tumor untill prove otherwise [Thyroid الغدة الدرقية]

↳ 80% :- Malignant and 80% is met2- 80% Sq. cell carcinoma

and 80% the origin is above the clavicle... ↳ from: larynx
pharynx
Thyroid

Neck swelling in children

Dr. Elias arteen
FRCSI
Consultant surgeon

Neck masses

Definition: **Any abnormal enlargement, Swelling, or Growth between clavicles & mandible.** [this is the site of the neck]

Lymphadenopathy is the most common cause. infection [mcc in children]

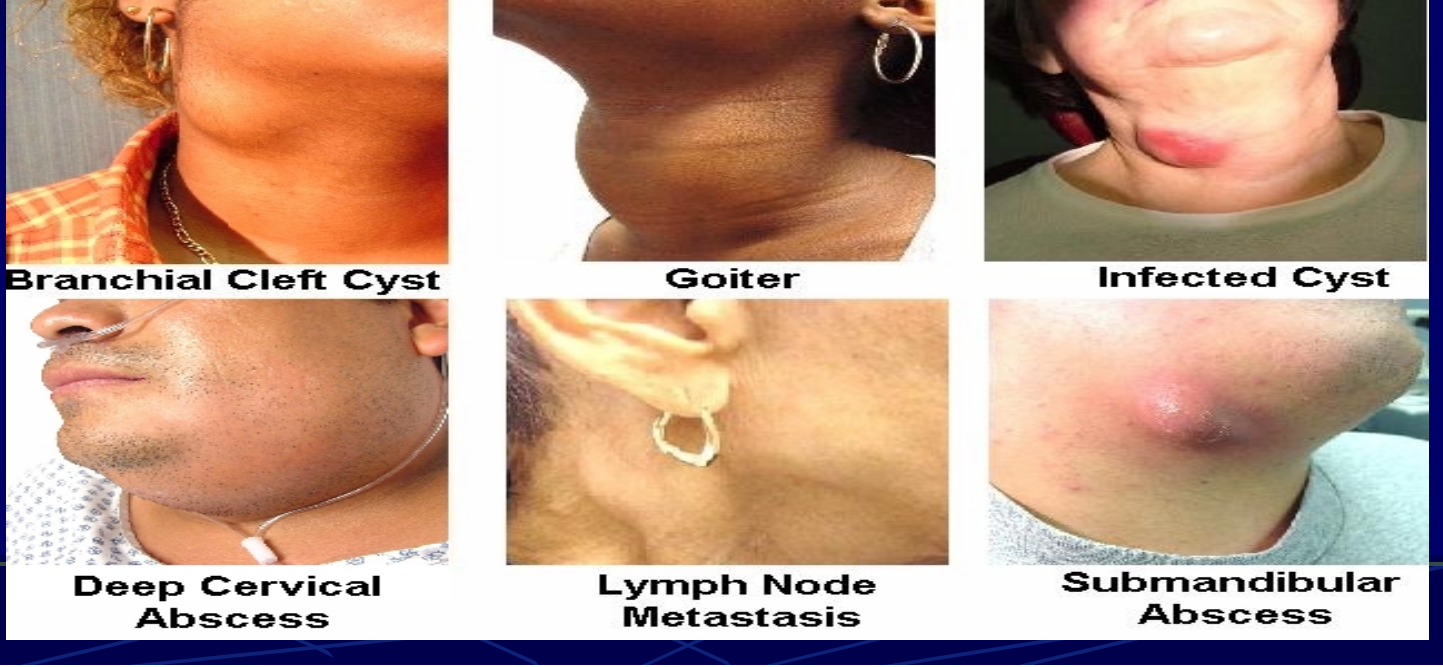

* The neck mass in childe may be:-

[1] InFlammatory
[mcc]
- viral [Bilateral]...
- Bacterial gram +ve
  - staph.
  - strept.

[unilateral and more tender LN]

[2] Conginital
- Branchial cyst...
- Thyroglossal cyst...

→ most important causes

* notes The post. Belly of digastric supplied by Facial nerve and the Ant. Belly of digastric supplied by Trigeminal nerve [mandibular branch]...

* Just above the intermediate tendon of digastric M., just above the hyoid Bone there is Hypoglossal nerve [supply the M. of the tounge]...
  - if it injured leed to deviation of the tounge into the diseased site...

Neck masses in children

- The management of neck masses in children (or adult) is determined by their **Location** (1) (to determine the origin...) and the **Length of time** (2) that they have been present. (مدة)

- Neck lesions are found either in the **Midline or Lateral Compartments**.
  - (called Triangels of the neck)
    - Ant. Triangle [from the lower border of the mandible - midline - sterno mastoid]...
    - post. Triangle [sterno mastoid - middle 1/3 of clavicle - Trapizus]...

Anatomy of the neck

The sternocleidomastoid muscle divides each side of the neck into 2 major triangles:

Anterior Triangle **(Digastric & Sup. Belly of omohyoid)**

- **Submandibular triangle**
- **Submental triangle**
- **Carotid triangle**
- **Muscular triangle** has the carotid artery
  - ↳ Between the sterno mastoid - Post. Belly of digastric - sup. Belly of omohyoid M.

Posterior Triangle

(inf. Belly of omohyoid)

- **Occipital triangle**
- **Supraclavicular triangle**

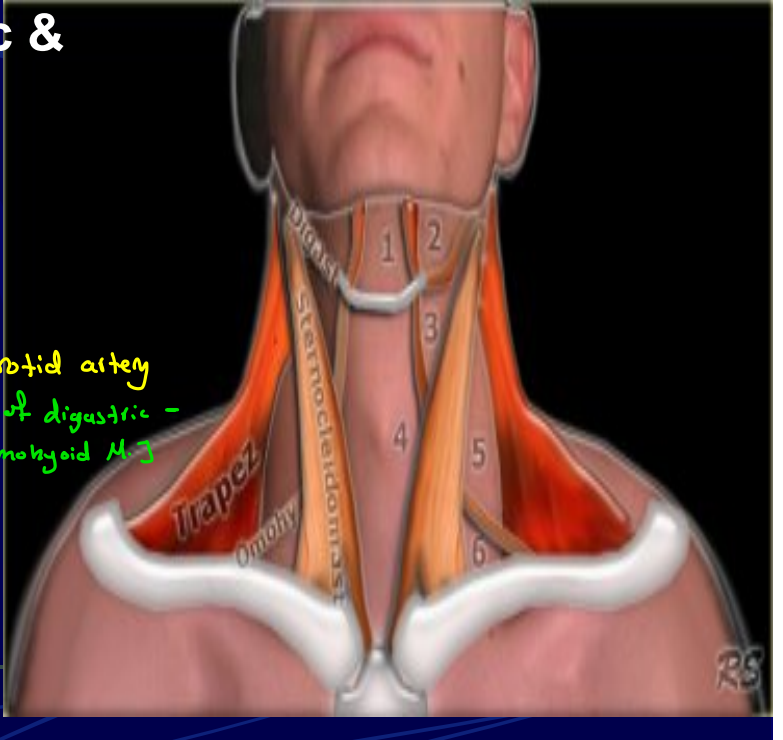

Anterior Triangle

Borders: ↳ The connection between the neck and the thorax...

- ***Laterally:*** **Anterior border of the SCM.**
- ***Medially:*** **Midline.**
- ***Superiorly:*** **Lower border of the Mandible.**

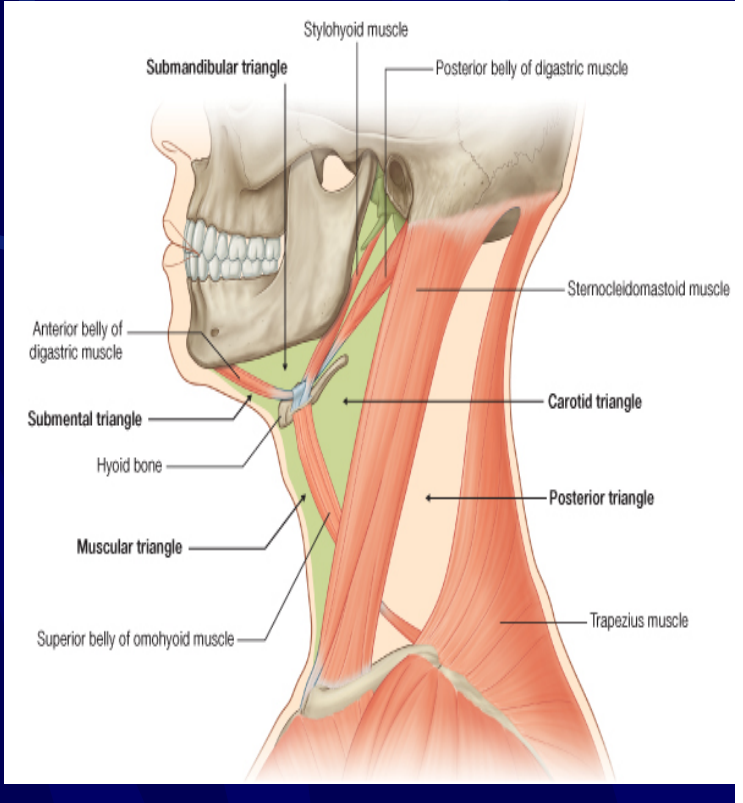

Posterior Triangle

Borders: ↳ The connection between the neck and the upper limb..

- ***Anteriorly:*** **Posterior border of the SCM.**
- ***Inferiorly:*** **Clavicle.**
- ***Posteriorly:*** **anterior border of Trapezius muscle.**

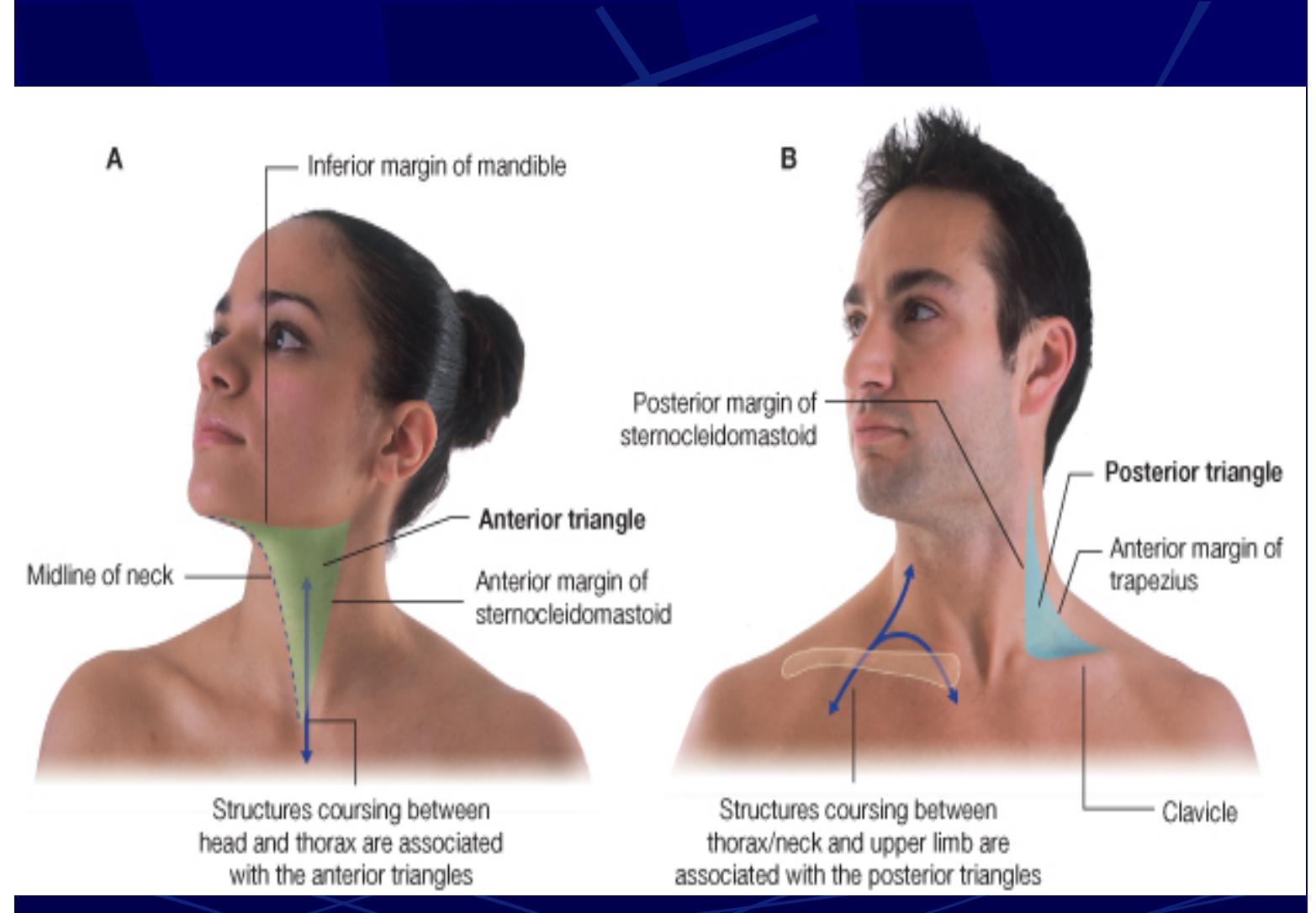
A
Inferior margin of mandible
Anterior triangle
Midline of neck
Anterior margin of sternocleidomastoid
Structures coursing between head and thorax are associated with the anterior triangles
B
Posterior margin of sternocleidomastoid
Posterior triangle
Anterior margin of trapezius
Clavicle
Structures coursing between thorax/neck and upper limb are associated with the posterior triangles

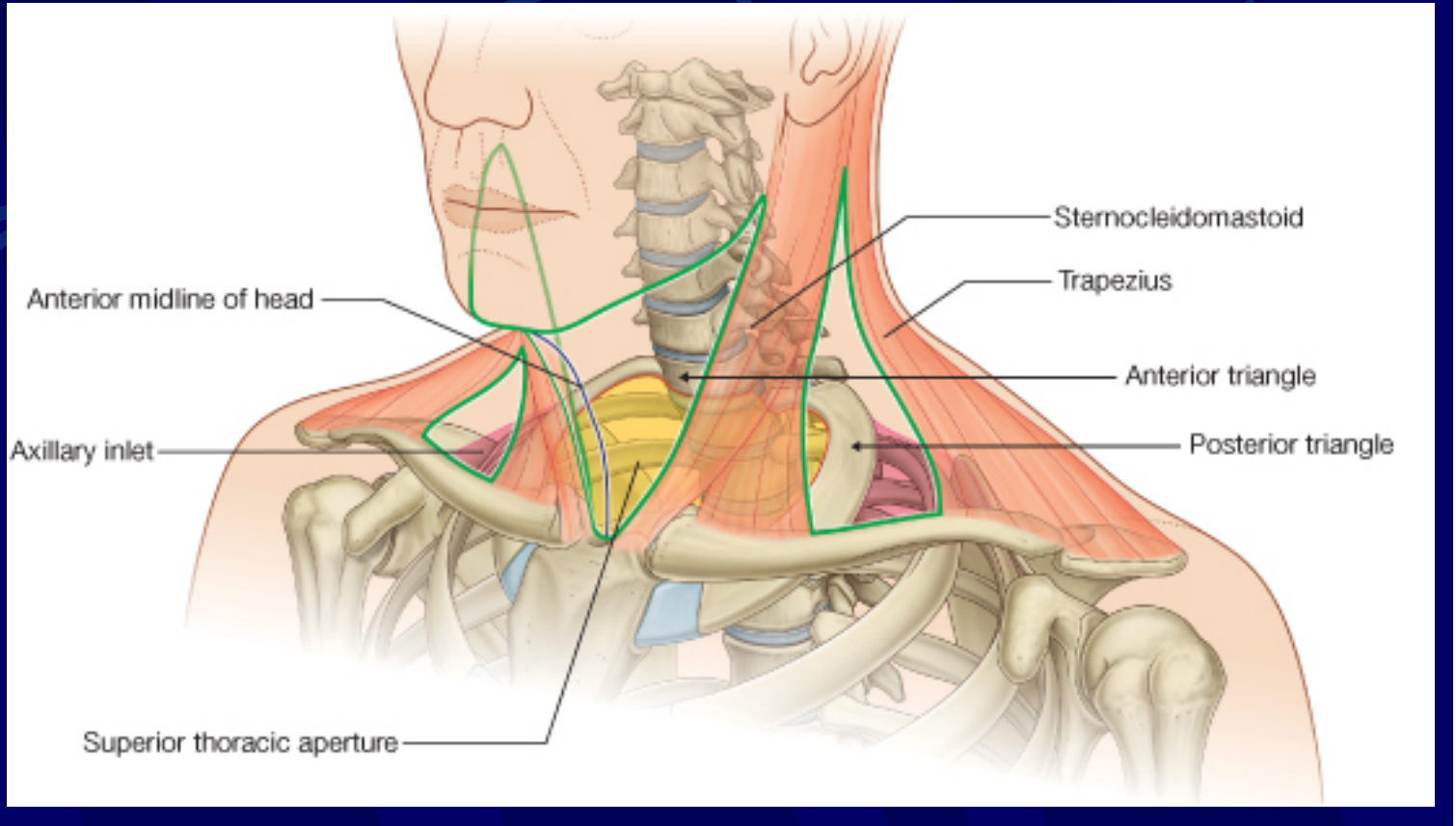
Sternocleidomastoid
Trapezius
Anterior midline of head
Anterior triangle
Axillary inlet
Posterior triangle
Superior thoracic aperture

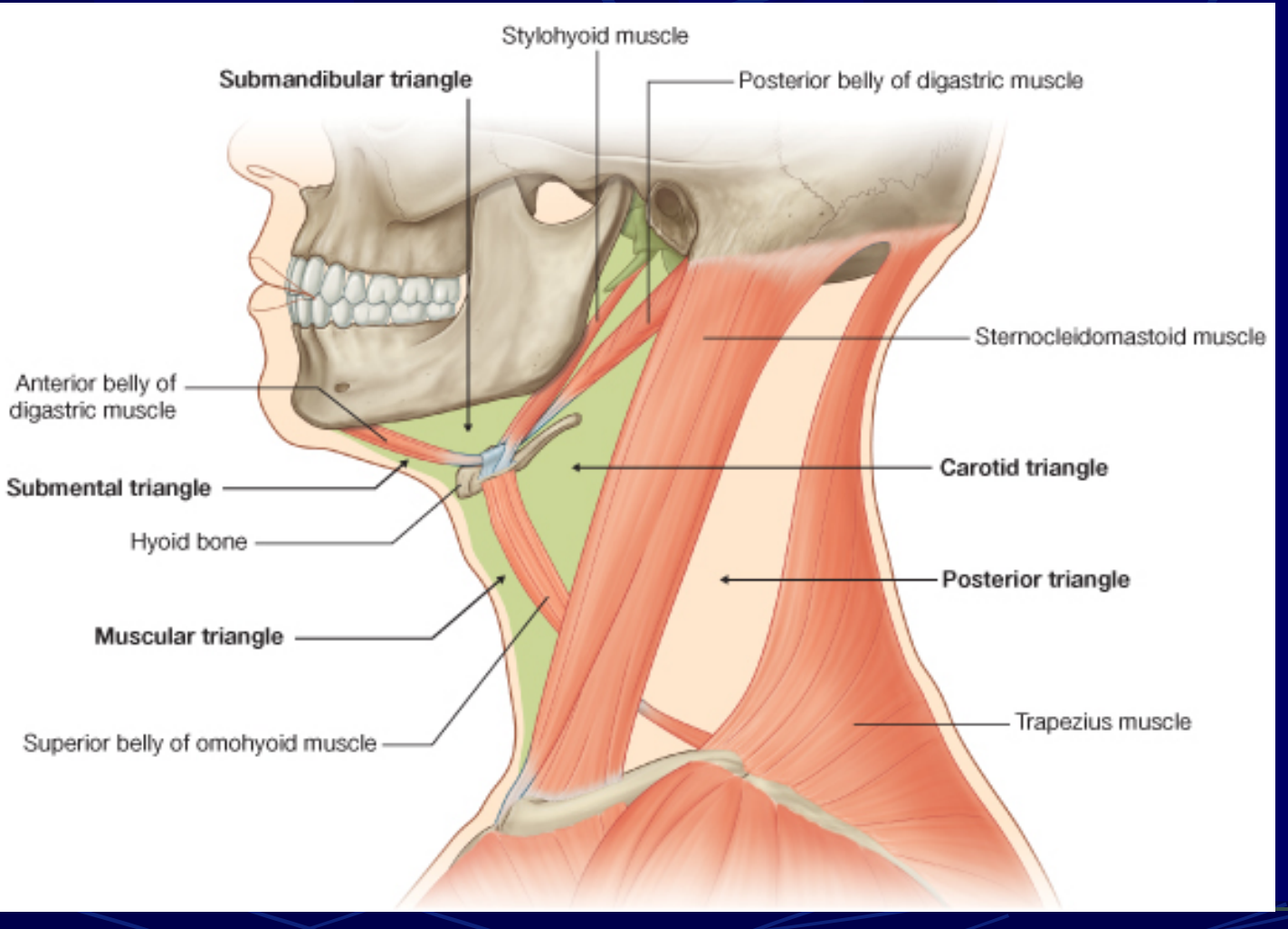
Stylohyoid muscle
Submandibular triangle
Posterior belly of digastric muscle
Sternocleidomastoid muscle
Anterior belly of digastric muscle
Carotid triangle
Submental triangle
Hyoid bone
Posterior triangle
Muscular triangle
Trapezius muscle
Superior belly of omohyoid muscle

General rules of thumb

Majority of pediatric neck masses are Congenital or Inflammatory.

85%

- neoplastic [1-2%]

Vascular malformations less common.

↳ as: Hemangioma

5-10 % of pediatric malignancies arise in H&N).

↳ Head and neck

↳ Thyroid malignancy [papillary thyroid cancer]...
↳ lymphoma...
↳ neuroblastoma...

Most common palpable neck mass in a child is *Lymph Node(s)* +/- lymphadenitis or lymphadenopathy .

very common in children [we should know the size of it + duration]

* The neck L N < 1.5 cm طبيعي But if it > 1.5 cm مرضي
* if the neck L N less than 2 week indicate inflammatory But if it 2-6 week may be chronic infl. But if it > 6 week indicate malignancy...

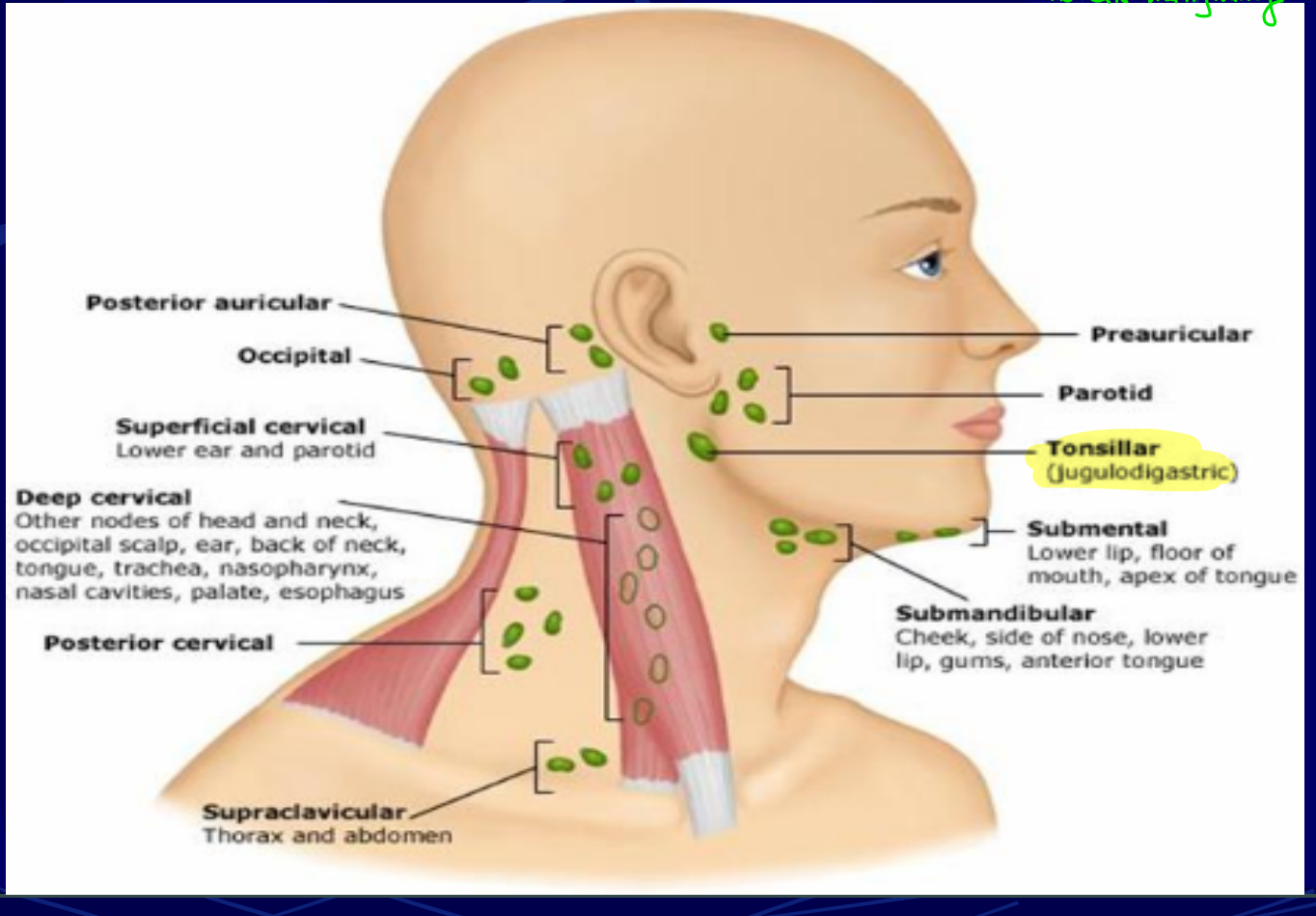

Lymphadenopathy

The most common cause of a neck mass in a child is an enlarged lymph node.

90% of children between 4-8 y have cervical lymphadenopathy. But it small and may be multiple in more than one level

Present in either zone VI, or zone II,III,IV,V. posterior triangle

Enlarged tender lymph nodes is usually the result of bacterial infection *(Staphylococcus or Streptococcus).* or viral

When the neck nodes are *Firm, Fixed*, and other groups of LNs also present in the Axillae or Groin, or indicate lymphoma

* The metz LN in the childre is < 1% [extremely rare]...

Neck masses -children

Children have larger lymphoid mass. due to stronger immune system...

Brisk lymphoreticular response. لذلك بتشيلها كتير في الاطفال any child has tonsilits → The jugulogastric LN become large and tender...

Present with lymphadenopathy after minor infection. رغم تكبر الدا بشكل كبير كبير

Nodes may continue to enlarge after initiation of treatment and resolution of infection. مع انو الالتهاب انتهى

Lymphadenopathy

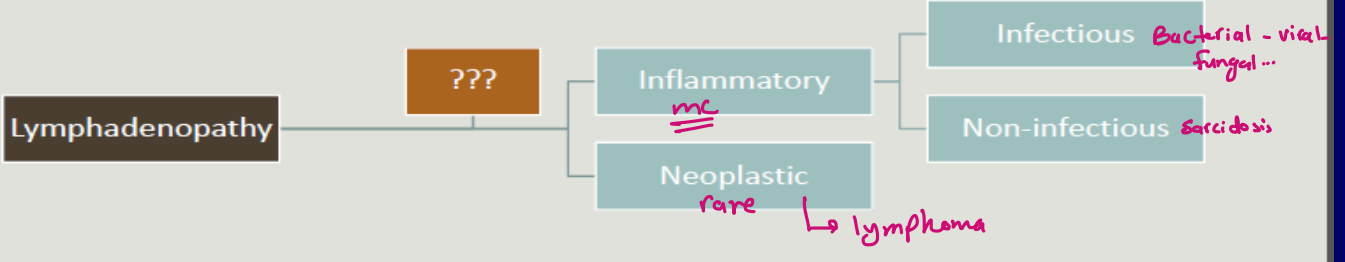

Lymphadenitis

- Surrounding inflammation
- Heterogeneous
- Central liquefaction
- Unilateral, often one level only
- Tender

Lymphoma

↳ night fever and sweat - loss of wt - anorexia - itching...

- Sharply delineated
- Homogeneous
- Hypoechoic
- Several levels — from same group or other groups
- Non tender

* The matted LN in TB [chronic infection] or tumor But the amalgamated LN more in lymphoma...
لـ كتلة LN بتتحرك لـ كتلة LN ما بتتحرك

Primary lymph Node Neoplasm

* 1st mc pediatric tumor [30%] is leukemia, the 2nd mc is CNS [Brain tumor]... ↳ 20%.
non solid tumor

Third most common pediatric tumor. is primary LN lymphoma.

Most common is lymphoma non solid tumor

(Hodgkin's and non- Hodgkin's)

Common in children and young adults.



Symptoms:

Painless slowly growing neck lump .

Malaise, Wt loss, Pallor, Pruritus , Fever, Night sweat.

lymphoma

Physical:

Site: Any cervical lymph node, common in posterior triangle.

No tenderness

Solid and rubbery

Smooth, discrete and well defined (not matted)

Mobile



RELATIVE FREQUENCY OF SPECIFIC NECK MASSES WITHIN CAUSATIVE GROUPS BY AGE (Years)

0 - 15

Inflammatory
- Adenitis
  - Bacterial (AT/PT)
  - Viral (AT/PT)
  - Granulomatous (PT/AT)

Congenital
- Branchial cyst (AT)
- Thyroglossal cyst (M)
- Vascular lesion (PT)
- Dermoid (M)

Neoplastic
- Lymphoma (AT/PT)
- Thyroid carcinoma (M)
- Sarcoma (AT/PT)

16 - 40

Inflammatory
- Adenitis
  - Viral (AT/PT)
  - Bacterial (AT/PT)
  - Granulomatous (PT/AT)
  - AIDS (AT/PT)

Congenital
- Branchial cyst (AT)
- Thyroglossal cyst (M)
- Dermoid

Neoplastic
- Lymphoma (AT/PT)
- Thyroid carcinoma (M)
- Salivary (AT)
- Metastatic (AT/PT)
- Vascular (AT/PT)
- Neurogenic (AT)

40+

Neoplastic 80%.
- Metastatic carcinoma (AT/PT)
- Thyroid carcinoma (M)

lymphoma 20%.

Inflammatory
- Adenitis
  - Viral (AT/PT)
  - Bacterial (AT/PT)
  - Granulomatous (PT/AT)
  - AIDS (AT/PT)

Congenital
- Branchial cyst (AT)
- Thyroglossal cyst (M)

Distribution of Childhood Cancer

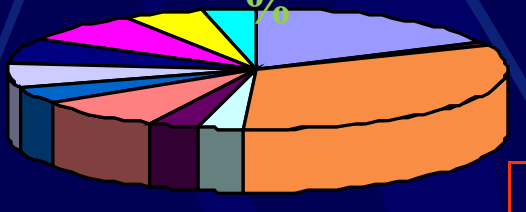

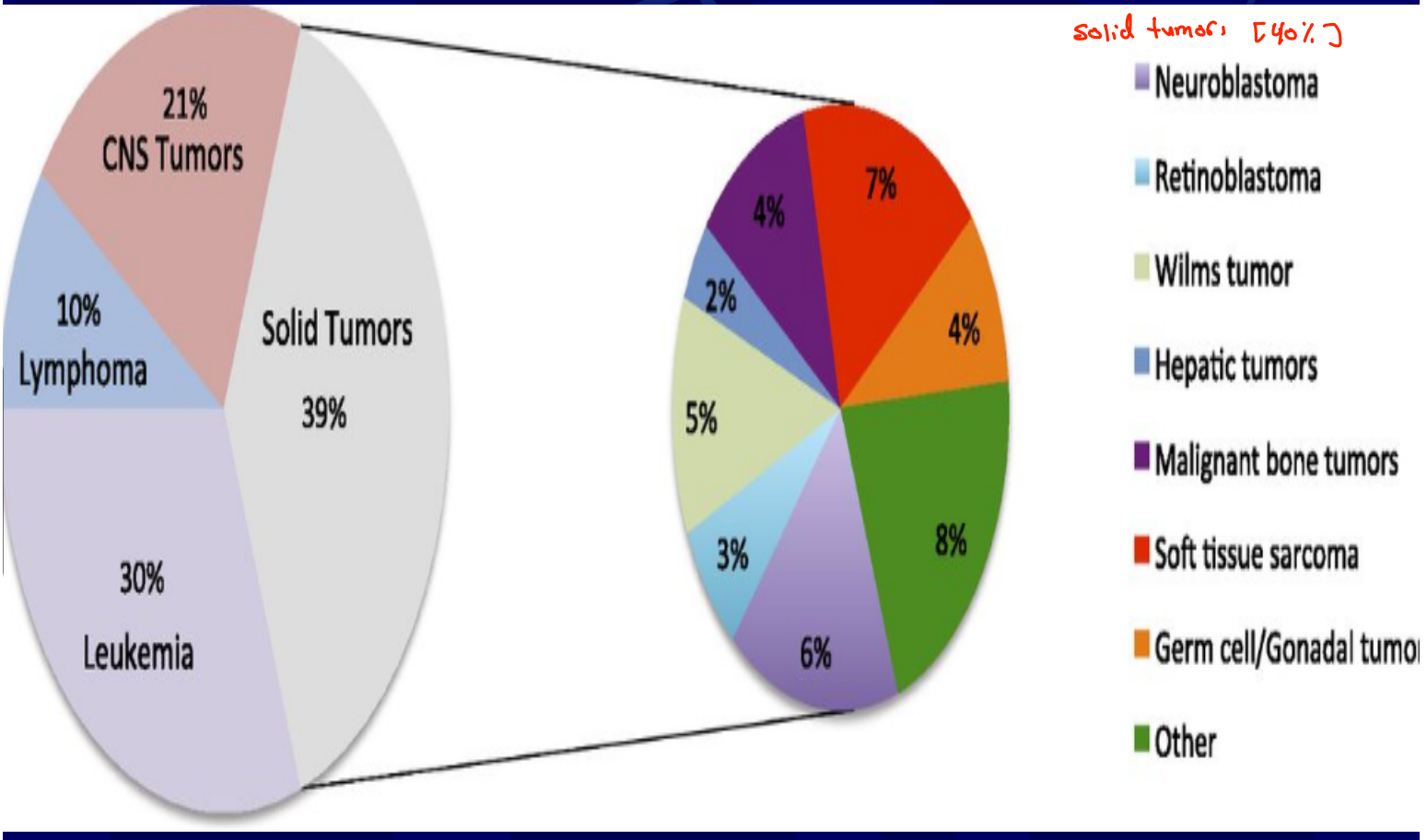

solid tumors [40%]

* The mandibular Branch of facial nerve supply the lower lip so if it injured lead to saliva drooling.
* The lingual nerve is the nerve of kissing...

Branchial cyst

90% of cases

Remnant of 2nd Branchial clefts .

Appear at any age (mostly 15- 25 y).

Painless swelling. Solid mass in the Ant. triangle of the neck

Behind the ***Anterior*** margin of the SCM. muscle , junction of upper 1/3 and lower 2/3 anterior to pharynx below mandible.

Hard, smooth, not very mobile .

Full of yellowish golden material, ***Cholesterol Crystals.*** لون طحيني

Can not be Reduced or Compressed to diff it from cystic Hygroma

May get infected. ✂/complete excision...





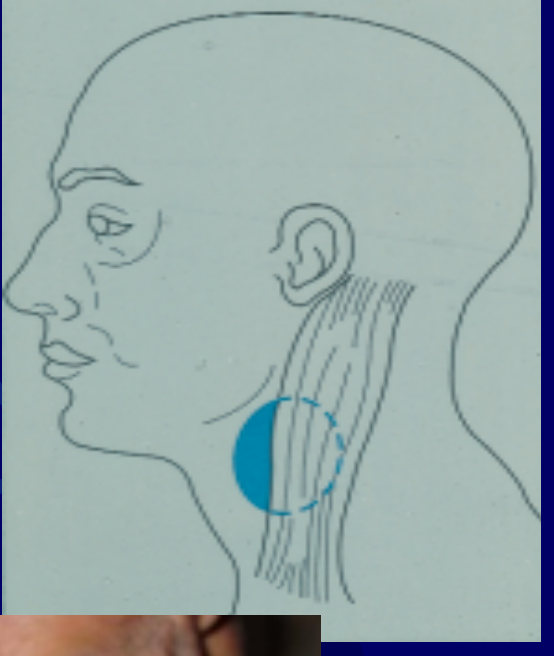





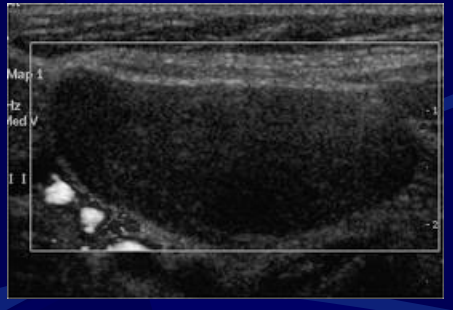

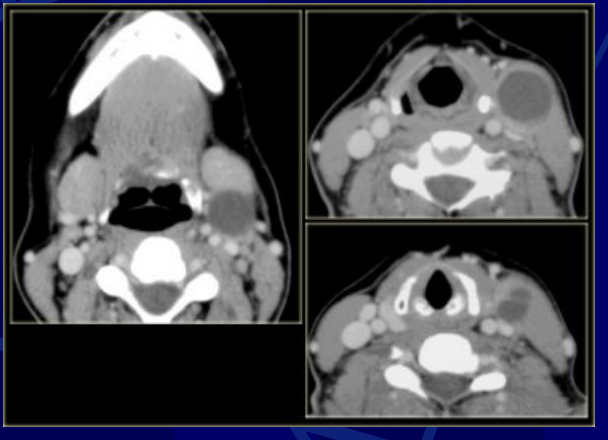

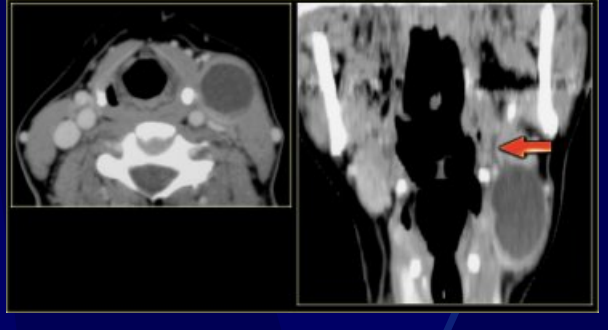

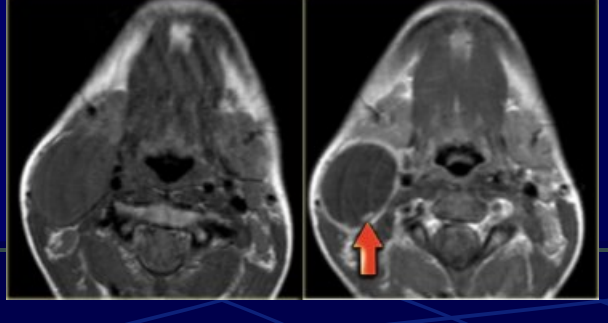



Spot diagnosis for Brachial cyst...





Branchial fistula (or sinus)

tonsilar fossa اذا حنه لكن تفتح محلك

Second Branchial Fistula

- Sinus or fistula can have skin pit anywhere along anterior border of SCM .
- Tract can extend all the way to ipsilateral tonsil . present between the palato glossus and palato pharyngeal M.
- Treatment is surgical excision; risk of recurrence if fail to excise entire tract .
- If its end is closed it is called a *sinus.*





2nd BAC

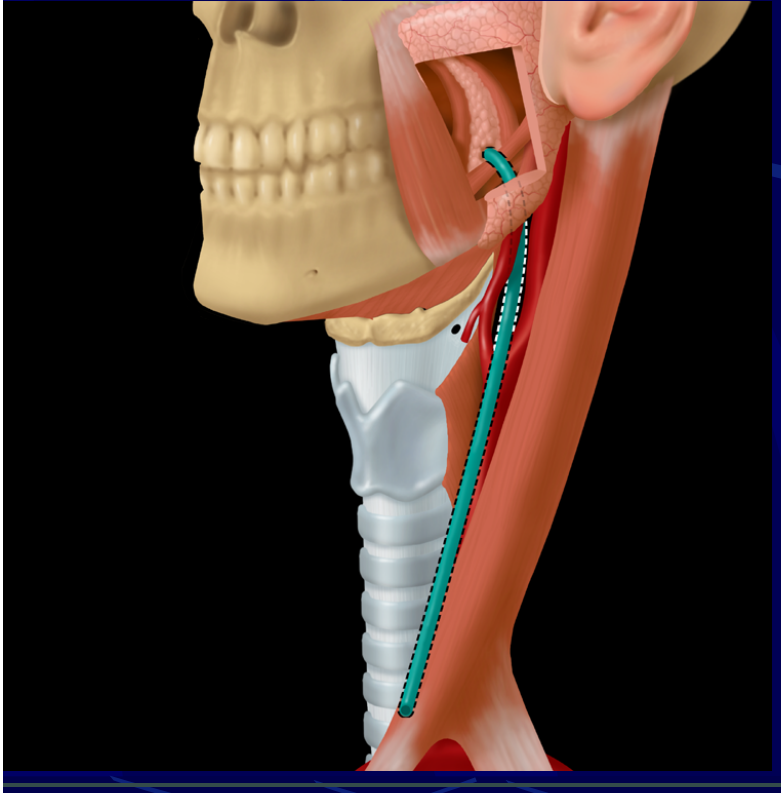

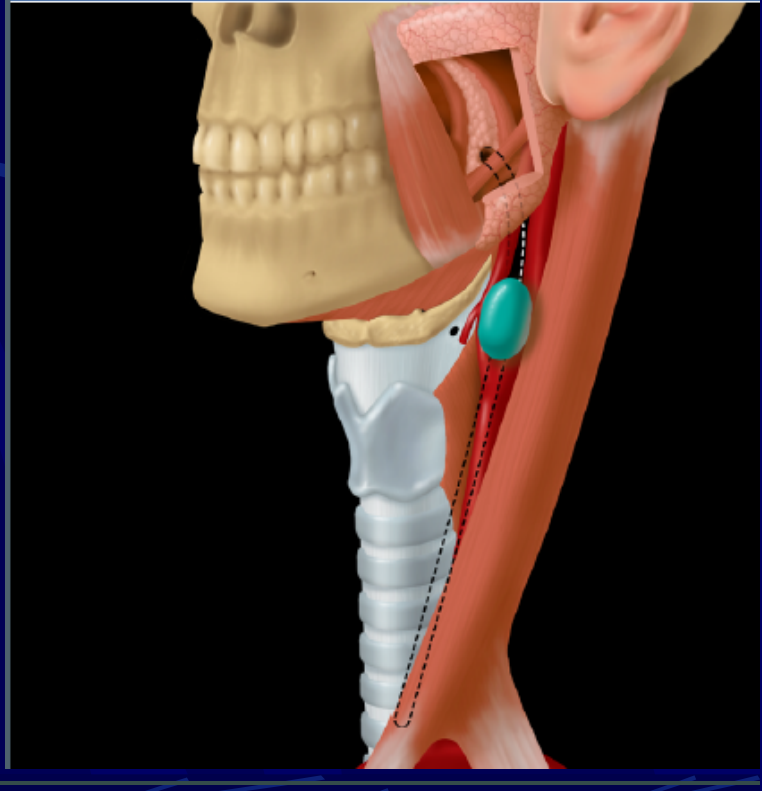

Thyroglossal cyst

begin at foramen cecum [between the ant. 2/3 of toung and post. 1/3] ↓ going down-ward.

[normally] thyroid الدرقية تنزل من مكان تكونها وبتضل تنزل لحد ما تتصل

Most common congenital neck mass 70%.

Usually diagnosed at 2- 4 years. [ممكن تنظر قبل سنتين وتلاقي حبة كيس بتكبر براحتها] 2ry infection بيصير حتى 8-12 y/o بنجلي بالعمر ما

Remnants of Thyroglossal tract.

At level of hyoid 50% or, infrahyoid .

rarely supra hyoid...

Usually present before age of 20 y.

Midline swelling 75%, near midline 25%. due to recurrent or 2ry infection or privous surgery



Painless lump in midline of neck ,

pain and redness if infected.

Spherical smooth and mobile.

Rise with swallowing and protruding

#/ surgery we remove the central part of hyoid bone... [Sis-trunk operation]

Sites of Thyroglossal cysts

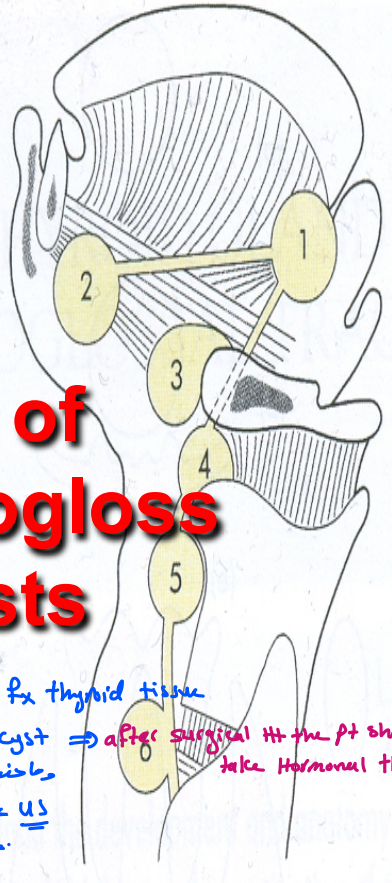

* Maybe the only fx thyroid tissue is presented in the cyst ⇒ after surgical th the pt should take Hormonal therapy...

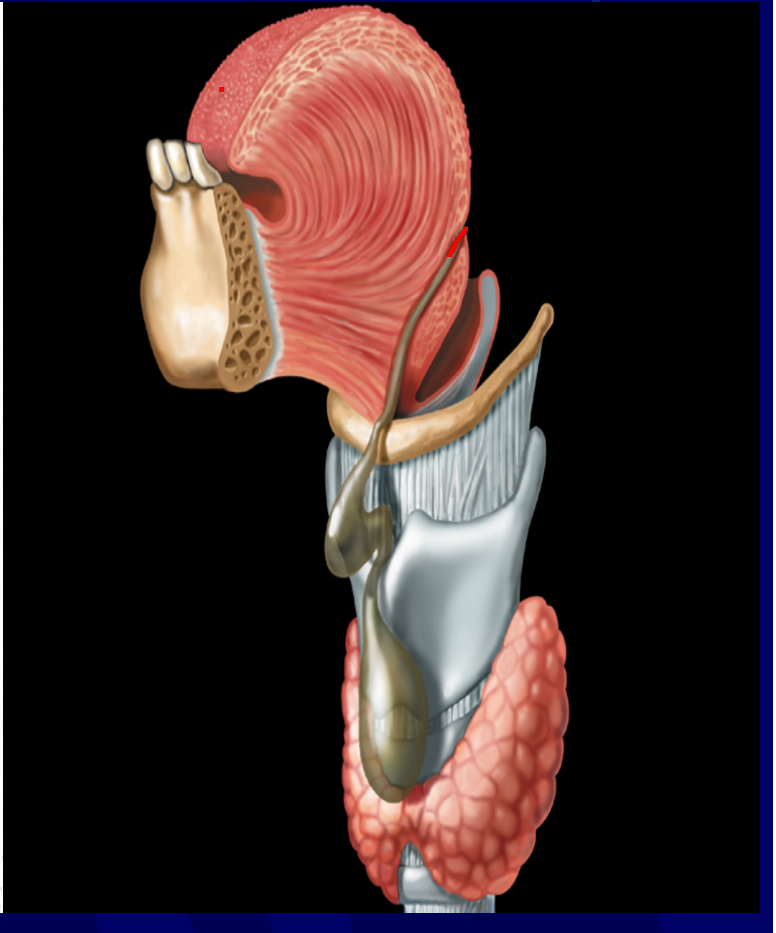

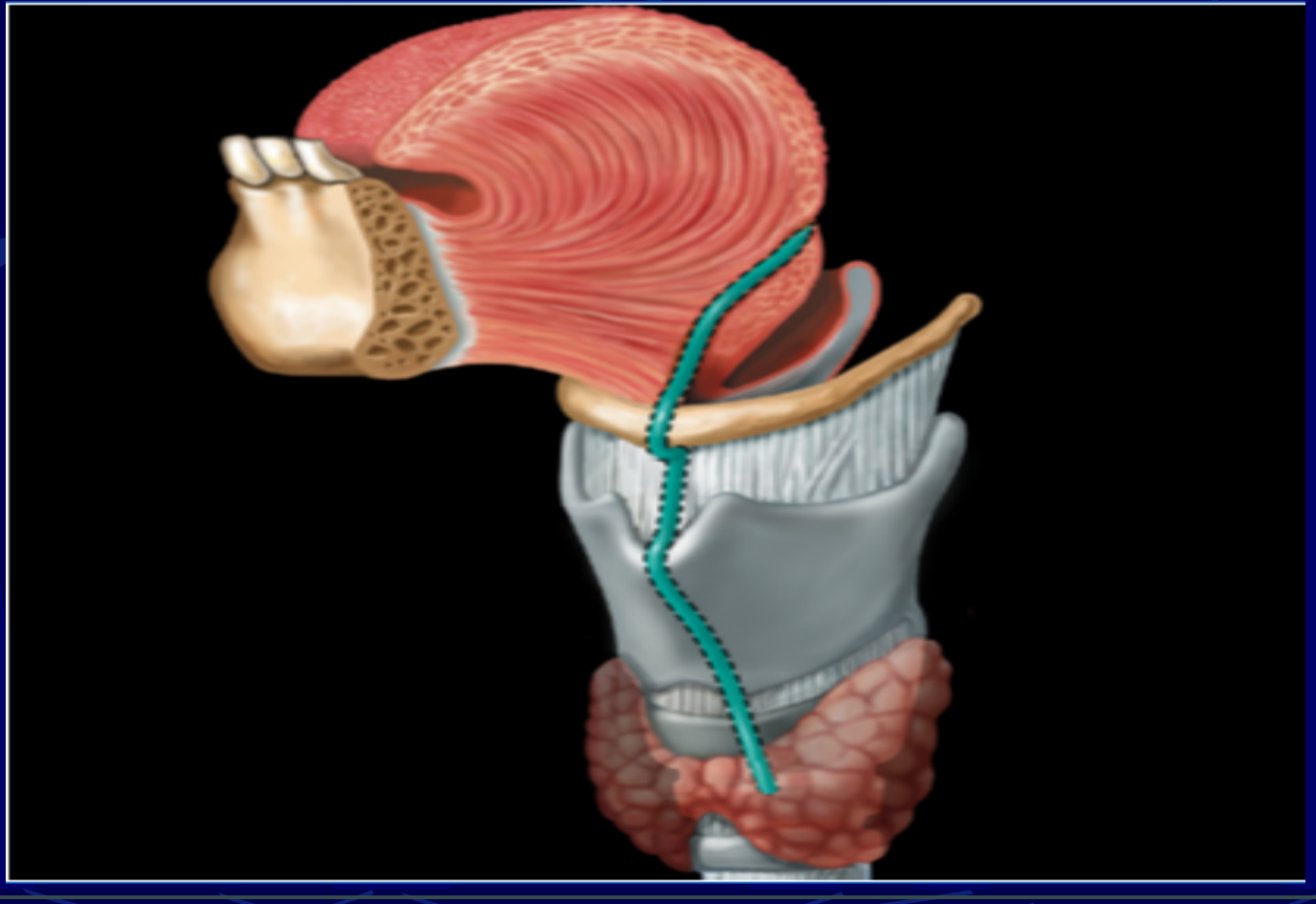



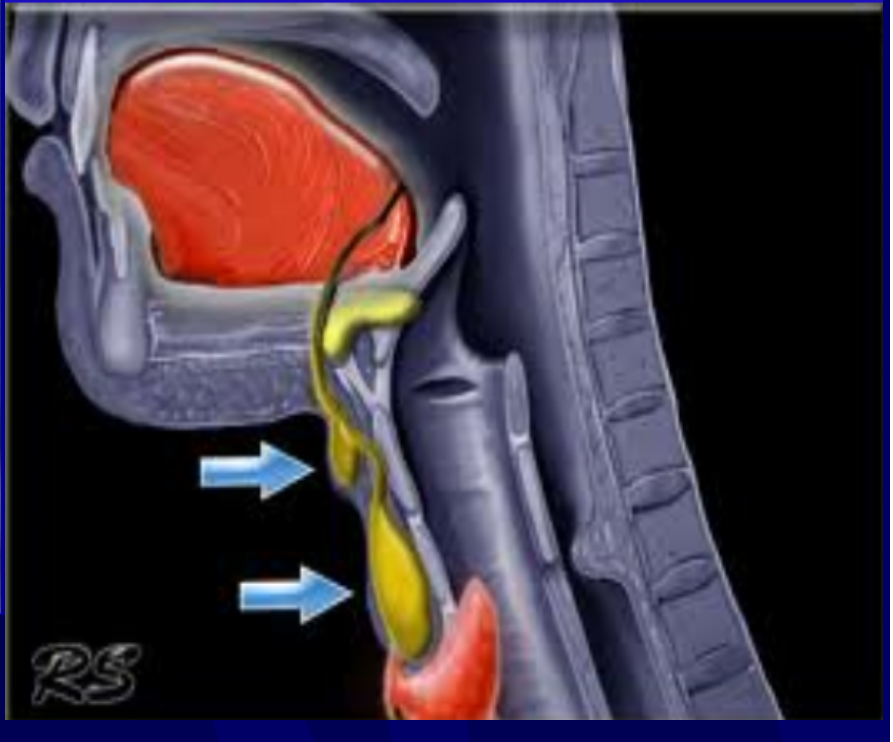
RS

Thyroglossal cyst

non infected cyst



infected cyst



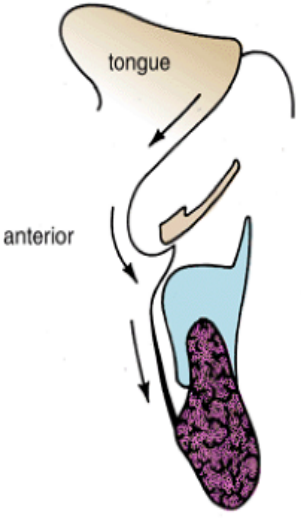

path taken by thyroid gland as it descends in the neck

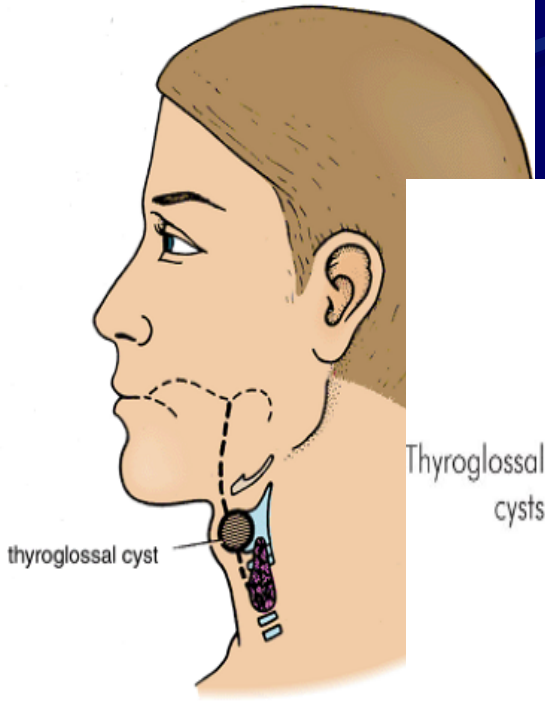

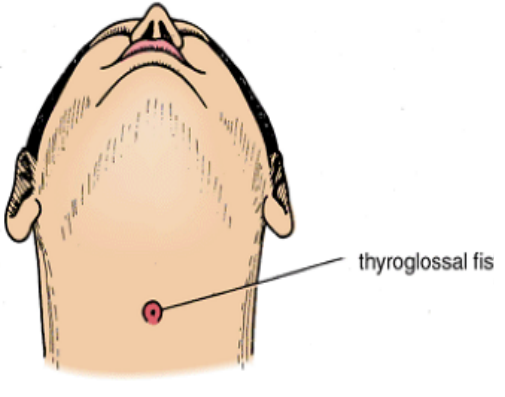

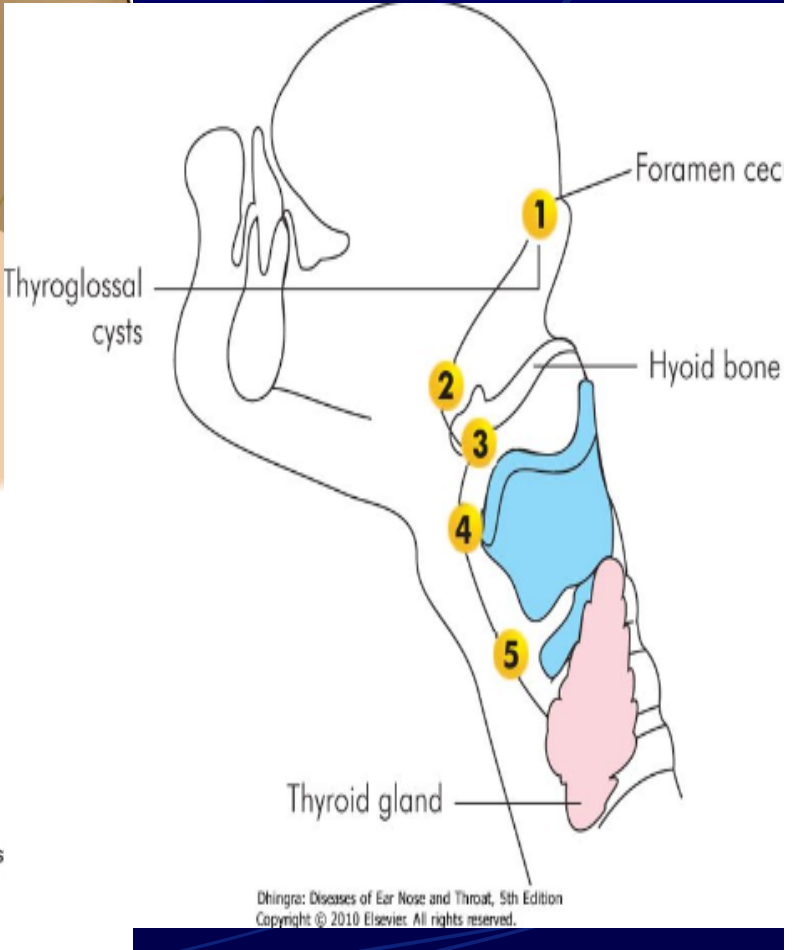

Copyright © 2010 Elsevier. All rights reserved.

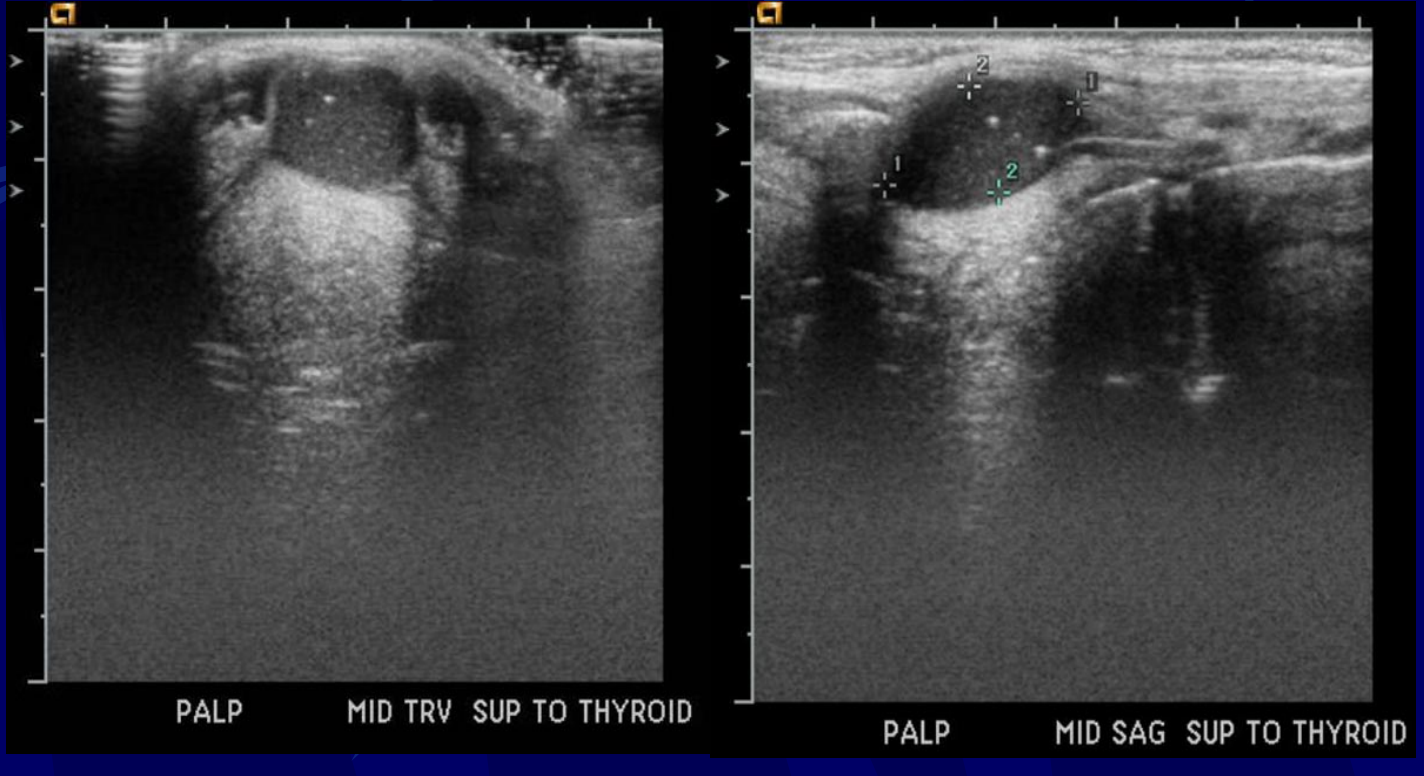
PALP MID TRV SUP TO THYROID
PALP MID SAG SUP TO THYROID

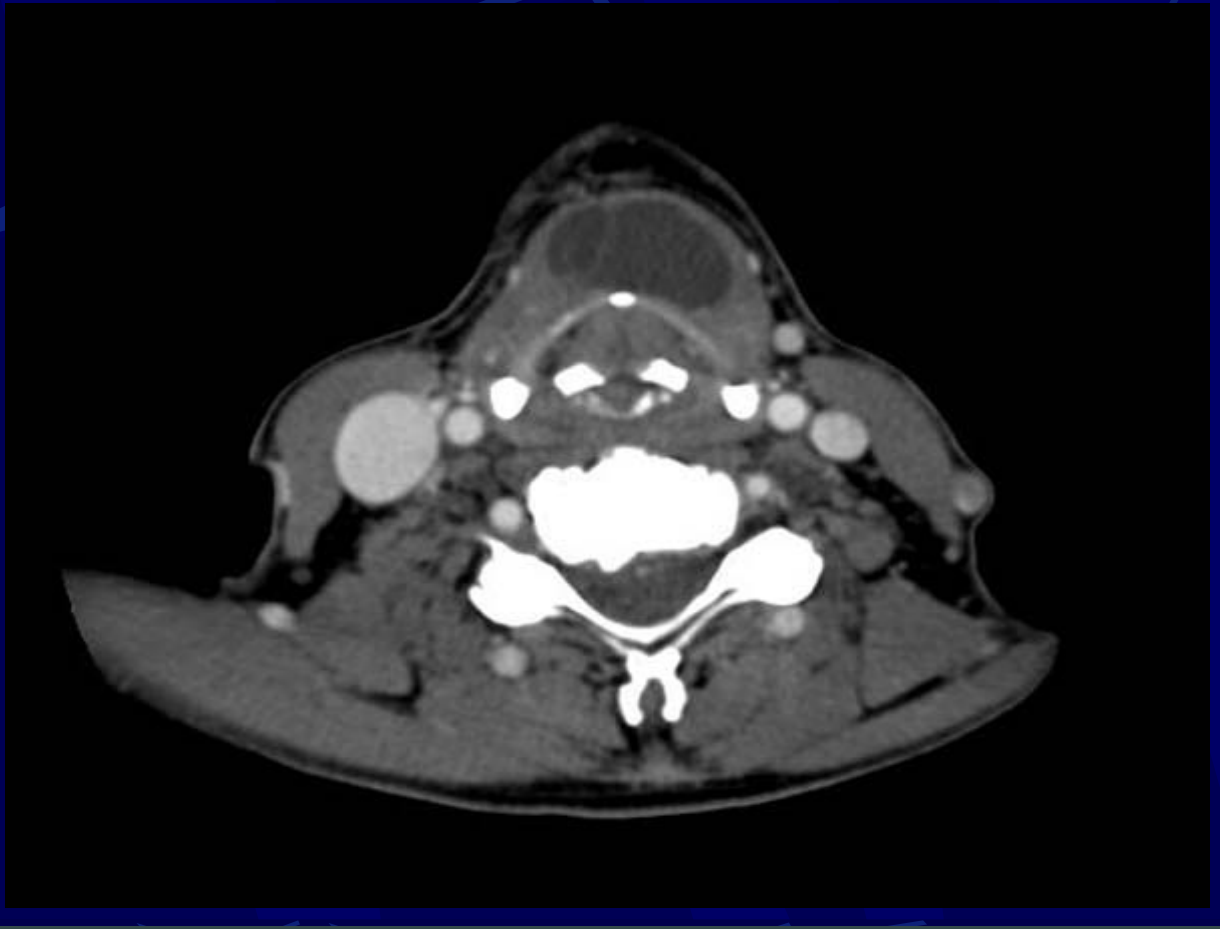

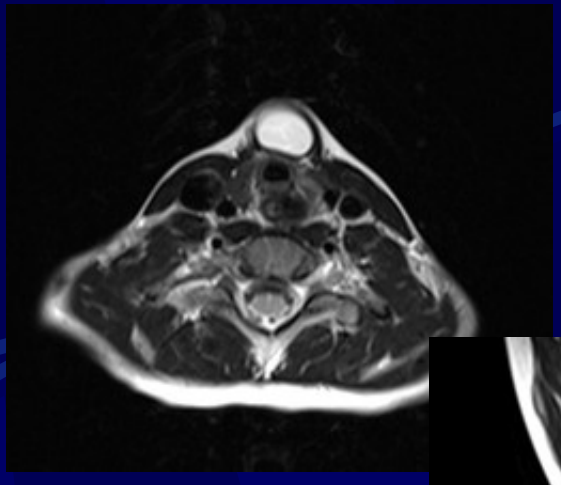

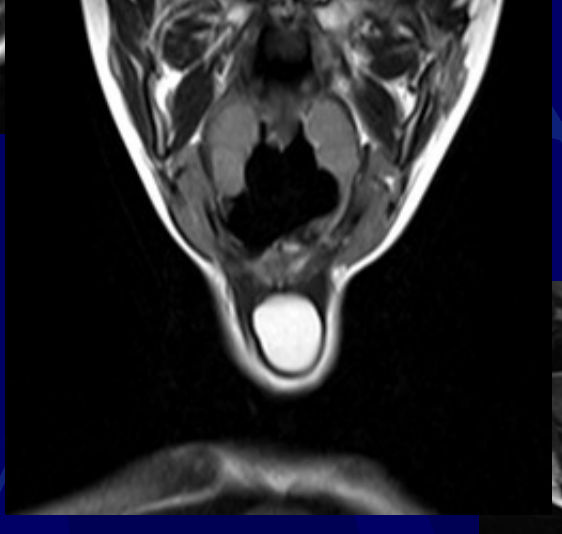

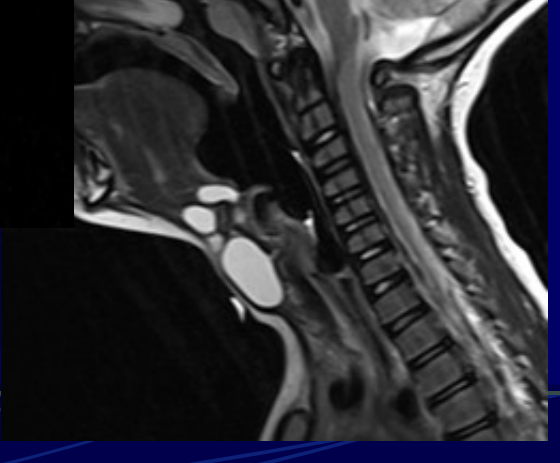

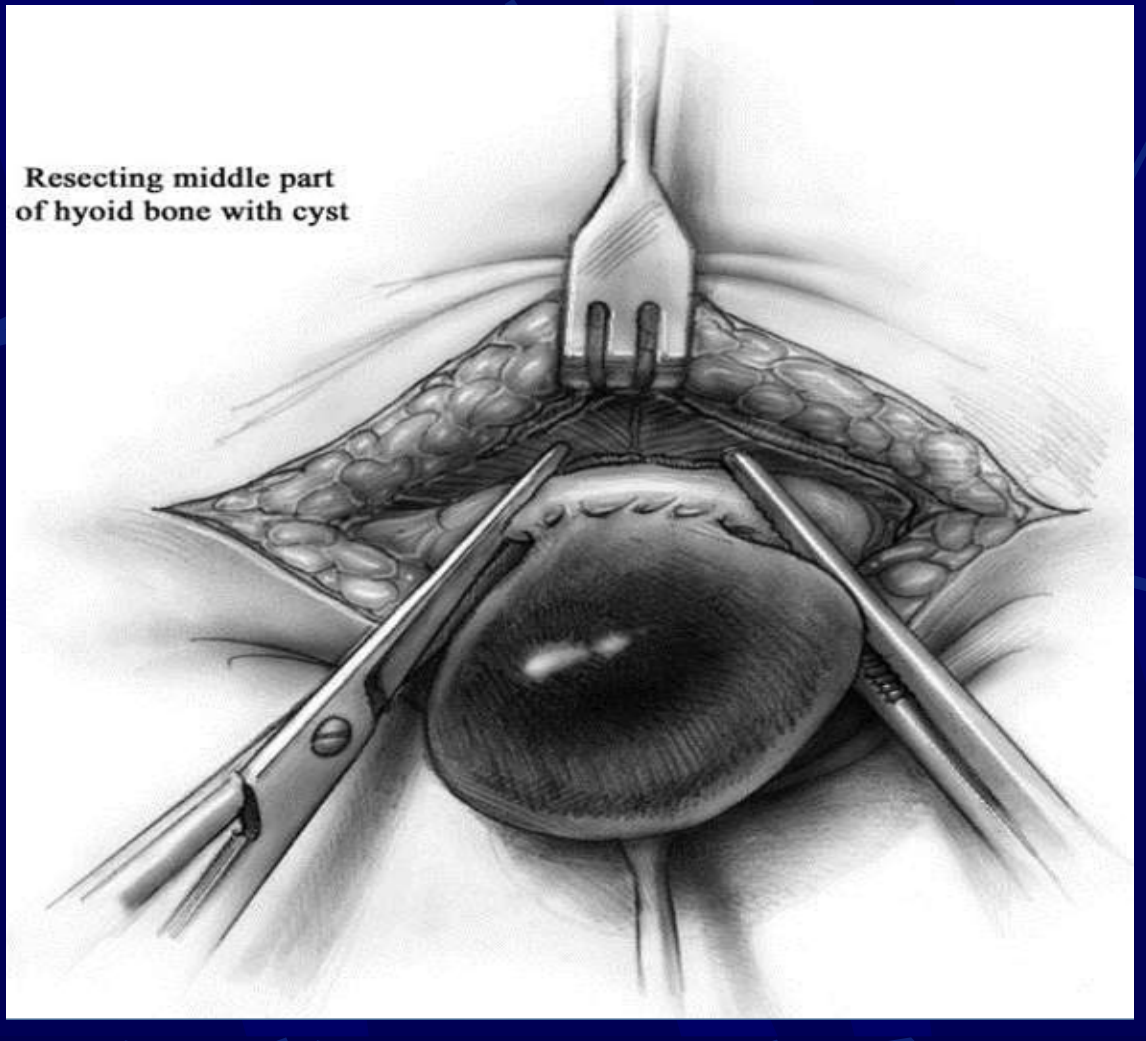

Sistrunk's Operation I

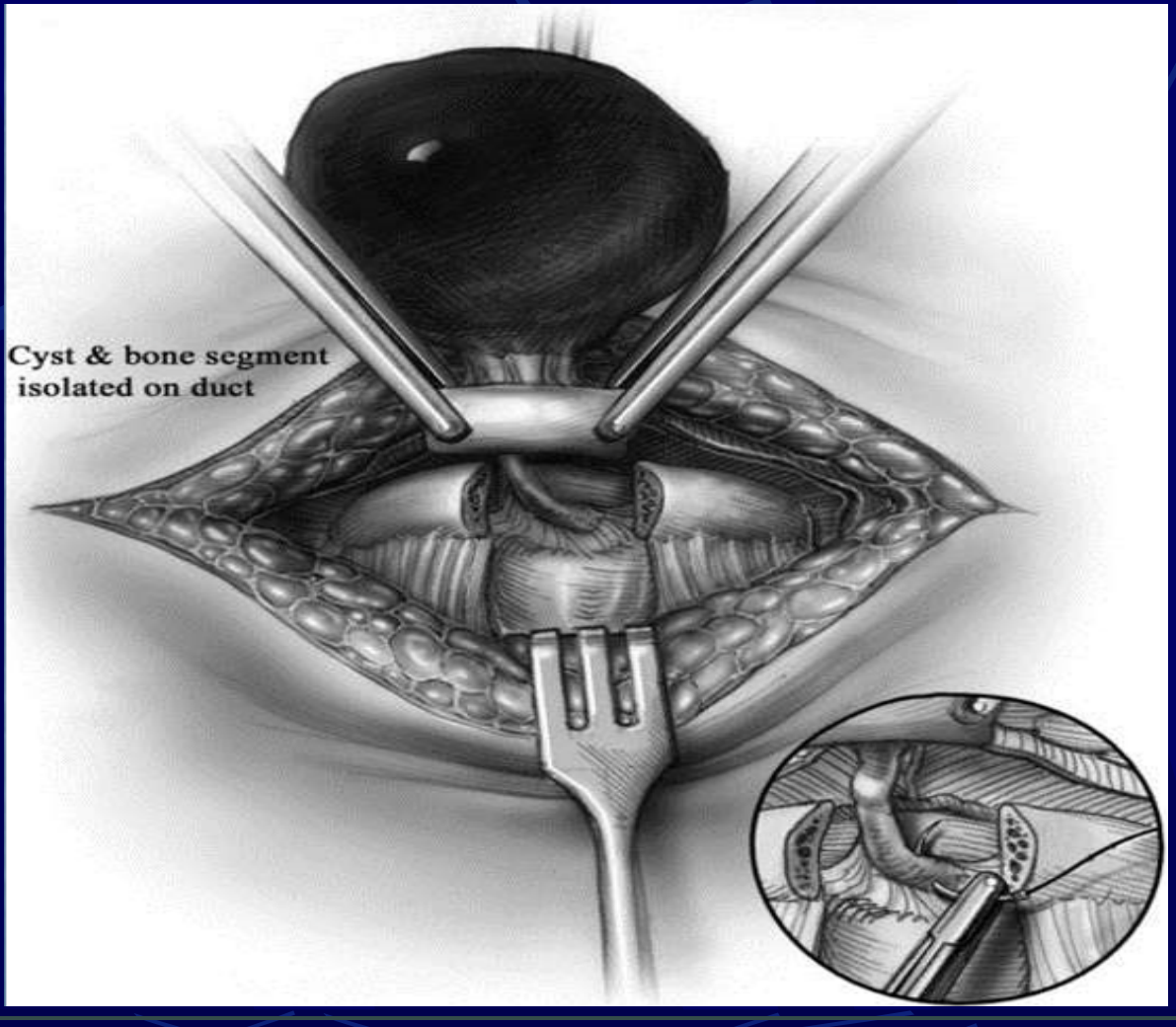

Sistrunk's Operation II

Cystic hygroma (lymphangioma)

→ neonatal surgery [difficult] has ↑ risk for recurrence..

Collection of lymphatic sacs which contain clear colorless lymph.

Congenital no sex prevelance .

Present at birth 50% or within the first years of life , usually 90% at 2 years.

Commonly found at the base of the neck, junction of upper 2/3 and lower 1/3 of SCM border occupying large space . ***Posterior***

Lobulated and flattened cysts. * multiple vesicle - thin wall..

Soft

Smooth and very close to skin and contain clear fluid → ***Trans illumination*** . [Translucent: clear lymph]

Diagnosis and management

US, CT scan MRI.

The modern management of most lymphatic malformations includes the combination of *Surgical Excision and Image-Guided Sclerotherapy*.



Cystic hygroma

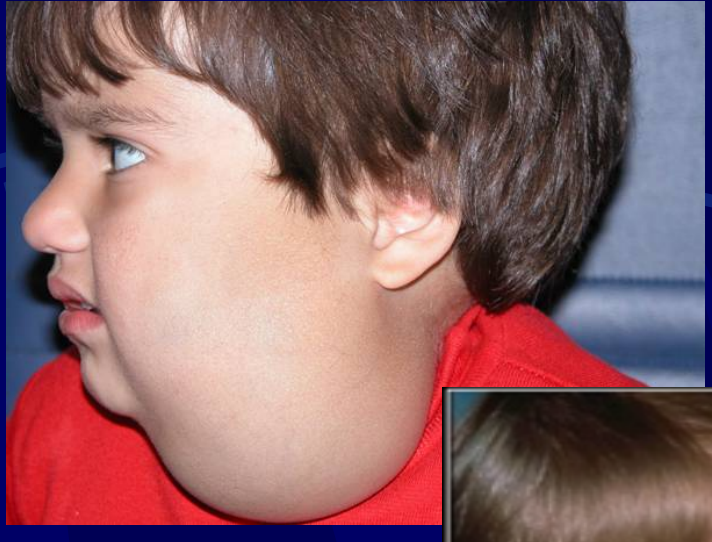





Cystic hygroma







Hemangioma(Birth mark)

may be flat or rise from the skin...

Capillary/ vascular hemangioma.

Purplish mass typical for diagnosis.

Can be found at any place in the body , mostly head and neck.

Girls: Boys 3 : 1.

* 1/3 cases appear at birth...

90% appear within 6 month of birth,10% disappear each year,70% disappear at 7 years.

The most common tumor of the body in children(Benign).

Treatment: propranolol liquid , Surgery / Laser/ Steroids.

B-Blocker [lead to feeding BV spasm → ↓ BF] ↓ size

or maybe we use the Atropine sulfate...



©Mayo Foundation for Medical Education and Research. All rights reserved.









Inclusion Cyst

[pinch test] under the skin

Acquired Dermoid cysts

↳ called implantation dermoid

Result from a part of the skin being traumatically implanted in the deeper layers after ectopic formation of a dermal cyst lined with squamous epithelium.



Congenital Inclusion Dermoid cysts

↳ called :- sequestration dermoid...

Form along the lines of embryologic fusion and contain both dermal and epidermal derivatives. Dermoid cysts of the head and neck are thought to be the congenital inclusion type.

ext. angle of dermoid

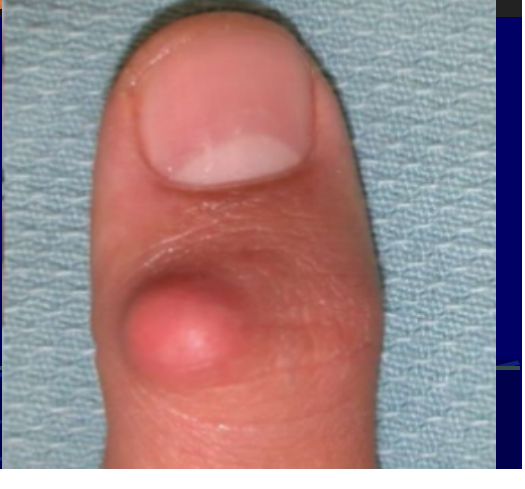

* outside the skull [< 1% inside [connect with] the skull need us or MRI]

there is intracranial part...








A

Dermoid cyst

Cystic teratoma need excision...

Contains mature skin complete with hair follicles and sweat gland. sometimes clumps of hair, and often pockets of sebum, blood, fat.

Almost always benign and rarely ma

Midline mass.

Not move with protruding the tongu

Solid or hard in consistency.

Usually limited to the skin



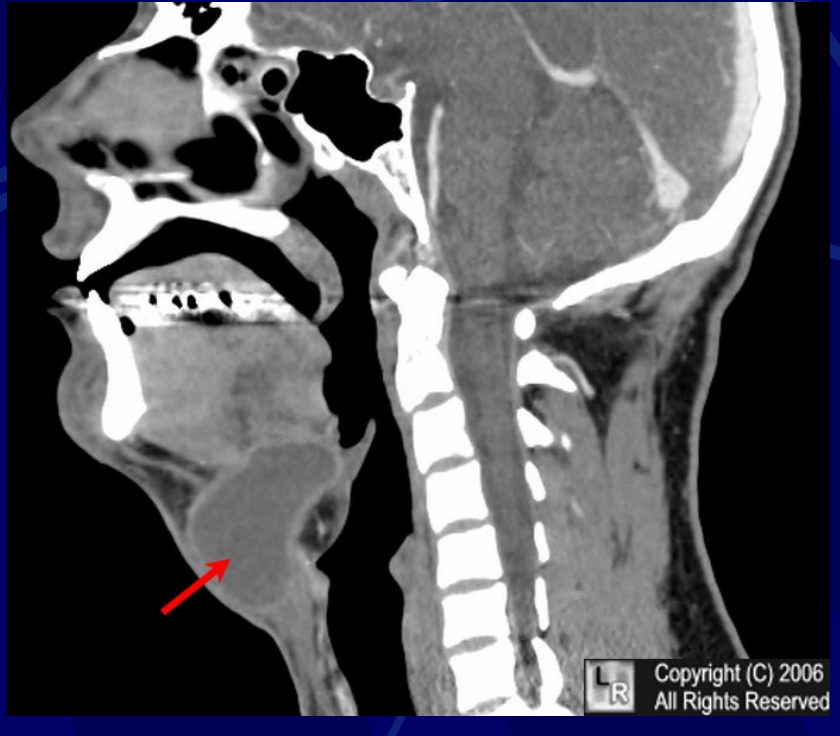
Copyright (C) 2006
All Rights Reserved



Ranula

Cystic swelling floor of mouth(Ranula little Frog).

Mucus extravasations from sublingual salivary gland

has whartonian duct

which secrete : mucus secretion...

May extend through FOM muscles into neck

floor of the mouth M.

"Plunging Ranula"

appear in the neck...





Ranula





Sternomastoid Tumor

Ischemic Contracture of a Segment of the SCM Muscle

A swelling of the middle third of the SCM.

In Neonates: **edema around an infracted segment of the muscle caused by birth trauma.**

As the patient grows the muscle becomes fibrotic and contracted .

SCM tumor

- Neck swelling at birth.
- Torticollis.
- Fibrosis → chronic torticollis .
- Examine the lump, neck, head and eyes.
- Examine for squint in straight head position (secondary torticollis) .
- ***Treatment*** by physiotherapy stretching exercises.





Torticollis

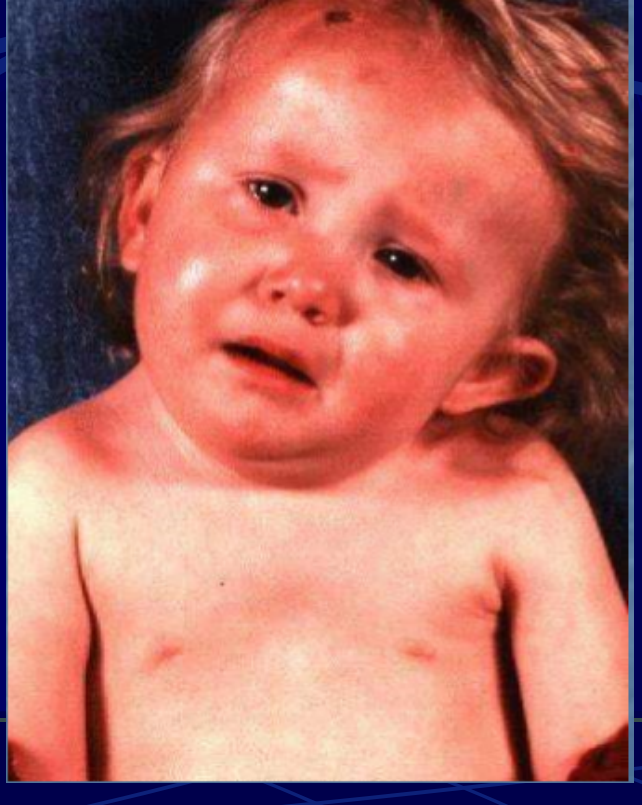



Thank You

Head and neck cancers

- 6th most common cancer overall.
- H&N SCC 5% of all cancers.
- SCC most common upper aerodigestive malignancy.
- Smoking and ETOH.
- 50% of head and neck cancer occur in oral cavity
- Multidisciplinary approach



Small floor of mouth SCC
N3 neck disease



T4 floor of mouth SCC
0/83 neck nodes





2. Metastatic lymph nodes

(Enlarged lymph node- Asymmetric- Adult)

Remember

Primary cervical malignancy is rare and almost all malignant cervical tumors except for lymphomas are metastatic.



When a patient comes to you with a malignant neck mass……

1. Step: Detailed History

- **Risk factors:**
  - ***Age***
  - Cigarette.
  - Alcohol.
  - Sun exposure: skin malignancies
  - Previous irradiation: thyroid, salivary glands.

- **Duration of the mass: infection vs malignancy**
- **Pain: infection, tbc**
- **Previous malignancy?**
- **Concomitant symptoms**

Otalgia, epistaxis, dysphagia, hoarsness, dyspnea……

2. Step: Physical examination

1. Localization of the mass in the neck

Level I masses:

Submental area

- Floor of the mouth
- Lip tumors

Submandibular area

- Anterior tongue
- Floor of the mouth
- Retromolar trigone

Level II masses:

- Oral cavity
- Oropharynx and tonsils
- Supra-glottic larynx
- Hypo-pharynx
- Nasoopharynx

Level III masses:

- Larynx
- Hypo pharynx
- Thyroid

Level IV masses:

- Subglottic larynx
- Thyroid
- Cervical esophagus
- Lung

Level V masses:

- Esophagus
- Lung
- GIT
- Nasopharynx

Level VI masses

- Thyroid
- Subglottic larynx
- Trachea

2. Characteristics of the mass:

- Hard and fixed
- Tender
- Multiple, elastic and mobile

3. Complete head and neck examination

- Scalp and skin examination.
- Thyroid examination
- Salivary gland examination

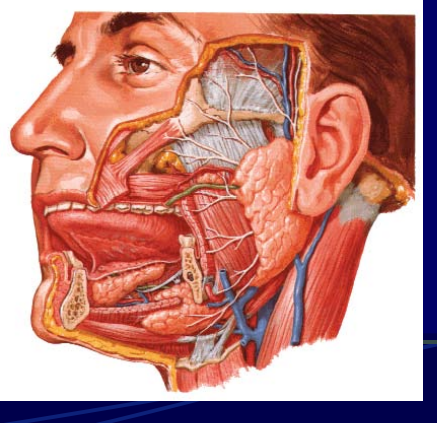

Summary

***If a patient comes with a tumoral mass in the neck*:**

- **Try to find the origin of the mass**

- **Do not rush to take biopsy**

And….

1. Take a very good history
2. Do a very careful head and neck examination and Consult the otolaryngologist of a complete ENT examination
3. FNABx
4. Radiologic evaluation (chest x-ray + neck CT)
5. Panendoscopy (otolaryngologist)
6. Excisional biopsy, frozen section,

Pearls

- Avoid excisional biopsies
- Use ***CT*** but consider MRI for salivary gland problems
- Role of nonionizing ultrasound
  Like a stethoscope?