Tracheoesophageal fistula

↳ The mortality rate high if we don't have ICU [pre and post op. care]...

* The most worried complication of surgery is leakage. [mc c of leak is tension]...

Dr. Elias arteen
FRCSI
Consultant surgeon

Definition

Developmental Anatomical Discontinuity of Esophagus with or without Communication with Trachea .

[مش كامل ال tract] مكر

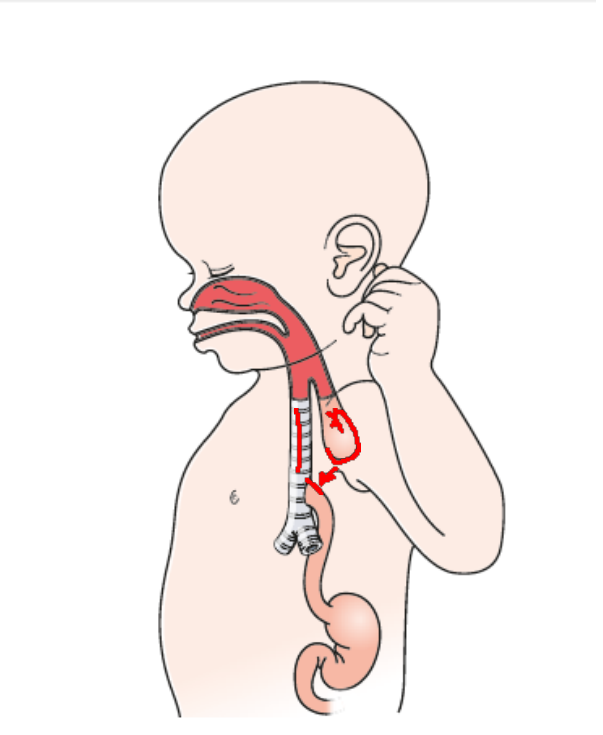

* may associated with imperforated anus or cardiac anomaly [mc]

↳ espically the:- VSD

Incidence

It is the most common congenital malformation of the esophagus.

Incidence approximately 1 out of every 3,000 babies.

Slight male predominance

60%-70% have other anomalies

10% have non-random non –hereditary association. [vectral anomaly]...

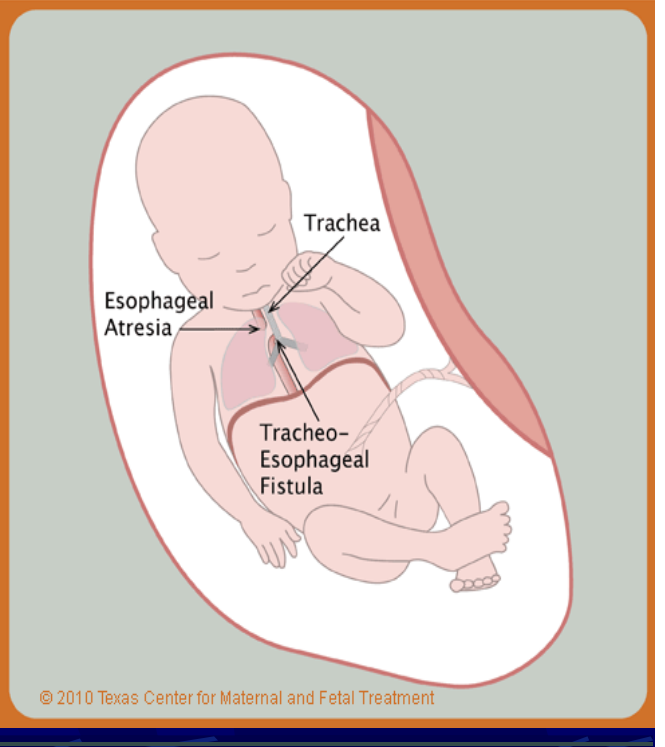

* The BS of the esophagus:-
1. inferior thyroid A. [good BS]
2. Bronchial A. from the abdominal Aorta
weak
3. If. gastric A. from the celiac trunk..

⇐ لو ضلينا نعمل mobilization بشكل كبير في ال distal esophagus راح يفردي لقطع ال BS يم جاي من ال If gastric or Aorta فراح يصير Ischemia...

* pt has fevere post op [may inelicate leak] so we do gastro graffin enema with CT to diagnose the leakage...

* when we do the neck disection we see:-
1. subclavian A.
2. internal jagular vein..
3. common carotid A.
4. Phrenic nerve...
5. spinal accesory nerve...

Type A



ما في اتصال ما بين ال trachea
and the esophagus..
so lead to gasless abdomen...

* 90% of cases has gas in the abdomen → abdominal distention → راح يرفع ال resp. distress ← diaphragm

Type B



Type C


- The esophagus is closed + there is distal connection Between the distal pouch of the esophagus and the trachea... [the connection is usually within 1cm from the carina]...
* There is gas in the abdomen...
Proximal atresia
Distal fistula
~85%
F Gaillard 2010
Radiopaedia.org CC-NC-SA-BY

* Any connection with the proximal trachea → the baby will die...
[Type B and D]...

Type D



Type E

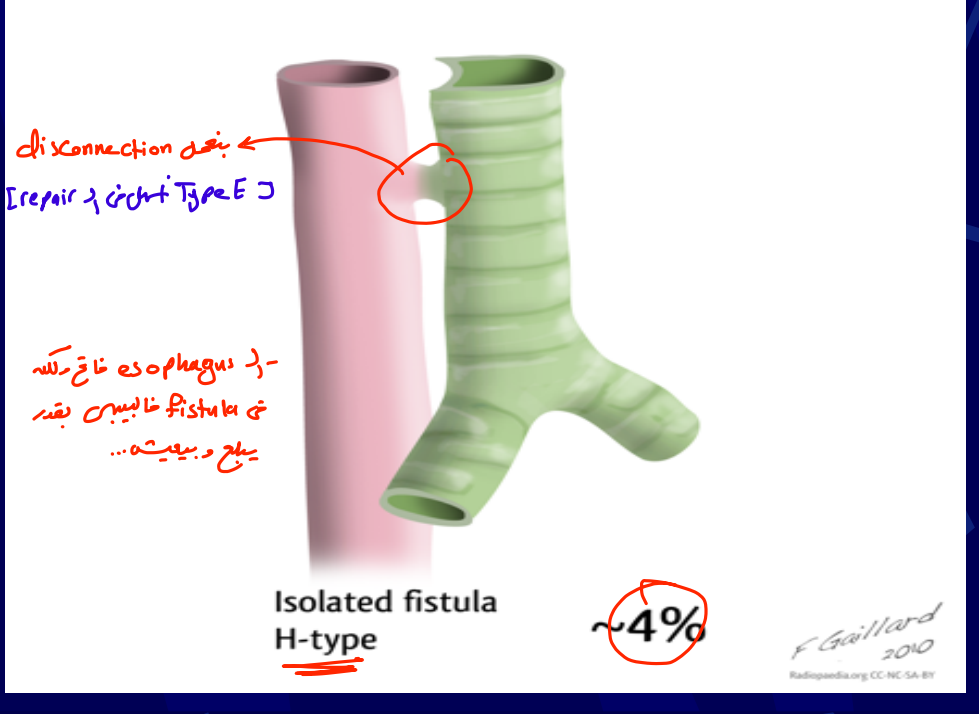

disconnection بنعمل
[repair ال ثابت Type E]
esophagus ال- فاتح ولكن
في fistula فالبيبي بقدر
يبلع و بيعيش...
Isolated fistula
H-type
~4%
F Gaillard
2010
Radiopaedia.org CC-NC-SA-BY

5 main categories of congenital TEFs:

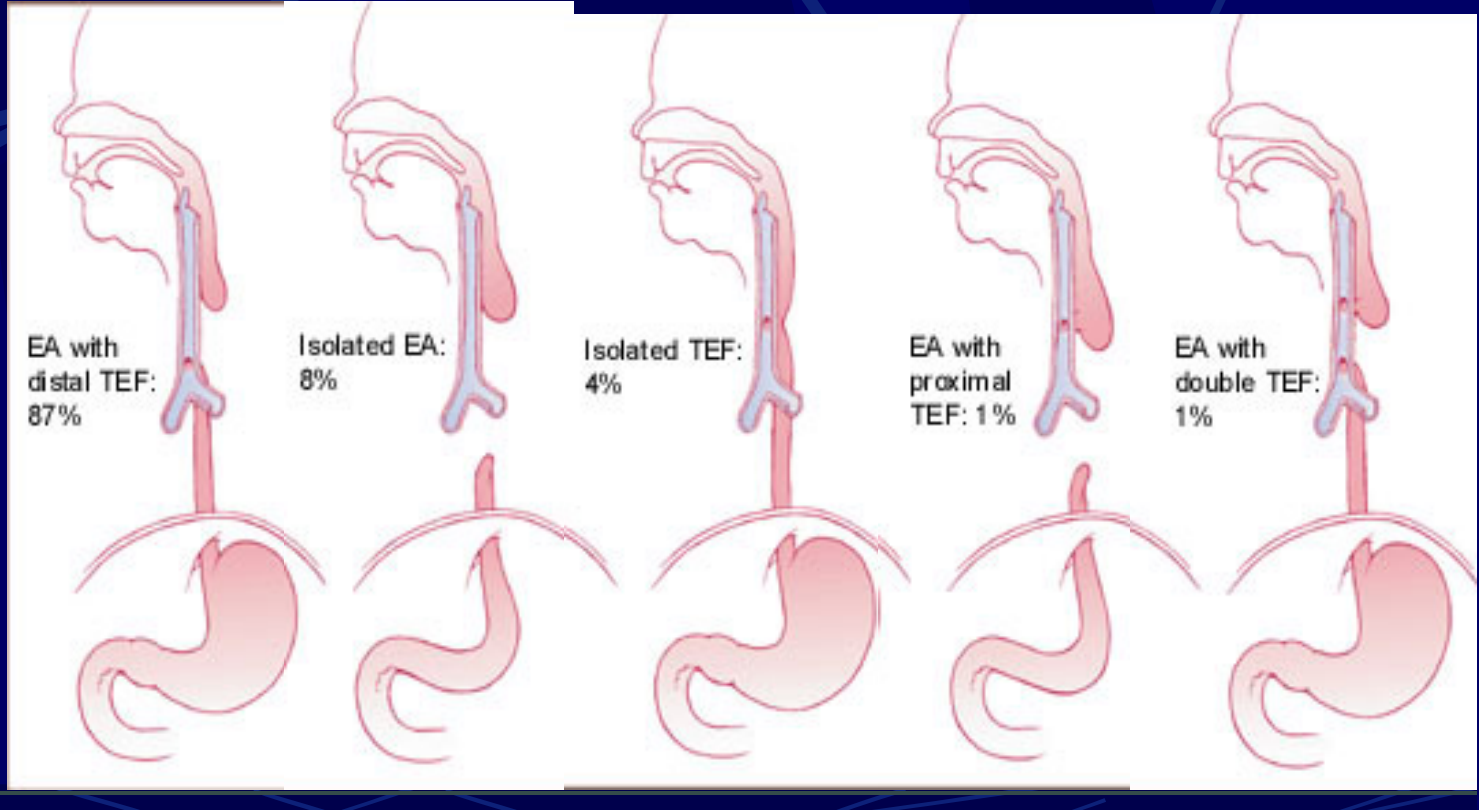

Types

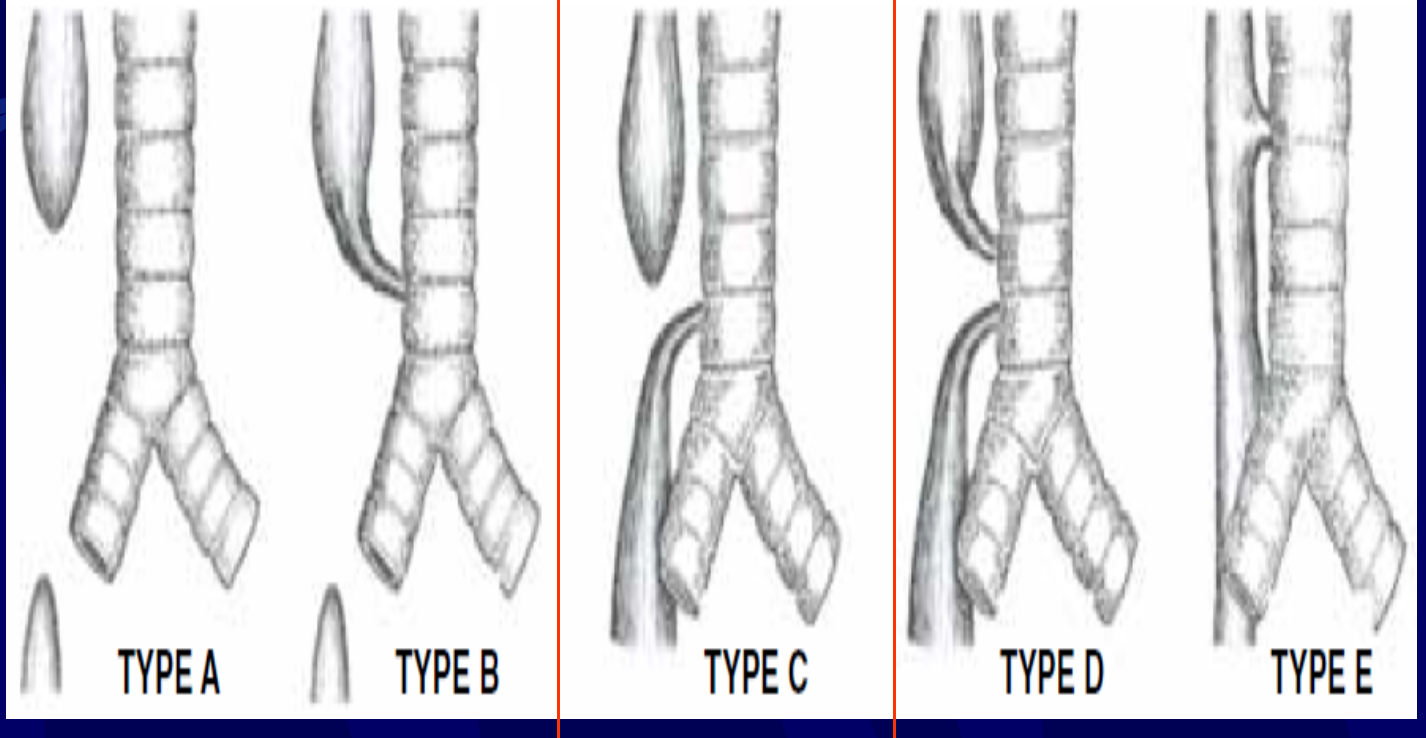

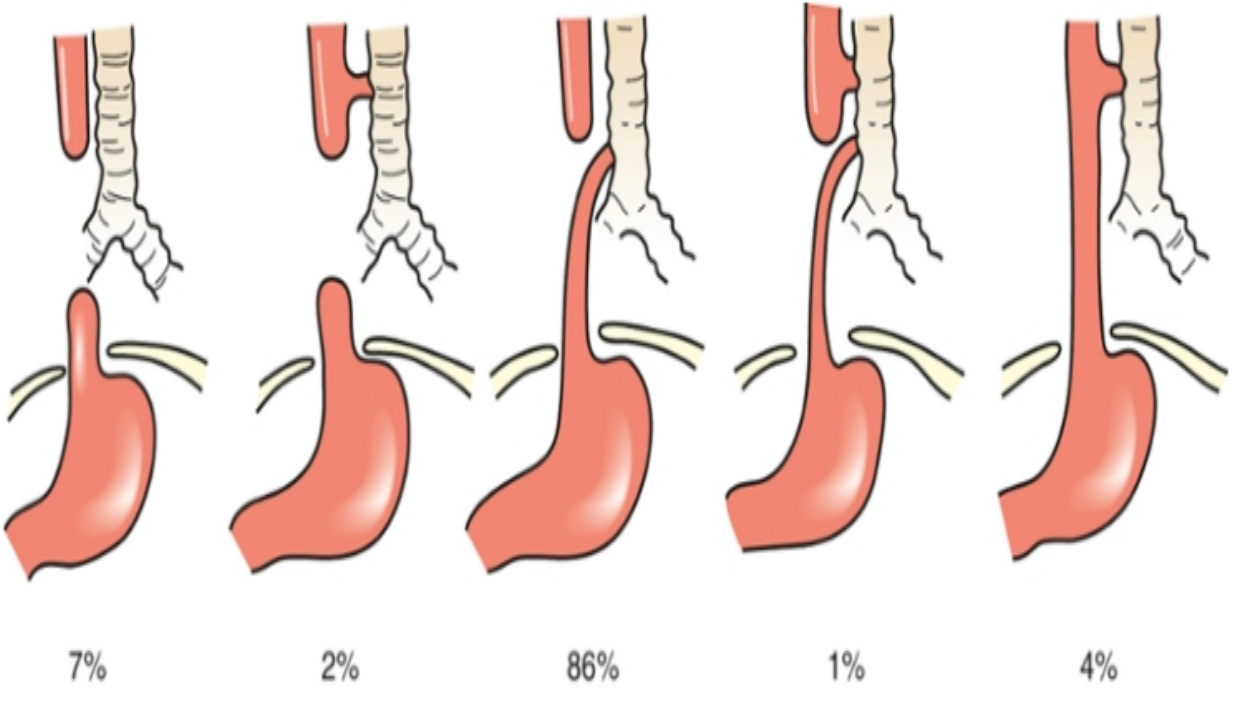

FIGURE 66-6 Anatomic variants and incidence of esophageal atresia with tracheoesop...

Clinical presentation:

Depends on the type

1,2,3,4 (with EA) Copious, fine white ***Frothy Bubbles*** of mucus in the mouth and nose , Baby can't be fed. only can Feed in type E..

2,4 First feeding may cause sudden arrest sudden death . due to proximal connection...

5 (without EA) Rattling respiration and episodes of coughing and choking in association with cyanosis.

3,4,5 *Abdominal Distention* may occur secondary to collection of air in the stomach (Atelectasis Respiratory failure) . → due to distal connection in 90% of cases...

1,2 *Gasless abdomen.*

Frequency of associated anomalies in esophageal atresia

Abnormality	Percentage
Cardiac VSD [mc] - ASD	25
Gastrointestinal	22
Vertebral/Skeletal	20
Renal	15
Chromosomal (Trisomy 18 & 21)	7

- **10% have non-random non –hereditary association**

VACTERL Syndrome

1. **V**ertebral anomalies.
2. **A**norectal malformation.
   - High [severe] and low...
3. **C**ardiac anomalies.
4. **T**racheo-esophageal fistula.
5. **E**sophageal atresia.
6. **R**enal anomalies.
7. **L**imb anomalies.

Vertebral anomalies

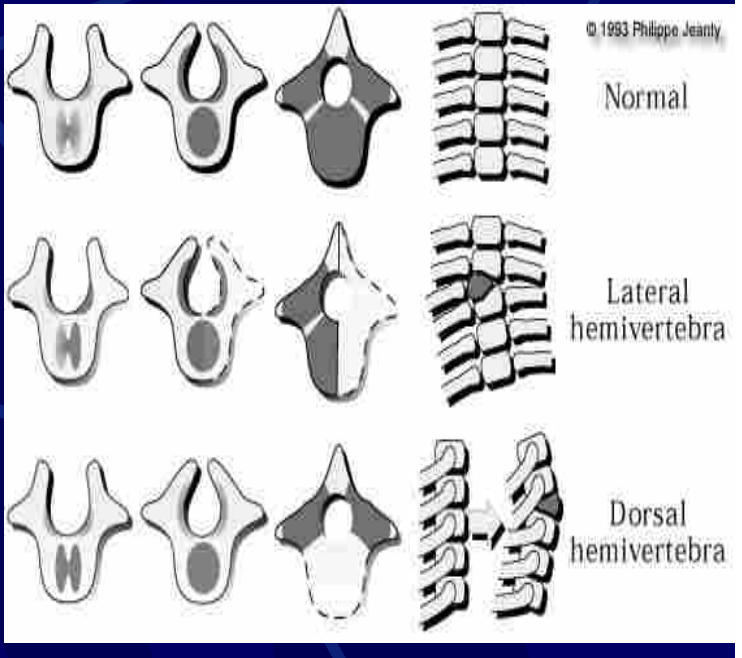

70 % of patients with VACTERL association

-*small (Hypoplastic) vertebrae or Hemivertebra*

-may put the child at risk for developing *scoliosis* or curvature of the spine.



Anorectal malformation

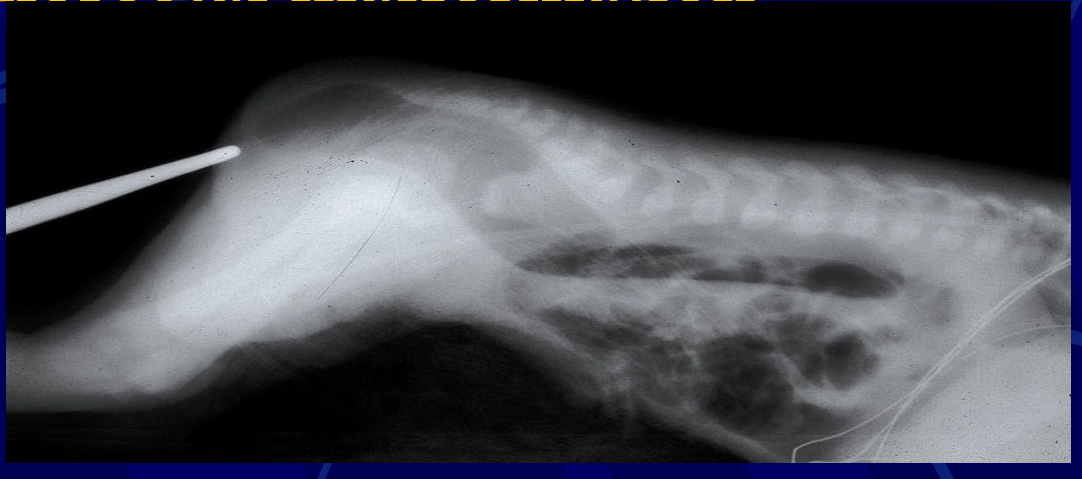

- **55% of patients with VACTERL association usually noted at birth and often require surgery in the first days of life.** ← كل ما كانت لتحت يعني أفضل ولكن الى فوق بتكون اخطر...

Cardiac anomalies

75% of patients with VACTERL association.

The most common heart defects seen are ventricular septal defect *(VSD)*, atrial septal defects *(ASD)* and tetralogy of Fallot.

Less common defects are transposition of the great arteries *TGA.*

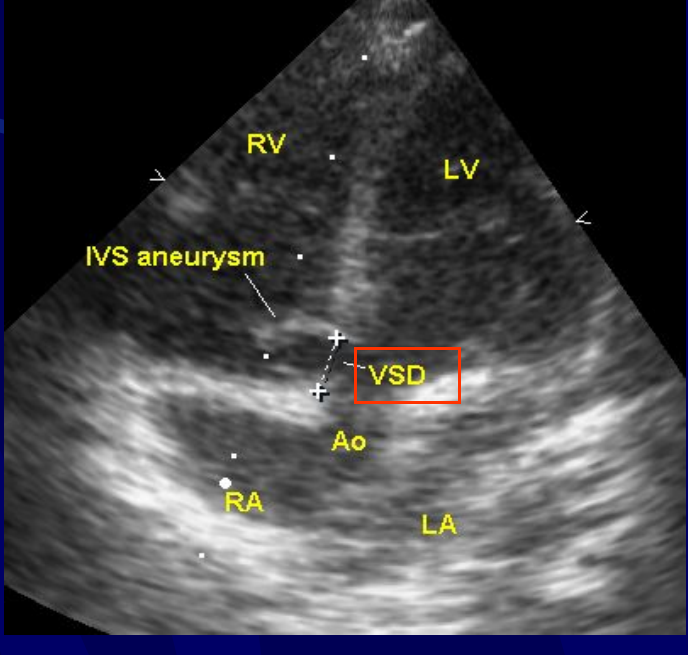

لازم ال NG tube تكون semirigid حتى لا تسبب esophegeal perforation

Tracheoesophageal fistula

coiling of NG tube...

- **70 % of patients with VACTERL association, although it can frequently occur as an isolated defect.**

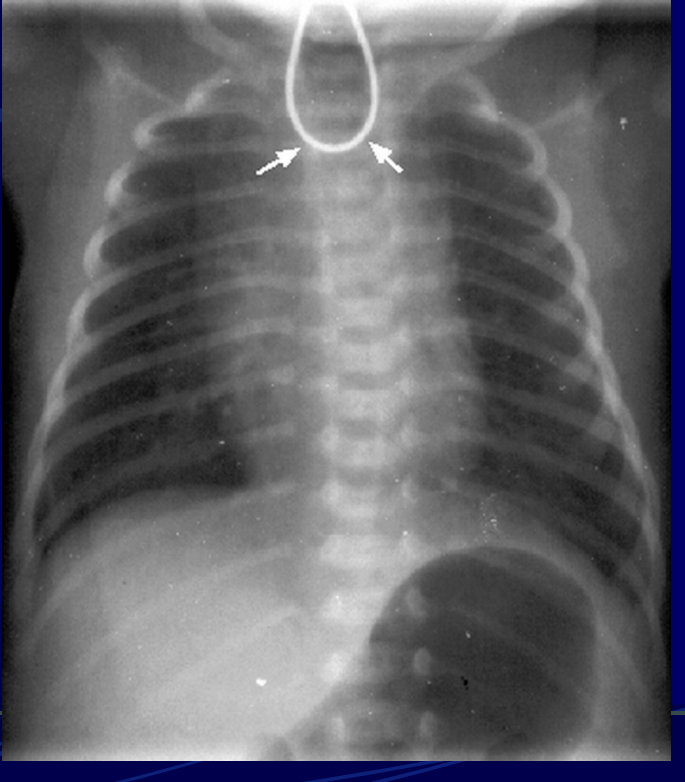

* The ureter length:- 25cm ① The upper part upto the sacro iliac joint ② The middle joint upto ischial spine ③ The lower part

Renal anc

50% of patients with VACTERL association.

- Renal agensis or severe reflux. → visico uretric reflux







Limb anomaly

75% of patients with VACTERL association.

- include

Hypoplastic Thumb,

Extra digits (polydactyly)

fusion of digits (syndactyly) and forearm defects such as radial aplasia.











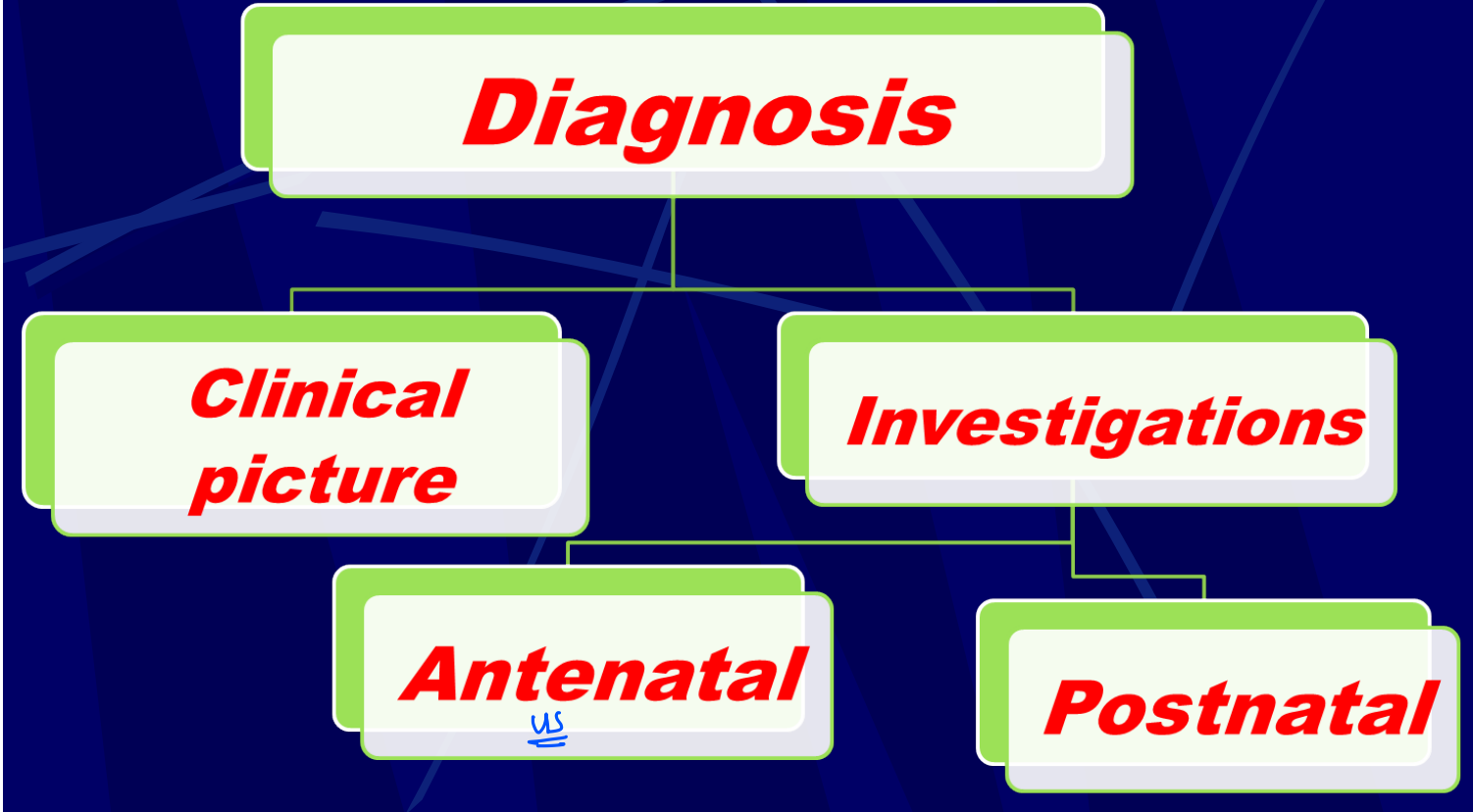
Diagnosis
Clinical picture
Investigations
Antenatal
US
Postnatal

Symptoms

Drooling of *Frothy Saliva* from the angle of the mouth.

Attacks of chocking and cyanosis on feeding.

↳ Blowish discoloration of skin and mucos membrane due to ↓ oxygenated Blood

Abdominal Distension (progressive) .

↳ in type 3-4-5...

Tachypnea and Aspiration pneumonia.

Signs

- Passage of a semi-rigid radio-opaque 10F catheter will be arrested and coiled back.
- Signs of respiratory distress
- Abdomen is distended in cases of large fistula.
- Other anomalies eg. Imperforate anus, skeletal anomalies.

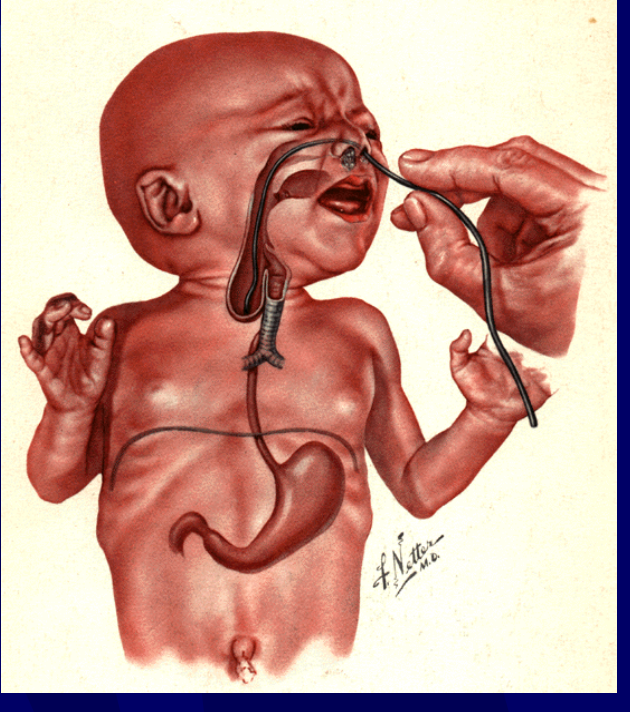

Causes of Respiratory Distress in EA/TEF

1. Regurgitation of saliva.
2. Regurgitation of milk on feeding attempts .
3. Reflux of gastric acid through distal pouch.
4. Abdominal distention when large fistula is present . So we don't put NG tube...

Investigations

Antenatal US

1. **Polyhydramnios**
   - occur also in pyloric stenosis
2. **Small stomach**
3. **Associated anomalie**





Fetal MRI

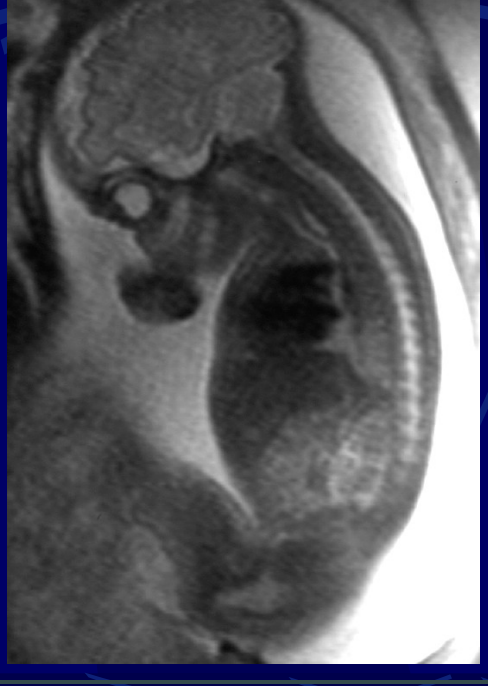



This 32 week fetus had esophageal atresia and an absent stomach, resulting in marked polyhydramnios

Investigations

Plain X-ray chest & abdomen

Blind upper pouch with a marker tube (coiled tube).

Signs of aspiration pneumonia.

Stomach full of air from the distal fistula. in 90% of cases

Also, aortic arch location, presence of vertebral or

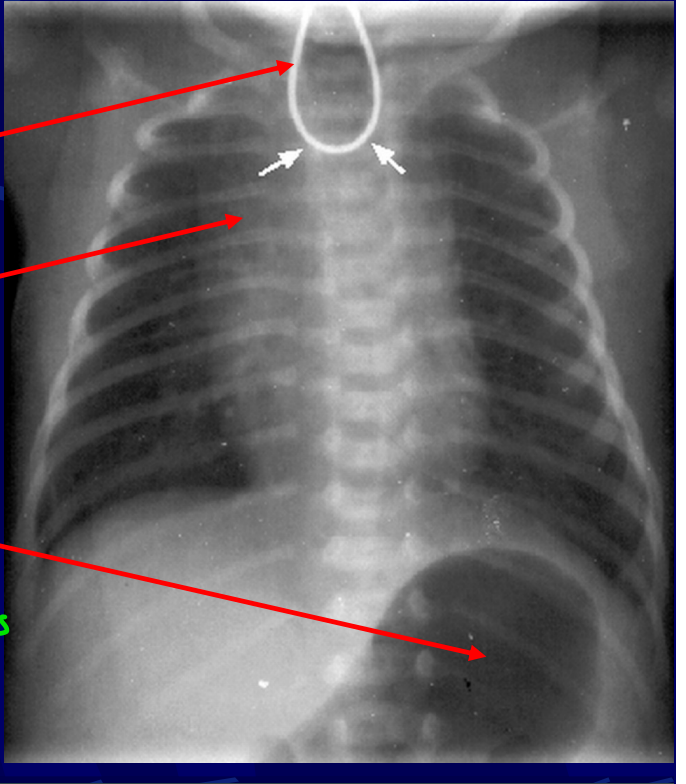

Investigations

Plain X-ray chest & abdomen

Blind upper pouch with a marker tube (coiled tube).

Signs of aspiration pneumonia.

Gasless abdomen indicates No Distal Fistula.

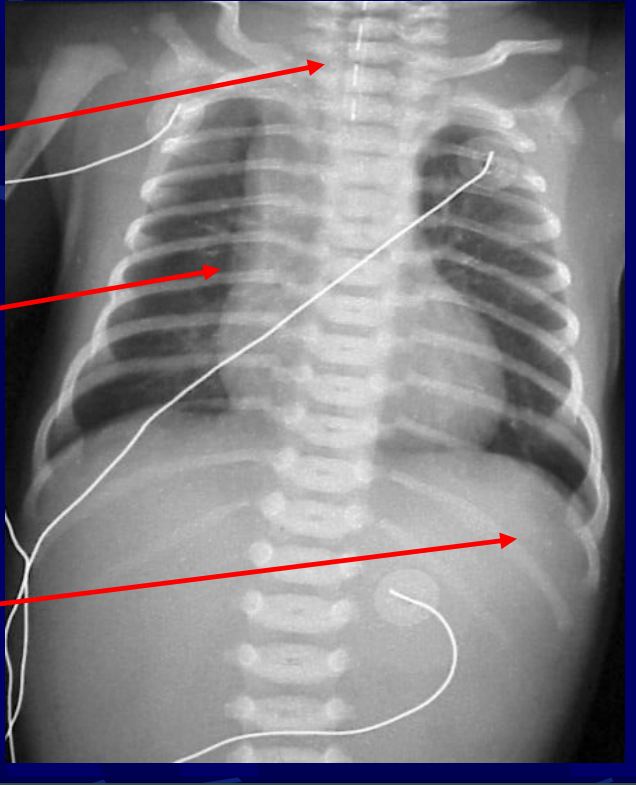

Clinical Diagnosis

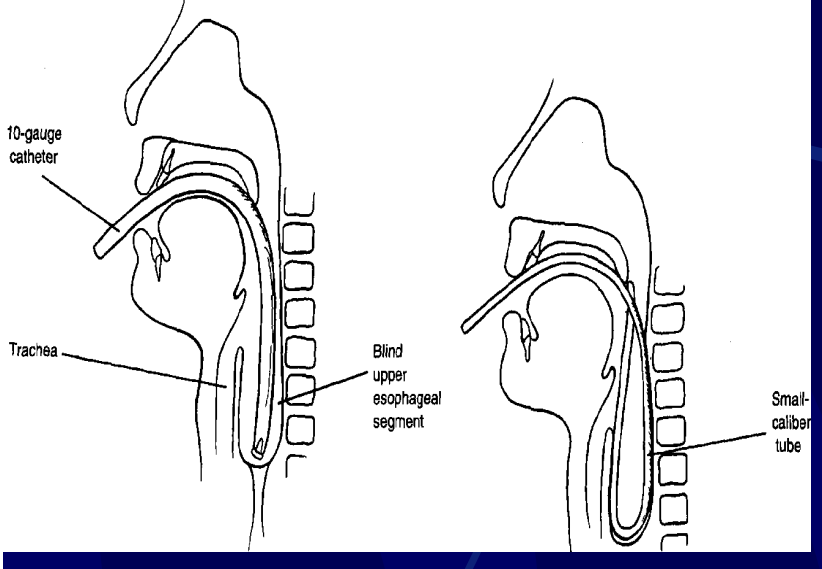

- (A) Diagnosis of esophageal atresia is confirmed when a 10-gauge (French) catheter cannot be passed beyond ***10 cm from the gums.***

(B) A smaller-caliber tube is not used because it may curl up in the upper esophageal segment, giving a false impression of esophageal continuity.

Investigations

- **Spinal US** to see if there is vertebral abnormalities...
- **Echocardiography**
- **Abdominal US**
- **Genetic counseling**

Treatment

← لغاية 8 سنوات بنضل نستعمل un cuffed endotracheal tube ...

Preoperative care

- Neonatal ICU admission and intubation.
- Head elevation at 45° (upright position). حتى ينزل ال diaphragm لتحت
- Continuous suctioning. حتى نمنع ال salivary aspiration
- IV fluids.
- IV Antibiotics.
- Intramuscular Vitamin K.

* Feeding gastrectomy :- في حالة العمليات الطويلة
* Avoid the Face mask :- حتى نعمل sucction
* cuffed endotracheal tube is placed distal to the Fistula site to prevent the aspiration...

↓ vit K in premature Babies...

Timing and selection of surgical intervention

The Degree of Prematurity

Baby weight .

Overall clinical condition .

Other associated anomalies .

Length of the gap between the ends of the esophagus.

⇐ الـ Tension عدد كل العمليات...

EA with TEF

* The Thoracotomy incision
  - Postro lat. → in chest problem
  - Antro lateral → - in trauma - in cardiac problem...

- In healthy near term or full-term infants without other severe anomalies and minimal pneumonitis:

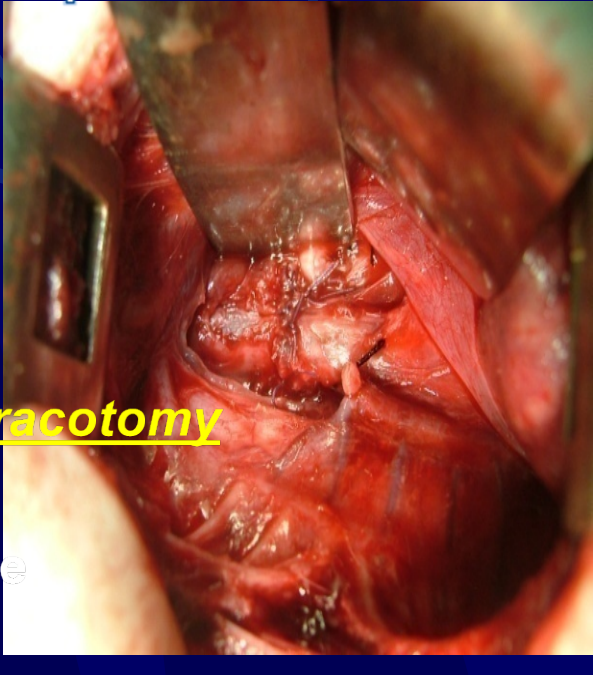

Primary Repair

- Within the first 24 to 72 hours after birth.
- ***Right Transverse Extra-Pleural Thoracotomy***
- Lower pouch is disconnected from the trachea by ligation & division of the fistula
- End to end anastomosis between the 2 pouches (distal and proximal ends نوصل ال)
- Rertropleural drain placement & closure.

Primary Anastomosis

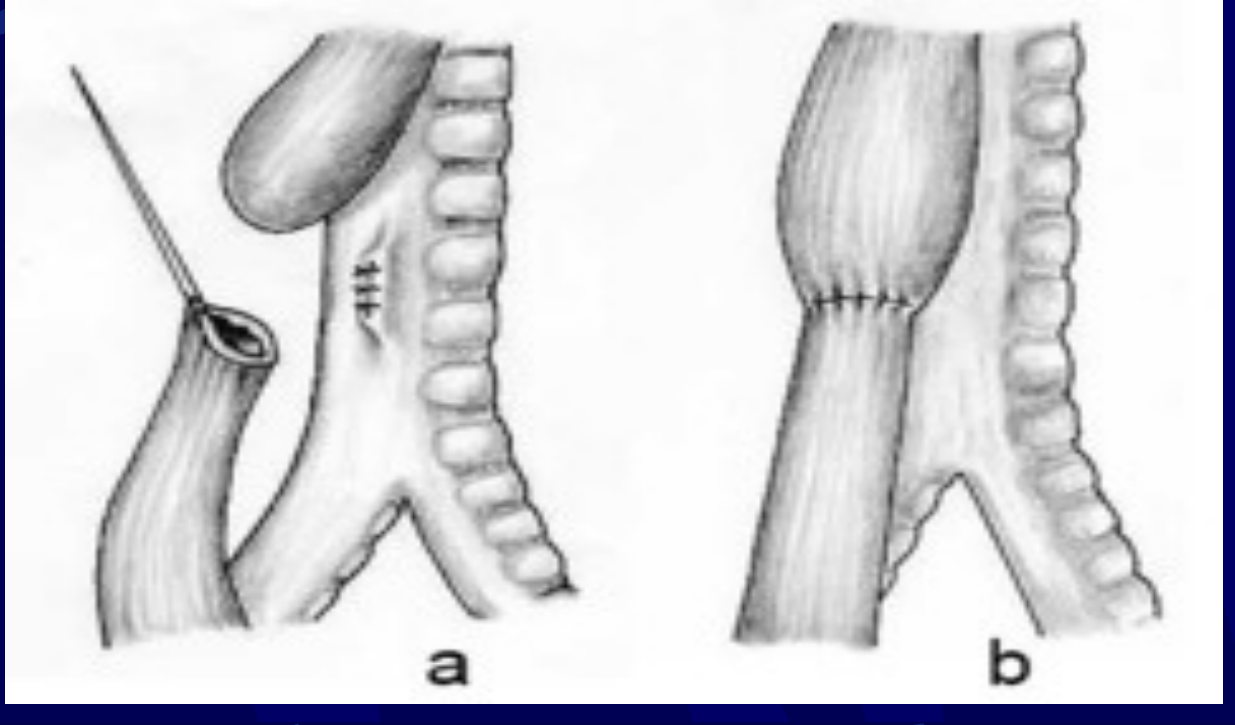

Surgery

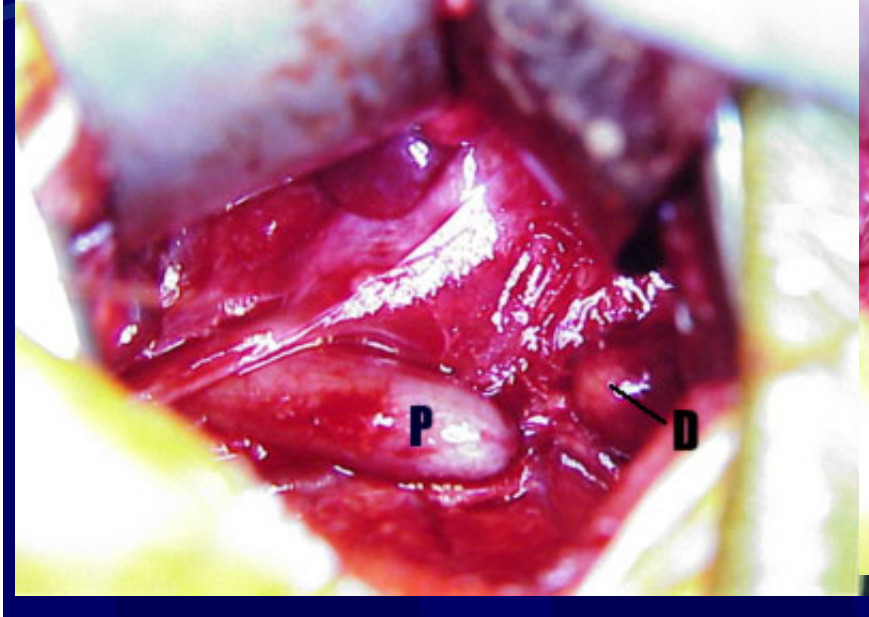

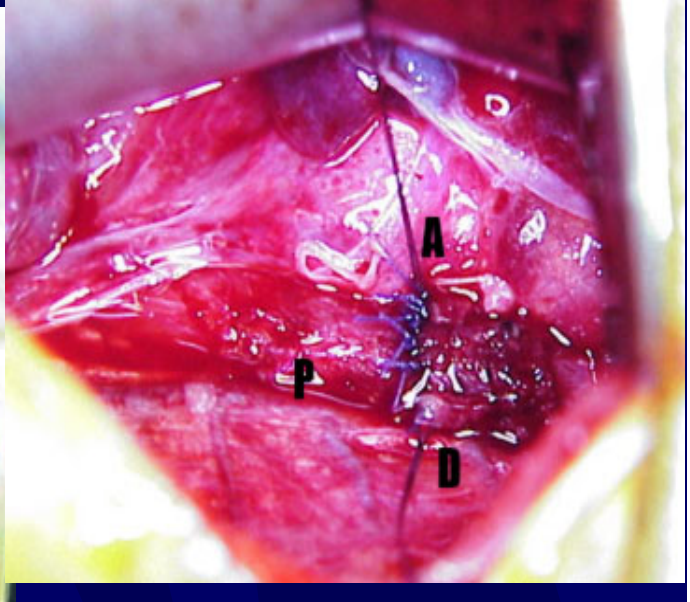

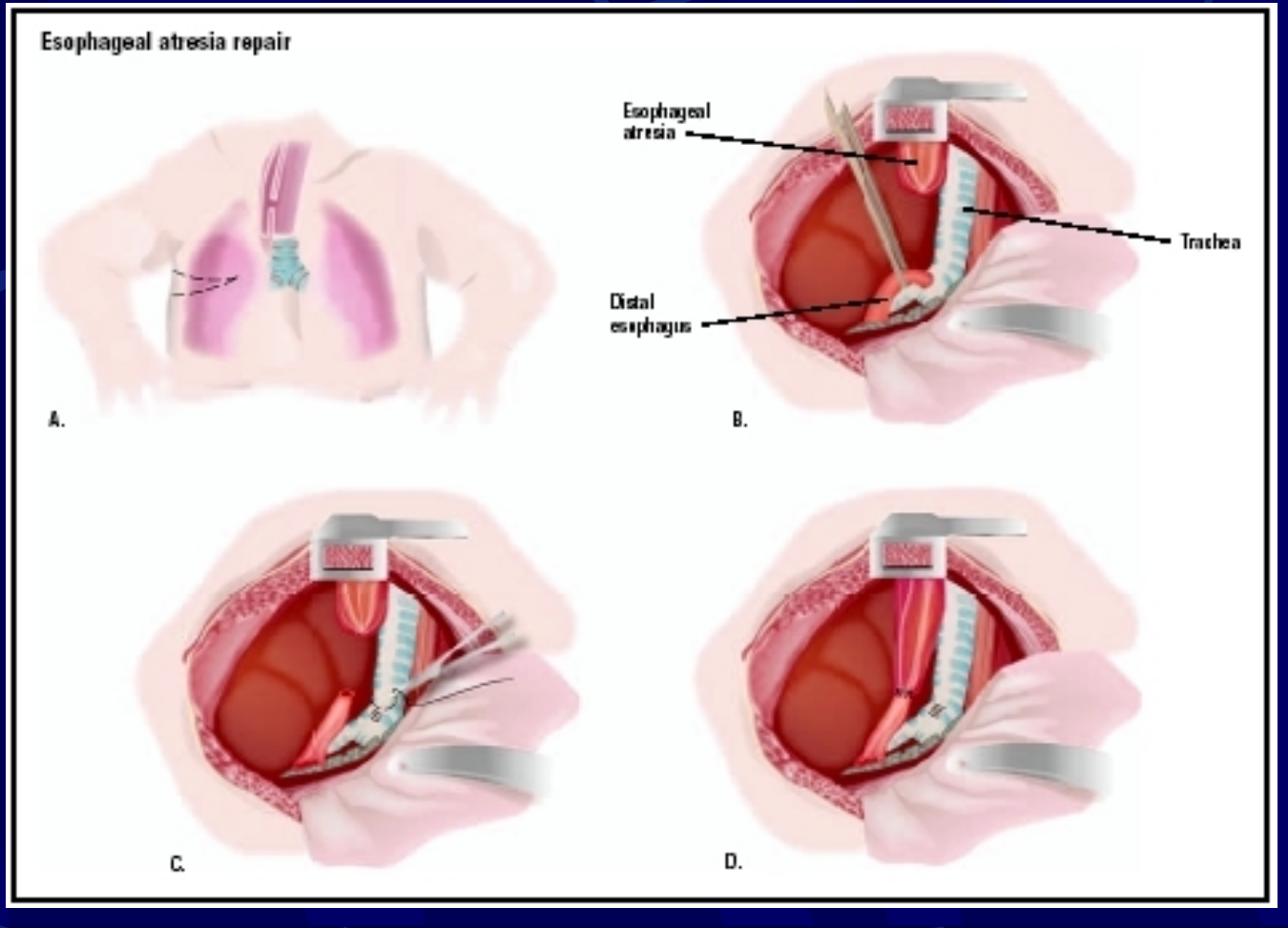
Esophageal atresia repair
Esophageal atresia
Trachea
Distal esophagus
A.
B.
C.
D.

Esophageal replacement

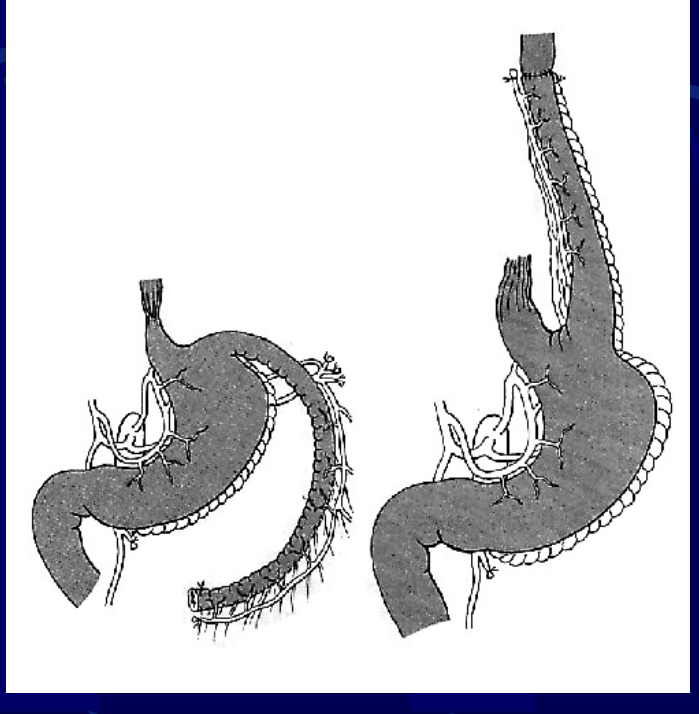

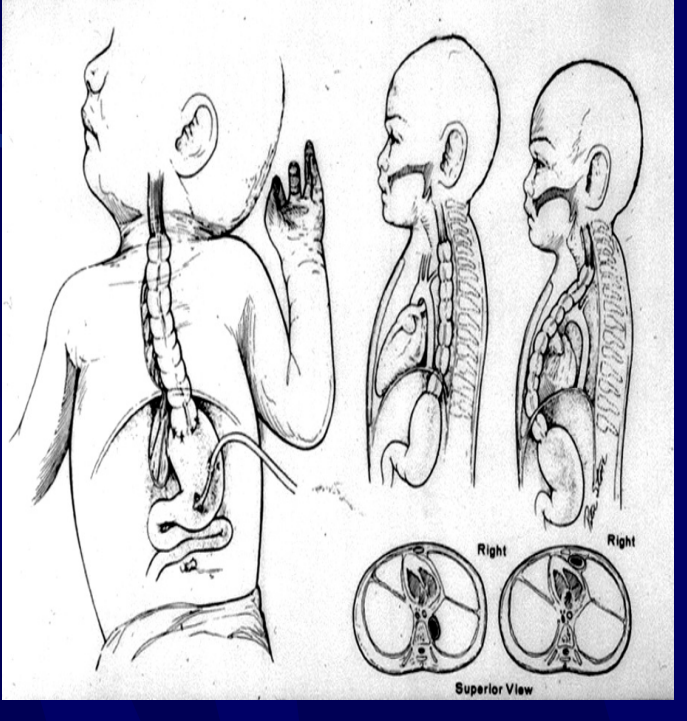

Colon transposition

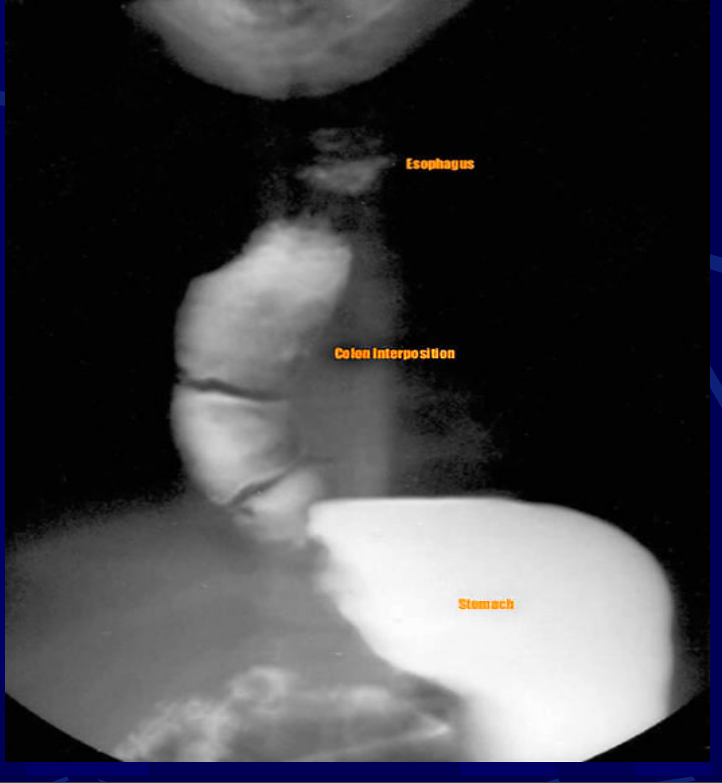

Gastric pull up

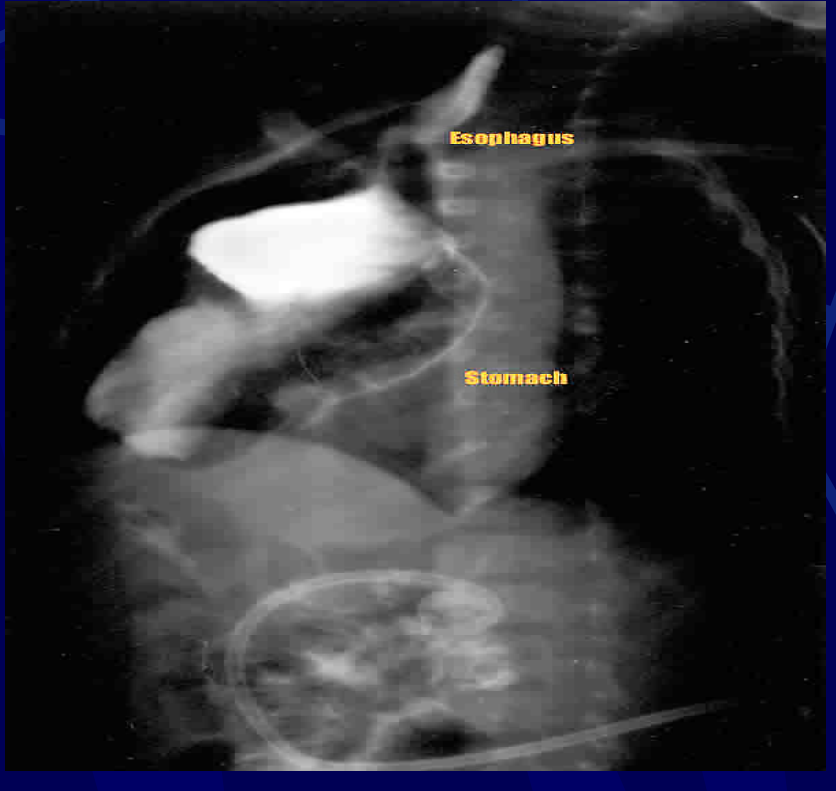

In infants with severe pneumonia, prematurity or other significant medical problems that increase the risk of major surgery.

Gastrostomy tube placement **is an effective method to decompress the intestinal tract and allow for medical optimization prior to esophageal repair.**

Postoperative care

Oral feeding starts on 3rd day.

Esophageal study at 5th day.

Daily assessment of the retropleural drain.

Post-operative check for leak – UGI study with head up 30°, water-soluble contrast [not barium] and NGT proximal to anastomotic site.

Complications

so we do partial fundoplication...

- **Gastro-esophageal reflux.** GERD
- **Anastomotic leakage.** [fatal]
- **Recurrent Tracheo-esophageal fistula.**
- ضعفت **Tracheomalacia.**
- **Stricture.**

* Good anastomosis need:-

1- good BS...

2- air and water tight...

3- ↓ tension...

4- no distal obstruction...

5- no leuminal

Compromize...

Minor leakage



Fistula following repair



Anastomotic stricture

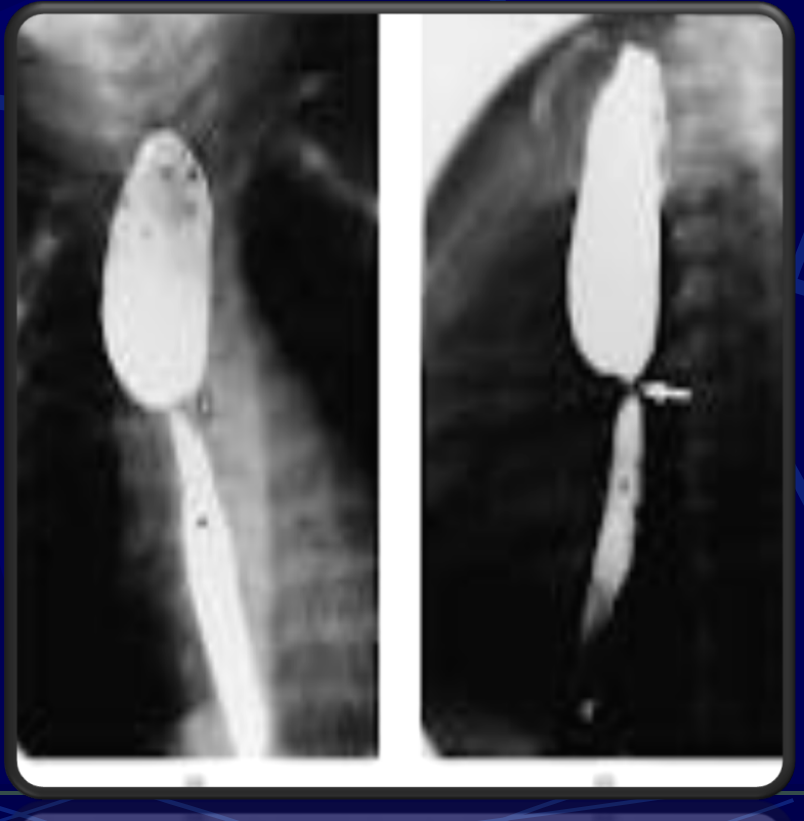

Impacted food



Summary


Esophageal atresia
Type
Proximal atresia & distal fistula
C/P
Failure to pass NGT
Investigation
X-ray chest showing coiled NGT
Prognosis
Cardiac anomalies
Post op. complications
GE Reflu


THANK
U

Thank You

A 2.8-kg neonate with excessive salivation develops respiratory distress.Attempts to pass an orogastric catheter fail because the catheter coils in the back of the throat. A chest film is obtained and shows right upper lobe atelectasis and a gasless abdomen. Which of the following types of EA would be consistent with this findings?

A. Type A

B. Type B

C. Type C

D. Type D

E. Type E

The initial treatment for a pure esophageal atresia is:

A. Repair of the esophageal atresia

B. Repair of the esophageal atresia with placement of a gastrostomy

C. Repair of the esophageal atresia, Nissen fundoplicalion and placement of a gastrostomy

D. Gastrostomy alone

A baby boy was delivered at 38-weeks gestation, who despite initial suctioning, appears to be salivating excessively. He has mild tachpnea, but is pink.

A) How can the cause be established?

B) What are the other anomalies that are likely to be present?

C) What would you do before proceeding to surgery?