A 4-week-old breast-fed boy was completely well until 2 days earlier, when he began vomiting all feeds. He was otherwise well , and keen to feed in spite the persistent vomiting.

What is the significant thing to ask about regarding vomiting?

What physical sign would you wish to find to confirm the diagnosis you suspect?

If you were unable to demonstrate this sign, what would you do if you still suspect?

What initial investigations would you perform to assist you in resuscitation?

Regarding infantile hypertrophic pyloric stenosis

(a) Usually presents between 6 and 12 months of age
(b) The female : male ratio is 4:1
(c) Has a strong familial predisposition
(d) Pathologically shows hypertrophy of the longitudinal muscle layer of the pylorus
(e) Presents with bile-stained projectile vomiting

Regarding infantile hypertrophic pyloric stenosis

(a) Usually presents between 6 and 12 months of age
(b) The female : male ratio is 4:1
(c) Has a strong familial predisposition
(d) Pathologically shows hypertrophy of the longitudinal muscle layer of the pylorus
(e) Presents with bile-stained projectile vomiting

Which of the following is most consistent with pyloric stenosis?

A. Na 140 Cl 110 K 3.2 HCO3 26
B. Na l42 Cl 90 K 5.2 HCO3 39
C. Na 139 Cl 85 K 3.2 HCO3 36
D. Na l40 Cl 95 K 4.0 HCO3 38

Which of the following is most consistent with pyloric stenosis?

A.	Na	140	Cl	110	K	3.2	HCO3 26
B.	Na	I42	Cl	90	K	5.2	HCO3 39
C.	Na	139	Cl	85	K	3.2	HCO3 36
D.	Na	I40	Cl	95	K	4.0	HCO3 38

A 3-week-old, first-born male develops forceful, non- bilious emesis. Which of these findings establishes the diagnosis?

(A) ultrasonographic pyloric muscle thickness of 2.5 mm

(B) ultrasonographic pyloric thickness greater than 2.5 cm

(C) ultrasonographic pyloric diameter of 1.0 cm or less

(D) an UGI series showing a classic "double bubble" sign

(E) palpable pyloric mass (olive) midline of the abdomen

A 3-week-old, first-born male develops forceful, non- bilious emesis. Which of these findings establishes the diagnosis?

(A) ultrasonographic pyloric muscle thickness of 2.5 mm

(B) ultrasonographic pyloric thickness greater than 1.5 cm

(C) ultrasonographic pyloric diameter of 1.0 cm or less

(D) an UGI series showing a classic "double bubble" sign

(E) palpable pyloric mass (olive) midline of the abdomen

12 week baby boy weighing 6kilo with repeated projectile non bilious vomiting, he is lethargic with sunken eyes .

What type of fluid should be given as replacement and maintenance fluid.

How much fluid should be given.

Congenital hypertrophic pyloric stenosis

[functional gastric outlet obst.]

↓

Hyperplasia and hypertrophy of the muscle of the pylorus...

↓ increase in the number.

↓ increase in the size...

Dr. Elias arteen
FRCSI
Consultant surgeon

Hypertrophic Pyloric Stenosis

(HPS) causes a ***Functional Gastric Outlet Obstruction*** as a result of hypertrophy and hyperplasia of the muscular layers of the pylorus.

Commonest cause of vomiting in pediatric surgery.

* The paralytic ilus is the mc post op. complication...

→ The prestalsis return after 12 hr in SI and 24 hr in the stomach and 36 hr in the colon...

* The enhance recovery programe after surgery [rapid]:-

① المريض يأكل بدري...

② تشيل ال foly catheter بدري...

③ ما تخلي NG tube لفترة طويلة...

④ ما تعطي opioid كتير

* The mcc of vomiting in pediatric syrgery:- Pyloric stenosis...

↳ we should ask if it ① surgical [Bilus] or not

→ The alarming vomiting is Bilus [Bile content]...

↳ duodenal - volvuls of SI ~~atresia~~ [fatal]...

* 90% of duodenal atresia is distal to the 2nd part of duodenum [below the ampula of vater - Bile - pancreatic secretion] so the vomiting is Bilus...

But 10% the obstruction is proximal to the ampula of vater so the vomiting is non Bilus...

* The non Bilus vomiting has:- medical cause as viral infection- UTI - meningitis ...etc

② Time of the vomitus:
- immediatly after eating :- GERD
- after 1/2 hr of eating :- pyloric stenosis
- after 1- 2 hr of eating :- duodenal or small Bowl cause...

* The gold standerd method to diagnose the pyloric stenosis in pediatric is US

* The charachterstic finding in us for Pyloric stenosis:-

① wide Stomach and has a milk + Stasis in the stomach ..

② Hypertrophy and Hyper plasia in the muscle...

③ The length of Pyloric cana > 15 - 17 ml ...

④ The serosa to mucosa width > 4 mL ..

* good apetite mean good Health...

* we Should prepare the pt before the Surgery by:-

① reduce the HCO_3^-...

② good hydration [1-2 day befor the surgery]...

③ give KCl...

Pathophysiology

Marked hypertrophy and hyperplasia of the (Circular and Longitudinal) muscular layers of the pylorus occurs, leading to narrowing of the gastric antrum.

→ to functional obstruction...

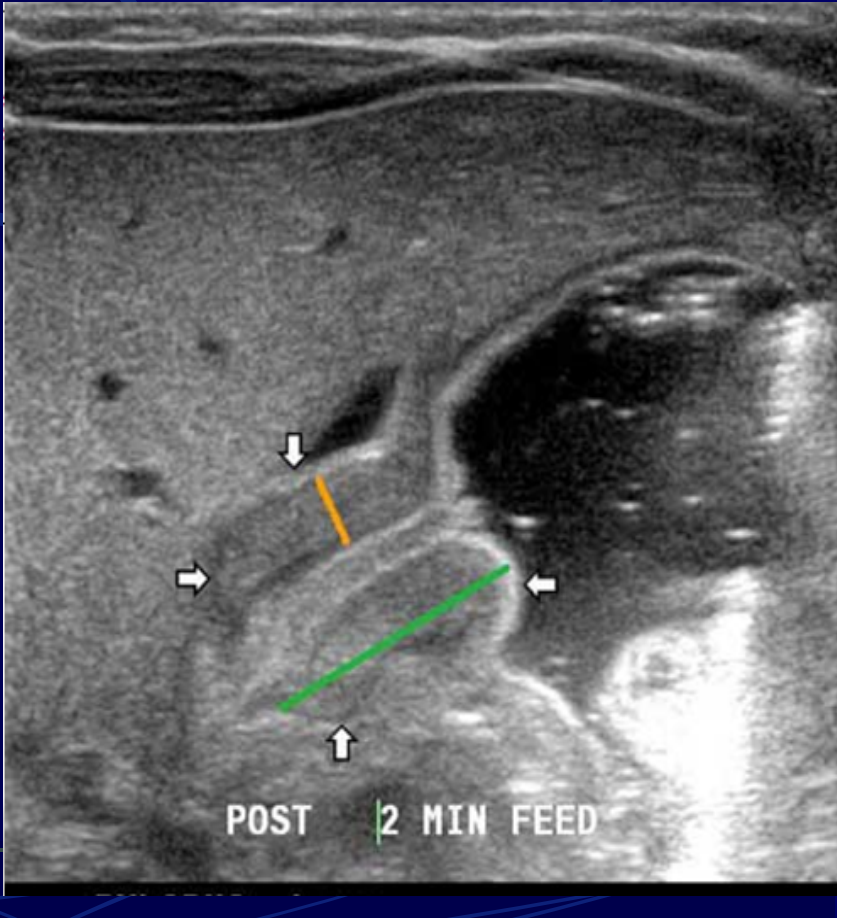

Etiology

→ unKnown multifactorial [genetic - environmental factors..etc]

- ***Nitrous oxide synthase deficiency*** (most accepted).
  ↳ lead to Pylorus spasm...
- Nerve cell theory (ganglion cell theory).
- Increased child & maternal gastrin .
- Exposure to Macrolide Antibiotics. (→ in 1st 2 weeks of Birth) as: erythromycin...
- Bottle Feeding. * cs Baby...

* The nitrous oxide fx:- relaxation of Pylorus...

* Nitrous oxide synthytase clificiancy lead to fx dz as :-

1. pyloric stenosis...
2. Achalasia...
3. Hirshbrung dz...
4. gastroparesis [in DM pt]..

Epidemiology [MCQ]

3 / 1000 live birth.

Definite familial incidence. ← 7% of parents has scar of previous pyloric stenosis surgery..

Male : Female = 4:1 [all congenital anomaly in children more common in males except hemangioma]...

Commonly in the First Born Male White ,Child

30%.

7% of parents have history IPS.

Most common cause for laparotomy before 1 year

Age: *3 weeks - 3 months 95 % of cases.*

(Mean age 3-6 weeks).

* now adays the age of pyloric stenosis diagnosis decrease [due to early diagnosis of the dz → typical presentation أعراض]

* we should give the pt enough fluid [normal Saline] + KCL 2 day befor the surgery...

presentation

lead to dehydration - metabolic alkalosis - Hypokalemia - ↓Cl⁻ → ↑HCO₃⁻

Classically, ***Non Bilious Vomiting*** or regurgitation, which may become ***Projectile*** with time 70% , after which the infant is ***Still Hungry ??.***

← بيضل جوعان ويستفرغ يلي بياكله

Emesis may be Intermittent or occur after each feeding.

due to gastric stasis

Coffee Ground Vomiting secondary to gastritis or a Mallory-Weiss tear at the gastro esophageal junction.

more in alcoholic pt - repeat vomiting lead to gastric mucosa injury then Blood vomiting

The infant begins to show signs of ***Dehydration*** and Malnutrition.

indirect ↑Bill - unknown cause...

The infant may develop ***Jaundice,*** which is corrected upon correction of the disease.

Type your text

improve after surgery...



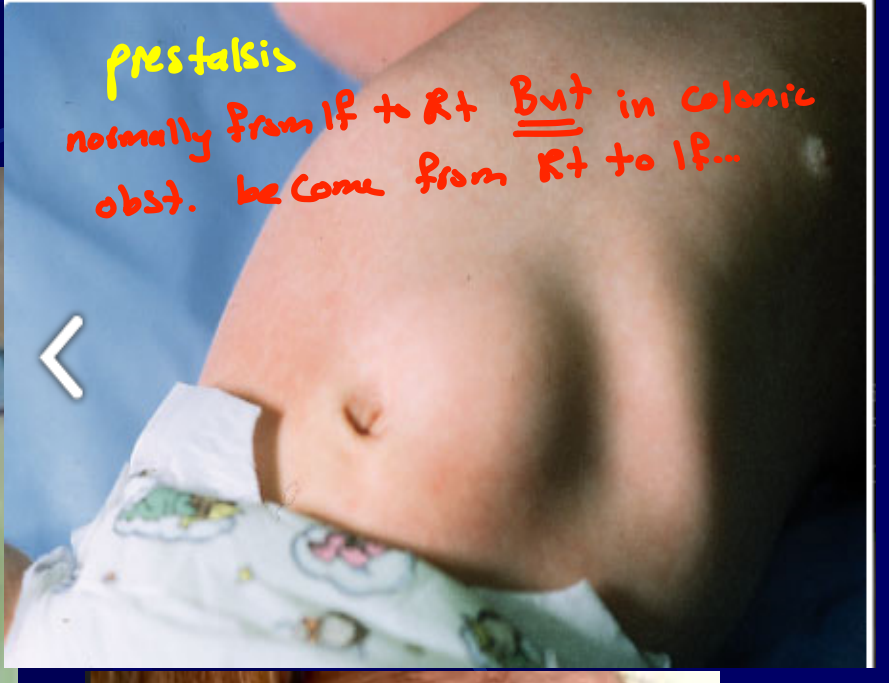



effortless vomiting

Examination

60-80% of the infants (IHPS), has a firm, non tender, and mobile hard pylorus that is 1-2 cm in diameter, an "Olive," may be present in the RUQ at the lateral edge of the rectus muscle .

Gastric peristalsis just prior to emesis as the peristaltic waves try to overcome the obstruction from Left to right.

Signs of dehydration .

The classic signs of IHPS are becoming less common.

Symptoms and signs of dehydration

↳ The symptoms get less common due to US [nowadays] Barium meal [in the past]...

- Tachycardia. + ↓ skin perfusion [capillary refell time less than 2sec]...
- Decreased urine output.
- Reduced skin turgor.
- Depressed fontanels.
- Absent tears.
- Lethargy.
- Poor feeding. - Hypotension [late]...

Work up

Laboratory Studies: **Electrolytes, PH , BUN, and Creatinine levels should be obtained.**

* ↑ KFt - ↓ Cl^- - ↓ K^+ - metabolic alkalosis]...

Hypochloremic, Hypokalemic **Metabolic Alkalosis is the Classic finding.**

* To do the surger :- $HCO_3^- < 28$ لازم يكون ال

Elevated Unconjugated Bilirubin levels may be present.

↳ improved after surgery

Radiology

* in dudenal atresia we find double bubble apperance.

Plain X-ray:

Single Bubble Sign.

Little gas distal to Stomach.

← مافي gas إلا في ال stomach

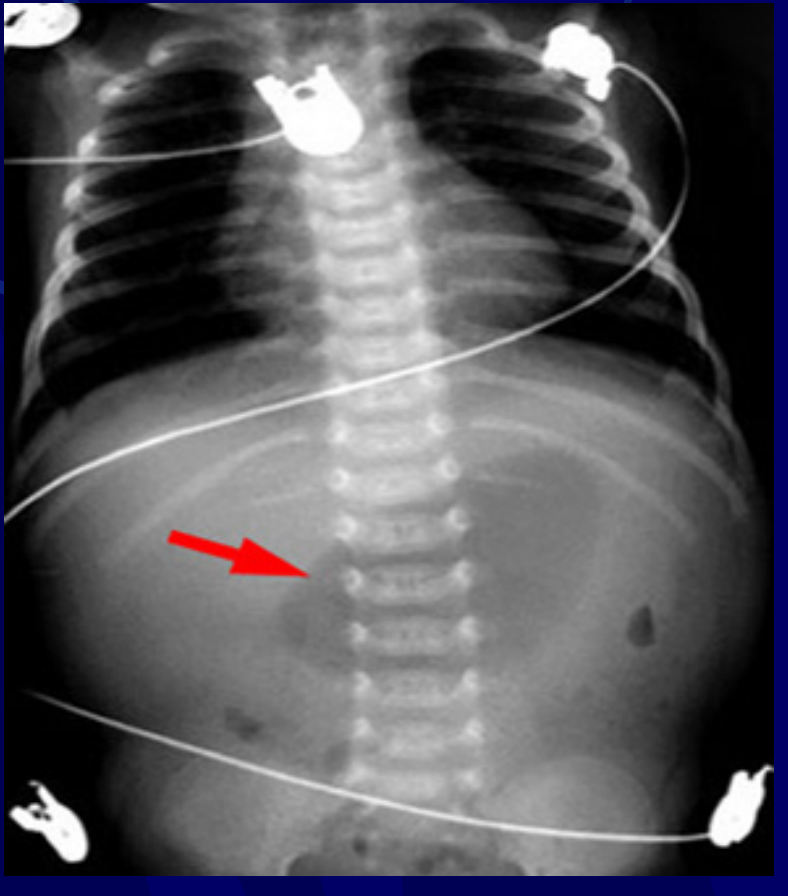

Iu8'

Type your text

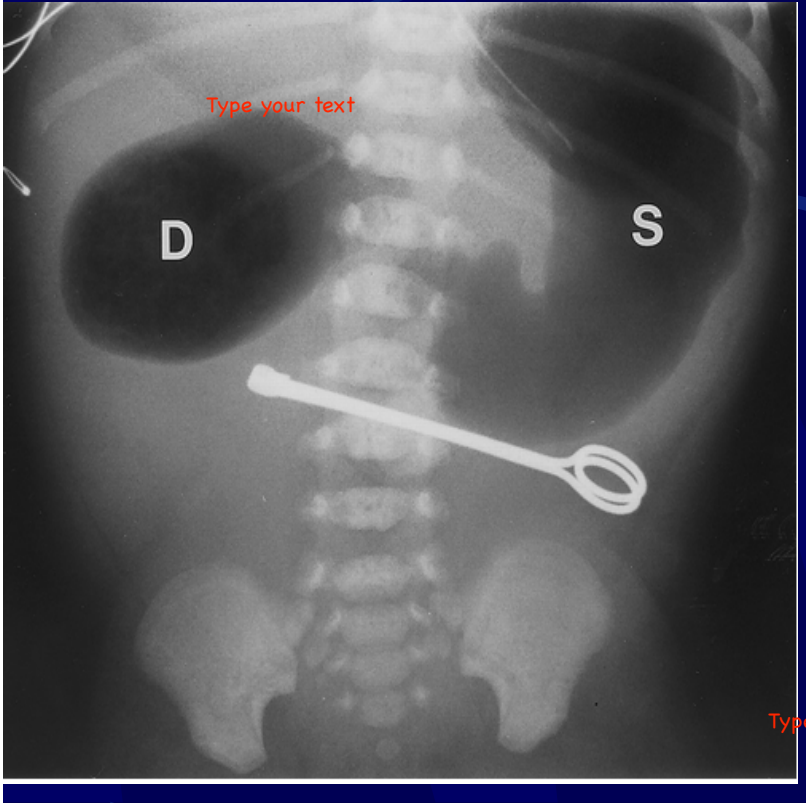



Type your text

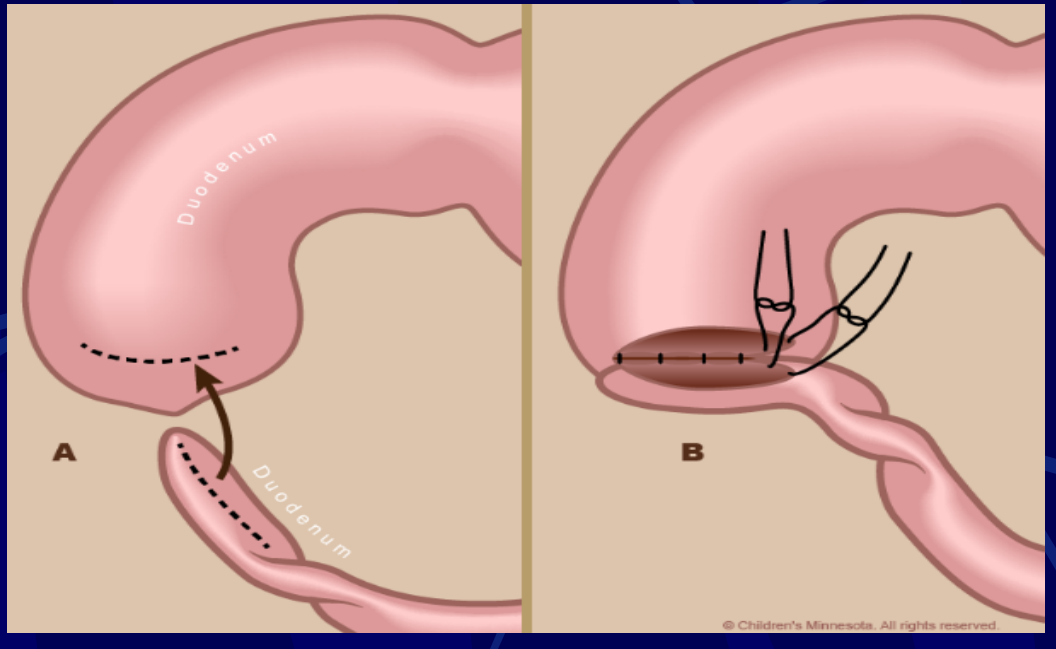
Duodenum
A
Duodenum
B
© Children's Minnesota. All rights reserved.

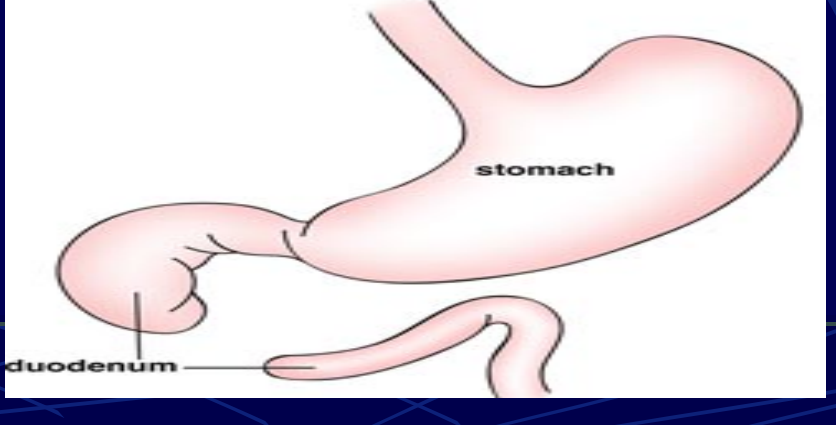
stomach
duodenum

Imaging Studies

The gold standerd nowadays..

Ultrasonography is The Imaging Modality of Choice

Sensitivity (90-99%) and Specificity (97-100%) .

The pylorus is viewed in longitudinal and transverse planes.

- olive mass...

Pyloric muscle thickness (serosa → mucosa) *4mm.*

Pyloric thickness (serosa →serosa) ≥ 15mm

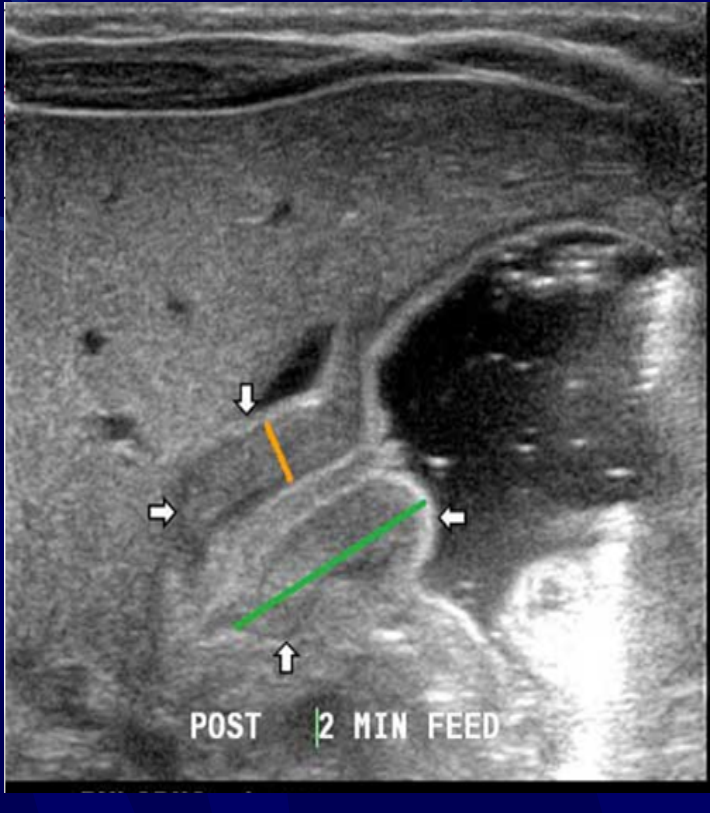

Ultrasonography

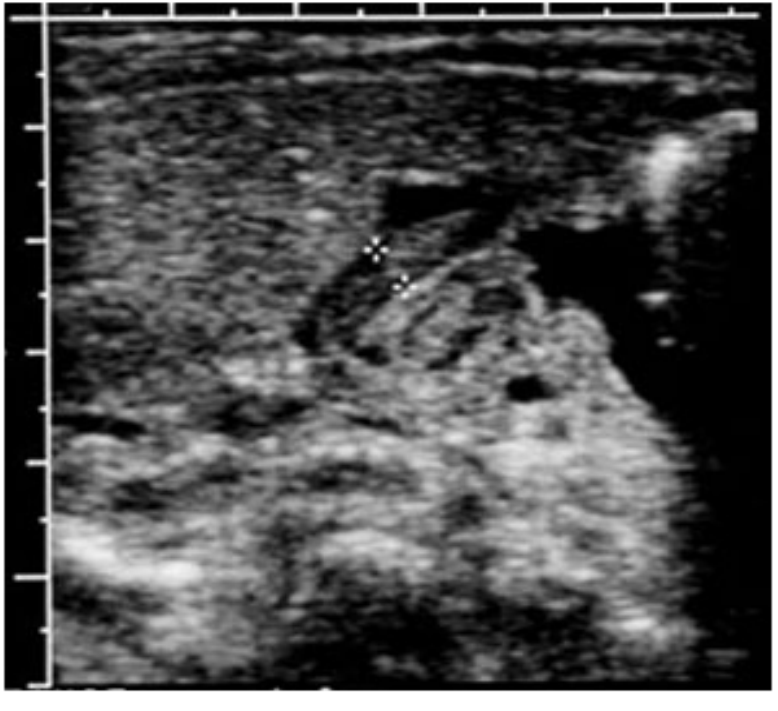

Thick pyloric muscle

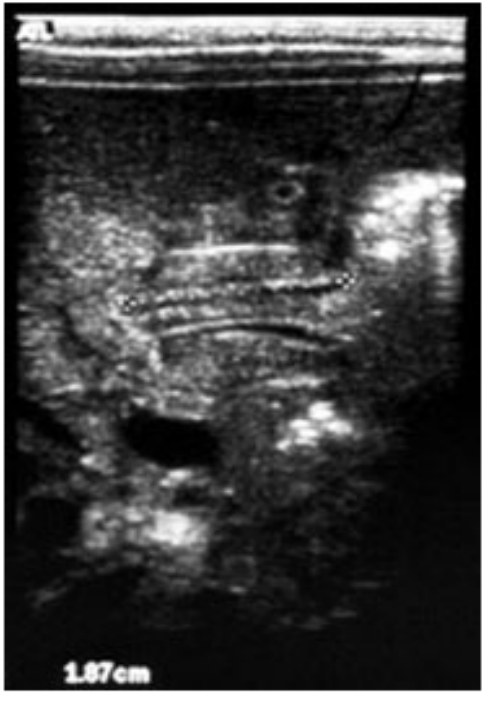

Elongated pyloric muscle

Barium meal

بطلنا نستخدمها

we see apple core appearance [narrow pylorus]...

+ healthy ductenal cap...



A © 2008 Elsevier Inc. B © 2008 Elsevier Inc.

Upper GI imaging confirm the diagnosis of but is not routinely performed unless ultrasonography is non diagnostic.

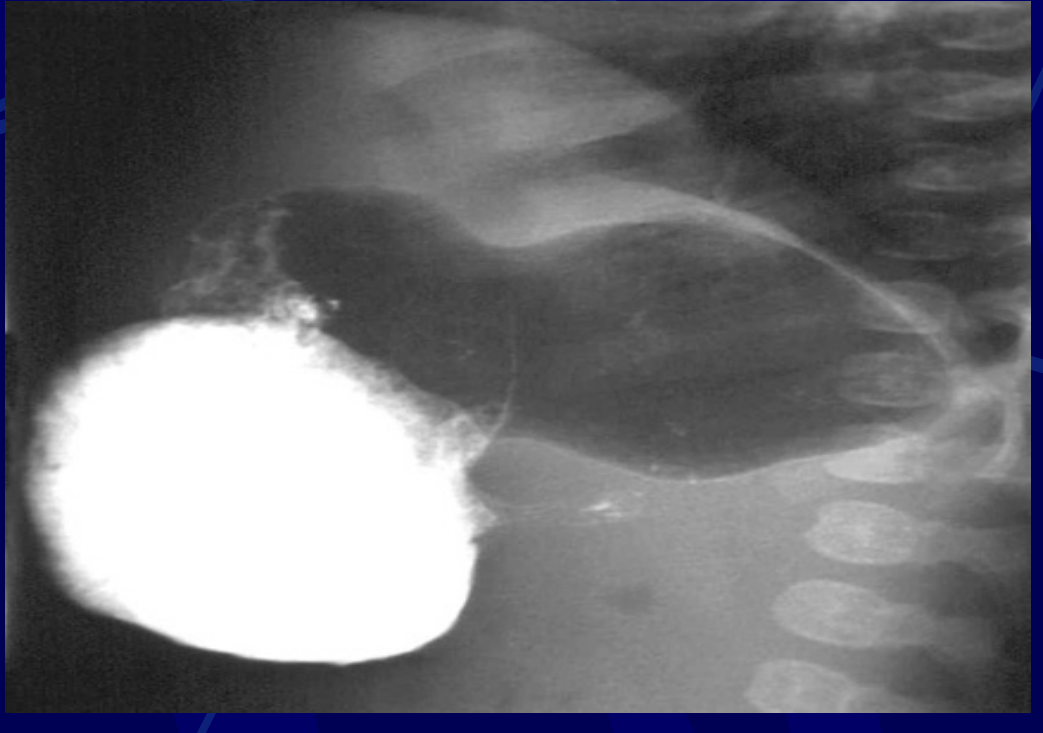

Management → mainly surgical ttt after correction the hypoKalemia-alkalosis ..etc.

150 mL / kg

Initial fluid bolus *(20 mL / kg)* of crystalloids should be infused immediately if the infant is dehydrated.

[we use normal saline or half strength saline]

Infants should receive 1.5-2 times maintenance intravenous fluid: *5% Dextrose in sol 0.45 with K Replacement .*

Infant's fluid status should be continuously reassessed with special attention to acid-base status and urine output.

Maintenance fluid in neonates *5-6 ml /kg / h* ***or*** *150 ml /kg.*

* The medical ttt in Pyloric stenosis is:- Atropine sulfate for 3 weeks..
↳ IV then oral when the vomiting improved.

Surgical treatment

The Definitive Treatment for infantile hypertrophic pyloric stenosis is Corrective Surgery.

open or laparoscopic

Ramstedt Pyloromyotomy : **is the procedure of choice, during which underlying antro-pyloric mass is split leaving the mucosal layer intact.**

supra umbilical

Right upper quadrant transverse incision.

Laparoscopic approach

need pediatric laparoscope...

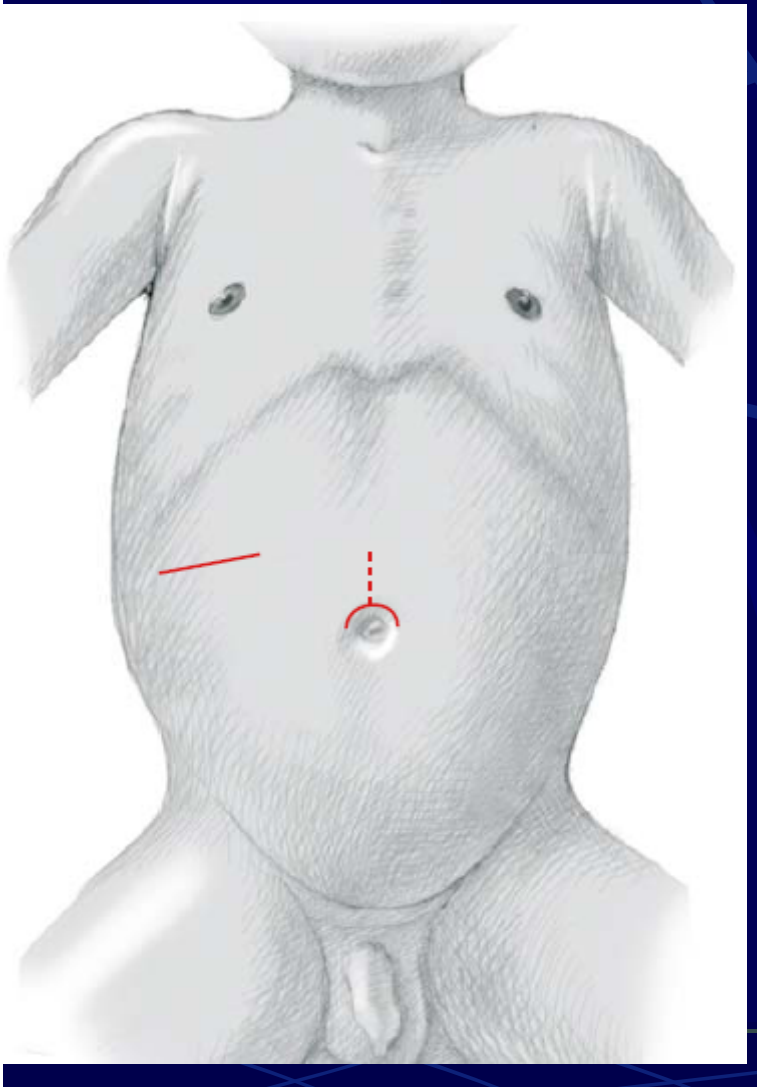

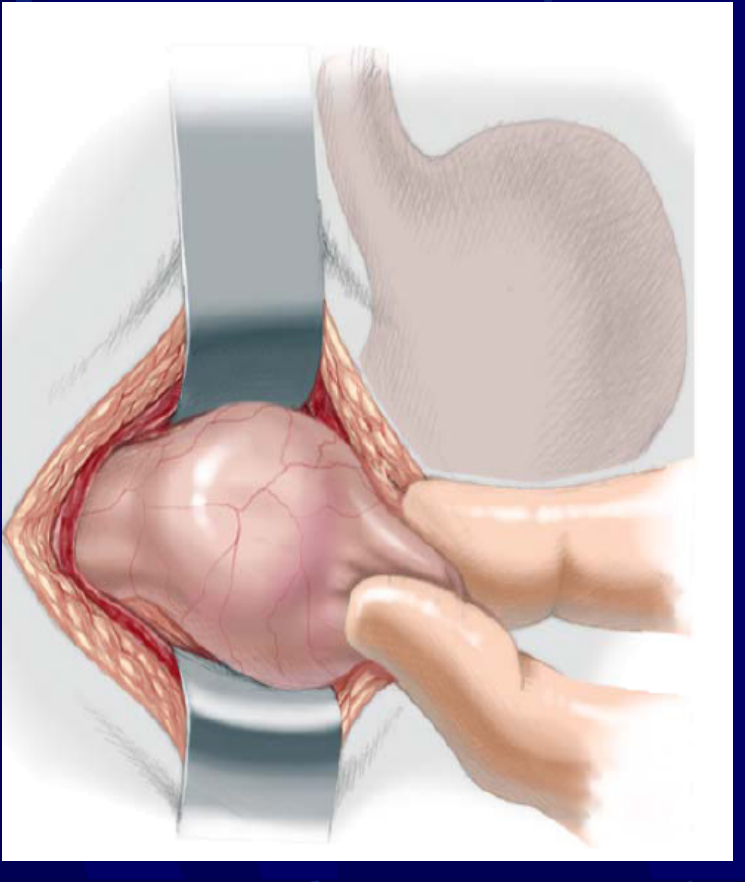



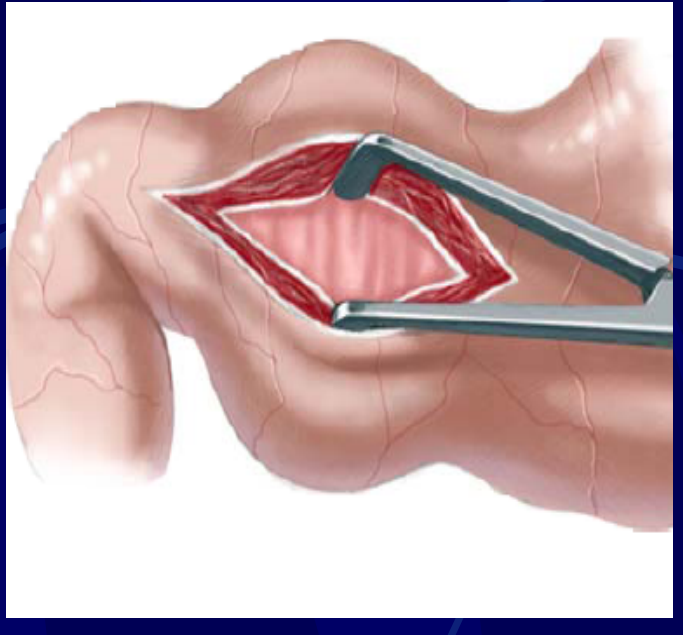

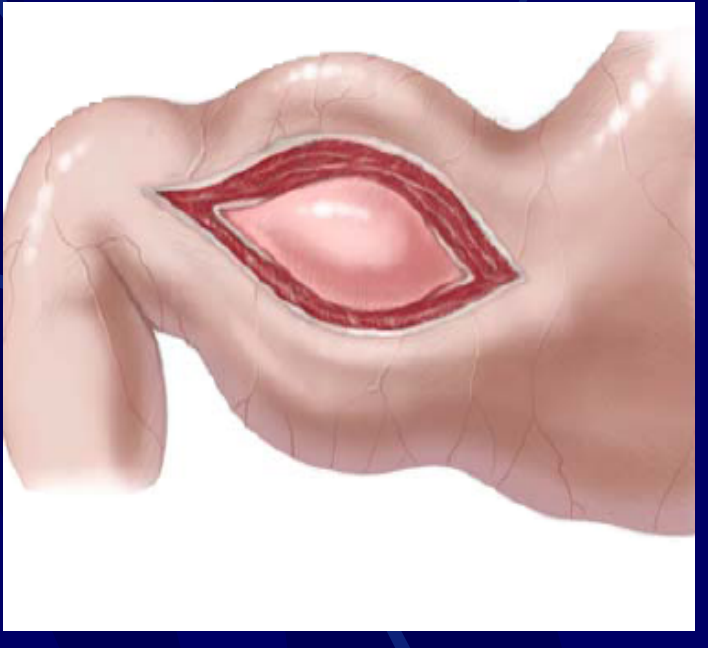

Incision extends from just proximal to the pyloric vein of Mayo to the gastric antrum; it typically measures between *1 and 2 cm* in length.

← يعني نقطع كل الـ muscles ماعدا الـ mucosa..

Operation

Fred-Ramstedt's Pyloromyotomy



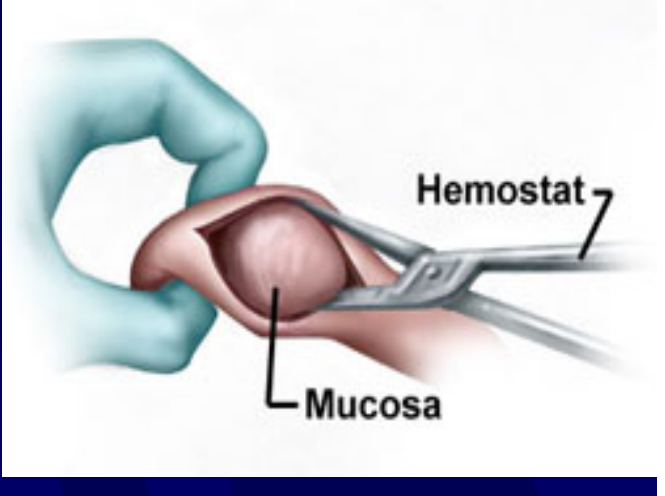

* inadequet myotomy lead to recurrent symptoms...

Operation

Fred-Ramstedt's pyloromyotomy





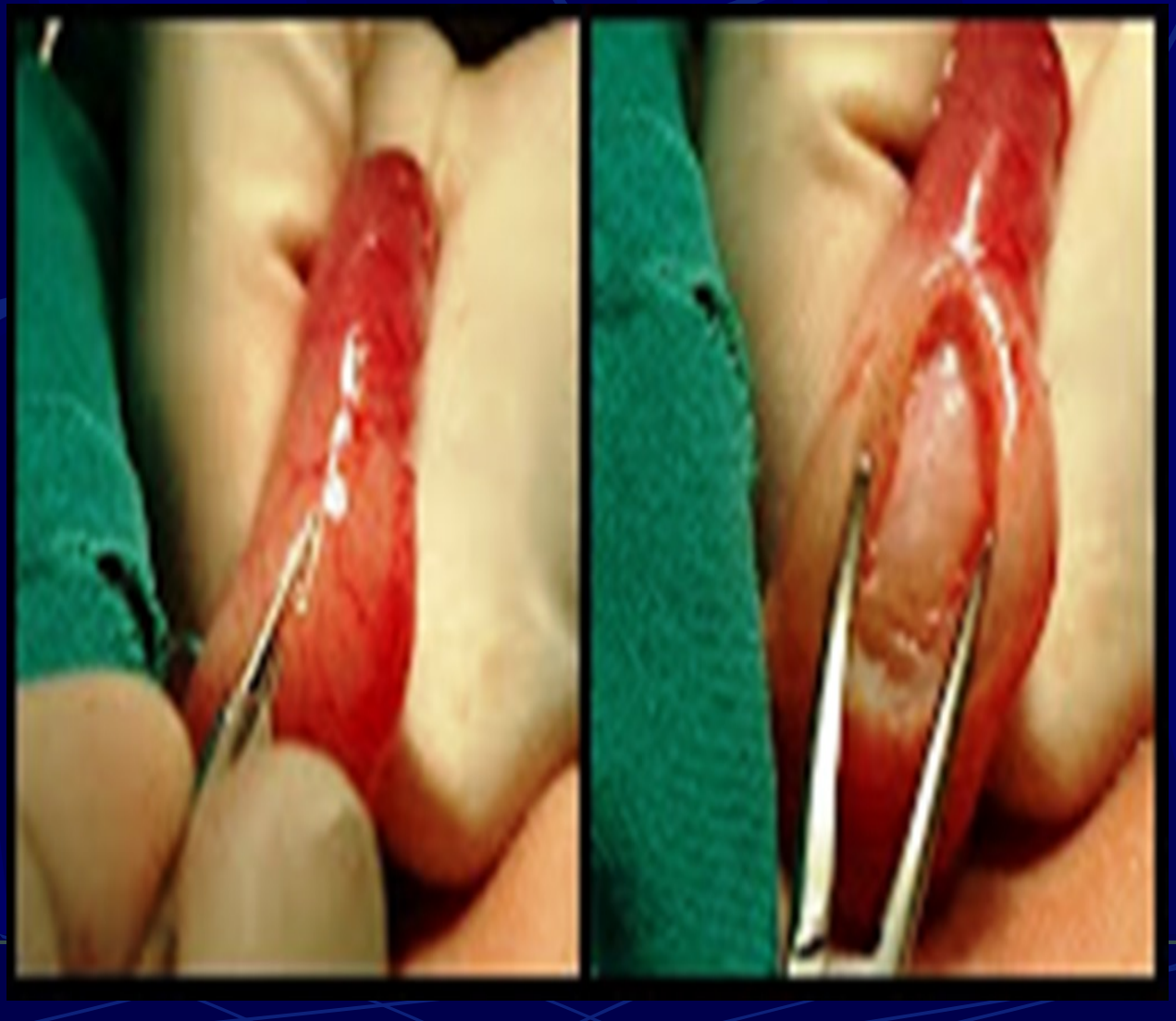

Laparoscopic pyloromyotomy



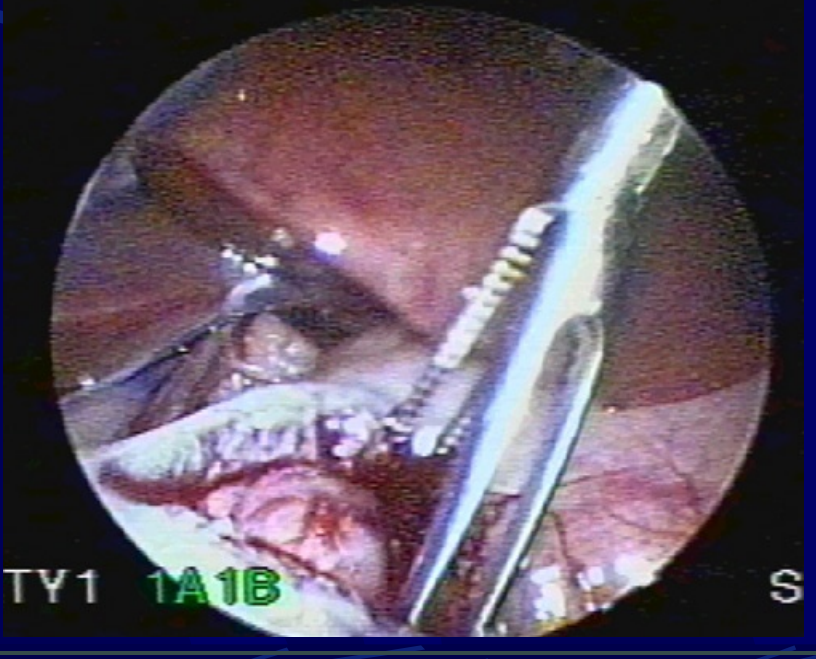

Complications

Wound infection Common.

Incisional hernia unlikely.

Persistent vomiting due to:

Stagnation Gastritis. ✓ or GERD...

Inadequate Pyloro-myotomy. ✓

Mucosal perforation.

من ناحية ال duodenum لأنه أرفع

← الطفل يرجع يأكل بعد العملية بـ 4.6 hour وبعد يومين بيروح...

Pyloric stenosis

Age — 3weeks – 3 months

Sex — Male predominance

Clinical — Non-bilious vomiting, Olive mass

Investigation — U/S

Treatment — Surgic

Thank You

Which of the following statements about Inguinoscrotal swellings is true

b. A hydrocele is a patent processes vaginalis, as is a hernia.

c. Complications is less common in indirect inguinal hernias than direct ones.

d. Sliding hernia is more common in boys.

e. Inguinal hernia in neonates an expectant policy is advocated.

f. A hydrocele needs an operation only after first year of life.

Which of the following statements about Inguinoscrotal swellings is true

b. A hydrocele is a patent processes vaginalis, as is a hernia.

c. Complications is less common in indirect inguinal hernias than direct ones.

d. Sliding hernia is more common in boys.

e. Inguinal hernia in neonates an expectant policy is advocated.

f. A hydrocele needs an operation only after first year of life.

1. **Regarding vomiting in infancy**

b. **Vomiting immediately after food is due to pyloric obstruction.**

c. **Vomiting ½ an hour after food is due to hiatus hernia and reflux disease.**

d. **Bilious vomiting is more alarming than non-bilious vomiting.**

e. **Vomiting of old food may denotes intussusception.**

f. **None of the above is true.**

1. **Regarding vomiting in infancy**

b. **Vomiting immediately after food is due to pyloric obstruction.**

c. **Vomiting ½ an hour after food is due to hiatus hernia and reflux disease.**

d. **Bilious vomiting is more alarming than non-bilious vomiting.**

e. **Vomiting of old food may denotes intussusception.**

f. **None of the above is true.**

a. In children hernia are most common
b. In boys on left side
c. In boys on right side
d. In girls on left side
e. Bilateral in boys
f. Left sliding hernia in girls

- In children hernia are most common
- In boys on left side
- **In boys on right side**
- In girls on left side
- Bilateral in boys
- Left sliding hernia in girls

a. Orchiopexy for undescended testicle
b. Decrease risk of testicular cancer
c. The fixation of testis to scrotum increase possibility of trauma, and torsion to testicle
d. Should be done at preschool age.
e. Should be done once diagnosed regardless to age.
f. Improve fertility

a. Orchiopexy for undescended testicle

b. Decrease risk of testicular cancer

c. The fixation of testis to scrotum increase possibility of trauma, and torsion to testicle

d. Should be done at preschool age.

e. Should be done once diagnosed regardless to age.

f. Improve fertility

1. Regarding intussusception
b. It is a rare cause of intestinal obstruction between 6 and 18 months.
c. 95% of children there is a cause intraluminal or intramural.
d. Babies with intussusception are usually malnourished.
e. Colicky abdominal pain, blood in the stool and Intra-abdominal sausage shape mass is commonest presentation.
f. Ileoileal intussusception is commonest type in children.

1. **Regarding intussusception**

b. **It is a rare cause of intestinal obstruction between 6 and 18 months.**

c. **95% of children there is a cause intraluminal or intramural.**

d. **Babies with intussusception are usually malnourished.**

e. **Colicky abdominal pain, blood in the stool and Intra-abdominal sausage shape mass is commonest presentation.**

f. **Ileoileal intussusception is commonest type in children.**

1. A 4-week-old breast-fed boy was completely well until 2 days earlier, when he began vomiting all feeds. He was otherwise well, and keen to feed in spite the persistent vomiting, most likely cause is

b. Infantile pyloric stenosis

c. Hirschsprung's disease

d. Ileocecal intussusception

e. Gut malrotation

f. Jejunal volvulus

1. A 4-week-old breast-fed boy was completely well until 2 days earlier, when he began vomiting all feeds. He was otherwise well, and keen to feed in spite the persistent vomiting, most likely cause is

b. **Infantile pyloric stenosis**

c. Hirschsprung's disease

d. Ileocecal intussusception

e. Gut malrotation

f. Jejunal volvulus

Inguinal hernia in children

Inguinal mesh repair is the most common general surgical operation in Pediatrics.

Inguinal hernia usually repaired at one year old baby.

Silk glove sign is due to presence of hernial sac.

Manual reduction is contraindicated in case of indirect strangulated hernia.

Complications of hernia are less common than in adults due to wider hernial neck.

Inguinal hernia in children

Inguinal mesh repair is the most common general surgical operation in Pediatrics.

Inguinal hernia usually repaired at one year old baby.

Silk glove sign is due to presence of hernial sac.

Manual reduction is contraindicated in case of indirect strangulated hernia.

Complications of hernia are less common than in adults due to wider hernial neck.

1. **Regarding hydrocele in infants and young children**

b. **Tense hydrocele should be repaired after first year of life.**

c. **Encysted hydrocele of cord there is no connection to peritoneal cavity.**

d. **In acute hydrocele conservative policy is recommended.**

e. **Soft hydrocele is repaired at 3 month of age.**

f. **Hydrocele in pediatric population is repaired through scrotal incision.**

1. **Regarding hydrocele in infants and young children**

b. **Tense hydrocele should be repaired after first year of life.**

c. **Encysted hydrocele of cord there is no connection to peritoneal cavity.**

d. **In acute hydrocele conservative policy is recommended.**

e. **Soft hydrocele is repaired at 3 month of age.**

f. **Hydrocele in pediatric population is repaired through scrotal incision.**

a. Varicocele in Pediatric patients

b. Are common below 10 year of age.

c. Secondary Varicocele is more common than primary Varicocele in children.

d. Affect left testis in 80-90 %% of cases.

e. Grade III means presence of impulse on cough.

f. The Right angle of fusion of the left testicular vein to IVC is an important etiological cause.

a. Varicocele in Pediatric patients

b. Are common below 10 year of age.

c. Secondary Varicocele is more common than primary Varicocele in children.

d. **Affect left testis in 80-90 %% of cases.**

e. Grade III means presence of impulse on cough.

f. The Right angle of fusion of the left testicular vein to IVC is an important etiological cause.

Regarding Meckel's diverticulum all are true except

b. Is the most common congenital anomaly of GIT tract.

c. Incidence is 2 % of general population, and 2% is symptomatic.

d. Risk of symptoms diminishes with age.

e. About half of those who become symptomatic are under the age of 2 years.

f. The most common presentation in children is diverticulitis.

Regarding Meckel's diverticulum all are true except

b. Is the most common congenital anomaly of GIT tract.

c. Incidence is 2 % of general population, and 2% is symptomatic.

d. Risk of symptoms diminishes with age.

e. About half of those who become symptomatic are under the age of 2 years.

f. The most common presentation in children is diverticulitis.

A 2-year-old boy has been sent in as an emergency with vomiting for 24 hours. According to the parents, the vomitus was greenish to start with but over the past few hours has consistency of dirty brownish fluid. There has been no bowel action. On examination the child looks toxic and is dehydrated — sunken eyes, depressed fontanelles, loss of skin turgor there is a tympanic abdomen with a red, irreducible swelling in the left groin not noticed by parents. Best line of management is

Infant should be resuscitated with intravenous fluids, nasogastric suction and Prophylactic antibiotics.

An emergency operation should be carried out.

Infant should be resuscitated with intravenous fluids, nasogastric suction and Prophylactic antibiotics followed by surgery in next elective list.

Infant should be resuscitated with intravenous fluids, nasogastric suction and Prophylactic antibiotics followed by immediate surgery.

Correct of dehydration followed by trial of manual reduction.

A 2-year-old boy has been sent in as an emergency with vomiting for 24 hours. According to the parents, the vomitus was greenish to start with but over the past few hours has consistency of dirty brownish fluid. There has been no bowel action. On examination the child looks toxic and is dehydrated — sunken eyes, depressed fontanelles, loss of skin turgor there is a tympanic abdomen with a red, irreducible swelling in the left groin not noticed by parents. Best line of management is

Infant should be resuscitated with intravenous fluids, nasogastric suction and Prophylactic antibiotics.

An emergency operation should be carried out.

Infant should be resuscitated with intravenous fluids, nasogastric suction and Prophylactic antibiotics followed by surgery in next elective list.

Infant should be resuscitated with intravenous fluids, nasogastric suction and Prophylactic antibiotics followed by immediate surgery.

Correct of dehydration followed by trial of manual reduction.

A 13-year-old boy with swollen scrotum but no impulse on cough, elevation of scrotum eases the pain, he has similar attach 4 month ago ,examination revealed tender swollen testis and leukocytosis ,most likely diagnosis is

- Urinary tract infection.
- Torsion testis
- Epidydimo-orchitis
- Non-specific abdominal pain
- Acute appendicitis

. A 13-year-old boy with swollen scrotum but no impulse on cough, elevation of scrotum makes pain worse the pain, he has similar attach 4 month ago ,examination revealed tender swollen testis and leukocytosis ,most likely diagnosis is

. Urinary tract infection.

. Torsion testis

. Epidydimo-orchitis

. Non-specific abdominal pain

Acute appendicitis

1. **Testicular torsion**

b. **Common at 4-8 years**

c. **Once diagnosed operation should be done within 6 hours.**

d. **All patients should have Doppler ultrasound**

e. **Is a rare cause of acute scrotum**

f. **None of the above**

1. **Testicular torsion**

b. **Common at 4-8 years**

c. **Once diagnosed operation should be done within 6 hours.**

d. **All patients should have Doppler ultrasound**

e. **Is a rare cause of acute scrotum**

f. **None of the above**

a. Regarding inguinal hernias in children
b. Boys and girls are equally affected
c. Are less common in preterm infants
d. 50% of hernias are bilateral
e. Contralateral side should be explored at the same time in infants
f. In infants approximately 50% present with incarceration

a. Regarding inguinal hernias in children

b. Boys and girls are equally affected

c. Are less common in preterm infants

d. 50% of hernias are bilateral

e. Contralateral side should be explored at the same time in infants

f. In infants approximately 50% present with incarceration

- In childhood appendicitis
- WBC count is often very high within the first 24 hours of symptoms.
- The best treatment for perforated appendicitis is good antibiotic cover, follow up and interval appendectomy.
- Shift to the right with normal total WCC is common in children.
- US has no rule in diagnosis of appendicitis.
- Appendicitis cannot be treated with antibiotics alone.

- In childhood appendicitis
- WBC count is often very high within the first 24 hours of symptoms.
- The best treatment for perforated appendicitis is good antibiotic cover, follow up and interval appendectomy.
- Shift to the right with normal total WCC is common in children.
- US has no rule in diagnosis of appendicitis.
- Appendicitis cannot be treated with antibiotics alone.

Regarding appendicitis in children all are true except

b. The highest incidence is in 2nd decade of life.

c. In children, obstruction of appendix usually results from lymphoid hyperplasia of the submucosal follicles.

d. The rate of perforation is 80-100% for children younger than 2 years of age.

e. Tip of appendix is retroceacal in 2/3 of cases.

f. Blumberg sign is very helpful in diagnosis appendicitis in children.

Regarding appendicitis in children all are true except

b. The highest incidence is in 2nd decade of life.

c. In children, obstruction of appendix usually results from lymphoid hyperplasia of the submucosal follicles.

d. The rate of perforation is 80-100% for children younger than 2 years of age.

e. Tip of appendix is retroceacal in 2/3 of cases.

f. **Blumberg sign is very helpful in diagnosis appendicitis in children.**

Appendicitis in pediatrics all are true except

In neonates the only symptoms is fever, and leukocytosis.

Obstructive type is present in 1/3 of cases.

Appendicular diameter of more than 6 mm in abdominal ultrasound has a sensitivity of 95 % and lower specificity.

In MANTRELS Score the most important is elevated temperature and nausea and vomiting.

The most causative organism is E.coli and Bacteroides species.

Appendicitis in pediatrics all are true except

In neonates the only symptoms is fever, and leukocytosis.

Obstructive type is present in 1/3 of cases.

Appendicular diameter of more than 6 mm in abdominal ultrasound has a sensitivity of 95 % and lower specificity.

In MANTRELS Score the most important is elevated temperature and nausea and vomiting.

The most causative organism is E.coli and Bacteroides species.

1. **Diagnosis of Hirschsprung's disease is made by**

b. **Inability to pass meconium after 48h of birth**

c. **Rectal biopsy**

d. **Barium enema**

e. **Contrast CT scan**

f. **Genetic analysis**

1. **Diagnosis of Hirschsprung's disease is made by**

b. **Inability to pass meconium after 48h of birth**

c. **Rectal biopsy**

d. **Barium enema**

e. **Contrast CT scan**

f. **Genetic analysis**

Hirschsprung's disease

Hirschsprung's disease is the result of a sex linked dominant gene and the Male to female incidence is 2:1

Cause of death in Hirschsprung's disease is intestinal obstruction.

During the newborn period, infants affected with HD may present with abdominal distention, failure of passage of meconium within the first 48 hours of life, and repeated vomiting.

Rectal examination commonly reveals rectum full of stool.

Older infants and children typically present with chronic constipation and night soiling.

Hirschsprung's disease

Hirschsprung's disease is the result of a sex linked dominant gene and the Male to female incidence is 2:1

Cause of death in Hirschsprung's disease is intestinal obstruction.

During the newborn period, infants affected with HD may present with abdominal distention, failure of passage of meconium within the first 48 hours of life, and repeated vomiting.

Rectal examination commonly reveals rectum full of stool.

Older infants and children typically present with chronic constipation and night soiling.

a. Hirschsprung's disease

b. Commonly is delayed in its diagnosis to above 2 year old.

c. The Male to female incidence is 2:1

d. Endo-anal pull through is one of the best one stage operation.

e. In newborn period, infants affected with HD may present with abdominal distention, failure of passage of meconium within the first 24 hours of life.

f. A family history of is present in about 10 % of cases.

a. Hirschsprung's disease

b. Commonly is delayed in its diagnosis to above 2 year old.

c. The Male to female incidence is 2:1

d. **Endo-anal pull through is one of the best one stage operation.**

e. In newborn period, infants affected with HD may present with abdominal distention, failure of passage of meconium within the first 24 hours of life.

f. A family history of is present in about 10 % of cases.

a. Branchial cyst one answer is false

b. Appear at any age (mostly 35-40 y).

c. Painless swelling, behind the anterior margin of the sternomastoid muscle. muscle at Junction of upper 1/3 and lower 2/3 of the muscle

d. Hard, smooth, not very mobile.

e. Full of yellowish golden material, cholesterol crystals.

f. Cannot be reduced or compressed.

a. Branchial cyst one answer is false

b. Appear at any age usually first year of life

c. Painless swelling, behind the anterior margin of the sternomastoid muscle. muscle at Junction of upper 1/3 and lower 2/3 of the muscle

d. Hard, smooth, not very mobile.

e. Full of yellowish golden material, cholesterol crystals.

f. Cannot be reduced or compressed.