هدية
مجانية

Gynecology & Obstetrics
For undergraduates

Notes on the Board of

Dr.Nadine's Lectures

4th Edition
2022

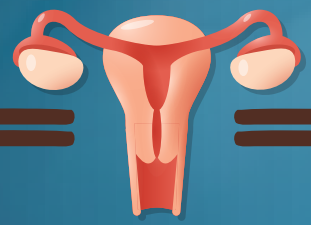

Notes of Dr. Nadine Alaa Sherif
Professor of Obstetrics & Gynecology
Faculty of Medicine – Cairo University

Written by:
Reem Abdelhakim
GP

www.nadine-alaa-sherif.weebly.com

This work is dedicated to the soul of my father, my beloved mother, my unique brother, and ... All the future doctors, whom I truly believe in their creativity, intentions and potentials .

Nadine Alaa Sherif



Website



YouTube channel



Telegram channel



Facebook Page

List of Abbreviations

AFI : Amniotic Fluid Index
AIS : Androgen insensitivity syndrome
ASCUS : Atypical squamous cells of undetermined significance
AUB : Abnormal Uterine Bleeding
BAD : Bis-acromial diameter
BCT : Benign cystic teratoma
BL : Broad Ligament
BLM : Broad ligament myoma
BMD: Bimastoid diameter
BPD : Biparietal diameter
BTD : Bitrochanteric diameter / Bitemporal diameter
BVs : Blood vessels
CIA : Common Iliac Artery
CILNs : Common Iliac Lymph notes
DMA : Direct Mento Anterior
DL : Diagnostic laparoscopy
DO : Detrusor overactivity
DOA : Direct Occipito Anterior
DOP : Direct Occipito Posterior
DZT : Dizygotic Twin
EH : Endometrial Hyperplasia
EILNs : External Iliac Lymph nodes
EMA-CO : Etoposide , Methotrexate, Actinomycin – D , Cyclophosphamide , Oncovin
FCA : Fetal congenital anomalies
FFP : Fresh Frosen Plasma
FG : Fundal Grip
FL: Fundal Level
GI : Granuloma Inguinale
HIFU:High Intensity Focused Ultrasound
HPL : Human Placental Lactogen
HSIL : High grade squamous intraepithelial lesion
HSM : Hepatosplenomegaly
IAP: Intra abdominal pressure
II LNs : Internal iliac lymph nodes
II vessels : Internal Iliac vessels
IIA : Internal iliac artery
IIV : Internal iliac vein
IPHge : Intra Peritoneal Hemorrhage
IUI : Intrauterine insemination
IUP : Intraurethral pressure
IVP: Intravesical pressure
LEEP : Loop Electrosurgical Excision Procedure
LGV: Lymphogranuloma Venereum
LLETZ : Large loop excision of the transformation zone
LMA : Left Mento Anterior
LMWH : Low Molecular Weight Heparin
LNG-IUD : Levonorgestrel - Intrauterine Device
LOA : Left Occipito Anterior
LPD : Luteal phase defect
LSA : Left scapula -anterior
LSIL : Low grade squamous intraepithelial lesion
MA : Mento-anterior / Monoamniotic
MC : Monochorionic
MCL : Midclavicular line
MCT : Malignant cystic teratoma
MDIF : Mullerian duct inhibiting factor
MH : Metropathia haemorrhagica
MP : Mento-posterior
MRKH : Mayer Rokitansky Küster Hauser syndrome
MSAFP : Maternal serum Alpha Fetoprotein
MSH : Melanocyte stimulating hormone
MST: Malignant solid teratoma
MTX : Methotrexate
MV: Mento-vertical
MZT : Monozygotic Twin
NT : Nuchal Translucency
NTD : Neural Tube Defect
OF: Occipito-frontal
OGTT : Oral Glucose Tolerance test
OHSS: Ovarian hyperstimulation syndrome
PAPP-A : Pregnancy Associated Plasma Protein A
PAS : Placenta Accreta Spectrum
PCT : Post coital test
PE : Preeclampsia
PEB : Premenstrual Endometrial Biopsy
PG: Primigravida / Pelvic Grip
POI : Premature ovarian insufficiency
POP: Pelvic Organ Prolapse
PPC : Post Partum Care
PROM : Premature Rupture of membranes
PUL : Pregnancy of Unknown Location
ROD : Right Oblique Diameter
ROM : Rupture of membranes
RSA : Right scapula – anterior
SIDS : Sudden infant death syndrome
SMB: Submento-bregmatic
SMM : Submucous myoma
SMV: Submento-vertical
SOB: Suboccipito-bregmatic
SOF : Suboccipito-frontal
SP: Symphysis Pubis
TD : Tubal Disconnection
TDF : Testicular differentiation factor
TENS : Transcutaneous Electrical Nerve Stimulation
TOA : Tubo-ovarian abscess
TOC : Tuboovarian cyst
TOT : Transobturator tape
TTTT : Twin To Twin Transfusion syndrome
TVT : Tension-free vaginal tape
UAE: Uterine artery embolisation
UG : Umbilical Grip
VaIN : Vaginal intraepithelial neoplasia
VIN : Vulvar intraepithelial neoplasia
VVF : Vesicovaginal fistula

Index

Gynecology

Physiology of menstrual cycle ---------- 7
Amenorrhoea ---------- 8
Puberty & Menopause ---------- 9
Anovulation , PCO , Hirsuitism & Hyperprolactinemia ---------- 10
Infertility ---------- 11
Fibroid ---------- 12
Endometriosis & Adenomyosis ---------- 13
AUB ---------- 14
Contraception ---------- 15
Pelvic Organ Prolapse ---------- 16
Urinary Incontinence & Rectovaginal fistula ---------- 17
Lower genital tract infections ---------- 18
Acute PID ---------- 19
Chronic PID ---------- 20
STDs ---------- 21
Scheme for oncology---------- 22
Endometrial Carcinoma ---------- 23
Cancer Cervix ---------- 24
Benign Ovarian Tumours ---------- 25
Malignant Ovarian Tumours ---------- 26
Functional cysts of the ovary ---------- 27
Benign conditions of the vulva & vagina ---------- 27
Malignant vulval & vaginal tumours ---------- 28
Anatomy of female genital tract ---------- 29 - 31
Sexual differentiation & abnormalities of female genital system --- 32
Endoscopy in Gynecology ---------- 33
Operative Gynecology ---------- 34

Obstetrics

Abortion ---------- 36
Ectopic pregnancy ---------- 37
GTDs & Vesicular mole ---------- 38
Anatomy of female pelvis & fetal skull ---------- 39
Normal Labor ---------- 40
Abnormal labor & CPD ---------- 41- 42
Occipito posterior / Face & Brow presentations ---------- 43
Breech presentation ---------- 44
Shoulder presentation ---------- 45
Multi fetal gestation ---------- 46
Operative vaginal delivery ---------- 47
CS / Episiotomy / Analgesia & Anesthesia in labor ---------- 48
APHge / Intrapartum Hge ---------- 49
Puerpurium ---------- 50
Complications of 3rd stage of labor ---------- 51
Puerpural sepsis ---------- 52
Assessment of fetal wellbeing ---------- 53
Premature Rupture of Membranes / Amniotic fluid disorders ---------- 54
Prematurity & Postmaturity ---------- 55
SGA & LGA ---------- 56
Fetal & neonatal asphyxia ---------- 57
Fetal birth injuries ---------- 58
Hypertension with pregnancy ---------- 59
RH isoimmunization ---------- 60
DM with pregnancy ---------- 61
UTI , Cardiac diseases & Seizures with pregnancy ---------- 62
Anemia , Thyroid disorders ,VTE & PE with pregnancy ---------- 63
GIT disorders with pregnancy ---------- 64
Prenatal diagnosis of congenital anomalies ---------- 65
Fertilization, implantation & placenta formation ---------- 66
Placenta , cord ---------- 67
Diagnosis of pregnancy / Physiological changes during pregnancy ----- 68
ANC ---------- 68
High risk pregnancy , Maternal mortality ---------- 69

Clinical History taking 71-76

GYNECOLOGY

Physiology of menstrual cycle

Hypothalamus : GnRH

Pituitary : FSH / LH

Ovary: E_2 / P

Endometrium : Glands

Cervix: Mucus

Vagina: Cells

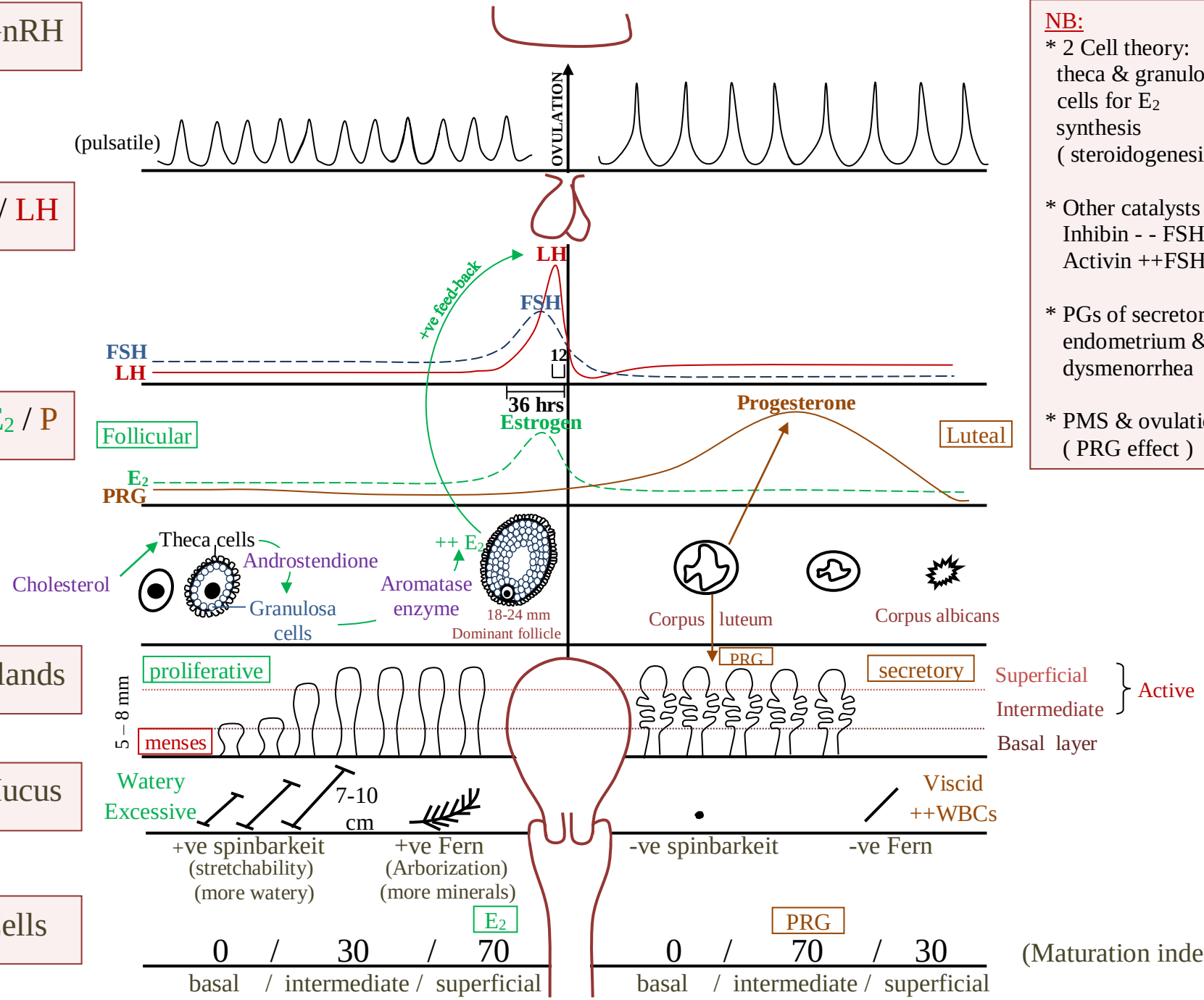

NB:

* 2 Cell theory: theca & granulosa cells for E_2 synthesis (steroidogenesis).
* Other catalysts as Inhibin - - FSH Activin ++FSH
* PGs of secretory endometrium & dysmenorrhea
* PMS & ovulation (PRG effect)

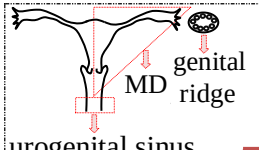

1ry Amenorrhea

XY → TDF, MDIF

- In the presence of 2ry sexual characters (∴ presence of E_2)
- In abscence of 2ry sexual characters (∴ abscence of E_2)

- Kallmann syndrome (+ anosmia)

Hypothalamus → GnRH

Axis is normal ✔ / Axis is affected ✖

Ant. Pituitary → FSH / LH

- Turner (45 XO)

Ovary → E_2 / PRG (E_2 ✔ / ✖ E_2)

- Mullerian agenesis (46 XX) (MRKH)
- AIS (46 XY)
- Asherman syndrome

Outflow tract obstruction (= cryptomenorrhea)
- Cx atresia
- Transverse vag septum
- Imperforate hymen

2ry Amenorrhea

- **Pregnancy**
- **Uncontrolled endocrinal disorders as thyroid / DM / cushing**
- Drugs (eg antipsychotic / GnRha / continuous OCPs)
- Psychological (stress / exercise/ anorexia nervosa / bulimia nervosa / pseudocyesis)
- Sheehan syndrome (H/O of PPHge)/ Simmond's disease
- Empty sella syndrome (↑ CSF & compression of pituitary)
- Prolactinoma (↑ ICT) → micro < 1cm, macro >1cm
- PCO (commonest cause of pathological anovulation)
- POI (& resistant ovary syndrome)
- Ashermann syndrome (after D&C)

Clinical approach to a case of amenorrhea

1) History

2) Examination
- External genitalia
- 2ry sexual characters

3) US
(presence or abscence of uterus)

4) Hormonal
- ++ FSH ∴ ovarian causes (hypergonadotrophic hypogonadism)
- -- FSH ∴ hypothalamic / Pituitary causes (hypogonadotrophic hypogonadism)
- (N) FSH ∴ PCO (eugonadotrophic hypogonadism)

5) Specific :
- Pregnancy test
- Karyotyping
- CT brain
- Laparoscopy
- Hysteroscopy
- Thyroid profile
- PRL level

Treatment of the cause → Surgical / Medical → Withdrawal / Induction of ovulation / or regulation of menses by COPs

Puberty (11-12yrs)

(Non reproductive → reproductive)

Due to maturation of pulsatility of hypothalamus

Normal sequence of pubertal changes:

1) Growth spurt
2) Thelarche (Tanner staging I→ IV)
3) Pubarche (Adrenarche)
4) Menarche
5) Axillarche

Abnormal puberty

- **Precocious < 8 years**
  - **True (common)**
    - ∴ axis is present
    - ∴ ovulation occurs
    - **Constitutional (mostly)**: Permanently short stature; ttt: GnRHa till certain age
    - **CNS lesion (Rarely)**: ttt of cause
  - **Pseudo (rare)**: only peripheral hormones, NO axis, ∴ NO ovulation
    - **Isosexual (∴ ++E_2)**: Eg: Drugs, E_2 secreting T., Hypothyroid
    - **heterosexual (∴ ++Androgen)**: Drugs, Androgen secret. T., CAH

Inv & ttt of the cause

Investigations for all :

1) History to detect cause (drug intake)
2) US : to detect any tumors
3) Hormonal profile : for levels of E_2 , FSH , androgen
4) Specific for suspected lesion eg : CT Brain

- **Delayed**

(as 1ry amenorrhea but due to familial / constitutional)

Menopause (51-52 yrs)

(Reproductive → non reproductive)

Due to depletion of follicles

--E_2, --Inhibin → -- SHBG, ++ Free Testosterone; ++ FSH

Clinical manifestations:

1) Atrophy of urogenital system :
   * Vulva : gaping
   * Vagina : dryness , dyspareunia (ttt : give local E_2 cream) / infection
   * Cx
   * Uterus : ET < 5mm
   * Breast
   * Urethra / bladder : infection / SUI
   * Ligaments : POP
2) Androgrnic manifestations : voice / temporal recession of hair / change in libido
3) **HOT FLUSHES (most irritant)** → ttt : HRT
4) Mood changes: insomnia
5) Skin : loss of collagen
6) Remote complications:
   * CVS manifestations → ++LDL / --HDL
   * Osteoporosis → ++ osteoclasts / -- osteoblasts

Management:

1) Reassurance
2) Change life style : exercise / stop smoking / dietary habits
3) Prophylactic : Ca^{++} / Vit D
4) Annual screening program: TVS / Pap smear / Mammography / Lipid profile / DEXA
5) ttt of complications :
   * Osteoporosis
     - → Biphosphonate (once weekly)
     - → SERM BUT ++ hot flushes
     - → Phytoestrogen BUT weak
     - → HRT BUT Ca breast / Ca endometrium / ++CVS
       - ∴ CI : H/O Breast ca / AUB / DVT / Active liver disease
       - Forms : continuous E/P , Cyclic E/P , E only in TAH
   * CVS complications : prevention / cardiology referral



Anovulation
{ = hypogonadism }

Def:

Et:
- Kallmann, Stress, Drugs → ↓ GnRh ∴ ↓ FSH → Hypothalamus
- prolactinoma, empty sella, sheehan → ↓ FSH → Ant. Pituitary

→ **I) HYPO**

Ovary:
- Turner, POI → ↓↓ E_2 ∴ ↑↑FSH → **III) HYPER**
- PCO → Ⓝ FSH → **II) EU**

Cl.picture:

S :
- Regular cycles / spasmodic dysmenorrhea / PMS
- Midcycle
  - Pain (Mittleschmerz)
  - Spotting
  - Discharge

Inv :

1) BBT chart
2) Folliculometry: at midcycle
3) PRG: at D_{21} > 5ng/ml (5-10 = LPD)
4) LH Kits urinary : at midcycle
5) PEB: not done

Ttt: of cause if present

induction of ovulation

* Clomiphene Citrate (CC) in eugonadotrophic
* HMG/ HCG in hypogonadotrophic
* Ovum donation ?? in hypergonadotrophic

PCO

* Stein & Leventhal 1935 (obesity / Hirsutism / Infertility)
* Rotterdam criteria 2012

(anovulation / hyperandrogen / US necklace appearance)

- Irregular cycles, Infertility
- hirsutism

Inc: 5-10%

Et : theory

++ leptin → ++GnRh & ++ LH (maintained)

- ++ insulin resistance
- ++ androgen
  - Hirsutism
  - peripheral conversion → ++E_1
- no ovulation → ∴ NO PRG < 5ng/ml

Hyperestrogenic state

Inv:

I) Labs:
- Ⓝ E_2
- ++ androgen
- ++ E_1
- ++ LH / Ⓝ FSH
- - - PRG < 5ng /ml
- ++ insulin resistance

II) US: Adam's criteria 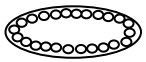 Necklace appearance

III) Lap: (not needed for diagnosis) oyster-shell appearance

Ttt:

1) Weight reduction / metformin
2) Symptomatic ttt:
   * COPs to regulate cycles
   * Spironolactone /cimitidine / OCPs for hirsutism
   * CC for anovulation (++ OHSS in HMG/HCG)
   * LOD (peritubal adhesions : not used)

Hirsutism

Def : ++ hair growth in androgen dependent areas

Et :
- Constitutional (commonest)
- Ovarian as PCO
- Adrenal é ++DHEAS
- Iatrogenic medication

Diagnosis :

1) Labs :
   * DHEAS
   * Total & free testosterone
2) US : for pelvis (ovaries & adrenal)

Ttt:

* Spironolactone (--5α reductase)
* OCPs (++SHBG ∴ -- free androgen)
* Cimetidine (antiandrogen) + hair removal

Ttt of cause if present

Hyperprolactinemia

Def : ++PRL > 29ng ml

Et :

* Physiological (commonest)
* Medication side effect (eg: antipsychotic)
* Prolactinoma
  - micro < 1cm
  - macro > 1cm

Diagnosis :

* Lab: PRL level
* CT Brain

Ttt : of cause

* Micro : Bromocriptine (dopamine agonist) Or Cabergoline
* Macro: surgical removal

Infertility

Def :
failure of conception after **1 year** in **1ry** or **2 years** in **2ry** infertility
Inc: 15%

Etiology :
1) Male causes 40% : congenital / traumatic / inflammatory/ neoplastic / others as heat exposure

Female 40-50%
2) Ovarian 40% : anovulation (hypothalamo – pituitary – ovarian causes)
3) Tubal 40% : PID / surgery(peritubal adhesions)
4) Uterine 15% : affection of endometrial cavity (polyp / septum / fibroid / Asherman…)
5) Cervical 5% : hostile mucus(as Ab , use of CC)
6) Sexual 5% : vaginismus / impotence / premature or retrograde ejaculation / dyspareunia
7) Unexplained 10 - 15% : no obvious cause (?? endometriosis)

Cl picture: of each one of etiologies
(Male /Ov/ Tubal / Ut /Cx / Sexual)

Inv :
1) Male : Semen (N) 15 million/ml , 50% motile , 30% normal , alkaline PH
- Hormonal profile / Duplex
- Testicular biopsy (in azospermia)

2) Ovarian: detect ovulation : BBT / Folliculometry
Midluteal PRG > 5ng/ml / LH kits / PEB
3) Tubal : HSG : for uterine cavity & FT patency & peritubal adhesions
If abnormal : laparoscopy
4) Uterine : US / HSG
If abnormal : hysteroscopy
5) Cx : PCT (post coital test): Not done now

Ttt:
1) Male:
- Stop smoking / Control DM / ttt of clinical varicocele
- Vitamins for 3 months
- IUI in oligospermia
- Or IVF – ICSI in severe male factor

2) Ov.cause : induction of ovulation
- Clomid
- HMG/HCG

3) Tubal : tuboplasty / IVF
4) Ut cause: hystroscopic ttt of cause
5) Cx cause : IUI
6) Unexplained or failed above lines : IVF – ICSI after DL

IVF – ICSI

a- Down regulation of pituitary by
- GnRh agonist
- Or
- GnRh antagonist

b- Start stimulation by HMG/ HCG till mature follicles
c- HCG for final maturation
d- Oocytes retrieval under GA
e- ICSI or IVFertilization for 2-5 days for division
f- ET(Embryo transfer) on day 2,3,5 (No need for GA)
g- Natural progesterone to support LP
(or for 3 months if pregnancy occurs)

Fibroid (myoma , leiomyoma)

Menorrhagia

- **Definition :** Benign tumour of smooth muscle fibers of the myometrium.
- **Incidence :** 25 % of ♀ in child bearing period !!! WOW
- **Etiology :** + + E_2 eg (Genetic / Racial / Nulligravida / Anovulation / Early menarche & Late menopause ….)
- **Pathology :**
  - Gross (site / size / shape / consistency / cut section / count)
  - Mic: < 10 mitotic figures / 10 HPF
  - Pathological changes
    - Atrophy
    - Necrosis
    - Infection
    - Degeneration → * Hyaline (commonest) * Cystic * Fatty * Calcification (menopause) * Red (Necro-biosis) commonest in pregnancy: incomplete necrosis
    - Malignant (very rare) ← (Uterine Sarcoma): * Rapid growth * Rapid recurrence * Growth after menopause
- **Clinical picture :**
  - S: Asymptomatic / Menorrhagia ,unless SM fibroid polyp metrorrhagia / Pain / Mass /Infertility…
  - S: → general → anemia
  - → abdominal → mass (can't reach lower border)
  - → PV & Bimanual → mass (in weeks → describe)
  - DD → symmetrical / asymmetrical enlarged uterus
- **Diagnosis :**
  - US : TVS (TAS) : Gold standard
  - Hysteroscopy / Laparoscopy / HSG / MRI / CT / X-Ray…

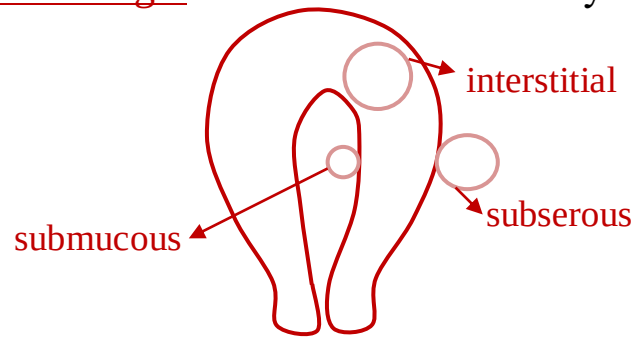

- **Treatment :**
  - Conservative: NO symptoms ∴ NO ttt
    EXCEPT : > 14wks / BLM / Infertility or RPL in SMM / Rapid recurrence / Growth after menopause
  - Medical: → Antifibrinolytic eg Tranexamic acid
    → Venotonics eg Daflon
  - Hormonal (Gestagens / GnRh agonist / OCPs)
  - Microinvasive techniques : UAE / lap. Myolysis / HIFU
  - Surgical (definitive ttt) : → Myomectomy (open / laparoscopic / hysteroscopic)
    → Hysterectomy (open / laparoscopic / vaginal ?)

NB: Fibroid during pregnancy , Never to be removed , due to high vascularity & ++ E_2 EXCEPT in certain conditions

Endometriosis

PAIN

Def: presence of end. glands & stroma outside ut. cavity
∴ uterus is clean

Incidence: 10% of all ! 😮 20% of ch.pelvic pain 30% of infertility

NB : Commonest cause of chronic pelvic pain is Idiopathic

Etiology: (++ E_2) / white races
+ theories
- Sampson Retrograde menstruation
- Halban Lymphatic theory
- Meyer's coelomic metaplasia theory
- Immunologic & genetic theory

Pathology:
- site
  - pelvic √√
  - extrapelvic
- size
  - small spots : burn match
  - large cysts :endometrioma (chocolate cyst)

Clinical picture :

Type of patient:

- Symptoms: PAIN / ± Infertility
  dysmenorrhea / dyspareunia (deep) / dyschezia / dysuria /ch. pelvic pain
- Signs :
  - General
  - Abdominal
  - Local: PV & Bimanual
    - fixed RVF
    - endometrioma (adnexal mass)
    - nodules in DP

DD of nodules in DP : Endometriosis / TB / Krükenberg

Inv:
- US : for endometrioma (Ground glass appearance)
- CA125: prognostic & follow up not diagnostic
- Laparoscopy : gold standard

Ttt:
- Symptomatic for pain
- Hormonal to atrophy end. glands : **continuous** COPs / gestagens
- Surgical
  - conservative:
    - lap ov.cystectomy if endometrioma > 4cm
    - lap. ablation of end. foci
  - definitive : TAH **&** BSO

Adenomyosis

Menorrhagia

Def: presence of end. glands inside myometrium
∴ uterus is affected

Etiology + theories: more in Multipara
(infiltration in myometrium during involution)

Pathology :
- localized: DD Fibroid (false capsule)
- diffuse

cut section : Granular trabecular pattern with no capsule

Clinical picture :

Type of patient:

- Symptoms:
  - bleeding (menorrhagia)
  - pain (2ry dysmenorrhea)
- Signs:
  - General : anemia
  - Abdominal : ± enlarged uterus
  - PV & Bimanual: Halban sign (enlarged tender uterus)
    Free adnexae
- DD: Fibroid (not tender)

Inv: US (TVS / TAS if large Ut)

Ttt:
- Symptomatic :
  - Analgesics / antifibrinolytics / venotonics
  - Hormonal : (to↓↓menses)
    eg : OCPs / gestagens / **mirena LNG-IUD**
- Definitive surgical ttt : TAH

AUB

After menopause (postmenopausal bleeding)
- (most common) Atrophic
- (most serious) EH / EC

Before puberty
- mostly FB introduction
- may be precocious puberty

Child bearing period
(Menorrhagia / Metrorrhagia / Contact bleeding)

1. Exclude: Complications of pregnancy (ie bleeding in early pregnancy) (β-HCG)
2. Exclude: Complications of contraception (IUD / Hormonal)

Then do US

4. Non - structural (= Dysfunctional DUB)

COEIN
- **C**oagulation disorder
- **O**varian disorder
  (sp after puberty & before menopause/ PCO / …)
  (*Metropathia Hgica)
- **E**ndometrial disorder
- **I**atrogenic drugs (eg anticoagulants)
- **N**on specific (HTN / Liver troubles / Thyroid troubles)

Ttt:
- of cause if present
- If ovarian disorder:

Dysfunctional menorrhagia
(mefenamic acid / antifibrinolytic / venotonics)

Dysfunctional metrorrhagia
- COPs / gestagens
- Mirena IUD (old / multipara)
- D&C (severe bleeding)
- End. ablation (alternative to TAH , less morbidity)
- TAH

3. Structural abnormalities

PALM
- **P**olyp
- **A**denomyosis
- **L**eiomyoma
- **M**alignancy → cx endometrium
- functioning ovarian tumor

ttt of cause

FIGO 2011

***NB :** Metropathia hemorrhagica: Abnormal excessive , often continuous bleeding due to persistence of proliferative phase of menstrual cycle = swiss cheese appearance (back to back arrangement of glands)

Dysmenorrhea

Def :

Types:
- 1ry spasmodic
- 2ry congestive
- Endometriosis
  (crescendo-decrescendo)

Cl picture:
- Type of pt
- S → type of pain
  → associated symptoms
- Signs → General
  → Abd
  → PV / PR / Bimanual

Inv :
to confirm or exclude organic lesions

Ttt:
- Spasmodic (NSAID / COPs)
- Congestive (ttt of cause)

PMS

(Premenstrual Tension Syndrome)

Keep diary ∮ monthly

Contraception

	Physiological	Barrier	IUD	Hormonal	Sterilization
Types	* safe period * coitus interruptus * lactation sp in first 6 months	*Physical → Condom ♂ / ♀ → Vag diaphragm → Cx cap *Chemical spermicidals → Nonoxynol-9	* Copper * Silver * Mirena (LNG – IUD)	Oral E / P (daily) P (daily) non-stop IM E / P (monthly) P (3months) subdermal Implants (3 years) P Vag ring E / P (3wks) Patches E / P (weekly for 3wks)	* Female ♀ Tubal ligation (lap /open / vag) * Male ♂ Bilat vasectomy
Mode of action	* - - Fertilization * - - Ovulation	* - - Fertilization * Kill sperms	* - - implantation (create unfavorable medium ie inflammatory)	* - - ovulation * Atrophic endometrium * Thick cx mucous (Hostile) } PRG * Affect tubal motility 4 PRG ONLY contraceptives	- - Fertilization
Benefit	Easy / Cheap / Available	* STDs protection with condom	Effective (commonly used in developing countries)	* Regular cycles (with COCPs) (commonly used in developed countries)	* Permanent ?
Side effects	* Ineffective * Need cultured couple		* Bleeding(menorrhagia) except é Mirena * Infection * Perforation / expulsion * Missed IUD * Pregnancy on Top	* Break through bleeding / ↓amount of menses * PMS like $ * Hypercoagulable state with E containing COPs * Render hypertension , DM difficult to be controlled	* Post ligation syndrome * Permanent
CI	* Irregular cycles	* lack of compliance	* Infection * undiagnosed bleeding * anatomical ut defect * H/O of: PID/ Ectopic	* H/O of DVT (with estrogen content) * Breast lesion or family H/O * Impaired liver function * HTN / DM * Migraine * Lack of compliance (é pills)	* Future desire for fertility (Undecided couple)

* **Emergency contraception:** OCPs : 4 tab $\xrightarrow{12hrs}$ 4 tab , LNG : 0.75 mg $\xrightarrow{12hrs}$ 0.75mg (up to 48hrs) / IUD : (up to 5 days)
* **Contraception during lactation:** All EXCEPT → E content (as Estrogen - - inhibits lactation)
  → Physiological safe period

Pelvic organ prolapse (POP)

Def : desent … below (N) anatomical position

Inc : 25% !!

Et : Weakness of support :

(**lig:** Mackenrodt's / uterosacral / pubocervical / **ms:** levator ani / **fascia**)

due to :
- Repeated childbirth
- Menopausal atrophy
- Congenital weakness

} + PPT factors

Types :

* Vaginal
  - ant (uretheocele / cystocele)
  - post (deficient perineum / rectocele / enterocele or hernia of DP)
  - apical (vault prolapse after hysterectomy)
* Uterine
  - 1st
  - 2nd
  - 3rd / complete procedentia

Pathology :
- Vagina : keratinization
- Cx : trophic (decubitus) ulcers
  Supravaginal elongation of Cx (sound)
- Bladder : stasis of urine / kinking of ureter

Cx { supravag portio-vaginalis

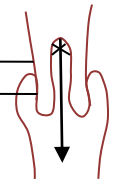

Cl picture:

* Symptoms:
  - Asymptomatic
  - Heaviness at end of day / backache / mass protruding
  - Symptoms of pelvic congestion
  - Ant: urinary symptoms (frequency or inability to complete except by reposition)
  - Post: rectal (defecation symptoms)
  - Sexual symptoms & lack of satisfaction
* Signs :
  - Gen : obesity/ chest / abd enlargement
  - PV : inspect / palpate / gurgling in case of enterocele
    sound in supravaginal elongation of Cx

Inv :

* Urine analysis (for urinary symptoms)
* Tests for SUI (in cases of cystocele)

Ttt :

*** Prevention** :
- Proper spacing
- Proper management of 1st , 2nd & 3rd stages of labor
- Kegel's exercise after delivery

*** Actual ttt:** (surgical at least 3-6 months after delivery)

Vaginal:
- Ant repair for cystocele
- Post repair for rectocele

} classical repair for cystorectocele

Uterine :
- Sacrospinous fixation & shortning of Mackenrodt's ligament in uterine prolapse to preserve fertility
- Vaginal hysterectomy in uterine prolapse & no need for fertility

in Cx elongation : Fothergill's or Manchester op

NB :

* LeFort operation : in very old é no sexual activity & can't withstand vag hysterectomy
* Pessary : in extremely fragile debilitating , can't withstand any form of anesthesia & surgery

Urinary incontinence (involuntary escape of urine upon …)

	SUI (urodynamic incontinence)	DO (urge incontinence)	GUF → total true (no desire) / Urethrovaginal
	Mixed incontinence		
Def	Involuntary escape of urine upon ↑ IAP	Involuntary escape of urine upon desire to micturate	Connection b urinary & genital tracts (Always wet except in urethrovaginal)
Et	* Same as POP * Hypermobile urethra	++ D.contractions (idiopathic / irritation / infection)	* Obstetric (developing countries) * Surgical (developed countries)
Cl.pict	Involuntary escape upon straining	Can't make it to toilet	May have desire in small high vesicovaginal fistula or in uretrovaginal fistula
Inv	* Cough test * Bonney's test (in POP +SUI) * Q – tip test > 30° mobility Ⓝ urodynamics : (D.filling pre <15 cmH_2O / 1st Desire 150 ml / Residual < 50ml / full at 400-600 ml) * Normal filling pressure * Leak on cough IVP > IUP	* urine analysis * urine C/S * Cystoscopy * Filling pr > 15cmH_2O (due to contraction of detrusor) * No leakage upon cough (as IUP > IVP)	* Sim's speculum & position * Methylene Blue (3 gauze test) * IVP (if KFTs Ⓝ) * Cystoscopy (to visualize fistula)
ttt	SURGICAL Start by - Kegel's - Scheduled voiding * Periurethral plication (Kelly's suture) é 60-70% success * TOT > TVT vaginal sling op (if without POP) * Retropubic urethropexy (Burch colposuspention) (Gold standard) success > 90% * Periurethral injection of Collagen in hypermobile urethra	MEDICAL : bladder training * ttt of infection * ttt of stones * Anticholinergic as oxybutynin (destrusitol)	CATHETER IF SMALL SURGICAL IF LARGE * Dedoublement vag in low fistulae & abd in high fistulae **NB :** *In uretrovag :* desire is present from Ⓝ ureter filling & continuous leakage from affected ureter at site of UVF –ve MB test / Abd repair *In urethrovaginal :* splinting urethra *Before surgical repair in VVF:* * 3-6 months from procedure while putting a urinay catheter to divert urine, decrease size of fistula & allow max healing * Post op: catheter for 10-14 days * No pregnancy for 1 year * Delivery by CS

In mixed incontinence: give medical ttt for urge incontinence first, before planning surgery for SUI

DD: * Retention with overflow (intermittent self catheterization) / * Nocturnal enuresis (psychological ttt)

Rectovaginal fistula

Def : track between rectum & vagina

Cl.pict :
* if small : incontinence to flatus
* If large: incontinence to stools

ET:
* mostly between lower rectum & vagina , due to failed episiotomy repair or obstetric trauma.

Ttt: SURGICAL

Preoperative : fluid diet & intestinal antiseptic for 3-5 days

OP :
* Low1/3 : transform to complete perineal tear & repair by Lawson Tait operation
* High fistula: Abdominal repair by dedoublement as VVF

Post operative :
* Low residue diet for 7 days
* Use laxatives to avoid constipation
* Episiotomy should be done in subsequent deliveries

Lower Genital Tract Infections (no fever)

LGT infections:
- **Vaginitis**
  - Childhood: foreign body / worms
  - Menopause : -- E_2 Atrophic / Alkaline PH
  - Childbearing: protected by
    - Stratified squamous epithelium
    - ++ E_2 ∴ ++ Glycogen
    - Lactobacilli / Lactic acid (acidic PH)
- **Cervicitis**

vaginitis

	Bacterial vaginosis (commonest)	Candidiasis (2nd common)	Trichomoniasis (3rd common)
organism	Bacteria Gardnerella vaginalis	Fungus Candida albicans	Protozoal Trichomonas vaginalis
Et	++++ anaerobes	--- immunity	STD
PH	Alkaline : 4.7-7	Acidic < 4.5	Alkaline : 5-6
Cl.picture	Fishy odour Profuse / non irritant Grayish discharge	Extremely irritant Cottage cheese Scanty Odorless discharge	Profuse / yellowish Mildly irritant / malodorous discharge / é BV & other STDs Strawberry Cx In 25% of cases
Mic +KOH	Clue cells	Hyphae / pseudohyphae	Flagellated protozoon 
Treatment	Metronidazole 500 mg bid / 7days (CI in 1st trimester, give local cream or supp only)	Fluconazole 150 mg once weekly for 2 weeks (CI all through pregnancy & in liver troubles, give local cream or supp only)	Metronidazole 2gm single oral dose + ttt of partner

Cervicitis

	Acute	Chronic	Erosion
Etiology	Polymicrobial sp. Neisseria & Chlamydia	On top of acute	*infection (ch.cervicitis) *hormonal(preg /COCPs) *congenital
Cl.picture	*Mucopurulent discharge *Dyspareunia *Backache	*Mucous polyp *Nabothian follicles *Hypertrophic cervicitis	Contact bleeding
Inv.	We may do C/S from discharge		Pap smear
Treatment	Doxycycline 100 mg bid / 7days Or Azithromycin 1gm single oral dose (in pregnant females)		* ttt of the cause. * Residual cases: Cauterization → Diathermy → Cryo → Laser

Acute PID (presence of fever)

Definition: Salpingitis , oophoritis , peritonitis & rarely endometritis due to regular monthly shedding in childbearing period.

Et:
- organism: N.gonorrhea, Ch.Trachomatis (mostly both together& others)
- route: ascending (mainly) , local or lymphatic , blood (rarely)
- risk F:
  - sexually active , multiple sexual partners
  - IUD , after menses , after sexual intercourse
  - é any procedure : D&C , HSG , Hysteroscopy, …

NB:
- OCPs & barrier contraception ↓ risk (ie are protective)
- Chlamydia may cause silent PID

Pathology:
- Endosalpingitis / interstitial salpingitis / perisalpingitis (acute catarrhal or acute suppurative)
- Oophoritis : é microabscesses on the surface
- Pelvic peritonitis

Clinical picture:
- Symptoms:
  - fever , malaise , headache ,
  - H/O of recent OBGYN procedure
  - Acute lower abdominal pain
  - Foul smelling purulent vag. discharge
- Signs:
  - Fever > 38.3˚ , tachycardia
  - Lower abdominal tenderness & rebound tenderness
  - Cx Motion tenderness , discharge
- Complications :
  - chronic PID (if inadequately treated)
  - Tubal obstruction & infertility (due to fibrosis & adhesions)
  - ++ risk of ectopic pregnancy

Inv:
- Blood tests: ++TLC , ++DLC , shift to Lt , ++ESR ,++ CRP
- US to exclude DD : ectopic , complicated ovarian , appendicular mass , degenerated myoma
- Laparoscopy: if diagnosis is doubtful

NB:
- Exam of discharge to detect causative organism & do C/S (not clinically needed)
- Fitz Hugh Curtis syndrome (filmy adhesions between the liver & under surface of diaphragm may be seen on laparoscopy in cases of chlamydia)

Treatment:
- Mild PID (é mild symptoms) → Outpatient
  - Ceftrioxone 250mg single IM dose
  - + doxycycline 100mg oral /12hrs/14days
  - ± Metronidazole 500mg oral bid / 14days
- Severe PID (é severe symptoms) → Hospitalization
  - IV fluids /IV analgesics / IV antipyretics
  - IV antibiotics :
    - Cefotetan 2g IV/12hrs or cefoxitine 2gm IV/6hrs
    - ⊕ Doxycycline 100 mg orally / 12hrs for 1-2 days till symptoms become milder then continue previous oral regimen of mild cases for 2weeks

NB:
1) IF IUD present → remove
2) In case of TOA → give clindamycin 900mg IV / 8hrs or Metronidazole 500 mg IV / 8hrs in addition to the 2 above mentioned drugs of severe PID
3) IF TOA doesn't resolve by medical ttt :
   - ∴ drainage through laparoscopy / laparotomy or colpotomy (vaginal drainage)

Chronic PID

Sequelae of acute

Pathology:

- Hydrosalpinx :
  sequelae of inadequately treated acute catarrhal salpingitis
- Pyosalpinx :
  sequelae of inadequately treated acute suppurative salpingitis
- TOC
- TOA
- Chronic Interstitial salpingitis

Clinical picture :

- Symptoms :
  * history of acute PID
  * dull aching lower abdominal pain
  * pelvic congestion

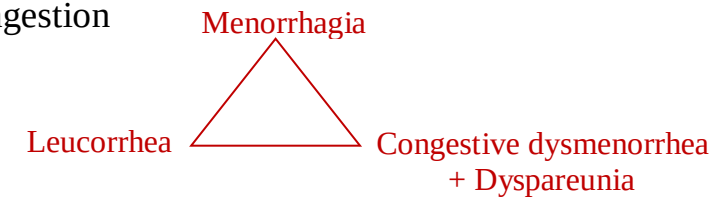

  * backache
  * infertility from tubal obstruction & peritoneal adhesions
- Signs:
  * adnexal tenderness/ fullness / cyst
  * fixed RVF in case of extensive adhesions

investigations:

- US for adnexal masses
- HSG for hydrosalpinx
- Laparoscopy is the gold standard

Treatment :

Symptomatic ttt

eg :
- infertility ttt → (TD + IVF)
- pain & congestion in old age → (TAH & BSO)

(antibiotics only in acute exacerbations)

TB (chronic from the start)

TB is a chronic granulomatous disease

Etiology:
- Mycobacterium tuberculosis
- Blood spread from lungs (most common)

Pathology : (genital TB)

- FT: (affected in 100% of cases of TB of genital tract)
  *Endosalpingitis: caseous material inside thick , tortuous ,
  tobacco pouch appearance (open everted fimbrial end)
  *Interstitial salpingitis : thick , beaded , salpingitis ithmica nodosa
  *Perisalpingitis: é multiple tubercles on the surface
  & on surrounding peritoneum
- Endometrium (80 %) : affection of basal layer → IU adhesions
  or Asherman syndrome (PEB is diagnostic)
- Oophoritis : with microtubercles
- Rarely : serpiginous ulcers / cervical ulceration (DD of cancer cx)

Clinical picture :

- Symptoms:
  - Asymptomatic
  - Low grade fever/ loss of wt / loss of appetite
  - 5-10% of infertility cases are due to TB salpingitis
  - Amenorrhea / oligomenorrhea
- Signs:
  - Mostly normal + Nodules in DP
  - Genital serpiginous ulcers é undermined edges

Investigations :

- X-ray chest (& pelvis for calcified LNs)
- HSG (not in active TB) : retort shape tube , IU adhesions
- PEB
- Laparoscopy ± biopsies from suspicial lesion (serosal tubercles to be stained by Ziel –Nielsen to show the acid fast , alcohol fast bacilli)
- Tuberculin is a good –ve test

Ttt:
- General ttt for anemia , proper nutrition
- Anti TB (Rifampicin , INH , Pyrazinamide , Ethambutol)
- Surgical ttt in case of tubal mass or endometrial TB
  & post operative anti-TB ttt

STDs

	Bacterial					Viral			$
	♂	Chlamydia Trachomatis	Chancroid	Donovanosis (GI)	LGV	HSV_2	HPV	HIV	$
Organism	Neisseria gonorrhea (columnar & transitional)	Chlamydia Trachomatis (columnar epithelium)	Hemophilus Ducreyi	Klebsiella granulomatis	Chlamydia $L_{1,2,3}$	HSV_2	HPV 6 / 11	AIDS	Treponema Pallidum
Cl.picture	PID		Vulval lesions					Vulval + Systemic manifestations	
	▶Mucopurulent discharge ▶Lower abdominal pain ▶Bartholin ▶Urethritis ▶Systemic (IP 3-5 days)	▶Subclinical ▶Mucopurulent discharge ▶PID (silent) ▶Squelae: Fitz Hugh Curtis syndrome in laparoscopy	Painful papule ↓ painful ulcer é exudation LNs +++ (IP 3-5 days)	Painless papule ↓ Ulcerate ××× NO ××× ××× LNs××× (IP 3 weeks)	Destructive lesion ↓ Ulcerate LNs +++ (IP 3weeks)	Painful Vesicles ↓ painful ulcer without exudation (IP 3weeks)	Painless warts (condyloma acuminata)  (IP 3months)	Asymptomatic ↓ Severe form Kaposi sarcoma (IP 3years)	▶1ry (chancre) Painless ▶2ry(condyloma latum) (maculopapular rash) ▶3ry(systemic) (tabes dorsalis)& gumma formation ▶Congenital: Vertical transmission
Inv.	▶Gram –ve diplococci ▶Culture: Thayer Martin ▶NAAT	▶Obligatory intracellular ▶Culture : expensive ▶NAAT	▶Coccobacilli ▶Cl.picture is enough	Gram –ve Donovan Bodies India/Africa	CF India/Africa	▶Culture of serum collected from vesicles ▶Ab	▶Pap smear (koilocytes) ▶Colposcopy	▶Western blot ▶Eliza	▶Dark field Mic (spirochetes) ▶Non-specific VDRL / RPR ▶Specific:TPH/TPI In 1ry $ ▶ Ag present In 2ry $ ▶ Ag & Ab In 3ry $ ▶ Ab present
Ttt	Ceftrioxone 250mg (IM) + Doxycycline 100mg / bid / (7days)	Doxycycline 100mg / bid / (7days)	Ceftrioxone 250mg (IM)	Doxycycline 100mg / bid / (3 weeks)	Doxycycline 100mg / bid / (3weeks)	▶Acyclovir 400mg 10 days (can be taken all through pregnancy) ▶Vesicles at labor = CS	Vaccine ▶Cryo ▶Diathermy ▶Podophyllin ▶Podofilox NB : CS only if large lesions obstructing labor	Antiretroviral ttt Vaccine ?	Penicillin In penicillin allergy: ▶If pregnant: Desensitization ▶If not pregnant: Doxycycline

NB: in case of pregnancy Doxycycline 100mg / bid / 7 days is substituted by Azithromycin 1 gm single oral dose as doxycycline is teratogenic

Other STDs : Trichomoniasis (protozoon) → infecting lower genital tract / Pediculosis pubis & scabies (Ectoparasites)

Scheme for oncology

Definition: From where the tumor arise

Incidence: How common / rare

Etiology :

- Predisposing F:
- Premalignant lesions :

Pathology:

- Gross :
  - * **Ulcer** with raised everted edges , irregular necrotic floor , indurated base
  - * Cauliflower **mass** with areas of hemorrhage & necrosis
  - * Firm / hard endophytic or exophytic **nodule**
- Microscopy : (depends on cell of origin)
  eg : squamous cell carcinoma /
  adenocarcinoma if arising from glands
- Grading :
  - *G I → < 5% malignant undiff.cells = best prognosis
  - *G II → 5-50% malignant undiff.cells = intermediate prognosis
  - *G III → > 50% malignant undiff.cells = poor prognosis
- Spread :
  - * Direct spread to surrounding structures
  - * Lymphatic to the draining LNs
  - * Blood : Lung Bone Liver Brain

Cl . picture :

- Symptoms:
  related to function / symptoms of metastasis
- Signs:
  - * General: for metastasis
    cachexia / anemia / jaundice / virchow's LN…
  - * Abdominal:
  - * PV & bimanual :
- Staging:
  - * Stage I : confined to the organ
  - * Stage II : limited local spread
  - * Stage III : more local spread ± LNs
  - * Stage IV: distant spread
    - IV a : mucosa of bladder & / or rectum
    - IV b : distant spread (L B L B)

Inv.

- To confirm diagnosis :
- To detect spread:
  - * eg: chest x-ray / abdominal & pelvic US / bone scan
- To assess fitness of pt for surgery: ECG & Lab testing

Ttt:

- Stage I , II : Surgery
- Stage III , IV : Radiotherapy / Palliative

Endometrial carcinoma



Def: Tumour arising from Endometrial glands

Inc: commonest tumour of ♀ genital tract & having best prognosis

Etiology :

- Predisposing F: ++ E_2 (unopposed) → early menarche / PCO late menopause /Granulosa cell tumor / use ERT / obesity /Tamoxifen
- Premalignant lesions : EH → simple 1% / complex 3%
  simple é atypia 9% / complex é atypia 29%

Pathology:

- Gross
  - Localized: endometrial polyp
  - Diffuse: ++ endometrial thickening > 5mm
- Microscopy
  - Adenocarcinoma (best prognosis) & commonest
  - Adenoacanthoma (+ benign sq metaplasia)
  - Adenosquamous (+ malignant sq cells)
  - Clear cell ca / papillary cell ca (undiff. so poorest prognosis)
- Grading :
  - G I → < 5% malignant undiff.cells = best prognosis
  - G II → 5-50% malignant undiff.cells = intermediate prognosis
  - G III → > 50% malignant undiff.cells = poor prognosis
- Spread :
  - **Direct:** myometrium / Cx / Ovaries / FT / vagina
  - Lymphatic: para aortic / inguinal / paracervical / parametrial
  - Blood : L B L B

Cl . picture :

- Type of pt / History
  (postmenopausal / white race / NG / PCO / Tamoxifen)
- Symptoms: Post menopausal bleeding (commonest)
- Signs:

*Gen: for metastasis : cachexia/ anemia / jaundice / virchow's LN…

*Abd: enlarged soft uterus ± signs of metastasis : ascites / liver

*PV & bimanual : enlarged soft uterus ± adnexal masses (? ut to ov or ov to ut)

Staging: (FIGO surgical 2018)

- Stage I : confined to the organ (uterus)
  - I a < ½ myometrial invasion
  - I b > ½ myometrial invasion ± endocervical glands
- Stage II : limited local spread : Cx. stroma
- Stage III : more local spread ± LNs
  - III a : Ovaries / FT
  - III b : Vagina / Parametrium
  - III c : LNs (parametric LNs / paraaortic LNs)
- Stage IV: distant spread
  - IV a : mucosa of bladder & / or rectum
  - IV b : distant spread (L B L B)

Inv.

- To confirm diagnosis :
  * Screening:TVS (if ET > 5mm in menopausal) / Hysteroscopy
  * Gold standard (confirmatory) : FC & endometrial biopsy
- To detect spread:
  * eg: chest x-ray / abdominal & pelvic US / bone scan
  * MRI for myometrial invasion & for LNs
- To assess fitness of pt for surgery: ECG & Lab testing

Ttt: * Early : Surgery * Late : Radiotherapy

- EH :
  depends on: type of EH, age of pt, desire for fertility
  options: PRG (DMPA / Mirena), Hysterectomy
- Stage I : TAH & BSO + cytology ± later radiotherapy
- Stage II : ttt as cancer Cx (Wertheim's operation)
- Stage III : radiotherapy → External beam = pelvis; Extended = pelvis + abdomen
- Stage IV : Palliative : pain relief / rediotherapy

NB : Unfit pt for surgery in stage I , II : Radiotherapy

Ut sarcoma : see fibroid , choriocarcinoma : see v. mole (obst)

Cancer Cx

Def: Tumour arising from ectocx (80%), endocx (20%) starting in reserve cells of TZ

Incidence: 2nd most common after endometrial Ca. / most preventable

Etiology :

- Predisposing F:
  - Sexuality: early / multiple / low socioeconomic / multipara / smoking
  - Viral: HPV (16 , 18) / HSV_2 / HIV
- Premalignant lesions: CIN 1 (LSIL) / CIN 2,3 (HSIL)

CIN 1: atypical cells involve lower $^1/_3$ of ep.
CIN 2: atypical cells involve lower $^1/_2$ (or $^2/_3$) of ep.
CIN 3: atypical cells involve all layers of ep.
} without invasion of BM

Pathology:

- Gross: Ulcer , Nodule , Friable mass (ectocx) / Barrel-shaped cx (endocx)
- Microscopy: Sq cell Ca (ectocx 80%) / Adenocarcinoma (endocx 20%)
- Grading :
  - G I → < 5% malignant undiff.cells (best prognosis)
  - G II → 5-50% malignant undiff.cells (intermediate prognosis)
  - G III → > 50% malignant undiff.cells (worst prognosis)
- Spread:
  - Direct: uterus / vagina / parametrium / uterosacral /bladder /rectum.
  - **Lymphatic:** 1ry : paracervical / obturator / ext iliac / int iliac
    2ry : common iliac / lat. sacral / para aortic
  - Blood : L B L B

Cl . picture :

- Symptoms → type of patient / Contact bleeding
- Signs → General: Signs of metastasis (anemia – jaundice – virchow's LNs…) / Uraemia
  - Abdominal: (N)
  - PV& bimanual : Nodule / Mass / Ulcer / vagina / normal sized uterus
  - **PR** : uterosacral & Parametrial involvement
- Staging (Clinical FIGO 2018)
  - Stage I (confined to cx) :
    - I a < 5mm depth of invasion
    - I b > 5mm depth of invasion (± uterus)
  - Stage II (local spread) :
    - II a: vagina (but not lower $^1/_3$)
    - II b: parametrium (but not to lat pelvic wall)
  - Stage III (more local ± LNs):
    - III a : vagina (+ lower $^1/_3$)
    - III b: parametrium till lat pelvic wall (Uraemia & Death)
    - III c : LNs
  - Stage IV (distant):
    - IV a: mucosa of bladder & rectum
    - IV b: distant spread L B L B



Inv.

- To confirm diagnosis :
  1) Pap smear (screening)
  2) Colposcopy
  3) Direct biopsy from lesion (Knife / Cone / LEEP)
- To detect spread: CXR / Abd & Pelvic US / Bone scan
  Ba enema / EUA / IVP / Cystoscopy / …
- To assess fitness of pt. for surgery : ECG / Lab tests

ttt

- 1ry prevention (HPV vaccine for teenage)
  only if unaffected by HPV
- 2ry prevention : screening program by pap smear for whole population / 3years in low risk ,
  annually in high risk
- CIN
  - **1** → Medical ttt & Pap smear after 3-6 months
    If refractory to medical ttt :
    Cryocautery / diathermy cautery / laser cautery
  - **2** → LEEP / LLETZ
  - **3** → Conization in young age (to preserve fertility)
    TAH in old age (not desiring fertility)
- Cancer Cx: - Early stage : Surgery
  - Late stage : Radiotherapy
  - Stage I a : TAH
  - Stage I b / II a : Wertheim's operation (radical hysterectomy)
  - Stage II b / III / IV: Radiotherapy / palliative

NB :

* Radiotherapy can be used in early stages giving same results as surgical ttt
* Unfit patient : Radiotherapy in all stages
* Ovaries may not be removed as it is not a hormone dependent cancer
* In recurrent cancer Cx : use opposite line of what was used before
* Ca. of cx stump → difficult surgery (adhesions)
  → no room for intracavitary radiation

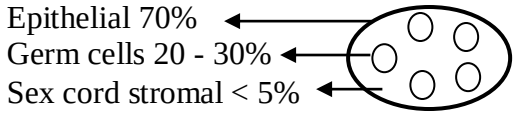

Benign ovarian tumours

(premalignant ovarian lesions)

Clinical classification: Cystic / Solid
Pathological classification: Benign / Malignant
Histological classification

	Epithelial tumours (post menopausal)				Germ cell tumours (child bearing)				Sex cord stromal			
	(Tubal ep)	(Endo Cx ep)	(End)	(urinary ep)	embryonic (endoderm , meso,ectoderm	extra embryonic villi	Yolk sac	undifferentiated germ cells & sex cord	Granulosa cells	Sertoli Leydig	Fibrous tissue	Theca cells
	Serous cystadenoma	Mucinous	Endometrioid (malignant from start)	Brenner	Dermoid (BCT)	Choriocarcinoma (malignant)	Yolk Sac (Endodermal sinus tumor) malignant	Gonadoblastoma	Granulosa cell tumour (E_2) (malignant)	Sertoli-leydig cell tumor (androblastoma)(malignant)	Fibroma	Thecoma
Gross – Size	Moderate	Huge		Small	Moderate			Small			Small-Moderate	Small
Gross – Site	bilateral in 50%	—		bilat in 15%	bilat in 15%			bilateral in 10%			bilat 10%	—
Gross – Consistency	Uni/multilocular Papillary (exo/endophytic)	Multilocular		Solid	Uniloc é thick capsule & long pedicle			Solid			Solid é long pedicle	Solid
Microscopy	Cuboidal ep (ciliated / Non)	Columnar ep é Goblet cells		Transitional ep	Endo / Ecto / Mesoderm			Undifferentiated Germ cells & Sex cord cells			Fibroblast	Theca interna cells
Characteristic features	Psammoma bodies (calcified cells)	Pseudo-myxoma peritonii ttt: chemotherapy (radioactive intraperitoneal colloid)		Coffee bean nuclei	hair/teeth /bone - mamilla - chemical Peritonitis			In dysgenetic gonads Y ch . as AIS			Meig's syndrome (+ ascites & Rt pl.effusion)	Post menopausal
Secretions	CA 125	CA 19-9		± E_2	Struma -ovarii (thyroxine)			——			——	E_2
Malignant transformation	30%	5%		——	< 1%			30% Dysgerminoma			——	——

Complications:

1) Torsion → gangrene (rare)
2) Hemorrhage → acute abdomen
3) Rupture → nothing (in serous)
   → chemical peritonitis (in dermoid)
   → pseudo-myxoma (in mucinous)
4) Infection → in puerperium
5) Incarceration → pressure symptoms
6) Malignant transformation

Cl.picture:

- symptoms:
  - asymptomatic
  - acute abdomen (pain)
  - pressure symptoms
  - mass (abdominal)
  - no bleeding (except functioning)
- signs
  - general : Cachexia in Mucinous
  - abd: swelling (insp. / palp. / percussion)
  - PV & Bimanual : Adnexal mass

Inv : US / CA 125 / ± Laparoscopy

Ttt:
- Ovarian cystectomy
- Oophorectomy (in huge mass)
- Panhysterectomy (TAH + BSO) (in old age)

(whether laparoscopic or laparotomy)

Malignant ovarian tumours

Def : malignant T. arising from surface ep , germ cells & sex cord stroma of the ovary.

Inc : 3rd most common malignancy of ♀ genital tract é worst prognosis , deaths from ovarian tumours > deaths from end. & cx cancer together

Et :
- Predisposing F : NG / induction of ovulation / white race / genetic (BRCA 1 & 2 , Lynch 2) , OCPs are protective as they - - ovulation
- Premalignant :Epithelial T(serous 30% & mucinous 5% cystadenoma) / Germ cells (BCT < 1% / Gonadoblastoma 30%)

	old age **Epithelial (> 70 %)**			Child bearing **Germ cell T (20 - 30 %)**					Extreme ages **Sex cord stromal T (< 5 %)**		**Metastatic**
Pathology	Serous cystadenocarcinoma	Mucinous	Endometriod	MCT	MST	Chorio ca	EST Yolk sac	Dysgerminoma	Granulosa cell T	Sertoli-Leydig (Androblastoma) Gynandroblastoma	Krükenberg Tumour
Gross	Tumor é solid & cystic parts é areas of hge & necrosis		Solid tumors with areas of hge & necrosis May be bilateral / fixed / with intact or ruptured capsule				Worst prog		Solid tumors with areas of hge & necrosis (Low grade malignancy)		Bilat. small solid nodules in DP (from pylorus,colon)
Microscopic / characteristics	Adenocarcinoma: Psammoma bodies	Pseudo - myxoma peritonii	é endometrial hyperplasia / ca	undiff embryonic cells (hair, teeth ,bone)	Cyto & Syncitio trophoblasts	Shiller Duval bodies		Lymphocytic infiltration so radiosensitive	Call Exner bodies (Rosette shape)	Androgenic cells	Signet ring cells
Sec	CA 125 / CA 19-9			____	HCG	AFP		LDH	E_2 / Inhibin	androgen	____

Grading :
- GI : < 5% malignant undiff. Cells (best prognosis)
- GII : 5 - 50 % malignant undiff. Cells (intermediate prognosis)
- GIII : > 50% malignant undiff. Cells (worst prognosis)

Spread :
- Direct: other ovary / uterus / fallopian tubes
- Lymphatic: para aortic LNs
- **Transcoelomic:** peritoneal seedling
- Blood : L B L B

Cl.pict:
- Symptoms : Type of pt / Asymptomatic (very late presentation) / GIT symptoms /mass /cachexia /NO bleeding except in functioning T
- Signs:
  - G: cachexia /anemia / jaundice / virchow's LNs / pl effusion
  - Abd: inspection / palpation / percussion (mass /ascites) peau d'orange
  - PV& Bimanual: Nodules in DP in krukenberg T / Adnexal masses
- Staging: FIGO surgical staging 2018
  - Stage I (confined to ovary) → Ia : one ovary , Ib : both ovaries; Ic : one or both é + ve peritoneal cytology
  - Stage II (local spread) → II a :Ut / FT , IIb : UB / colon / rectum
  - Stage III (more local ± LNs)
  - Stage IV (distant spread) → IVa :lung & pleural effusion; IVb: distant liver parynchyma / brain / bone

Inv :
- To confirm diagnosis
  - US: bilateral / solid / papillae /ascites (1 or more)
  - Doppler for vascularity / Tumour markers (CA 125) / Laparoscopy
  - RMI = US (1 or 3) × Menopause (1 or 3) × CA 125 → IF > 200 (High risk) (**1** if one criterion in US or **3** if more than one criterion in US)
- To detect spread: Ba meal / enema / upper & lower GI /CXR /CT abd & pelvis
- To assess fitness of pt for surgery : ECG / Labs /…

Ttt: Early : surgery / Late : surgery (debulking + chemotherapy)

Surgery (in **all** stages) ± chemotherapy (stages IIb → IV)

Exploratory laparotomy and TAH + BSO + omentectomy + peritoneal cytology + sampling LNs

NB:
* Debulking in late stages with fixed tumor (as above + removal of all tumor tissue > 1cm) :to decrease toxicity of post operative chemotherapy
* Stage Ia (germ cell T):can be unilat salpingo oophorectomy till completing her family

Functional ovarian cysts

Characteristics:

- Occurs in childbearing period
- Represents 25% of all adnexal masses
- Unilocular
- Ecolucent
- ≤ 7 cm
- Spontaneous regression is a rule

Types:

- Follicular cyst (commonest): Occurs in 1st half of cycle
- Corpus luteum cyst (2nd most common): Occurs in 2nd half of cycle , vascular & may cause acute pain

ttt: Spontaneous regression is the rule , if not , give cyclical COCPs monthly with US follow up

- Theca lutein cysts: as in V.mole & OHSS
- Endometriomas: if more than 4cm , laparoscopic cystectomy is needed. Otherwise medical ttt by continuous COPs
- Inflammatory cysts (TOC / TOA): ttt broad spectrum antibiotics & follow up for size by US , if no regression , then surgical drainage is needed
- Inclusion cysts: precursor of epithelial ovarian tumors

Pruritis vulvae

With vaginal discharge (80%)

- Candida albicans
- Trichomonas vaginalis

Without vaginal discharge (20%)

- Generalized disease
- Allergy
- Scabies , seborrhea
- Lichen sclerosus (postmenopausal) → ttt: corticosteroid cream (need follow up as it may be premalignant)
- Psychogenic
- Urinary or rectal incontinence

Vulval swellings

Cystic swellings

- Bartholin's duct → Cyst → ttt: marsupialization
  → Infected cyst → ttt: antibiotics
  → Abscess → ttt: drainage
- Inclusion dermoid → ttt: excision & biopsy
- Sebaceous → ttt: excision & biopsy
- Hydrocele of canal of Nuck → ttt: surgical excision (as hernia repair)
- Endometrioma → medical / surgical depending on size
- Hematoma → incision & drainage
- Varicosities → medical ttt: sclerosing material or ligation of the veins (if not pregnant)
- Hidradenitis suppurativa (it affects sweat glands in the axilla & mons pubis & causes very bad odor) → ttt : check for DM & local antibiotic cream
- Urethral caruncle (it causes dysuria & contact bleeding) → ttt :excision & cauterization

Solid swellings

- Lipoma - Fibroma - Nevus - Caruncle
- Papilloma / warts - Hydradenoma

ttt: excision & biopsy

Malignant tumours of vulva

Def: Malignant tumour arising from labia majora / minora / clitoris .

Inc: 4th most common tumour of ♀ genital tract after end , cx & ovaries

Etiology :

- Predisposing F: rare in young age (smoking / HPV infection) / old age
- Premalignant lesions:
  - VIN (1,2,3) : VIN 1 & 2 usually regress
  - Lichen sclerosus & Atrophicus (in old age)
  - Paget's disease (adenoca. in situ)(multifocal)

Pathology:

- Gross:
  - VIN : may appear (N)
  - Invasive: Nodule / Ulcer / Mass
- Mic:
  - VIN 1 , 2 , 3 / lichen sclerosus
  - VIN 1: atypical cells in lower 1/3 of ep
  - VIN 2: atypical cells lower 1/2 or 2/3 of ep
  - VIN 3: atypical cells in all ep.

  } without invasion of BM
  - Invasive:
    - Squamous cell ca.(commonest)
    - Paget's Adeno ca. / Melanoma / Basal cell ca (rare)
- Grading
  - G I : < 5% malignant undiff.cells (best prognosis)
  - G II: 5-50% malignant undiff.cells(intermediate prognosis)
  - G III : > 50% malignant undiff.cells (worst prognosis)
- Spread :
  - Direct: vagina / urethra / anus / perineum
  - **Lymphatic:** inguinal → femoral (LNs of Cloquet)
  - Blood : L B L B

Cl . picture :

- Symptoms
  - Type of pt
  - In VIN : Asymptomatic or Pruritis vulvae
  - In invasive : Pain / Mass / Ulcer / Contact bleeding (in addition to long standing pruritis valvae)
- Signs : *General: signs of metastasis
  - *Abdominal : rare
  - *Local:
    - In VIN :
      - raised rough skin / thin reddish epithelium
      - white hyperkeratinization (leukoplakia)
    - In invasive:
      - ulcerated / pigmented mass
      - labia majora mostly then minora then clitoris
      - ± enlarged inguinal LNs

Staging: (FIGO surgical 2009)

- Stage I : (confined to vulva)
  - * Ia: < 2cm width & < 1mm depth of invasion
  - * Ib: > 2cm width & > 1mm depth of invasion
- Stage II: (local spread) : to lower vagina / lower urethra / anus
- Stage III: (more local spread ± LNs) : Inguinofemoral LNs
- Stage IV: (distant spread)
  - * IVa: UB mucosa / Rectal mucosa
    All urethral mucosa / All vaginal mucosa
  - * IVb: L B L B

Investigations:

- To confirm diagnosis: Direct excisional biopsy
  If no apparent lesion: use colposcopy or paint é acetic acid & take biopsy from the white lesions
- To detect spread :
  - Colposcopy for cervix & vagina to detect associated involvement (as all are predisposed by HPV infection)
  - CXR / CT abdomen & pelvis
- To assess fitness of pt. for surgery : ECG & Lab tests

Treatment: Early stages: Surgery / Late stages : Radiotherapy

- In lichen sclerosus : corticosteroid ointment
- In VIN 1& 2 :
  - Symptomatic ttt to relieve pruritis for 3-6 months by topical steroids (as usually regress spontaneously)
  - In small lesions : excisional biopsy
  - In wide lesions (if not responding to topical steroids): skinning vulvectomy ± skin graft
- In VIN 3 , Stage Ia : excision
- Stage Ib : wide local excision
  ± inguinofemoral LNs sampling from separate incision
- Stage II → IV : external irradiation (radical vulvectomy is not done nowadays)

Malignant tumors of vagina

*Least common * 2ry far more common than 1ry

ttt : * in VaIN : 5- flurouracil vaginal cream for multifocal lesions *Surgery : Wertheim for early cases * Radiotherapy for most of cases

NB: Sarcoma Botryoides in prepubertal girls → Mass & Bleeding

Anatomy of female genital tract

	Gross	Histology	Arterial supply	Lymphatics	Applied anatomy
Vulva	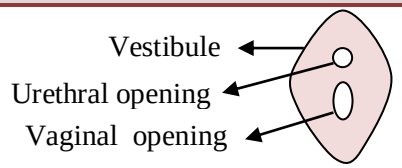 - **Mons veneris** (hairy pad of fat over SP) - **Clitoris:** midline erectile organ - **2 labia majora:** lat hairy é fat , sweat & sebaceous glands - **2 labia minora:** med é non hairy skin , no fat - **Hymen :** memb 2 cm deep to vulval opening - **Bartholin glands** on posterolat aspect of labia majora , duct opening in vestibule	- Stratified squamous epithelium (keratinized) -Transitional ep. For Bartholin gland	- Int pudendal artery (one of 2 terminal branches of ant division of IIA)	Superficial inguinal LNs	- **FGM** é 4 types with early(bleeding , infection) & late (loss of satisfaction, sexual problems & frigidity) complications. 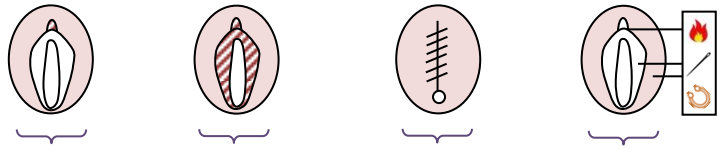 Type 1 Removal of clitoris Type 2 Removal of clitoris & labia minora Type 3 Removal of clitoris, labia minora & labia majora Type 4 Burning or pricking or piercing - **Clitoridal cyst :** post circumcision - **Cryptomenorrhea**:in imperforate hymen - **Bartholin cyst** : in obstructed duct
Vagina	- **Fibromuscular potential tube é rugae** - **7 – 9 cm anterior wall related to** UB & urethra - **10 – 11 cm posterior wall related to** DP , rectum , perineal body - **Lat borders related to :** 1) ureter 1cm 2) cardinal (Mackenrodt's) lig 3) levator ani (deep perineal ms) 4) bulbocavernous (superficial perineal ms)	- Non keratinized stratified squamous epithelium	- Vaginal artery from IIA	**Upper third :** as Cx **Lower third :** to Inguinal LNs **Middle third :** II LNs	- **Septum :** longitudinal / transverse - **Ant. wall prolapse:** Cystocele , urethrocele - **Post wall prolapse:** Enterocele , rectocele , deficient perineum - **Support :** Mackenrodt's lig / Uterosacral lig / Pubocervical lig - **Episiotomy :** cut through post or posterolat vag wall - **Post colpotomy or culdocentesis :** for drainage of pelvic abscess in DP - **US guided oocyte retrieval** through post colpotomy - **Ureter may be injuried at** lat fornix while clamping the vag angles in TAH - **Pudendal n block :**done at level of ischial spines

	Gross	Histology	Arterial supply	Lymphatics	Applied anatomy
Uterus	**- Pear shape 1× 2× 3 inches** 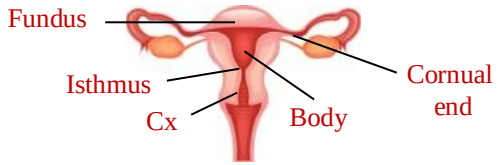 **- AVF (85%) or RVF (15 %)** **- Ant :** UB / Pubocervical lig **- Post :** DP / Uterosacral lig **- Lat:** Broad lig & inside it : ├ Fallopian tubes ├ Remnants of Wolffian ducts ├ Uterine artery └ Ureter & Mackenrodt's lig	**- Endometrium** (modified mucosa é glands & stroma) **- Myometrium of body of ut** formed of 3 ms layers : ├ Outer longitudinal ├ Middle criss-cross └ Iner circular While Cx is formed of outer & inner layers only **- Perimetrium :** peritoneal adherent over the body but loose over Cx	- Uterine a (tortuous course on lat borders) from ant division of IIA - Anastomosis at cornu with ovarian a	**- Fundus :** paraaortic LNs **- Cornu :** superficial inguinal LNs **- Body :** II LNs **- Cx :** 1ry → paracervical parametrial , obturator , II LNs & EILNs 2ry → CI LNs , Lat. sacral & Paraaortic LNs	- **Ut prolapse :** 1st , 2nd & 3rd degrees - **Ut. support :** Mackenrodt's lig / Uterosacral lig / Pubocervical lig (as vagina) - **MRKH Syndrome** in case of 1ry amenorrhea é presence of secondary sexual characters - **Cong anomalies :** as septate / bicornuate / didelphys with RPL , PTL - **Cx is sensitive only to dilatation** (Cx dilatation should be done under anesthesia)
Fallopian tubes	**2 Tortuous tubes 10cm in length** 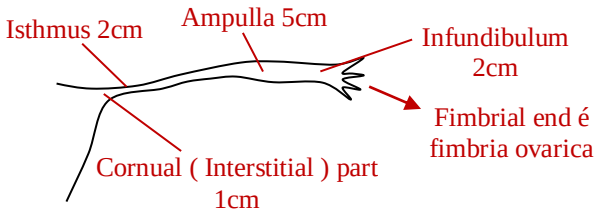 **- Runs in upper part of broad lig** **- For ovum pick up , transport & nutrition for ovum & sperm**	**- Mucosa (endosalpinx)** cubical or columnar partially ciliated **- Musculosa:** 2 ms layers (outer long & inner circular) **- Serosa** or loose peritoneal covering	- Branches from uterine & ovarian arteries	Paraaortic LNs	- **Tubal point** (½ inch above mid inguinal point) in cases of pain , PID , ectopic . - **Commonest site for ectopic pregnancy (ampullary part)** - **Hydrosalpinx & pyosalpinx** (ch . PID) - **Commonest permanent method of contraception** (tubal ligation) - **Tubal disconnection (TD)** in cases of hydrosalpinx prior to IVF
Ovaries	**- Almond shape 1×2×3cm** **- On ureter & bifurcation of II vessels** **- Not covered by peritoneum** **- Corrugated surface** due to repeated stigmata of ovulation **- Attached to ut by ovarian ligament , to lat pelvic wall by infundibulopelvic lig , to the back of the BL by mesovarium**	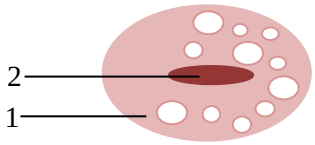 **1) Outer cortex** é follicles **2) Inner medulla** **3) Hilum** (site of attachment of mesovarium)	- Ovarian arteries from abdominal aorta **NB :** - Rt ov. v → IVC - Lt ov. v → Lt Renal v	Paraaortic LNs	- **In ovariotomy :** 6 clamps needed 2 on each pedicle (ovarian , infundibulopelvic & mesovarium) ligaments. - **Streak gonads** in absence of sex cord cells covering the germ cells , forming Turner syndrome (45 XO) - **Responsible for** 1) ova production (ie ovulation) 2) hormone formation (E_2 , PRG) by granulose & theca cells of oocytes

Ureter

Gross :
25 cm in length , retroperitoneal
- Enters pelvis in ovarian fossa above the bifurcation of CIA
- Runs downwards in the base of BL below uterine artery .
- crosses forward related to lateral vaginal wall to enter trigone of the urinary bladder.

Histology :
Lined by transitional epithelium

Arterial supply :
Branches from IIA , uterine artery , Inf. vesical artery , vaginal artery

Lymphatic drainage :
Iliac LNs

Applied anatomy :
- Injury at
  - Clamping infundibulopelvic ligament
  - Clamping Uterine artery 1 cm lateral to Cx
  - Clamping Vaginal angles
- Avascular necrosis in meticulous dissection → uretro vaginal fistula , symptoms manifest few days post – operatively

Pelvic floor

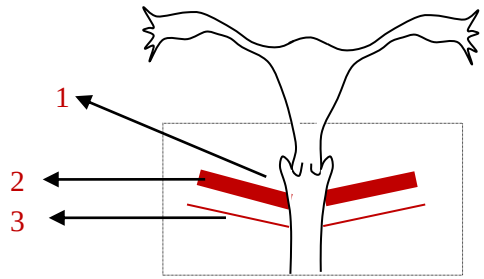

1) Peritoneum of DP with extra peritoneal fat & cellular tissue
2) Levator ani ms (deep perineal ms) , (urogenital diaphragm) with :
   - ischiococcygeus
   - ileococcygeus
   - pubococcygeus
     - → pubourethralis (decussation around urethra)
     - → pubovaginalis (decussation of ms fibers around vagina)
     - → Puborectalis (decussation of ms fibers around rectum)
3) Perineal ms (superficial) (ischiocavernosus , bulbocavernosus & transverse perineii ms) Fat & skin of vulva

* The midline is pierced by urethra , vagina & anal canal

Perineum

Area of 5 cm between vaginal orifice & anus covered by less hairy skin & less SC tissue

Perineal body :
- a fibromuscular pyramidal structure between posterior vaginal wall (lower $^1/_3$) & anterior wall of anal canal

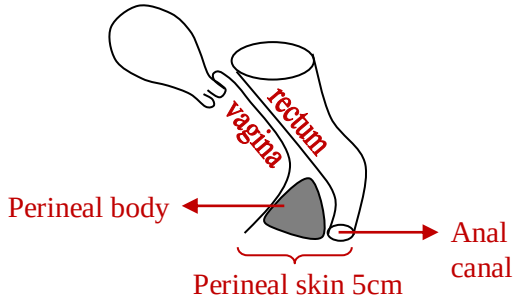

- It is the point of insertion of superficial perineal ms & above it passes the levator ani muscle

Applied anatomy :
If defective , ie: deficient perineum that causes sexual problem & is treated by posterior colpoperineorrhaphy .

Uterine & cervical ligaments

Support (to prevent prolapse)

1) Lateral cervical = Mackenrodt's ligament = Cardinal ligament (strongest)
Fanning from uterus to lateral pelvic wall

2) Uterosacral (posterior) :
From uterus & Cx to periosteum of sacrum

3) Pubocervical (anterior) :
From Cx to back of SP

Protect important structures

1) Broad ligament: (lateral from uterus to lateral pelvic wall) , Contents :
- Fallopian tube (FT)
- Parametrial lymphatics & LNs , S & PS nerves
- Remnants of Wolffian duct:
  - → Hydatid cyst of Morgagni at fimbrial end of FT
  - → Epoophoron
  - → Paroophoron
  - → Gartner duct : lateral to tube & downward to anterolateral wall of vagina
  - → Paraovarian cyst : in case of cystic dilatation of remnants of Wolffian duct
- Uterine vessels
- Ureter

2) Ovarian ligament (Med between uterus and ovary) : Protects ovarian vessels

3) Infundibulopelvic ligament (Lat between ovary & lateral pelvic wall): Protects ovarian vessels

NB : Round ligament :

Gubernaculum that attaches cornual end of of uterus to labia majora passing through inguinal canal , it protects Sampson artery & keeps AVF position of uterus.

Sexual differentiation

Gonadal differentiation (Genital ridge)

XY → TDF

XX → NO TDF

Gonads :

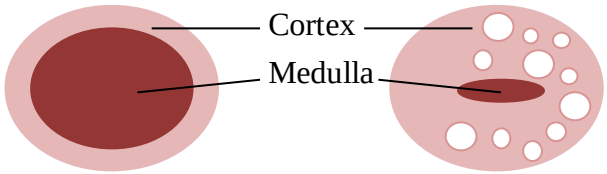

= testicles = ovaries

Germ cells :

Spermatocytes — oocytes

Sex cord cells :

* Sertoli cells W secrete MDIF — Granulosa cells, Theca cells

* Leydig cells → atrophy → Hilar cells

Internal organ differentiation (Wolffian duct / Mullerian duct)

XY → Testosterone → growth of Wolffian duct

XX → NO TDF / NO testosterone
∴ atrophy of Wolffian duct

XX → NO Sertoli cells / NO MDIF
∴ growth of Mullerian duct (paramesonephric duct)

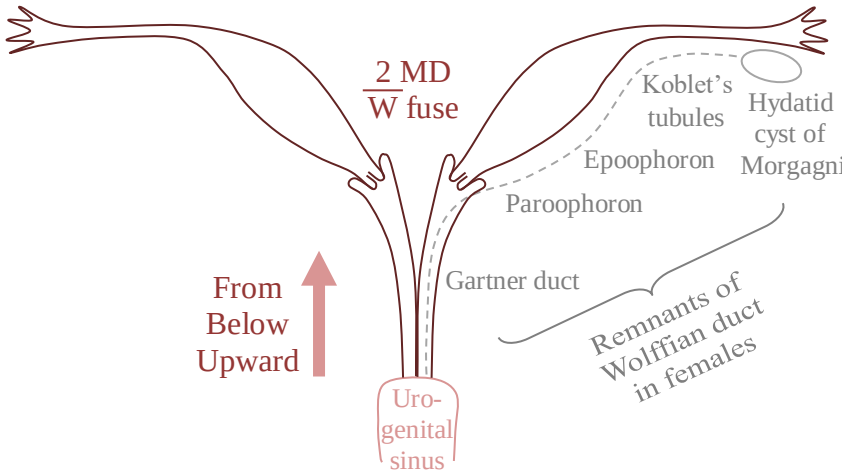

External organ differentiation (Urogenital sinus)

XY XX

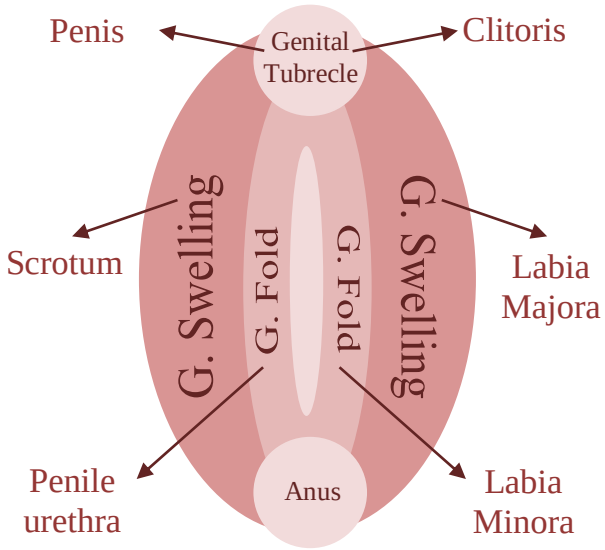

Anomalies of Ovary

* Aplasia
* Hypoplasia
* Acccessory
* Streak gonads (dysgenetic) as in Turner Syndrome

Anomalies of

* **FT :** Aplasia / hypo / accessory osteum / diverticulum
* **Uterus :** Aplasia / hypo / septate / bicornuate / didelphys / unicornuate / arcuate / rudimentary horn
* **Cx:** Aplasia / atresia / incompetent
* **Vagina :** Aplasia / hypo / transverse septum / longitudinal septum

Anomalies of Hymen

* Imperforate hymen:
  Failure of canalization of lower part of urogenital sinus

Endoscopy in Gynecology

	Laparoscopy	Hysteroscopy
	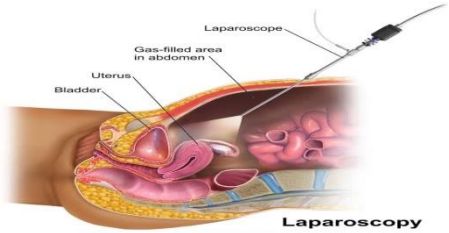 Laparoscopy	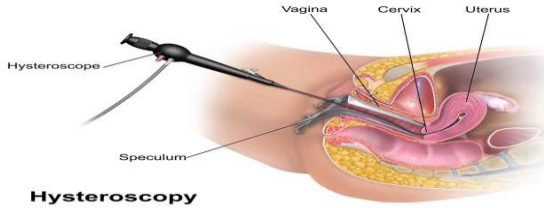 Hysteroscopy
Def	Introduction of an optic lens through <u>umbilicus</u> to visualize peritoneal cavity & pelvic organs	Introduction of an optic lens through <u>cervix</u> to visualize the uterine cavity
Indications	* Diagnostic : → Unexplained infertility → Ch. Pelvic pain / Endometriosis → Cong anomalies of uterus * Operative : → Ovarian (cystectomy / oophorectomy) → Tubal (ectopic / ligation / disconnection) → Uterus (myomectomy / hysterectomy) → Endometriosis : ablation of foci → Adhesiolysis	* Diagnostic: → Infertility → RPL / Ut septum → AUB / Polyp * Operative : → Polypectomy → Septum resection → Myomectomy (submucous) → Division of of IU synechia → Tubal occlusion
Technique	- GA - Trendlenberg position (head down) - Veress needle at umbilicus & inflate 3-5 liters CO_2 é pressure 15 mmHg - Introduce lens , light source , camera & manipulator - MB dye may be injected through Cx to visualize patency of FT - Irrigation , evacuation at the end of procedure	- NO anesthesia (in office procedure) , Local or GA in operative procedures - Dorsal lithotomy position - Dilatation of Cx in operative procedures - Uterine distension by CO_2 , glycine (is a must in op procedures) - Lens , light source ,camera are introduced - Removal of instruments at the end of procedure
Comp.	- Anesthesia complications / Cutaneous surgical emphysema - Electrosurgical complications to bowel , uterus , nerves - Injury to vessel , intestine , bladder / Infection - Neurological injury in poor patient positioning	- Fluid overload (commonest complication) - Electrolyte imbalance - Anesthesia complications (if used)
Adv.	- Less hospital stay , early return to work - Minimal adhesions - Early recovery , less GIT complications (ileus , gastric dilatation) - Better cosmetic - Rare wound complications (dehisence & infection)	- Can be done without anesthesia as an office procedure (no dilatation for diagnosis) - Proper visualization of uterine cavity

Operative Gynecology

	Sounding	Dilatation	Curettage
	NO ANESTHESIA	**ANESTHESIA NEEDED**	
	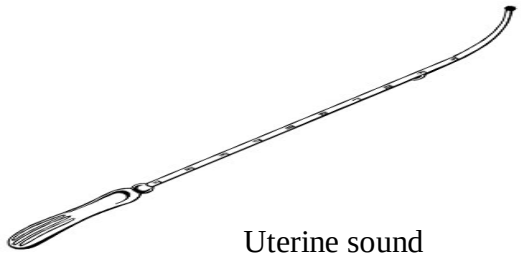 Uterine sound		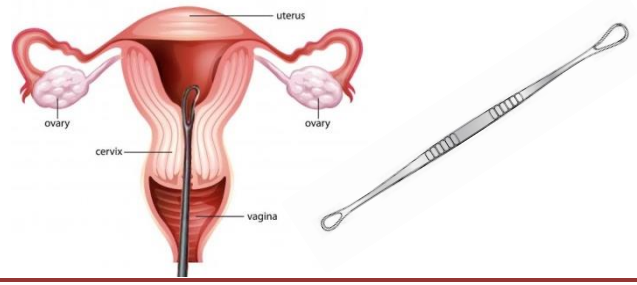
Uses	1) Measure <u>length</u> of uterine cavity in IUD insertion , before D&C 2) Diagnose <u>direction</u> of Ut (AVF or RVF) 3) Diagnose supravaginal elongation of the Cx in prolapse 4) Diagnose ut hypoplasia Cx : body , (N) → 1 : 2 5) Diagnose Cx stenosis 6) ttt of pyometra (as mere sounding → drainage)	*<u>* Dilatation alone in</u> :* - Spasmodic dysmenorrhea - Cx stenosis - Drainage of pyometra or hematometra *<u>* Dilatation preliminary to another operation:</u>* - Op on Cx as Fothergill - Op on Ut as curettage , polypectomy	*<u>* Diagnostic :</u>* - PEB to detect ovulation - In AUB & DUB to detect endometrial pattern & type - Diagnose malignancy of Ut & Cx - Diagnose diseases of Endometrium as TB endometritis *<u>* Theraputic :</u>* - Postabortive - Endometrial , Cx polypi - DUB
Comp.	- Perforation - Infection - Bleeding - Abortion in case of pregnancy	- Anesthesia complications - Ut perforation - Cx laceration → incompetent isthmus - Infection - Shock in case of inadequate anesthesia	- Anesthesia complications - Dilatation complications - Asherman Syndrome

<u>NB:</u> In case of uterine perforation :
- Stop procedure
- Give antibiotics
- Observe vital signs → If normal : Discharge the patient
  → If deteriorates or intestinal contents appear through Cx : Exploratory laparotomy and proceed.

OBSTETRICS

Abortion

BLEEDING

Definition : Interruption of pregnancy before viability (< 24 wks) whether fetus is living or dead

Incidence : 15%

Etiology :

* Spontaneous abortion → Chromosomal anomalies
* RPL —1st trimester→ APS / LPD / ut cavity anomalies (ttt of cause)
* RPL —2nd trimester→ Cx incompetence (painless / living fetus / é PROM) / Inv: during preg : us for cx lengh < **2.5cm**
  inbetween preg : HSG (funneling)

ttt: during pregnancy : cx cerclage at 12-13 wks usually Mc Donald's , rarely Shirodkar or abd)

Types			Threatened منذر	Inevitable حتمي	Incomplete غير مكتمل	Complete مكتمل	Missed منسي	Septic
Cl.picture	S	Bleeding	+	++++	++	±	— (Brownish discharge)	Foul vag discharge
		Pain	+	++++	++	—	—	Dull aching pain
	S	Gen	—	± SHOCK	± Shock	—	— (rarely DIC)	Fever / dehydration
		Abd	= amenorrhea	= amenorrhea	< amenorrhea	(N) sized uterus	< amenorrhea	Tender ut
		PV(Cx)	**Closed**	**Open**	**Open**	**Closed**	**Closed**	Closed or Open
Inv		US	Living fetus	Living or dead	Remnants	Empty ut	Dead fetus (anembryonic sac = blighted ovum)	Usually remnants
		β-HCG	(N)	Not done in emergency	↓↓↓	—	↓↓	↓↓ ++TLC/ CRP /?ESR
Ttt			* Rest * PRG supplement	* Correct shock * Termination (SE)	* SE	—	* Termination → <12wks (no bones) ∴ SE ; >12wks (∴ bones) = medical PGs If failed medical ∴ hysterotomy	* Broad spectrum antibiotics * Ecbolics Then SE

Give anti-D in Rh-ve ladies

Ectopic pregnancy

PAIN 😖

Def : pregnancy outside the normal lining of uterine cavity.

Inc : 1.5% (> 95% tubal ectopic)

Et: abnormalities in tube → inflammation / adhesions
→ PRG only contraception / IUD

Pathology :

- Tubal : tubal distension / tubal abortion (tubal mole) / tubal rupture & IPHge
- Uterine : only decidua (absence of villi = Arias stella reaction)

Cl.picture:

- Symptoms : → **PAIN** , mild vaginal bleeding
  → May present é syncopal attacks / shock
- Signs: → Gen : ± shock
  → Abd : tenderness at tubal point / "Cullen sign" in case of long standing IPHge
  → PV : Cx motion tenderness (jumping sign = Frog sign) / adnexal fullness/ ut is bulky but < amenorrhea

Inv :

- US : empty ut & adnexal fullness when βHCG > discrimination zone → TVS = 1500
  → TAS = 6500
- βHCG : increase but < 75% after 48 hrs (doubling time)
- ± laparoscopy : If done then proceed to ttt via laparoscopy

Ttt:

- Anti shock measures
- Medical ttt: (MTX 1mg / kg BW **IM**) if :
  * pt vitally stable / undisturbed ectopic
  * GS < 3.5 cm
  * βHCG < 6000
  * no fetal pulsations
  * liver & kidney functions normal

  FU by β HCG at D_4 / D_7 it should ↓ by ≥ 15 %
- Surgical : → Laparoscopy (if vitally stable) : salpingostomy/salpingectomy
  → Open laparotomy (if vitally unstable) : salpingectomy
- Anti-D if pt is Rh-ve

*** Other rare types of ectopic :**
-in Rudimentary horn
-in ovaries
-in cervix
-over CS scar
-abdominal pregnancy
Ttt: → medical (MTX) : if fulfilling criteria
Or → surgical removal

Inc: 0.15%

GTDs (Abnormal proliferation of villi)

Differentiated (With villi)

V.Mole (benign)

Et:
- Complete mole : sperm + Anucleated ovum → 46 XX (paternal)
  23X — 23X
- Partial mole : 2sperms + ovum → 69XXX/ XXY / XYY
  23X /23Y 23X

In extreme Ages , ↓ fat diet , Race (Asia)

Pathology:
- **Uterus**
  - Gross: ut enlarged , soft , filled é grape like vesicles é no fetus / sac or liquor (or presence in partial mole)
  - Mic: (same in invasive mole too) : differentiated villi
- **Ovaries:** OHSS like (HCG theca lutein cysts)

Clinical picture:
- Symptoms: vaginal bleeding / prune juice discharge; Lower abdominal pain / enlargement
- Signs: Gen : anemia / thyrotoxic (TSH like) / ↑BP (HCG effect)
  - Abd : Ut > period of amenorrhea /soft Doughy ut
  - PV& bimanual : soft Cx / vesicles / full adnexa
- Complications: Invasive mole 20% / Chorioca. 5%

Inv:
- To confirm diagnosis : US: snow storm appearance / Ov theca lutein cysts
- For follow up : β- HCG : very high level
- To detect complications : CXR / MRI pelvis

Ttt:
- Suction Evacuation (é ecbolics & antibiotics)
- FU é β- HCG weekly till –ve then monthly for 1 year (use COCPs as contraception)

NB:
- In old age , no desire for fertility = TAH
- If plateau or rising HCG : use MTX
- Anti - D in partial mole in Rh –ve non sensitized pts

Undifferentiated (NO villi) (metastatic) GTT (GTN)

Invasive Mole (locally m) Chorio Ca. Placental site T. Epithelioid T.

Low risk	High risk
* Age < 40 * < 4 months from preg.	* Age > 40 * > 4 months from preg.
* < 100.000 βHCG * < 6 cm theaca lutein	* > 100.000 βHCG * > 6 cm theaca lutein
* No liver or brain M. * No prev chemo	* Liver or brain M. * Previous chemo
ttt: Single agent chemotherapy (MTX) good prognosis	ttt: Combined chemotherapy (EMA - CO) bad prognosis

Pathology:
- Gross: enlarged ut é friable tissues é areas of hge &necrosis
- Mic: undifferentiated villi
- Grading :
  - G1: < 5% malignant undiff.cells
  - G2: 5-50% malignant undiff.cells
  - G3: > 50% malignant undiff.cells
- Spread:
  - Direct : to surrounding
  - Lymphatic : very rare
  - **Blood** : Lung B L B

Cl.pict
- Ⓢ: vaginal bleeding é H/O of pregnancy event
- Ⓢ
  - Gen : anemia / metastasis
  - Abdominal : enlarged soft uterus / metastasis
  - PV& bimanual : enlarged ut / adnexal fullness /vag.masses
- FIGO staging
  - Stage I : confined to uterus
  - Stage II : local spread (ut / ov / vagina)
  - Stage III : + lungs
  - Stage IV : distant other than lung

Inv:
- To confirm diagnosis : **HCG** / US
- To detect spread : Chest X-ray / MRI pelvis
- To assess fitness of pt for ttt: LFTs / KFTs

Ttt:
- Low risk: single agent chemo (MTX) é FU 1year after -ve HCG
- High risk: combined chemo (EMA-CO) é FU 1year after -ve HCG

NB: Hysterectomy if:
- old age (no desire for fertility)
- or chemoresistant (placental site & Epithelioid)
- or recurence after chemo

Female bony Pelvis

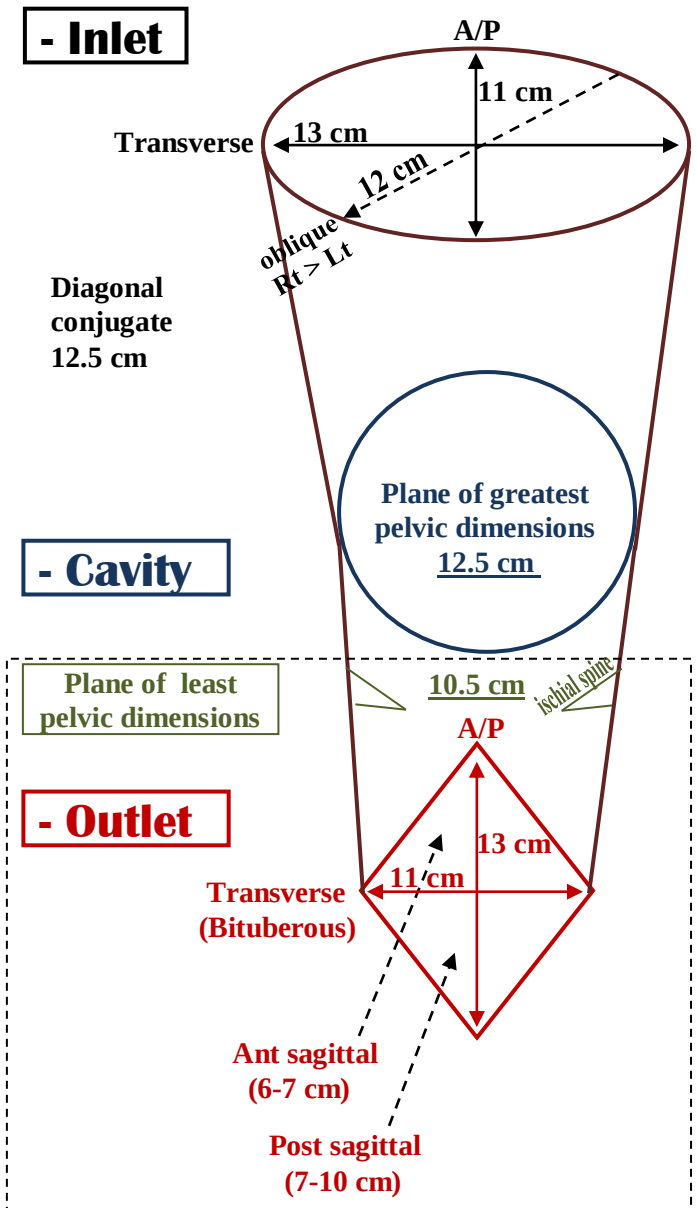

Anatomy of Fetal skull

Engaging diameters

A /P engaging diameters:

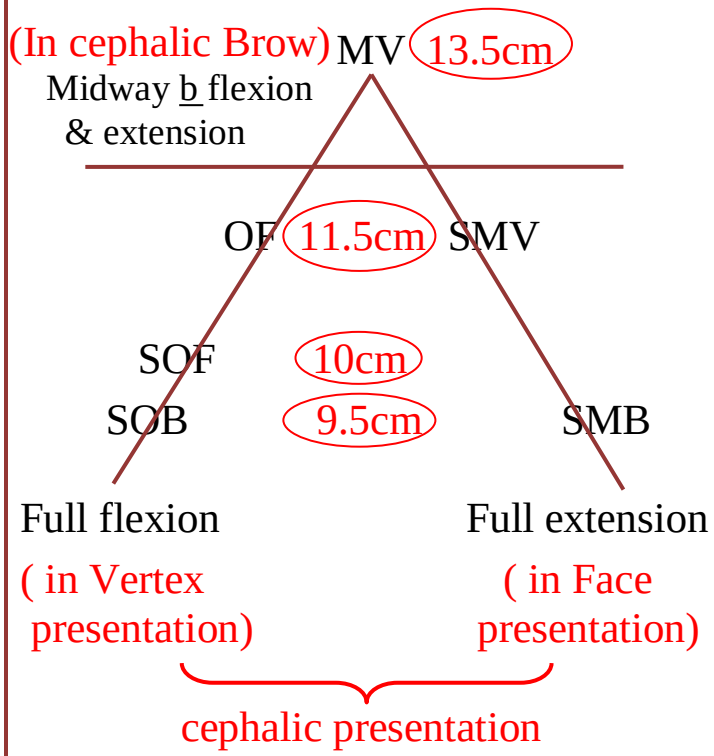

Transverse engaging diameters:

- BPD (largest) = 9.5 cm
- Supra parietal / Sub parietal = 9 cm (in asynclitism)
- BTD = 8 cm
- BMD = 7.5 cm

Terminologies

Engagement: passage of widest transverse diameter of the presenting part (eg :BPD) through plane of pelvic inlet.

Lie: (longitudinal / transverse)

Attitude: fetal parts (flexed / extended)

Presentation: 1st felt on PV

- Cephalic 96%
  - Vertex 95% → occiput
  - Face 0.5% → chin (mentum)
  - Brow 0.1% → no engagement
- Breech 3.5% → sacrum
- Shoulder 0.5% → scapula

Denominator : Bony landmark of the presenting part

Asynclitism (tilt) : (eg : ant asynclitism = post parietal bone presentation , when sagittal suture is toward ant.)

Position: Relation of fetal denominator to the right / left & ant /post of the mother

Station: **0** when occiput is at the level of ischial spines in vertex presentation = Engagement

Leopold manoeuver: (F.level / F.grip / UG / 1st & 2nd PG)

Naegle's formula :

LMP —(+ 7days + 9months)→ EDD

Obstetric code:

F	P	A	L
> 36 wks	24-36	< 24 wks	now

Normal labor

Def : passage of single / living / cephalic / vertex / term / through birth canal / éout interference / é no complications (maternal & fetal) / éin 4 – 24 hrs

Et (Theories): ++PGs / ++ fetal cortisol / ++ ut distension / -- PRG / -- pl oxytocinase

Stages	1st stage (Latent < 4 cm / Active > 4 cm)	2nd stage	3rd stage
Def	Cervical changes (effacement & dilatation)	Fetal delivery	Placental delivery
Duration	12 -18hrs in PG 6 - 8hrs in MG	2hrs in PG 1hr in MG	30 min in both
Mechanism	Ut contractions (true labor pains) → Cx effacement & dilatation 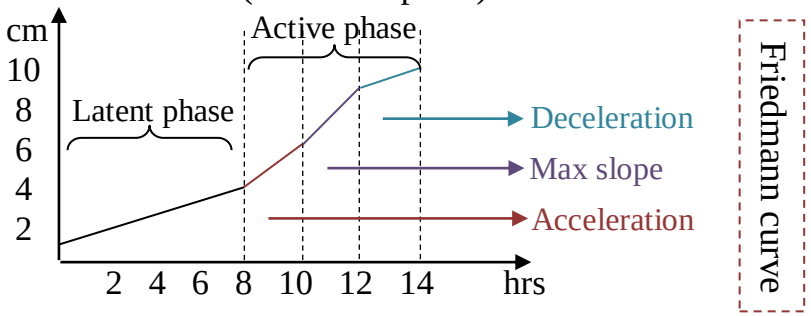	- Descent - Engagement - ↑ Flexion - Int rotation - **Extension** - Restitusion - Ext. rotation - Expulsion } may occur in late pregnancy	- Placental separation, detected through : * Gush of blood * Elongation of cord * Suprapubic bulge - Placental expulsion: * Schultze * Duncan
Aim	To get strong efficient (3 cont/ 10 min / each lasting 1 min / é intensity 40-60 mmHg) to cause dilatation of **1 cm/hr in PG** Or **1.5 cm/hr in MG**	To allow extension after crowning to distend vulva by SOF (↓↓ perineal tears)	To do active management through use of ecbolics To ↓ bleeding (500cc)
Management	- H/O: medical / surgical / obstetrics F P A L LMP, EDD,GA - Exam : → Gen : vital signs → Abd : Leopold maneuvers / FHS → PV : presentation / position / Cx dilatation / effacement / station / ROM …. - Nutrition ? IV fluids / Analgesics / Enema - Partogram : for FU progress of labor 	- Lithotomy / sterilization / towling - Instruct her to bear down during contractions& relax inbetween - Ritgen maneuver (perineal support) to allow extension after crowning	- Wait for signs of separation - Brandt – Andrews maneuver - Explore placenta & memb after their delivery for completion - Explore birth canal for tears
NB:	External CTG **ONLY** in high risk pregnancy (maternal / fetal / obstetric)	Episiotomy **ONLY** if indicated	- 2hrs later observe for complications (4th stage) - Give Anti-D in Rh –ve

Abnormal labor

Def : labor lasting < 4hrs or > 24 hrs due to abnormalities in **passages (pelvis)** / **passenger (fetus)** / **power(ut. contractions)**

Types:

1) Precipitate labor

Def : < 4 hrs for 1st , 2nd & 3rd stages

Et : multipara / small fetus / roomy pelvis / strong contractions

Comp: * Maternal: lacerations of Cx / P.sepsis / PPHge * Fetal : fetal birth injuries

Ttt: If seen before delivery : epidural to slow down progress / Perineal support in 2nd stage

Explore birth canal for lacerations / antibiotics prophylaxis /neonatal exam for birth injury

2) Prolonged labor

Def : delay in progress <1cm /hr in PG or < 1.5cm /hr in MG

"While arrest of labor : no progress at all (in Cx changes or fetal descent) for **1 hr in MG** or **2 hrs in PG** in the presence of strong efficient ut contractions whether in active 1st or 2nd stages"

NB: Double this time if epidural is used

Et : CPD

Hypo / Hypertonic ut. Inertia

Comp: * Maternal: exhaustion / PPHge / P.sepsis * Fetal : distress / asphyxia

Ttt : If CPD : CS

If hypotonic : amniotomy / oxytocin augmentation

If hypertonic : stop oxytocin / IV fluids / epidural

NB: In 2nd stage arrest , assess whether it is due to exhaustion (∴ use instrumental delivery if engaged) or obstruction (∴ do CS)

3) Obstructed labor

Def : arrest of 2nd stage (although presence of strong uterine contractions) due to CPD.

Cl. picture : * Gen : dehydration / exhaustion

* Abd : pathological retraction ring (Bandl's ring) DD from contraction ring

Pathological retraction ring (Bandl's ring)	Constriction / contraction ring
* Between UUS & LUS	* Spasm of circular smooth ms fibers
* Moves upward	* Any site
* Seen abdominal & felt vag	* Felt vag only
* + Fetal distress / severe maternal exhaustion	* No maternal or fetal distress
* Relieved by CS	* Ms relaxation / anasthesia

* PV : caput / dry vagina / oedematous / fully dilated Cx / station -2 -1

Comp : * Maternal : rupture ut / necrotic VVF / PPHge / P. sepsis * Fetal : distress / asphyxia

Ttt: delivery by **CS** (NO instrumental as head is NOT engaged)

NB : PG responds to obstruction by atony while MG responds to obstruction by rupture uterus

4) Cx dystocia

Def : rigid Cx that doesn't dilate or efface in the presence of efficient ut .contractions
Et : spasm / scarred Cx
Ttt: spasmolytic / CS (to avoid annular detachment of Cx or rupture ut)

5) Shoulder dystocia

Def : Failure of delivery of shoulder after head delivery due to impaction of anterior shoulder at the symphysis pubis
Et : fetal macrosomia
Cl.picture: Turtle sign
ttt: → Prevention by CS when indicated
→ Actual :
* Mc Roberts (hyperflexion of maternal thigh)
* Wood Cork Screw * Post. Shoulder delivery
* Symphysiotomy * Zavenilli Maneuver

CPD

Def : one or more of the pelvic diameters is decreased so as to interfere é normal vag delivery

Et : diseases or trauma to spine , femur or pelvic bones of the mother

Cl.picture :
* H/O
* Exam → Gen: for gait / height
→ Abd : pelvimetry
→ PV : Internal pelvimetry & CPD tests:
1) Pinard : NO PV
2) Muller-Kerr : é PV

Ttt: → If no CPD : allow VD
→ Moderate CPD (1st degree) : trial of labor
for undetermined factors (moulding of head / yielding of pelvis / strong ut cont.)
→ Severe CPD (2nd degree): CS

Malposition & Malpresentations

	Occipito - posterior	Face
Def	Longitudinal lie in which head is flexed & occiput posterior (occiput is denominator) {It's a malposition & not a malpresentation}	Longitudinal lie in which head is fully extended (mentum is denominator)
Inc	20% at time of labor	1/500
Position	ROP : most common occupying wider Right oblique diameter	LMA : most common as it results from extension of ROP
Et	Gen: CPD / Fetal anomalies / MFG / ... Specific : Android / Anthropoid pelvis	Gen : CPD / Pendulous abdomen / … Specific : Anencephaly
Mechanism	* 90% : long ant rotation → DOA & delivery by **extension** * 6% : short post rotation → DOP (face to pubis) & delivery by **flexion** * 4% : NO rotation (deep transverse arrest or persistent oblique OP) → **obstructed**	* MA : ant rotation → DMA & delivery by **flexion** * MP → ⅔ long ant rotation to MA & delivery by **flexion** → ⅓ no rotation or post rotation to DMP : **obstructed**
Comp.	Maternal : Prolonged labor / PROM / PPHge / Puerperal sepsis Fetal : Distress / Asphyxia / Birth injuries / Instrumental delivery / Comp of associated anomalies	
Management	Pregnancy : Leopold : as OA : FL (same) / FG (buttocks) / UG (back Rt) / 1st Pelvic Grip (done : delayed engagement) / 2nd Pelvic Grip (not done) Auscultation : FHS below umbilicus / US	
	Labor: PV : occiput 1st stage : watchful expectancy for ***factors that favor long anterior rotation*** : ***(Roomy pelvis (no CPD) / Good pelvic floor muscles / Strong uterine contractions / Adequate liquor)***	PV : chin (Tumefaction)
	*90%: as OA (assess factors for long ant rotation) *6% : Face to pubis (distending diameter OF 11.5 cm) ∴ do episiotomy *4% → Kielland for rotation &extraction → Ventouse for rotation &extraction } If no CPD or → **Safer CS**	*MA : delayed engagement + episiotomy (SMV 11.5 cm) *MP → ⅔ factors for long ant rotation (as MA) → ⅓ → Forceps delivery (not done) → NEVER ventouse (CI) or → **Safer CS**

Brow

Def: Head is midway between flexion & extension **Inc :** 1/2000 **Et :** general causes

Mechanism : → Transient brow :delivery as OP or MA
→ Persistent brow (MV = 13.5 cm) : **Obstructed**

Management : → Transient brow : manage accordingly
→ Persistent brow : CS

Breech presentation

Def : It is a longitudinal lie in which buttocks with feet (complete) / buttocks only (frank) / feet (footling) / knee are the presenting part.

Incidence: 3.5% at full term / 25% at 28 wks

Position: LSA

Etiology:
- General : contracted pelvis / ut septum / fibroid / pl.previa / MFG
- Specific: Hydrocephalus (in full term) , Prematurity

Types:
- Complete (MG)
- Frank (PG)
- Footling / knee …

Mechanism :

for
- Buttocks (Descent / Eng (BTD 9.5cm) / Int rotation / ant buttock hinge below SP, post buttock deliver 1st by **Lat Flexion of spine**)
- Shoulders (Descent / Eng (BAD 12 cm) / Int rotation / post shoulder deliver 1st by **Lat Flexion of spine**)
- After coming head (Descent /Eng (BPD 9.5) / Int rotation(opposite direction as it enters pelvis in opposite axis)/ delivery by **Flexion**)

Complications:

- Maternal : 4 Ps (Prolonged labor / PROM / PPHge / Puerperal sepsis)
- Fetal
  - Retained after coming head
  - Post. rotation of the head → do → Prague manoeuvre
  - Extension of arm → do → Lövset manoeuvre
  - Fetal birth injuries
    (nerves: Erb's palsy / bones : hip dislocation / viscera: rupture spleen,rupture liver, rupture anal sphincter& hymen defloration)
  - Fetal distress / Sudden compression & decompression

Diagnosis :
- During pregnancy
  - Leopold maneuver (FL:same as amenorrhea period / FG: head / UG / PG: buttocks)
  - FHS (above umbilicus)
  - US
- During labor (+ PV) (tip of sacrum + ischial tuberosities at same plane)

Management:

- During pregnancy: ECV (60% success) , at 36 wks if not CI , Side effects: **1)** ROM /cord prolapse **2)** Pl. separation **3)** Loops of cord around fetal neck **4)** Fetal distress **5)** ++ labor
- During labor : (Assess for unpredictable hazards sp in PG)
  - VD: **Assisted breech delivery :* spontaneous delivery of buttocks & shoulders , BUT Assisted delivery of head
    - Burns-Marshall (Leave baby hanging by its weight)
    - Mauriceau-Smellie-Veit ± Kristiller's manoeuver (Jaw flexion shoulder traction) (supra pubic pressure on head by assistant)
    - Piper's forceps
    - **Breech extraction* ONLY done in : 2nd twin if breech / fetal distress é fully dilated Cx and NO CPD
  - CS

Indications of CS: 1) Extended neck / 2) Twins 1st breech (locked twins) / 3) Preterm / 4) PG (80%) ??
5) weight < 2 kg , > 3.5 kg / 6) Breech presentation other than complete or frank / 7) Other indications for CS

Shoulder presentation

Def : Transverse Lie é scapula as denominator (ant or post)

Incidence: 0.5%

Etiology:
- General : CPD / Septate ut / Pl. previa
- Specific Pendulous abdomen in multipara

Position:
- LSA
- RSA

Mechanism : NO mechanism (Obstructed labor)

Complications:
- Maternal → 4 Ps
- Fetal + neglected shoulder

Diagnosis :
- During pregnancy
  - Leopold manoeuver (FL → less than period of amenorrhea / FG → empty
    UG → head on one side & buttocks on the other side / 1st PG → empty)
  - FHS → at level of umbilicus at the head side
  - US
- During labor: + PV → Grid – iron (ribs)

Management:
- During pregnancy: ECV till 1st stage of labor
- During labor : CS

NB : IPV and breech extraction is ONLY done for 2nd twin (if transverse)

NB : neglected shoulder : Arm prolapse with ROM for long time & IUFD , delivery by **CS (mostly upper segment)**
for maternal safety to prevent rupture uterus

Cord presentation & Cord prolapse

é intact memb. ← Cord presentation & Cord prolapse → é ROM — Obstetric emergency

Def : cord is below presenting part either é intact membranes (presentation) or é rupture membranes (prolapse)

Et : general :
- Maternal
- Fetal (specific) : malpresentations as shoulder / incomplete breech / footling / …

Diagnosis : **PV** : mind PULSATING or NOT

Management :
- IF PULSATING : reposit the cord & urgent CS / IF fully dilated Cx :
  - forceps in cephalic engaged
  - breech extraction in breech presentation
- IF NON PULSATING : allow VD (not an emergency)

Complex presentation

Def : **Arm** beside head or buttocks in **2nd** stage

Management : reposit the arm & proceed é VD

Unstable Lie

Def : Fetus continuously changes its position & / or presentation after 34 weeks GA

Management : stabilized induction ie induction of labor while it is in a cephalic presentation after 36 wks

Multi fetal gestation (Twins in 97% of cases , Triplets in 1-2%)

Definition: Simultaneous presence of 2 or more fetuses in the uterus **Inc:** DZT 1-2% > MZT $^{1}/_{250}$

ET:
- MZT (1 sperm + 1 ovum)
  - cleavage in MZT
    - If < 3 days → Dichorionic Diamniotic 30%
    - If 4-8 days (chorion formed) → Monochorionic Diamniotic 65%
    - If 8-12 days (ch & amnion formed) → Monoch. Monoam. 5% MOST SERIOUS
    - If > 12 days (parts formed) → Conjoined (rare)
- DZT(2 sperms + 2 ova) é induction of ovulation



Cl. picture :
- S : large sized abdomen / ++ S of pregnancy
- S :
  - General : ++ anemia / PIH / HEG / GD / …
  - Abdominal : Leopold maneuvers (FL / FG / UG / 1st Pelvic) FHS : galloping sign
  - PV: presenting part small in comparison to large abdomen

Inv: US

Mechanism : Depends on the presentation of 1st & 2nd fetuses

Complications:
- Maternal : 4 Ps + ↑↑ rate of medical disorders (hyperemesis / HTN / anemia / GD /…) + pressure symptoms
- Fetal
  1) vanishing twins (in 1st trimester)
  2) MZT
     - MC , MA & tttt : discordant twins (shared placenta)
       - One fetus LGA / polyhydraminos / polycythemia
       - Other fetus SGA / oligohydraminos / anemic
     - ttt : laser ablation of anastomotic vessels
     - Conjoined twins (due to delayed cleavage)
  3) locked twins , if we allow VD when 1st fetus is breech (which should not be done)
  4) death of one fetus : 1st trimester (early) : Little risk / 3rd trimester (late) : ++ DIC
  5) PTL (COMMONEST complication) & prematurity complications

Management :
- During pregnancy : more frequent ANC visits due to more ++ of medical disorders during pregnancy
- During labor :
  - CS : if 1) other indications of CS 2) > 2 fetuses 3) monoamniotic twins or conjoined twins 4) 1st fetus is non cephalic
  - VD : if 1st fetus is cephalic & no other indications of CS

Delivery of 2nd twin

If cephalic (most common)	if breech	if transverse
ROM & Allow VD spontaneous	ROM & Do breech extraction	ROM & Do IPV & breech extraction

Guard against Atonic postpartum hge by prophylactic ecbolics

OVD (operative Vaginal delivery)

	Forceps	Ventouse
Start	By Chamberlen family (1st to use forceps on living fetus) in year 1560-1730	By Malmstrom in 1954
Benefits	* In modern obstetric , only low (outlet) forceps is used for extraction only * Kielland long forceps is rarely used for rotation & extraction in OP * in fetal distress to shorten 2nd stage * In Face presentation & PTL * Aftercoming head of Breech (Piper's forceps) * Dead fetus	* For rotation & extraction in OA or OP positions * Less enchroachment on maternal pelvic space * Time consuming (need 20minutes to induce –ve pressure) ∴ not used in fetal distress * CI in face or preterm (only used in vertex presentation) * Only used on living fetus as –ve suction & scalp edema formation ie chignon (which is the mechanism of action of ventouse) needs living fetus to be formed
Pre-requisites	Fully dilated Cx / Engaged head (ie station 0 at least) / NO CPD / Membranes ruptured / Presence of uterine contractions / Empty bladder & rectum / Antiseptic techniques / Anesthesia	
Complications	**Maternal (mainly) :** - lacerations & tears (perineal / vaginal / cervical & even rupture uterus) - PPHge (traumatic or atonic) **Fetal :** - if wrong application : head compression , skull fracture & ICHge - cephalhematoma (bone fracture or fissure) - facial nerve injury	**Fetal (mainly) :** - cephalhematoma - scalp lacerations - ICHge if excessive –ve pressure in preterm fetus with fragile BVs **Maternal :** - If wrong application (includes cervical tissue in the ventouse cup) → lacerations

Cesarean Section

Def : Delivery of a viable fetus through an abdominal & ut incisions.

Types of CS :
- LSCS
- USCS (Classical CS) usually in PAS

Indications:
- Maternal : CPD / previous CS
- Fetal : Malpresentations / fetal distress

Techniques:

	LSCS	USCS
Uses	Usually done	In placenta accreta
Inc of rupture	0.2 – 0.9 %	×10 times (2-9 %)
Scar	Formed of 2 ms layers ∴ less Hge / better coaptation / less hematoma ∴ better healing (strong scar)	Formed of 3 ms layers ∴ more Hge / less coaptation / more hematoma ∴ worse in healing (weaker scar)
Peritoneum	Better peritonization & less adhesion formation	Visceral peritoneum is adherent ∴ more adhesions later

Complications of CS :
- Intraoperative :
  - * Anesthesia complications
  - * Injury to bladder/ intestine / BVs
- Early post operative:
  - * Reactionary Hge
  - * Ureteric injury symptoms / fistula
- Late post operative :
  - * Wound infection
  - * Paralytic ileus , acute gastric dilatation
  - * Thromboembolic complications
  - * Adhesions & subsequent tubal & peritoneal factors of infertility

*** Placenta accreta if implanted on the scar site**

NB : VBAC (Vaginal Birth After CS) or TOLAC (Trial Of Labor After CS)

Prerequisites :
- Only one previous LSCS
- Never after USCS (classical CS), hysterotomy or myomectomy scars
- No current indication for CS

Complications of VBAC : rupture uterus

" Previous normal VD followed by CS improves the chance of a safe and successful VBAC "

Episiotomy

Definition : an incision in post vaginal wall , perineum & skin done during vaginal delivery to widen the vulval introitus for the fetus

Indications:

Maternal :
- rigid perineum
- instrumental delivery

Fetal :
- macrosomia
- malpresentations or malposition
- prematurity (to avoid sudden compression & decompression of fetal head)

Timing : Just before crowning

Types :

	Median	Mediolateral
Benefit	More anatomical More cosmetic Less dyspareunia Less pain Less blood loss Easier repair Better healing	No extention to anal sphincter & rectum so avoid damage of anal sphincter (ONLY advantage over median episiotomy)

Complications :
- extension to anal sphincter in median type
- hematoma → Infection
- later dyspareunia

Analgesia & Anesthesia

Anesthesia in labor

Spinal is anesthesia of choice for CS : in subarachnoid space
(hypotension & headache, ∴ IV preload is needed)

Epidural :
(hypotension , ∴ IV preload is needed)

General : IV anesthetics as thiopental Na (ketalar) , in addition to inhalation gas drugs as N_2O & O_2
(affect fetus & mother)

Analgesia in labor

I) Pharmacological

General	Local
1) Narcotics: *Pethidine *Morphine × 10 *Butorphanol × 5 Side effect: Neonatal RDS if given < 2hrs before delivery Antidote : naloxone (Narcan) **2) Non- Narcotics :** * Benzodiazepines: diazepam (valium) * Phenothiazine derivatives **3) Inhalation :** * $N_2O + O_2$ → 50:50 (laughing gas) * Trilene (obsolete due to its toxic metabolites)	**1) Epidural : used all through labor, ie: intrapartum & postpartum** Side effects : * block motor too (not just sensory) * loss of urge of straining * accidental puncture of dura : headache **2) Local infiltration anesthesia (é lidocane)** Most commonly used (for episiotomy or tears) **3) Pudendal nerve block** At level of ischial spine , injected through the vagina **4) Paracervical block** * Injected on either side of the cervix through the lateral fornices * Side effect : fetal bradycardia (∴ rarely used)

II) Non-Pharmacological

1) ANC classes (how to relax / breathing excercises / abdominal & pelvic floor ms exercises)
2) TENS (Gate theory of pain)
3) Acupuncture (Gate theory of pain)
4) Water birth

APHge

Definition : Bleeding after fetal viability (24 wks) till delivery

Etiology :
- Maternal
  - Obstetrics : Abruptio-placentae (accidental hge) / Placenta pervia (PL PRV)
  - Gynecology : Vaginal lesion / Cervical lesion
  - Systemic : Drugs (anticoagulants) / Systemic disorders
- Fetal : vasa previa (minimal bleeding → severe fetal distress)

		Accidental Hge (commonest)	Placenta previa (2nd most common)
Definition		 Normally implanted placenta	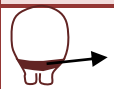 Placenta implanted on LUS
Risk Factors		PG (PIH) / External trauma / APS /Smoking Sudden ROM in polyhydramnios	Multipara / old age / Prev CS / prev PL PRV Malpresentations / Twins
Mechanism (Pathology)		* **In PIH:** Blood → inbetween myometrial fibers → tender hard ut → Couvelaire ut (concealed accidental Hge) ▶ Atonic PPHge * **In trauma:** soft ut & normal myometrium (revealed accidental Hge)	Shearing mechanism between LUS that forms & placenta → Unavoidable bleeding
Types		Mixed / Revealed / Concealed	Complete centralis / incomplete centralis Marginalis < 2 cm from os / Lateralis > 2 cm from os
Cl.picture	Symptoms	±Vag bleeding usually abdominal pain	Always vag bleeding Painless causeless recurrent bleeding
	Signs → General	PIH ? ± Shock (BP may not be ↓)	Type of patient ± anemia ± Shock
	Signs → Abd	**Tender ut (in concealed)** / FL > amenorrhea	No ut tenderness / FL = amenorrhea / malpresentations
	Signs → PV & speculum	Contraindicated till exclusion of PL PRV	
Complications		HELLP / DIC / Atony	Placenta Accreta / Increta / Percreta
Investigations		Maternal : US /CBC / LFTs / KFTs / Inv for DIC / HELLP Fetal : Assessment of fetal wellbeing (DFMC / NST / BPP / Doppler)	

Management of APHge:

Termination if : * Reached maturity
OR * Labor pains
OR * Maternal or fetal complication

Otherwise Conservative until one of 3 factors above are reached

Termination

- VD — In Accidental hge (unless CI)
- LSCS — In PL PRV (unless Lateralis)

NB: Placental migration : < 24 weeks
Lower edge of placenta may be seen near int os , but é formation of LUS , placenta migrates upward to its normal position, away from internal os & the condition resolves in > 90% of cases

* In case of abnormal adhesions of placenta, with no plane of cleavage (Increta / Percreta) → ttt : Cesarean hysterectomy (= USCS followed by hysterectomy) as any attempt to separate the placenta increta / percreta will result in severe bleeding

NB: *Rescussitation in shock (if present) *** ttt of complications if present ie DIC / HELLP / Atony**

Intrapartum Hge
= Obstetric Trauma

	Uterine rupture	Cx /Vag / Perineal lacerations
Predisposing factors	* Scarred uterus UUS (2 - 9%) > LUS (0.2 - 0.9 %) * Grand Multipara * Maluse of PGs / oxytocin * Over distended uterus * Instrumental delivery * Obstructed labor	* Scarred Cx / vagina / perineum * Instrumental delivery * Precipitate labor * Large sized fetus * Cx: manual dilatation of Cx (delivery through incompletely dilated Cx) OR omitting episiotomy when indicated
cl.picture	S: relieve of abd pain S: *Gen : ± shock *Abd :easily felt fetal parts / FHS↓↓↓ *PV: vag bleeding / fetal head receed upward	S: Bleeding after 2nd stage S: *Gen: ± shock *Abd: ut contracted *PV : bleeding / tears Cx ,vag ,perineum
Ttt	* Prophylactic to guard against obstetric trauma by proper management of 1st (ecbolics) , 2nd (instrumental / episiotomy) & 3rd (explore genital tract) stages * Rescussitation ± blood transfusion	
	* exploratory laparotomy : ut repair (subsequent elective CS at 36wks) ± subtotal hysterectomy (if unrepairable)	* vaginal exploration under GA & repair

Puerpurium

Definition : period of 6 wks following delivery during which all changes that occurred during pregnancy , will return back to normal.

Changes:

Uterus:
- Lochia(endometrium) : rubra → serosa → alba
- Myolysis
- Size at umbilicus on day of delivery
  then SP (2wks later)
  then prepregnancy size (4wks later)
- After pains: contractions that occur – specially é breast feeding – to help uterine involution
- Cx & lig back to normal (4wks later)

Vagina / Vulva :
- Reformation of rugae
- Gapping of vulva disappears

Breast :
- PRL for milk formation
- Oxytocin for milk expression
- Colostrum (++Ptns , ++ Ig , -- CHO , -- Fat) first 3 days , then milk expressed
- lactational amenorrhea in 50% of females
- pigmentation of areola remains

vital signs :
- BP back to normal
- ++ T° , but < 38 in 1st 24hrs after labor
- Transient ++ pulse
- Diuresis (retention only with painful episiotomy)
- Constipation (due to lax muscles)
- Emotional liability
- Post partum blues are very common (needs support & reassurance) but rarely depression (needs ttt) & psychosis (needs hospitalization)

PPC Program : 1week after labor , then 4-5 weeks later

to check :

* vital signs returned back to normal
* breast feeding & no milk engorgement
* uterus back to normal & lochia
* abdominal & pelvic floor excercises
* wounds : CS or episiotomy wound
* care for bladder & bowel by normal evacuation
* contraceptive counselling

Puerpural pyrexia

Definition: ++ T° ≥ 38° after 1st 24hrs of delivery , persisting for 24hrs or recurring within 24hrs till end of puerpurium.

Etiology :

1) Mastitis / Breast engorgement (most common)
2) P. sepsis (most serious)
3) UTI
4) Wound infection
5) Respiratory tract infections as COVID – 19 infection
6) DVT , Thrombophlebitis
7) other causes of fever as typhoid , malaria

" Any case of puepural pyrexia should be considered p.sepsis until proved otherwise "

Complications of 3rd stage

I) PPHge

1ry : 1st 24hrs
2ry : > 24hrs till end of puerperium due to infection

1ry PPHge

Def : bleeding > 500cc in VD / > 1000cc in CS
Inc : leading cause of maternal mortality in Egypt
Et :
1) Atony (overdistension , prolonged labor , ecbolics, anemia ,…) (most common)
2) Traumatic (Cx , perineal , vag laceration due to instrumental or macrosomia) (2nd common)
3) Retained placenta (remnants) (3rd common)
4) DIC or systemic disorders
5) Ut inversion (may not present é bleeding but pain)

Cl.picture :
S :
- Gen :anemia / shock
- Abd : lax ut (atony) / firm (trauma) / inverted cup (inversion)
- PV : dark blood clots (atony) / fresh bleeding (trauma) / lacerations / retained placenta / inverted ut

Complications : Death / Sheehan $…
Inv : CBC (inv for complications)
Ttt:
A) PREVENTION
(proper ANC / 1st , 2nd , 3rd stage management)
B) Actual
- Vag:
  1) Ecbolics + massage + bimanual compression
  2) Exploration of genital tract for trauma
  3) Intrauterine Bakry ballon (placed vag)
- Abd:
  4) Bilat uterine / IIA ligation Vs 4) B-Lynch suture
  5) Subtotal hysterectomy

NB : Resussitation while doing these measures

II) Retained placenta

Def : placenta didn't deliver within 30 min of fetal delivery
Et :
- Retained separated (atony / rupture ut / constriction ring (rare))
- Retained non separated (PAS)

Ttt: 1) Ecbolics + Brandt - Andrew's
2) Manual separation
3) If only parts = D&C by ovum forceps
4) ttt of cause (if present)

NB: in PAS
*Accreta (80%) : there is usually a plane of cleavage so separation of placenta occurs (take care if increta / percreta)
*Increta / Percreta : planned cesarean hysterectomy ie classical CS, removal of fetus , closure of wound & proceeding to TAH with ovarian preservation éout any attempt to separate placenta (to avoid severe bleeding)

III) Uterine inversion

Def :
Et :
traction on placenta while uterus is lax
Cl.picture :
Gen : neurogenic shock
Abd : absent fundus
PV : inverted cup (decidua seen)
Ttt:
*Avoid
*Actual : Manual reposition
Or Hydrostatic pressure reduction

IV) Shock (Hgic / Neurogenic / Septic)

Hgic shock

Def : state of circulatory impairement
Cl.picture :
1) Amount of blood loss (< 15% , 15-30 % , 30-40% , > 40 %)
2) HR (< 100 , 100-120 , 120-140 , > 140)
3) BP (N or ↓)
4) Urine output (> 30ml/ hr ,15-30 , 5-15 , < 5ml/hr)

Ttt: **A**irway (maintained patent)
Breathing (oxygenation)
Circulation (adrenaline / perfusion)

Replacement :
* Whole blood
* Packed RBCs
* Fresh Frosen Plasma (all clotting factors)
* Cryoprecipitate (factors VIII , XIII , Fibrinogen)
* Platelets

Septic shock

Ttt : Broad spectrum antibiotics + ttt of cause

V) DIC

Def :
consumptive coagulopathy / hypofibrinogenemia
Et :
* Massive blood loss
* Massive transfusion
* Concealed accidental Hge
* HELLP
* Amniotic fluid embolism

(++ intrinsic pathway (endothelial cell damage))

* IUFD → ++ extrinsic pathway (thromboplastin release)

Cl.picture : of cause / bleeding from venipuncture
Inv :
- ↓ fibrinogen < 100 mg / dl
- ++ FDPs (++ D-dimer)
- ++ PT , PTT

Ttt :
- Of cause
- Replacement (FFP / Cryoppt)
- Never ×× Heparin

Puerpural sepsis (3rd cause of maternal mortality in Egypt)

Definition : Infection of the genital tract after labor till end of puepurium

Etiology :

- Predisposing F :
  - General : ↓ immunity/ anemia / DM
  - Local : tears / septic conditions / instrumental delivery
  - Prolonged labor & prolonged PROM
  - Retained parts of placenta or membranes
- Organism : Polymicrobial (Gram –ve / +ve / anaerobes)
- Route of infection :
  - Ascending from vagina
  - Autogenous from elsewhere in body
  - Exogenous from attendees

Pathology :

- 1ry site (symptoms immediately after delivery)
  - * Uterus , Cx , Vagina , Perineal lacerations
- 2ry site (late symptoms after 7-10 days)
  - * Parametritis , salpingo oophoritis , peritonitis , pelvic thrombophlebitis (after 14 days)

Cl.picture:

- Symptoms:
  - * Fever/ foul smelling discharge / lower abdominal pain / ± oedematous white swollen limbs (phlegmasia alba dollens)
- Signs:
  - * General :Fever / tachycardia / toxic facies / dehydration
  - * Abdominal : tenderness / guarding / rebound tenderness
  - * PV: jumping sign / horse-shoe induration around Cx
  - * ± LL affection : swollen white painful limbs
  - * Septicemia in severe untreated cases

Investigations :

* To exclude other DD :
- Breast exam (for engorgement & mastitis)
- Chest X-Ray (for chest infections)
- Urine analysis (for UTI)
- C/S (for wound infection)
- Doppler US (for DVT)

* To confirm diagnosis :
- Culture & sensitivity from discharge
- Blood test (++CRP , ++ESR , ++TLC ,++DLC (shift to the left) , ++ staff / segmented ratio)
- Pelvic US

Treatment :

* Prevention :
- by proper ANC (control anemia , DM)
- 1st stage of labor :
  - Avoid prolonged labor
  - Give antibiotics in PROM
- 2nd stage:
  - Proper use of instrumental delivery
  - Proper aseptic techniques while doing episiotomy
- 3rd stage:
  - Explore placenta & memb. for any missing parts
  - Repair of any laceration under aseptic technique

* Active ttt :
- Hospitalization
- IV fluids / IV analgesics / IV antipyretics
- IV antibiotics
  - Cephalosporins for Gram +ve
  - Gentamycin for Gram –ve (Max for 3 days as they are nephrotoxic)
  - Metronidazole for anaerobes

* Special situations : (in addition to above mentioned ttt)
- Abscess : drainage
- In retained parts : Ecbolics ± D&C
- Infected wound : remove suture& drainage
- Septic thrombophebitis : anticoagulants& immobilization
- Pelvic abscess: Fowler position ± drainage by colpotomy

Assessment of fetal wellbeing

Antepartum

(from viability till labor)

1) DFMC : (N) 10 movements / 12 hrs

2) NST : fetal heart acceleration in relation to its movements (for 20 min)

(N) 15 b/min acceleration for 15 sec (= reactive NST)

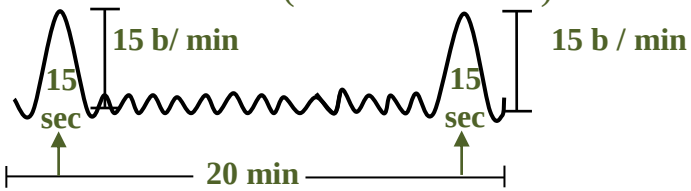

- If non reassuring NST → Repeat for another 20 min
- If non reactive NST → ∴ Do BPP

3) BPP : US to detect (movement / tone / breathing / AFI)

Each item → 0 if not present
→ 2 if present

∴ Total score = 8

- If < 6 / 8 ∴ do doppler

(NB: Modified BPP = NST + AFI)

4) Doppler study: for umbilical artery , MCA

- If + + resistence (low flow) ∴ placental insufficiency
- If NO flow ∴ Alert sign
- If reversed flow ∴ Action should be taken

NB : If high risk cases ∴ assessment of fetal wellbeing

DFMC → done daily

NST / BPP → done biweekly

Doppler → done weekly

Intrapartum

(in 1st & 2nd stages of labor)

1) Passage of Meconium (in cephalic presentation) :

indicates fetal distress

2) CTG : relation of FHR to uterine contractions

- (N) FHR = 110 – 160 b / min
  - If < 100 bradycardia
  - If > 160 tachycardia

} = fetal distress

CTG ONLY FOR HIGH RISK

-Loss of beat to beat variability = fetal acidosis

-Early deceleration = head compression (N)

-Variable deceleration = cord compression (exclude cord prolapse)

-Late deceleration = fetal distress (sp if persistent late deceleration)

-Sinusoidal rythm

3) fetal scalp PH (N) PH = 7.25 – 7.35

- If 7.2 – 7.25 → ∴ mild acidosis
- If < 7.2 → ∴ severe acidosis

Management of Intrapartum distress (asphyxia)

* Stop oxytocin / give IV fluids
* mask O_2 / put pt in Lt lateral position

Persistent distress → Immediate Termination

- Not fully dilated → CS
- fully dilated → VD → Forceps in cephalic pr. / Breech extraction in breech pr.

Returns back to (N) → continue labor é close observation

PROM

Definition : ROM after fetal viability & before onset of labor

Incidence : 10%



Etiology:
- Idiopathic
- Infection (commonest) : GTI , UTI
- Cx incompetence
- Polyhydramnios
- Local membrane defect / smoking

Complications :

Maternal : infection : Chorioamnionitis (most serious)

Fetal: Preterm labor within 24-48 hrs (commonest)

Clinical picture :

Symptoms : gush of fluid

Signs :
- General : fever (in case of infection)
- Abdominal : FL < period of amenorrhea / tender uterus in chorioamnionitis
- PV(under STRICT aseptic conditions) : speculum for fluid pooling in posterior fornix

Investigations :

Confirm diagnosis : Speculum / Nitrazine paper / +ve fern / Amniosure

Detect complications (infection) : CRP / TLC / DLC / ESR

US for AFI : If < 5 ∴ oligohydramnios

Management : **ANTIBIOTICS**

NO TOCOLYSIS

IF
- < 36 wks
- NO maternal or fetal complications
- NO Ut contractions

Conservative : Antibiotics + Follow up maternal & fetal conditions

IF
- > 36 wks
- OR Presence of maternal or fetal complications
- OR Presence of Ut contractions

Antibiotics + Termination (whether VD or CS depending on obstetric condition)

Oligohydramnios

Def: ↓ liquor < 500cc AFI < 5
or deepest pocket < 2cm

Inc : 5%

Et : (↓ production by fetus or placenta)
* Renal agenesis
* Pl.insufficiency

Cl.picture:
* Small size abdomen < amenorrhea
* Picture of the cause (eg : PE)

Inv

US for volume / AFI / Deepest pocket

Complications:
* Of cause (placental insufficiency)
* Limb deformity / lung hypoplasia / amniotic band syndrome
* Cord compression / fetal distress

Ttt:
* ttt of cause
* Termination if :
  - reach 36 weeks
  - occurance of complications
  - start of labor pains
* Amnio-infusion (rarely done)

Polyhydramnios

Def : ↑ liquor > 2liters AFI > 25
or deepest pocket > 8cm

Inc : 0.5%

Et : (↓ swallowing by fetus or ↑ production)
* Idiopathic
* DM (uncontrolled)
* Oesophageal or duodenal atresia
* Anencephaly

Cl.picture:
* Oversize abdomen > amenorrhea
* Pressure symptoms (as resp. embarrassment)
* Picture of the cause (eg : DM)

Inv :

US for volume / AFI / Deepest pocket

Complications:
* Of cause (uncontrolled DM)
* Pressure symptoms
* Sudden ROM , Placental abruption, Cord prolapse
* Malpresentations , Dysfunctional labor , Atonic PPHge

Ttt:
* ttt of cause
* Termination if :
  - reach 36 weeks
  - occurance of complications
  - start of labor pains
* Amniodrainage (to relieve pressure symptoms)

NB : * Amniotic fluid functions : protect from infection / regulate temperature / lung expansion / limb movements / nutrition
* Amniotic fluid composition : 99% water, clear, alkaline / mainly **FETAL** contribution

Preterm labor

Definition: start of labor pains after fetal viability & < 36 wks

Incidence: 5-10%

Etiology:
- Idiopathic / miscalculation .
- Cx incompetence / septate or bicornuate uterus
- Over distended ut (polyhydramnios / MFG / fibroid ut)
- Medical / obstetric indication for termination.
- PROM / GTI / UTI / smoking / excessive physical activity
- Iatrogenic (induced PTL in complicated uncontrolled pregnancies)

Clinical picture:
- Symptoms : true labor pains < 36 wks
- Signs:
  - General : of cause or risk factor
  - Abd : true ut contractions / cause
  - PV: start cx changes (dilatation / effacement)

Complications (ALL FETAL) **:**
- RDS / Retinopathy of prematurity / Cerebral hge
- Neonatal sepsis / Necrotising enterocolitis

Investigations :
- CTG to confirm PTL
- US : short cervical canal < 2.5 cm
- FFN (Fetal fibronectin): from 24-32 wks

(N) absent , if present (by vag swab) ∴ 50% PTL within 2 wks

Management:

* Prophylactic against RDS: steroids 24mg IM & delivery 24hrs after last dose :

Betamethasone (long acting) 12mg $\xrightarrow{24\,h}$ 12mg

Dexamethasone (short acting) 6mg $\xrightarrow{12h}$ 6mg $\xrightarrow{12h}$ 6mg $\xrightarrow{12h}$ 6mg

* IF still in latent phase (Cx < 4cm dilatation & < 50% effacement) can use Tocolysis to delay labor till Steroids work / NICU transfer:

1) Ca channel Blocker (Nifedipine)
2) β_2 agonist (Ritodrine)
3) PGs synthetase inhibitor (Indomethacin) < 32wks
4) Anti- oxytocin (Atosiban)
5) $MgSO_4$ if < 28wks to prevent CP
6) Natural Progesterone (17 OH Progesterone caproate) IM weekly

Post term pregnancy

Definition: pregnancy continue after 42 weeks

Incidence: 5-10%

Etiology:
- Miscalculation.
- Idiopathic.
- Anomalies as Anencephaly.
- Placental cause

Clinical picture:
- Symptoms : of cause / may be oversized abdomen (80%)
- Signs : may be normal or oversized abdomen (80%)

Complications:
- 80% LGA (in normally functioning placenta)
- 20% IUGR with its sequelae (in placental aging)
- ↓ liquor / meconium stained liquor & meconium aspiration during delivery

Investigations:
- US : for AFI / placental grading
- Growth curves

Management:

Assessment of fetal wellbeing (DFMC / NST / BPP / Doppler)

When to terminate:
- 42 wks
- occurrence of labor pains
- occurrence of complications

How to terminate: IOL
- Amniotomy
- Oxytocin : If Bishop > 5
- PGs : IF Bishop < 5

	0	1	2	3
Dilatation	closed	1-2 cm	3-4 cm	>5 cm
Effacement	< 30%	30-50%	50-80%	>80%
Position	posterior	mid	anterior	
Consistency	firm	mid	soft	
Station	-3	-2	-1 / 0	+1 / +2

Bishop score

Fetal growth disorders

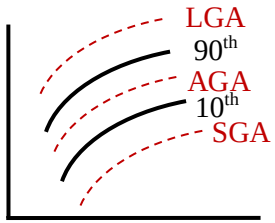

SGA (IUGR)

Def: < 10th percentile for GA

Inc:
- asymmetrical (maternal causes) 80%
- symmetrical (fetal causes) 20%

Et :

Fetal : ch.anomalies / infection in utero

Maternal : pl. insufficiency

Pathology : brain sparing effect in asymmetrical IUGR

Cl.picture :

Symptoms : small sized abdomen (< period of amenorrhea)

Signs:
- General : of cause
- Abdominal : ↓↓ FL / ↓↓ SFH (24 - 32 wks)

Inv : US for fetal growth curve assessment:

* In asymmetrical IUGR → Ⓝ BPD & --FL --AC
* In symmetrical IUGR → -- BPD , -- FL & --AC

ttt:

Manage cause if present

+ Terminate if :
  * Reaches 36wks
  * Or maternal or fetal complications
  * Or labor pains occur

LGA (Macrosomia)

Def : > 90th percentile for GA

Et : Idiopathic / DM / Past date

Cl.picture:
- Symptoms : of the cause / oversized abdomen
- Signs:
  - General : of cause
  - Abdominal : ++ FL / ++ SFH

Inv : US for fetal growth assessment

ttt: manage cause if present & observe till:
  * Occurrence of complications
  * Labor pains

Delivery by IOL or CS according to obstetric indication but **avoid Instrumental delivery** for fear of shoulder dystocia

IUFD

Definition: Death in utero after fetal viability

Etiology:
- Idiopathic in 50%
- Maternal as in placental insufficiency
- Fetal anomalies / infections

Cl.picture:
- ↓ or NO fetal movements
- ↓↓ FL < period of amenorrhea

Complications : DIC if retained for weeks

ttt:
- Wait for spontaneous labor pains while closely monitoring fibrinogen level , FDPs to guard against DIC
- If anxious or start complication : Terminate VD OR CS according to obstetric condition

Fetal asphyxia
(In utero)

Def: ↓O_2 & ↓ elimination of CO_2 ∴ ↑ CO_2 → acidosis (PH < 7.2)

Etiology:

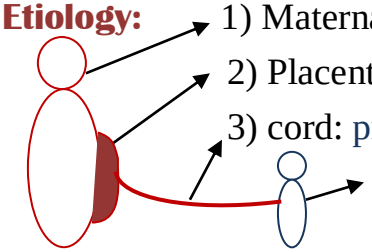

1) Maternal : uncontrolled medical disorders
2) Placenta : separation / insufficiency
3) cord: prolapsed / loops around the neck
4) fetus: anomalies / instrumental deliveries

Cl. Picture: **(FETAL)**

1) Abnormal CTG in assessment of fetal wellbeing:
   - Loss of beat to beat variability
   - Sinusoidal rhythm
   - Late deceleration (sp.persistent)
   - Brady < 100 (OR) Tachy >160 b/min
2) Meconium stained liquor in cephalic presentation
3) Fetal scalp PH < 7.25

Management:

*** First aid measures:**

1) Stop oxytocin + IV fluid rehydration
2) Turn mother to Lt lateral position + O_2 mask
3) Atropine to the mother

*** If distress**

→ Relieved : continue VD é continous CTG monitoring
→ Not relieved : immediate delivery

- If engaged presenting part & fully dilated Cx → Forceps (or) Breech extraction
- If not fully dilated → CS

Neonatal asphyxia
(Post natal)

Def: ↓O_2 & ↓ elimination of CO_2 ∴ ↑ CO_2 → acidosis in neonate

Etiology:
- persistent fetal asphyxia
- morphine given to the mother 2 – 4 hrs before delivery
- meconium aspiration
- cong anomalies of respiratory , circulatory systems
- prematurity
- birth injuries

Cl. Picture: APGAR score at
- 1min for need of rescussitation
- 5min for prognosis

	0	1	2
Appearance (color)	Blue	Trunk → pink Extremities → blue	Pink
Pulse	—	< 100 b/min	> 100b/min
Grimace (reflexes)	—	Grimace	Active cough & sneeze
Activity (movement)	Flaccid	Some flexion	Active movement
Respiration	—	Slow , irregular	Active cry

Ttt:

▸ Prevention
- proper ANC & control of maternal diseases
- proper intranatal care
  - * Proper use of Instrumental delivery
  - * Episiotomy whenever needed
  - * Proper use of morphine
  - * Care during delivery of after coming head

▸ ttt : A (Airway & suction)
B (Breathing & O_2 mask)
C (Circulation CPR & warmth)
D (Drugs):
- Naloxone : morphine antidote
- $NaHCO_3$: to combat acidosis
- Adrenaline : to combat bradycardia
- Antibiotics : in case of sepsis

Fetal birth injuries

Definition: Injuries of fetus at birth (iatrogenic)
Etiology: (Instrumental / prematurity / CPD …..)
Types:

1) Bone injuries:

- Skull : ± ICHge*

	Subperiosteal Hge (cephalhematoma)	Caput succedaneum (scalp edema) (chignon)
Causes	Wrong application of forceps / * Depressed fracture or fissure fracture	Normal ventouse application Prolonged / obstructed labor
When	After few hours	At birth
Shape	Overlie a certain bone Never crosses suture line Skin over it is normal	Any area of the scalp May cross the suture line Skin over it is echymotic
Fate	May be infected Calcification Hyperbilirubinemia ttt: → Expectant ttt (Antibiotics & follow up) → Measures to ↓ ICT (in cases of ICHge)	Subside spontaneously in 1-2 days

- Other bones : humerus / clavicle / spine injuries / shoulder dislocation
  → ttt: Splint / slab (for long bones injury)

2) Muscle : as sternomastoid → ttt: Passive traction

3) Nerves : → Brachial plexus
- C5,6 : Erb's palsy (Policeman tip position)
- C8,T1: Klumpke's palsy (failure of grasp reflex) (Ape hand)

→ Facial nerve injury : (flat nasolabial fold)
due to forceps pressure at stylomastoid foramen

→ ttt: Physiotherapy (will resolve if edema)

4) Organs : liver / spleen / anus / hymen (as in breech delivery)



Erb's palsy



Klumpke's palsy

NB: proper management of the 2nd stage of labor will prevent most of these iatrogenic birth injuries

Pregnancy Induced Hypertension (PIH)

Hypertensive disorders of pregnancy :
* Preeclampsia (PIH) : HTN + Ptnuria > 20 wks GA
* Gestational HTN : HTN > 20 wks GA
* Chronic HTN :HTN < 20 wks GA
* Superimposed PE : chronic HTN + PE
* ECLAMPSIA : PE + Seizures

Definition : HTN + Ptnuria > 20 wks



Types :
* Mild : BP ≥ 140/90 , ptn > 300mg
* Severe: → uncomplicated : BP ≥ 160/& or 110 , ptn > 5gm (no symptoms or lab changes)
  → complicated (é symptoms or lab changes in addition to the above mentioned criteria)

Inc : 4-7% (one of the leading causes of maternal mortality)

Et : → Risk f : PG / renal disorders / SLE / APS / DM / +++ HCG (v.mole / MFG)
→ Theories & pathophysiology:

Failure of Trophoblastic invasion in spiral arteriole

⇩

Narrower vessels with ++ vascular resistance ∴ ↓↓ placental perfusion → IUGR, Oligohydramnios, Ch. Fetal distress
& release of toxic mediators

Reaching all or any organ (liver / brain / retina / kidney / BVs)
So affecting their function

Cl.picture : → (S) disease of **Signs** : BP / ptn in urine / weight (due to edema)
→ (S)ymptoms ONLY in severe PE :

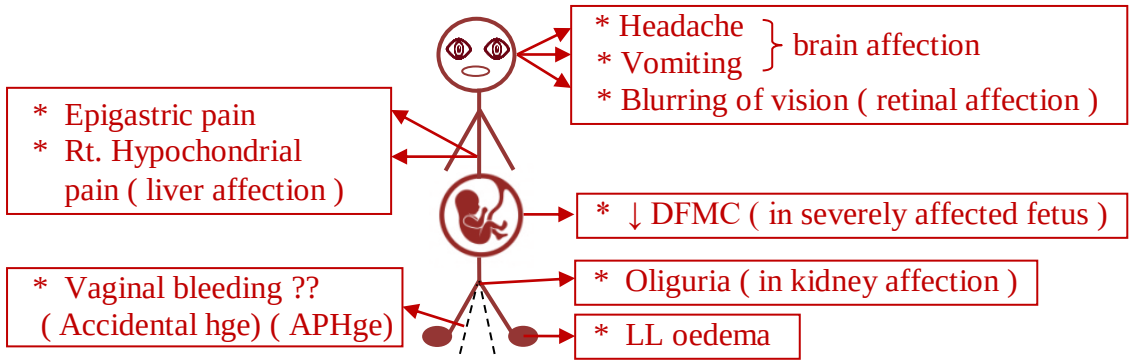

Warning signs

Complications : → Maternal : → Severe PE é symptoms or lab changes (HELLP) Retina / liver / kidney / brain / DIC … } Maternal mortality
→ Eclampsia (convulsions)
→ Fetal: IUFD

Inv : → Maternal : A/C ratio > 0.3 , CBC(Hb , Hct , PLT) , LFTs , KFTs , coagulation , fundus exam , ? CT brain
→ Fetal : US (growth assessment , liquor) / assessment of fetal wellbeing

Ttt:

Mild PE :

continue to term but NOT post term
é close observation

Severe PE :

* IF Symptoms or lab changes :
  Immediate termination

* IF only BP & ptnuria
  NO symptoms or lab changes:

< 36wks	> 36wks
Antihypertensive & close observation Till: → reach 36wks → labor pains → occurrence of complications	↓ terminate

NB:
* $MgSO_4$ in severe complicated PE or Eclampsia needing termination : to avoid / control seizures
* Prophylaxis ? LDA / Ca / Vit D
* Uric acid : increases in PIH & used for its prediction

Rh isoimmunization

Definition: hemolysis of fetal RBCs by maternal Ab (problem occurs when mother is Rh negative & fetus is Rh positive)

Etiology : sensitization of the mother by
- Rh –ve Mother received Rh+ve blood transfusion
- Rh –ve Mother × Rh+ve Father → Rh+ve fetus

Pathogenesis :

dd × DD (Dd)

Dd (100%) Dd (50%) & dd (50%)

- 1st baby may be affected if previous maternal blood transfusion with Rh+ve blood
- Fetus may be spared if :
  - 1st baby
  - 2nd baby but 1st one was Rh-ve (heterozygous father)
  - With ABO incompatibility
  - Small amount of exposure

Effect: depends upon
- Immune system of the mother
- Associated ABO incompatibility
- She may marry Rh –ve or heterozygous Rh+ve man

Clinical picture: (FETAL ONLY)
- Hemolytic anemia (mild form)
- Neonatal jaundice : Icterus gravis neonatorum (commonest & moderate form)
  ± kernicterus if bilirubin > 20 mg % cross BBB
- Hydrops fetalis (severe form) → anemic HF & generalized edema (Buddha attitude)

Investigations:
- Rh blood group of mother & father
- Indirect coomb's test to mother
- Amniocentesis (if indirect coomb's > $^1/_{16}$)
- US for fetal anomalies (HSM / Ascites)

Treatment:
- Prevention: Anti D (only for non sensitized Rh –ve mothers)within 72hrs of delivery of Rh+ve fetus & at 28wks GA & immediately after any procedure done during pregnancy (Abortion , Ectopic , Amniocentesis , …)
- If indirect coomb's
  - < $^1/_{16}$ → repeat after 4 wks
  - > $^1/_{16}$ → amniocentesis
    - If ↑ bilirubin & ↓ Hb (∴ hemolysis)
      - < 34wks → Intrauterine transfusion
      - > 34wks → Terminate
    - Hb (N) 18gm% , bilirubin (N) < 2 mg / dl → Follow up with titre
- After delivery: exchange transfusion for the baby with O –ve blood
- Definitive ttt is plasmapheresis for maternal blood to remove antibodies (very costly, available in limited centers, doubtful prognosis)

DM with pregnancy

Definition :
hyperglycemia / glucosuria / microangiopathy

Et:
- GDM : Only during pregnancy
- Overt DM :
  - Type I : insulin dependent
  - Type II : non insulin dependent

Risk F :
old age , multipara , H/O of IUFD , H/O of congenital anomalies

Pathophysiology :
pregnancy is diabetogenic due to placental anti insulin hormones (PRG , Cortisol , HPL) & insulinase enzyme

Cl.picture :
- Maternal:
  - ↑ infection (vulvovaginitis)
  - Abortion / PTL / PROM / Puerpural sepsis
  - Instrumental deliveries
  - ++ DKA / PE
- Fetal :
  - Macrosomia / polyhydramnios
  - FCA :VSD (most common) , Sacral agenesis (most specific)
  - Sudden IUFD
  - Fetal birth injuries & shoulder dystocia
- Neonatal :
  - Hypoglycemia (give IV glucose to the new born upon delivery)
  - Hypocalcemia
  - Polycythemia
  - Hyperbilirubinemia
  - RDS

Inv :
- Maternal :
  - Screening for all pregnant ladies (24-28wks):
    - 50gm OGTT If ≥ 140 mg /dl
  - Diagnostic :
    - FBS > 95mg % **&** 100gm 1 hour OGTT > 165 mg/dl
  - HbA1c: to assess glycemic control over past 3 months (best indicator for occurrence of fetal congenital anomalies)
- Fetal
  - US
    - 1st trimesteric for NTD , Anencephaly
    - 2nd trimesteric for FCA
    - 3rd trimesteric for Macrosomia , Polyhydramnios
  - Assessment of fetal wellbeing

Treatment:
- Diet + exercise : if blood sugar < 200mg/dl
- Continue metformin (if was given since before pregnancy)
- Insulin : if blood sugar > 200 mg /dl
  $^2/_3$ dose at morning & $^1/_3$ dose at night
  50 : 50 (regular : NPH)
- ××× Oral hypoglycemic ××× as teratogenic & long acting so difficult to be controlled
- Delivery : depends on glycemic control
  * if good control → ∴ wait for spontaneous labor pains
  * if uncontrolled → ∴ terminate after giving steroids for lung maturity.

WHITE classification for DM :
- A : GDM
  - A 1: no need for insulin
  - A 2: with need for insulin
- B : overt DM started > 20yrs age for duration of < 10yrs
- C : overt DM started 10- 20yrs age for duration of 10-20yrs
- D : overt DM started < 10 yrs age for duration of > 20yrs
- E : overt DM with calcified pelvic vessels
- F : overt DM with nephropathy
- R : overt DM with retinopathy

UTI é pregnancy

1) Asymptomatic bacteruria

Def : > 100.000 CFU
Inc: 6% of pregnant females
(↑↑ in 2nd trimester due to stasis & compression)
Diagnosis : → urine analysis
→ urine culture & sensitivity
Ttt : oral antibiotics is a must as 30 – 45 % → pyelonephritis

2) Acute cystitis (lower UTI)

frequency , dysuria , lower abd suprapubic pain & tenderness
NO systemic manifestations (ie : no fever)
Inv : urine analysis , urine culture & sensitivity
Ttt : oral antibiotics

3) Acute pyelonephritis (upper UTI)

Def : upper UTI with systemic manifestations
Cl.picture: fever/ loin pain
Complications:
→ Maternal: pulmonary dysfunction from sepsis & anemia
→ Fetal : PROM , PTL , Morbidity & Mortality
Inv : → Urine analysis / Urine culture & sensitivity
→ US
→ Assessment of fetal wellbeing
Ttt: Hospitalization + IV fluids , antipyretics , analgesics
Start IV antibiotics then modify according to C/S

Cardiac diseases é pregnancy

Types: RHDs (developing) , CHDs (developed) countries.
Pathophysiology :
→ ± BP = [↑↑CO] × ↓↓↓TPR
[↑SV × ↑HR] (hyperdynamic circulation)
→ Waterhummer pulse: (++ S / D) difference
→ Apex :shifted to 4th intercostal space outside MCL
→ Split S_1 / appearance of S_3 / Systolic murmur
Risk F : anemia / hypertension / infection / hyperthyroidism
Clinical picture (NYHA classification) :
I : Dyspnea on > ordinary effort **II** : Dyspnea at ordinary effort
III : Dyspnea on < ordinary effort **VI** : Dyspnea at rest
Effect (complications):
→ Maternal : Worsen NYHA classification by 1grade
→ Fetal : LBW / IUGR / Fetal anemia
Inv : ECG / Echo / US for fetal biometry (SGA)
Management:
**** In pregnancy***
→ More frequent ANC
→ Guard against anemia / infection / HTN / Hyperthyroidism
→ Digitalis to be continued or started whenever needed
**** In Labor:***
→ Semisitting / O_2 mask / Analgesics / Antibiotics
→ Avoid fluid overload : care é oxytocin (has ADH like action)
→ Shorten 2nd stage by forceps / ↓ bearing down
→ Smooth VD or CS (whenever indicated)
→ In 3rd stage : * Lasix to ↓ VR & heart load * **NO Ergometrine**
**** In puerpurium :***
→ Breast feeding CI in HF
→ Proper selection of contraception

Seizures (convulsions , Epilepsy) é pregnancy

75% remain same , 25% worsen due to metabolism of anticonvulsants.
Effect of anticonvulsants on fetus : FCA , CP/MR ,- - VitK (é phenytoin)
Management : → Maternal : * Extra folic since before pregnancy 800µg daily * Monotherapy is better é least possible dose to control seizures
→ Fetal : anomaly scan

Anemia é pregnancy

Def: ↓ Hb less than 11gm%
or less than 10.5gm% in 2nd trimester
Inc: commonest medical disorder during pregnancy
Effect of pregnancy on blood :
* Physiological (dilutional anemia)
(++ plasma > + RBCs)
* Tachycardia & Hyperdynamic circulation
* Max effect at 20 wks
Etiology :
* Nutritional (Fe deficiency anemia) COMMONEST
* Megaloblastic (folic A. & Vit B_{12} deficiency)
* Hemorrhagic
(bleeding in early, late pregnancy & PPHge)
* Hemolytic (congenital or acquired)
* Hereditary (thalassemia , sickle cell anemia)
* Aplastic
Effect (complications):
- Maternal: easy fatigability , PTL , PPH , Puerpural sepsis
- Fetal:IUGR, LBW, PTL, neonatal sepsis , anemia

Inv:
- Maternal (for iron deficiency anemia):
CBC / serum ferritin / TIBC
- Fetal : Assessment of fetal wellbeing

Ttt:
- Prophylactic
- Mild (10-11gm/dl) : oral iron
- Moderate (7-10gm/dl) :parentral iron
- Severe (4-7gm/dl) / Decompensated (< 4gm/dl): blood or packed RBCs
- Guard against PPH / P.sepsis
- Continue iron in puerpurium

Thyroid disorders é pregnancy

1) physiological Goiter

Due to
- ++ blood supply
- - - iodine
- ++ total T_3 & T_4

due to ↑ TBG
(free T_3 & T_4 unchanged)

2) Hyperthyroidism

* Graves' disease (commonest during pregnancy):
Autoimmune
* Thyroid storm :
Hypermetabolic
* Complications:
Abortion , PTL , IUGR
* Inv: - -TSH , + + freeT4 ,
+ +TSH receptor Ab
* Ttt:
Propylthiouracil ± βB / Steroids

× × NO radioactive iodine × ×

3) Hypothyroidism

Rare in pregnancy as it causes infertility & anovulation
Commonest cause:
Autoimmune
(Hashimoto thyroiditis)
Inv : + + TSH , - - freeT4
Ttt : Eltroxine

NB:
requirements ↑↑ in pregnancy

Venous thromboembolism

Effect of pregnancy on blood:
- + + clotting factors & - - fibrinolysis
- + + platelets activation
- Venous stasis due to pressure by gravid ut.
- ∴ + + thromboembolic events in pregnancy & puerpurium

Risk F: > 35 yrs , multipara , obese , VV, H/O of DVT , thrombophilia , APS , CS, sepsis sp . pelvic
Cl.pict of DVT: red , hot , tender , swollen calf ms
Complications : 25% of DVT will result in PE of which 15% are fatal
Inv:
- Doppler US
- Venography (CI during pregnancy)

Ttt:
- Prophylactic :
  * Hydration & mobilization
  * LDA
  * Elastic stocking
  * LMWH (clexane) single SC injection : in high risk multifactorial , till end of puerpurium
- Actual ttt :
Therapeutic dose of IV heparin or LMWH & immobilization

NB: Warfarin is CI in 1st trimester (teratogenic) & in 3rd trimester r (fetal ICHge)

When to stop anticoagulants before delivery?
- Aspirin 1 week before delivery
- Clexane 24hrs before delivery

Pulmonary Embolism

Cl.pict: Breathlessness / Hypoxia / Tachycardia / Pleuritic chest pain
Inv:
- ECG changes
- Ventilation / perfusion scan
- Pulmonary angiography

Ttt: ICU support , O_2 Therapy , IV Anticoagulant (high therapeutic dose)

GIT disorders with pregnancy

1) Emesis Gravidarum (NVP)

Reassurance / small frequent meals / ↓↓ fat & ↑↑ carbohydrate intake

2) Hyperemesis Gravidarum (HEG)

Def: Excessive vomiting in 1st trimester that affects general condition

Etiology (theories) : ++ HCG / - - Vit B_1 (Thiamine) / Psychogenic

Pathogenesis & Complications:
- Dehydration / hemoconcentration
- Electrolyte disturbance / Starvation ketosis
- ↓ liver glycogen & ++ AST , ALT
- Mallory Weiss Syndrome
- Wernicke's encephalopathy

Inv : Na^+ / K^+ / LFTs / Hct / chloride in urine

Treatment:
- Hospitalization / NPO
- IV fluids & correct electrolytes
- IV or PR Antiemetics as metoclopramide , meclozine , ondansetrone
- Rarely termination (in severe cases of encephalopathy)

3) GERD

Definition: epigastric discomfort after meals

ttt: Reassurance & symptomatic ttt:
- Small frequent meals & avoid recumbency after meals
- Antacids 1hr after meal
- H_2 receptor antagonist (Cimetidine , Ranitidine = Zantac)
- Proton pump inhibitor (Omeprazole = Controloc)

4) Intrahepatic cholestasis

Def : cholestasis & pruritis > 20 wks GA

Inc : 1-4 % , Etiology : unknown ?! genetic

Diagnosis :
- Cl.picture :
  - Itching éout rash , sp. palms & soles
  - Jaundice (rare)
- Inv:
  - ++ bile acids
  - Mild + AST, ALT , Bilirubin

Ttt:
- Symptomatic : cold baths , antihistaminics
- Ursodeoxycholic acid tab
- Termination if : reach 36 weeks / occurance of labor pains / maternal or fetal complications

5) AFLP (acute & may be fatal)

Definition: fat deposition within liver cells in 3rd trimester ∴ affection of function +++AST & ALT

Incidence : extremely rare

Etiology : unknown ?! error of metabolism (enzymatic)

Cl.picture :
- nausea , vomiting , abdominal pain , jaundice
- hypoglycemia , HTN (PE)
- coagulopathy , DIC

Inv: ++PT , PC , INR , Bilirubin , AST , ALT , hypoglycemia

ttt: prompt delivery (serious condition) & ICU admission to support general condition

	6) HBV	7) HCV
virus	DNA virus	RNA virus
Vertical transmission	* Rare during pregnancy Mostly in 3rd trimester * during labor from infected maternal secretion	* < 5% risk * during labor if instrumental delivery é abrasions of baby
Treatment	* Duing pregnancy: Antiviral ttt in 3rd △ * VD is safe * Neonate **immediately** receives: → HBIG (passive) → HB vaccine (active immunization) * Breast feeding is allowed	* ttt is CI during pregnancy (teratogenic) * Breast feeding is allowed (except in cracked , bleeding nipples)

Prenatal diagnosis of congenital anomalies

Definition : In utero identification of structural or chromosomal (aneuploidy / non disjunction) abnormalities in the fetus for early management (ie early induction of abortion if needed , counselling of the parents to be prepared)

Indications: High risk cases needing screening

1) Maternal age > 35 yrs (more risky for Down syndrome)
2) Early exposure to teratogens (drugs , radiation , infection)
3) Previous H/O of anomalies in babies or family H/O of genetic disorders

NB : If screening test is positive → ∴ confirmatory test is needed



Screening Tests (cheap / non invasive / high sensitivity)	**Diagnostic (confirmatory) Tests (accurate / invasive / high specificity)**
1) Maternal serum biochemical markers :	**1) Chorion Villous Sampling : (trophoblastic tissue biopsy)**
- DMT : β HCG + PAPPA (11 – 13 wks) - TMT : β HCG + MSAFP + uE_3 (14 – 16 wks) - Quadruple test : same markers as TMT + Inhibin A (16 – 20 wks) NB : in Down syndrome all markers ↓↓↓ EXCEPT β HCG ↑↑↑	- vaginal (at 11wks) / abdominal (at 14 wks) - both TAS guided / abortion risk 2 %
	2) Amniocentesis: (Amniotic fluid & cells shedded obtained by needle US guided)
2) US :	- abdominal at 14-16 wks - risk of abortion 1% , infection , ROM , Pl.separation
- NT , presence of nasal bone (11-13 wks) (NT > 3mm , hypoplastic nasal bone in Down) - Other soft markers : as cardiac echogenic focus , pelvicalyceal dilatation , short femur , Tricuspid regurge (as in Down) (18-22wks)	**3) Cordocentesis : (Fetal blood sample , US guided)** - diagnostic & therapeutic in exchange transfusion in Rh isosensitization - abdominal at 16-20wks
3) Cell free Fetal DNA : (10 -11 wks)	**4) Advanced US (level 2)**
- used as screening & confirmatory - non invasive but expensive & not available in all centers - diagnostic only for 5 -12 chromosomes (including ch. 21, 13 , 18) , but not the whole 23pairs of ch. as other diagnostic tests as CVS & amniocentesis	- anencephaly , cystic hygroma , skeletal anomalies (11-13 wks) - major anomalies : NTDs , skeletal , cardiac , renal & GIT anomalies , diaphragmatic & ventral hernias (18-22 wks)
	5) Cell free Fetal DNA: (as before)

NB : PGD (Pre implantation genetic diagnosis):

Done in association with IVF procedure

Single cell at 8 cell stage or dozen cells in blastocyst stage :

→ stage can be taken with no damage to fetus , to provide DNA for PCR analysis for inherited genetic disorders.

" for diagnosis of anomalies before doing the embryo transfer & in preimplantation sex selection (in cases of sex linked anomalies)"

Prenatal diagnosis of Down syndrome

H/O : maternal old age

Screening	Confirmatory
10wks: Cell Free Fetal DNA **11 – 13 wks:** → DMT : ↑ β HCG + ↓ PAPPA → US: * NT > 3mm , * hypoplastic nasal bone **14-16 wks:** TMT: ↑ β HCG + ↓MSAFP +↓ uE_3 **18-22wks:** US: Other soft markers	**10wks:** Cell Free Fetal DNA **11wks:** Vaginal CVS **14-16 wks:** Amniocentesis

Fertilization , Implantation & Placenta formation

3) Fetal development → **Endoderm**, **Mesoderm**, **Ectoderm**

é

a) Placenta formation

b) Umbilical cord

c) Extraembryonic membranes (amnion /chorion)

d) Amniotic fluid (1.5 liters , 99% water)

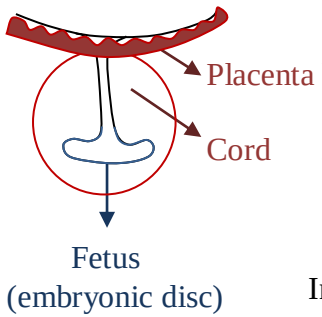

2) Implantation

1) Fertilization

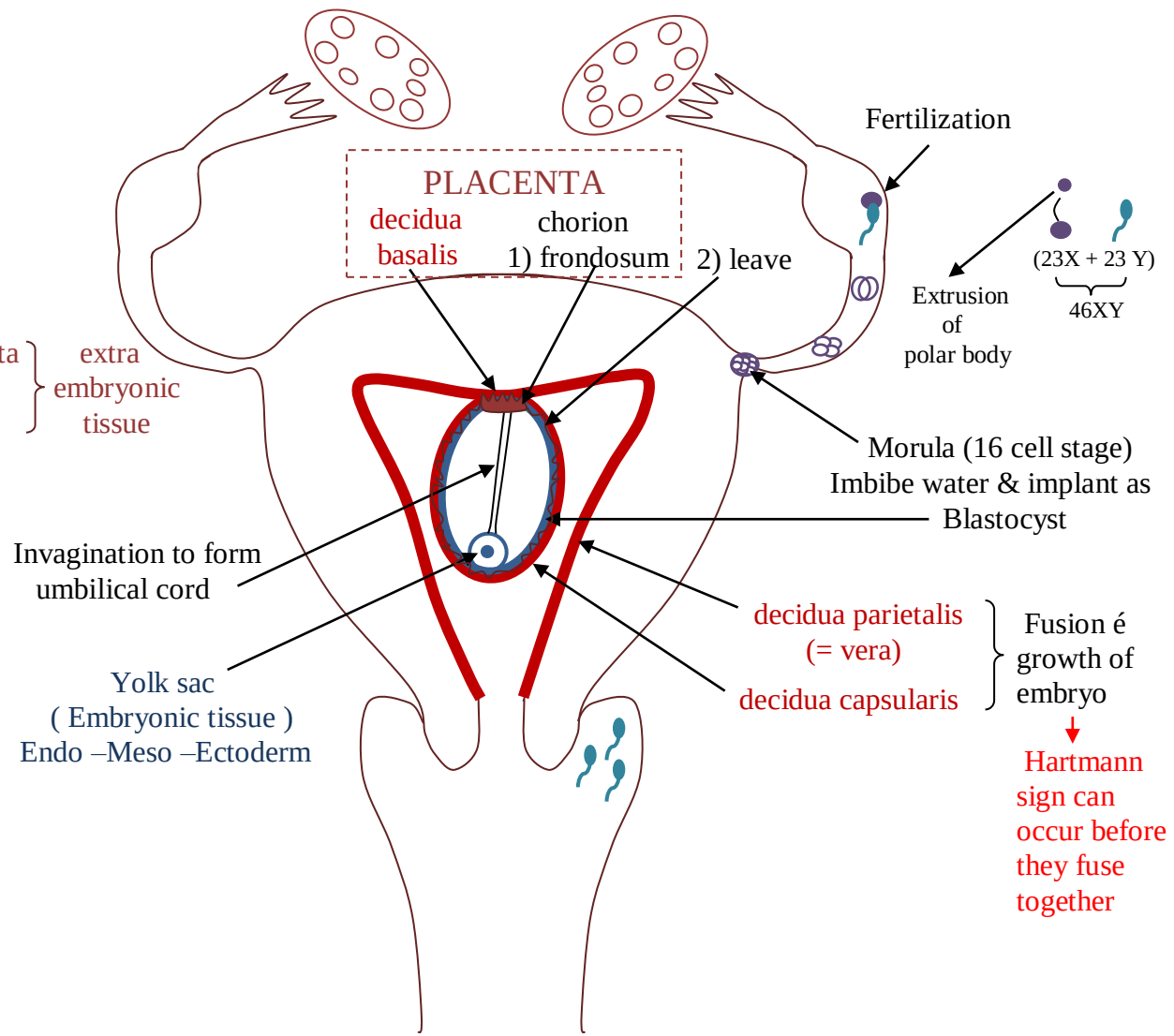

Placenta

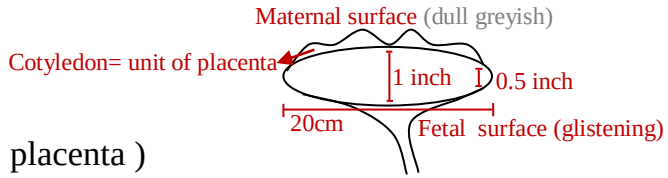

Definition : interface between mother & fetus
Formation : Chorion frondosum + decidua basalis
Gross: 20 cm diameter (discoid) , 500gm weight , formed of 10-38 cotyledons (unit of the placenta)

Functions:

1) Transfer :
- Simple diffusion : é conc gradiant as H_2O , O_2 , CO_2
- Facilitated diffusion : é carrier as glucose , ketones , FA
- Active transport : against conc. gradient as aa , Ca^{++} , Fe
- Pinocytosis : for large molecules as LATS , Ig

2) Endocrine :
- HCG : glycoptn to maintain CL of pregnancy in 1st△
- HPL : ptn , main metabolic hormone , provide glucose , aa , FA to fetus
- Estrogen : steroid for hyperplasia of ut ms , breast duct ↑PRL , ++ Oxytocin receptors
- PRG : steroid for hypertrophy of myometrium , decidua, Breast alveoli , oedema , immunological

5) Immunological : for fetal acceptance

Abnormalities :

1) In shape :
- Membranacea (diffuse / large) placenta (Circumvellate)
- Bilobate : 2 lobes é tissue inbetween
- Bipartite : 2 parts é membranes inbetween
- Succenturiate : one large part & another small accessory lobe (may be missed & retained in delivery)

2) In size & weight : ++ in $, hydrops fetalis , DM (> 600gm & > 5cm thickness)
3) In adhesions : accreta / increta / percreta
4) In implantation : on LUS = pl.previa
5) Pl.infarcts:
- White : fibrin deposition / calcium deposition
- Red: hge as in HTN

6) Calcification: with advanced aging of placenta

Umbilical cord

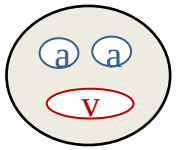

Definition : develops from the ventral (connecting) stalk ,measures 50cm , 1-2 cm diameter

Abnormalities :

1) Insertion :
- Marginal (battledore)
- Velamentous (in membranes)

2) Knots :
- False: accumulated Wharton's jelly (no complications)
- True :→ fetal asphyxia

3) Length :
- Too long (> 60 cm)→ cord prolapsed & true knots , loops around neck
- Too short (< 35 cm)→ prolonged 2nd stage of labor

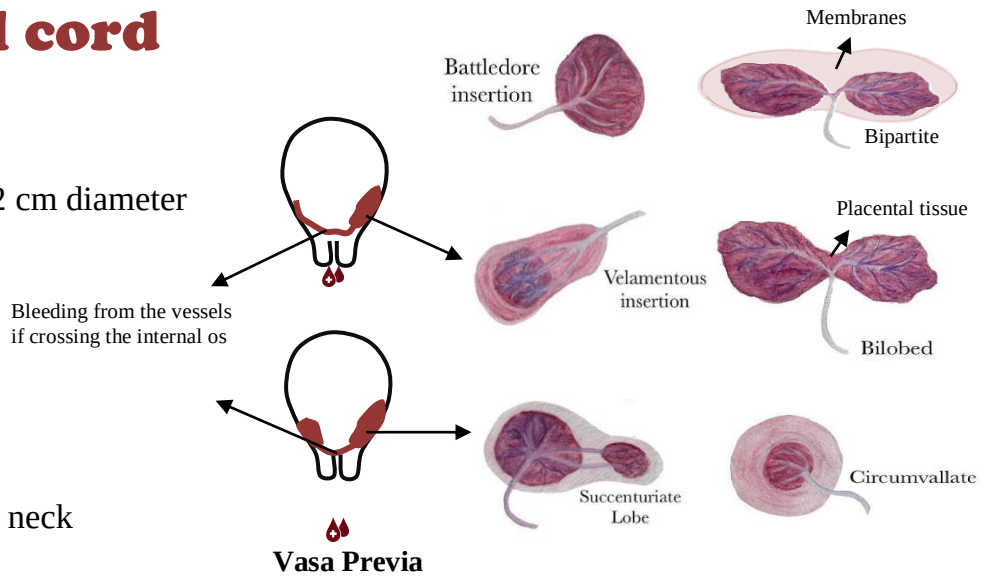

4) Vasa previa : Vessels crossing Cx . connecting placenta to another lobe as in velamentous insertion (If bleeding→ severe fetal distress ± death)

Diagnosis of pregnancy

1) β HCG detection :

** Urinary pregnancy test :*

1week after missed period

** Blood HCG :*

Quantitative : at time of missed period
± doubling

Qualitative : at time of missed period
(just +ve or –ve)

2) Ultrasound :

- TVS : at 5weeks (β HCG 1500 iu/ml)
- TAS : at 6weeks (β HCG 6500 iu/ml)

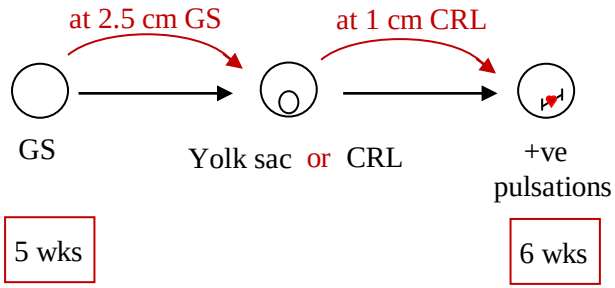

NB:

If the next step is not seen : rescan after 1wk

3) Abd exam : at 2nd trimester

- At 12 wks → FL at SP
- At 20-24 wks → FL at umbilicus
- At 36 wks → FL at XS

(Leopold maneuver & FHS auscultation)
When engagement occurs → FL ↓↓

NB : 4) PV : is not routinely done , only in certain situation as early vag bleeding , …

Physiological changes during pregnancy

Systems:

1) Respiratory :
- Hyperventilation

2) Cardiac :
- Apex change
- ±BP = CO×TPR
- Bl volume ↑↑ (Plasma > cells)

3) Blood:
- Hypercoagulable
- Stasis

4) GIT :
- Morning sickness
- Ptyalism (salivation)
- Heart burn
- Constipation

5) Urinary :
- Frequency in 1st / 3rd trimesters

6) Endocrine:
++ E_2 → ++ SHBG
∴ ++ Total form of hormones , but not free (active) form

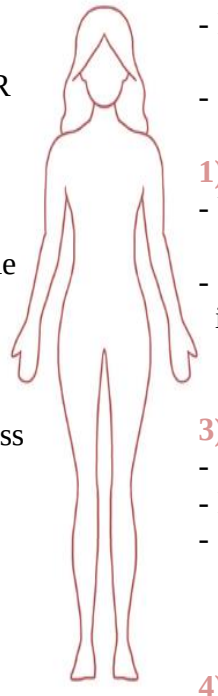

2) Breast :
- ↑ size / 2ry areola deep pigmentation / nipple
- Montgomery tubercles
- colostrum

1) Genital:
- Ut → UUS
  → LUS
- Cx , vag , vulva increase vascularity

3) Skin :
- Striae gravidarum
- Linea nigra
- chloasma of pregnancy

4) Back :
- Backache (lig relaxation)
- lordosis

5) LL:
- Oedema gravitational & compression

ANC

Def : program of preventive obstetric

Frequency :
/ month in 1st 6 months
/ 2 weeks in 7th & 8th months
/ week in 9th month

What to check ?

Return visits → BP/ BW
→ Leopold maneuvers / FHS
→ CBC / urine analysis

Booking → H/O (present /past / family)
→ Rh Blood group / CBC / LFTs
→ KFTs / FBS / urine analysis /
→ Hepatitis markers

Supplement :
1st trimester → folic acid
2nd , 3rd → Ca, Fe , Vit

Drugs & vaccines
- Preferable class B medications
- Only killed vaccines and Ig are given , while live attenuated vaccines are contraindicated

US :
- 1st T : single / living / intrauterine
- 2nd T : anomaly scan
- 3rd T : growth curves

Special care for high risk
- Elderly primi
- Grand multipara ≥ P5
- Medical disorders
- Obstetric complications

High risk pregnancies

* **Definition :** pregnancy that endangers health of mother / fetus or newborn

* **Examples :**

1) Elderly primi (> 35yrs) , pregnancy > 40 yrs old , grand multipara (≥ 5 deliveries)
2) Maternal medical condition : uncontrolled DM , HTN , cardiac , SLE, …
3) Obstetric problems: H/O of RPL, current APHge , ROM , PTL ,Placenta accreta, …
4) Fetal problems : anomalies , IUGR , Multiple pregnancies , …

* **Management :**

- More frequent ANC visits
- Delivery in specialized equiped place
- Management in pregnancy & labor accordingly

Maternal mortality in Egypt

* **Incidence :** 52 /100.000 deliveries as per year 2013 (number of maternal deaths due to Obstetric causes)

* **Common causes:**

1) obstetric hemorrhage : as PPHge 30% , as in Egypt
2) PE & Eclampsia : 15% , as in developed countries
3) puerpural sepsis : 3.5% , as in developing or very underdeveloped countries
4) others as pulmonary embolism , DIC , Cardiac problems ,…

Clinical History Taking

General sheet

Personal H/O : Name / Age / Marital status / Parity / Occupation / Residency / Special habits

C/O : in patient's own words (+ duration)

Present H/O :

Gynecological sheet	Obstetric sheet
1) Analysis of complaint (onset / course / duration) 2) Analysis of Pain / Bleeding / Mass 3) Ask about etiological F , symptoms & complications of your DD to reach a provisional diagnosis 4) Investigations & ttt done for this patient 5) Review of other systems involvement	1) LMP EDD ± GA 2) Analysis of 1st trimesteric symptoms → Vomiting → Bleeding → Frequency of micturition 3) Analysis of 2nd trimesteric symptoms → Quickening → Relieve of 1st trimesteric symptoms 4) Analysis of 3rd trimesteric symptoms: ⚠ (warning symptoms) ⚠ 5) Analysis of C /O (if present) 6) Investigations & ttt done 7) Review of other systems

WARNING SYMPTOMS

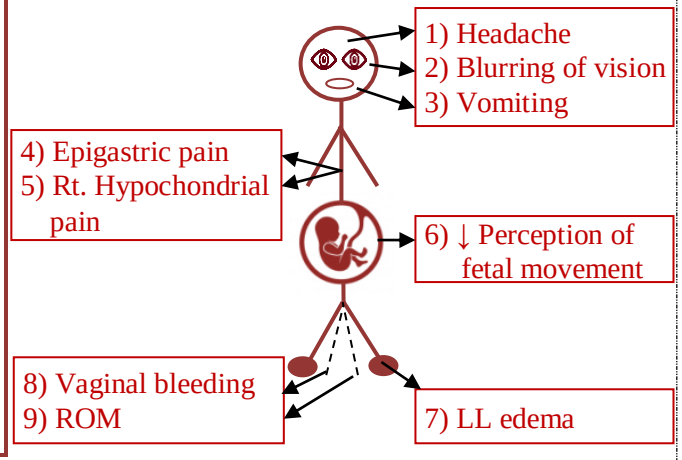

Past H/O: → Medical : medical disorders prior to C/O
→ Surgical : operations done prior to C/O

Family H/O : of similar condition / consanguinity

Menstrual H/O : menarche / menstrual index eg : $^{3}/_{28}$ / dysmenorrhea / intermenstrual bleeding

Obstetric H/O :

F	P	A	L
> 36 wks	24-36	< 24	now

/ GPL / history of contraceptions

eg:

Year of pregnancy	GA at termination / delivery	Outcome	Mode of delivery / termination	place	Pregnancy complications	Postpartum complications	lactation
1999	± 8 wks	abortion	SE	KA	NO		
2003	± FT	L ♀	VD	home			Failure of lactation
2007	± 28wks	SB ♂	CS	Private clinic		Wound sepsis	

IUD

OCPs

Provisional diagnosis : patient's name ثلاثي / Age / GPL / complaint in medical terms (+ duration) / provisional diagnosis / relevant medical problems / relevant surgical operations

Examples of certain sheets:

I. Bleeding sheet

Personal history : as general sheet
Complaint: Excessive or Irregular or Excessive irregular vaginal bleeding for how long
Present history:

- Analysis of the complaint:(menorrhagia, metrorrhagia, menometrorrhagia)
  - onset, course ,duration , amount of bleeding (number of pads, clots)
- Analysis of other related gynecological complaints :
  - pain (type,site,radiation,severity,…..)
  - mass (onset, course, duration,site,..)
  - discharge (amount, colour, odour ,itching)
- Analysis of the causes :
  - preceding event e.g. period of amenorrhea, I.U.D. insertion, injectables
  - contact bleeding
  - bleeding from other body orifices, ecchymosis
  - thyroid disorders
  - heart disease (dyspnea ,palpitation ,L.L.O. ,….)
  - hypertension
- Analysis of the Consequences: anemia (dyspnea, easy fatigability, blurring of vision)
- Analysis of investigations and treatment : U/S, D&C, CBC, coagulation profile
- Review of other systems.

Menstrual, Obstetric, Past, Family history, Diagnosis: **as general sheet**

Modifications in a case of postmenopausl bleeding

Personal History: if widow or divorced should be stated
Complaint: vaginal bleeding after ……. years of cessation of menstruation.
Present history:

- Duration of menopause
- Symptoms suggestive of distant metastasis:
  - Lung (cough , hemoptysis,..) Liver (rt hypochondrial pain , jaundice)
  - Bone (aches and pathological fractures) Brain (projectile vomiting , headache,…)
  - G.I.T. symptoms (vomiting , constipation , bleeding per rectum)

II.Genital prolapse sheet

Personal history: as general sheet
Complaint: mass protruding from the vulva , sense of heaviness + duration
Present history:

- *Analysis of the complaint:*
  - Onset , course , duration,
  - effect of straining and lying down, (mention if the onset was following delivery)
- *Analysis of other gynecological symptoms:*
  - bleeding(menorrhagia)
  - pain (congestive dysmenorrhea)
  - discharge (leucorrhea)

  N.B. these are the triad of pelvic congestion due to prolapse.
- *Analysis of the consequences :*
  - urinary symptoms: frequency, nocturia, dysuria, sense of incomplete evacuation, urine retention, loin pain, pyelonephritis, stress incontinence, inability to complete micturition except after digital reduction of the mass.
  - rectal symptoms: inability to complete defecation except after digital reduction of the mass , constipation , incontinence to flatus or stools (if associated with complete perineal tear)
  - sexual troubles: dyspareunia
  - backache (traction on uterosacral ligaments in uterine prolapsed)
- *Analysis of the Causes:*
  - precipitating factors: chronic cough , chronic constipation, obesity
  - predisposing factors: symptoms suggestive of weak mesenchyme e.g. hernia, flat foot, varicose v.
- *Analysis of investigations and treatment:* previous repair , use of pessary
- *Review of Other systems:*

In Obstetric history: It is important to ask whether her deliveries were difficult and prolonged ended with use of forceps or ventouse, delivery of macrosomic baby

Menstrual, Past, Family history, Diagnosis: *the same as general sheet*

III. Infertility sheet

Personal history **As general sheet plus**

- ask about previous marriage
- children from previous marriage
- the age of the youngest child
- husband personal history: age/ occupation/ smoking/ another marriage and the age of the youngest child from the other marriage.

Complaint:Failure of conception for …….. years despite of regular marital life

Present history:

- *Duration of her current marriage:*
- *Analysis of the causes:*
  - ***Male factor of infertility:***
    - semen analysis (results, time) - treatment (nature, duration, result)
    - previous operations (hernia, varicocele) - medical disorders and drugs.
  - ***Ovarian factor:***
    - symptoms suggestive of ovulation (regular cycles ,spasmodic dysmenorrhea, premenstrual mastalgia, intermenstrual bleeding ,pain and discharge)
    - hirsuitism , oligomenorrhea ,hypomenorrhea (P.C.O.)
    - symptoms suggestive of ovarian failure (hot flushes , nervousness , bony aches)
  - ***Tubal factor:***
    - symptoms suggestive of salpingitis (bilateral lower abdominal pain associated with offensive vaginal discharge, fever and chills)
    - previous abdominal operations that may lead to adhesions
  - ***Uterine factor :***
    - previous dilatation and curettage followed by decrease in the amount of menstrual flow (suggestive Asherman syndrome)
  - ***Cervical factor***: vaginal discharge + backache, erosion, cautery, cervical amputation
  - ***Sexual factor***: Fequency per week, Dyspareunia (superficial or deep), vaginismus, effluvium seminis
- *Analysis of investigations and treatment :*
  - Investigations as: hormonal profile, hystrosalpingography , sonohystrography, premenstrual endometrial biopsy, folliculometry, laparoscopy (mention the results)
  - Induction of ovulation : tablets, injections, how long,
  - History of Tuboplasty
  - Previous ART (IUI, ICSI)
- *Review of other systems:* General or Endocrine as thyroid dysfunction, DM, TB, Hyperprolactenemia

Menstrual, Obstetric, Past, Family histories and Diagnosis: as General Sheet.

IV. Primary Amenorrhea sheet

***Personal history*:** As general sheet

Complaint: Non occurrence of menstruation Or Absence of menstruation

Present history:

- *Analysis of the complaint* a case of primary amenorrhea till age of ….
- *Development of secondary sexual characters :* breast development, pubic hair, axillary hair
- *Analysis of the cause:*

➢ Hypothalamic cause: psychological disorders, stress, anosmia, head trauma, drugs

➢ Pituitary causes: galactorrhea , symptoms suggestive of increased intra cranial tension, visual field changes

➢ Ovarian causes: hirsuitism, deepening of voice , pelvi-abdominal mass

➢ Uterine causes: History suggestive of T.B.(night fever ,night sweat, loss of weight, loss of appetite)

➢ Out flow obstruction (cryptomenorrhea): cyclic lower abdominal pain , progressive abdominal swelling, if +ve ask about urine retention .

➢ General causes: thyroid dysfunction, DM, severe debilitating disease

- *Analysis of investigations and treatment:*

  ➢ Hormonal profile, ultrasound, IVP, MRI

  ➢ Progesterone withdrawal

  ➢ E .+P. withdrawal

- *Review of other systems*

No menstrual or obstetric history
Family history: ask about similar condition in the family (her sisters)
***Past history and Diagnosis*:** as general Sheet

Modifications in case of 2ry amenorrhea

Personal history: as above
Complaint: cessation of menstruation for …..(how long)
Present history:

- *Exclusion of pregnancy:*
  - pregnancy symptoms (nausea, vomiting, abdominal enlargement)
  - pregnancy test

- *Analysis of the last pregnancy event:*
  - post partum hemorrhage (amount , cause, blood transfusion)
  - puerperal sepsis (fever , offensive lochia)
  - in case of abortion ask about (fever , D&C, offensive discharge)

- *Hormonal treatment:* e.g. injectable contraception

- *Hypothalamic cause:* psychological troubles

- *Pituitary cause:*
  - galactorrhea
  - symptoms suggestive of pituitary adenoma (increased I.C.T. , visual field changes)

- *Ovarian cause :*
  - hirsuitism , deepening of voice , pelvi-abdominal mass
  - hot flushes , nervousness, bony aches

- *Uterine cause:*
  - Symptoms suggestive of T.B.
  - history of D&C (over curettage suggestive of Asherman syndrome)

- *General cause:*
  - As 1ry amenorrhea

Menstrual history taken about menstrual condition before amenorrhea



رقم الإيداع : 2021 / 23473

I.S.B.N : 978-977-203-4062

جميع حقوق الملكية الفكرية و النشر محفوظة

هذه النسخة للتداول الإلكتروني فقط