

KASR EL-AINI

Essentials of
GYNAECOLOGY

Department of
Obstetrics and Gynaecology
Cairo University

Kasr El Aini

ESSENTIALS OF GYNACOLOGY

Fifth Edition 2020

Professor ABDELMEGUID RAMZY

*Professor of obstetrics and Gynaecology - **Cairo University***

Head of editorial board 2019-2020



Chief Editor

Professor KHALED RASHEED

*Professor of Obstetrics and Gynaecology **Cairo University***

Advisory and IT Committee

*Professor **Hossam Badrawy***
*Professor **Ihab Soliman***
*Professor **Ahmed Elminawy***
*A. Professor **Moaataz Elsherbiny***

Honorary Committee

*Professor **Nabil Abdelhakim***
*Professor **Mohammed Abdelhady***
*Professor **Mohammed Elmeleigy***
*Professor **Raafat Reyad***

Editorial Board

*Professor **Reda Ismail***
*Professor **Gamal Abdelsamei***
*Professor **Tarek Fawzy***
*Professor **Magdy Ibrahim***
*Professor **Alaa Elabrashy***
*Professor **Ahmed Soliman***
*Professor **Mamdouh Sheeba***
*Professor **Mahmoud Salem***
*Professor **Nadin Alaa***
*Professor **Sherif Negm***
*Professor **Mostafa Abdelbar***
*A. Professor **Reham fouad***

Department of Obstetrics and Gynaecology
Cairo University
2020

LIST OF CONTRIBUTORS

Staff members of the department of Ob GYN – Cairo University

In alphabetical order

- Abdelhamid Attia
- Adel Farouk
- Ahmed Abdelmeguid
- Ahmed Mahmoud
- Akram El adawy
- Alaa El Ebrashy
- Ashraf Younis
- Essam Abolfotouh
- Fadel Shaltout
- Fouad Abohamila
- Gamal Abdelsamaei
- Gamal Eid
- Gamal Youssef
- Hany El Didiy
- Hazem Ashamawy
- Hesham Badawy
- Hesham Mourad
- Inas Abdelhamid
- Ismail ElEsseily
- Khaled Abdekmalek
- Khaled Rasheed
- Magdy Ibrahim
- Maha Mosaad
- Mahmoud Salem
- Moaataz Elsherbiny
- Mohamed Abdelhady
- Mohamed Abolkassem
- Mohamed Ihab
- Mohamed Momtaz
- Mohamed Osman
- Mohamed Aly
- Mohamed Iismail,
- Mona Fawzy
- Mostafa Abdelbar
- Moustafa Abdelhamid
- Moustafa Metwally
- Nadin Alaa
- Omar Abdelaziz
- Omayma Idris
- Reham fouad
- Salah Sanad
- Samah Abolgheit
- Sameh Zaki
- Sherif Khattab
- Sherif Negm
- Somaya hassan

Preface to the fifth Edition

Hello dear students.

This is the 5th edition. Our book is now 15 years old, but is even growing younger, as we are keen to update the information within in accordance with the latest studies in our field. You will find in the current edition, in an appealing form, full of illustrations whether in the book itself or on the adjoining CD.

This edition, in its final version, met my vision into upgrading the book into the digital mobile platform. So that you, can study anywhere and any place you go, make it on the road, in the coffee shop, or club.

In addition I asked our active editorial board to add quick response codes (QR) alongside each chapter to link to external sources for optional further reading and explanatory videos. This will help broaden your vision on the topic for better understanding the facts and make it easier for you to accumulate the knowledge and retain the information in accordance with scientific fact stating that the brain assimilates knowledge more readily in a picture form.

Thanks to the enthusiasm and perseverance of the editorial board, headed by Prof. **Khaled Rasheed**, and the valuable contribution of the faculty members of the department in Cairo University, this edition in its final version met my expectations, and I hope it will meet yours as well.

• • •••book is a valuable addition to our department's efforts to upgrade our education standards to meet and hopefully surpass the most recent education advances worldwide.

This book will be a valuable learning tool for both our undergraduate students as a requirement, as well as for our postgraduate students as a baseline for further reading sources.

I hope you make good use of this rich source of medical information both in your undergrad education and in your practice later on in your career

Abdel Maguid Ramzy

Head of department of Obstetrics and Gynaecology 2018-2019

Faculty of medicine, Cairo University

CONTENTS

	Page
BASIC GYNEACOLOGY	
1. Gyn. History and Examination	1
2. Anatomy of the Female Genital Tract	9
3. Development of the Female Genital Organs	27
GYNAECOLOGIC ENDOCRINOLOGY	
4. The Menstrual Cycle an Associated Disorders	35
5. Puberty and its Disorders	47
6. Menopause and Associated Disorders	51
7. Amenorrhoea	57
8. Hirsutism	69
9. Chronic Anovulatory Disorders and PCOS	79
FEMALE GENITAL TRACT INFECTIONS	
10. Female LGT Infections	81
11. Female UGT Infections	92
12. Sexually Transmitted Diseases	100
GENERAL GYNAECOLOGY	
13. Infertility and Assisted Reproduction	108
14. Contraception and Family Planning	121
15. Benign Conditions of the Vulva and Vagina	133
16. Pelvic Organ Prolapse	141
17. Perineal Lacerations	153
18. Urinary Incontinence	158
19. Abnormal Uterine Bleeding	171
GYNAECOLOGIC ONCOLOGY	
20. Uterine Leiomyomas	179
21. Endometriosis and Adenomyosis	191
22. Screening for Premalignant Lesions of FGT	199
23. Endometrial Carcinoma and Uterine Sarcoma	205
24. Invasive Cancer of the Cervix	215
25. Malignancies of the Vulva and Vagina	223

26. Non Neoplastic Ovarian Swellings 227

27. Benign Ovarian Neoplasms 234

28. Malignant Ovarian Neoplasms 244

DIAGNOSTIC PROCEDURES AND OPERATIONS IN GYNAECOLOGY

29. Imaging Techniques in GYN 256

30. Endoscopy in GYN 262

31. Differential Diagnosis In Gynaecology 266

- Uterine polypi
- DD of a Pelvi-abdominal Masse
- DD of an Adnexal Swelling
- DD of a mass in the Pouch of Douglas
- Gynaecologic causes of Acute Abdomen and Chronic Pelvic Pain

32. Operative Gynaecology And Postoperative Complications 273

01 GYNAECOLOGIC HISTORY AND EXAMINATION

- *Gynaecologic History*
- *Gynaecologic Examination*
- *Commonly used Diagnostic Investigations*

GYNAECOLOGICAL HISTORY

The most important evidence is always provided by the history given by the patient or one of her attending relatives. In many cases a provisional diagnosis can be reached before starting detailed physical examination.

1. PERSONAL HISTORY:

- Patient's name, age, address, occupation, marital status, gravidity and parity
- Special habits of medical importance

2. COMPLAINT:

Complaint is best written in the ***patient's own words*** as; excessive vaginal bleeding, pelvic pain, painful intercourse, progressive abdominal enlargement, mass filling or protruding from the vagina, excessive vaginal discharge, vaginal itching or burning sensation, low back ache, swelling of lower limbs, etc...

3. PRESENT HISTORY:

- Analysis of the **onset, course,** and **duration,** of the **present complaint**.
- Ask about **symptoms** relevant to, or associated with, the **present complaint**.
- Ask about **symptoms** related to **other body system affection** as; urinary, GIT, cardiac, pulmonary, neurologic, etc...

4. PAST HISTORY:

A) Medical Disorders:

- *Systemic disease:* hypertension, diabetes mellitus, cardiac, renal, or liver disease.
- *Endocrine disorders:* especially thyroid and adrenal disorders.
- *Blood dyscrasias:* as ITP & von Willebrand disease (VWD).

B) Drugs and Medications: as ongoing medical or hormonal therapy.

C) Surgical Procedure:

- *Gynaecologic & Obstetric procedures;* D&C, CS, Myomectomy, Hysterectomy, Laparoscopic and hysteroscopic procedures.
- *Relevant Surgical procedures:* as pelvic surgery (appendicitis, peritonitis, pelvic masses) and bariatric procedures (gastric banding, and sleeve operations)
- *Other Surgical procedures:* thyroidectomy, breast lumps, cholycystectomy, etc...

5. MENSTRUAL HISTORY:

- ***Age at menarche:*** normally 11-13 years
- ***Cyclic pattern:*** normally every 25-32 days (mean 28 days)
- ***Duration of bleeding:*** normally 3-5 days.
- ***Amount:*** 30-50 ml/cycle, changing 2-3 blood soaked diapers/day.
- ***Character of bleeding:*** usually dark in colour with no or minimal clots.
- ***Dysmenorrhoea:*** Menstrual pain and its relation to the onset of bleeding.
- ***Last menstrual period (LMP):*** calculated from 1st day of onset of menses.

6. OBSTETRIC HISTORY:

- ***Previous pregnancies and deliveries*** in sequence of their occurrence.
  - *Duration of each gestation* (term, preterm, or abortion)
  - *Route of each delivery:* vaginal delivery (VD), or caesarean section (CS)
  - *The condition of the newly born:* living, still born (SB), or neonatal death (NND).
  - *Complications related to pregnancy, delivery, and puerperium;* as gestational diabetes, hypertension, haemorrhage and sepsis.
- ***Previous abortions:***
  - *Duration of pregnancy at occurrence of each abortion* (1st or 2nd trimester)
  - *Method of termination* (spontaneous, medical, or surgical termination).
  - *Post-abortive complications* (bleeding, sepsis, infertility, etc...)
- ***The Obstetric Code:*** The obstetric history can be described for simplicity by either;
  - ***The 4 digit code*** (0000):
    - *First 3 digits:* stand for duration of pregnancies (term, preterm, & abortions).
    - *The 4th digit:* stands for number of living offspring.
  - ***The Gravidity / Parity code*** (G0/P0):
    - *Gravidity* describes the *number of pregnancies*, including the current pregnancy if present (term + preterm + abortions).
    - Parity stands for *number of previous deliveries* (term + preterm).
- ***If present pregnancy is ongoing:*** establish LMP, EDD, and complaints related to each trimester.

7. COITAL HISTORY: Particularly in cases of infertility.

- Frequency of sexual intercourse (times /week)
- Associated symptoms; as presence of dyspareunia (painful intercourse).
- Husbands age, occupation, and any previous investigations for male infertility, previous marriage and children .

8. CONTRACEPTIVE HISTORY:

Methods used, by both partners, duration of its use, and time of its termination.

9. FAMILY HISTORY:

Inherited diseases, genetic disorders, and hereditary malignancies

GYNAECOLOGIC EXAMINATION

1. GENERAL EXAMINATION:

- General medical examination; measurement of the Pulse, temp, and B.P.
- Gait, height, weight, and body mass index (BMI) = weight kg /height in meter square
- Hair distribution and development of the secondary sexual characters.
- Breast examination is an important part of any gynaecological examination.
- Inspection of the back: for spina bifida, hair tuft, severe kyphosis, or scoliosis.

2. ABDOMINAL EXAMINATION: bladder should be empty

- ***Inspection:*** abdomen exposed from costal margin till symphysis pubis;
  - Abdominal masses, scars of previous operations, pigmentation, etc...
  - Hernia orifices, and divarication of the rectii muscles (during straining)
- ***Palpation of all abdominal quadrants***
  - ***9 quadrants:*** (right and left hypochondruim, right and left lumbar, right and left iliac fassa, hypogastrium, umbilical, and suprapubic regains)
  - ***4 quadrants:*** (right and left upper quadrant and right and left lower quadrants)
  - Palpation for enlarged liver, spleen, renal, abdominal, and pelviabdominal masses.
- ***Percussion of the abdomen:***
  - Normally there is resonance in the centre and in the flanks due to air in intestinal loops.
  - Tumours show uniform dullness all over the tumour area.
  - Moderate ascites shows central resonance (floating bowel) with dull flanks (fluid). Shifting dullness will occur when patient is turned on her side with upper flanks becoming resonant (due to shift of ascites to more dependent parts and intestines floating over fluid).
  - Tense ascites gives generalized dullness on percussion (fluid everywhere).

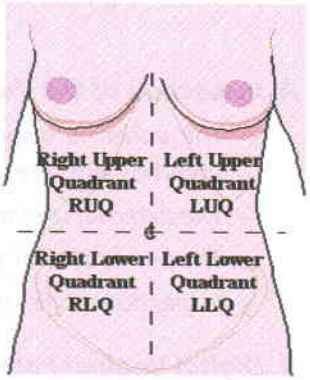

Fig 1-1: 4 quadrants of the abdomen

3. BREAST EXAMINATION

Breast examination is an integral part of a comprehensive gynaecologic examination. It is an important method for both **screening** for benign and malignant breast tumours, and **diagnosis** of breast conditions as a breast lump, fibrocystic breast disease, mastitis, breast abscess, and galactorrhoea.



Fig 1-2: Breast examination

A) Inspection: with patient in upright position, for contour, symmetry, skin changes or nipple retraction.

B) Palpation: with patient in upright then supine position, of

- The 4 breast quadrants, areola, and nipple with the flat of the hand.
- Each axilla is examined for lymph node groups (medial, lateral and apical) while the patient's arm is supported.
- The supraclavicular fossae are also palpated for lymphadenopathy.

C) Investigations in case of presence of a suspicious lesion include:

- Breast Ultrasonography: especially 3D US for primary diagnosis and follow up
- Mammography & MRI: for highly suspicious palpable lesions and high risk cases (e.g.; BRCA gene positive women)
- Tumour marker as CA 15.3 may be also used.

4. LOCAL EXAMINATION

- Patient's attendance is by itself considered consent for a pelvic examination. However presence of a third party (a female relative or a nurse), is ethically important.
- The patient's bladder must be empty, and only disposable gloves should be used.
- Instruments used are either ***disposable*** or should be ***sterilized by autoclaving***, to avoid the risk of transferring infecting vaginal organisms from one woman to another.
- The patient is examined locally while lying down in the lithotomy position (see fig1-1)



Fig 1-3: Lithotomy position



Fig 1-4: Inspection of the vulva

A. Inspection of the Vulva and Perineum:

- *The vulva:* is inspected for anatomical abnormalities, swellings, tumours, warts, or ulcers, together with presence of abnormal vaginal discharge or bleeding.
- *The external urethral meatus:* for any redness, discharge, or presence of urethral caruncle.
- *The perineum:* for old lacerations, and the presence of piles around the anal orifice.
- *Inspection while straining:* for presence of genital prolapse and stress incon-tinence.

B. Digital Vaginal Palpation (PV):

The index finger is inserted into the vagina first, and as the patient relaxes, it is followed by the middle finger, and together slope gradually deeper in the vagina following its direction (upwards and backwards). As the fingers are withdrawn, the following structures are palpated:

- *The cervix:* noting its size, consistency, mobility, direction, and level. Presence of lacerations, hypertrophy, dilatation, and any descent on straining, or any contact bleeding.
- *The vaginal walls:* palpated for any mass, ulcer, or fistulous opening.
- *The bladder and urethra:* can be palpated through the anterior vaginal wall.
- *The rectum and pouch of Douglas:* can be palpated through the posterior vaginal wall.
- *Bartholin's glands:* are palpated to detect any swelling.
- *The condition of the levators ani muscles:* can be determined by two fingers in the vagina, and the thumb on the perineum. Ask the patient to cough and feel the muscle as it contracts.



Fig 1-5: PV Examination



Fig 1-6: Bimanual Examination

C. Bimanual Pelvic Examination:

The index and middle fingers of the right hand are placed in the anterior vaginal fornix, while the left hand is placed flat on the abdominal wall.

1. Examination of the Uterus:

The vaginal fingers of the right hand should push the cervix upwards, rotating the fundus forwards. The abdominal hand is placed below the umbilicus and gradually moved lower suprapubically until the fundus is caught and pressed against the fingers of both hands in the anterior fornix, in AVF uterus, or at the posterior fornix in RVF uterus.

2. Examination of the Adnexae and Vaginal Fornices:

The fingers of the vaginal hand move towards one lateral fornix with the abdominal hand following, trying to gently squeeze the adnexa to palpate any masses, swellings, or elicit tenderness. The same procedure is then repeated in the other lateral fornix.

3. Examination of the Pouch of Douglas:

The vaginal hand is moved to the posterior fornix, while the abdominal hand follows trying to reach the vaginal fingers behind the uterus suprapubically

- **Points to be Determined During Bimanual Pelvic Examination:**

  - **Uterine Size, Shape, Consistency, and Contour:** the uterus is a pear shaped organ with firm consistency, and smooth outer contour. It normally measures nearly 7.5 X 3.5 X 5.5 cm in Long/AP/Transverse, diameters. It may be felt with difficulty in women with marked trunk obesity.

  - **Uterine Position:** The uterus is commonly Anteverted flexed (**AVF**) in position, with the external os pointing towards the posterior fornix. In nearly 20% of cases the uterus is retroverted flexed (**RVF**), with the external os pointing towards the anterior fornix.

  - **Uterine Tenderness and Mobility:** The uterus is slightly tender when squeezed between the two hands. It is normally mobile, but might be fixed with adhesions or pelvic masses.

  - **Presence of Adnexal Tenderness, Fullness, or Masses:**

    - The normal tubes are never palpable even in the very thin patient, while the normal ovaries can be felt in the thin patient, in absence of pelvic tenderness.

    - Presence of adnexal tenderness, fullness, or masses (cystic or solid), is always abnormal, and should raise suspicion for presence of pelvic pathology as; PID, ectopic pregnancy, and tubo-ovarian masses.

  - **Evaluation of vaginal discharge:**

    - The amount and character of vaginal discharge, if present, are noted on the examining fingers while being withdrawn outside the vagina at the end of vaginal examination.

D. Speculum Examination:

Inspection of the cervix and vaginal walls is achieved by the aid of a vaginal speculum. The one commonly used is the self retaining Cusco's bivalve speculum, which is inserted directly without rotation (remember that the vagina is wider from side to side than from front to back).

The cervix is inspected to detect ectopy, laceration, polyp or ulceration.



3. Opening to view cervix *2. Inside vagina* 1. At the introitus

Fig 1-7: Speculum examination

E. Rectal Examination (PR)

Rectal examination is indicated in:

1. Examination of virgins.
2. In cancer cervix; to detects extens-ion to parametrium along the uterosacral ligament.
3. In cases of prolapse: to detect presence of rectocele and exclude presence of enterocele.
4. Cases with complete perineal tears if diagnosis is not sure by inspection alone.
5. Cases with mass in Douglas pouch.
6. Cases with postmenopausal bleed-ing (piles, cancer rectum).
7. Any patient complaining of rectal symptoms.



Fig 1-8: PR examination

COMMONLY USED DIAGNOSTIC INVESTIGATIONS IN GYNAECOLOGY

A) DIAGNOSTIC IMAGING PROCEDURES

1. ULTRASONOGRAPHY (US): *see imaging in gynaecology*

US may be performed transabdominally (TAS) or transvaginally (TVS), either in a two dimensional scan (2D US), or more recently in a three dimensional scan (3D US). It is the most often diagnostic tool used in both obstetrics and gynaecology, with a very high degree of accuracy and safety.

2. CT and MRI:

Computerized axial tomography **(CT)** and magnetic resonance imaging **(MRI)** may confirm US findings, in addition to assessment of lymph node affection in gynecologic malignancies. They have generally a limited place in gynaecology compared to US.

3. HYSTEROSALPINGOGRAPHY (HSG): *see imaging in gynaecology*

HSG is performed via injection of a radio-opaque dye into the uterine cavity, using a special cannula, to examine the uterine cavity, and to detect tubal patency *(see also infertility).*

B) DIAGNOSTIC ENDOSCOPY PROCEDURES

1. COLPOSCOPY:

Examination of the cervix and vagina via special magnifying lens instrument allows detection of cervical lesions at the squamo-columnar junction *(see premalignant lesions CIN).*

2. HYSTEROSCOPY:

Insertion of a special endoscope via the cervical canal, with a light source and video camera, allows inspection of the endometrial cavity and tubal orifices, together with performing some operative procedures *(see endoscopy in gynaecology).*

3. LAPAROSCOPY:

Insertion of a special endoscope through the abdominal wall, under general anaesthesia, with a light source and a video camera, allows visualization and inspection of the pelvic organs, together with performing some operative procedures *(see endoscopy in gynaecology).*

C) OFFICE DIAGNOSTIC PROCEDURES

1. VAGINAL SWAB:

For obtaining vaginal discharge for culture and sensitivity using cotton bud stick

2. PAP SMEAR:

For obtaining cells from the endocervix and ectocervix, using cytobrush and wooden spatula, stainad by Papanicolau stain for early detection of premalignant and malignant cervical lesions.

3. OFFICE ENDOMETRIAL BIOPSY:

For obtaining cells from the endometrial lining using endometrial pipelle instrument for histopathological examination.

EXAMINATION UNDER ANAESTHESIA (EUA)

When pelvic examination is difficult or impossible, examination will be made easier with relaxed patients abdominal wall and vaginal introitus yielding better data for diagnosis.

LAPAROTOMY:

Sometimes the diagnosis is so much in doubt to the point that justifies opening the abdomen to visualize the internal genital organs. It is not justifiable to do this, however, unless it is reasonably certain that some organ requires surgical attention.

C) LABORATORY TESTS

- **HORMONAL ASSAYS**
  - *Chorionic Gonadotrophins:* urinary hCG, serum B-hCG
  - *Pituitary Gonadotrophins:* serum FSH & LH.
  - *Other Pituitary Hormones:* serum PRL, TSH, GH, & ACTH
  - *Ovarian Hormones:* serum E2, PRG, Inhibin, AMH, & Testosterone.
  - *Adrenal Hormones:* DHEAS, serum Cortisol.
- **TUMOUR MARKERS**
  - *CA 125*
  - *AFP: Alpha Fetoprotein*
  - *CEA: Carcino Embryonic Antigen*
- ***Units of Measurements in Hormonal Assay***

Test	Unit
FSH & LH	mIU/ml
PRL	ng/ml
PRG	ng/ml
E2	pg/ml
T3, T4	ng/dl
FT3	pg/ml
FT4	ng/dl
T	ng/ml

02 ANATOMY OF THE FEMALE GENITAL TRACT

- *The vulva*
- *The vagina*
- *The uterus*
- *The fallopian tubes*
- *The ovary*
- *The ureter*
- *The uterine ligaments*
- *The cervical ligaments*
- *The pelvic floor muscles*
- *The perineum*

I. ANATOMY OF THE VULVA

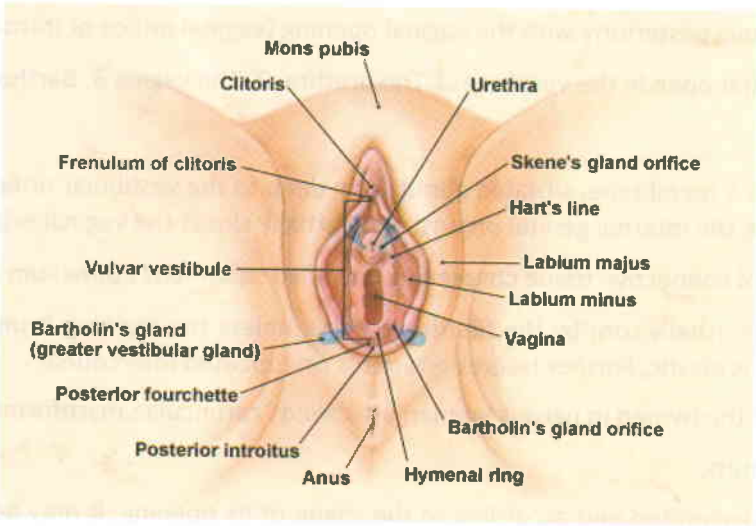

Fig. 2-1: The vulva

female external genital structures are collectively called the vulva and consist of:

1. Mons Veneris: Is the pad of fat overlying the symphysis pubis and covered by skin & hairs.

2. Clitoris:

- The clitoris is an erectile cavernous structure situated below the symphysis pubis. It is homologous to the penis in the male, and is formed of a small glans and a body (formed of two corpora cavernosa).
- The glans is a sensitive structure and is covered by the folds of clitoris that are the biforked anterior end of the labia minora (prepuce above and frenulum below the glans).

3. Labia Majora:

- They are the outer two skin folds, raised by underlying fat, and passing back from the mons veneris to the perineum. The outer skin is covered by hairs while the inner medial surface is smooth, hairless and contains sebaceous and sweat glands.
- They are homologous to the scrotum in the male, and contain fat and Bartholin's gland.

4. Labia Minora:

- These are two thin folds of modified skin situated medial to the labia majora.
- They vary in size, are larger in children, and contain loose connective tissue devoid of fat
- The labia minora are very vascular and become turgid during coitus.
- **Anteriorly:** they divide into two folds (prepuce and frenulum of glans).
- **Posteriorly:** they meet to form the fourchette that is separated from the hymen by a depression known as the "fossa navicularis".

5. Vestibule:

- The vestibule is the area between the inner aspects of the labia minora and the fourchette.
- It is continuous posteriorly with the vaginal opening (vaginal orifice or introitus).
- Structures that open in the vestibule: 1.The urethra. 2. The vagina 3. Bartholin's glands duct.

6. The Hymen:

- The hymen is a membrane, situated about 2 cm deep to the vestibular orifice it demarcates the external from the internal genital organs, and partially closes the vaginal orifice.
- It is formed of connective tissue covered by stratified squamous epithelium on both sides.
- The hymen is usually torn by the first intercourse unless the opening is unusually large or the hymen itself is elastic. Further lacerations occur on repeated intercourse.
- Remnants of the hymen in parous women are called "carunculae myrtiformis".

• Types of hymen:

- It is usually perforated and according to the shape of its opening; it may be; crescent, annular, fringed, cribriform, or bi-perforate.
- Rarely the hymen may be imperforate resulting in accumulation of the menstrual blood in the vagina after puberty resulting in crypto-menorrhoea with haematocolpos (see amenorrhea)

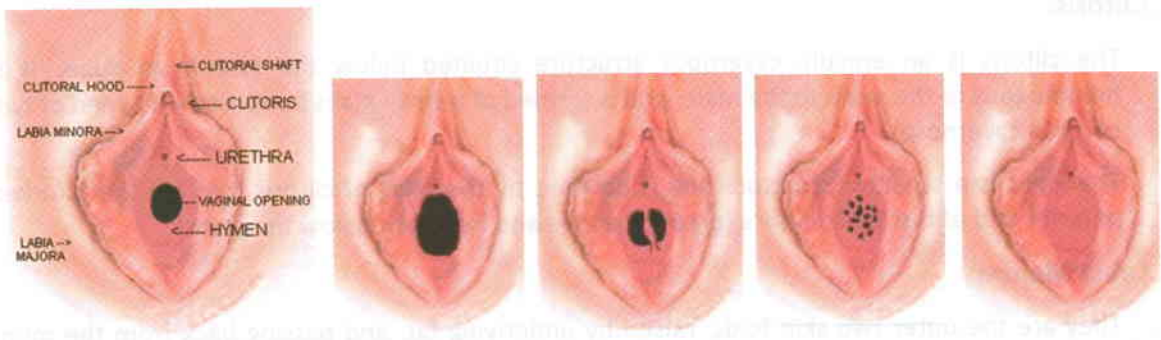

Fig. 2-2: Types of hymen

7. Bartholin's Glands: (Greater Vestibular Glands):

- Bartholin's glands are bilateral compound racemes glands situated deep in the labia majora, at the junction of its posterior and middle thirds
- They secrete mucus during sexual excitement to act as a lubricant.
- Its duct is 2 cm long and opens between the hymen and the labium minus.
- If the duct is obstructed it may form a vulvae swelling (Bartholin's cyst, or abscess).
- The gland is rarely a site for a Bartholin's gland tumour (see swellings of the vulva).

8. Vestibular bulbs: Oblong masses of erectile tissue that lie on each side of the vaginal introitus

9. The urethra and external urethral meatus:

- In the female the urethra is a tubular structure, 4 cm in length, extending from the bladder neck to the external urethral meatus that opens in the vestibule anteriorly below the clitoris.

10. Skene's duct:

- Two blindly ending para-urethral tubules which open in the floor of the urethra, few millimetres from the external urethral meatus.

N.B.: The vaginal orifice is bounded anteriorly by the vestibule, inferiorly by the fourchette, and laterally by the labia minora and is partially closed by the hymen in virgins.

BLOOD SUPPLY AND LYMPHATIC DRAINAGE OF THE VULVA

Arterial Supply:

a) Internal pudendal artery: One of the two terminal branches of the anterior division of the internal iliac artery that ends as the dorsal artery of the clitoris.

b) Branches from the femoral artery, supply the anterior part.

c) Superficial and deep external pudendal arteries.

Venous Drainage:

- The veins draining the vulva form a venous plexus from which veins accompany their corresponding arteries. Veins draining the clitoris join vaginal and vesical venous plexuses

Lymphatic Drainage of the vulva

- From the skin and appendages, to the superficial inguinal lymph nodes, to the deep inguinal and femoral lymph nodes of which the lymph node of Cloquet drains the clitoris directly.
- From the former superficial group, lymphatic channels pass to the deep pelvic nodes including; the external iliac, common iliac, then para-aortic lymph nodes.

NERVE SUPPLY OF THE VULVA

- The vulva is supplied mainly from the pudendal nerve (S 2, 3 & 4).
- Additional sensory nerves are supplied from; the Ilio-inguinal nerve (L1), the genital branch of genito-femoral nerve (L 1, 2), and the posterior cutaneous nerve of the thigh.

II. ANATOMY OF THE VAGINA

- **The vagina** is a fibro-muscular tube that extends upwards and backwards from the vulva to the uterus forming an angle of 60□□with the horizontal plane. Its mucous (skin) is elevated into folds or rugae allowing the vagina to be distended during labour.
- **Vaginal Length:** The anterior wall is 8-9 cm and the posterior wall is 10 - 11 cm long.
- **Vaginal fornices:** The cervix projects in the upper blind end of the vagina that forms a pouch (vaginal pouch) around the cervix and is divided into four fornices: two lateral, anterior and posterior (deeper) fornices.

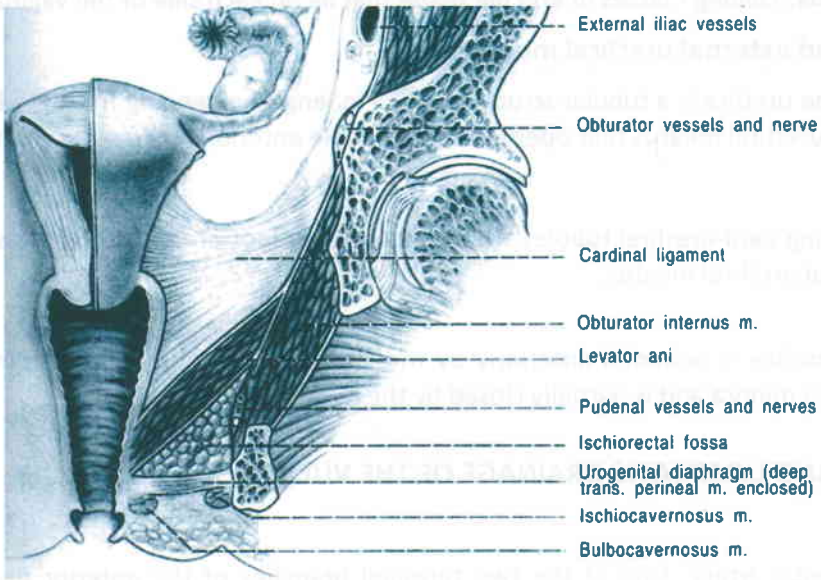

Fig 2-3: Anatomy of the vagina

ANATOMICAL RELATIONS OF THE VAGINA

- Anteriorly: trigone of the urinary bladder in the upper 1/3 and the urethra in the lower 2/3.
- Posteriorly: Peritoneum of the pouch of Douglas in the upper 1/3, the ampulla of the rectum in the middle 1/3, and the perineal body in the lower 1/3.
- Laterally:
  - Lower end: Bulbocavernosus muscle, vestibular bulb, and Bartholin's gland.
  - 1 cm above orifice: urogenital diaphragm
  - 2½ cm above the orifice: levators ani muscle with the pelvic fascia above it.
  - The lateral fornix gives attachment, to the lower part of the cardinal ligaments.
  - The ureters pass through the cardinal ligaments 1 cm lateral to the vagina.



Fig 2-4: Anterior and lateral relations of the vagina

VAGINAL SUPPORTS:

- **Ligaments** attached to the upper vagina:
  - Pubocervical ligament anteriorly
  - Mackenrodt's ligament laterally,
  - Uterosacral ligament posteriorly.

  Levators ani muscles: pubo-vaginalis **part of pubococcygeus**
- **Triangular ligament** and the **perineal membrane.**
- **Vaginal fascia:** Connective tissue fascia that condenses anteriorly forming the vesico-vaginal fascia and posteriorly forming the recto-vaginal fascia.

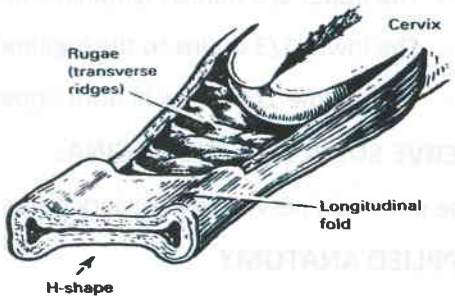

Fig 2-5: H shaped vaginal cut section

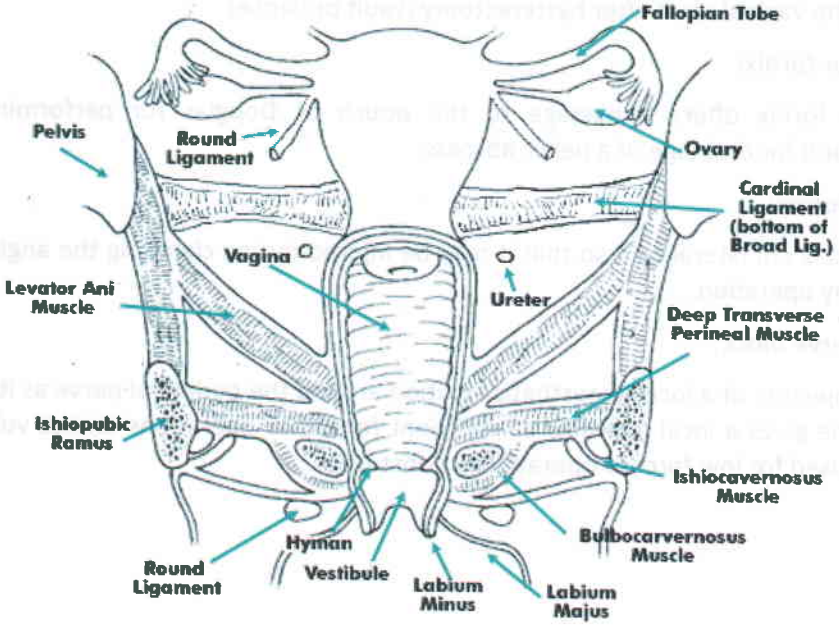

Fig 2-6: Vaginal supports

BLOOD SUPPLY AND LYMPHATIC DRAINAGE OF THE VAGINA

I. Arterial supply:

a. The vaginal artery (from internal iliac artery) is the main blood supply to the upper vagina

b. Additional branches to the lower vagina from:

- Middle rectal artery (from internal iliac artery)
- Inferior rectal artery (from the internal pudendal artery, of the internal iliac artery)

II. Venous drainage:

Veins form the vaginal plexus connect with the plexuses around the bladder and the rectum and drain into the internal iliac vein by veins that accompany their corresponding arteries.

III. Lymphatic drainage of the vagina

- The upper 1/3 follows lymphatic drainage of the cervix (see later)
- The lower 1/3 drains to the inguinal lymph nodes.
- The middle 1/3 drains in both upper and lower directions.

NERVE SUPPLY OF THE VAGINA:

The pudendal nerve gives sensory fibres to the lower vagina.

APPLIED ANATOMY

1. Vaginal Prolapse:

Weakness of the vaginal supports (ligaments, fascia and muscles) may lead to descent of anterior vaginal wall (cystocele or urethrocele), descent of posterior vaginal wall (rectocele or enterocele), or descent of the vaginal vault after hysterectomy (vault prolapse).

2. The posterior fornix:

The posterior fornix offers a passage to the pouch of Douglas for performing culdoscopy, culdocentesis and for drainage of a pelvic abscess.

3. The lateral fornix:

The ureters lie1-2 cm lateral to it so that it may be injured during clamping the angle of the vagina in hysterectomy operation.

4. Pudendal nerve block:

Transvaginal injection of a local anaesthetic solution around the pudendal nerve as it passes around the ischial spine gives a local anaesthesia sufficient for minor operations on the vulva and vagina, and has been used for low forceps operations in obstetrics.

III. ANATOMY OF THE UTERUS

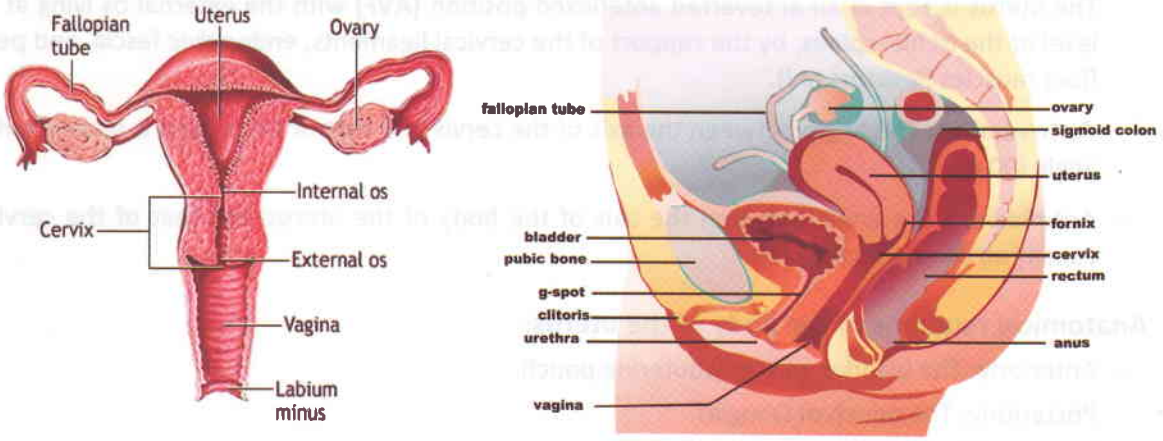

Fig 2-7: Anatomy of the uterus

The adult uterus is a pear shaped hollow muscular organ measuring around 7.5 x 4.0 x 2.5 cm in the longitudinal, transverse, and antero-posterior diameters. It is slightly larger in the multipara than in the nullipara. The uterus is divided into:

1. The corpus uteri:

- The corpus uteri include; the ***body*** that lies above the internal os, the ***cornu***, which is the area of insertion of the fallopian tubes, and the ***fundus*** which lies above the insertion of the tubes.
- Three structures are attached to the cornu; the round ligament anteriorly, the Fallopian tube centrally, and the ovarian ligament posteriorly (collectively known as the adnexa).

2. The isthmus:

- It is an area 4-5 mm in length that lies between the anatomical internal os above, and the histological internal os below. It is lined by low columnar epithelium and few glands.
- The isthmus expands during pregnancy forming the lower uterine segment (10 cm in last trimester).

3. The cervix:

- The cervix is the elongated lower part of the uterus measuring 2.5-3.0 cm.
- It is divided by the vaginal attachment into supravaginal portion above, and vaginal portion (portio-vaginalis) below.
- The cervix - body ratio is 2/1 at birth, 1/1 at puberty, and 1/2 in adults.
- The cervical canal is the cavity that communicates above with the uterine cavity at the internal os and below with the vagina at the external os.
- The external os is round in nullipara and slit shaped in multiparous.
- The cervical mucosa has two ridges (anterior and posterior) from which transverse ridges radiate to form the arbour vitae uteri (racemose glands).

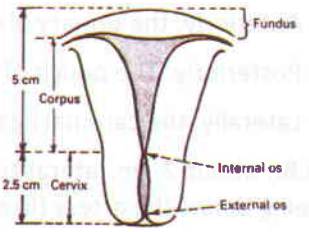

Fig 2-8: Cervix to body ratio

The position and direction of the uterus

- The uterus is kept in an anteverted anteflexed position **(AVF)** with the external os lying at the level of the ischial spines, by the support of the cervical ligaments, endopelvic fascia, and pelvic floor muscles (levators ani).
- **Anteversion:** The angle between the axis of the cervix and that of the vagina is usually a right angle (90 d).
- **Anteflexion:** The angle between the axis of the body of the uterus and that of the cervix is usually an obtuse angle.

Anatomical relations of the body of the uterus:

- Anteriorly: The bladder and vesicouterine pouch.
- Posteriorly: The pouch of Douglas.
- Laterally: The broad ligament on each side.

N.B.: At the base of the broad ligament the uterine artery crosses above the ureter 1/2 an inch lateral to the internal cervical os.

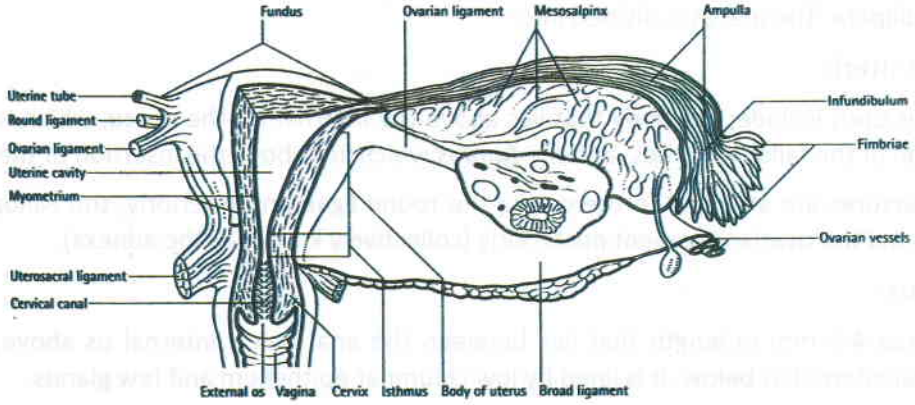

Fig 2-9: Lateral relations of the uterine body and cervix

Anatomical relations of the supravaginal cervix:

- Anteriorly: the urinary bladder, and pubocervical ligament.
- Posteriorly: The pouch of Douglas, and attachments of the uterosacral ligaments.
- Laterally: the cardinal ligament, the uterine artery and the ureter.

N.B.; about 2 cm lateral to the internal os the ureter is crossed by the uterine artery, the ureter being below the artery (like the water under the bridge).

Histology of the uterus

1. Endometrium: (mucosa) **The endometrium is modified mucosa that contain glands &stroma**

- Lined by simple cubical or columnar epithelium.
- It shows cyclic changes with the menstrual cycle under the influence of ovarian hormones; oestrogen and progesterone (see physiology of menstruation).

2. Myometrium (musculosa); formed of 3 layers;

- Outer longitudinal muscle layer
- Middle layer of interlacing criss-cross muscle fibres surrounding the blood vessels (its contraction controls blood loss during menstruation and after labour)
- Inner circular muscle layer which is well developed over tubal openings and isthmus uteri.

3. The perimetrium (the peritoneal covering):

- Anteriorly: The peritoneum is firmly attached to the fundus and body till the isthmus where it becomes loose and is reflected on the superior surface of the urinary bladder forming the vesicouterine pouch.
- Posteriorly: The peritoneum is firmly attached to the fundus, body, cervix, and posterior vaginal fornix then is reflected on the pelvic colon forming the Douglas pouch.
- Laterally: At the sides of the uterus, the anterior and posterior peritoneal coverings blend as the anterior and posterior layers of the broad ligaments.

Histology of the cervix:

A) **Endocervix:** Lined by simple columnar epithelium with compound racemose glands or crypts that is liable to chronic infection. It secretes alkaline cervical mucus.

B) **Muscle layer:** Outer longitudinal and inner circular muscles.(2 layers only)

C) **Ectocervix:** Formed of stratified squamous epithelium covering the outer portion of the cervix. The junction between squamous and columnar epithelium at the external os is either abrupt or it may form a transitional zone 1-3 mm known as the transformation zone.

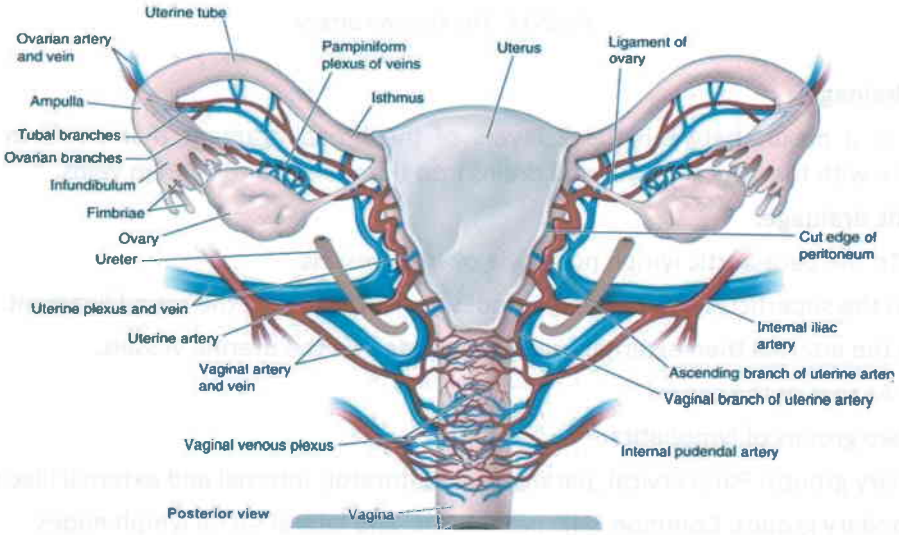

Fig 2-10: Blood supply of the uterus

Blood Supply and lymphatic drainage

I. Arterial supply:

The uterine arteries form the main supply of the uterus. They arise from the anterior division of internal iliac artery and run medially towards the isthmus, in the base of the broad ligament, crossing above the ureter 1/2 an inch lateral to the supravaginal cervix.

At the level of the internal os each artery gives an ascending and a descending branch, with their contralateral fellows they form the circular arteries which supply the uterus and the upper cervix.

a) The ascending branches pass upwards in a tortuous manner parallel to the lateral border of the uterus between the 2 layers of the broad ligament to end by anastomosing with branches of the ovarian arteries near the uterine cornu.

b) The descending cervical branch supplies the lower cervix.

- **The main branch**, along its length, divides into anterior and posterior coronary arteries that surround the uterus circumferentially, thus the uterus is least vascular in the midline.
- The coronary arteries give rise to the radial arteries that penetrate the myometrium to end as the basal arteries supplying the endometrium.

N.B.; the tortuous course of the uterine artery allows for increase in the size of the uterus without overstretch of the artery (no ischaemia).

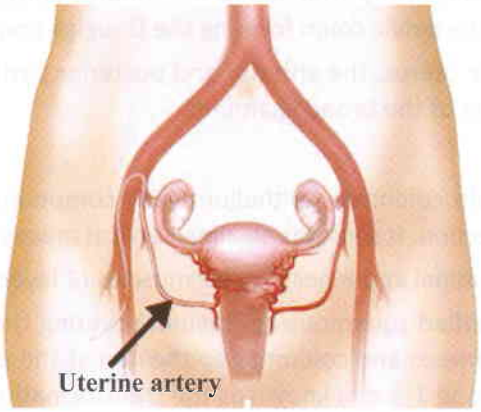

Fig 2-11: The Uterine artery

II. Venous drainage:

Starts as a plexus between the 2 layers of the broad ligament (Pampiniform plexus) that communicate with the vesical plexus and drains into the uterine and ovarian veins.

III. Lymphatic drainage:

- Fundus: To the para-aortic lymph nodes via ovarian vessels.
- Cornu: To the superficial inguinal lymph nodes via lymphatics of the round ligament.
- Body: To the internal then external iliac lymph nodes via the uterine vessels.
- Isthmus: As that of the cervix.
- Cervix: Two groups of lymphatics:
  - Primary groups: Paracervical, parametrial, obturator, internal and external iliac nodes.
  - Secondary groups: Common iliac, para-aortic, and lateral sacral lymph nodes.

Nerve supply of the uterus

- The cervix and body are relatively insensitive to touch, cutting and burning.
- The cervix is sensitive to dilatation and the body is sensitive to distension.
- **Parasympathetic innervations** are received form S2, 3, 4,
- **Sympathetic innervations** from T5 and T6 (motor) T10, T11, T12, and L1 (sensory). Both reach the uterus through branches of inferior hypogastric plexus.

IV- ANATOMY OF THE FALLOPIAN TUBE

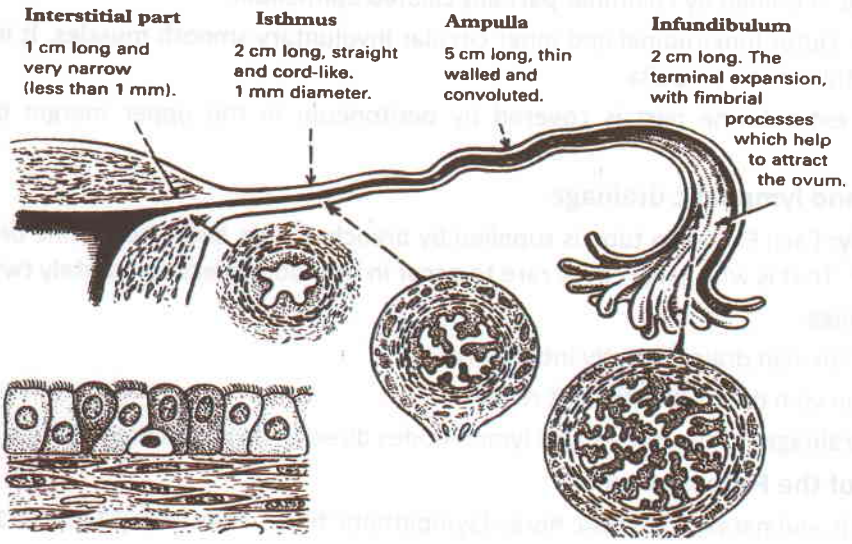

Fig 2-12: The Fallopian tube

The Fallopian tubes are two tortuous tubes that lie in the free upper part of the broad ligament. They blend medially with the cornu of the uterus, while laterally their free outer end curves backwards towards the ovary.

The lumen of the Fallopian tubes communicates between the uterine and the peritoneal cavities. Each tube is about 10 cm in length and is divided into four parts;

1. **Interstitial part (1 cm):** It is the part that pierces the uterine wall. Its lumen is very narrow, and has no peritoneal covering and no outer longitudinal muscles.
2. **Isthmus (2 cm):** It is the straight, narrow, thick walled portion just lateral to the uterus.
3. **Ampulla (5 cm):** It is the widest, tortuous, and thin walled outer part.
4. **Infundibulum (2 cm):** It is the trumpet shaped outer end that opens into the peritoneal cavity by the tubal ostium. The ostium is surrounded by fimbriae, one of which is long and directed towards the ovary (fimbria ovarica). The fimbriated end is free and turns backwards towards the ovary.

Tubal functions:

The major functions of the Fallopian tubes include ***ovum pick up***, at the time of ovulation, by their free fimbrial end, ***transport of the ova*** through the tubal lumen, by their peristaltic and ciliary movements, and ***production of secretions*** necessary for capacitation of the sperm and nutrition of the ova during their journey, by their lining cells.

Anatomical relations:

The Fallopian tubes lie in the free upper part of the broad ligament, bounded *above* by loops of intestine, and *below* by the broad ligament and its contents. *Medially* they blend with cornu of the uterus while *laterally* they are bounded by the lateral pelvic wall. The ovaries lie posterior and inferior to the Fallopian tubes at each side.

Histology of the Fallopian tubes

a. *Mucosa (endosalpnix):* Arranged into 4-5 main longitudinal ridges that give rise to subsidiary folds or plicae. It is lined by columnar partially ciliated epithelium.

b. *Muscle layer:* Outer longitudinal and inner circular involuntary smooth muscles. It is thick at the isthmus and thin at the ampulla.

c. *Serosa:* The extrauterine part is covered by peritoneum in the upper margin of the broad ligament.

Blood supply and lymphatic drainage

I. Arterial supply: Each Fallopian tube is supplied by branches from both the *uterine artery*, and the *ovarian artery*. That is why gangrene is rare to occur in the tube unless completely twisted.

II. Venous drainage:

- Right ovarian vein drains directly into the IVC
- Left ovarian vein drains into the left renal vein.

III. Lymphatic drainage: to the para-aortic lymph nodes directly via ovarian lymphatics.

Nerve supply of the Fallopian tubes

Sympathetic and parasympathetic fibres (Sympathetic fibres arise from T11 and T12).

Applied anatomy

Tubal pain is referred to the tubal points which lie on the lower abdominal wall 1/2 an inch above the midinguinal points.

V- ANATOMY OF THE OVARY

The ovary is an almond shaped organ lying in the fossa ovarica on the lateral pelvic wall, measuring 3 x 2 x 1.5 cm. It is the only organ in the abdomen that is not covered by peritoneum. Its surface is pearly white and corrugated by the effect of the monthly ovulatory activity that leaves surface gyrii indentations.

During the child bearing period its main function is production of ova and sex hormones, after menopause it atrophies and diminishes in size. The ovaries and the Fallopian tubes are included in the term adnexa.

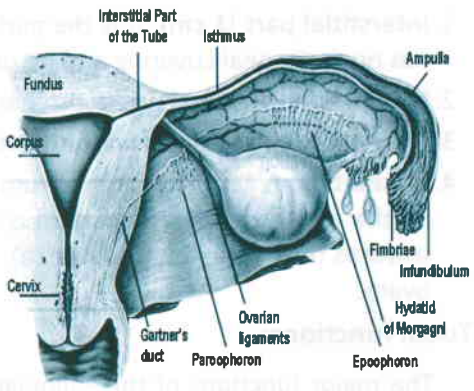

Fig 2-13: Attachments of the ovary

Ovarian attachments:

The ovary is fixed in the pelvis by three attachments:

1. The *mesovarium:* A peritoneal fold that suspends the ovary to the back of the broad ligament.
2. The *infundibulopelvic ligament:* suspends the upper pole of the ovary to the lateral pelvic wall and carries the ovarian vessels, nerves and lymphatics.
3. The *ovarian ligament:* attaches the lower pole to the cornu of the uterus.

Anatomical relations:

The ovary is bounded *medially* by the Fallopian tube, *laterally* by the lateral pelvic wall. *Superiorly and anteriorly* it is surrounded by the small intestine, and *inferiorly* by the ovarian fossa where the ureter and the internal iliac vessels pass.

Histology of the ovary

The ovary is subdivided into; Cortex, medulla, and hilum.

1. **The medulla:** The central core of the ovary surrounded by the cortex and continuous with the hilum. It is formed of connective tissue.
2. **The cortex:** The outer active part of the ovary that produces hormones and oocytes. It is formed of:
   - *The surface epithelium:* A single layer of cuboidal cells, called the germinal epithelium, covering the free surface of the ovary (NB: no peritoneal covering).
   - *Connective tissue stroma:* Composed of dense connective tissue containing the oocytes. It is condensed on the surface to form the tunica albuginea.

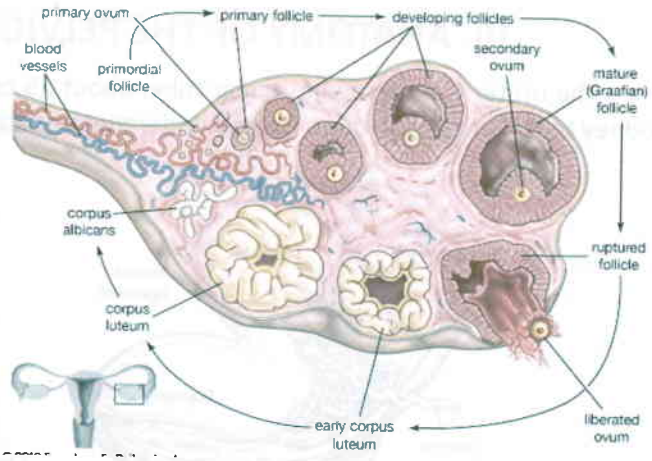

Fig 2-14: Histology of the ovary

3. **The hilum:** Is the site of attachment of the mesovarium that carries blood vessels, nerves and lymphatics entering and leaving the ovary.

Blood supply and lymphatic drainage

I. Arterial supply:

a. *Ovarian artery:* Arises from the *aorta* at the level of L2 and passes through the infundibulopelvic ligament.
b. *Ovarian branch* from the *uterine artery;* which anastomose with the ovarian vessels at the broad ligament.



Fig 2-15: Blood supply of the ovary

II. Venous drainage:

The *ovarian veins* accompany the arterial supply, and join with the *pampiniform plexus* of veins and the *uterine vein*.

III. Lymphatic drainage:

Lymphatic drainage of the ovaries is directly to the para-aortic lymph nodes via the ovarian vessels.

Nerve supply of the ovary

The ovary is insensitive except to squeezing on P.V examination. It is supplied by sympathetic and parasympathetic nerves (T10 and T11) that accompany the ovarian vessel.

Applied anatomy

Removal of the ovary (Ovariotomy or ovariectomy) needs the application of 6 clamps, two on each pedicle (mesovarium, infundibulopelvic, and ovarian ligaments) and cutting in between to free the ovary completely and remove it.

VI. ANATOMY OF THE PELVIC PART OF THE URETER

The ureter is a narrow muscular tube, about 25 cm in length. It runs retroperitoneal from the kidney to the urinary bladder. Its wall undergoes peristaltic movement to propel urine downwards.

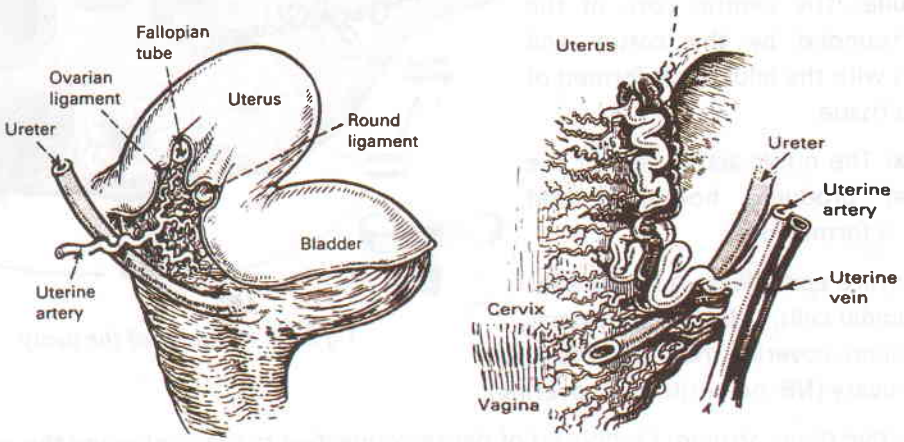

Fig 2-16: Blood supply of the ovary

- **At the pelvic inlet:** The ureter enters the pelvis above the bifurcation of the common iliac artery anterior to the sacroiliac joint.
- **In the pelvis:** It runs downwards lying in front of the internal iliac artery.
  - At the base of the broad ligament it runs medially and forwards through the parametrium till it reaches about 1 cm lateral to the supravaginal cervix where it passes below and at right angle to the uterine artery (i.e. the artery crosses over the ureter).
  - The ureter then passes forwards through the ureteric canal in the upper part of the cardinal ligament, closely related to the lateral vaginal fornix, to enter the trigone of urinary bladder.

Blood supply of the ureter

The ureter is supplied throughout its course by branches from the internal iliac artery, the uterine artery, the inferior vesical artery, and the vaginal artery.

Applied anatomy – Sites of ureteric injuries during hysterectomy:

- On clamping the infundibulopelvic ligament where the ureter passes below ovarian vessels.
- On clamping the uterine arteries as it passes below the uterine artery 1 cm lateral to cervix.
- During clamping the vaginal angles and the parametrium 1.0 cm lateral to vaginal vault.

N.B.: Avascular necrosis of its wall may occur due to cutting of its blood supply during dissection of the parametrium in Wertheim's operation.

N.B.: Ischaemic necrosis of the ureter may occur due to exposure of the ureter to overdose of irradiation in treatment of cancer cervix.

VII. THE UTERINE AND CERVICAL LIGAMENTS

Ligaments attached to the uterine fundus and body on each side include; the broad ligament, the round ligament, and the ovarian ligament. These ligaments being soft, lax, and easily stretchable, play a very limited or almost no role in the pelvic support of the uterus in contrast to the strong, tough cervical ligaments.

A) THE BROAD LIGAMENT:

The broad ligament is a double sheet of peritoneum that extends from the lateral wall of the uterus to the lateral pelvic wall. Its outer upper part forms the infundibulopelvic ligament in which the ovarian vessels traverse there way to the ovary.

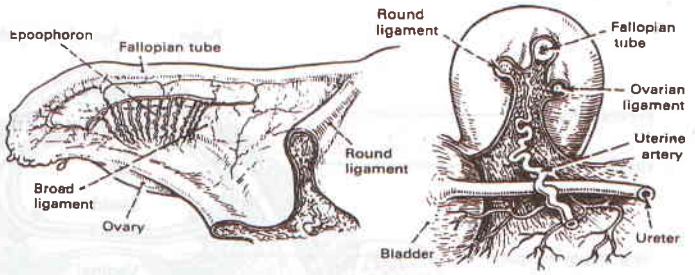

Fig 2-17: The broad ligament

Contents of the broad ligament:

- *The round ligament, the ovarian vessels, the uterine vessels, the ureter, parametrial lymphatics and lymph nodes, sympathetic and parasympathetic nerves, parametrial pelvic cellular tissue and fascia.*
- *Embryological remnants of the Wolffian ducts*
- *Hydatid cyst of Morgagni: A pea sized thin walled cyst attached to the fimbrial end of the tube.*
- *Koblet's tubules: Blind tubules lying on the outer aspect of the ligament*
- *Epoophoron: Tubules lying between the ovary and the tube.*
- *Paroophoron: Tubules lying between the ovary and the uterus.*
- *Gartner's duct: Runs in the broad ligament parallel to the tube then downwards lateral to the uterus then anterolateral to the vagina.*

Applied anatomy; Remnants of Wolffian duct may undergo cystic dilatation giving rise to:

- ***A paraovarian cyst*** that lies in between leafs of the broad ligament.
- ***Gartner's duct cyst*** in the anterolateral wall of the vagina.

B) THE ROUND LIGAMENT:

This is a fibromuscular ligament attached to the uterine cornu. It runs downwards and forwards in between the two leafs of the broad ligament to enter the inguinal canal via the internal inguinal ring and comes out of it at the external inguinal ring to be inserted in the upper part of the labium majus. It pulls the uterus forwards and help keeping it in an anteverted position.

- Applied anatomy; Lymphatics accompanying the round ligament drain the cornu of the uterus to the superficial inguinal lymph nodes.

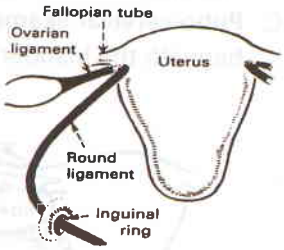

Fig 2-18: Attachment of the round ligament

C) THE OVARIAN LIGAMENT:

It is a fibromuscular ligament that attaches the inner lower pole of the ovary to the cornu of the uterus. It plays no role in pelvic support of the uterus.

THE CERVICAL LIGAMENTS

The cervical ligaments are ***condensed thickening of the pelvic cellular tissue***, that lies between the pelvic peri-toneum above and the levators ani below and radiates outwards from the cervix to reach the pelvic walls. These strong ligaments, that contain few smooth muscle fibres, act as the chief support of the uterus and pelvic structures

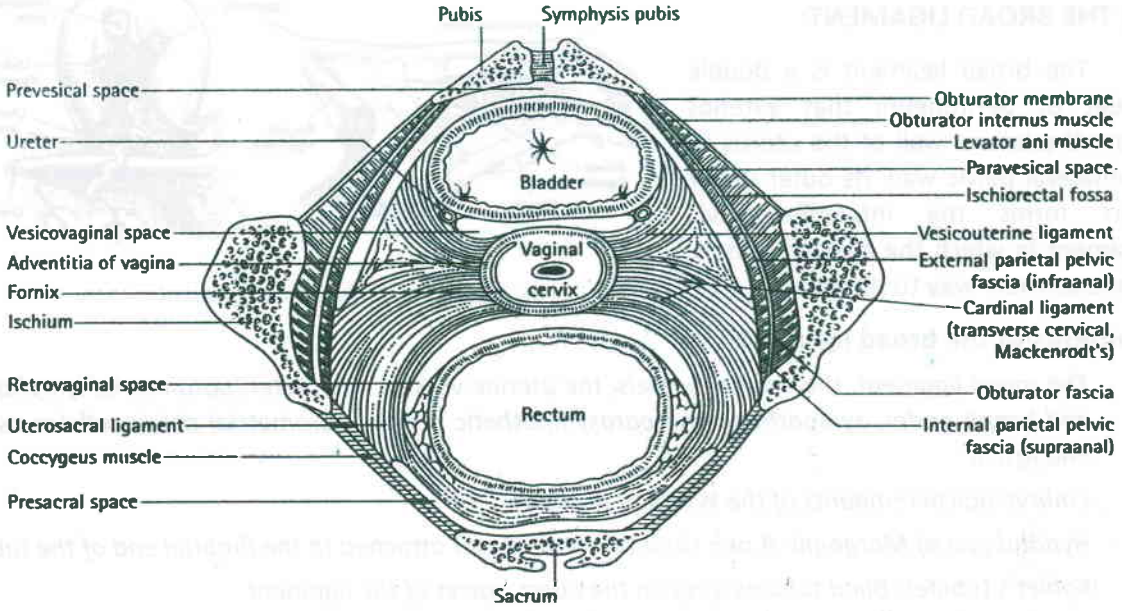

Fig 2-19: The cervical ligaments

Three pairs of ligaments can be distinguished, which *extend from the supravaginal part of the cervix and upper part of the vagina* to the pelvic walls:

A. **Mackenrodt's ligaments** (The cardinal ligaments of the cervix): spread out on either side from the lateral surface of the cervix and vagina, in a fan-shaped manner, and are inserted in the lateral pelvic wall.
B. **Utero-sacral ligaments:** From the posterior aspect of the cervix and vagina, backwards surrounding the rectum, below the utero-sacral folds of peritoneum, to become inserted in the third piece of the sacrum.
C. **Pubo-cervical ligaments:** extend from the anterior surface of the cervix and vagina, forwards beneath the bladder and surrounding the urethra, to the posterior surface of the pubis.

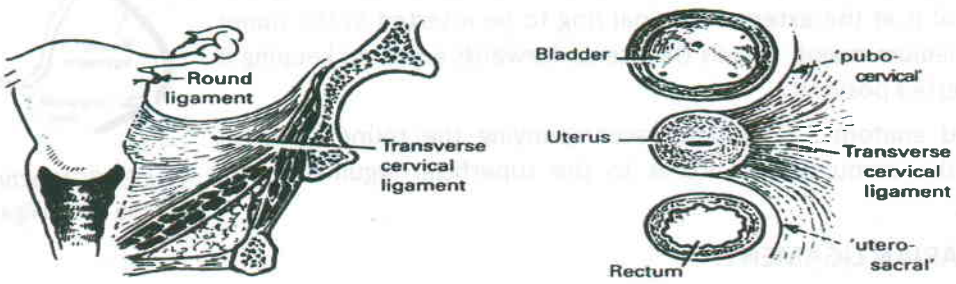

Fig 2-20: Attachments of the cervical ligaments

VIII. THE PELVIC FLOOR

The pelvic floor consists of all tissues lying between the pelvic cavity and, the surface of the vulva and perineum. It includes the pelvic peritoneum, extraperitoneal fat and cellular tissue, the levators ani and their fascial coats, the triangular ligament (urogenital diaphragm), the perineal muscles and their aponeuroses, subcutaneous fascia and fat, and finally skin.

The levators ani muscles together with the fascia which covers their upper and lower surfaces are collectively called the pelvic diaphragm. In the midline, the pelvic floor is pierced by the urethra, the vagina and the rectum.

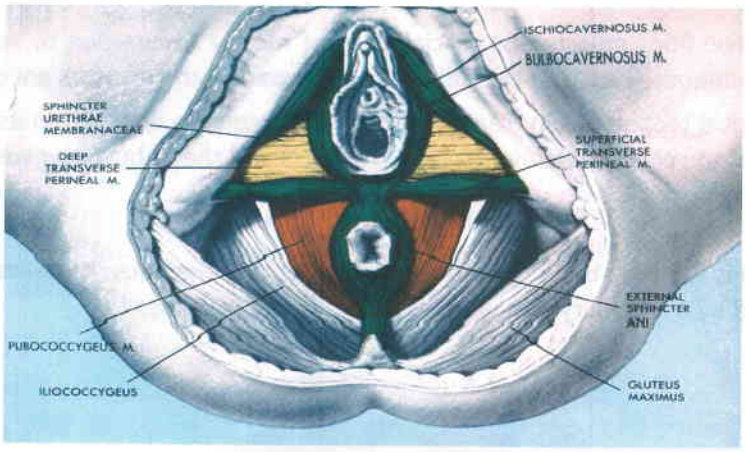

Fig 2-21: Levators ani muscles

THE LEVATORS ANI MUSCLE:

A. **The ischiococcygeus** part; arises from the spine of the ischium and spreads out in a fan-shaped manner backwards and upwards to be inserted into the front of the coccyx.

B. **The iliococcygeus** arises from the "white line" on the lateral Wall of the pelvis, directly from the pelvic fascia, and passes backwards and inwards, to be inserted partly into the tip of the coccyx and also into the raphe, which passes from the rectum to the tip of coccyx.

C. **The pubococcygeus** muscle is the most important of the three muscles:

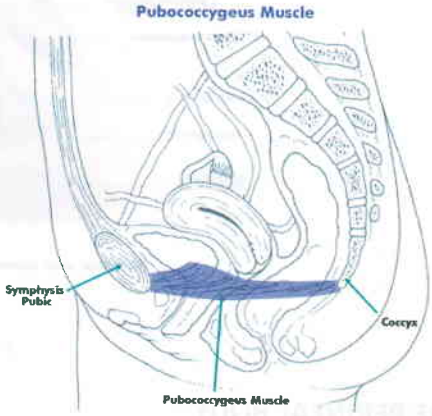

Fig 2-22:

- It arises from the back of the pubic ramus and passes backwards to be inserted, partly into the tip of the coccyx and into the raphe which passes between the rectum and the coccyx.
- The pubococcygeus sends fibres to the urethra (*pubourethralis)*, to the vagina (*pubo-vaginalis)*, and rectum (*puborectalis)* to blend with their intrinsic muscles, giving them muscular support.
- The innermost fibres of the pubococcygeus muscle decussate in between the vagina and the rectum. The decussating fibres divide the opening in the pelvic floor into urogenital hiatus and rectal hiatus. During perineorrhaphy suturing these fibres together is vital to reduce the dimension of the urogenital hiatus

Applied anatomy

- The uterus is kept in its normal anatomic position (anteverted anteflexed with the external cervical os at the level of the ischial spines) by the traction of the cervical ligaments, the round ligament, and the support of the pelvic floor muscles and fascia.
- Loss of the anteverted position will bring the uterus in the axis of the vagina facilitating its prolapse through the vagina with chronic increase in intra-abdominal pressure.
- Weakness of cervical ligaments is the major predisposing factor for pelvic organ prolapse, whether being due to congenital weakness, repeated child birth trauma, or menopausal atrophy.
- Loss of the pelvic floor muscle and fascial support mostly occurs due to repeated child birth trauma and inadequate repair of the pubococcygeus part of the levators ani during childbirth.
- Success of surgical techniques in treatment of genital prolapse depends in its major part on the proper repair of the cervical ligaments, fascial defects and the pubococcygeus muscle.

IX. THE PERINEUM

The perineum is the area between the vaginal orifice and the anus. It covers the perineal body and is characterized by a less hairy skin with less subcutaneous tissue.

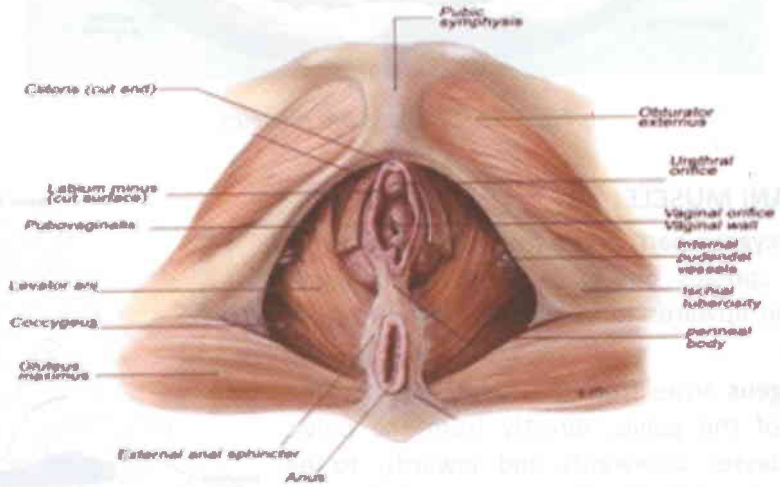

Fig 2-23: The Perineal Body

THE PERINEAL BODY

The perineal body is the wedge of tissue that lies between the posterior vaginal wall in its lower third, and the anterior wall of the anal canal. Its apex is at the lower end of the recto-vaginal septum at the point where the rectum and posterior vaginal wall come in contact. Its base is covered by perineal skin between vaginal orifice and the anus. It is the point of insertion of the superficial perineal muscles, bounded above by decussating fibres of the levator ani muscles where they meet together between posterior vaginal wall and the rectum.

03 DEVELOPMENT OF FEMALE GENITAL ORGANS

- *Sexual differentiation*
- *Development of thegenitalorgans:*
- *Ovaries-Fallopiantubes-Uterus-Vagina*

SEXUAL DIFFERENTIATION

Genetic sex is determined at the moment of conception by the **presence or absence of a Y chromosome**. Until week 6 development it is the same in all fetuses, after week 6 it will guide subsequent fetal development into either male or female.

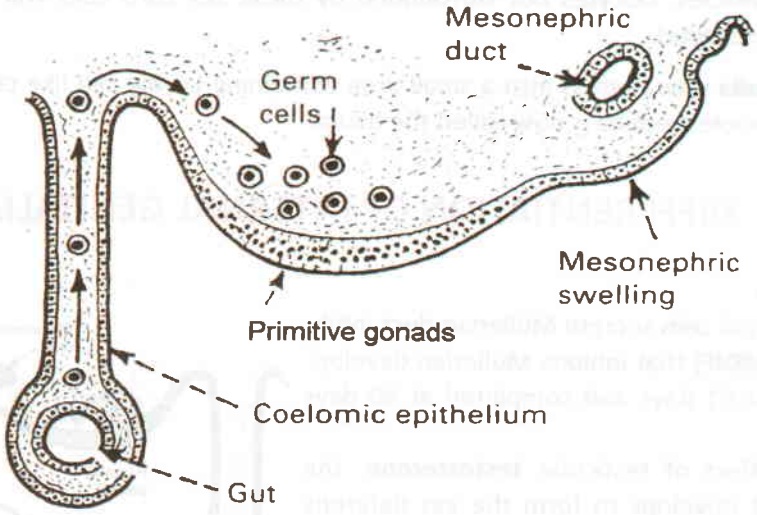

Fig 3-1: Migration of primitive germ cells

GONADAL DIFFERENTIATION

- At the **sixth week** of fetal life, gonads are capable of differentiating into either testis or ovary.
  - The indifferent gonad is formed of a cortex and medulla of mesenchymal tissue with some primitive cells called the sex cord cells.
  - Primitive germ cells (primordial cells) migrate from the wall of the yolk sac towards the developing gonads. Subsequent differentiation depends on the presence or absence of a Y chromosome.

1. TESTICULAR DIFFERENTIATION:

In males (XY), a gene present on the Y chromosome known as testicular differentiation factor **(TDF)** produces a protein called **H-Y antigen** which is the signal for testicular differentiation.

- At the **seventh week**:
  - **Testicular differentiation** occurs where sex cord cells migrate taking with it many germ cells to the gonadal medulla which expands on expense of the cortex.
  - The **germ cells** will form the spermatogonia **while the sex cord cells** will form the Sertoli cells, both of them will form the **seminiferous tubules**.
- At the **eighth week**:
  - **Leydig cell** formation occurs from local mesodermal differentiation.

2. OVARIAN DIFFERENTIATION:

In females (XX), absence of the **Y chromosome with** subsequent absence of the TDF and H-Y antigen will allow for ovarian differentiation of the gonads.

- The **cortex** dominates while the medulla shrinks.
- **Sex cord cells** surround the arriving dividing **germ cells** (primary oocytes) to form the primordial follicles. **Oocytes not surrounded by** these sex cord cells will die (what occur in Turner syndrome).
- The **medulla** now regress into a small area containing Leydig cell like cells called hilar cells and the whole medulla is now called the hilum.

DIFFERENTIATION OF INTERNAL GENITALIA

A) IN THE MALE:

- Testicular Sertoli cells secrete Müllerian duct inhibitory factor **(MDIF)** that inhibits Müllerian development (start at 61 days and completed at 80 days fetus).
- Under the effect of testicular **testosterone**, the **Wolffian** duct develops to form the vas deferens and the seminal vesicles, while Mullerian (para mesonephric) ducts atrophy.
- The effect of MDIF and testosterone is local affecting the side of the secreting gonad only.

B) IN THE FEMALE:

- Absence of MDIF, due to absence of Sertoli cells, will allow the **Müllerian** duct to develop forming the **Fallopian tubes**, uterus, cervix and the upper 4/5 of the vagina.
- In absence of testosterone, the Wolffian duct will regress and is represented in the female adult by the Gartner's duct.

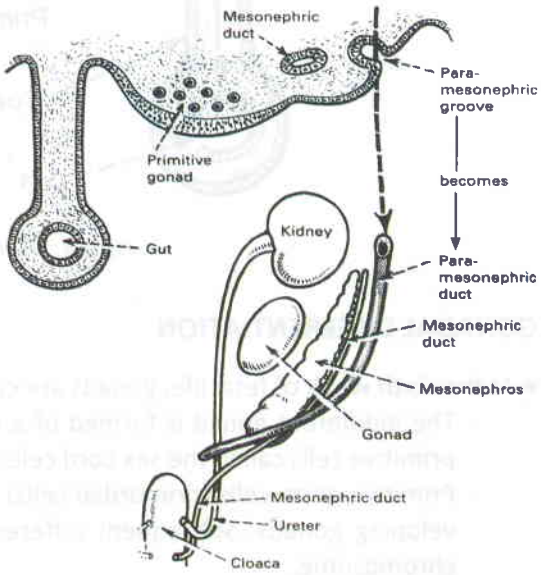

Fig 3-2: Development of the Mullerian (para mesonephric) duct in the female

DIFFERENTIATION OF THE EXTERNAL GENITALIA

External genitalia start to develop from the **urogenital sinus** (part of the primitive cloaca) about the 10th week of gestation. The basic parts of the primitive (undifferentiated) external genitalia are:

1. A medial pair of swellings called genital folds.
2. A lateral pair of swellings called genital swellings.
3. A central swelling called genital tubercle.

In the male: (in presence of androgens)

- The genital tubercle enlarges markedly forming the penis
- The gen-ital folds fuse to become the penile part of the male urethra.
- The genital swellings enlarge, fuse and form the scrotum.

In the female (in absence of androgens);

- The genital tubercle enlarges slightly and becomes the clitoris.
- The genital folds become the labia minora.
- The genital swellings enlarge to form the labia majora.

Factors needed for normal sexual differentiation:

1. Normal sex chromosomal pattern (XX in the female and XY in the male).
2. Normal testicular functioning (producing androgens) is needed for male development.
3. In the female ovarian function is not needed for sexual differentiation.
4. Responsive male end organs for testicular testosterone.

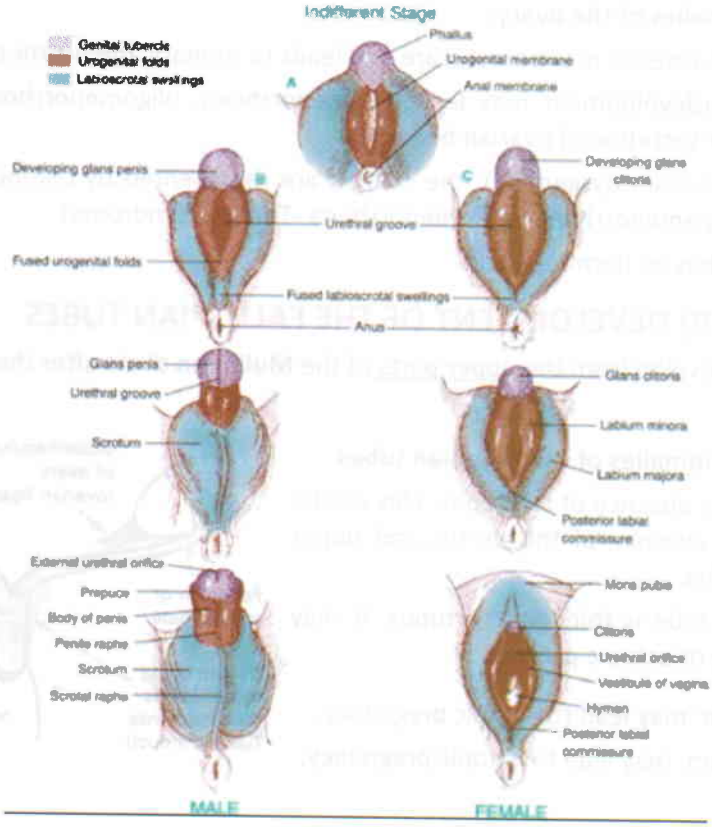

Fig 3-3: Development of male and female external genitalia

DEVELOPMENT OF THE FEMALE GENITAL ORGANS

Development of the female genital organs begins at the **fifth week** of intrauterine life. Two structures participate in the development;

THE UROGENITAL RIDGE (UGR): situated in the middle line of the posterior abdominal wall of the embryo, and includes three important structures;

1. The genital ridges; medially that give rise to the ovaries.
2. The Wolffian ducts; situated lateral to the genital ridges. They undergo atrophy in females.
3. The Mullerian ducts; situated lateral to the Wolffian ducts. They give rise to the Fallopian tubes, uterus, and the upper 3/4^{ths} of the vagina.

THE UROGENITAL SINUS (UGS): caudally, gives rise to lower 1/4th of the vagina and the vulva.

A) DEVELOPMENT OF THE OVARIES

The ovaries develop from the **genital ridges** at the level of the 10th – 11th dorsal (thoracic) vertebrae and descend later on to the pelvis.

- The germ cells, that give rise to the ova, develop in the yolk sac then migrate to the genital ridge. Failure of its migration gives rise to streak gonads.
- The genital ridge is attached to the inguinal region by a fibro-muscular band called the gubernaculum that runs in the inguinal canal. The gubernaculums becomes shorter pulling the ovary down to the pelvis and attaches to the uterus posteriorly forming the ovarian ligament and anteriorly forming the round ligament

Developmental anomalies of the ovary:

- Aplasia: complete absence is extremely rare and leads to primary amenorrhoea.
- Hypoplasia: underdevelopment may lead to amenorrhoea, oligomenorrhoea or hypomenorrhoea due to poor secretion of ovarian hormones.
- Streaks gonads (ovarian dysgenesis): the ovaries are represented by con-nective tissue bands leading to primary amenorrhoea (see amenorrhoea -Turner's syndrome).
- Accessory ovary: has no harmful effect.

B) DEVELOPMENT OF THE FALLOPIAN TUBES

The fallopian tubes develop from the upper parts of the **Mullerian** ducts after their canalisation.

- **Developmental anomalies of the Fallopian tubes**

1. Aplasia: complete absence of the tubes. This will be associated with absence of the uterus and upper 3/4^{ths} of the vagina.
2. Hypoplasia: the tube is thin, and tortuous. It may lead to infertility or ectopic pregnancy.
3. Accessory ostium: may lead to ectopic pregnancy.
4. Tubal diverticulum: may lead to ectopic pregnancy.

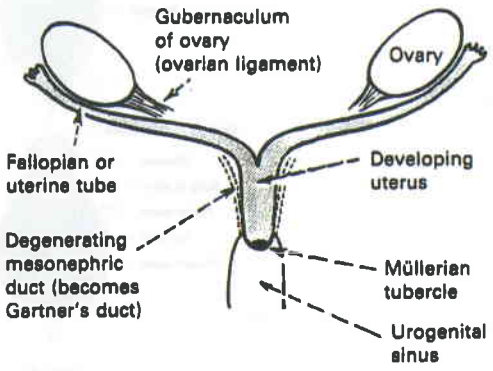

Fig 3-4:

C) DEVELOPMENT OF THE UTERUS

The uterus develops from the middle part of the **Mullerian** ducts after their fusion and canalisation. Uterine anomalies may be due to failure of Mullerian duct development, failure of fusion of both Mullerian ducts, or failure of their canalization.

I) IMPROPER MULLERIAN DUCT DEVELOPMENT

1. **Uterine aplasia:** complete absence of the uterus (rare anomaly). Cases will present after puberty with primary amenorrhoea and well developed secondary sexual characters.
2. **Uterine hypoplasia:** small solid uterus with no cavity, or small infantile uterus with a body to cervix ratio of 1: 2. Cases will present after puberty with primary amenorrhoea, oligomenorrhoea, infertility, or rarely recurrent pregnancy loss (RPL)

II) IMPROPER MULLERIAN DUCT FUSION AND CANALIZATION

1. **Arcuate uterus**: broad fundus with a depression from outside. It is of no clinical significance
2. **Subseptate uterus:** the uterine cavity is divided by a longitudinal incomplete median septum starting at the fundus downwards not reaching the isthmus.
3. **Septate uterus:** the uterine cavity is divided by a longitudinal complete median septum extending from the fundus to the isthmus, not reaching the cervix.
4. **Bicornuate uterus:** the uterine body is divided into two horns, both attached to one cervix, joining one vagina.

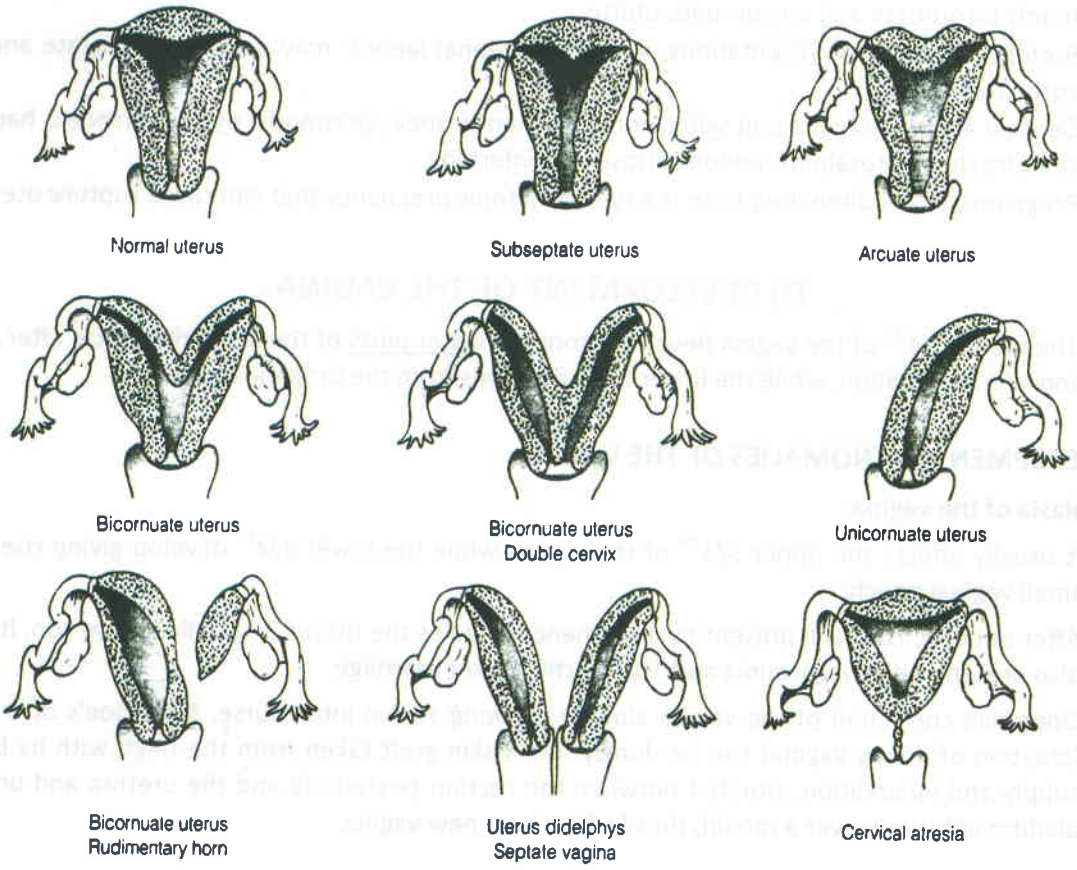

Fig 3-5: Anomalies of the uterus

5. **Bicornuate uterus with double cervix** (pseudo-didelphys); two uterine bodies (2 horns) each attached to a cervix (2 cervices) attached to each other and both open together in one vagina.
6. **Uterus didelphys:** there are two separate uteri (two bodies & two cervices) with two vaginae (separated by a longitudinal septum).
7. **Rudimentary horn:** one horn of the uterus is well developed, but the other is rudimentary.
8. **Unicornuate uterus:** One Mullerian duct is well developed forming a well canalized Fallopian tube connected to one horn of the uterus opening into the cervix and vagina. The other Mullerian ducts failed to develop with absent other tube, and second uterine horn.
9. **Cervical atresia;** Improper canalization of the cervical canal may lead to cervical atresia with entrapment of menstrual blood after puberty leading to haematometra and haematosalpinx (false amenorrhoea or Cryptomenorrhoea).

COMMON CLINICAL PRESENTATIONS OF UTERINE ANOMALIES:

a. Primary amenorrhoea: in cases with uterine aplasia, hypoplasia, and cervical atresia.
b. Severe dysmenorrhoea: in cervical atresia, and non communicating rudimentary horn
c. Primary infertility: in cases with uterine aplasia, hypoplasia, cervical atresia, and less commonly with septate and bicornuate uterus.
d. Recurrent pregnancy loss (RPL) in first trimester; may be associated with infantile uterus, septate uterus, and rarely bicornuate uterus
e. RPL in second trimester: due to incompetent isthmus associated with septate and less commonly bicornuate and unicornuate uterus
f. Preterm labour, malpresentations, and dysfunctional labour: may occur with septate and bicornuate uteri.
g. Cervical atresia may present with; primary amenorrhoea, spasmodic dysmenorrhoea, haematometra, haematosalpinx, endometriosis and infertility.
h. Pregnancy in a rudimentary horn is a type of ectopic pregnancy that can cause rupture uterus.

D) DEVELOPMENT OF THE VAGINA

The upper 3/4^{ths} of the vagina develops from the lower parts of the **Mullerian** ducts after their fusion and canalisation, while the lower 1/4th develops from the urogenital sinus.

DEVELOPMENTAL ANOMALIES OF THE VAGINA:

1. Aplasia of the vagina:

- It usually affects the upper 3/4^{ths} of the vagina while the lower 1/4th develop giving rise to a small vaginal pouch.
- After puberty, they will present by 1ry amenorrhoea as the uterus is usually absent too. It may also present with dyspareunia and 1ry infertility after marriage.
- Operative correction of the vagina aims at allowing sexual intercourse. Mc Indoe's operation (creation of a new vagina) can be done using a skin graft taken from the thigh with its blood supply and innervation, situated between the rectum posteriorly and the urethra and urinary bladder anteriorly over a mould, thus fashioning a new vagina.

2. Transverse vaginal septum:

- Results from improper fusion between the urogenital sinus and the Mullerian ducts. After puberty these cases will present with 1ry amenorrhea, and severe dysmenorrhoea, while the 2ry sexual characters are normally developed.
- Entrapment of menstrual blood will lead to haematocolpos, haematometra, and later haematosalpinx. Backflow of blood into peritoneal cavity may cause pelvic endometriosis
- Diagnosis is by history, general and P.R. examination, and ultrasonography.
- Treatment is by surgical excision of the septum.

3. Imperforate hymen:

- Occurs due to improper canalization of the urogenital sinus.
- After puberty, clinical presentation will include 1ry amenorrhea and severe dysmenorrhoea, with normal 2ry sexual characters. By time haematocolpos will develop, that may extend to haematometra, and haematosalpinx in rare cases.
- Diagnosis is by history, general and P.R. examination, inspection of the vulva and hymen.
- Treatment is by cruciate incision of the imperforate hymen under anaesthesia



Fig 3-6: Haematocolpos and haematometra

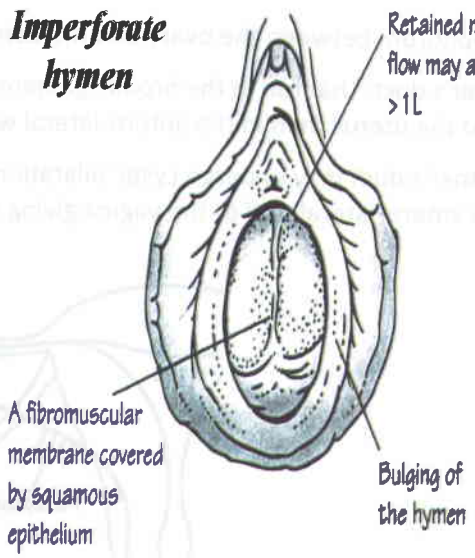

Fig 3-7: Imperforate hymen

4. Longitudinal vaginal septum:

Occurs due to improper fusion of the two Mullerian ducts.

Clinically it may lead to dyspareunia and is treated by surgical excision of the septum.

N.B.; Both transverse vaginal septum and imperforate hymen are common causes for false amenorrhoea or Cryptomenorrhoea (see amenorrhoea).

- **Clinical presentation vaginal anomalies:**
  - Amenorrhea, dysmenorrheal, dyspareunia, and infertility. 2ry sexual characters are preserved.
  - Haematocolpos leading to a pelvic mass.
  - Rarely Urinary symptoms as retention of urine are associated with large haematocolpos.

E) DEVELOPMENT OF THE VULVA

1. The genital tubercle forms the anterior boundary of the urogenital sinus and gives rise to the clitoris.
2. The inner and outer genital folds lie lateral to the urogenital sinus and give rise to the labia minora and majora respectively.

NB: In males, the genital tubercle develops into the penis and the inner and outer genital folds fuse to develop into the penile urethra and the scrotum respectively.

THE WOLFFIAN REMNANTS IN THE FEMALE

Infemales, the Wolffian ducts undergo atrophy leaving remnants that lie between the two layers of the broad ligament and in the antero-lateral wall of the vagina. These remnants are:

1. Hydatid cyst of Morgagni lateral to the tube.
2. Koblet's: tubules in the outer part of the broad ligament.
3. Epoophoron: between the ovary and the tubes.
4. Paroophoron: between the ovary and the uterus.
5. Gartner's duct: that run in the broad ligament parallel to the tubes then descends downward parallel to the uterus then in the antero-lateral wall of the vagina.

NB: Gartner's duct may undergo cystic dilatation in the broad ligament giving rise to parovarian cyst or in the antero-lateral wall of the vagina giving rise to Gartner's duct cyst.

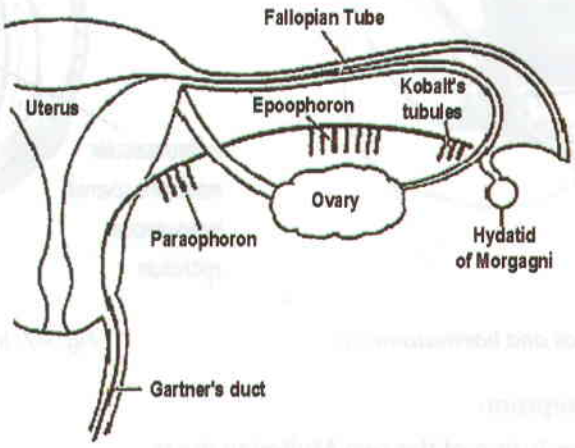

Fig 3-8: Wolffian duct remnants in the female

04 THE MENSTRUAL CYCLE AND ASSOCIATES DISORDERS

- *The Hypothalamus*
- *The Pituitary gland*
- *The Ovarian cycle*
- *Theendometrialcycle*
- *Dysmenorrhea*
- *The Premenstrual Syndrome*

OVERVIEW

The average menstrual cycle lasts for 3-7 days (mean **5** days), recurs every 21-35 days (mean **28** days), with an average blood loss of about **30-50** ml/cycle. The first few cycles following menarche and those in the few years prior to menopause are usually irregular mostly due to **anovulation**. Along their lifetime from puberty to menopause women will have around **400** menstrual cycles. Each cycle represents a complex interaction between the hypothalamus, pituitary gland, ovaries and the endometrium.

THE HYPOTHALAMUS

The hypothalamus is a small neural structure situated at the base of the brain above the optic chiasma and below the third ventricle. It is connected to the pituitary gland.

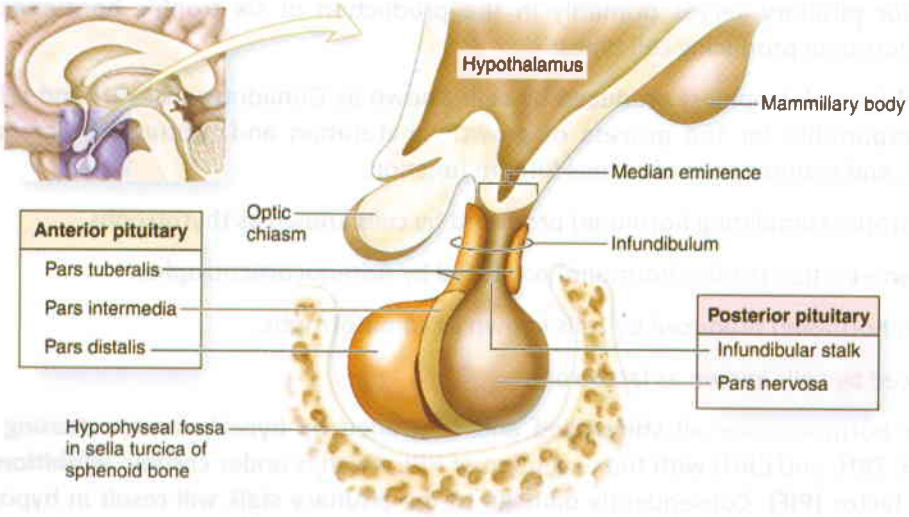

Fig. 4-1: The hypothalamus and pituitary gland

Hypothalamic Releasing Hormones

Releasing hormones are small peptides characterized by having short half-lives of few minutes due to their rapid degradation. They are released in minute quantities in a pulsatile manner, and reach the anterior pituitary via the hypothalamic portal circulation.

Biologically active concentrations of these factors are locally restricted to the anterior pituitary gland with very low concentrations in peripheral circulation rendering them undetectable in serum. Levels of their corresponding pituitary hormones are measured as markers for their presence and activity.

Hypothalamic releasing hormones include:

1. **Gonadotrophin-releasing hormone (GnRH):** It is a decapeptide produced by the arcuate nucleus in the hypothalamus and is responsible for synthesis and release of **pituitary gonadotropins (FSH and LH).**
2. **Thyrotropin-releasing hormone (TRH);** regulates secretion of **TSH**
3. **Corticotrophin-releasing hormone (CRH);** stimulates the release of **ACTH**.
4. **Growth hormone-releasing hormone (GHRH);** stimulates the release of **GH**
5. **Prolactin inhibiting factor (PIF or dopamine);** it inhibits production of prolactin (PRL)

THE PITUITARY GLAND

The pituitary gland lies at the base of the brain, below the hypothalamus within a bony cavity known as the sella turcica. It is divided into two major portions:

A. The Anterior Pituitary Gland (adenohypophysis)

It consists of an anterior lobe (pars distalis), an intermediate lobe, and pars tubalis which surround the neural stalk. It is derived from the ectoderm, and is indirectly connected to the hypothalamus through the hypophyseal-pituitary portal system which represents a major route of transport of hypothalamic releasing factors to the anterior pituitary gland.

The anterior pituitary serves primarily in the production of six trophic hormones produced through five hormone producing cell types:

1. **FSH** and **LH** (gonadotrophins) produced by cells known as Gonadotrophs. FSH and LH are glycoproteins responsible for the process of growth, maturation and rupture of Graafian follicles (ovulation), and maintenance of corpus luteum function.
2. **TSH** (thyrotropin stimulating hormone) produced by cells known as thyrotrophs.
3. **ACTH** (adreno-cortico-trophic hormone) produced by Adrenocorticotrophs.
4. **GH** (growth hormone) produced by cells known as somatotrophs.
5. **PRL** produced by cells known as lactotrophs.

Pituitary hormones are all **stimulated** and controlled by hypothalamic releasing hormones (GnRH, GHRH, TRH, and CRH) with the exception of PRL which is under chronic **inhibition** by prolactin inhibiting factor **(PIF)**. Consequently damage to the pituitary stalk will result in hypopituitarism for FSH, LH, GH, ACTH, and TSH, but with an associated increase in PRL secretion.

B. The posterior pituitary gland (neurohypophysis):

The posterior pituitary (neurohypophysis) consists of the posterior lobe (pars nervosa), and the neural stalk (Infundibulum). It is derived from neural tissue and is in direct continuity with the hypothalamus and CNS.

The posterior pituitary serves primarily in the transport **oxytocin** and **vasopressin** (antidiuerteic hormone ADH) along neuronal axons from the supraoptic and paraventricular nuclei of the hypothalamus to their release into the circulation.

THE OVARIAN CYCLE

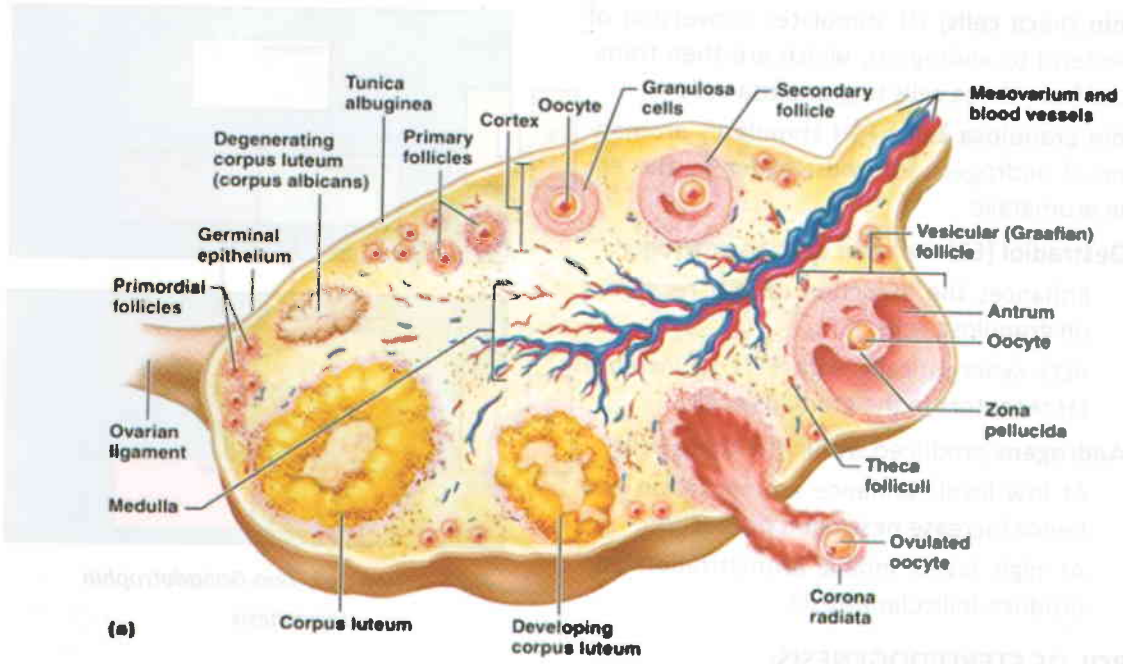

Fig 4-2: histology of the ovary at different phases of ovarian cycle

The **foetal ovary** contains a maximum number of **7 million** primordial follicles at mid-gestation. The number then declines sharply reaching **1.5-2.0 million** at birth, then declines gradually to reach around **400.000** primordial follicles at puberty. Throughout the menstrual cycles ovarian follicles become gradually exhausted until they become **depleted** by the time of the **menopause**.

The ovarian cycle is divided into **follicular phase**, and **luteal phase**, separated by **ovulation**.

A. FOLLICULAR PHASE:

This phase lasts from the **1st day** of menses till **ovulation**. It is of **variable** length (mean **14** days). Graafian follicles grow and mature under the influence of follicle stimulating hormone **FSH**. They produce increasing amounts of **E2**, which lead to **proliferative** changes in the endometrial glands.

1. THE PRIMORDIAL FOLLICLE

Each primordial follicle consists of a single oocyte, arrested in the diplotene stage of the prophase of the first meiotic division, surrounded by a single layer of flattened cells (granulosa cells) and cells of the ovarian stroma (theca cells).

2. THE PRE-ANTRAL FOLLICLE

FSH stimulates growth of several primordial follicles, the oocytes grow and the granulosa cells multiply to become multilayered cuboidal shape, thus changing into a *preantral follicle*.

THE TWO-CELL, TWO-GONADOTROPHIN hypothesis of oestrogen production

A) Within theca cells; LH stimulates conversion of cholesterol to androgens, which are then transported from theca cells to granulosa cells

B) Within granulosa cells; FSH stimulates aromatization of androgens into oestrogens by the enzyme aromatase.

- **Oestradiol (E2)** the chief ovarian oestrogen;
  - Enhances the induction of FSH receptors on granulosa cells.
  - Acts synergistically with FSH to increase LH receptors in the granulosa cells.
- **Androgens** produced within the theca cells;
  - At low levels enhance aromatization and hence increase oestrogen production.
  - At high levels inhibit aromatization and produce follicular atresia.

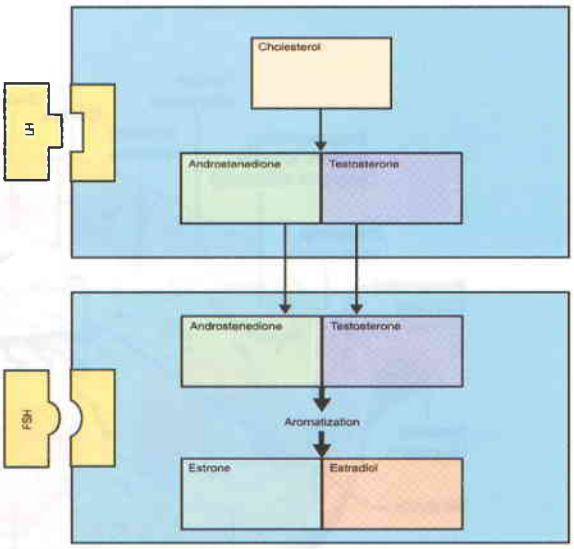

Fig 4-3: Two-Cell, Two-Gonadotrophin Hypothesis

CONTROL OF STEROIDOGENESIS:

Apart from FSH, LH, oestrogen and androgens, some **autocrine and paracrine mediators** play an important role in the process of folliculogenesis as:

A. **Inhibin:** A peptide produced by granulosa cells that attenuates FSH production and enhances LH-induced androgen synthesis, thus the dominant follicle can continue development and other follicles undergo atresia.

B. **Activin:** A peptide produced by granulosa cells and the pituitary gland that augments FSH production, an action almost directly opposite to that of inhibin.

C. **Growth Factors:** As Insulin like growth factor **(IGF)**, fibroblast growth factor **(FGF)**, and epidermal growth factor **(EGF)**, may all help enhanced responsiveness to FSH.

SELECTION OF THE DOMINANT FOLLICLE

- During folliculogenesis a dominant follicle is selected to continue growth, maturation, and ovulation. Other follicles will be arrested and later become atretic.
- The selected follicle is characterized by having the highest number of FSH receptors in its granulosa cells, having the most efficient aromatase activity, the highest concentration of FSH induced LH receptors, the greatest amounts of E2 and inhibin produced, and thus requiring the least FSH and LH levels to complete maturation.

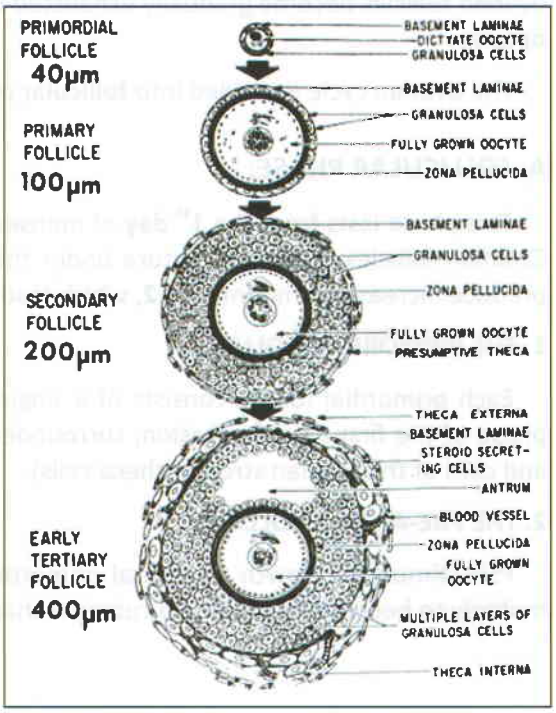

Fig 4-4: development of the primordial to mature follicle

3. THE PREOVULATORY FOLLICLE (MATURE GRAAFIAN FOLLICLE)

The oocyte is pushed to one side of the follicle, secretes clear gelatinous material around itself forming the zona pellucida. Simultaneously the theca cells become differentiated into theca interna and theca externa around the multiple layered granulosa cells.

B. OVULATION

- **Late in the follicular** phase, **FSH** results in production of increasing amounts of **oestradiol (E2)** by the dominant follicle, and induces **LH receptors** on the granulosa cells. High **E2** levels exert a positive feedback effect on the pituitary gland, with release of **LH** rapidly and in increasing amounts.
- **LH** induces luteinization of granulosa cell in the dominant follicle so that **progesterone (P)** starts to be produced. **(P)** Amplifies **(E2)** induced positive feed back on LH secretion leading to an **LH surge**.
- **Ovulation** occurs approximately 36 hours after the onset of the **LH surge** and about 12 hours after the **LH peak.**
- **Oocyte release** is facilitated by FSH, LH, and (P) induced activation of collagenase enzyme that breaks down the follicle wall, preparing for its rupture.
- **Resumption of meiosis** occurs during the process of ovulation, with oocytes progressing from prophase I through metaphase II.

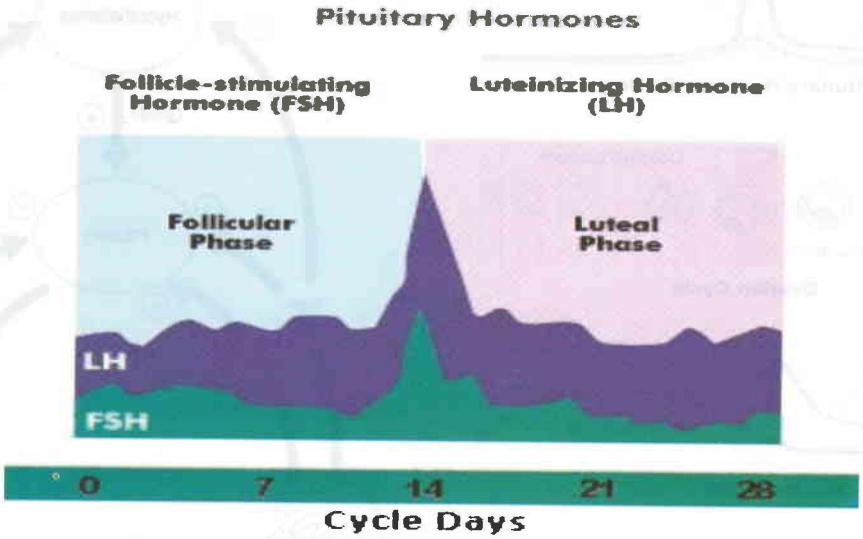

Fig 4-5: Diagram showing LH surge

C. THE LUTEAL PHASE

- The luteal phase extends from the time of ovulation till the onset of menstruation, and is fairly constant lasting for about **14 days**.
- **Corpus luteum (CL) formation:** After ovulation, and under the influence of **LH**, the granulosa cell of the ruptured follicle undergoes **luteinization.** These luteinized granulosa cells, plus the surrounding theca cells, capillaries, and connective tissue, form the **CL**. The luteinized cells of the CL have a vacuolated appearance associated with the accumulation of a yellow pigment **(lutein)** where the name CL is derived.

- **The CL**, in response to the continuous pituitary **LH** stimulation, will produce copious amounts of Progesterone **(P)** and smaller amounts of **(E2)** and little **inhibin** leading to decreased FSH & LH production hence the initiation of new follicular growth in the luteal phase will be inhibited.
- **Progesterone** produced by the CL will lead to secretory changes in the endometrium, which is necessary to prepare the endometrium for implantation of the embryo
- **Fate of the CL:** The duration of the luteal phase is fairly constant in most women being around **14 days**. The life span of the **CL** is around **9 days** after which it undergoes **luteolysis** and becomes replaced by the avascular corpus albicans.
  - In absence of pregnancy; the CL undergoes apoptosis and cease to produce (P) by 12-14 days after ovulation. Gonadotrophin inhibition is released and FSH starts to rise
  - In presence of pregnancy trophoblastic production of human chorionic gonadotropins (hCG) will maintain (P) secretion from the CL until placental steroidogenesis is established about the 8th week of gestation
- **As the CL dies**, E2, P, and inhibin levels decline and the pituitary gland becomes released from the negative feed back effect of these hormones. FSH levels start to rise, cohorts of follicles which happen to be in the preantral stage are rescued from atresia, and a new ovarian and menstrual cycle is now initiated.

Hormonal Patterns in the Menstrual Cycle

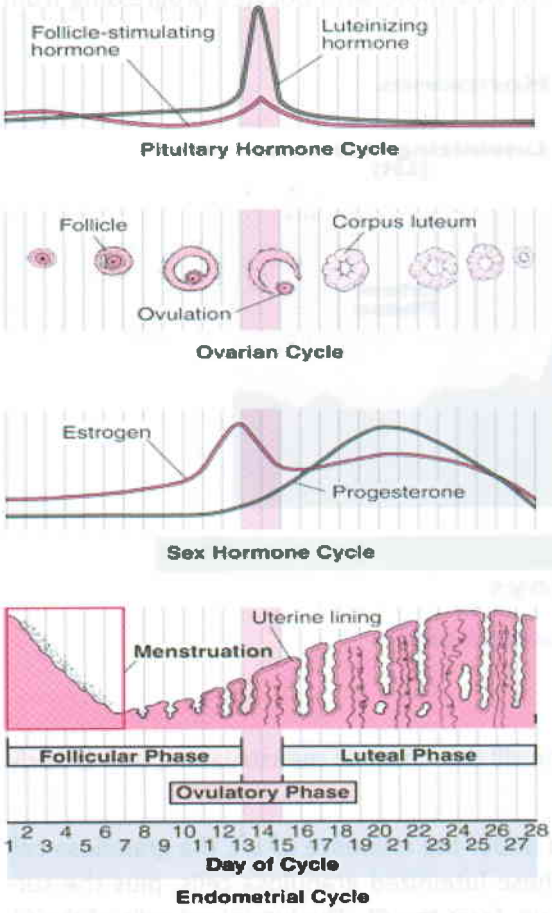

Fig 4.6: hormonal patterns in the menstrual cycle

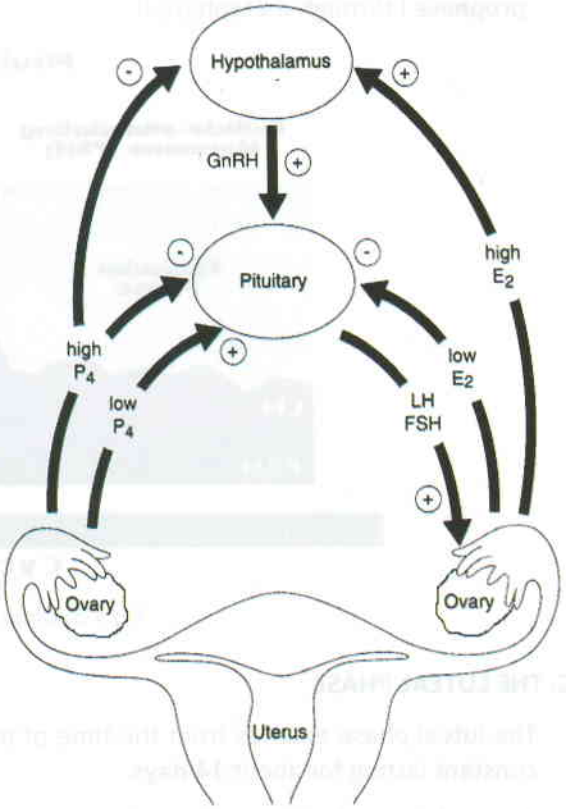

Fig 4-7: H-P-O axis showing positive and negative feedback of hormones (P4: progesterone, E2:oestradiol)

Levels of feed-back to the hypothalamus

a. *The long feedback loop*, from ovarian hormones (oestrogens and androgens).

b. *The short feedback loop*, from the pituitary hormones (FSH & LH).

c. *The ultra-short feedback loop*, from the hypothalamic releasing factors.

Positive and Negative feed back loops

- Low levels of E2 have an inhibiting effect on LH **(negative feedback)**, whereas high E2 levels stimulate LH production **(positive feedback)**.
- Low levels of P have a **positive feedback** effect on FSH & LH and share in the production of an LH surge prior to ovulation. High P levels present in the mid-luteal phase inhibit LH & FSH consequently inhibiting growth of primordial follicles in the luteal phase thus producing a **negative feedback** effect.

THE ENDOMETRIAL CYCLE

Changes in the endometrium in response to ovarian hormones throughout the menstrual cycle are divided into three phases; proliferative phase, secretory phase, and menstruation.

1. THE PROLIFERATIVE PHASE

- The proliferative phase of the endometrium coincides with the follicular phase of the ovarian cycle, and is characterized by both glandular and stromal growth.
- It starts with shedding of the endometrium at menstruation, and continues under the effect of ovarian **oestrogen** produced by the maturing **follicles** till ovulation occurs.
- The epithelium lining the endometrial glands changes from a single layer of low columnar cells to pseudo-stratified epithelium with frequent mitoses, and the stromal component of the endometrium also expands rapidly.
- The endometrial thickness grows from 0.5 mm at the end of menstruation to about 5-8 mm at the end of the proliferative phase.

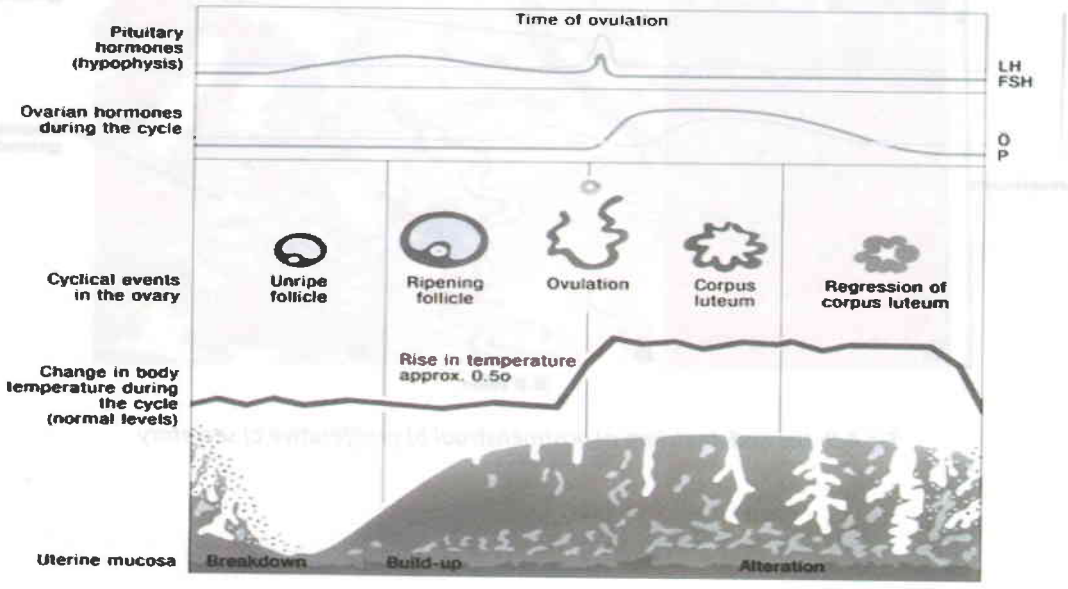

Fig 4-8: the endometrial cycle

2. THE SECRETORY PHASE

The secretory phase of the endometrium coincides with the luteal phase of ovarian cycle, and is characterized by endometrial glandular secretory activity. It starts shortly after ovulation and continues, under the effect of **P and E2** produced by the **CL**, till menstruation starts.

- **Progesterone** inhibits oestrogen induced cellular proliferation restricting the depth of endometrial thickness, while endometrial glands continue to grow leading to increased tortuosity of both glands and spiral arteries in order to fit in the endometrial layer.
- In the **early secretory phase**; shortly after ovulation, vacuoles containing subnuclear intracytoplasmic granules appear in glandular cells. These vacuoles progress to the apex of the glandular cells and their contents are released into the endometrial cavity.
- In the **mid-secretory phase;** peak secretory activity occurs at the time of implantation, seven days after the LH surge (mid luteal phase), with associated stromal oedema. Within the endometrium large granulated lymphocytes predominate, which may play a role in regulating trophoblastic invasion during implantation if pregnancy occurs.
- In the **late secretory phase;** progesterone induces irreversible decidualization of the stroma. The surrounding stroma cells display increased mitotic activity and nuclear enlargement. Three distinct zones of the endometrium can be seen:
  a. ***The basal portion*** *(basalis)*: represents the basal 25% of the endometrium, which is retained during menstruation and shows few changes during the menstrual cycle.
  b. ***The mid-portion*** *(spongiosum)*: composed of oedematous stroma, glandular tortuosity and secretions.
  c. ***The superficial portion*** *(compactum)*: composed of decidualized stromal cells.

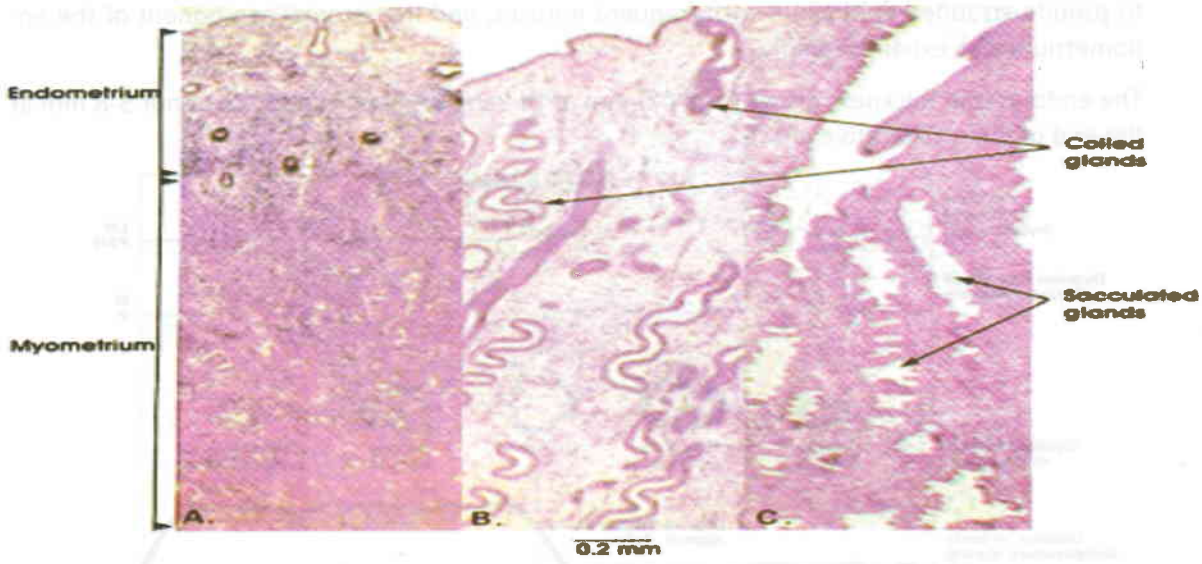

Fig 4-9: the endometrium a) postmenstrual b) proliferative c) secretory

3. MENSTRUATION

Menstruation is the cyclic shedding of the superficial and intermediate layers of the endometrium in response to progesterone withdrawal after CL demise.

A) Endometrial shedding:

- Premenstrual sharp and rapid decline in P & E2 levels result in coiling and **vasoconstriction** of the endometrial spiral arteries, with **ischaemia** to the functional portion of the endometrium (superficial and intermediate layers)
- Vasoconstriction is initiated and controlled through the action of prostaglandin F2 alpha **(PGF2-a)**, endothelin-1 **(ET-1)** and platelet-activating factor **(PAF)**.

Haemostasis:

- Achieved by vasoconstriction of spiral arteries, and increased platelet aggregation.
- Enhanced fibrinolysis with breakdown of blood clots minimizes endometrial scarring and clot formation.

Regeneration and Repair:

- Within 2 days from the onset of menstruation the surface epithelium begins to regenerate under the influence of follicular phase oestrogen.
- Angiogenesis (new blood vessel formation) and endometrial regeneration lead to complete cessation of bleeding within 5-7 days from the start of menstruation

CERVICAL MUCUS CHANGES DURING THE MENSTRUAL CYCLE

The physical and chemical properties of the cervical mucus vary in relation to the changing oestrogen and progesterone levels in the follicular and luteal phases of the menstrual cycle.

In the follicular phase, cervical mucus becomes more profuse, watery, and less cellular, to allow for easier sperm penetration at the time of ovulation (peak oestrogen effect).

After ovulation and throughout the luteal phase, cervical mucus becomes scanty, viscid, and more cellular, and less ready for sperm penetration (peak progesterone effect)

Cervical mucus changes in the menstrual cycle

Follicular phase (oestrogen effect)	Luteal phase (progesterone effect)
• Profuse	• Scanty
• Decreased viscosity (thin-watery)	• Increased viscosity (thick-viscid)
• Decreased leucocytes	• Increased leucocytes
• Positive Ferning test	• Negative Ferning test
• Positive Spinbarkeit test (threads 7-10 cm)	• Negative Spinbarkeit test (threads 3-4 cm)

- **Ferning test**: Microscopic examination of a drop of cervical mucus left to dry for 10 minutes on a glass slide in the **follicular phase** will reveal an **arborizing palm leaf pattern**, due to its high sodium chloride and potassium content in response to a high oestrogenic levels (+ve test). In the luteal phase the arborizing pattern is lost giving a negative test.
- **Spinbarkeit test** is positive when the cervical mucus can be drawn between two slides into threads stretching up to 10 cm due to high mucus content in response to high oestrogen levels

Vaginal Epithelial Cellular changes during the menstrual cycle

The vaginal epithelium is composed of basal, intermediate, and superficial (mature) cells.

- **In the follicular phase** under oestrogenic effect superficial cells predominate
- **In the luteal phase** progesterone causes shedding of more intermediate cells

N.B.; Maturation index calculates the ratio of basal, intermediate, to superficial cells on vaginal cytology

Cytology of the vaginal epithelium in different phases of the menstrual cycle

Follicular phase vaginal cytology	Luteal phase vaginal cytology
• Superficial cells with non rolled edges • Eosinophilic cytoplasm • Pyknotic nucleus	• Intermediate cells with rolled edges • Basophilic cytoplasm • Vesicular nucleus
• Few lymphocytes	• Many lymphocytes
• Maturation index 0-30-70	• Maturation index 0-70-30

DYSMENORRHOEA

DEFINITION

Dysmenorrhoea is defined as **pain** and **cramping** during menstruation that **interferes** with normal activities, and requires the use of **medications** to control the symptoms. **Pain** may range from **mild** discomfort, to **severe** pain that causes some patients to be bedridden for 1-3 days each month.

INCIDENCE

Dysmenorrhoea affects **45-90%** of women in their reproductive age with variable degrees of severity. Almost **50%** of women will suffer significant pain, with **10%** of these become incapacitated during the first few days of the cycle.

CLASSIFICATION

- **Primary** dysmenorrhoea is idiopathic menstrual pain without identifiable pathology
- **Secondary** dysmenorrhoea is painful menses due to underlying pathology (endometriosis, fibroids, adenomyosis, PID, cervical stenosis).

PRIMARY DYSMENORRHOEA

Primary Dysmenorrhoea is almost always associated with ovulatory cycles, with *no obvious organic cause.*

Aetiology

- Mostly results from increased levels of endometrial prostaglandins **(PGLs)**
- Additional **psychological** component may be involved in some patients
- The condition usually spontaneously improves after term pregnancies and deliveries

Diagnosis

- *Age;* usually occurs in younger women <20 years of age
- *Pain;* occurs on the 1st or 2nd days of ovulatory cycle
- *Associated symptoms;* nausea, vomiting, and headaches
- *Physical examination;* reveals no obvious abnormalities or pelvic pathology
- *Pelvic US;* reveals normal uterus, ovaries, and adnexa.

Treatment

1. ***Non steroidal anti-inflammatory drugs (NSAIDs):*** this is the first and most important line of treatment (aspirin, Ibuprofen, ketoprofen, and naproxen). They are taken at onset of menses, continued for 1-3 days then taken as needed.
2. ***Combined oral contraceptive pills (COCs):*** OCPs are the second line of treatment in cases which do not get adequate pain relief with the use of NSAIDs alone, or cannot tolerate their side effects.

SECONDARY DYSMENORRHOEA

Secondary dysmenorrhoea may occur in both ovulatory and anovulatory cycles.

Aetiology

Symptoms are 2ry to an **identifiable cause**, such as endometriosis, uterine leiomyomas, cervical stenosis, pelvic adhesions, and PID.

Diagnosis

- *Age;* women are commonly middle aged (30-35 years)
- *Parity;* it occurs in both parous and nulliparous women
- *Pain;* starts few days before menses and gradually decreases by onset of menses. It is dull aching or colicky suprapubic pain commonly associated with low back ache that usually occurs after several years of relatively painless menstruation.
- *Physical examination;* may detect sizable uterine or adnexal masses
- *Pelvic US;* may diagnose smaller uterine myomas, ovarian endoemtriomas, and tubo-ovarian masses
- *Laparoscopy;* for diagnosis of endometriosis, pelvic adhesions, and PID.

Treatment

- ***Medical treatment:*** to control pain via NSAIDs
- ***Hormonal treatment:*** OCP, Gestagens, and GnRH agonists (see endometriosis)
- ***Surgical treatment:*** for larger myomas, endoemtriomas, and tubo-ovarian mass

THE PREMENSTRUAL SYNDROME

The premenstrual syndrome **(PMS)** describes a group of **physical** and/or **emotional** changes that constantly **occur** and **recur** in the **luteal phase** of successive cycles, severe enough to interfere with the patient's regular life style.

Symptoms and changes include; headache, weight gain, bloating, breast tenderness, mood fluctuation, restlessness, irritability, anxiety, depression, and fatigue.

Symptoms should occur in the **2 weeks prior to menstruation** (luteal phase), with at least a *7 day symptom free interval* in the first half of the menstrual cycle.

The **highest incidence of PMS** occurs in women in their late 20's to early 30's.

Up to **80%** of women will report uncomfortable symptoms in the premenstrual period. However in only **5-10%** symptoms will be **severe** enough to interfere with daily activities. In almost **60%** of severe PMS cases an underlying **psychiatric disorder** can be elicited.

Aetiology

The causes of PMS are **not completely understood.**

- PMS may be due to the interaction between the **neurotransmitter serotonin** and cyclic changes in **ovarian steroids.**
- PMS is more pronounced in **genetically** and **psychologically** susceptible women.
- Although women with PMS have normal levels of E2 & PRG, they may have an **abnormal response** to normal hormonal changes.

TREATMENT

Treatment of PMS is based on alleviating symptoms with special consideration to the psychological aspects of PMS. They include;

1. **Selective serotonin reuptake inhibitors** have demonstrated reasonable efficacy in treating both physical and mood symptoms in women with severe PMS, taken as daily oral tablets throughout the menstrual cycle.
2. **Changes in the life style:** as regular exercise, balanced diet, avoid premenstrual stress, eliminate caffeine, cigarette smoking, and alcohol ...etc
3. **Calcium** 600 mg BID, **Vitamin D** 800 IU/day, **Vitamin B6** (100 mg/day), & **Magnesium** 20 mg/day), all may slightly improve PMS symptoms in many women.
4. **OCP:** may improve some cases as it minimizes fluctuations in ovarian steroids.



05 PUBERTY AND ITS DISORDERS

Normal puberty
- *Definition*
- *Pathophysiology*
- *Clinical manifestations*

Disorders puberty
- *Precocious puberty*
- *Delayed puberty*

PUBERTY

DEFINITION

Puberty is the period of life that marks the normal physiologic transition from childhood to sexual and reproductive maturity (physical, mental, sexual growth).

During puberty the hypothalamus, pituitary gland, and ovaries undergo a maturation process that ultimately leads to the complex development of secondary sexual characters involving the breast, sexual hair, and genitalia, in addition to a limited acceleration in physical growth.

Normally, pubertal changes start by the age of 8-9 years, and is completed by the age of 12-14 years culminating by the onset of menses and acquiring the reproductive capacity.

PATHOPHYSIOLOGY OF PUBERTY

- In childhood hypothalamic Gn RH is centrally suppressed mostly via control by a gene in the Gn RH nucleus.
- At initiation of puberty single nocturnal spikes of **Gn RH** start to occur, and gradually increase in frequency becoming night and day over a period of 1-2 years, until the normal adult frequency is achieved.
- Pituitary FSH secretion starts in response to pulsatile GnRH stimulation, resulting in stimulation of follicular development, oestrogen production, appearance of secondary sexual characters, and finally the onset of menstruation with the establishment of ovulatory cycles.
- Other factors as leptin play an important role in the initiation of puberty

CLINICAL MANIFESTATIONS OF PUBERTY

1. **Growth spurt:** is the first sign of puberty to occur with a peak growth velocity at age of 11 years, followed by a slower growth rate until cessation usually by age of 15 years, where closure of bone epiphysis occurs in most girls as an effect of increased oestrogen levels.
2. **Thelarche: (Breast Development):** The breast grows in phases (5-stages) under the effect of oestrogen. This starts by growth of the body of the breast (budding), followed by pronounced areolar development and ends by full breast development, where the breast tissue grows to become confluent with the areola (fig 5-1 Tanner stages of breast development).
3. **Pubarche:** Growth of pubic hair occurs under effect of ACTH and androgens. Pubic hair growth is classified into (5-stages) according to degree of distribution (fig. 5-2 Tanner stages of pubic hair growth).
4. **Menarche:** This is the onset of first menstruation. Its average age in Egypt is 12.5 years.
5. **Axillarche:** growth of axillary hair, appears later also under effect of androgens.

TANNER STAGES OF PUBERTAL GROWTH

Pubertal cascade starts usually by growth spurt, followed by breast development, pubic hair, menarche, and finally axillary hair. **Tanner** had classified physical stages of puberty into 5-stages depending on the degree of breast development and distribution of pubic hair.

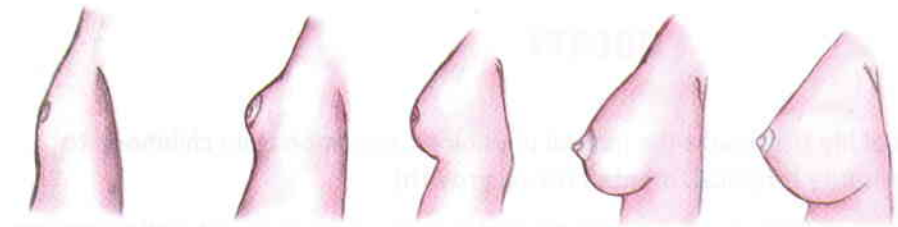

Fig 5-1: Tanner Stages of the Breast

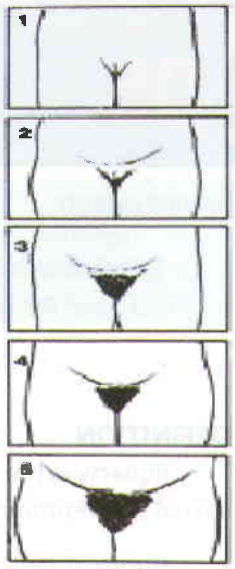

Fig 5-2: Tanner Stages of pubic hair

DISORDERS OF PUBERTY

I. PRECOCIOUS PUBERTY

Precocious puberty describes **appearance of secondary sexual characters before 8 years** of age, with or without onset of menstruation. Besides the psychological impact of the syndrome, early oestrogen production will carry the risk of short stature from early epiphyseal bone closure.

A) ISOSEXUAL PRECOCIOUS PUBERTY (IPCP)

The secondary sexual characters are in agreement with genetic and phenotypic sex

1. True IPCP: (GnRH dependant, possibly be associated with ovulation)

- ***Constitutional:*** due to idiopathic premature activation of the gene in the GnRH cell, leading to early FSH production, and early onset of ovarian E2 secretion (74% of cases).
- ***Organic:*** due to CNS lesions that impede neural signals that normally inhibit GnRH release in childhood
  a. Tumours; craniopharyngioma, adenoma, glioma, etc....
  b. Infections; meningitis, encephalitis, etc...
  c. Malformations; hydrocephalus, empty sella syndrome, hamartomas, etc....
  d. Head trauma

2. Pseudo IPCP: (GnRH independent, not associated with ovulation)

a. Oestrogen secreting ovarian tumours(granulosa theca cell tumours)
b. Primary hypothyroidism; elevated TSH may induce FSH production
c. Exogenous oestrogen intake

B. HETEROSEXUAL PRECOCIOUS PUBERTY (HPCP)

The secondary sexual characters are in disagreement with genetic and phenotypic sex.

a. Androgen secreting tumours (virilizing ovarian or adrenal neoplasia)

b. Congenital adrenal hyperplasia (CAH)

c. Exogenous androgen intake

C. ISOLATED PREMATURE PUBERTAL EVENTS

Isolated pubertal events may occur, as premature menarche only, or premature thelarche only, etc, without other oestrogen induced pubertal events or advancement of bone age. Such condition is usually benign and does not usually necessitate treatment.

DIAGNOSIS OF PRECOCIOUS PUBERTY

- **History and Physical examination:** Age, height, growth spurt, breast development, and hair distribution, according to Tanner stages of pubertal development.
- **Hormonal assays:**
  - Pituitary gonadotropins (serum FSH & LH)
  - Serum E2, and DHEAS, to detect ovarian and adrenal contribution.
  - Thyroid function tests (TSH, T3, & T4) to exclude 1ry hypothyroidism.
- **Radiological investigations:**
  - X-ray to the wrist of the non dominant hand to determine bone age.
  - CT & MRI for brain tumours and intracranial masses.
  - Pelvic ultrasound for exclusion of ovarian tumours or cysts.

MANAGEMENT OF PRECOCIOUS PUBERTY

The chief goal at therapy aims at slowing down accelerated growth and inducing regression of secondary sex characters through reducing pituitary and ovarian hormones, thus avoiding premature epiphyseal closure which predisposes to **short stature.**

a. Idiopathic PCP: long acting GnRH agonists will suppress pituitary FSH & LH, and ovarian E2, halting the progression through puberty. Treatment is continued until an appropriate age has been reached for resumption of pubertal development.

b. Functioning ovarian tumours are surgically removed

c. Primary hypothyroidism is treated with thyroid replacement therapy (Eltroxin)

d. Adrenal tumours are treated with surgery or irradiation

II. DELAYED PUBERTY

Puberty is considered delayed if no secondary sexual characters are noted by the age of 13-14 years, or if menses is still absent by the age of 15-16 years. Delayed puberty affects almost 3% of adolescents. Causes, diagnosis and management are discussed in primary amenorrhoea.

Aetiology

A. Hereditary Factors:

These may account for about 10-20% of cases. Constitutional delay may run in families mostly due to delayed activation of the GnRH pulse generator.

B. Chromosomal abnormalities, genetic, and autoimmune disorders:

These may be present in up to 50% of cases. The ovaries, or gonads, are non-functioning and unable to respond to gonadotropins, leading to markedly elevated FSH & LH levels (hypergonadotrophic hypogonadism). Examples include Turner syndrome (45 X), premature ovarian failure, autoimmune ovarian failure, and gonadal dysgenesis.

C. Pituitary and hypothalamic tumours and severe illness:

These conditions account for 10-15% of cases with delayed puberty. The ovary is normal however there is lack of production of hormonal stimulation from the hypothalamus, leading to low FSH & LH levels (hypogonadotrophic hypogonadism). Examples include Kallmann syndrome (isolated GnRH deficiency), and hypothalamic suppression by stress, severe disease, and malnutrition.

D. Pituitary tumours and lesions:

Prolactinomas and empty sella syndrome; induce hyperprolactinaemia which suppresses GnRH pulses, while tumour invasion by craniopharyngiomas suppress Pituitary gonadotrophins (hypogonadotrophic hypogonadism).

E. Congenital Mullerian agenesis or dysgenesis: absent or hypoplastic uterus, in presence of normal ovaries will result in primary amenorrhea with normal development of 2ry sexual characters (euogonadotrophic hypogonadism).

DIAGNOSIS AND INVESTIGATIONS

See examination and investigations for Precocious puberty and primary amenorrhoea

TREATMENT FOR DELAYED PUBERTY

Treatment for delayed puberty depends on the cause of the problem. Often, when the underlying cause is treated, puberty proceeds normally.

- If the delayed puberty is due to heredity, no treatment is usually necessary.
- In some cases, treatment may involve hormone therapy to stimulate the development of secondary sexual characteristics (combined oestrogen progesterone therapy), or surgery to correct an anatomical problem.
- In gonadal dysgenesis with a Y chromosome present gonadectomy should be performed for the risk of neoplastic changes in the gonads

06 MENOPAUSE AND ASSOCIATED CONDITIONS

- *Perimenopause*
- *Menopause*
- *Postmenopause*
- *Hormone therapy in menopause*
- *Prevention and management of Osteoporosis*

PERIMENOPAUSE

- **Climacteric** is the phase of the aging process during which a woman passes from the reproductive to the non-reproductive stage *(Figo definition)*.

- **The Perimenopause,** also known as the **menopausal transition**, refers to the part of the climacteric before the menopause (*2-8 years prior to the FMP),* in which there is transition from normal ovulatory cycles to permanent amenorrhoea of menopause.
  - This period is characterized by irregular menstrual cycles together with some of the symptoms associated with the menopause as; hot flushes, night sweats, and mood swings.
  - During this period, **inhibin-B** secretion from granulose cells falls due to diminished follicular number, and as result **FSH** levels rise, and **PRG** levels become low.
  - Ovarian **E2** secretion is preserved until late perimenopause

MENOPAUSE

Menopause is the final menstruation that occurs at the end of climacteric. It is defined by *12 months of amenorrhea after the final menstrual period* ***(FMP)***, in the absence of any other pathological or physiological cause.

Menopause occurs due to depletion of ovarian primordial follicles due to their consumption since menarche (the adult ovary at puberty contains around 400.000 primordial follicles).

- **Natural Menopause:** occurs due to intrinsic ovarian failure that usually occurs between 45-55 years with a median age of **51** years. It is characterized by complete, or near complete, ovarian follicular depletion, with subsequent cessation of ovarian estrogen (E2) secretion.
  - *Late or delayed menopause:* menopause occurring > 55 years of age
  - *Early or premature menopause:* menopause occurring between 40-45 years of age

- **Induced Menopause:** menopause can be artificially induced;
  - *Surgically;* as *after bilateral oophorectomy*
  - *Ablation of ovarian function;* as pelvic irradiation or systemic chemotherapy
  - *Medically:* during the use of long acting GnRH agonists in the management of endometriosis.

- **Premature Menopause** occurring at an age 40-45 years may be either;
  - *a) Premature ovarian insufficiency* ***(POI):*** due to congenitally deficient number of ovarian follicles at puberty, leading to their early exhaustion at a relatively young age.
    - Idiopathic: no underlying etiology
    - Gonadal dysgenesis: as in cases of mosaic turner syndrome (46XX/45XO)
  - *b) Induced:* surgical, irradiation, or chemotherapy before the age of 45 years

ENDOCRINE CHANGES CHARACTERISTIC OF MENOPAUSE

- *Decreased* serum **inhibin-B** levels that started at the perimenopause.
- Marked *increase* in serum **FSH** & **LH** levels.
- Marked and persistent *decrease* in Ovarian **E2** levels
- *Decrease* in sex hormone binding globulin **(SHBG)**
- *Increased* free testosterone **(FT)** levels
- *Persistent* production of ovarian testosterone **(T).**

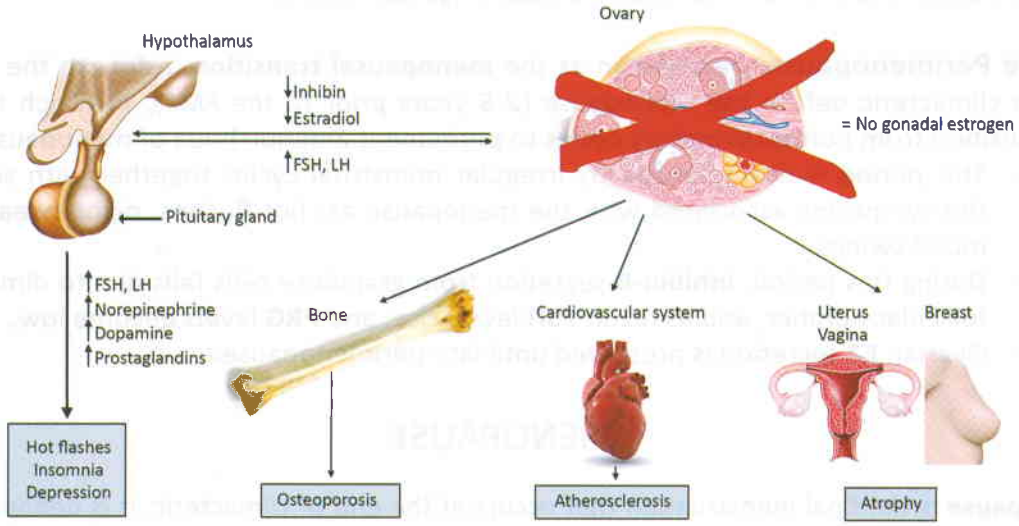

Fig 6-1: Changes in both the ovary and the hypothalamus contributing to changes of the menopause

CHANGES IN BODY SYSTEMS ASSOCIATED WITH MENOPAUSE

Changes in the menopause start in the climacteric period, and continue gradually and persistently after cessation of menstruation. They are almost all related to **estrogen deficiency**, and are therefore gradually progressive and time related.

- ***The vagina*** becomes smaller, thinner, with gradual loss of its rugae, decreased vascularity, and increased vaginal PH. Vaginal smears become atrophic.
- ***The pelvic ligaments*** become weaker predisposing to pelvic organ prolapse (POP).
- ***The uterus*** becomes smaller in size. If myomas are present they undergo atrophy.
- ***The endometrium*** becomes thin and atrophic (< 5 mm thickness)
- ***The cervix*** becomes gradually flushed with vaginal fornices, and the squamo-columnar junction migrates higher in the endocervical canal.
- ***The urethra*** and ***bladder mucosa*** show loss of elasticity, bladder dysfunction, and stress incontinence (due to relaxation in the weak pelvic ligaments).

- ***The Breasts*** become gradually smaller and flabby with progressive fatty replacement of breast tissue and atrophy of active glandular elements.
- ***The skin*** shows gradual decrease in thickness and collagen content.
- *Increased* ***facial hair*** and androgenic alopecia in response to increased androgens
- Gradual changes in ***cognitive function*** and ***mood swings***.
- *Decreased* ***mineral bone density*** leading to osteoporosis (see later)
- *Nervous* and *Psychological changes*

CLINICAL FEATURES OF THE MENOPAUSE (Symptoms & Signs)

Most menopausal manifestations are secondary to the chronic low serum E2 levels characteristic of the menopause.

Symptoms usually start gradually in the perimenopause, increase sharply after FMP, and extend years into the menopause.

In almost 50% of women menopausal symptoms will be severe enough to call for gynaecologic consultation and or treatment.

Menstruation may stop abruptly, however the FMP is more commonly preceded by a period of oligomenorrhoea in the late Perimenopausal period.

1. Vasomotor Symptoms (VMS); Hot flushes & Cold sweating

- *Hot flushes:* are recurrent waves of heat over the chest, neck, and face, followed by *cold sweating*. A flush may last for 1-5 minutes, and may be associated by palpitation, dizziness or headaches.
- *Flushes affect at least 50%* of menopausal women but with variable grades of severity.
- *Flushes start in the perimenopause* and become more aggressive in the menopause.
- *Flushes result from* inappropriate stimulation of the thermoregulatory centres in the hypothalamus with vasodilatation of the skin over the head, neck, and chest, causing a skin temperature rise although core body temperature does not change.

2. **Nervous and psychological symptoms:** Anxiety, irritability, mood changes, insomnia, and lack of concentration, are common although with variable degrees.
3. **G.I.T. symptoms:** Constipation, abdominal distension, and tendency to weight gain
4. **Dyspareunia:** due to vaginal atrophy, dryness, and senile vaginitis.
5. **Urinary symptoms:** as frequency, dysuria, and stress urinary incontinence, may occur alone or in association with pelvic relaxation and genital prolapse.
6. **Tendency towards pelvic organ prolapse (POP)**: uterine and vaginal prolapse occur more frequently due to weakness and atrophy of pelvic and cervical ligaments.
7. **Androgenic manifestations:** increased facial hair and baldness affect women variably.
8. **Symptoms related to osteopenia and osteoporosis** (see later)

DIAGNOSIS OF MENOPAUSE

- Amenorrhoea for I year after the FMP in premenopausal women
- Elevated serum FSH levels (> 30 mIU/ml)
- Low E2 levels (<25mIU/ml)
- Menopausal symptoms; as flushes, cold sweats, irritability, insomnia, and weight gain

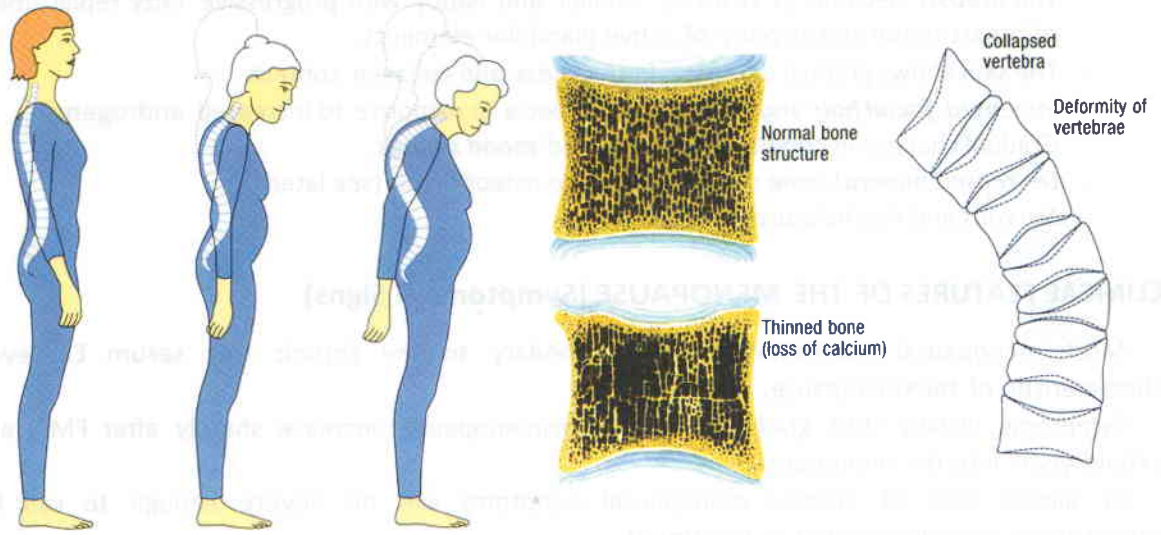

Fig 6-2: Osteoporotic changes in menopause

MANAGEMENT OF THE MENOPAUSE

- *Reassurance* about the physiological nature of the menopausal symptoms
- *Education for healthy life style;* Calcium rich diet, suitable exercise, and avoid smoking.
- *Symptomatic treatment for some menopausal symptoms;* Sedatives, tranquilizers, or antidepressants on individual basis whenever needed.
- *Periodic tests* for early detection of premalignant and malignant lesions including; Mammography, TVS, Pap smear cytology, and colposcopy.
- *Diagnosis, prevention, and treatment of osteoporosis* (see later).
- *Hormone therapy (HT)* in selected cases with severe menopausal symptoms (see later).

REMOTE HEALTH HAZARDS RELATED TO MENOPAUSE

CARDIOVASCULAR SYSTEM CHANGES (CVS)

- ***Pathogenesis:*** Oestrogen deficiency may lead to hypercholesterolemia with increased LDL and decreased HDL (reversed LDL/HDL ratio).
- ***Clinical manifestations:*** reversed LDL/HDL ratio may predispose to ischaemic coronary heart disease (ICHD), myocardial infarction (MI), atherosclerosis, hypertension (HTN), and cerebrovascular strokes.

OSTEOPOROSIS

- ***Definition:*** Osteoporosis is a disorder characterized by decreased bone mineral density leading to compromised bone strength with increased risk of bone fractures.
- ***Pathogenesis:*** Oestrogen deficiency results in accelerated bone mineral calcium loss, and increased activity of osteoclasts (bone destroying cells), affecting mainly the vertebrae, femoral neck, distal radium, and the calcaneum.
- ***Clinical manifestations:*** bone demineralization is usually a silent disease that manifests years after menopause with; decreased height, increased curvature of the spine, silent fractures of the vertebrae, or fractures of the hip and long bones on exposure to mild trauma

- ***Risk factors:*** premature menopause, heavy smoking, lack of exercise, low body weight, together with hereditary and genetic factors (white race).
- ***Diagnosis:***by X-ray bone densitometry (DEXA).
- ***Prevention of osteoporosis:***
  - Balanced diet with rich calcium intake of 1500 mg daily.
  - Vitamin D 600-800 IU/day.
  - Healthy life style; including weight bearing exercises, stop smoking, and avoid long term corticosteroid therapy.
- ***Treatment of Osteoporosis:***

A) Drugs that slow bone breakdown during bone remodeling

- *Biphosphonates:* orally once per week, decrease non vertebral fractures.
- *Calcitonin:* nasal spray increase the vertebral bone mass and reduce fractures risk.

B) Drugs that have anabolic effect that stimulate bone remodeling

- *Teriparatide:* IM injections over a period up to 18-24 months. It decreases vertebral and non vertebral fractures.

C) Hormone Therapy (HT)

- *Hormone Therapy (HT):* although effective in prevention and management of osteoporosis, is rarely used as a primary therapy, except in cases which need HT for control of menopausal flushes, or in cases of premature menopause.
- *Selective Oestrogen Receptor Modulators (SERM)* e.g.; Raloxifene 60 mg/d; has a combined oestrogen effect on bone and anti-oestrogen effect on the breasts and uterus. It is approved for prevention of osteoporosis but may induce hot flashes.
- *Phyto-oestrogens:* plant substitutes that have a weak oestrogen action

HORMONE THERAPY IN MENOPAUSE

Types of Hormones used

A) ***Oestrogen + Progestin therapy (Combined HT)***: where a progestin is added to avoid oestrogen induced endometrial hyperplasia (EH) and possible endometrial carcinoma.

B) ***Oestrogen only therapy (ET):*** suitable for women who have undergone hysterectomy (no risk for oestrogen induced endometrial hyperplasia or carcinoma).

Benefits of Oestrogen in the Menopause

1. It reduces menopausal symptoms as; hot flashes, sleepiness, and mood disorders
2. Treats vaginal dryness and atrophy which may cause dyspareunia and senile vaginitis
3. Prevents or reduces the risk of osteoporosis during the period of therapy

Risks of Hormone Therapy

- Small but significant increase for CVS disease, stroke, and venous thromboembolism
- Small but significant increase in the risk of breast cancer
- Endometrial cancer risk: with prolonged oestrogen only therapy (> 5 years).

Indications of HT in menopause

- Menopausal symptoms affecting the patient's life style and psychological condition
- Premature menopause (idiopathic or surgically induced), till age of natural menopause.
- Prevention of osteoporosis in high risk cases. The effect is limited to the period of HT.

Contraindication to the use of HT

a. Undiagnosed abnormal bleeding from the genital tract
b. Known or suspected breast cancer, or oestrogen dependent neoplasia
c. History of DVT, stroke, or thromboembolic disease
d. Active liver disease

Commonly used schedules for HT

- **Continuous Combined E/PRG therapy:** daily oral tablets throughout duration of therapy (1-2 years). No withdrawal bleeding expected.
- **Cyclic Combined E/PRG therapy:** daily oral oestrogen tablets for 3 weeks, PRG added last12 days. Treatment stopped for one week in which withdrawal bleeding is expected.
- **Oestrogen only therapy (ET):** daily oral doses, sub-dermal implants, or transdermal patches are used for patients with absent uterus (after hysterectomy).
- Oestrogen vaginal cream preparations: for local application in cases of vaginal atrophy

Types of Hormones used

- *Natural oestrogens* are preferred over synthetic ones e.g.; conjugated equine oestrogen 0.625 mg/day or oestradiol valerate 1-2 mg/day.
- *Synthetic Gestagens* are preferred being more effective in smaller doses. Side effects include mastalgia, mood changes, PMS like symptoms, weight gain, etc...

Key Points

- *Menopause is the permanent cessation of menstruation that affects all women at ages ranging 45-55 years, due to exhaustion or depletion of ovarian follicles.*
- *Perimenopause describes the few years prior to menopause in which some of the features and symptoms of menopause start to be clinically evident*
- *Premature menopause describes cessation of menses < 40 years of age*
- *Symptoms and clinical features characteristic of menopause are all related to lack of ovarian E2 production, and its effect on various body systems*
- *Changes in body systems due to menopause may affect the vagina, cervix, uterus, endometrium, ovaries, skin, breasts, psychiatric & CNS, and skeletal systems.*
- *Symptoms of menopause include: cessation of menstruation, hot flushes, insomnia, irritability, weight gain, mood swings, depression, anxiety, vaginal dryness, dyspareunia, loss of libido, and susceptibility to skeletal fractures, and tendency to POP.*
- *Remote health hazards related to menopause include: CVS changes and osteoporosis*
- *Diagnosis of menopause is based on; history, symptoms, and hormonal assays revealing elevated FSH & LH levels together with decreased E2.*
- *Management of menopause includes; reassurance, education, changes of life style, prophylaxis and management of CVS problems and osteoporosis.*
- *HT in menopause is reserved to selected cases, and is mainly directed towards treatment of acute symptoms of menopause, and prophylaxis against osteoporosis.*
- *HT should be carefully monitored, to guard against long term complications of its use.*

07 AMENORRHOEA

- *Physiologic amenorrhoea*
- *Pathologic Amenorrhoea*
- *Clinical assessment*
- *Guidelines in management*
- *Hyperprolactinaemia*

DEFINITION

The term **amenorrhoea** describes absence or cessation of menstruation, it may be either;

A. Primary Amenorrhoea: Menstruation has never occurred before

B. Secondary Amenorrhoea: Cessation of menstruation after a period of regular cyclic bleeding

- N.B.: primary amenorrhoea should be **investigated** in all females if:
- Menses delayed **>14** years of age in absence of developed 2ry sexual characters
- Menses delayed **>16** years weather 2ry sexual characters has started development or not

CAUSES OF AMENORRHOEA

A. PHYSIOLOGIC AMENORRHOEA

1. ***Before puberty:*** due to absence of pituitary FSH / LH stimulation
2. ***After menopause:*** due to exhaustion and depletion of oocytes in the ovaries
3. ***During pregnancy:*** due to continuous production of oestrogen and progesterone
4. ***During lactation:*** high prolactin levels interfere with LH surge and cause anovulation

B. PATHOLOGIC AMENORRHOEA

1. ***Outflow Tract Disorders:*** imperforate hymen, transverse vaginal septum, and cervical atresia
2. ***Uterine Disorders:*** as Mullerian agenesis, androgen insensitivity, and Asherman's syndrome
3. ***Ovarian Disorders:*** as Turner's syndrome, premature ovarian failure, and PCOS
4. ***Pituitary Gland Disorders:*** pituitary adenomas, empty sella syndrome, pituitary insufficiency
5. ***Hypothalamic and CNS Disorders:*** as GnRH deficiency, psychiatric disorders, rapid weight loss, excessive exercise, drug induces, hypothalamic tumours and infiltrative disease
6. ***Endocrine Disorders:*** as hypothyroidism, hyperthyroidism and Cushing's syndrome

COMMON CAUSES OF PRIMARY AND SECONDARY AMENORRHOEA

PRIMARY AMENORRHOEA	SECONDARY AMENORRHOEA
– Imperforate hymen – Transverse vaginal septum – Turner syndrome (45 XO) – Mullerian agenesis (46 XX) – Androgen insensitivity (46 XY) – Congenital GnRH deficiency – Kallman's syndrome	– Polycystic ovary syndrome (PCOS) – Hyperprolactinaemia – Thyroid disorders – Drug induced (OCPs – GnRH agonists) – Rapid weight loss – Stressful exercise – Asherman syndrome – Premature ovarian failure (POF – POI)

I. OUTFLOW TRACT DISORDERS

These disorders describe cases with obstruction of the menstrual flow at the level of the; hymen, vagina, or cervix. Such cases present with **1ry Amenorrhoea** usually at a young age, with normal development of their 2ry sexual characters.

Because menstruation occurs but is not revealed this type of 1ry amenorrhoea is commonly known as false amenorrhoea or **cryptomenorrhoea**.

A) IMPERFORATE HYMEN:

Imperforate hymen is a congenital anomaly in which the hymeneal orifice is absent. The condition may affect up to 0.1% of the newly born females, and is the commonest cause for cryptomenorrhoea.

- ***Pathogenesis:*** at puberty, menstruation will start, but blood will accumulate behind the imperforate hymen leading to;
  - *Haematocolpos;* blood entrapped and accumulating inside the vagina
  - *Haematometra;* in long standing cases blood will extend to the uterine cavity
  - *Haematosalpinx;* blood collecting in the fallopian tubes retrograde from the uterus
- ***Clinical Presentation:*** young girls with 1ry amenorrhoea and well developed 2ry sexual characters.
- ***Symptoms:*** lower abdominal pain synchronous with the timing of the menstrual period.
- ***Signs***:
  - *Inspection and palpation of the lower abdomen;* may reveal a suprapubic bulge only if the haematocolpos is large enough to extend upwards to the suprapubic region.
  - *Inspection of the vulva & vagina:* hymeneal orifices are absent, and if haematocolpos is large the hymen will bulge at the hymeneal ring with a slight bluish colour.
  - *PR Examination:* a sizable haematocolpos can be easily palpated by PR examination
- ***Special Investigation:*** pelvic ultrasound is the gold standard in diagnosis.
- ***Treatment:*** once diagnosed, surgical cruciate incision is performed dividing the imperforate hymen

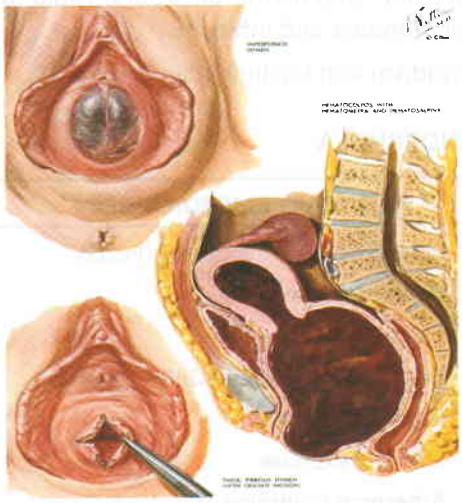

Fig 7-1: Imperforate hymen with haematocolpos and haematometra

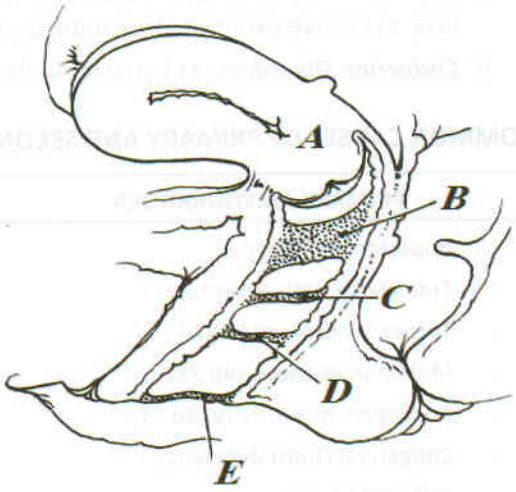

Fig 7-2: Transverse vaginal septum site from above downwards

B. TRANSVERES VAGINAL SEPTUM

One or more transverse vaginal septae may be **congenitally present** at any level between the hymeneal ring and the cervix leading to occlusion of the lower, middle, or upper segment of the vagina. The condition is rare, but is the 2nd most common cause for **cryptomenorrhoea.**

- ***Clinical Presentation:*** cryptomenorrhoea as seen with imperforate hymen (see above)
- ***Diagnosis:*** haematocolpos diagnosed by US, while hymen, if present, is apparently normal
- ***Treatment:*** surgical excision of the transverse septum.

C. CERVICAL ATTRESIA

Congenital cervical atresia is a very rare condition, in which there is failure of canalization of the cervical canal as a part of Mullerian dysgenesis.

- ***Clinical Presentation:*** picture of cryptomenorrhoea as seen with imperforate hymen (see above)
- ***Diagnosis:*** Pelvic US reveals marked haematometra, absent cervix, and no haematocolpos.
- ***Treatment***: is difficult and controversial. Cervical reconstruction and canalization is attempted, but with poor results, and if fails hysterectomy may be the only option.

II. UTERINE ABNORMALITIES AND DISORDERS

Uterine causes of amenorrhoea are not uncommon, they include

- Complete or Partial Mullerian Agenesis (congenital)
- Complete Androgen Insensitivity Syndrome CAIS (congenital)
- Asherman Syndrome (acquired)

A) MULLERIAN AGENESIS (COMPLETE or PARTIAL)

(Mayer Rokitansky Kauster Hausser Syndrome):

These are **females** (**46 XX** karyotype) with congenital genetic defect that resulted in failure of development of the Mullerian structures (the uterus, cervix, and upper vagina).

- *Aetiology:* possibly due to an unwanted intrauterine exposure to anti-mullerian hormone (AMH), with failed development of the Mullerian ducts.
- *Incidence:* Mullerian agenesis may occur in 1:4000 female births and accounts for almost 20% of cases with 1ry amenorrhoea (2nd common after Turner syndrome)
- *Clinical Presentation:* 1ry amenorrhoea with normal 2ry sexual characteristics. Such cases have normal ovaries, as the gonads develop from the genital ridge, and are capable of producing normal amounts of E2 due to an intact hypothalamic-pituitary-ovarian axis.
- *PV Examination (if not virgin):* reveals a blind ended short vagina, with absent cervix and uterus.
- *Pelvic US:* reveals absent uterus, and upper vagina, with normal ovaries.
- *Karyotyping:* a blood sample for genetic study reveals a 46 XX chromosomal pattern
- *Management:* a short vagina can be managed surgically by lengthening the vaginal canal through vaginoplasty as with McIndoe procedure

▪ **N.B.:** Associated urinary tract and skeletal anomalies are common associations

B. COMPLETE ANDRPGEN INSENSITIVITY SYNDROME (CAIS)

(Testicular feminization Syndrome):

These are **male** subjects (**46 XY** karyotype) with an X-linked inherited recessive disorder that render them androgen resistant due to a defect in peripheral androgen receptors.

These male subjects fail to develop testosterone dependent male sexual characteristics, inspite of normal male testosterone levels. They therefore develop phenotypically as females. *They present by* 1ry amenorrhea, female external genitalia, and a blind ended vagina.

- *Incidence:* rare, but is 3rd common cause of 1ry amenorrhoea after Mullerian agenesis.
- *Pathogenesis:* male gonadal tissue may be present in the labia or inguinal canal, but incapable of spermatogenesis. The presence of a Y chromosome, and Mullerian inhibiting factor (MIF) leads to failure of Mullerian system development (uterus, cervix and upper 1/3 vagina).
- *Management:*
  - Gonadectomy must be performed in such patients as they carry a 20% risk of gonadoblastoma, however treatment is usually deferred until after puberty.
  - Creation of a neo-vagina surgically via McIndoe procedure if the patient rquires, as such cases are reared as females.

- **N.B.:** Hormone therapy in the form of oestrogen preparation will help keeping the external female appearance, and prevent accelerated bone loss (osteoporosis)

C. ASHERMAN'S SYNDROME (Intrauterine Synaechae)

Asherman's syndrome describes acquired intrauterine adhesions which prevent endometrial proliferation, leading to 2ry amenorrhoea.

- *Aetiology:* Endometritis (post abortive, puerperal, IUD induced, or T.B), or iatrogenic via vigorous curettage during D&C procedures especially with surgical evacuation.
- *Clinical presentation:* 2ry amenorrhoea following endometritis or curettage
- *Diagnosis:* both HSG and hysteroscopy are excellent diagnostic tools.
- *Treatment:* Lysis of adhesions best under vision via hysteroscopy, or through D&C like procedure. This is followed by cyclic combined EST/PRG therapy for at least 3 cycles to restore endometrial regeneration.

III. OVARIAN DISORDERS

A) TURNER SYNDROME: (Gonadal Dysgenesis)

In Turner syndrome a chromosomal defect occurs in which an X chromosome will be missing (45-XO) and the ovaries will be replaced by fibrous tissue (streak gonads).

- ***Incidence:*** It is the **commonest cause of 1ry amenorrhoea**, being responsible for **30%** of cases
- ***Clinical presentation:*** 1ry amenorrhoea with pheno-typic characteristics including; low hair line, short stature, webbing of the neck, increased carrying angle at the elbow, Cardiac anomalies as; coarcitation of the aorta.

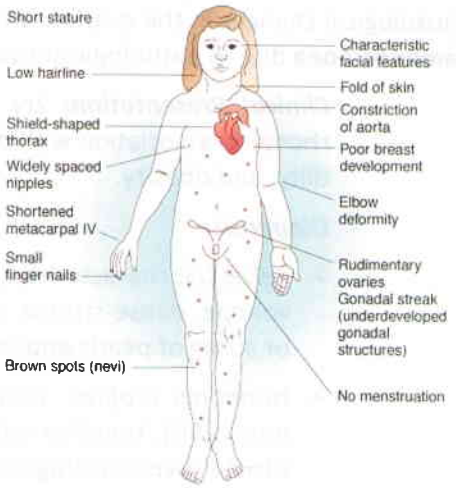

Fig 7-3: Features of Turner syndrome

- ***Pathogenesis:*** Absence of the Y chromosome will allow for normal development of Mullerian elements (the vagina, uterus, and fallopian tubes), however at puberty the streak gonads fail to produce enough E2, inspite of elevated FSH and LH levels, leading to 1ry amenorrhoea.
- ***Treatment:*** HRT, in the form of cyclic combines EST/PRG will induce regular cycles, and preserve the 2ry sexual characters, and act as prophylaxis from bone osteoporosis.

▪ **N.B.:** In some cases with a mosaic karyotype (45X0/46XX), spontaneous menstruation and in some cases pregnancy might occur (2%-5% of cases), but most cases will develop premature ovarian failure (POF) and premature menopause.

B) PREMATURE OVARIAN FAILURE OR INSUFFICIENCY (POF or POI)

Premature ovarian failure occurs due to early exhaustion of ovarian primordial follicles before the age of 40 years leading to premature menopause.

- *Aetiology:*
  - ➢ Idiopathic; associated with autoimmune ovarian destruction
  - ➢ Karyotype abnormalities; as loss of a small portion of the X chromosome
  - ➢ Viral infections; as mumps
  - ➢ Induced; by radiation therapy, chemotherapy, or surgical removal
- *Clinical Presentation:* Premature menopause (2ry amenorrhoea with high FSH & LH levels)
- *Treatment:* cases of POF should be offered HRT (combined EST/PRG) to avoid hazards and complications of premature menopause (see chapter 6)
  - ➢ **Resistant Ovary Syndrome:** 2ry amenorrhea with high FSH and LH levels may occur when viable ovarian follicles fail to respond to pituitary gonadotropins due to a defect in their FSH/LH receptors. In few cases the condition is temporary and some may ovulate and conceive.

C) POLYCYCTIC OVARY SYNDROME (PCOS)

PCOS describes a syndrome characterized by chronic anovulation, and hyperandrogenism, in association with morphologic and histological changes in the ovaries. It is the **commonest cause** for **2ry amenorrhoea** due to pathologic anovulation.



Fig 7.4 US picture of PCO

- ***Clinical Presentation:*** 2ry amenorrhoea or oligomenorrhoea, in association with one or more of hirsutism, infertility, and obesity.
- ***Diagnosis:***
  - *Pelvic US:* characteristic picture with increased size and volume, dense stroma, and peripherally arranged equal size small follicles (necklace or string of pearls appearance).
  - *Hormonal profiles:* show abnormally reversed FSH/LH ratio (elevated LH level > 2 times FSH), together with elevated total and free Testosterone levels, and increased DHEAS (hyperandrogenism).
  - N.B.: Some cases show increased insulin resistance and hyperinsulinaemia.
- ***Treatment:*** according to the patient's complaint, (see details in chapter 8 PCOS)

IV. ANTERIOR PITUITARY GLAND DISORDERS

A. PITUITARY ADENOMAS: (see hyperprolactinaemia)

Hyperprolactinaemia, by itself, is responsible for up to 20% of cases of **2ry amenorrhoea.** It acts via its effect on suppression of GnRH and LH surge inducing a state of chronic oligo-ovulation, anovulation, and finally 2ry amenorrhoea.

Prolactinomas are the commonest cause for hyperprolactinaemia, and the most common pituitary cause for 2ry amenorrhoea. They are classified histologically as either;

- *Microadenomas (< 10 mm in size):* these are the commonest, and are usually associated with moderate elevations in serum PRL levels.
- *Macroadenomas (>10mm in size):* are relatively rare, and are associated with high serum PRL levels and possible signs of increased intracranial tension (ICT).

- ***Diagnosis and Treatment:*** (see hyperprolactinaemia)

B. EMPTY SELLA SYNDROME:

The condition refers to enlarged sella turcica that is not entirely filled with pituitary tissue.

- *Pathogenesis:* It occurs mostly due to a defect in the diaphragm sella that allows cerebrospinalfluid (CSF) pressure to enlarge the sella.
- *Clinical Presentation:* 2ry amenorrhoea or oligohypomenorrhoea with hyperprolactinaemia
- *Diagnosis:* MRI or CT scan is the mainstay in its diagnosis.

C. PITUITARY INSUFFICIENCY

Pituitary insufficiency will result in diminished FSH and LH secretion, leading to a state of chronic anovulation with hypogonadotrophic amenorrhoea. Causes are rare but include;

- Sheehan's Syndrome: (anterior pituitary necrosis following severe postpartum haemorrhage)
- Simmond's Disease.
- Radiation necrosis, pituitary infarctions, and non-lactotrophic adenoma
- Infiltrative lesions of the pituitary gland, such as lymphocytic hypophysitis.
- *Management:* according to the cause, but generally HRT with combined EST/PRG is suitable. Induction of ovulation can be attempted using FSH/hCG preparations, but clomiphene citrate is contraindicted due to inability of the pituitary to produce FSH and LH.

V. HYPOTHALAMIC AND CNS DISORDERS

Hypothalamic and CNS disorders may cause amenorrhoea due to decreased GnRH pulse frequency with it consequences of Low FSH & LH production, absent LH surge, low E2 levels, and chronic anovulation (hypogonadotrophic amenorrhoea). Common causes include;

A. CONGENITAL GnRH DEFICIENCY:

Congenital GnRH deficiency is a rare condition that presents with 1ry amenorrhoea in association with infantile sexual development (hypogonadotrophic hypogonadism).

- Kallmann's syndrome describes congenital GnRH deficiency in association with anosmia due to congenital failure of neuronal migration of olfactory placode in the nose.
- *Treatment:* HRT with combined EST/PRG therapy is essential to help preservation of 2ry sexual characters, uterine size, and attempt to induce uterine withdrawal bleeding. In cases with normal size uterus and responsive endometrium, induction of ovulation may be attempted using FSH/LH/hCG protocols.

B. PSYCHIATRIC DISORDERS:

1. ***Emotionally stressful events:*** as family problems, work, study, travel, death or severe illness may cause 2ry amenorrhoea in some women.
2. ***Pseudocyesis:*** (false pregnancy): is a rare condition that may occur in emotional women extremely desirous of pregnancy. The etiology is unknown but appears to be a voluntary alteration of hypothalamic function. Prolactin levels may be elevated enough to cause galactorrhoea.
3. ***Anorexia nervosa:*** may affect 1% of young women. Bulimia (induced vomiting) may be present in 50% of cases

C. RAPID WEIGHT LOSS AND EXCESSIVE EXERCISE:

1. ***Rapid and Excessive weight loss:*** a minimum of 20% of body fat by weight is required for initiation of menarche and maintenance of menses. Rapid weight loss (below 20% of ideal body weight) may cause 2ry amenorrhoea
2. ***Excessive stressful Exercise:*** is usually associated with increased circulating endorphins and may cause 2ry amenorrhoea in female athletes as marathon runners, ballet dancers, etc..., especially those with markedly decreased body fat.

D. DRUG-INDUCED AMENORRHEA:

1. ***GnRH Agonists;*** the use of long acting GnRH agonists will induce initial stimulation of GnRH for a short period, followed by a longer suppression of FSH & LH due to a down regulation receptor effect. A state of 2ry amenorrhoea is induced, which is useful in treatment of cases with severe endometriosis, some cases of severe AUB, and to reduce the size of large uterine myomas prior to surgery if necessary.
2. ***Progestins;*** continuous synthetic progesterone therapy will prevent endometrial shedding, and inhibit GnRH pulses, leading to delay in the cycle and 2ryamenorrhoea. Normal menses is resumed after stopping therapy.
3. ***Combined EST/PRG therapy:*** continuous therapy will also prevent endometrial shedding and inhibit GnRH pulses as long as therapy continues. **Post pill amenorrhoea** may occur in 1% of women after long use of combined OCPs, due to chronically decreased gonadotropin levels. The condition is self limiting, and normal menses is usually spontaneously resumed in 2-6 months.
4. **Androgenic drugs** as Danazol (formerly used in treatment of endometriosis) induces atrophic endometrial changes by its androgenic and progestational effects.
5. ***Anti-psychoticsandtri-cyclicanti-depressants***(stimulateprolactinsecretion)

E. HYPOTHALAMIC TUMOURS AND INFILTRATIVE LESIONS (rare):

- *Craniopharyngioma:* is associated with visual field defects, and calcification on X-ray
- *Lymphoma, Langerhans cell histiocytosis, and sarcoidosis:* can result in decreased GnRH secretion, low or normal serum FSH and LH, and amenorrhoea.

▪ **N.B.:** Most women will have **2ry amenorrhoea** with one or more neurologic symptoms as severe headaches, change in personality or marked mood changes.

VI. ENDOCRINE DISORDERS

Some endocrine disorders may be severe enough to cause hypothalamic pituitary ovarian disturbances, leading to transient 2ry amenorrhoea, which is managed by correcting the endocrine disorder

1. ***Hypothyroidism:*** TRH is usually elevated which results in an elevated serum PRL levels.
2. ***Cushing's Syndrome:*** increased adrenal activity leads to a hyperandrogenic state.

CLINICAL ASSESSMENT IN A CASE OF AMENORRHOEA

- Proper **history** taking to differentiate between **1ry** and **2ry** amenorrhoea.
- Exclusion of **physiologic** amenorrhoea (pregnancy, lactation, and menopause)
- **General** examination including development of **2ry sexual characters**
- **Local** examination including inspection of the vulva, PV and Bimanual examination if possible
- **Pelvic US;** for evaluation of the proper development of the uterus and the ovaries
- **Hormonal assays** including pituitary hormones (FSH, LH, and PRL), Ovarian hormones (E2 and PRG), ovarian androgens (Total and free Testosterone), Thyroid hormones (TSH, T3 & T4), adrenal androgens (DHEAS).
- **Genetic studies** and karyotyping may be required to confirm diagnosis in some cases.

A. PRIMARY AMENORRHOEA with Non-Developed 2ry Sexual Characters

- Exclude **delayed puberty**: history, clinical examination, FSH, LH, & E2 assays.
- Exclude **Turner** syndrome (Gonadal Dysgenesis) via:
  - Physical features suggestive of Turner syndrome (see before)
  - Pelvic US for presence of a small uterus and streak gonads
  - Elevated FSH & LH levels (Hypergonadotropic hypogonadism)
  - Echocardiography for associated cardiac anomalies
  - karyotyping (45 XO abnormality) to confirm diagnosis and exclude mosaic Turner cases

B. PRIMARY AMENORRHOEA with Well-developed 2ry Sexual Characters

- Exclude **Cryptomenorrhoea** due to imperforate hymen or transverse vaginal septum via;
  - Local examination including PR examination
  - Pelvic US revealing haematocolpos and haematometra

Differentiation between Mullerian Agenesis and Androgen Insensitivity syndromes

	Mullerian Agenesis Mayer Rokitansky Syndrome (MRS)	Complete Androgen Insensitivity Syndrome (CAIS)
– Karyotype	– XX	– XY
– Gonads	– Ovaries	– Testicles (inguinal)
– Uterus	– Absent	– Absent
– Vagina	– Short vaginal pouch	– Absent or small dimple
– Axillary/pubic hair	– Present	– Absent/sparse
– Associated anomalies	– Renal, skeletal, and deafness	– Absent
– Reproduction	– Possible oocyte retrieval	– Not possible
– Surgical interventions	– Vaginoplasty only if short pouch	– Vaginoplasty & Gonadectomy
– EST HRT	– Not required	– Required for appearance and osteoporosis

CASES OF SECONDARY AMENORRHOEA

- **History and Symptoms:**
  - Cessation of menstruation after a period of regular menstrual cycles **(2ry amenorrhoea)**
  - Menopausal symptoms and hot flashes in **POI & POF**
  - Headaches and visual field limitation in pituitary **adenomas** and brain tumours
  - Galactorrhoea in cases of **Hyperprloactinaemia** and pituitary hyperplasia
  - Psychiatric disorders and antidepressant drugs
  - Hormonal treatment of endometriosis; as OCPs, gestagens, Visanne, & GnRH agonists
  - Drug addiction and drug abuse; as with opioids
  - History of post abortive **sepsis** or endometritis following repeated curettage (Asherman syndrome)
- **General Examination**: Obesity, hirsutism and signs of hyperandrogenism in cases with **PCOS**
- **Breast Examination:** Galactorrhoea in cases with **Hyperprloactinaemia**
- **Hormonal Assays:**
  - Elevated Serum FSH & LH: in cases with **POI or POF**
  - Abnormal FSH/LH ratio in PCOS
  - Elevated serum PRL in Hyperprloactinaemia and Galactorrhoea
  - Elevated serum androgens and DHEAS in some cases with PCOS
  - Elevated E2 and/or testosterone levels in cases of suspected functioning ovarian tumours
  - Thyroid function tests for severe hypothyroid and hyperthyroid disorders
- **Pelvic US:**
  - Increased ovarian volume and characteristic necklace appearance for **PCOS**
  - Small uterus with **atrophic** endometrium and ovaries in **POI and POF**
  - Ovarian **swelling** in cases of functioning ovarian tumours (granulosa theca and Sertoli-Leydig)
- **CT and MRI:**
  - For diagnosing prolactinomas, empty-sella syndrome and craniopharyngioma
- **Exclude Asherman's syndrome:** TVS, saline infusion sonography, hysterography, and hysteroscopy
- **Exclude psychiatric disorders:** as anorexia nervosa, and severe depression

GUIDELINES IN THE MANAGEMENT OF A CASE OF AMENORRHOEA

The goal for treatment in amenorrhoea is to restore regular menstrual cycles, preserve fertility, and maintain development of 2ry sexual characters, and allow for satisfactory sexual life in married women.

1. **Treatment of the Underlying Cause of Amenorrhoea:** examples include
   - ***Induction of ovulation*** in cases with PCOS and chronic anovulation (Clomiphene and HMG)
   - ***Treatment of hyperprolactinaemia*** (Brompcryptine and Cabergoline)
   - ***Hormone replacement therapy (HRT)*** in POF (oestrogen or combined oestrogen/progesterone)
   - ***Treatment of severe thyroid disorders*** (Euthyrox or Thiouracil)

2. Surgical treatment in Amenorrhoea:

- ***Relief of outflow tract obstruction:*** hymenotomy or excision of a transverse vaginal septum
- ***Reconstruction of a neo-vagina:*** in cases of vaginal agenesis to allow for sexual intercourse
- ***Gonadectomy:*** in patients with a **Y** containing gonad, gonadectomy is performed once diagnosis is genetically confirmed to avoid the risk of malignant transformation into gonadoblastoma. However in cases with androgen insensitivity syndrome (testicular feminization) gonadectomy can be postponed till puberty is complete to allow for normal bone growth. Such cases will require long term HRT to improve 2ry sexual development and avoid excessive bone loss and asteoporosis.
- ***Trans-sphenoid resection or gamma knife:*** in some cases with pituitary macroadenoma and craniopharyngioma
- ***Laparoscopic Ovarian Drilling (LOD):*** in some cases of PCOS resistant to medical induction of ovulation or susceptible to severe forms of ovarian hyperstimulation (OHSS) when treated medically.

HYPERPROLACTINAEMIA AND GALACTORRHOEA

Prolactin is a polypeptide hormone secreted by the lactotrophic cells of the anterior pituitary gland. Its secretion is controlled by hypothalamic Prolactin inhibiting factor **(PIF)** known as **dopamine**. It is the hormone responsible for initiation and maintenance of lactation in females.

Hyperprolactinaemia; elevated serum Prolactin levels (N: 2.9-29 ng/ml.)

Galactorrhoea; refers to the continuous extrusion of milk from the nipples in the absence of recent pregnancy or lactation. It is almost always secondary to hyperprolactinaemia.

AETIOLOGY

1. ***Physiologic causes:*** During pregnancy and lactation.
2. ***Drug induced:*** Phenothiazine derivatives, Reserpine, psychotropic drugs, Metclorpramide, and oestrogens. These drugs act by reduction in hypothalamic secretion of dopamine (PIF).
3. ***Primary hypothyroidism:*** due to persistently elevated TRH levels.
4. ***Prolactin secreting pituitary adenomas*** (Prolactinomas);
   - Microadenomas (tumours < 10 mm) are a common cause for hyperprolactinaemia.
   - Macroadenomas (tumours > 10 mm) are rare; may be associated with symptoms and signs of increased intracranial tension (headache, vomiting, and diminution in the field of vision).
5. ***Hypothalamic disorders:***
   - Severe stress and psychological conditions.
   - Hypothalamic tumours (craniopharyngioma); cause damage to hypothalamus, or compression on the pituitary stalk interfering with production of prolactin, or transport of dopamine.

CLINICAL PICTURE

Hyperprolactinaemia may clinically present by one or more of the following;

a. **Mastalgia** (breast pain and tenderness), with or without galactorrhoea
b. **Menstrual disorders** (irregular cycles, 2ry amenorrhoea); due to chronic anovulation
c. **Infertility:** due to anovulatory dysfunction (PRL interferes with GnRH pulses and with ovarian sensitivity to pituitary gonadotrophins).

DIAGNOSIS

1. **History:** of breast pain (mastalgia), and breast milky secretions (galactorrhoea), with or without menstrual disturbance and/or infertility.
2. **Clinical Examination:** gentle pressure on the nipples results in extrusion of milky secretion.
3. **Diagnostic Investigations:**
   - *Laboratory:* elevated serum PRL levels (N: 2.9-29 ng/ml).
     - N.B.: markedly elevated levels of PRL > 100 ng/ml suggest PRL secreting adenomas.
   - C.T scan and MRI: in cases of persistently high serum PRL levels, or in cases with signs of increased intracranial tension suggestive of brain tumours.

TREATMENT

a. **Stop medications** that may cause hyperprolactinaemia.
b. **Treat primary hypothyroidism** by thyroid hormone replacement therapy (e.g.; Eltroxin)
c. **Drugs used for treatment of hyperprolactinaemia** (dopamine agonists)
   - *Bromo-ergo-cryptine:* 2mg (1-2 tablets daily, until normal PRL levels restored).
   - *Lisuride hydrogen maleate:* 0.2mg (1-2 tablets daily, until normal PRL levels restored)
   - *Cabergoline:* 0.5 mg (1/2 tablet twice weekly for 4 weeks, until normal PRL levels restored).
d. **Treatment of pituitary adenoma:**
   - *Medical treatment:* using dopamine agonists; is the primary treatment for most cases.
   - *Trans-sphenoidal surgery, or Gamma Knife techniques:* are reserved to cases with failure of response to medical treatment, or Macroadenomas with CNS pressure symptoms.

Key Points in Amenorrhoea

1. *Primary amenorrhea may occur either due to outflow tract disorders, uterine developmental or acquired conditions, chromosomal abnormalities, Gonadal or Mullerian agenesis, central hypothalamic disorders, or endocrine disorders.*
2. *Physical examination for the development of 2ry sexual characters, integrity of external genitalia, presence of the uterus and gonads by US and hormonal assays are the key points for proper diagnosis, and management.*
3. *In absence of uterus and presence of breasts, karyotype will differentiate between Mullerian agenesis (46XX), and testicular feminization (46XY).*
4. *Secondary amenorrhoea is mostly due to anovulatory disorders namely PCOS, hypothalamic dysfunction, or hyperprolactinaemia, whenever pregnancy has been excluded. Ashermann and Sheehan syndromes are rare causes*
5. *Pituitary FSH and LH levels will differentiate between hypergonadotrophic and hy- pogonadotrophic amenorrhea, while prolactin levels will exclude hyperprolactinaemia.*
6. *Treatment of amenorrhoea is specific to the cause, and may include hormone replacement therapy, induction of ovulation, treatment of hyperprolactinaemia, correction of thyroid and adrenal disorders.*
7. *Surgical treatment includes correction of outflow tract disorders, creation of neovagina ,and Gonadectomy in cases with Y chromosome disorders.*
8. *Hyperprolactinaemia is a common cause of 2ry amenorrhoea treated medically by dopamine agonists in the vast majority of cases.*

08 HIRSUTISM

- *Hirsutism*

DEFINITIONS

- **Hirsutism;** Excessive growth of *androgen dependent sexual hair* (present on the upper lip, chin, inner thighs, limbs, chest, abdomen and pubic triangle).
- **Hypertrichosis;** Excessive growth of *androgen independent hair* (as in the forearm and legs)
- **Virilization;** is hirsutism associated with other signs of **hyperandrogenism** such as; increased muscle mass, cliteromegaly, temporal baldness, and voice deepening.

CLASSIFICATION

1. **Mild:** fine pigmented hair affecting the face, chest, abdomen and perineum.
2. **Moderate:** coarse pigmented hair affecting same areas as in mild cases.
3. **Severe:** coarse pigmented hair affecting the face (complete beard), tip of nose, ear lobes, chest, abdomen, and perineum.

AETIOLOGY

1. Idiopathic: increased hair follicles sensitivity to normal female androgen levels
- Increased receptor activity in the skin, or
- Increased activity of the enzyme 5 alpha reductase (responsible for conversion of T into DHT which has a more potent action than T).

2. Adrenal gland causes:
- Congenital adrenal hyperplasia (partial or complete 21 hydroxylase deficiency....).
- Adrenal tumours: secrete DHA, DHAS, and rarely Testosterone.

3. Ovarian causes:
- PCOS, hyperthecosis, and stromal cell hyperplasia (increased ovarian androgens).
- Androgenic ovarian tumors as sertoli lyedig cell tumor, adrenal rest tumor, hilar cell tumor, and gonadoblastoma. (increased testosterone production)

4. Mixed ovarian & adrenal hyperandrogenism: (30-40% of cases)
- Increase adrenal production of androgen leads to inhibition of follicular maturation & induction of premature atresia with increased production of ovarian androgen.

5. Pituitary gland:
- Cushing's syndrome due to increase production of ACTH.
- Acromegaly due to increased production of GH.

6. Androgenic drugs: Rarely, long term use of drugs with androgenic side effects (as Danazol in endometriosis) may cause hirsutism and virilizing effects.

INVESTIGATIONS OF A CASE OF HIRSUTISM

a. Hormonal assays

1. Plasma T level (n= 0.2-0.8 ng/ml), levels > 2 ng/ml suggest androgen secreting tumor.
2. Free T level (n= 1-3% of total T) it is a good index for androgenicity.
3. DHAS (n= 1500-2500 ng/ml), levels > 9000 ng/ml suggests adrenal tumour.

b. Radiological investigations:

- CT or MRI on the pituitary gland.
- IVP and abdominal US for adrenal tumor.
- Pelvic US, for PCOS, and virilizing ovarian tumours.

TREATMENT OF HIRSUTISM

A combination of hormonal suppression of hair growth and mechanical hair removal offers the most complete and effective treatment for patients with hirsutism. Once terminal hair has been established withdrawal of androgen does not affect the established hair pattern.

1. Elimination of specific causes

- Removal of androgen secreting ovarian or adrenal tumours
- Elimination of drugs suspected to contribute to the abnormal hair growth
- Treatment of Cushing syndrome, thyroid disease, or hyperprolactinaemia

2. Hair removal techniques

- Shaving, tweezing, waxing, and use of depilatories, performed at repeated intervals
- Bleaching is effective for mild hair growth
- Permanent destruction of hair follicles by electrolysis or by laser is reasonably effective.

3. Suppression of androgen synthesis

- Oral contraceptive pills (OCPs), containing combined low dose E and P, decrease ovarian androgen production, increases SHBG, and decrease free T levels. Progestins may also inhibit 5-alpha reductase activity.
- Corticosteroids (dexamethazone 1-5 mg/day); induce suppression of adrenal androgen production in severe cases of CAH. Long term side effects include osteoporosis, diabetes mellitus, and avascular necrosis of the hip.
- Spironolactone is an aldosterone antagonist used frequently as a diuretic that also inhibits 5alpha reductase and variably suppresses ovarian and adrenal synthesis of androgen.
- Cypretorone acetate is a potent progestin and antiandrogen that inhibits LH and decreases androgen levels. It is used for 10 days each cycle. **Diane 35** is an OCP that uses cypretorone acetate as a progestin and is widely used in treatment of hirsutism in females that request contraception.

4. Androgen receptor blockers

- Androgen receptor blockers inhibit binding of DHT to androgen receptors thus directly inhibiting hair growth. When combined with OCPs or progestins further benefit may be obtained.
- Cimetidine: competes with androgen at the receptor site. Dose: 300mg 5 times daily.

Key Points in Hirsutism

1. *Hirsutism is mostly idiopathic in the majority of cases.*
2. *It may be one of the androgenic manifestations of PCOS, or otherwise secondary to endocrine disorders in the pituitary, thyroid, or adrenal glands*
3. *Diagnosis is based on clinical examination for the site, density, and character of the hair*
4. *Laboratory investigations aim at measurement of testosterone and DHEA levels, together with exclusion of adrenal, thyroid, ovarian, or pituitary contribution.*
5. *Pelvic US, MRI, and CT are useful in excluding ovarian, adrenal & pituitary tumours.*
6. *Treatment of hirsutism includes; elimination of the cause, suppression of androgen synthesis, use of androgen receptor blockers, and mechanical removal by depilation.*

09 CHRONIC ANOVULATORY DISTURBANCES
PCOS AND LUTEAL PHASE DEFECT

- *Chronic anovulation*
- *Polycystic Ovary Syndrome (PCOS)*
- *Luteal phase defect (LPD)*
- *Ovarian Hyper-stimulation Syndrome (OHSS)*

ANOVULATION

Ovulatory menstrual cycles are characterized by being regular, rhythmic, occurring at predictable intervals due to the fixed span of its luteal phase (about 14 days from ovulation to onset of the next menses). **Anovulatory cycles** on the other hand are commonly prolonged, irregular, and unpredictable, due to the variations in the follicular phase duration in absence of regular follicular growth and maturation.

Anovulation, whether spontaneous or induced, sporadic or chronic, is the commonest cause for menstrual irregularities and secondary amenorrhoea in women, especially at the premenopausal and child bearing periods.

AETIOLOGY OF CHRONIC ANOVULATION

Anovulation is caused by **failure** or **disturbance of hypothalamic-pituitary-ovarian axis** it will therefore have the same aetiology as amenorrhoea excluding uterine and vaginal causes (see physiology of the menstrual cycle Ch 4 and amenorrhoea chapter 7).

WHO CLASSIFICATION OF OVULATORY DYSFUNCTION

- **GROUP 1: Hypothalamic / Pituitary Failure** (Hypogonadotropic Hypogonadism): as in Kallman syndrome, Sheehan's syndrome, pituitary tumours, stress or exercise induced amenorrhoea
- **GROUP 2: Hypothalamic / Pituitary Dysfunction** (Eugonadotropic Hypogonadism): as in Polycystic Ovary Syndrome (PCOS)
- **GROUP 3: End Organ Failure** (Hypergonadotropic Hypogonadism): as in Primary Ovarian Insufficiency (POI) formerly called primary ovarian failure (POF), and Turner syndrome

PATHOLOGICAL CAUSES OF OVULATORY DYSFUNCTION:

1. Hypothalamic Causes: *(decreased GnRH pulse frequency and amplitude)*

a. Functional disorders;

- Emotional stress in its severe forms, especially if associated with psychic disturbances
- Exercise; when excessive and under stress as with athletic training and competition
- Marked weight loss reaching to <20% of ideal body weight. *e.g.; anorexia nervosa*
- Severe psychological disturbances; including depression, and pseudocyesis

b. Organic lesions;

- Brain tumours, cystic malformations, and infiltrative brain disease
- Excessive scarring; after brain surgery, or irradiation.

c. Congenital disorders;

- Kallmann's syndrome; anosmic primary amenorrhoea with absent Gn-RH

2. Pituitary Causes: *(disturbed FSH & LH production)*

a. Pituitary adenomas:

- Prolactinomas (prolactin secreting adenomas); causing hyperprolactinaemia, are responsible for >90% of pituitary causes for anovulation. Microadenomas < 10 mm are far more common than macroadenomas >10 mm

b. Empty sella syndrome; causing hyperprolactinaemia (see amenorrhoea)

c. Pituitary insufficiency; as occurs in Sheehan syndrome or Simmond's disease (see amenorrhoea)

3. Ovarian Causes:

a. Polycystic ovary syndrome (PCOS); is one of the commonest causes for anovulation encountered especially in infertile females. Patients will present by 2ry oligomenorrhoea, with or without signs of hyperandrogenism. PCOS is characterized by an abnormal LH/FSH ratio > 2:1 (see later in PCOS).

b. Premature ovarian failure*, insensitive ovary syndrome, and gonadal dysgenesis;* due to absence or resistance of ovarian follicles to FSH stimulation. These conditions are characterized by high menopausal levels of FSH & LH with low serum E2 levels

c. Bilateral surgical removal, or destruction, of the ovaries by irradiation.

4. Endocrine Disorders:

- *Thyroid disorders;* as hypothyroidism
- *Adrenal disorders;* as Cushing's disease (adrenal hyperplasia)

5. Drug induced effect:

- *OCPs;* decrease FSH production, inhibit Gn-RH, and LH surge
- *Progestin therapy and androgenic drugs as Danazol* in endometriosis treatment.
- *Gn-RH agonists;* for suppression of FSH and LH as in treatment of endometriosis.
- *Drugs that induce hyperprolactinaemia;* e.g.; psychotropic agents, etc.
- *Antihypertensive drugs;* (reserpine and alpha methyl dopa), opiates and barbiturates.
- *Chemotherapeutic agents;* are some times followed by a transient period of anovulation

DIAGNOSIS OF CHRONIC ANOVULATION

CLINICAL PRESENTATION

1. Amenorrhoea or oligomenorrhoea (mostly 2ry, rarely 1ry amenorrhoea)
2. Infertility whether primary or secondary
3. Dysfunctional uterine bleeding (DUB), e.g.; metropathia heamorrhagica
4. Hirsutism which may rarely be associated with signs of virilization.

DIAGNOSIS OF ANOVULATION

A. **History:** suggestive of irregular cycles, with periods of 2ry amenorrhoea or oligomenorrhoea is strongly suggestive of anovulatory dysfunction, but not diagnostic.

B. **Symptoms:** Absence of symptoms suggestive of ovulation, as primary dysmenorrhoea, midcycle pain, or spotting, is only assumptive but not reliable in diagnosis of anovulation.

C. Test for detection of ovulation (see later).

TESTS FOR DETECTION OF OVULATION

1. Basal body temperature charts (BBT):

A daily record of the patient's oral temperature is taken in the morning just before rising from bed in two or three successive cycle. A temperature rise is expected to occur in the luteal phase of ovulatory cycles due to progesterone induced thermogenic effect. These charts although cheap and easily applicable, yet have the disadvantage of being easily biased by other factors that may cause any rise in BBT throughout the month.

- ***Ovulatory cycles*** show a **biphasic BBT** chart with a rise in temp (0.2–0.3 C) in the luteal phase of the cycle. This temperature rise declines few days before the next cycle.
- ***Anovulatory cycles*** will show a flat **monophasic BBT** chart due to absence of thermogenic progesterone thermal effect.

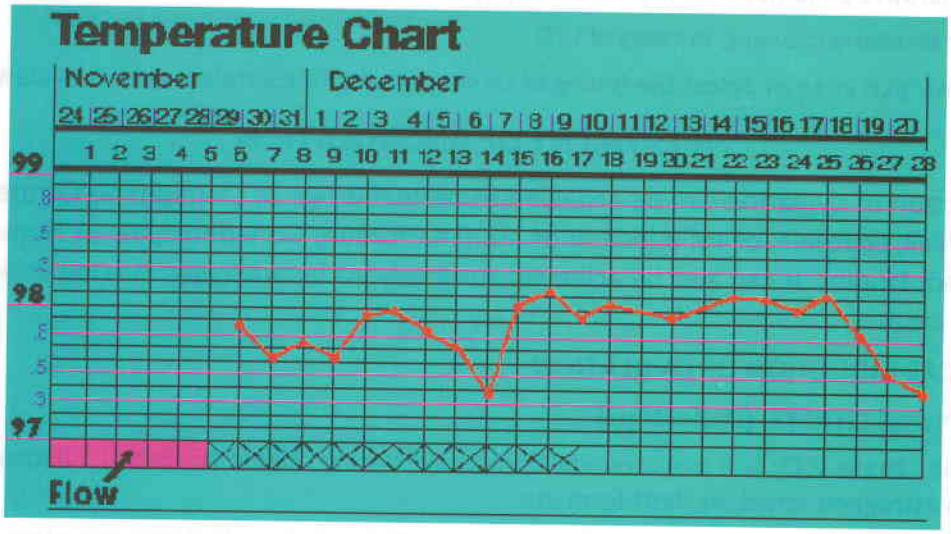

Fig. 8-1: Biphasic BBT

2. Ultrasound monitoring of ovulation (Folliculometry):

Serial TVS scans, in the follicular phase, allow monitoring growth, maturation, and ovulation (rupture of dominant follicles at a mean diameter of 18-24 mm), and tracing early CL formation.



Fig. 8-2: Preovulatory follicle by TVS

3. Mid luteal serum progesterone assay (MLSP): *measured by RIA;*

MLSP is performed 7 days after ovulation, or day 21 of the cycle (maximum CL activity).

- Levels <5 ng/ml suggest anovulation
- Values >10 ng/ml suggest ovulation with adequate CL function.
- Levels 5-9 ng/ml suggest ovulation but with inadequate CL function (LPD)

4. Premenstrual endometrial biopsy (PEB):

PEB can be performed without cervical dilatation as an office procedure, using a small caliper cannula (Pippele), or under general anaesthesia if cervical dilatation is mandatory (see D&C operation). PEB done 2-3 days prior to menstruation will reveal either;

- *Secretory endometrium,* in ovulatory cycles due to progestational effect of the CL.
- *Proliferative endometrium*, in anovulatory cycles.
- *Poor secretory changes,* in cases of LPD

- **N.B:** Urinary LH kits can detect the timing of LH surge that immediately precedes ovulation

TREATMENT OF ANOVULATION

Induction of ovulation can be achieved using oral drugs as Clomiphene Citrate, Tamoxifen, Cyclofenil, Letrozole, or IM injection of human Pituitary Gonadotropins or Human Chorionic Gonadotropins. It can also be achieved surgically via laparoscopic ovarian drilling (LOD) in special cases

A) MEDICAL INDUCTION OF OVULATION

1. CLOMIPHENE CITRATE: (Oral tablets)

Clomiphene Citrate (CC); is a non-steroidal compound closely related to diethyl stilbosterol (DES), but has no estrogenic effect on short term use.

- ***Mode of action:*** It competes with endogenous E2 for its hypothalamic receptors leading to their blockage. The hypothalamus reacts by increasing its pulsatile release of GnRH to combat this artificially induced hypo-oestrogenic state.
- Increased GnRH pulse frequency and amplitude increases pituitary FSH production, which directly stimulates follicular growth and maturation leading to production of increasing amounts of E2 levels.
- Markedly elevated E2 levels will exert a positive feedback on LH stimulating a strong LH surge (after CC has been stopped), finally leading to the release of one or more of the mature oocytes (ovulation).
- ***Dosage:*** 50 mg oral tablets, twice daily for 5 days starting day 3, 4 or 5 of menstruation. Dose can be increased up to 200 mg/day (4 tablets)
- ***Indications:*** CC is the first line of treatment in *anovulatory conditions with normal FSH production* and intact hypothalamic pituitary axis as in cases of PCOD, and post pill amenorrhea.
- ***Success rates:*** CC is successful in induction of ovulation in around 85% of cases.

- ***Side effects:***
  - Vasomotor flushes, nausea, headache, and visual disturbances
  - Increased risk of twin pregnancy (10%), and of multifetal pregnancy (1%).
  - Ovarian hyperstimulation (OHSS), grade I-II, with mild pelvic pain and discomfort
  - Anti-estrogenic effects on the endometrium may cause LPD, and on cervical mucous may cause hostile cervical mucous only repeated use.

- **Tamoxifen:** is a weak anti-oestrogen (used in treatment of oestrogen receptor positive breast cancers after mastectomy) that acts by a mechanism similar to CC.
  - Dosage: 10-40 mg daily orally (1-4 tablets) for 5 days starting from the 2nd day of cycle.
- **Cyclofenil:** It is a compound chemically related to CC with a weak oestrogenic effect.
  - Dosage: 400 mg twice daily, orally, for 5 days starting 5th day of the cycle.
- ***Letrozole:***
  - Letrozole is an aromatase inhibitor that blocks conversion of testosterone to oestrogen, leading to increased pituitary FSH, and stimulation of follicular growth. .

2. PITUITARY GONADOTROPINS (FSH & LH DERIVATIVES): (repeated I.M. injections)

A. **Human menopausal Gonadotrophins (HMG):** derived from urine of menopausal women. It contains **75** IU FSH + **75** IU LH.

B. **Purified Urinary FSH:** derived from urine of menopausal women and contains only one IU of LH (**75** IU FSH + **one** IU LH). They are more suitable for cases with high endogenous LH as those of PCOD, to minimize possibility of severe OHSS, and in IVF/ICSI protocols (see assisted reproduction in infertility).

C. **Synthetic FSH:** containing **no** LH is prepared by **recombinant DNA technology**, used mostly in IVF/ICSI protocols in same indications as purified urinary FSH.

- *Mode of action of gonadotrophins;* direct stimulation of growth and maturation of ovarian primordial follicles, with production of increasing amounts of E2.
- ***Indications:***
  - CC resistant cases
  - Cases with hypogonadotrophic anovulation (low FSH / LH levels)
  - In ICSI/IVF/ET protocols to stimulate growth of multiple follicles.
  - Purified and synthetic FSH are suitable both for cases with high endogenous LH (as PCOS), and in ICSI protocols to help retrieval of largest number of oocytes.
- ***Dosage:*** repeated I.M. Injections given from mid-follicular phase of the cycle until complete follicular maturation. Doses are repeated with TVS monitoring of follicular growth to avoid the complications of severe OHSS (see later).
- ***Side effects:*** **Same as those with CC however;**
  - **OHSS is more frequent especially** severe forms (grade III-IV OHSS).
  - Marked increased risk of twin and multifetal pregnancy (10-30%)
  - No adverse effects on cervical mucous or endometrium

3. HUMAN CHORIONIC GONADOTROPINS (hCG): (single I.M. injection)

- ***Preparation and action:*** hCG is prepared from urine of pregnant women. It has a strong LH action that induces an artificial LH surge leading to ovulation & oocyte release
- ***Indication:*** to assist ovulation especially in CC or HMG induced cycles.
- ***Dosage and timing:*** 2 ampoules 5000 m/IU each, given by I.M. injection as one shot after full oocyte maturation (size of dominant follicle > 18 mm by TVS).
- ***Side effects:*** OHSS, especially if given after HMG (see later)

4. GONADOTROPIN RELEASING HORMONE (GN RH) ANALOGUES:

- ***Preparation:*** **GnRH agonists** are synthetic decapeptide forms of GnRH, given either by repeated S.C. injection or as a nasal spray.
- *Dosage* ***& Mode of action:*** In small repeated doses they act as GnRH thus increasing FSH production, and inducing follicular maturation. In larger doses (long acting preparations), they induce initial FSH stimulation, followed by down regulation of hypothalamic receptors, with consequent suppression of FSH & LH production.
- ***Indications:*** They are used mostly in IVF & ICSI protocols to prevent premature ovulation via LH suppression, allowing for timed retrieval of maximum number of eggs.

5. COMBINED THERAPY

- **CC/HMG/hCG: A**dding CC to HMG/hCG has the benefit of minimizing the dose of HMG thus reducing both the cost and chanced for OHSS.
- **GnRH/HMG/hCG** is used in practice in various doses and different protocols of stimulation especially in IVF/ICSI stimulations protocols.

6. ADJUVANT DRUGS USED TO ASSIST IN INDUCTION OF OVULATION:

A. **Bromocryptine:** 0.2 mg 1-2 tablets daily, or **Cabergoline:** 0.5 mg 1/2 tablet twice weekly in cases of hyperprolactinaemia (see amenorrhea)

B. **Metformin:** 500-800 mg daily in cases with insulin resistance (see PCOS)

C. **Thyroid extract:** Eltroxin 50-150 ug daily in cases of hypothyroidism

D. **Corticosteroids:** in cases of Addison's disease, adrenogenital syndrome, and PCOS

B) SURGICAL PRODECURES USED FOR INDUCTION OF OVULATION

- *Laparoscopic Ovarian drilling (LOD):* LOD is a procedure in which a diathermy needle is used to make multiple small punctures in the surface of the ovary via laparoscopy.
  - *Effect of drilling:* LOD may decrease ovarian androgen environment resulting in spontaneous ovulation, or at least minimize doses of CC/HMG required for stimulation.
  - *Indications:* LOD is reserved to selected PCOS cases that are resistant to stimulation or may require large doses of HMG with high costs and increased risk of OHSS.
  - *Disadvantages:* The use of LOD is hindered by its time limited effect on ovulation (3-6 months), and its potential for creating ovarian and peritubal adhesions.

POLYCYSTIC OVARY SYNDROME (PCOS)

- In 1935 Stein and Leventhal described a group of patient showing **cystic changes in their ovaries** in association with **amenorrhea, hirsutism, obesity,** and **infertility.**
- **PCOS** is the more recent description of the syndrome which is characterized by **2** or more of:
  - **Chronic anovulation**; presenting clinically by 2ry amenorrhoea or oligomenorrhoea
  - **Hyperandrogenism**; (hirsutism, elevated serum LH, and increased free Testosterone levels)
  - **Characteristic ultrasound morphology**; increased ovarian size and volume, with peripherally arranged small follicles in a dense stroma (necklace appearance).



The peripherally arranged multiple small follicles (Necklace appearance)

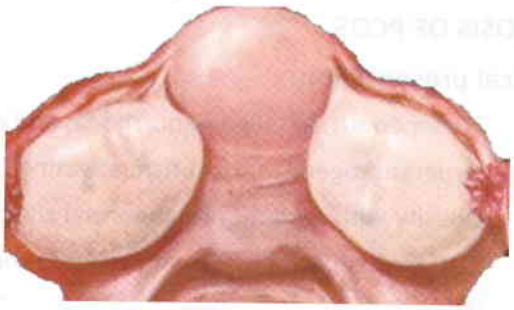

Enlarged ovaries with pearly white smooth surface as seen during laparoscopy

Fig. 8-3: PCOS

PREVALENCE AND AETIOLOGY:

- PCOS may affect up to **5-10%** of women in the reproductive age.
- It is **the commonest** ovarian cause for 2ry amenorrhoea, chronic anovulation, and infertility.
- The exact **aetiology** of PCOS remains unclear however a familial background is suggested with a *special gene* related to its development.

PATHOGENESIS OF PCOS

PCOS is characterized by **a triad of**; high LH, high serum androgen, and high plasma insulin:

A. High LH:

- Aetiology: it is due to increased LH pulse and frequency. It is manifested by an abnormally high LH/FSH ration (> 2:1).
- Effect: it stimulates secretion of androgen by ovarian theca cells, and inhibits aromatase enzyme responsible for conversion of ovarian androgen into oestrogen, resulting in *increased ovarian androgen*.

B. Hyperandrogenaemia:

- Aetiology: it is due to stimulation of theca cells (by both high LH and high insulin levels), together with inhibition of aromatase enzyme
- Effect: excess ovarian androgen leads to;
  1. Atresia of developing follicles leading to anovulation and amenorrhoea
  2. Hyperandrogenaemia; high serum androgen
  3. Hirsutism
  4. Excess androgen is converted in fat cells into oestrone (peripheral conversion). This results in acyclic increase in oestrone which leads to
     - Increased pituitary LH, and suppression of FSH
     - Unopposed oestrogen leads to endometrial hyperplasia or carcinoma

C. Hyperinsulinaemia:

- Aetiology: PCOS may be associated with peripheral insulin resistance disorder leading to hyperinsulinaemia.
- Effect: hyperinsulinaemia leads to;
  1. Increased sensitivity of ovarian theca cells to LH, thus increasing LH induced androgen production by the ovaries
  2. Decreased aromatase enzyme activity leading to excess ovarian androgen production
  3. Decreased production of SHBG leading to increased free androgen substrate.

DIAGNOSIS OF PCOS

A. Clinical presentation:

- 2ry amenorrhea, oligomenorrhoea, and or infertility (chronic anovulation)
- Hyperandrogenism (Hirsutism affecting face, chest and inner thighs)
- Obesity with tendency to abnormal glucose tolerance.
- DUB may occur in cases with chronic anovulation associated with endometrial hyperplasia.

B. Laboratory investigations:

- Elevated LH levels with normal FSH lead to an abnormal LH/FSH ration of >2.
- Elevated levels of plasma E1, androstenedione (AD), and free Testosterone (FT).
- Hyperinsulinaemia due to associated increased insulin resistance.

C. Ultrasound diagnosis: *(Adam's criteria)*

- The ovaries are increased in size and volume.
- The ovaries show central dense stroma surrounded by small follicles (2-10 mm in diameter) peripherally arranged giving the characteristic *necklace appearance*.
- No dominant or mature follicles are present due to chronic anovulation.
- US picture of PCOS may be encountered in up to 25% otherwise normal females.

D. Laparoscopic appearance: Enlarged ovaries with thick capsule, and absent gyrii due to absence of ovulation stigma on ovarian surface (*oyster shell ovary*), see Fig 8:2



Fig. 8-4: PCOS by TVS



Fig. 8-5: PCOS by Laparoscopy

LONG TERM RISKS OF PCOS

1. Increased risk for diabetes mellitus, obesity, hyperlipidaemia, and cardiovascular disease.
2. Increased risk of endometrial hyperplasia (EH); due to increased oestrogen effect on the endometrium unopposed by progesterone.
3. Increased risk of endometrial carcinoma if atypical EH develops.

MANAGEMENT OF PCOS

1. **Weight reduction;** In obese females a reduction of 5-10% of body weight, reduces insulin and androgen and improves response to therapy, and may by itself re-establish ovulation.
2. **Hormone therapy:** In cases with menstrual disorders as amenorrhoea or DUB;
   a. Cyclic gestagen therapy for 10 days every cycle (day 16-25), to induce a regular 28-30 days cycle (e.g. medroxy progesterone acetate 10 mg per day)
   b. Combined OCP (day 5-25), to establish regular cycles in cases not requesting pregnancy
3. **Induction of ovulation for infertility** (see details in treatment of chronic anovulation).
   - Clomiphene Citrate (CC): oral tablets twice daily for 5 days staring 3rd, 4th, or 5th day of the cycle, is the drug of choice in PCO patient presenting with anovulatory infertility. It has the least risk for ovarian hypertstimulation syndrome (OHSS).
   - Human Menopausal Gonadotropins (HMG); given as repeated IM injections, is effective in ovulation induction but with increased risk for OHSS.
   - Purified HMG or Recombinant FSH; given by IM injections have lower incidences of OHSS compared to HMG due to their minimal or absent LH content.
   - hCG IM injections; can be used to facilitate rupture of follicles when they reach maturity
4. **Insulin sensitizing drugs** (metformin 500 mg/day orally) improve insulin sensitivity, thus decreasing hyperinsulinaemia and androgen levels. Such drugs also increase sensitivity of PCO to endogenous FSH and drugs like CC, and may by itself establish ovulatory cycles.
5. **Corticosteroid therapy** to suppress ACTH production in case of adrenal hyperandrogenism.
6. **Surgical treatment** via laparoscopic ovarian drilling **(LOD)**; aims at decreasing ovarian androgen production. However, adhesion formation is an unfavorable side effect of surgery.
7. **Hirsutism:** Cypretorone acetate, laser depilation, or electrolysis (see later for details)

Key Points in PCOS

1. PCOS is the commonest cause of pathologic 2ry amenorrhoea occurring in 5-10% of females.
2. Besides menstrual disorders it may present with infertility, hirsutism, and obesity.
3. Diagnosis of PCOS is based on combination of clinical, laboratory, and US criteria.
4. Menstrual irregularities are management by hormonal therapy (gestagens or combined OCPs), while anovulatory infertility is managed by induction of ovulation.
5. Weight reduction in obese patients, and insulin sensitizers as metformin, play an adjuvant role in improving response of patients to various ovulation induction protocols.
6. Surgical treatment by LOD should be reserved to highly selected cases resistant to all other stimulation protocols, to avoid ovarian destruction and creation of peri-ovarian adhesions.

OVARIAN HYPER-STIMULATION SYNDROME (OHSS)

OHSS is an **iatrogenic disorder** that describes the occurrence of ovarian multicystic enlargement secondary to the use of **drugs for induction of ovulation**, namely HMG/hCG. It is classified into four grades according to severity of symptoms.

- **Mild forms (Grades I-II);**
  - These cases may be associated with variable degrees of abdominal pain and distension, oedema, mild ascites, hypotension, and oliguria.
  - Cases are managed by rest, reassurance, follow up, and symptomatic treatment



Fig 8-6 OHSS Grade II

- **Severe forms (Grades III-IV);**
  - These cases may be associated with fluid shift from intravascular to extravascular compartment leading to severe ascites, pleural effusion, hypoalbuminaemia, electrolyte imbalance, haemoconcentration and changes in blood coagulability with tendency to DIC and increased risk of pulmonary embolism.
  - These life-threatening cases are best managed by **hospitalization**, restoration of fluid and electrolyte imbalance, use of anticoagulants and sometimes tapping for aspiration of ascites. Diuretics are avoided as they will increase haemoconcentration with risk of thrombosis.
  - **Prevention of severe OHSS** could be achieved by both careful TVS monitoring of HMG doses during stimulation, and withholding hCG injections in cases with Gr II-III hyperstimulation.

LUTEAL PHASE DEFECT

Luteal phase defect (LPD); is a condition in which the endometrium shows poor secretory changes in the luteal phase of ovulatory cycles. These cycles are characterized by either low progesterone levels in the luteal phase, or short luteal phase duration (<11 days interval between ovulation and menstruation), or both.

Sporadic LPD may occur in isolated cycles in normally ovulating women while recurrent LPD may be a cause of infertility in 3-4 % of cases. The incidence is much higher in cases with recurrent first trimesteric abortion.

Aetiology

a. Inadequate follicular phase FSH production or inadequate FSH/LH ratio at time of ovulation.
b. Hyperprolactinaemia (decrease FSH and blunted LH surge)
c. Prolonged use of CC for induction of ovulation (decreased endogenous FSH release)

Diagnosis

- Biphasic BBT chart showing a short luteal phase
- Low midluteal serum P levels (5-10 ng/ml)
- Dated PEB showing secretory changes with a lag > 2 days behind that for a normal cycle

Treatment

- Progesterone support throughout luteal phase using oral or vaginal tablets
- Repeated hCG injections in the luteal phase to stimulate CL progesterone secretion
- Bromocryptine or Cabergoline for cases with elevated serum PRL levels
- Drugs used to stimulate super ovulation (CC/HMG/hCG)

10 FEMALE LOWER GENITAL TRACT INFECTIONS

- *Natural defense mechanisms*
- *Predisposing Factors*
- *Vaginitis*
- *Cervicitis*
- *Vaginal discharge*

VAGINAL FLORA AND VAGINAL PH

- **Vaginal flora** (ecosystem) of a normal asymptomatic reproductive age woman includes;
  - *Multiple aerobic or facultative species*
  - *Obligate anaerobic species*. Ratio of anaerobes to aerobes is approximately **(10:1).**
- **Nonpathogenic bacteria;** normally inhabit the vagina without causing infection include;
  - *Group B streptococcus*
  - *Escherichia coli, and*
  - *Lactobacilli.*
- **Lactobacillus acidophilus** is the dominant bacterium in a healthy vagina. They play a critical role to maintain the normal vaginal environment through:
  - *Production of lactic acid* responsible for acidic vaginal environment **(PH: 3.8-4.5).**
  - *Lactic acid and hydrogen peroxide* produced are toxic to anaerobic bacteria.
- **Glycogen content of vaginal mucosa** provides nutrients for vaginal flora, especially lactobacilli, thus maintaining an *acidic vaginal PH*.

  N.B.: Decreased glycogen content of vaginal mucosa will result in diminished acid production, leading to a *rise in vaginal PH* that becomes alkaline **(PH: 6.5- 7.0).**

Common vaginal FLORA

Aerobes

- **Gram positive:** Lactobacillus spp, Diphtheroids, Staphylococcus aureus, Group B streptococcus, Enterococcus faecalis.
- **Gram negative:** E. coli, Klebsiella spp, Proteus spp, Enterobacter spp, Pseudomonas spp

Anaerobes

- **Gram positive:** Peptostreptococcus, Clostridium, Lactobacillus spp, Gardnerella vaginalis
- **Gram negative:** Bacteroides spp, Bacteroides fragilis, Fusobacterium spp
- **Yeast:** Candida albicans, Candida tropicalis, Torulopsis glabrata

NATURAL DEFENSE MECHANISMS AGAINST GENITAL TRACT INFECTION (GTI)

A. **Vaginal PH:** The slightly acidic vaginal PH acts as an unfavorable medium for many pathogenic organisms. Changes of vaginal PH towards alkaline environment, renders the vaginal epithelium more vulnerable for infection.

B. **Vaginal epithelium:** the thick stratified squamous epithelium lining of the vagina is protective against pathogenic organisms and toxic substances. Normal oestrogen levels further protects it against atrophic changes.

C. **Cellular and Humoral immunity** play a role in normal vaginal defense mechanisms

FACTORS THAT PREDISPOSE TO VAGINAL INFECTIONS

1. **Alterations in the normal Vaginal PH:**
   - *Menstrual blood flow;* results in a more alkaline vaginal PH
   - *Vaginal douching;* unnecessary routine vaginal douching alters vaginal PH
   - *Decreased oestrogen;* as in childhood and menopause, may lead to lowered prevalence of lactobacilli leading to decreased glycogen content and higher vaginal PH
   - *Sexual intercourse;* may lead to higher vaginal PH due to the alkaline PH of the semen
2. **Imbalance between vaginal bacterial flora and Candida species**
   - *Recent treatment with broad spectrum antibiotics*
3. **Decreased resistance of vaginal epithelium**
   - *Atrophic vaginal epithelium:* as in childhood and menopause.
   - *Introduction of new organisms;* as with STDs that alter vaginal microbiology.
   - *Foreign bodies;* as vaginal tampons, IUD threads, and neglected pessaries in cases of POP.
4. **Suppression of immune system:** as with HIV infections, autoimmune disorders, corticosteroid therapy, and diabetes mellitus, may all result in recurrent vaginal infections especially Candidiasis.

COMMON TYPES OF VAGINITIS

Vaginitis, with or without vaginal discharge, is one of the commonest complaints encountered in gynaecologic practice. It commonly occurs in different periods of women's life:

a. **In the child bearing period:**
   - Bacterial vaginosis (BV).
   - Candida vaginitis (CV).
   - Trichomonas vaginalis (TV).

b. **In childhood:** as Vulvovaginitis of childhood.

c. **In menopausal women:** as Senile or Atrophic vaginitis.

VAGINITIS IN THE CHILD BEARING PERIOD

1. BACTERIAL VAGINOSIS

Bacterial vaginosis (BV) is the **commonest bacterial vaginal infection** encountered in gynaecologic practice (previously known as non-specific vaginitis and Gardnerella vaginitis).

It is also the **commonest cause** for non-irritant, malodorous **vaginal discharge** encountered in women attending routine gynaecologic and obstetric clinics.

▪ AETIOLOGY AND CAUSATIVE ORGANISMS

Anaerobic bacteria normally found in the vagina including:

- Gardnerella vaginalis (GV)
- Bacteroides species and Mycoplasma hominis.

- **BV** represents a state of **unexplained alteration of the normal vaginal flora**, where;
  - **Anaerobic organisms** markedly **increase** in concentration (thousands of times)
  - Hydrogen peroxide producing lactobacilli markedly **decrease** (or even disappear)
  - The **vaginal PH rises**, ranging **4.7-7.0** (alkaline PH).
- Anaerobic bacteria produce enzymes that break peptides to amino acids and amines, resulting in its characteristic discharge and odour.
- BV is not sexually acquired hence the sexual partner does not need to be treated.

CLINICAL PICTURE (Symptoms & Signs)

- **Asymptomatic** in 50% of women.
- **Vaginal discharge** is the commonest symptom. It is usually profuse, thin, homogenous, non-irritant, malodorous discharge that is adherent to vaginal walls. It may be yellowish grey or white in colour.
- **Characteristic fishy amine smell** is especially noticeable around the time of menses or following sexual intercourse.

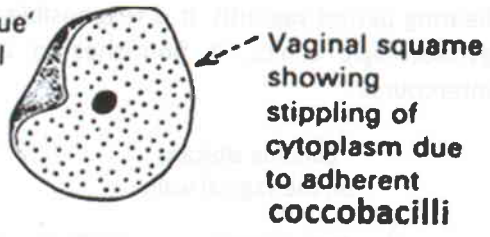

Fig 10-1: Clue cells in BV

DIAGNOSTIC INVESTIGATIONS (AMSEL CRITERIA)

1. **Microscopic examination** of a saline wet preparation of vaginal secretions; reveal characteristic clue cells which are vaginal epithelial cells heavily coated with bacteria obscuring its borders *(fig.11-1)*. The positive predictive value for this test in diagnosis of BV reaches almost 95%
2. **Adding 10% KOH** to a fresh sample of vaginal secretions releases volatile amines that have a characteristic fishy odour (whiff test).
3. **Vaginal PH > 4.5:** results from diminished acid production due to markedly decreased number of lactobacilli.

N.B.: Trichomonas vaginalis infection may be also associated with anaerobic overgrowth, increased pH, and release of volatile amines, therefore women diagnosed with BV should have no microscopic evidence of Trichomoniasis.

N.B.: Cultures from a vaginal swab yields mixed anaerobes and a high concentration of Gardnerella vaginalis (GV). However *GV can be grown from **over 50%** of women with normal vaginal flora, therefore its presence alone is not diagnostic of BV.*

TREATMENT OF BV (CDC 2010)

- **Oral Preparations:**
  - *Metronidazole tablets:* 500 mg twice a day for 7 days*,
- **intravaginal Preparations:**
  - *Metronidazole gel vaginally:* 0.75%, one full applicator (5 g) daily for 5 days, **OR**
  - *Clindamycin cream vaginally:* 2%, one full applicator (5 g) daily 7 days†
- **During Pregnancy:**
  - *Vaginal Clindamycin* may be used from first trimester throughout pregnancy.
  - *Oral Metronidazole* may be used in 2nd and 3rd trimesters safely.

† Clindamycin cream is oil-based and might weaken latex condoms and diaphragms for 5 days after use.

N.B.:

- Cure rates in non-pregnant women with BV will reach up to 80-90% at one week.
- Recurrent infection may occur in up to 30% of treated women within 3 months, especially those with heterosexual contacts.
- Women with BV are at increased risk for: second trimester abortion, preterm labour, endometritis, and pelvic inflammatory disease (PID).
- Screening for BV should be offered for women with a history of idiopathic preterm labour or second trimester abortion. Treatment for positive cases is best initiated before a new pregnancy is allowed.

2. CANDIDA VAGINITIS

Candida vaginitis CV (Candidiasis or Moniliasis) is the second most common causes for child bearing period vaginitis. It is responsible for almost 30% of cases presenting with vulvovaginitis in gynaecologic clinics. It flourishes in acidic media, and is rarely transmitted during sexual intercourse.

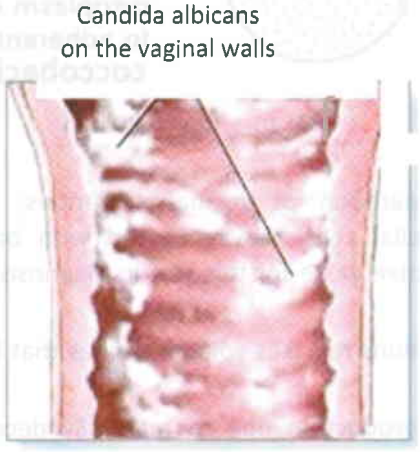

Fig 10-2: Cand1da albicans on the vaginal walls

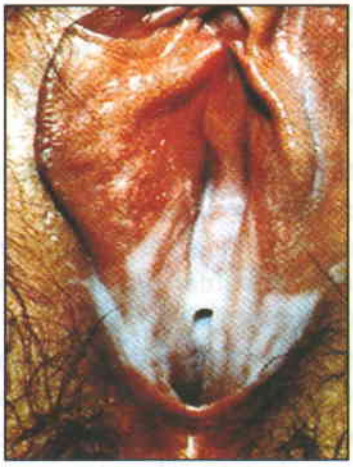

Fig 10-3: Cand1da albicans vaginal discharge

AETIOLOGY AND CAUSATIVE ORGANISMS

- **Candida albicans:** (a fungus causing yeast infection) is the causative organism in **> 80%** of cases. It is a normal inhabitant of the bowel and peri-anal region. Almost *30%* of women may have vaginal colonization with *no symptoms of infection*.
- **Non albicans strains:** as Candida tropicalis and Torulopsis glabrata, are **less common** being encountered in **< 20%** of cases. They are usually *resistant to standard antifungal treatment* regimens.

PREDISPOSING FACTORS FOR SYMPTOMATIC INFECTION

A. Changes to a more acidic vaginal PH:

- *During pregnancy* and *long term use of OCPs*: due to increased glycogen content of vaginal epithelium, allowing for more production of lactic acid by lactobacilli.
- Routine *vaginal douching* in absence of infection
- During the use of some *vaginal Spermicidals* as a method for long term contraception.

B. Decreased host immunity:

- During *pregnancy*, *diabetes mellitus*, long term use of *corticosteroid* therapy, and *HIV infection*.

C. Altered vaginal microbiology:

- During long term use of *antibiotics* or *chemotherapy*, thus disturbing the balance between different types of bacterial inhabitants and vaginal flora.

D. Increased local warmth and moisture: as with tight clothing, nylon underwear, and bathing suits.

CLINICAL PICTURE (Symptoms & Signs)

- *Intense **pruritus*** with itching and progressive scratching is usually the main symptom.
- *Vaginal **burning** sensation* that may cause discomfort and dyspareunia
- *Vaginal **discharge**;* scanty thick white discharge (cottage cheese discharge)
- ***Dysuria*** may be an associated symptom in some cases
- *The **vulva*** may be red and swollen, sometimes showing the classic satellite lesions
- *The **vagina*** may show patches of scantv, adherent, cottage-cheese discharge

DIAGNOSTIC INVESTIGATIONS

- **Vaginal pH** may be normal or slightly acidic (< 4.5)
- **Wet mount microscopic examination** with **saline** and **10% KOH**; reveals hyphae or pseudo- hyphae, with budding yeast in 50%-70% of women with yeast infections
- Vaginal swabs for culture are not necessary except in resistant or recurrent infection

TREATMENT OF VAGINAL CANDIDIASIS (CDC 2010)

- **Oral preparations:**
  - *Fluconazole;* Single oral dose 150 mg, for treatment of uncomplicated cases
- **Intravaginal preparations**
  - *Butoconazole* 2% cream 5 g daily for 3 days, **OR**
  - *Clotrimazole* 2% cream 5 g daily for 3 days, **OR**
  - *Miconazole* 4% cream 5 g daily for 3 days, **OR**
  - *Tioconazole* 6.5% ointment 5 g as a single application, **OR**
  - Butoconazole 2% 5 g for 1 day, **OR,**
  - Terconazole 80 mg vaginal suppository, one suppository for 3 days
- **During pregnancy**; intravaginal treatment for **CV** is considered safe throughout pregnancy.

N.B.:

- **Cure rates** of > 80-90% are expected within one week of treatment
- Routine **treatment of sexual partners** is not recommended, except in recurrent infection.
- **Recurrent infection**: (5% of cases), may be due to:
  - Infection with non albicans strains (C. tropicalis & T. glabrata)
  - Sexual transmission from male partner
  - Immunocompromized hosts; as pregnancy, DM, HIV, or chemotherapy treatment
  - Treatment of recurrent cases: Prolonged and repeated courses of vaginal and oral therapy.

3. TRICHOMONAS VAGINALIS VAGINITIS

Trichomoniasis is the 3rd most common cause for vaginitis, accounting for almost 25% of cases presenting with vulvovaginitis accompanied by vaginal discharge. It is a multifocal infection that involves the vaginal epithelium, Skene's glands, Bartholin gland and urethra.

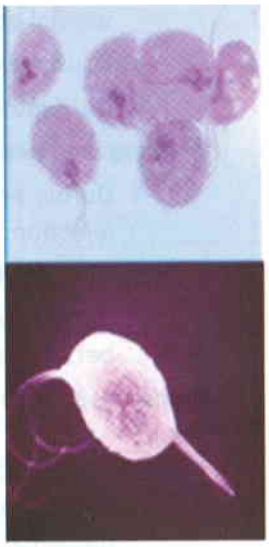

Fig 10- 4: Flagellated organism in TV

AETIOLOGY AND CAUSATIVE ORGANISM

- **Trichomonas vaginalis (TV):** an ovoid, motile, flagellated protozoon, with 4 anterior flagellae and an axostyle, which traverses its body to end in a spike. It is slightly larger than a leucocyte (20mm length & 10mm width).
- **Sexual transmission:** In 70% of cases TV can be recovered from male partners, hence it is considered a sexually transmitted disease (STD)

CLINICAL PICTURE (Symptoms and Signs)

- ***Asymptomatic*** in 25% - 50% of women.
- ***Vaginal discharge:*** Copious, yellow or green, frothy, offensive.
- ***Vulval irritation*** causing vulvitis and pruritus
- **Speculum examination:** reveals vaginal or cervical punctuate haemorrhages in 25% of cases also known as strawberry spots.

DIAGNOSTIC INVESTIGATIONS

- **Vaginal pH:** is usually weak acidic (5.0 - 6.0)
- **Saline wet mount preparations:** of the vaginal discharge reveal numerous leukocytes and highly motile flagellated trichomonads in 70% of cases
- **Cultures:** are sensitive in diagnosis, but are not widely used as they need special media which are not easily available in many laboratories.
- **Pap smear:** Trichomoniasis may be noted on Pap smear screening for cervical neoplasia, with a sensitivity approaching 60%.

TREATMENT (CDC 2010)

- *Metronidazole:* 2 g orally in a single dose, **OR**
- *Tinidazole:* 2g orally in a single dose
- **During Pregnancy:** Oral Metronidazole can be used after 1st trimester
- **The male sexual partner** should be promptly treated by oral Metronidazole re-infected.
- **Recurrent and resistant infection** necessitates searching for reinfection. If reinfection is excluded, the patient can be treated with metronidazole 500mg twice daily for 7 days.

CHILDHOOD VAGINITIS

Childhood vulvovaginitis is **rare**, however may occur mostly due to decreased vaginal wall resistance secondary to low oestrogen levels and low vaginal PH.

RISK FACTORS

- *Poor hygiene;* leading to Infection by pathogenic organisms.
- *Foreign body* introduced inside the vagina, usually accidentally.
- *Pinworms* (Enterobius vermicularis), may reach the vagina from anus as they migrate by night, causing intense pruritus and itching by night.

CAUSATIVE ORGANISMS:

- **Bacterial infection**: E. coli, streptococci, staphylococcus aureus, and gonococci
- CV and TV (rare causes).

CLINICAL PICTURE (symptoms and signs)

- **Vaginal discharge**: which is purulent, foul odour, and sometimes bloody
- **Pruritus** vulvae: itching, scratching, pain, and sometimes dysuria

DIAGNOSTIC INVESTIGATIONS

- Culture and sensitivity of discharge to choose the appropriate antibiotic
- U.S. and /or X-ray to detect foreign body
- Investigations to detect Enterobius vermicularis and Oxyuris worms.

TREATMENT

1. **Local** cleanliness with diluted antiseptics
2. **Systemic antibiotics** according to culture and sensitivity of discharge.
3. **Treatment** of Enterobius and oxyuris **worms**,
4. Removal of **foreign body** in the vagina under anaesthesia

ATROPHIC VAGINITIS

Atrophic vaginitis occurs due to loss of the normal protective thickness of the vaginal epithelium associated with decreased oestrogen levels. It is often seen in postmenopausal women **(senile vaginitis)**, but can be seen in breast feeding women.

The vaginal epithelium becomes thin, the amount of glycogen content decreases, and PH becomes alkaline. The vagina becomes pale with predominance of parabasal cells.

CLINICAL PICTURE (Symptoms and signs)

- Leucorrhoea, **pruritus**, vaginal **burning**, **tenderness**, and **dyspareunia**
- **Speculum examination** shows atrophic vagina, inflamed walls, and sometimes discharge that may be offensive if secondary infected.

DIAGNOSIS

- Vaginal **PH** is usually **low < 4.5,** while in menopause it should be >4.5.
- Vaginal infection is usually not identified on wet mount preparation

TREATMENT

- **Systemic antibiotics;** according to culture and sensitivity, in 2ry infected vaginal discharge
- **Intravaginal oestrogen cream** administered every night for 2 weeks, then once weekly.
- **Systemic hormone therapy (HT):** is given only if otherwise medically indicated for treatment of menopausal symptoms (as hot flashes) or osteoporosis.

ACUTE AND CHRONIC CERVICITIS

1- ACUTE ENDOCERVICITIS

Acute endocervicitis describes acute inflammation of the endocervical glands and underlying tissues, mostly secondary to infection by sexually transmitted pathogens.

AETIOLOGY AND CAUSATIVE ORGANISMS

- **Sexually transmitted pathogens:** *Neisseria gonorrhoea, Chlamydia Trachomatis, and TV.*
- **Other bacterial organisms**: as *streptococci* and *staphylococcus aureus*, in relation to IUD insertion, puerperal, post-abortive, or post-operative infection (D&C procedures).

CLINICAL PICTURE (symptoms and signs)

- ***Vaginal discharge***: Mucopurulent discharge, backache, dyspareunia, and sometimes mild fever
- ***On speculum examination;*** the cervix is red swollen with mucopurulent discharge.
- ***On bimanual examination;*** marked tenderness on moving the cervix

DIAGNOSIS

- ***Culture and sensitivity*** of the discharge for appropriate antibiotic therapy

TREATMENT (CDC 2010)

- *Azithromycin* 1 g orally in a single dose, **OR**
- *Doxycycline* 100 mg orally twice a day for 7 days.

N.B.: Consider concurrent treatment for gonococcal infection if prevalence of gonorrhea is high in the patient population under assessment.

COMPLICATIONS

1. **Chronic Cervicitis:** high tendency for chronicity due to the racemose (branching) nature of the cervical glands, and lack of cyclic shedding of cervical mucosa
2. **Spread of the infection** to the upper genital tract, may lead to **pelvic inflammatory disease (PID)**

2- CHRONIC CERVICITIS

Chronic cervicitis describes chronic inflammation of the endocervical glands. It usually occurs as a common sequel of acute Cervicitis.

CLINICAL PICTURE

- **Symptoms:**
  - ***Vaginal discharge:*** mucopurulent offensive discharge in association with endocervicitis
  - ***Backache*** due to spread of infection along the uterosacral ligament
  - ***Dyspareunia*** due to parametrial infection if present
  - ***Dysmenorrhoea*** due to pelvic congestion
  - ***Contact bleeding*** in some cases in association with congestion and cervical erosion
  - ***Infertility*** due to infected hostile cervical discharge
  - ***Frequency of micturition*** due to cystitis caused by lymphatic spread
- **Signs on Speculum examination:**
  - **Mucopurulent offensive discharge** coming out from the cervix (Endocervicitis)
  - **Cervical erosion** *(see later)*
  - **Chronic hypertrophic cervicitis:** the cervix becomes swollen and hyperaemic.
  - **Mucous polyp:** reddish pedunculated small polyp protruding from the endocervical canal, due to hyperplasia of the endocervical epithelium
  - **Nabothian cysts:** small blue or yellowish cysts within the substance of the cervix, projecting on the portio-vaginalis. It represents distended cervical glands with secretions due to blockage of their ducts.

DIAGNOSIS

1. Culture and sensitivity of the discharge.
2. Exclusion of malignancy by vaginal and cervical smear in cases of suspicious cervix.

TREATMENT (CDC 2010)

Oral or vaginal antimicrobials according to the causative organism (clinical and lab screening).

CERVICAL EROSION

Cervical erosion (ectopy) is a bright red area around the external os due to replacement of the stratified squamous epithelium of the ectocervix with the endocervical columnar epithelium, which is thin and shows the underlying blood vessels.

AETIOLOGY

1. **Chronic Cervicitis:** The infected cervical discharge from the endo- cervix produces a devitalized denuded area of the stratified squamous epithelium around the external os.
   - *First healing phase:* columnar epithelium from the endocervix grows to cover the denuded area on the ectocervix.
   - *Second healing phase:* the stratified squamous epithelium from the ectocervix grows under the columnar epithelium leading to blockage of the ducts of cervical glands and formation of retention (Nabothian) cysts.
   - *Exacerbation of infection* leads to repetition of the whole process.



Fig 10-5: Cervical erosion

2. **Congenital erosion:** Persistence of the intra-uterine condition where the columnar epithelium covers an area on the ectocervix (very rarely seen after puberty).
3. **Hormonal erosion:** Excess oestrogen (as during pregnancy and with oral contraceptive use) causes growth of columnar epithelium replacing the stratified squamous epithelium.

CLINICAL PICTURE

- **SYMPTOMS**
  - *Vaginal discharge:* excessive mucoid in nature.
  - *Contact bleeding:* manifested after douching or intercourse.
  - *Symptoms of chronic cervicitis* if complicated by associated infection (mucopurulent foul discharge, backache, dysmenorrhoea, dyspareunia, etc...)
- **SIGNS**
  - *Vaginal examination:* velvety sensation and occasional contact bleeding.
  - *Speculum examination:* reveals flat erosion (red flat area), or papillary erosion (red area with raised folds) or follicular erosion (red are with glandular distension).

DIAGNOSIS

- Vaginal and cervical smears exclude malignancy

TREATMENT

- **Hormonal erosion:** require **no treatment** except if they persists for more than 3 months.
- **Antimicrobials** to treat **associated infection** as in chronic cervicitis (mainly C.trachomatis and N. Gonorrhea): CDC recommendations (2010)
- **Azithromycin 1g orally single dose OR**
- **Doxycycline 100mg orally twice daily for 7** days. Followed by should be offered after treatment since recurrence and re-infection is not rare.
- **Resistant or recurrent infections** are mainly treated by repeated antibiotic courses. Destruction of cervical tissue by cauterization, cryotherapy, or laser is not commonly done nowadays.

VAGINAL DISCHARGE

Normally the vagina and the introitus are kept moist with minimal discharge that may occasionally stain the underclothes by one or two drops. The discharge consists of fluid formed from as a transu- dation from the vaginal walls, desquamated epithelial cells, bacteria (mainly lactobacilli), together with mucus secreted mainly from cervical glands.

Normal vaginal discharge is characterized by being white in colour, semi fluid in nature, small in amount, with a slightly acidic PH (3.8-4.5).

- **Sources of Normal Vaginal Discharge:**

Vaginal discharge is formed from vaginal transudate and exfoliated cells, endocervical glandular secretions and exfoliated cells, vulval secretions from Bartholin glands (thin alkaline mucus during sexual intercourse), micro-organisms and their metabolic products.

- **Characters of Normal Vaginal Discharge:**

Normal vaginal discharge is characterized by being clear in colour, semi-fluid in nature, with little or no smell. Its PH ranges from 3.8-4.5 (acidic), and its amount< 0.5 ml/day.

(For details on DD of vaginal discharge see lower genital tract infections and vulvovaginitis).

LEUCORRHOEA

This is the term used to describe the *excessive white non infected vaginal discharge* due to excess of the normal secretion or transudation of the cervix, vagina, and Bartholin's gland. It may be related to:

- **Physiologic causes:** mostly related to oestrogen effect with increased vascularity and associated pelvic congestion; as in puberty with onset of menstruation, at the preovulatory and the premen- strual phases of the menstrual cycle, and during pregnancy.
- **Pathologic causes:** Associated with pelvic congestion; as in pelvic inflammatory disease (PID), fibroids, pelvic, and adnexal masses.

ABNORMAL VAGINAL DISCHARGE

a. **Coloured offensive discharge:** bacterial vaginosis & trichomonas vaginalis

b. **Muco-purulent discharge:** e.g.; chronic cervicitis

c. **Purulent offensive discharge:** septic abortion, puerperal sepsis, foreign body in vagina, ne- glected pessary, pyometra, pelvic abscess evacuating vaginally, and infected neoplasms as sub- mucus fibroid polyp, endometrial, cervical, and vaginal cancers.

d. **Blood stained (sanguineous) discharge:** atrophic vaginitis, vaginal and cervical ulcers, cervical erosion, fibroid polyp, and malignancies of the vagina, cervix, and endometrium.

e. **Serous (watery) discharge:** Intermittent hydrosalpinx, and urinary fistula.

THE CLINICAL APPROACH FOR A CASE OF VAGINAL DISCHARGE

A. History & related conditions:

- Age at onset of symptoms; childhood, childbearing period or menopause.
- Recent use of systemic or local antibiotics
- Previous or recurrent vulvovaginal infections.
- Vaginal hygienic practices e.g., frequency of repeated and routine douching.
- Menstrual history: relation of discharge to menstruation.
- Obstetric history: relation of discharge to recent pregnancy, delivery, or abortion
- Contraceptive history: Use of vaginal spermicidals, diaphragms, and hormonal rings
- Sexual history: relation of intercourse to vaginal discharge and associated symptoms
- History of medical illness as diabetes mellitus, or HIV.

B. Symptoms & associated conditions

- Character of discharge, its amount, consistency, colour, and odour
- Associated burning sensation in the vulva and vagina (the commonest symptom)
- Presence of itching or pruritus; that may be intense and distressing to the patient

C. Signs on examination of the vulva and vagina

- The vulva; is inspected for associated vulvitis, or Bartholinitis
- The vagina and cervix; are inspected using a dry sterile speculum, for white plaques in cases of CV, strawberry cervix in TV, and grey frothy discharge in BV
- Milking of the urethra through the vagina to detect gonorrhoea
- Bimanual examination to exclude uterine or adnexal masses.

D. Laboratory diagnosis

- Wet mount preparations and microscopic examination; reveals clue cells in BV, hyphae in CV, and flagellated trichomonads in TV.
- Addition of 10% KOH; may reveal fishy amine odour in cases of BV.
- Vaginal swabs for culture, will reveal other bacterial causes for vaginitis Pap smears may reveal trichomonas vaginalis
- Biopsy from suspicious vaginal or cervical ulcers or tumours.
- X-ray may reveal a vaginal foreign body in infants with resistant and recurrent vaginitis.

TREATMENT:

- Treatment of the cause e.g. trichomonas, moniliasis or neoplasms.
- Genital hygiene including vaginal douching when necessary, proper treatment of first attack and adequate treatment of repeated or recurrent infection.

11 FEMALE UPPER GENITAL TRACT INFECTIONS

- *Acute PID*
- *Chronic PID*
- *Chronic specific FGTI*

PELVIC INFLAMMATORY DISEASE (PID)

Pelvic inflammatory disease (PID) is an infection of the **upper reproductive tract organs**. The fallopian tube is the most common and most important organ affected hence PID is commonly used to describe acute salpingitis and/or salpingo-oophoritis. PID is usually caused by bacterial pathogens ascending from the lower to the upper female genital tract.

DEFINITIONS AND TYPES

A. Acute PID: acute infection ascending from the cervix, to the tubes and ovaries.

B. Chronic PID: chronic pelvic infection that can follow an acute episode of PID, or may occur as a sequel to an inflammatory pelvic lesion or genital T.B.

N.B: PID may be silent, occurring with asymptomatic or mildly symptomatic pelvic infection. It is usually diagnosed only when the sequelae of tubal damage is found later, as with formation of fine peritubal adhesions detected at laparoscopy.

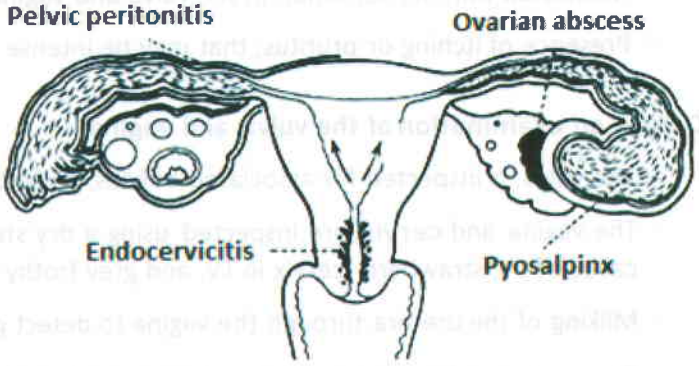

Fig 11-1:

1- ACUTE PELVIC INFLAMMATORY DISEASE (PID)

MICROBIOLOGY OF PID

Acute PID is a polymicrobial infection that may be caused by;

- ***Neisseria gonorrhea:*** a Gram negative diplococcus, recovered from the cervix in 27% to 80%, and from the fallopian tubes from 13% to 18% of cases with PID. It is the most common cause for acute salpingitis.
- ***Chlamydia trachomatis:*** Chlamydial antibodies are found in 20% to 40% of women with history of PID, although C. Trachomatis does not by itself cause an acute inflammatory response. N. gonorrhea and C. trachomatis may coexist together in 25% to 40% of cases of PID.
- ***Endogenous bacteria;*** which may be:
  - *Aerobic* as E.coli, Streptococcus species, bacillus proteus, and Klebsiella.
  - *Anaerobic* as Bacteroides fragilis, and Peptostreptococcus.

ROUTES OF INFECTION:

1. Ascending infection from endocervicitis (namely gonorrhoea! & chlamydial) by transluminal spread leading to endosalpingitis.
2. Direct or lymphatic extension from inflammatory GIT conditions as; appendicitis, colitis, and diverticulitis (whether aerobic or anaerobic bacteria). Puerperal infection spreads along peri-tubal lymphatics leading to interstitial or perisalpingitis.
3. Rarely the tubes may be affected by blood borne extension from pulmonary T.B.

RISK FACTORS

- ***Factors associated with increased risk for PID***
  - Young, sexually active women are at **highest risk** for infection representing almost 85% of cases, mostly occurring in the age group ranging from 25-35 years.
  - Women with multiple sexual partners have a **3 fold risk** for PID than a single partner.
  - Use of **intrauterine contraceptive device (IUCD)** has been associated with an increased incidence of PID especially in the period following its insertion.
- ***Factors associated with decreased risk for PID***
  - Barrier methods for contraception; as the male condom, the female diaphragm, sponge, and contraceptive gel-foams, all **decrease the risk** of STDs and PID.
  - Oral contraceptive pills (OCPs); are associated with significantly **low incidence of PID**, probably through its effect on regular endometrial shedding, decreased menstrual flow, and its progestational effects on the cervical mucus rendering it less penetrable by bacterial patho- gens.
- ***Factors facilitating ascending infection:***
  - **Menstrual periods:** due to degenerating endometrium, retrograde menstruation, and cervical mucous changes.2/3 of acute PID cases begin just after menses
  - **Sexual intercourse:** bacteria may be pushed into the cervix during intercourse, and ascent to the uterus assisted by associated uterine contractions.
  - **Iatrogenic procedures:** as D&C operations, IUD insertion, hysterosalpingography (HSG), hysteroscopy, and during dye tubal patency testing in laparoscopy.

PATHOLOGY OF ACUTE SALPINGO-OOPHORITIS

Infection is usually bilateral, however unilateral infection is possible.

1. **Endosalpingitis**; with congestion, oedema, and destruction of tubal luminal cells, cilia, and mucosal folds. It is either catarrhal or suppurative
2. **Interstitial salpingitis and perisalpingitis;** due to extension of infection to the tubal muscularis and serosa. Infection also spread by direct extension to the tubal ostea and abdominal cavity.
3. **Oophoritis;** may occur with development of micro-abscesses on ovarian surface
4. **Pelvic peritonitis;** may occur either by direct extension from the tubal lumen laterally, or by lymphatic spread.
5. **Chronic PID;** see later

REMOTE SEQUELAE AND COMPLICATIONS OF PID

Medical complications may develop in one out of 4 cases of acute PID.

1. **Tubal obstruction and infertility:** such risk correlates with the severity and the number of PID episodes. It reaches up to 11o/o after one episode, 23 o/o after 2 episodes, and 54% after the third episode.
2. **Ectopic pregnancy:** the rate increase 10 fold in women with PID. Approximately 50% of tubal ectopic pregnancy is thought to result from tubal damage caused by PID.
3. **Chronic pelvic pain:** develops in almost 20% of women with acute PID, sometimes associated with dyspareunia.
4. **Mortality:** Rarely occurs, only in neglected cases with septic shock and ruptured tubo-ovarian abscess

CLINICAL PICTURE (Symptoms & Signs)

A. **History:** recent IUD insertion, D&C procedure, recent delivery or abortion, or recently performed HSG for infertility, in a young sexually active woman.

B. **Symptoms:** Symptoms often start in the postmenstrual period. Women with chlamydial PID usually have clinically milder disease than those with gonococcal PID. Symptoms are generally non-specific including:
   - Acute lower abdominal pain is the most common symptom
   - Fever, headache, and malaise
   - GIT symptoms; as nausea and vomiting.
   - Increased vaginal discharge, and sometimes vaginal bleeding.

DIAGNOSTIC INVESTIGATIONS

1. Examination of Cervico-vaginal discharge:
- *Gram stain:* is useful in diagnosis of N. gonorrhoea although alone may miss up to half of cases and does not diagnose C. trachomatis.
- *Testing for Chlamydial and gonorrheal antibodies:* presence of antibodies will help in diagnosis in cases where clinical symptoms are suggestive of acute PID.

2. Blood tests:
- *Increased WBCs (Leucocytosis);* is not accurate for diagnosing acute PID.
- *Increased ESR;* is a non-specific finding although elevated in >75% of PID cases (good sensitivity but low specificity).

3. Ultrasound:
- Findings may be normal or non-specific.
- TVS to exclude ectopic pregnancy, uterine myomata, and ovarian swellings.

4. Laparoscopy:
- Laparoscopy is considered the gold standard to confirm the diagnosis whenever in doubt or in cases with poor response to parentral antibiotic therapy after 48-72 hours of initiating treatment.
- Laparoscopy will reveal; tubal serosal hyperemia, tubal wall oedema, and purulent exudates from the fallopian tubes pooling in the cul-de-sac.

5. Culdocentesis:
- Aspiration of purulent fluid in the pouch of Douglas may assist diagnosis and antibiotic selection after culture and sensitivity, yet its use is limited by its associated pain, and tendency for secondary infection.

6. Testing for HIV and STDs: should be offered to all women diagnosed as PID.

CDC Criteria for Diagnosis of Acute PID (2015)

Treatment for PID should be initiated in sexually active young women if one or more of the following minimum clinical criteria are present on pelvic examination:

- Cervical motion tenderness **or** uterine tenderness **or** adnexal tenderness.
- One or more of the following additional criteria can be used to support a diagnosis of PID:
- Oral temperature >38.3°C
- Abnormal cervical mucopurulent discharge or cervical friability
- Presence of abundant numbers of WBC on saline microscopy of vaginal fluid
- Elevated erythrocyte sedimentation rate
- Elevated C-reactive protein **and**
- Laboratory documentation of cervical infection with *N. gonorrhoeae* or *C. trachomatis*.

Laparoscopic Evidence of PID:

– Peri-tubel adhesions, peritonitis, pelvic abscess and tubo-ovarian complex

DIFFERENTIAL DIAGNOSIS FOR ACUTE PID

1. Ectopic pregnancy
2. Torsion or ruptured ovarian cyst
3. Degenerating fibroids
4. Endometriosis and ovarian endometriomas.
5. Inflammatory bowel disease; as appendicitis and diverticulitis

TREATMENT OF ACUTE PID

Empiric treatment is immediately started whenever minimal diagnostic criteria are met with in women with high risk factors. The primary goal of therapy is to eradicate bacteria, relieve symptoms, and prevent adverse sequelae especially tubal damage.

- **Rest in bed**
- **Analgesics and antipyretics** are important to alleviate pain and fever.
- **Antibiotic treatment**

CDC antibiotic regimens (2010)

A. IM regimen is indicated in mild-moderate cases of acute PID. The recommended drugs are:
Ceftriaxone 250 mg IM single dose **PLUS**
Doxycycline 100 mg orally twice a day for 14 days
WITH or WITHOUT
Metronidazole 500 mg orally twice a day for 14 days

B. IV regimen is used in severe PID cases, which require hospitalization. IV regimens are continued for at 24-48 hours after clinical improvement then oral treatment is continued to complete 14 days. The recommended drugs are:
Cefotetan 2 g IV every 12 hours **OR**
Cefoxitin 2 g IV every 6 hours **PLUS**
Doxycycline 100 mg orally/12 hours

- If no improvement occurs within 72 hours of start of standard treatment, the patient should be hospitalized (if not) for further investigations and surgical treatment may be indicated.
- If the woman is using an IUCD, it should be removed but after starting the antibiotic cover.
- Evaluation and treatment of male partner is essential.

Treatment of Tubo-Ovarian Abscess (TOA):

A. Medical:

- Clindamycin 900mg IV/8 hours + Metronidazole 500 mg IV/8 hours + Doxycycline 100mg orally/12 hours (triple therapy).

B. Surgical: Considered in severe cases whenever the patient's condition worsens or does not improve within 72 hours of treatment, or whenever diagnosis is not definitive.

- **Laparoscopy:**
  - *Diagnostic laparoscopy* confirms diagnosis whenever in doubt
  - *Operative laparoscopy* may assist drainage or for performing unilateral salpingo-oophorectomy.
- **Laparotomy:** To perform drainage, or salpingo-oophorectomy.
- **Vaginal drainage** rarely done is selected cases of localized TOA.

2- CHRONIC PELVIC INFLAMMATORY DISEASE (PID)

Chronic PID is an ill-defined term including all sequelae of acute PID either with complete resolution of microbial load leaving residual fibrosis or incomplete bacterial resolution leaving chronic inflammatory pathology affecting the upper genital organs and the surrounding structures.

AETIOLOGY

1. **Sequelae of acute PID** (inadequate treatment or neglected cases)
2. **TB** starts as chronic disease (however it is better to be a separate entity).

PATHOLOGY

1. **Hydrosalpinx:** sequelae of acute catarrhal salpingitis. The tube is retort shaped, thin walled, transparent, containing serous fluid, with no or minimal surrounding adhesions.
2. **Pyosalpinx:** sequelae of acute suppurative salpingitis. The tube is thick walled, containing pus, and surrounded by dense adhesions.
3. **Chronic interstitial salpingitis.**
4. **Tubo-ovarian cyst:** communicating between hydrosalpinx and ovarian cyst
5. **Tubo-ovarian abscess:** connecting between pyosalpinx and ovarian abscess

CLINICAL PICTURE (Symptoms & Signs)

A. Symptoms

- History of acute PID
- Dull aching lower abdominal pain
- Lower Backache; especially sacral
- Pelvic congestive symptoms; as vaginal discharge, and menorrhagia
- Secondary dysmenorrhoea: due to pelvic congestion and/or tuba-ovarian mass
- Chronic pelvic pain
- Infertility (primary or secondary) due to tubo-peritoneal factor whether associated with dense adhesions or tubal occlusion.

B. Signs: Adnexal swelling; usually bilateral, tense cystic, tender, fixed, with fixed RVF

DIAGNOSTIC INVESTIGATIONS

- **Pelvic ultrasonography (TAS I TVS):** to detect adnexal masses
- **Diagnostic Laparoscopy:** to confirm the nature of adnexal mass
- **For TB** *(see later)*

DIFFERENTIAL DIAGNOSIS:

- Pelvic endometriosis, or pelvic malignancy.
- Other non gynaecologic causes of chronic pelvic pain

TREATMENT OF CHRONIC PID

- **Antibiotics** are used only in acute exacerbations or when bacterial existence is diagnosed.
- **Symptomatic treatment** for pain (analgesic), inflammation (NSAID) and congestion (anti-congestives).
- **Infertile patients;** are best advised for ICSI/IVF procedures since tubal surgery (salpingolysis or salpingostomy) have poor prognosis.
- **Elderly patients and cases resistant to medical treatment** that have completed their family may benefit from surgery with total abdominal hysterectomy and bilateral salpingo-oophorectomy (TAH-BSO).

N.B.: Surgery in cases with chronic PID carry a high risk for intestinal and ureteric injury due to associated dense adhesions.

TUBERCULOSIS OF THE FEMALE GENITAL TRACT (TB)

Tuberculosis (TB) is a chronic granulomatous disease caused by Mycobacterium tuberculosis. Female genital TB is always secondary to a lesion elsewhere in the body, most commonly the lungs, and less commonly the bones and urinary tract. Spread of infection through the genital tract is mainly hematogenous, via the blood, or less commonly through the lymphatics. 95% of female genital TB is due to human strain.

PATHOLOGY:

A. Sites affected: The tubes are affected in almost all cases of genital T.B.; the endometrium will be involved in up to 80% of cases, and the ovaries in nearly 20-30%.

B. Macroscopic picture:

1. The tube:

a. *Endo-salpingitis:*

- The tube is thickened and tortuous, commonly with patent fimbrial end. The tube may be filled with caseous material forming a TB pyosalpinx, and may be matted with the ovary forming a TB tube-ovarian abscess.
- T.B pyosalpinx is characterized by eversion of fimbriae (tobacco pouch appearance), presence of external tubercles, and scarce adhesions to the surroundings.
- During healing by fibrosis some ectopic endosalpinx is driven within the muscle wall in the region of the isthmus producing "Salpingitis isthmica nodosum".

b. Perisalpingitis: The serosa of the tubes, ovaries, uterus, intestines and wall of Douglas pouch are all studded by multiple tubercles.

c. Interstitial salpingitis: There is thickening and nodularity of the tubes.

2. The Endometrium:

- Tuberculous follicles may be found in the endometrial stroma especially in the 2nd half of the cycle therefore for diagnosis an endometrial biopsy should be performed pre-menstrual
- Intrauterine synechiae may develop due to destruction of surface epithelium and fibrosis lead to partial or complete obliteration of the uterine cavity by adhesions resulting in Asherman's syndrome.

3. The ovaries:

- Peri-oophoritis
- Oophoritis with foci of caseation

4. Other rare sites:

a. Vulvar ulcerative lesions; the vulva may be affected especially in children, leaving an ulcer with undermined edges that may lead to fibrosis and scarring of the labia.
b. Cervical ulcerative lesions; that can be misdiagnosed as cancer cervix.

C. Microscopic picture:

- Tuberculous follicle; is the characteristic lesion, with central Langhan's giant cells, surrounded by epithelioid cells, then a coat of round cell infiltration.
- Caseation, from the center outwards may occur, due to coagulative necrosis, with formation of necrotic structureless material surrounded with epithelioid and round cells. Caseous material may soften and liquefy forming cold abscess
- Fibrosis or even calcification may occur from the periphery inwards.

CLINICAL PICTURE (Symptoms & Signs)

A. Symptoms:

- Early cases are usually asymptomatic.
- More advanced disease will usually present with infertility associated with symptoms and signs suggestive of PID with or without menstrual disorders.

1. Infertility: genital TB may be the underlying cause in almost 5-10% of infertile women mostly due to; tubal destruction, peritoneal adhesions, or endometrial synechiae.
2. Chronic pelvic pain associated with low grade fever, is a common presentation.
3. Acute lower abdominal pain with high fever may occur if 2ry infection develops on top of a TB pyosalpinx.
4. Abnormal bleeding may occur from ulcerative lesion in the endometrium.
5. 2ry amenorrhoea or oligomenorrhoea may occur in about 10% of cases due to intrauterine synechiae, and/or ovarian destruction.

B. Signs

- Most cases are normal on gynaecologic examination.
- A Tender, fixed, adnexal swelling, with low grade fever, especially in an infertile patient with no previous history of pelvic infection, should be strongly suspicious for TB
- Genital ulcerative lesions: with serpiginous margin and undermined edges, characteristic of TB, may develop on the vulva and cervix, with later scarring or sinus formation.

DIAGNOSTIC INVESTIGATIONS

1. **Chest x-ray** to look for evidence of pulmonary TB
2. **Plain x-ray pelvis:** may detect calcification at tubal sites or pelvic nodes, in chronic cases.
3. **Ultrasonography:** may detect solid adnexal masses with scattered calcification.
4. **H.S.G:** (not done if active T.B or 2ry infection is suspected to avoid flaring up infection): usually diagnosis of TB is made retrospectively when a HSG is performed for infertility. HSG characteristic findings are:
   - The endometrial cavity may be normal, or may be small showing linear filling defects due to intrauterine synechiae.
   - The tubes are usually affected showing beading, pipe-stem appearance, and terminal block with sacculation (Hydrosalpinx).
5. **Endometrial Biopsy:**
   - An endometrial biopsy is usually divided into 2 parts one for histopathology (formalin preserved) and the second for microbiology (saline preserved).
   - PEB (premenstrual endometrial biopsy) obtained from the uterine fundus and cornu and subjected to histopathologic examination is strongly suggestive.
   - Bacteriologic examination (the acid and alcohol fast organism stains by Zeal-Nelsen stain), bacterial cultures, and animal inoculation are more conclusive in some cases. Recently PCR can be used as a specific test for diagnosis of TB
6. **Laparoscopy:**
   - Usually indicated to confirm abnormal HSG findings suggestive of TB in an infertile patient.
   - Performed also in presence of an adnexal mass suspicious of TB detected on pelvic examination or ultrasonography.
   - Biopsies are taken from serosal tubercles and suspicious lesions for bacteriologic and pathologic examination, together with culture from peritoneal fluid in the pouch of Douglas.

N.B.: Tuberculin test is good negative test for exclusion of the disease rather than for establishing the diagnosis.

GUIDELINES IN THE TREATMENT OF FEMALE GENITAL TB

- Even in the absence of symptoms, the disease always calls for active treatment.
- **General treatment;** for anaemia and malnutrition and to increase the general resistance.
- **Antituberculous drugs:** The treatment should last for 18-24 months.
  - Rifampicin, I.N.H. (isonicotinic acid Hydrazide), Ethambutol, or pyrizinamide.
- **Surgical treatment:** Indicated only in cases of:
  1. Adnexal mass not responding to medical treatment.
  2. Recurrent endometrial T.B, one year after treatment.
- Post-operative antituberculous treatment is mandatory.



12 SEXUALLY TRANSMITTED DISEASES

- ***Bacterial STDs***
  - *Gonorrhoea*
  - *Chlamydia Trachomatis*
  - *Chancroid*
  - *Granuloma Inguinale*
- *Lymphogranuloma venereum*
- ***Viral STDs***
  - *HSV*
  - *HPV*
  - *HIV*
- ***Syphilis***

Sexually transmitted diseases (STDs) are infections acquired principally through sexual contact or sexual intercourse. They are among the most common encountered infectious diseases.

Urinary tract infections (UTI) may be triggered by sexual intercourse although the organism is colonizing the woman beforehand. They are thus not considered as STDs.

RISK FACTOR FOR STDS

- Young sexually active females especially< 25 years of age
- Multiple sexual partners
- Lack of sexual hygiene
- Previous or present infection of one STD increases the risk for other STDs

CAUSATIVE ORGANISMS FOR STDS

- **Bacterial:** N. Gonorrhea, C. Trachomatis, H. ducreyi (Chancroid), Klebsiella (Granuloma inguinale), and Gardnerella vaginalis (Bacterial vaginosis).
- **Viral:** Human papilloma virus (HPV), Herpes simplex virus (HSV), Human immune deficiency virus (HIV), Molluscum contagiosum, and Hepatitis B virus (HBV)
- **Spirochetes:** Syphilis.
- **Protozoons:** Trichomoniasis *(see LGT infections chapter 10)*
- **Ectoparasites:** Pediculosis pubis, and scabies

BACTERIAL SEXUALLY TRANSMITTED DISEASES

1. GONORRHEA

Gonorrhea is an STD caused by the Gram negative diplococci **Neisseria gonorrhea**, a bacterium species that involves infection of columnar and transitional epithelium primarily causing gonococcal endocervicitis. The vagina is not involved being lined by squamous epithelium (except in childhood).

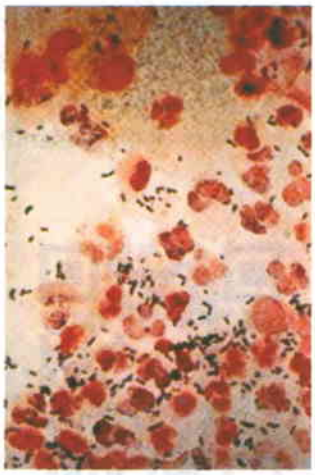

Fig 12-1:

PATHOLOGY

- **Primary sites of infection include:** the cervix (endocervicitis), urethra (urethritis) and Bartholin gland (bartholinitis)
- **Secondary sites of infection include** pelvic inflammatory disease (PID) *(see female upper genital tract infections Chapter 11)*.

- **Other sites of infection:**
  - **In women:** Oropharynx (pharyngitis), and the rectum (proctitis).
  - **In the new born:** Eye (ophthalmitis), and joints (arthritis).
  - **In men:** Urethra (urethritis), prostate (prostatitis), and epididymis (epididymitis).

CLINICAL PICTURE (Symptoms & Signs)

A. Frequently **asymptomatic**

B. In **symptomatic cases;** symptoms usually appear 2 to 5 days after exposure, but may be delayed for up to 30 days. They include;
   - Mucopurulent cervical discharge; as occurs in acute cervicitis.
   - Lower abdominal pain, anorexia, and fever if PID develops
   - Dysuria may occur in both men and women if there is associated urethritis and cystitis.
   - Symptoms of bartholinitis may occur if infection of Bartholin gland occurs
   - Symptoms of pharyngitis and proctitis may be present and should be looked for.
   - Disseminated gonococcal infection (< 3% of cases); may cause arthritis, endocarditis, and septicaemia.
   - Other sequelae of infection include; infertility, and chronic pelvic pain.

DIAGNOSTIC INVESTIGATIONS

A. **Gram stains:** shows Gram negative diplococci within polymorph nuclear leucocytes (PNLs). However presence of vaginal flora can yield false positive results, therefore it is considered a good negative test if NO gram (-ve) diplococci are seen.

B. Culture on Thayer-Martin medium; besides being highly accurate, it is suitable for use for specimens obtained from various body sites as the cervix, rectum, and oropharynx.

C. Nucleic acid amplification test (NAAT): this test uses nucleic acid sequence unique to a specific organism for identification. NAAT has a sensitivity of 96.7% in endocervical specimens.

TREATMENT

Gonococci are fragile organisms that rarely develop resistance to commonly used antibiotics. Treatment of uncomplicated cases is usually sufficient trough single dose therapy:

CDC regimens for treatment of uncomplicated N. Gonorrhoea (2010)

A- Uncomplicated genital, urinary and rectal infections:

Ceftriaxone 250 mg IM in a single dose

PLUS

Azithromycin 1g orally in a single dose

OR

Doxycycline 100 mg a day for 7 daysexcluded

- No test of cure is required.
- Sex partners within 60 days of appearance of symptoms should be evaluated and treated for gonorrhea and chlamydia

B- Disseminated gonococcal infections: Ceftriaxone 1 g IM or IV every 24 hours then cefixime 400 mg orally twice daily to complete 7-14 days of treatment

SEQUELAE OF UNTREATED GONORRHEAL INFECTIONS

- Ascending infection may lead to salpingitis and tubal damage that may predispose to infertility and ectopic pregnancy (*see PID*).
- In the new born exposure during vaginal delivery, from an infected mother with endocervicitis, may cause ophthalmitis, blindness, or serious sepsis.
- In males, it leads to urethritis, prostatitis, epididymitis and repeated transmission to the female.

2. CHLAMYDIA TRACHOMATIS

Chlamydia trachomatis is the second most commonly reported STD in many countries. It is an obligatory intracellular Gram negative bacterium that causes chlamydial genital infection.

Chlamydia grows only intracellular as do viruses. They attack only columnar epithelial cells causing mild inflammatory reaction usually localized to the infected area without deep tissue invasion.

RISK FACTORS: *See risk factors for STDs*

PATHOLOGY

- **Primary sites for infection:** include the endocervix and less commonly the urethra
  - *Chlamydial endocervicitis:* Infection usually starts as endocervicitis, causing mucopurulent discharge milder or similar to that seen with gonorrhea.
- **Secondary sites for infection:** include upper genital infection (PID)
  - *Chlamydial endosalpingitis:* ascending infection occurs insidiously and may later cause PID.
- **Co-infection** with N.gonorrhea is common, and susceptibility to HIV is 3 folds increased.

CLINICAL PICTURE (Symptoms & Signs)

- **Asymptomatic** in almost 75% of cases
- **Symptomatic cases** may present with:
  - *Mucopurulent endocervicitis:* mucopurulent discharge, with oedematous and hyperaemic cervix.
  - *Symptoms of urethritis and pyuria:* in association of negative urine culture is highly suggestive in sexually active women.
  - *Fever and lower abdominal pain* suggest PID; which may occur in up to 40% of women with untreated chlamydia. Infection is more insidious and protracted than that seen with gonococcal PID.

DIAGNOSTIC INVESTIGATIONS

A. **Microscopic examination** of endocervical secretions following saline preparation typically reveals 20 or more leucocytes by HPF.

B. **Culture:** from endocervix is a highly specific technique although expensive, and results are difficult to standardize, thus limiting its use.

C. **Nucleic acid amplification tests (NAAT):** This sensitive test amplifies organism-specific nucleic acid sequences using polymerase chain reaction (PCR). Endocervical sampling in women has sensitivity of 85% and specificity of 99%.

TREATMENT

CDC regimens for treatment of uncomplicated cases of urethritis and cervicitis (2010)

Azithromycin: I g orally once (4 tablets 250 mg each), suitable during pregnancy

OR

Doxycycline: 100 mg orally twice daily for 7 days (not used in pregnancy)

- Abstinence from sexual intercourse for 7 days from treatment start.
- Test of cure is not recommended

SEQUELAE OF UNTREATED CHLAMYDIAL INFECTION

- Ascending infection may lead to chlamydial salpingitis and tubal damage that may predispose to ectopic pregnancy and infertility (*see PID*).
- During labour the vaginally delivered neonate may develop chlamydial conjunctivitis in 50% of cases and late onset pneumonitis in 10%. Premature delivery and postpartum endometritis are also associated problems.

3. CHANCROID

Chancroid is a genital ulcerative disease, caused by the Gram negative coccobacillus **Haemophilus ducreyi**. The disease is generally rare, but may occur as outbreaks of infection.

Epidemiology: Trauma facilitates entry of coccobacilli into the vulval mucosa with an incubation period of 3-5 days. Co-infection with HIV is common, while associated syphilis or herpes is found in 10% of cases.

Clinical picture: Lesions begin as small papules that later break into painful genital vulval ulcers in 2-3 days that may be accompanied with inguinal lymphadenopathy.

Diagnostic investigations: Cultures and PCR for chancroid are not readily available in many centers. Probable diagnosis is made when painful genital ulcers are present without evidence of herpes, or syphilis.

Treatment (CDC 2010):

- *Azithromycin: 1g orally once* **OR**
- *Ceftriaxone 250mg IM single dose.*

4. GRANULOMA INGUINALE

It is a genital ulcerative disease, caused by a gram negative bacterium Klebsiella granulomatis.

Epidemiology: The disease is endemic in some countries as India and Africa.

Clinical picture: Painless friable ulcerative genital lesions with inguinal swelling but without lymphadenopathy.

Diagnostic investigations: Scrapings from the ulcers show pathognomonic cells known as Donovan bodies.

Treatment (CDC 2010):

- *Doxycycline* 100 mg orally twice a day for at least 3 weeks and until all lesions have completely healed **OR**
- *Azithromycin* 1 g orally once per week for at least 3 weeks and until all lesions have completely healed.

5. LYMPHOGRANULOMA VENERUM

Lymphogranuloma venereum (LGV) is caused by ***C. trachomatis serotypes L1, L2, and L3***, producing local and regional ulcerations and destruction of genital tissues.

Epidemiology: LGV is a rare disease that is endemic in some parts of Africa and India.

Clinical picture: Primary genital ulcers appear 3-5 weeks after exposure and resolve spontaneously. 2 to 6 weeks later tender 2ry unilateral inguinal lymphadenopathy develops that can break into ulcers.

Diagnostic investigations: Complement fixation tests with titers >1/64 indicate active infection.

Treatment (CDC 2010): Doxycycline 100 mg orally twice a day for 21 days.

VIRAL SEXUALLY TRANSMITTED DISEASES

1. HERPES SIMPLEX VIRUS

Herpes simplex virus (HSV) is a double strand DNA virus of two main types:

- ***HSV 1:*** primarily transmitted by non-venereal routes particularly following contact with infected saliva. It is responsible for facial and oropharyngeal infections like herpetic gingivostomatitis and the common cold sore or fever blister.
- ***HSV 2:*** is usually transmitted by venereal route to the sexual partner, or maternally to the new born during vaginal delivery. It is responsible for genital herpes and neonatal infections, and has been linked epidemiologically with carcinoma of the cervix.

CLINICAL PICTURE (Symptoms & Signs)

- **The first attack:** is the most severe with pain, vulvitis, Lymphadenopathy, and discharge. It occurs after an incubation period of around 21 days, and is manifested by multiple painful anogenital vesicles or painful ulcers with erythematous base that usually resolve after 3-4 weeks.
- **Subsequent attacks:** are normally shorter and less severe.

DIAGNOSTIC INVESTIGATIONS

- **Culture of serum** collected from vesicles by aspiration or by swabbing base of the ulcer.
- **Serum anti-HSV antibody** levels are increased with both type-1, and type-2 infection.

TREATMENT

- Treatment is mainly supportive with analgesics
- Treatment of any associated secondary infection.
- First attack: Acyclovir 400 mg orally three times a day for 7–10 days. Treatment can be extended if healing is incomplete.
- Subsequent attacks: Acyclovir 400 mg orally three times a day for 5 days.

2. HUMAN PAPILLOMA VIRUS (HPV)

The genital virus in this double stranded DNA family is responsible for a variety of mucocutaneous genital lesions, commonly resulting in genital warts (condyloma accuminata). HPV is also associated with female LGT cancers especially cervical intraepithelial neoplasia (CIN).

EPIDEMIOLOGY:

- **Types of HPV:** HPV types 6 and 11 are the usual causes for visible external warts. HPV types 16, 18, 31, 33, and 35 have all been strongly associated with CIN and with external genital squamous intraepithelial neoplasia
- **Prevalence:** In the USA 50% to 75% of sexually active men and women acquire HPV at some time of their lives. HPV are associated with other STDs in almost 25% of cases.
- **Mode of transmission:**
  - *Contact with infected male partners:* yield a risk of 60-80% for contracting genital warts, with an incubation period (IP) ranging from 6 weeks to 18 months (mean 3 months).
  - *Maternal to fetal transmission;* very rare (1:1000), through transplacental, intrapartum, or postnatal routes. Foetal affection may cause neonatal and juvenile respiratory papillomatosis.

CLINICAL PICTURE (Symptoms & Signs)

- **Asymptomatic:** genital HPV are frequently asymptomatic.
- **Skin lesions** (genital warts or condylomata acuminate): appear on the vulva and peri-anal region as warty like, scattered and multifocal lesions. Secondary infection will result in an irritating itchy sensation.

DIAGNOSIS OF HPV

- **Direct inspection:** easily diagnose overt warts. Biopsy is rarely required, only if in doubt.
- **Pap smear test:** demonstrates the pathognomonic koilocytes or hallo cell exfoliated from the cervix, designated as low-grade squamous intra-epithelial lesions (LSIL).
- **Colposcopy:** on staining with 1% acetic acid lesions appear as flat, small, acetowhite areas, with vascular punctuation or mosaicism.
- **HPV DNA test**: is a diagnostic procedure that uses a small plastic spatula to collect material from the cervix and vagina. This sample allows identification of 14 high risk types of HPV, including HPV 16 & HPV 18.

TREATMENT OF EXTERNAL CONDYLOMAS (CDC 2010)

- **Podofilox** 0.5% solution or gel administered by the patient
- **Destruction:** using cryotherapy, Podophyllin resin 10%–25%, Trichloroacetic acid (TCA) or Bichloroacetic acid (BCA) 80%–90% or surgical removal.
- **Barrier contraception** is advised during treatment.

TREATMENT OF HPV RELATED PRECANCEROUS CONDITIONS (CDC 2010)

- **Destruction of abnormal cells** via colposcopy using laser ablation or cryotherapy.
- **Surgical excision** by Loop electrode excision of the transformation zone (LEETZ)

N.B: Recurrence and relapse are common in immune-compromised patients, and whenever treatment of infected male partners is neglected.

N.B: Vaccination against HPV was introduced in the USA in 2006. It is recommended in young girls, years before starting sexual activity. This will hopefully decrease infection and subsequent development of CIN.

3. HUMAN IMMUNODEFICIENCY VIRUS (HIV)

HIV was first identified in 1981 as a retrovirus that causes acquired immunodeficiency syndrome (AIDS). The syndrome is responsible for severe deficiencies in cell mediated immunity, leading to unusual opportunistic infections, malignancy, and eventually death.

HIV has a variable and long asymptomatic latent period that ranges from 2 months to17 years in which patients are asymptomatic carriers. The mean age at diagnosis of AIDS infection is around 35 years.

EPIDEMIOLOGY

- HIV is worldwide. Men are affected more than women, but prevalence in women seems to be increasing.
- Most of infections are caused by HIV type I. HIV type II is rare and less virulent.
- Modes of transmission:
  - **Horizontal transmission:** from one sexual partner to another through micro-abrasions of the mucous membranes or through skin penetration by needles.
  - **Vertical transmission:** from an infected mother to the fetus by trans-placental route.

HIGH RISK POPULATIONS INCLUDE:

- Male homosexuals and bisexuals and female heterosexual consorts of infected men
- Intravenous drug users, recipients of infected blood, or concentrated blood products
- Infection with other STDs
- Neonates born to infected women

CLINICAL PICTURE (Symptoms & Signs)

1. **Asymptomatic:** 80% of HIV infected cases remain asymptomatic for around 10 years
2. **Initial HIV exposure:** fever, sweats, headache, pharyngitis, myalgia, and arthralgia.
3. **AIDS is the final stage**: with associated generalized lymphadenopathy, Kaposi sarcoma, opportunistic infections, malaise, diarrhea, and weight loss.

DIAGNOSTIC INVESTIGATIONS

1. **ELIZA screening:** for individuals at risk detects > 95% of patients within 3 months of infection.
2. **Western blot analysis:** Confirmatory test for ELIZA positive cases.
3. **Viral load testing for HIV plasma RNA:** if acute retroviral syndrome is suspected.

TREATMENT (CDC 2010)

1. Immediate medical care and referral to specialized centers.
2. Prophylaxis for opportunistic infections by vaccination against pneumococcal infection, Hepatitis B, measles, and haemophilus influenza B.
3. There is now a great development in antiretroviral therapy as well as vaccination against HIV that helped in reducing the disease prevalence and improved prognosis.

SYPHILIS

Syphilis is a systemic STD caused by the spirochete Treponema pallidum.

EPIDEMIOLOGY:



Fig 12-2:

- After the introduction of Penicillin treatment regimens, by the second half of the 20th century, the disease showed a sharp decline in prevalence in most developed countries. However, the last 2 decades have shown an increase in the incidence of infection concomitant with the rise in the incidence of HIV.
- Modes of transmission: Syphilis can be transmitted either by Treponema pallidum
  - A. Direct contact with an infected lesion, or contact with infected blood
  - B. Intrauterine vertical transmission from mother to fetus (congenital syphilis).
- Once the organism reaches circulation, there is a rapid systemic spread via the blood and lymphatics to reach different organs.

CLINICAL PICTURE (Symptoms & Signs)

1. **Primary syphilis:** the initial lesion is a painless, ulcerated, **hard chancre,** usually on the external genitalia, although vaginal and cervical lesions may be detected. The IP ranges from 10-90 days. The primary lesion usually resolves in 2-6 weeks.
2. **Secondary syphilis:** in untreated patients this chancre is followed in 6 weeks to 6 months by a secondary or bacteremic stage with infection of the skin and mucous membranes that usually resolve in 2-6 weeks.

- Mucous patches; maculo-papular rash of the palms, soles, and mucous membranes.
- Condyloma latum (moist flat confluent plaques), and generalized lymphadenopathy.

3. **Tertiary syphilis:** will affect approximately 33% of untreated patients with multiple organ involvement. This is a non-contagious but highly destructive phase of syphilis.
   - Aortitis (the basic lesion); with endarteritis, aortic aneurysm, and aortic insufficiency.
   - Tabes dorsalis, optic atrophy, meningovascular syphilis, and gummatous lesions (gummas are nodular lesions characterized by granulomatous inflammation that may occur in any organ).
4. **Congenital syphilis:** due to materno-fetal transmission may cause still birth, nonimmune hydrops, jaundice, infant hepatosplenomegaly, and skin rash. Identification of and treatment of pregnant women with diagnosed syphilis is the mainstay of prevention for congenital syphilis.

N.B.: Latent infection may occur in infected individuals with no clinical manifestations of the disease

DIAGNOSTIC INVESTIGATIONS

- **Dark field examination:** of fresh specimens obtained from tissue exudates and mixed with saline detects spirochetes in the primary and secondary stages of the disease.
- **Serologic tests:** In primary disease serology may be negative until individuals have enough time to mount an immune response. In secondary and tertiary syphilis serologic test are helpful in diagnosis.
  1. **Non treponemal tests:** Rapid Plasma Reagin (RPR) and Venereal Disease Research Laboratory (VDRL) measured in titers, usually correlate with disease activity. These tests may give false positive results being positive in a variety of other medical conditions.
  2. **Treponemal antibody tests:** Fluorescent Treponemal Antibody Absorption (FTA-ABS) and T. pallidum Particle Agglutination (TP-PA) can remain positive for life although may turn negative with early treatment. These tests are specific and used to confirm the diagnosis

TREATMENT (CDC 2010)

A. Early disease; primary, secondary, early latent and asymptomatic recent contacts:
- *Benzathine penicillin G* 2.4 million units IM in a single dose
- *Doxycycline* 100 mg orally twice daily for 2 weeks in non-pregnant patients with penicillin allergy

B. Late disease: late latent syphilis or tertiary syphilis (not including neurosyphilis)
- *Benzathine penicillin* G 2.4 million units IM every week for 3 weeks
- *Doxycycline* 100 mg orally twice daily for 4 weeks in non-pregnant patients with penicillin allergy

C. **Neurosyphilis:**
- *Aqueous crystalline penicillin* G 18-24 million units/day IV infusion for 10-14 days.
- *In pregnant or penicillin sensitive cases:* Penicillin desensitization.

D. **Congenital syphilis:** infants and children with history of inadequate maternal treatment
- *Early disease:* Aqueous crystalline penicillin G 50.000 unit/kg IM single dose up to the adult dose.
- *Late disease:* Aqueous crystalline penicillin G 50.000 unit/kg IM up to the adult dose every week for 3 weeks.

• All patients should be evaluated clinically and serologically at 6 months, 1 year and 2 years (for latent & tertiary cases.

13 INFERTILITY AND ART

- *Male Infertility*
- *Female infertility*
- *Assisted Reproduction*
- *Coital dysfunction*
- *Unexplained Infertility*

OVERVIEW

Infertility (or subfertility) is the term that describes **failure** of a couple to achieve **conception** after one year of regular sexual intercourse, without using any method of contraception.

Almost **15%** of couples may suffer infertility after the first year of marriage. Problems may be found either in the **female** (50-60%) or in the **male** partner (30-40%). In about **25%** of cases problems will be found in **both partners** at the same time.

Fecundability is the monthly probability of pregnancy among fertile couples. It ranges around 20-25% per cycle with unprotected intercourse.

The **cumulative pregnancy rates** increase by time to reach up to **50%** in 6 months, and up to **85%** after one year of regular marital life.

- **Infertility** may be either primary or secondary;
  - ***Primary infertility:*** pregnancy has never been achieved before.
  - ***Secondary infertility:*** history of previous one or more pregnancies, but failure to conceive again.

Investigations for infertility should be carried out on both the male and the female partners, and should cover all the possible factors that may be responsible for delaying pregnancy in each of them.

In the female, investigations include ovarian, uterine, tubal, peritoneal, and cervical factors.

In the male, evaluation always starts by a semen analysis, and if abnormal further tests and clinical evaluation will be considered.

Pregnancy can be **achieved** in nearly **50-60%** of infertile couples after performing thorough investigations, and receiving appropriate medical and or hormonal treatment for both partners.

Assisted reproductive techniques (ART), will be indicated in cases with severe male factor, severe tubal and peritoneal factors, and in some cases of unexplained infertility. ART includes;

- ***IUI:*** Intra Uterine Insemination
- ***IVF-ET:*** In Vitro Fertilization & Embryo Transfer, in which Intra Cytoplasmic Sperm Injection **(ICSI)** is the most commonly applied technique

FACTORS RESPONSIBLE FOR INFERTILITY

- Male factor (30-40%)
- Female factor (50-60%)
- Coital dysfunction
- Unexplained Infertility (10-15%)

MALE INFERTILITY

It is estimated that 2% of men demonstrate issues with their seminogram. The male is responsible alone for up to 40% of infertility cases, and should be evaluated separately and thoroughly in every couple presenting with infertility, before going into invasive female investigations.

AETIOLOGY

A) Abnormal Spermatogenesis

1. *Increased Scrotal temperature:* (scrotal temperature should be 1°C less than body temperature):
   - Undescended testes
   - Varicocele
2. *Genetic Causes:* as in micro-deletion of the Y chromosome
3. *Drug Induced:* as anti-hypertensive drugs, anti-epileptics, psychotropic agents, prolonged antibiotic administration, and chemotherapeutic agents

B) **Failure of Sperm Transport** through the Vas deferens:

1. *Bilateral Epididymeal Obstruction:* Gonorrheal inflammation is the commonest cause.
2. *Bilateral Vas Ligation:*
   - Intended: as in male sterilization.
   - Iatrogenic: rarely faulty ligation during bilateral inguinal hernioplasty operations
3. *Immotile Cilia Syndrome:* All sperms are immotile.

C) **Failure of Semen Deposition:** (due to ejaculatory dysfunction):

- Impotence
- Premature ejaculation
- Retrograde ejaculation, and an-ejaculation

DIAGNOSIS OF MALE FACTOR

A) History:

- Related operative procedures: repair of inguinal hernia or varicocele.
- Infection by STDs; as gonorrhea, chlamydia, etc...
- Coital problems; as erection and ejaculation disorders
- Heavy smoking; due to decreased oxygen tissue perfusion
- Chronic drug intake; as antihypertensive, antiepileptic, psychotropic drugs, etc...

B) Clinical Examination:

- To exclude: undescended testicles, testicular masses, and small testes.
- To detect: the presence of hydrocele, and/or varicocele, and their extent.

C) Special Investigations:

1. *Semen Analysis:* should be obtained from all males during infertility investigations. Samples are collected by masturbation after 3-4 days of abstinence from intercourse.
2. *Hormonal assay:* FSH, LH, Prolactin, Testosterone,
3. *Doppler US:* on the testicles to detect varicocele
4. *Testicular biopsy:* to differentiate between defective spermatogenesis and obstructive disorders
5. *Chromosomal studies:* to diagnose genetic disorders

CRITERIA FOR NORMAL SEMEN ANALYSIS (WHO 2010)

Parameter	Normal Criteria
Volume	2 ml or more
Count	15 million / ml or more
PH	7.2 – 7.8
Motility	50% or more with forward progressive motility
Morphology	30% or more with normal morphology

Term	Definition
Aspermia	Absence of semen
Azoospermia	Zero sperm count
Oligospermia	Count < 15 million / ml
Asthenospermia	< 50% with forward progressive motility
Teratospermia	> 70% abnormal forms

MANAGEMENT OF MALE INFERTILITY

Improvement in poor semen parameters may take from 3-6 months of appropriate therapy

A. **Stop** smoking (to improve oxygenation).
B. Use of **Multivitamins** and **Antioxidants,** are thought to improve sperm count and motility.
C. **Treat erection disorders;** using medications (as Viagra), or synthetic prosthesis.
D. **Shift** to other types of antihypertensive and psychotropic drugs if they were a cause.
E. **Hormonal treatment:** CC & HMG are useful in cases of defective spermatogenesis.
F. **Surgical treatment:**
   - Ligation of varicocele: may improve sperm count and motility in some cases.
   - Artificial prosthesis: in some erection disorders
G. **Assisted Reproductive Techniques (ART):** ***see later for details***
   a. ***Intrauterine insemination (IUI):*** It is indicated in cases with;
      - Mild oligospermia
      - Coital dysfunction and erection disorders.
      - Unexplained infertility.
   b. ***In-Vitro Fertilization and Embryo transfer (IVF/ET):*** suitable for
      - Mild male factor or
      - Unexplained infertility (see details in ART).
   c. ***Intra Cytoplasmic Sperm Injection (ICSI/ET):*** suitable for severe male factor as
      - Severe oligoasthenospermia.
      - Obstructive Azoospermia; sperms recovered directly by testicular sperm aspiration.

N.B.: Cases with *genetic disorders* & *obstructive azoospermia* carry the poorest prognosis.

FEMALE INFERTILITY

Females are **responsible alone** for delayed conception in nearly **50%** of cases. **Anovulation, tubal damage**, and **peritoneal adhesions** are the most frequently encountered causes. **Uterine** and **endometrial** factors are less common, while **cervical factor** is rare. In **10-15%** of cases no identifiable cause will be reached in either partner referred to as **unexplained infertility**.

FACTORS CAUSING FEMALE INFERTILITY

1. OVARIAN FACTOR

Anovulatory disturbance is the most commonly encountered factor for female infertility being the primary cause in almost 40% of cases, including;

a. ***PCOS:*** the most common cause of anovulation in the childbearing period
b. ***Hyperprolactinaemia:*** due to stress, drug induces, or pituitary hyperplasia and/ or adenomas
c. Severe ***thyroid disorders*** (hyper and hypo thyroidism)
d. ***Premature ovarian failure*** and insufficiency (POF & POI)
e. Severe ***stress***, exhausting ***exercise***, and rapid excessive ***weight loss***
f. ***Drug induced:*** OCPs, GnRH agonists, gestagens, chemotherapy, opiates, barbiturates, etc...

- **Luteal phase defect (LPD):** due to inadequate progesterone sufficiency causes failure of implantation and recurrent early pregnancy loss (see chapter 8)
- **Age of the female** is the single most important factor in anovulatory infertility, where fertility declines rapidly after the age of 35 years and mor sharply after the age of 40 years
- **N.B.:** See amenorrhoea and chronic anovulatory disturbances (chapters 7 and 8)

II. TUBAL AND PERITONEAL FACTORS

Tubal and Peritoneal factors may be responsible for almost **30** % of female infertility.

- ***The following mechanisms may be responsible:***
  - *Impaired ovum pick up;* due to fimbrial destruction and / or peritubal adhesions.
  - *Impaired oocyte or embryo transport;* due to tubal obstruction.
  - *Tubal epithelial damage;* with absent nourishment to the oocyte during transport

1. Salpingitis, Salpingo-oophoritis, and Pelvic Peritonitis: causing tubal damage & pelvic adhesions
- STDs: Gonococcal and Chlamydial infections causing *endosalpingitis*.
- Puerperal and post abortive infections: lymphatic spread casing *perisalpingitis*
- Chronic specific infections as T.B. : causing *interstitial salpingitis*
- Chronic non specific infection especially if it leads to *tubo-ovarian abscess*.
- Extension from appendicitis, ruptured gall bladder, perforated peptic ulcer.
- Sepsis following pelvic surgery.

2. Mechanical Obstruction: causing compression, stenosis, or overstretching of the tubes
- Large multiple ISM & SSM.
- Large ovarian and adnexal masses

3. Surgical Trauma (Iatrogenic): leading to direct tubal damage or peritubal adhesions
- Salpingectomy (ectopic pregnancy), tubal ligation (for sterilization), or tuboplasty.
- Gynaecologic surgery; after myomectomy, and ovarian cystectomy.
- Pelvic surgery; as during surgery for intestinal obstruction and appendectomy.

4. Pelvic Endometriosis: extensive disease may cause pelvic and peritubal adhesions.

III. UTERINE AND ENDOMETRIAL FACTORS

Uterine and endometrial factors may be responsible for **10-15%** of female causes of infertility, mostly via the following mechanisms;

- Impairment of blastocyst implantation within the endometrial cavity
- Bilateral cornual obstruction of tubal ostea
- Interference with transport of sperms through the endometrial cavity

1. **Congenital Uterine Anomalies:**
   - Septate and Bicornuate uterus (infertility and or RPL)
   - Uterine hypoplasia and or aplasia (amenorrhoea and infertility)
2. **Uterine Leiomyomas:** especially large and multiple ISM and SMM
3. **Uterine Polyps:** SMF polyps or endometrial polyps.
4. **Intrauterine Synechae** predisposed to by;
   - Over curettage of basal endometrial layer (Ashermann's syndrome)
   - Acute septic endometritis (puerperal, post abortive sepsis, and IUD associated)
   - Chronic specific infections (e.g.; T.B. endometritis)

IV. CERVICAL FACTOR

Abnormalities of cervical mucus that affect its amount, quality, and constituents may impair sperm transport through the cervical canal making it incapable of fertilization, via the following mechanisms;

- Changes in physical and chemical properties, e.g.; scanty amount or increased viscosity
- Infection and presence of pus cells, e.g.; acute and chronic endocervicitis
- Presence of anti-sperm antibodies in cervical mucus
- Destruction of mucus secreting glands; by conization or excessive cauterization
- Elongation of cervical canal by a cervical fibroid may rarely be an underlying factor

INVESTIGATIONS FOR FEMALE INFERTILITY

In the **apparently normal couple**, investigations for infertility do not usually start before **6 months to 1 year** of regular marital life without contraception. **Earlier investigations** may be started whenever;

- *Age* of the female partner is *above 35 years*
- History reveals marked *menstrual disorders*
- History strongly suspicious of *uterine, tubal, or peritoneal pathology*
- Suspicion of a severe *male factor* especially in older age males.

Female evaluation usually starts by a detailed **history**, general and local **examination**, pelvic **US**, and a **hormonal assay**. If no apparent cause was revealed, and the male **semen analysis** was normal, then more invasive tests as **HSG, hysteroscopy,** and **Laparoscopy** will be required to evaluate **uterine**, **tubal** and **peritoneal factors**.

In 10-15% of cases investigating both partners by standard tests may not reach a cause, a condition known as **unexplained infertility** (see later)

I. ASSESSMENYT OF ANOVULATORY DYSFUNCTION

1. ***Basal Body Temperature (BBT) Chart:*** reveals absence of a biphasic BBT chart
2. ***US monitoring of ovulation:*** serial TVS revealing inadequate growth of follicles and failure of ovulation
3. ***Urinary LH kits:*** reveal absence of an LH surge at mid-cycle
4. ***Mid-luteal serum PRG:*** revealing low levels < 5 ng/ml in anovulation and < 10 ng/ml in LPD
5. ***Premenstrual endometrial biopsy (PEB):*** done as office procedure using a suction Pipelle or Novak curette revealing proliferative endometrium in the premenstrual period instead of secretory endometrium.

II. ASSESSMENT OF UTERINE AND ENDOMETRIAL FACTORS

1. PELVIC ULTRASOUND (US): see imaging in gynaecology

TAS and **TVS** are considered the *gold standard* in evaluation of uterine and endometrial factors. Introduction of **3D US** and Saline Infusion Sonography **(SIS)**, has improved the accuracy of US diagnosis:

- Congenital uterine anomalies; as septate and bicornuate uterus (TVS & 3D US)
- Uterine leiomyomas: (TAS, TVS, & 3D US)
- SMM, SMF polyp, and endometrial polyps (3D US & SIS).
- Intra uterine adhesions (SIS)
- Associated adnexal masses (TAS & TVS)

2. HYSTEROSALPINGOGRAPHY (HSG): see imaging in gynaecology

HSG entails injection of a radio-opaque dye within the endometrial cavity through the cervical canal, to visualize the endometrial cavity and the fallopian tubes.

HSG is considered the gold standard in infertility evaluation as it allows diagnosis of;

- Mullerian anomalies: as septate, bicornuate, and unicornuate uterus.
- Endometrial pathology: as polyps, SMM, and intrauterine adhesions
- Diagnosis of tubal obstruction: with delineation of its site, nature, and bilaterality
- Diagnosis of peritubal and peritoneal adhesions, in the post dye injection control film.

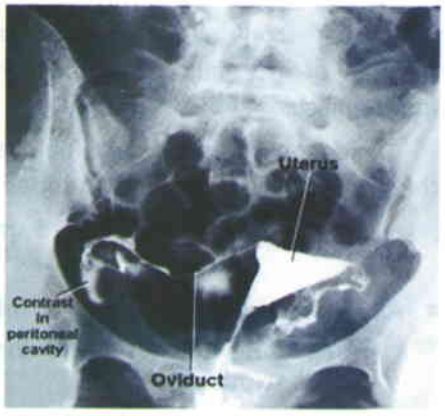

Fig 13-1: HSG showing normal uterine cavity with no filling defects, and bilateral tubal patency

3. HYSTEROSCOPY: see imaging in gynaecology

Office hysteroscopy, done as an outpatient procedure, allows direct visualization of the uterine cavity, using an optic lens, a light source, and a distending medium (saline, or glycine). Minor surgical procedures can be also performed via hysteroscopy.

III. ASSESSMENT OF TUBAL AND PERITONEAL FACTORS

1. HYSTEROSALPINGOGRAPHY (HSG): see imaging in gynaecology

HSG done to investigate uterine and endometrial factor at the same time is considered a cornerstone in investigating tubo-peritoneal factors (see before).

- **Normal HSG:**
  - Bilateral tubal patency; normal tubal caliber and free spill of the dye
  - Absence of significant pelvic adhesions; free dispersion of the dye in the pelvis.
- **Abnormal HSG:**
  - Unilateral or bilateral, distal or proximal tubal obstruction.
  - Presence of hydrosalpinx; distal tubal obstruction with dye filled sacculation.
  - Suspected pelvic adhesions; loculation of the dye in the pelvis in control film.
- **Advantages of HSG in Infertility**
  - Easy to perform and does not require general anaesthesia or operating theatre
  - Investigates both uterine and tubal factors at the same time.
  - Accurately detects the site of tubal obstruction (cornual, proximal, distal, etc...)
  - High suspicion in diagnosis of T.B. endometritis and T.B. salpingitis.
  - Improves pregnancy rates in the first 3 months in cases of unexplained infertility
- **Disadvantages and Complications associated with HSG:** generally rare, but may include
  - Allergic reactions with shock and collapse
  - Infection; causing flaring up of endometritis, salpingitis, and rarely peritonitis.
  - Oil embolism and oil granuloma.

B. LAPAROSCOPY AND DYE INJECTION: see endoscopy in gynaecology

Laparoscopy allows direct visualization of the pelvic peritoneum, pelvic organs, and external surface of the fallopian tubes through an optic lens and a light source, introduced via the umbilicus.

Injection of methylene blue dye through the cervix, allows for observing its spillage through the fimbrial ends of fallopian tubes to ensure tubal patency, and evaluate its ciliary function.

The procedure is performed under general anaesthesia.

- **Advantages of laparoscopy in infertility;**
  - Accurate diagnosis of fimbrial, peritubal, and pelvic adhesions.
  - Diagnosis of pelvic pathology as endometriosis, PID, and T.B. peritonitis.
  - Diagnosis of ovarian pathology as PCO and endometriomas.
  - Operative laparoscopy can be used in lysis of pelvic adhesions, treatment of pelvic and ovarian endometriosis, and ovarian drilling in PCO.

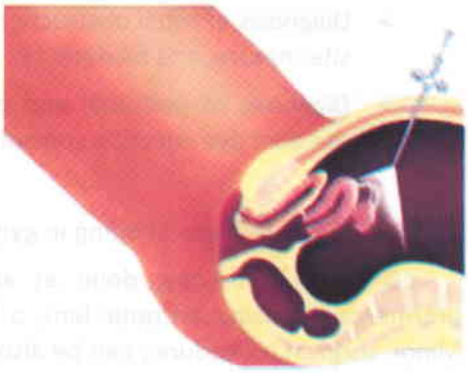

Fig 13-2: Diagnostic laparoscopy

IV. ASSESSMENT OF CERVICAL FACTOR

A. Assessment of the Physical properties of the Cervical mucus

Preovulatory	Postovulatory
– *Thin , profuse, and watery* – *Acellular and Alkaline* – *Positive thread test (stretch 6-10 cm)* – *Maximum Ferning when dried under microscopy*	– *Thick and scanty* – *Cellular* – *Negative thread test (threads break < 6.0 cm)* – *Minimal Ferning when dried under microscopy*

B. The Post Coital Test (PCT): rarely performed nowadays

- Examination of the cervical mucus 6-10 hours after intercourse, at time of ovulation, to assess the number of living and dead sperms and presence of leucocytes, affecting sperm motility within the cervix (normally> 20 progressively motile sperms / HPF)
- An abnormal PCT may point to hostile cervical mucus, or presence of antisperm antibodies, yet its value has been recently questioned being of limited prognostic value.

HORMONAL ASSAYS COMMONLY REQUIRED FOR INFERTILITY

- **Serum FSH & LH** (day 1-3 of cycle): abnormal LH/FSH ratio in PCOS
- **Urinary LH assays:** positive urinary LH denotes impending ovulation (24 hours)
- **Mid luteal Serum PRG:** usually day 21 of the cycle (> 10ng/ml denote ovulation)
- **Serum PRL:** (N: 2.8-28 ng/ml); high levels denote hyperprolactinaemia
- **Serum androgen levels:** (total and free T, DHEA) in cases with hirsutism and PCOS.
- **Thyroid function tests:** (TSH, T3, T4) to detect major thyroid disorders

COITAL DUSFUNCTION AFFECTING FERTILITY

Coital dysfunction may prevent penetration and deposition of male sperms into the vagina. It may also affect the frequency and efficiency of sexual intercourse

a. ***Superficial Dyspareunia:*** painful or difficult coitus at the level of the vulva and lower vagina.

b. ***Vaginismus:*** violent reflex spasm of levators ani, gluteus muscle, and adductors of the thigh on any attempt at intercourse.

c. ***Male Erectile disorders:*** as impotence, and premature ejaculation, etc...

N.B.: Effluvium seminis (excessive escape of the seminal fluid from vagina after intercourse) is a common complaint that does not really affect or delay fertility.

UNEXPLAINED INFERTILITY

Unexplained infertility is a diagnosis of exclusion. It may be present in almost 15% of infertile couples when all standard male and female infertility investigations fail to detect a possible cause. Almost 60% of these couples will conceive within 3 years without treatment.

Possible Contributing Factors

- Immunological and psychological factors
- Defective sperm fertilization capacity
- Decreased ovarian reserve: decreased number and quality of oocytes (day 3 FSH level > 10 mIU/ml, and low AMH < 1ng/ml).
- Occult cervical infection.

MANAGEMENT OF FEMALE INFERTILITY

After the cause of female infertility has been apparently revealed, treatment will be initiated according to the cause discovered.

INDUCTION OF OVULATION FOR ANOVULATORY INFERTILITY

A. ORAL DRUGS *(for details see chapters 7,8)*

1. **Clomiphene citrate (CC):** is the drug of choice for anovulatory infertility. It acts by blocking E2 receptors and inducing pituitary FSH production stimulating follicular growth and maturation. It is given in a dose of 50-200 mg/daily/5 days starting day 3, 4, or 5 counted from the 1st day of the LMP.
2. **Tamoxifen:** a weak anti-oestrogen that acts by blocking E2 receptors as CC, with increased pituitary FSH stimulating follicular growth and maturation. It is given in a dose of 10-40 mg/daily/5 days, staring day 3, 4, or 5 counted from 1st day of LMP.
3. **Letrozole:** an aromataze inhibitor that blocks conversion of testosterone to osterogen, leading to increased pituitary FSH production and stimulation of follicular growth and maturation.

B. I.M. GONADOTROPHINS

1. **Human Menopausal Gonadotrophins (HMG):** repeated doses each containing (75 IU FSH and 75 IU LH) given according to the size of growing follicles by US and / or serum oestrogen levels
2. **Purified HMG:** repeated doses each containing (75 IU FSH and 1 IU LH), suitable for PCOS cases with high endogenous LH to avoid severe OHSS
3. **Synthetic HMG:** repeated doses each containing (75 IU FSH), suitable for cases of PCOS and for protocols of induction in IVF / ICSI cases to induce controlled stimulation of multiple follicles for recruitment

C. Human Chorionic Gonadotrophins (hCG):

5000-10000 IU if hCG are given IM as one shot to facilitate rupture of mature Graaffian follicles as evidenced by US size > 20 mm or high oestrogen levels. Injection is withheld if a large number of follicles has reached maturity and > 20 mm size to avoid severe OHSS in cases not undergoing ICSI procedures.

D. SURGICAL INDUCTION OF OVULATION

This can be achieved through laparoscopic ovarian drilling (LOD), a procedure in which small punctures are made within the ovary using a diathermy needle. It is assumed that this may decrease intra-ovarian androgens resulting in spontaneous ovulation.

- *Indications*; PCOS cases that are either CC or HMG resistant, or easily develop OHSS
- *Side effects and limitations:* The use of LOD is hindered by;
  - ❖ It's time limited effect on ovulation (3-6 months).
  - ❖ It's potential for creating ovarian damage compromising ovarian reserve.
  - ❖ It's potential for creating periovarian, and peritubal adhesions (tubo-peritoneal factor).

ADJUVANT DRUGS USED IN ANOVULATORY INFERTILITY:

- ➢ *Drugs for Hypeprolactinaemia:*
  - Bromocriptine: 2.5 mg, 1-2 tablets daily, or
  - Cabergoline: 0.5 mg, 1/2 tablet twice weekly, until PRL levels drop to normal

- *Insulin Sensitizers:* Metformin:500-1000 mg daily in cases with insulin resistance (see PCOS)
- *Thyroid extract:* Eltroxin 50-150 ug daily in cases of hypothyroidism
- *Corticosteroids:* in cases of adrenal insufficiency and some cases of PCOS.

N.B.: A combination of drugs can be used for induction of ovulation according to different protocols that may use ORAK drugs only or in Combination with IM HMG and hCG, in addition to one or more of adjuvant drugs.

N.B.: Patients with class 2 & 3 obesity will benefit from significant weight reduction before starting protocols of induction, this will help in better follicular stimulation with lower doses and combinations of drugs and less side effects and OHSS.

MANAGEMENT OF TUBAL AND PERITONEAL FACTORS

Tubal occlusion can usually be anatomically corrected by various surgical techniques however restoration of tubal function 2ry to tubal damage could not be easily achieved.

a. Laparoscopic Procedures:

- **Lysis of Peritoneal Adhesions (Adhesiolysis):** Lysis of mild thin inflammatory peritubal and periovarian adhesions, using Diathermy cauterization or Laser ablation, can be successfully achieved via laparoscopy. It improves ovum pick up mechanism and may restore fertility as long as tubal function and patency are ensured.
- **Excision & Ablation of Pelvic Endometriosis:** small peritoneal and ovarian endometriotic implants, may be easily laparoscopically excised or fulgurated using Diathermy or Laser, with good results.

B. Laparotomy for Tuboplasty:

The role of laparotomy for performing tuboplasty procedures, as fimbrioplasty and neosalpingostomy, has largely diminished in the last decade in favour of much better success rates for ICSI procedures. When indicated it should follow strict microsurgical techniques with complete haemostasis and minimal tissue handling. Results are not encouraging as post operative adhesions are common, and initial occult tubal damage is already present in the majority of cases.

MANAGEMENT OF UTERINE FACTOR

1) Operative hysteroscopy can deal successfully with many uterine abnormalities in infertility;

- *Hysteroscopic Septoplasty:* resection of uterine septum (septate uterus)
- *Hysteroscopic Polypectomy:* excision of endometrial polyps
- *Hysteroscopic Myomectomy:* excision of certain types of SMM and SMF polyp
- *Hysteroscopic Adhesiolysis:* division of thin intrauterine synaechiae.

2) Myomectomy via Laparotomy or laparoscopy : indicated in large leiomyomas causing infertility

MANAGEMENT OF CERVICAL FACTOR

- ***Treatment of the cause***; as chronic cervicitis, hostile cervical mucus, removal of polyps
- ***Use of oestrogen and mucolytic drugs*** to improve cervical mucus physical properties
- ***Intrauterine Insemination IUI:*** injection of processed semen directly within the endometrial cavity bypassing the cervix.

5. MANAGEMENT OF UNEXPLAINED INFERTILITY

- Reevaluation of both partners and obtaining more recent investigations.
- Further tests, not previously performed, as diagnostic laparoscopy and hysteroscopy.
- Serum Chlamydia antibodies, and cervical mucus assessment.
- Super ovulation induction protocols with purified HMG under TVS guidance.
- Repeated IUI, for at least 3 cycles, may improve the chances of conception.
- IVF & ICSI procedures are the last resort, but with best prognosis.

ASSISSTED REPRODUCTIVE TECHNIQUES

Assisted reproductive techniques **(ART),** describe the use of advanced technologies to facilitate or assist oocyte fertilization. The commonly used techniques nowadays include:

- Intrauterine insemination **(IUI)**
- In-Vitro Fertilization and Embry Transfer **(IVF/ET)**
- IntraCytoplasmic Sperm Injection **(ICSI).**

I. INTRA UTERINE INSEMINATION (IUI)

IUI entails intrauterine injection of processed male semen into the uterine cavity through the endocervix at the time of ovulation. Semen is processed before injection, where high quality spermatozoa are mixed with an enriched media (Ham F10) to ensure maximum sperm activity.

IUI is indicated in cases with coital dysfunction, male factor as erection disorders or mild oligospermia, female cervical factor, or cases with unexplained infertility.

Success rates for IUI are limited, reaching almost 15% conception rates after at least 3 trials within 6 months duration.

II. IN-VITRO FERTILIZATION AND EMBRYO TRANSFER IVF-ET

IVF involves incubation of US guided retrieved female o ocytes with male spermatozoa in the laboratory to facilitate their fertilization. The resultant embryos are transferred back into the uterus (ET).

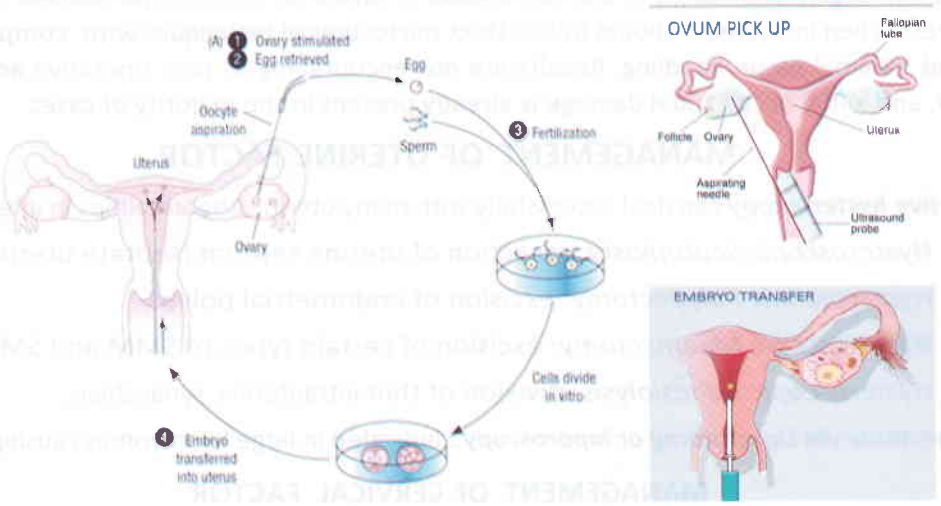

Fig 13-3: IVF-ET

III. INTRACYTOPLASMIC SPERM INJECTION (ICSI}

ICSI: is a micromanipulation technique that differs from IVF in that a sperm is injected directly into the cytoplasm of the oocyte to enhance fertilization. It is the procedure of choice commonly performed almost replacing older IVF procedure.

Indications for IVF/ICSI Procedures

a) Severe tubo-peritoneal factor with tubal damage and/ or extensive tubo-peritoneal adhesions.
b) Failed adhesiolysis and/ or tuboplasty procedures.
c) Severe male factor: as severe oligoasthenospermia, and Azoospermia.
d) Uexplained infertility: especially after repeated failed IUI.

Steps and Techniques in IVF/ICSI Procedures

1. ***Pituitary down-regulation:*** daily S.C. or intranasal doses of Gn RH agonists are essential to prevent natural LH surge during follicular stimulation as this may result in follicular rupture before egg retrieval.
2. ***Ovarian stimulation:*** controlled ovarian stimulation by daily IM FSH injection to induce multiple follicular growth and maturation. Injections are continued for 11-14 days until the leading follicles reach 18 mm in diameter by TVS.
3. ***Ovulation trigger:*** by hCG: in order to induce an artificial LH surge
4. ***Oocyte retrieval:*** egg collection: is performed via US guided transvaginal needle aspiration of mature oocytes (larger than 18 mm in diameter), 24 hours after hCG ovulation trigger.
5. ***Laboratory sperm-egg fertilization:***
   a. ***In IVF:*** 100,000-200,000 sperms are incubated with retrieved oocytes, 4-6 hours after collection, in a special container to allow spontaneous fertilization.
   b. ***In ICSI:*** a sperm is injected directly into the cytoplasm of the metaphase II oocyte through the zona pellucida under a special inverted phase microscope
   c. ***Oocytes are transferred*** to a fresh culture medium and examined for fertilization and cleavage by the presence of 2 pro-nuclei.

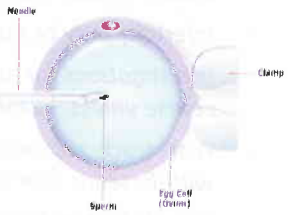

Fig 13-4: ICSI

6. ***Embryo transfer (ET):*** trans-cervical transfer of the embryos into the uterine cavity is carried out 2-3 days after oocyte retrieval.
7. ***Luteal phase support:*** administration of progesterone to assist blastocyst implantation and avoid premature shedding of the endometrium is started after ET and continued for 2 weeks. If serum B- hCG revealed a positive test 2 weeks after ET, progesterone support will be continued throughout the first trimester of pregnancy.

Success Rates of IVF / ICSI Procedures

- ***Success rates*** in ICSI procedures are higher than IVF, reaching around **25-40%.**
- ***Success rates depend largely on***
  - Maternal age
  - Quality of oocytes retrieved
  - Quality of embryos fertilized
  - Presence of pelvic pathology as endometriosis or PID.
  - The protocol chosen for stimulation, technique performed in oocyte retrieval and embryo transfer, and the control on media used for oocyte/embryo incubation

Complications of IVF/ICSI Procedures

1. Allergic reaction to ovulation induction agents
2. OHSS with its complications (see OHSS in treatment of anovulation CH 8)
3. Trauma during oocyte retrieval: as vaginal haemorrhage, injury to major pelvic vessels, or injury to adjacent uterine, tubal, or intestinal organs.
4. Pelvic infection related to the procedure of oocyte aspiration.
5. Complications of ART pregnancies as; increased incidence of abortion, ectopic pregnancy, MFP, and a slight increase in some congenital anomalies.

Gn RH Analogues in IVF/ICSI Protocols:

- **GnRH agonists** are synthetic decapeptide forms of GnRH.
  - *Route of administration:* repeated S.C. injection or nasal spray.
  - *Indications:* used mostly in IVF/ICSI protocols to suppress endogenous FSH & LH through their down regulation receptor effect, thus preventing premature ovulation, and allowing maximum egg retrieval.
- GnRh antagonists: are gaining popularity now in the protocols of IVF/ICSI procedures. This is due to the fact that is shorter in duration, safer in cases who more prone for OHSS (including cases of PCOS), and cheaper in terms of using less medications. GnRH antagonists are used as well in cases running on GnRh agonist protocol and who develops signs of impending OHSS. Its value is that it almost immediately shuts down the endogenous FSH and LH production thus preventing the development of OHSS.

Key points in Infertility

- *Infertility* is a *problem of* a *couple, therefore history, examination, investigations, and counseling should include both partners.*
- *Infertility may be due to male factors, female factors, or a contribution of both*
- *Investigations for infertility usually start at least 6 months after unprotected regular sexual intercourse unless history* is *suggestive of a significant male or female problem.*
- *Fast track diagnosis and management is essential in women over 35 years of* age *and in women with baseline FSH > 10 ngl ml indicating compromised ovarian* reserve.
- *Female factors for infertility include; ovarian, tubal, peritoneal, uterine, and cervical factors*
- *Treatment of anovulatory infertility carries the best prognosis.* Success *rates in induction of ovulation may reach about 80-90%, with pregnancy* rates *approaching 70-80%.*
- *Induction of ovulation usually* starts *by CC alone, CC/hCG, or CC/HMG/hCG. It should be performed under TVS monitoring to avoid the serious complication of OHSS.*
- *Many uterine factors are surgically correctable via hysteroscopy or laparotomy as polypectomy. Septoplasty, and myomectomy*
- *Treatment of mild tubo-peritoneal factors m a y have* success rates reaching around *30%.*
- *Severe tubal damage or extensive adhesions carry poor prognosis even after surgery*
- *IUI* is *usually offered to cases of mild male factor, suspected cervical factor, or unexplained infertility, before attempting at IVF or ICSI.*
- Success rates *for ICSI are approaching 25-40% in most centres.*
- *Best prognosis* is *achieved in younger females, with absent pelvic pathology, and those with mild male factor or unexplained infertility.*
- *ICSI seems to be the only hope for cases with severe male factor or severe tubal damage*



14 CONTRACEPTION AND FAMILY PLANNING

- *Physiologic contraception*
- *Barrier contraception*
- *Intrauterine contraceptive device*
- *Hormonal contraception*
- *Female sterilization*
- *Contraception during lactation*
- *Emergency postcoital contraception*

OVERVIEW

Family Planning is practiced by many couples aiming at spacing pregnancies and choosing the proper time for conception and childbirth.

Delaying conception is usually a **temporary** need for most couples, however **permanent contraception** may be required either because of an already completed family, or due to the presence of severe chronic medical disorder that may complicate or be complicated by pregnancy.

An ideal method for contraception should be cheap, readily available, easy to use, with minimal side effects and complications, and with maximum efficiency in protection from unwanted pregnancies.

Finally the best contraceptive method is one that has no or minimal effects on the future female fertility, once the couple decided planning for a new pregnancy, i.e. **reversible contraception**.

Temporary contraception; can be achieved via physiologic methods, barrier methods, chemical methods, IUCDs, and hormonal methods.

Permanent contraception; can be achieved in the female via tubal ligation, or hysterectomy, while in the male permanent sterilization is achieved via bilateral surgical ligation of the vas deferens.

Occasionally, an urgent contraceptive method may be required whenever a coital relationship has occurred in absence of a suitable protection, in an attempt to minimize the risk of unwanted pregnancy.

PHYSIOLOGIC CONTRACEPTION

Physiologic or natural methods for contraception are easy, cheap, readily available methods with reasonable efficiency, but are not reliable when used alone. Combining more than one method will very much improve the efficacy without additional costs or hazards.

1. COITUS INTERRUPTUS

Withdrawal and ejaculation outside the vagina during intercourse is one of the oldest most commonly practiced methods for contraception.

Efficacy of this method is not high, as in some cases the pre-ejaculatory fluid may contain sperms capable of fertilization. It is best coupled with the safe period method.

2. THE SAFE PERIOD

Intercourse is totally prevented, or protected (by a condom or coitus interrupted) at the time of expected ovulation (day 10-18 of a 28 days cycle), while allowed for the rest of the month without protection methods. This method is suitable only for intellectual couples, with regular cycles.

Efficacy is good, and is improved when coupled with additional methods that allow for more accurate prediction of ovulation as the **BBT** chart and **urinary LH** tests.

3. LACTATION

During lactation, at least 60 % of females will experience amenorrhoea, anovulation, and oligo-ovulation during the first 6 months of the puerperium, due to elevated prolactin levels.

- Efficacy: is not high (nearly 50% protection if used alone), due to the fact that some women may resume ovulation at variable unpredictable periods of time. Efficacy is improved by adding other methods as barrier, spermicidals, and coitus interruptus.

BARRIER CONTRACEPTION

These methods work by physically or chemically preventing sperm egg interaction.

To be effective barrier methods need to be used correctly and consistently with every act of sexual intercourse. Correct use requires motivation, skills and, communication between partners.

Advantages of Barrier Methods	*Disadvantages of Barrier Methods*
– *Easy to initiate and discontinue* – *No systemic side effects* – *No effects on future fertility* – *No effect on lactatioon* – *Failure rates < 10/HWY* – *Some may prevent transmission of STDs*	– *Difficult to use consistently and correctly* – *May interrupt sexual activity and pleasure* – *Some require partner's participation* – *Less effective than other modem methods*

1. MALE AND FEMALE LATEX CONDOM

Latex condoms, used by the male, are the most widely used barrier contraceptive method all over the world. The female latex condoms are not widely available in many countries.

- *Efficacy:* high pregnancy prevention rate reaching up to **97%** which is additionally increased when used with spermicidal creams, coitus interruptus, or the safe period.
- *Advantages:* high efficiency, ready availability, easy use, cheap price.
- *Medical benefits:* prevention of STDs (as HIV & HPV), HCV, and treatment of premature ejaculation.
- *Disadvantages:* rarely becomes torn, or slips out, thus losing protection

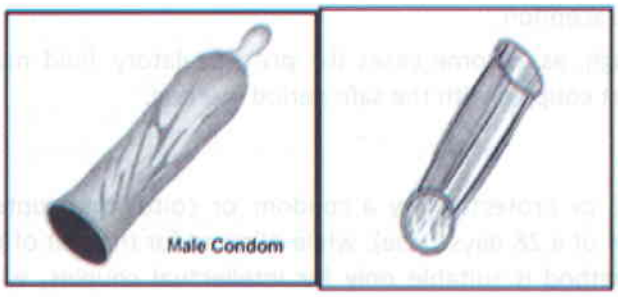

Fig. 14-1: Male condom



Fig 14-2: Spermicide cream

2. SPERMICIDES (NONOXYNOL-9)

Spermicides inactivate sperms deposited in the vagina during intercourse.

- ***Forms***: vaginal tablets, creams, gel, or sponge applied 30 minutes before intercourse.
- ***Efficacy:*** failure rates reach up to 30 /HWY if used alone however they are more effective when used with condoms or vaginal diaphragms.
- ***Disadvantages:*** spermicidals may cause allergic vaginitis in some women.

INTRA-UTERINE CONTRACEPTIVE DEVICE (IUCD or IUD)

The **IUD** is the most commonly used method in national family planning programs, in developing countries, due to its high efficacy and long term duration of use.

The **IUD** is made of a **polyethylene** material that is Barium Sulphate coated to render it radio-opaque on X-ray.

The **stem** is usually covered with a thin **Copper** (Cu) wire, but may also contain **silver** or **gold**.

Progesterone impregnated IUD, as the Levo-Norgestrel Releasing Intrauterine System **(LNG-IUS)** have been introduced in the last decade, with increased **efficiency**, and excellent control of uterine bleeding. They are nowadays commonly used in treatment of **DUB**.

The **limbs** of the IUD emerge from its **upper stem**. They are usually plain, but in some IUDs may be covered by Copper bars. The limbs serve as an anchor holding the device properly at the fundus of the uterine cavity, avoiding its expulsion during menstruation.

Two **nylon threads** are attached to its **lower stem** and protrude out of the cervix. They serve as **markers** for its presence and at the same time facilitate IUD **removal** by simply pulling on the threads outwards.

IUD is the **preferable** method for **long term contraception** especially for **multiparous** women after completing their family. It is generally suitable for most women except those with irregular cycles, menorrhagia, DUB, and those with uterine or pelvic pathology as uterine septum, leiomyomas, and PID.



Fig. 14-3:

MECHANISM OF ACTION: (not completely understood)

A) Interference with Blastocyst Implantation, rendering the endometrium unsuitable, via:

- *Local foreign body inflammatory responses*
- *Increased local endometrial PGL production*
- *Inhibition of Carbonic anhydrase and Alkaline phosphatase activity (Copper IUD)*
- *Induction of atrophic endometrial changes (LNG-IUS)*

B) Interference with Sperm Motility rendering them incapable of fertilization.

- *Inhibits sperm motility through the endometrial cavity and fallopian tubes*
- *Induces and antisperm phagocytic activity(Cu IUD)*
- *Toxic effect on sperms inhibiting its capability of fertilization(Cu IUD)*
- *Produces thick cervical mucus interfering with transcervical sperm penetration (LNG-IUS)*

TYPES OF IUDS:

1. *Copper medicated IUD:* (Cu T 380) is the most commonly used type with a surface area of the copper 380 mm^2. It lasts effectively for 6-8 years then changed by a new device.
2. *Copper+ Silver medicated IUD* (Nova T): Cu T 200 IUD in which silver is added to minimize fragmentation of copper.
3. *Progesterone medicated IUD:* (LNG-IUS Mirena IUD) with sustained release of levo-norgestrel 35 ug/day. It acts effectively for 3-4 years then changed by a new device.

IUD INSERTION:

A) Timing of Insertion:

- Best inserted by end of menstruation to ensure a slightly dilated cervix, absence of pregnancy, and minimal post-insertion bleeding.
- It can be inserted 4-6 weeks after delivery, or 3-4 weeks after an abortion.

B) Technique of insertion:

The contraceptive device is composed of a polythene IUD, an insertion tube and a plunger rod.

- A preliminary US is performed to ensure the size and direction of the uterus, and to exclude myomas, polyps, and adnexal masses.
- Cusco speculum is introduced into the vagina with the patient in the lithotomy position.
- The anterior lip of the cervix is grasped by a multiple toothed Volsellum
- A uterine sound is passed through the cervix to reassure uterine length and direction.
- The IUD is launched in the insertion tube which is gently passed through the cervical canal reaching just short of the uterine fundus.
- *Withdrawal Technique:* the plunger rod is used to fix the IUD near the fundus, while the insertion tube is gently rotated and withdrawn back releasing the limbs of the IUD with the T arms spreading towards each uterine cornu (see diagram)
- The long IUD threads are then cut 2 cm from the external os.

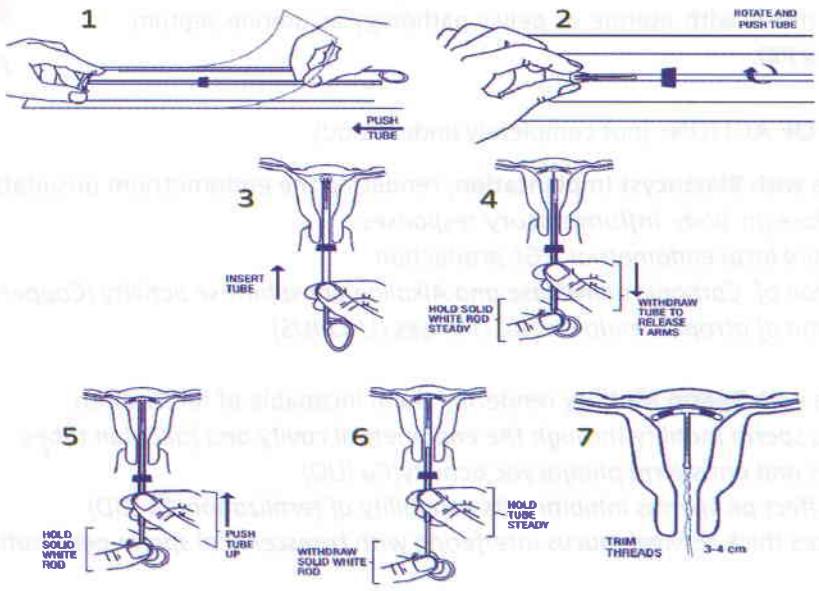

Fig 14-4: IUD insertion

C) Follow up after insertion:

- Periodic follow up visits after IUD insertion are recommended to ensure its proper fitting.
- Threads can be felt on PV examination, or seen on speculum examination.
- TVS or TAS is generally the best method to reassure proper IUD fitting within the uterine cavity.
- Dealing with associated side effects or complications (see later).

ADVANTAGES OF IUD:

- Single choice method, with a long term protection (6-8 years).
- It does not affect lactation, in recently delivering women.
- It does not affect or interfere with sexual intercourse
- Very low failure rate: 0.5/HWY {Hundred Women Yearly).

PROBLEMS AND COMPLICATIONS ASSOCIATED WITH IUDs:

1. Abnormal Uterine Bleeding AUB:

a) Post Insertion Bleeding:

Mild bleeding, or spotting, may occur in the first few days following insertion. Bleeding usually stops spontaneously, but if persists use antifibrinolytics and venotonics.

b) Menorrhagia:

Heavy menstrual bleeding **(HMB)** is common in the first few cycles following IUD insertion, but may continue for a longer period in some cases.

- Aetiology: mostly due to increase **PGLs** production, or increased **fibrinolytic** activity. Copper IUD increases blood loss by almost 35% in many women.
- Management:
  - *Exclude uterine and pelvic pathology;* by clinical examination and pelvic US
  - *Anti-fibrinolytic agents* (Tranexamic acid 500 mg orally 2-3 times daily) and/or
  - *NSAIDs* (Brufen 600 mg orally 2-3 times daily) till bleeding stops.
  - *Remove IUD;* if displaced, or discovered significant uterine or pelvic pathology.
  - *LNG-IUS* induces endometrial atrophic changes, leading to a **70%** reduction in menstrual blood loss, and hence can be used as an alternative in cases who suffered intractable bleeding with the use of regular Cu IUD.

c) Metrorrhagia:

Irregular intermenstrual bleeding is usually associated with anovulatory dysfunction, pelvic infection, or partial expulsion of an IUD.

- Management:
  - Proper replacement of a cervically displaced IUD
  - *Antifibrinolytics & NSAIDs* (see before)
  - *Cyclic Gestagens* (nor-ethisterone acetate 5 mg orally 2-3 times daily for day 10-15th every cycle for 2-3 cycles. (See DUB).
  - Combined oestrogen / PRG therapy (OCPs 21 days each cycle for 2-3 cycles)

2. Pelvic Pain:

- *During insertion:* cramping pain is common due to forcible insertion. Give NSAIDs
- *After insertion:* possibly due to incorrect placement. Check position and replace properly
- *Backache:* due to pelvic congestion, or chronic cervicitis.
- *Acute Abdominal pain:*
  - With IUD is in situ; as with abortion, tubal ectopic pregnancy and PID, or
  - With a missed IUD; as in cases with uterine perforation (see later).

3. Pelvic Infection:

- Chronic cervicitis and cervical erosions; are more common in presence of an IUD.
  - Antibiotics should be given, then IUD removed
  - Cauterization of cervical erosion.
- PID is more common in presence of IUD s; the threads of an IUD may facilitate ascending infection, especially with STDs, causing endometritis and salpingitis
  - Managements; Antibiotics, then removal of IUD.

4. Vaginal Discharge:

- Increased watery cervical discharge, due to pelvic congestion.
- Mucopurulent discharge may occur in chronic cervicitis.
  - Management: treat the cause

5. Expulsion of an IUD:

Spontaneous expulsion may occur usually in the first few cycles after insertion due to;

- Intermittent uterine contractions especially during menstruation, or
- Misplacement at the time of insertion.
  - Management: In both cases IUD should be removed and correctly re-inserted.

6. Perforation:

Perforation mostly occurs at the time of insertion.

- *Symptoms:* sharp stabbing or colicky pelvic pain, together with persistent vaginal bleeding.
- *Signs:* the threads will not be felt by the patient, nor seen by speculum examination.
- *Investigations:* TVS will fail to detect the IUD within the uterine cavity, while a plain X-ray will reveal its presence in the pelvic cavity.
  - *Management* (see later in missed IUD).

PREGNANCY ON IUD:

Failure rates for IUDs are very low < 0.5 / HWY. Most pregnancies occur when the IUD is displaced downwards intracervically, leaving the rest of endometrial cavity unprotected.

- Management of pregnancy with IUD:
  - *If threads are visible;* IUD removed, pregnancy continues with an abortion rate 25%
  - *If threads are not visible;* IUD is left in place, pregnancy continues with an abortion rate of around 50%, with higher incidence of septic abortion.

IUD & ECTOPIC GESTATION

IUD prevents intrauterine but does not prevent extra uterine pregnancy to the same extent. Incidence of ectopic gestation may be slightly increased especially in the presence of PID. Management (see ectopic gestation)

MANGEMENT OF MISSING IUD THREADS:

If IUD threads are not felt by PV nor seen at speculum examination, a TVS should be performed to confirm the presence or absence of the IUD within the uterine cavity, and exclude pregnancy

a) **If IUD is intrauterine;** leave it in place if there is no other indication for removal.

b) **If IUD is not detected by TVS;** a plain X-ray to the abdomen and pelvis is performed:

- *Absence of IUD on plain X-ray* denotes expulsion outside the body. A new IUD may be inserted if the patient asks for one.
- *Presence of IUD on plain X-ray* denotes perforation and presence inside the abdominal or pelvic cavity. Such cases are managed by removal of the IUD via laparoscopy or laparotomy, as its presence will provoke an inflammatory reaction leading to peritoneal, omental, and intestinal adhesions, and / or injury.

CONTRAINDICATIONS FOR THE USE OF IUD:

1. *Undiagnosed vaginal bleeding*
2. *Uterine anomalies* that interfere with proper insertion (as septate or bicornuate uterus).
3. *Uterine pathology* that interferes with proper insertion or cause complications (leiomyomas, polyps, and adenomyosis).
4. *History of PID;* as IUD may provoke or aggravate PID.
5. *History of ectopic pregnancy;* relative contraindication for fear of higher incidence of repeat ectopic gestation.

HORMONE METHODS FOR CONTRACEPTION

Hormone contraception methods are among the most commonly used methods for contraception used around the world, owing to its very high efficiency and its ease for its administration or its discontinuation.

HORMONAL CONTRACEPTION:

A. **OESTROGEN PROGESTOGEN CONTRACEPTION:** OCPs, Vaginal rings, and dermal patches

B. **POGESTERONE ONLY CONTRACEPTION;** POPs, IM injectables, subdermal implants, and LNG-IUS

I. COMBINED HORMONE CONTRACEPTION

MODE OF ACTION:

This type of hormone contraception contains a ***combination*** of an ***oestrogen*** and a ***gestagen*** in the form of oral pills, vaginal ring, or adhesive dermal patches. They exert their contraceptive effect through the following mechanisms;

1. **Oestrogen:** Inhibits ovulation via suppression of GnRH, FSH, LH, and LH surge.
2. **Gestagen:** synthetic progesterones exert their contraceptive effect through;
   - *Endometrial changes unfavourable for implantation:* due glandular atrophy and stromal oedema.

- *Cervical mucus changes* resulting in thick cervical mucus hostile to sperm penetration
- *Altered tubal motility and secretions;* unfavourable for oocyte transport
- *Interference with ovulation;* through FSH & LH suppression (but less than oestrogen)

N.B.; In addition to its contraceptive effect, gestagens also result in;
Excellent cycle control; due to cyclic endometrial shedding.
Prevent oestrogen induced endometrial hyperplasia.

TYPES OF COMBINED HORMONE CONTRACEPTION

A. *Combined Oral Contraceptive Pills COCs:* contain a combination of;

- **Oestrogen** (Ethinyl Oestradiol EE: 30 ug), **and**
- **Gestagen** (synthetic progesterone) that may vary from;
  - *2nd generation:* Levo-norgestrel and Norethisterone
  - *3rd generation:* Desogestrel and Gestodene
  - *4th generation:* Drospirenone

Monophasic COCs;

Contain same EE/PRG content in every pill, started Day 3-4 from 1st day of LMP and taken once dailyfor 21 consecutive days, then stopped for one week allowing for withdrawal bleeding (menstruation), then restarted for a new cycle. Monophasic pills are commonest form of COCs with greatest popularity.

Biphasic & Triphasic COCs;

Contain different EE/PRG content in two phases or three phases, i.e. not all the pills in each pack contain the same EE/PRG content. There are no proven benefits for a biphasic or a tri-phasic COCs over monophasic pills hence their use has not gained enough popularity.

B) Vaginal Contraceptive Ring VCR:

The ring is introduced vaginally by the patient by the end of the menstrual period, left for 3 weeks then removed followed by a 7-day ring free period, to allow for menstruation. The mode of action of VCR is similar to that for the COC pills without the need for daily intake owing to its slow hormone release that is readily absorbed from vaginal mucosa, giving an additional benefit of bypassing the first hepatic absorption.

C) Contraceptive Adhesive Skin Patches:

The contraceptive patch is applied to the skin of the abdomen, buttock, or thigh, started on the 3rd or 4th day of menses, changed on the same day every week for three consecutive weeks, followed by a 7-days patch free interval to allow for menstruation.

ADVANTAGES OF COMBINED HORMONE CONTARCEPTION (mainly COCs):

1. Contraceptive benefits of COCs

- Most effective method of contraception 0.1-1/HWY. If pregnancy occurs it is said that it is rather patient failure than method failure.
- Excellent cycle control, especially in patients with previously irregular cycles.
- No long term adverse effects on fertility, with rapid recovery after pill discontinuation.
- No effects on sexual intercourse compared to coitus interruptus, spermicidals, condoms, and calendar methods for the safe period.

2. ***Non contraceptive benefits of COCs:***
   - Treatment of DUB.
   - Postponing next menstruation (delaying an expected cycle).
   - Treatment of spasmodic dysmenorrhoea.
   - Less risk for PID, functional cysts of the ovary, endometrial carcinoma, and epithelial ovarian cancer.

DISEASE RISK ASSOCIATED WITH THE USE OF COCS

Disease	Relative risk
1. Lschaemic Coronary Heart Disease (ICHD	slightly **increased** risk
2. Ischaemic stroke	**2 fold increased** risk
3. Venous thrombo-embolism VTE	**3-5 fold increased** according to type of gestagen
4. Breast cancer	**small increase** in risk on prolonged use (time related)
5. Cervical cancer	**small increase** in risk on prolonged use (in smokers)
6. Epithelial ovarian cancer	**50% decreased** risk lasting for a long period after stopping
7. Endometrial cancer	**50% decreased** risk lasting for short period after stopping
8. Colorectal cancer	slightly **decreased** risk

SIDE EFFECTS OF OCPS:

1. **Spotting:** mostly due to inappropriate hormone content of the pill. In such cases shift to other preparation with higher dose of gestagen in the following cycles.
2. **Breakthrough Bleeding:** inter-menstrual bleeding during the course of pill taking. If persists more than 3 cycles, then shift to higher hormone content pills .
3. **Hypomenorrhoea:** It is common with OCP as gestagens cause glandular atrophy. Pills should be stopped if the symptom is unacceptable by the user.
4. **Amenorrhea:** during intake or after stopping the pills, is managed by excluding pregnancy, inducing withdrawal bleeding by gestagens, and shifting to another non hormonal method.
5. **Thrombo-embolic Disorders:** increased due to increased platelet adhesiveness, increased level of factor II, VII, IX, and X. The risk for DVT and pulmonary embolism is increased from 4 to 6 folds if OCP were not stopped at least 4 weeks before surgery.
6. **Hypertension (HTN):** increased incidence in predisposed patients after prolonged use.
7. **Diabetes mellitus (DM);** impaired carbohydrate metabolism may predispose to DM, an d in diabetic patients will lead to difficult glycaemic control.
8. **Liver:** transient impairment of liver functions is not uncommon, with increased hepatic cholestatsis, higher incidence of gall stones, and rarely benign hepatocellular adenoma.
9. **Effect on Lactation:** decreased milk production & quality protein, only with COCs.

OTHER MINOR SIDE EFFECTS:

a. ***Nausea and vomiting:*** may be encountered in the first few cycles.
b. ***Migraine headache:*** if severe needs discontinuation and shift to non-hormonal method.
c. ***Irritability and depressive mood:*** shift to lower progestogen content pills.
d. ***Weight gain:*** usually minor, mainly due to salt and water retention.
e. ***Breast tenderness, and enlargement:*** shift to lower E/P pills
f. ***Acne:*** may worsen during OCP intake..
g. ***Skin pigmentation:*** Chloasma similar to pregnancy due to increased pigment deposition.
h. ***Change in Libido:*** decreased sexual desire may rarely occur in some women.

i. ***Vaginal Discharge:*** Leucorrhoea may occur due to associated cervical congestion.

j. ***Eye Symptoms:*** corneal oedema, contact lens wearers suffer from blurring of vision & corneal irritation. Reported cases of transient optic nerve ischaemia, and transient blurring of vision. The previous conditions call for the pills to be stopped

CONTRAINDICATIONS FOR USE OF OCP

Absolute Contraindications	Relative Contraindications
1. *Thrombophlebitis or thromoembolic disease.*	1. *Superficial thrombophlebitis.*
2. *History of DVT.*	2. *Varicose veins.*
3. *Coronary heart disease.*	3. *Migraine headache.*
4. *Cerebrovascular accidents or strokes.*	4. *Hypertension.*
5. *Liver disease (impaired function).*	5. *Diabetes mellitus.*
6. *Malignancy of the female genital system.*	6. *History of liver disease.*
7. *Abnormal bleeding from the genital tract.*	7. *Gall bladder stones.*
8. *Benign or malignant liver disease.*	8. *Age >35 years.*
9. *Suspected or known carcinoma of breast or history of benign neoplasms of the breast.*	9. *History of: Pre-eclampsia, Diabetes with pregnancy, Cholestasis with pregnancy.*

II. PROGESTOGEN ONLY CONTRACEPTION

A) PROGESTOGEN ONLY PILLS (POPS)

In POP each pill contains the same amount of gestagen (levo-norgestrel, norethisterone, or desogestrel), administered orally, daily, around the same time every day, without a pill free interval irrespective of menstrual cycle.

- **Indications:**

Although POP are suitable for most women, they are most often used by women for whom a COC is contraindicated (e.g.; breast feeding women, hypertension, age above 40, women who smoke regularly, and those who commonly get severe migraine headaches especially with aura).

- **Mode of Action:**

  POP affects mainly the cervical mucus rendering it thicker preventing sperm penetration. It has an atrophic endometrial effect, together with inhibiting of ovulation in only 60% of cases.

- **Side Effects:**POP have minimal side effects compared to COC, but are generally associated with higher incidence of menstrual irregularities, and ectopic pregnancy.

B) PROGESTOGEN ONLY INJECTABLE CONTRACEPTION

The most commonly used injectable progestogen is composed of depot medroxyprogesterone acetate (DMPA), given IM every 12 weeks.

- **Mode of Action:**

  It acts mainly through inhibition of ovulation. Its main advantage is the convenience of its 3 monthly dose.

- **Side Effects:**

  Vaginal spotting is common in the first few months, while up to 70% of women will have amenorrhoea at the end of the first year.

C) SUBDERMAL PROGESTAGEN IMPLANTS

A subdermal implant is made from a non-biodegradable polymer which contains an active slow release progestogen formulation and is about the size of a matchstick.

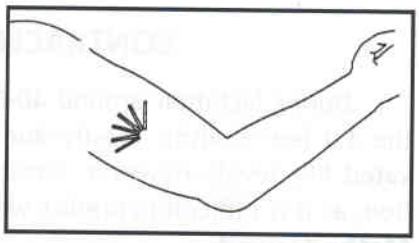

Fig 14-5: Subdermal implants

- **Application & Mode of Action:**

  It is placed subdermally by a special introducer, and will provide contraception for almost 3 years, mainly via inhibition of ovulation.

- **Side Effects:**

  About 20% of women will have amenorrhoea within three months, while up to 50% will have frequent or prolonged cycles.

- **Advantages:**

  Implants are not associated with significant weight changes, mood changes, or loss of libido, but their side effects cannot be easily dealt with owing to their prolonged slow hormone release.



Fig 14-6: Tubal Ligation

FEMALE STERILIZATION

Female sterilization is a permanent method for contraception that entails surgical occlusion of both fallopian tubes to prevent egg fertilization.

- **Indications:**
  - Its use should be reserved only to those cases with medical or surgical diseases or conditions that contraindicate pregnancy, and necessitate pregnancy termination if it occurs.
  - It should not be advised for cases who just need to limit their family number.

- **Techniques for tubal occlusion:**
  - ***Laparoscopy:*** using clips, rings, or bipolar diathermy (commonest method used).
  - ***Laparotomy***: using delayed absorbable sutures, performed via a mini-laparotomy incision, or more often during repeat CS procedure.
  - ***Vaginal tubal ligation***; performed via a posterior colpotomy in the vaginal fornix

- **Side Effects:**

  Some cases may suffer pelvic congestion (post ligation syndrome), leading to heavy menstrual bleeding, and pelvic pain.

MALE STERIIZATION

- **Surgical:** via ligation of the vas deferens. The most commonly practiced method
- **Medical:** Gossypol (the male pill), inhibits spermatogenesis. Not commonly available.

CONTRACEPTION FOR LACTATING FEMALES

During lactation around 40-60% of females will experience amenorrhea and anovulation in the 1st few months, mostly due to the anti-gonadotrophic effect exerted by the markedly elevated PRL levels. However, lactation alone is not considered reliable as a method of contraception, as it is difficult to predict when ovulation will be restored.

Methods used:

1. **IUD:** is an ideal method as it gives long term contraception without interference with lactation.
2. **Progestogen only injectables:** DMPA: 150 mg I.M./3 months are suitable in most cases.
3. **Progestogen only pills (POP):** daily administered in the same time, without pill free intervals, regardless presence or absence of menstruation, are a good alternative to injections
4. **Barrier Method:** male and female condom and diaphragm are suitable especially with back-up methods as spermicidals or coitus interruptus.
5. **Spermicidal gel or foam:** used in cases with infrequent intercourse (husband travelling, etc.)
6. **Physiologic Methods:** Coitus interruptus is a popular method **widely practiced. The** safe period is not always suitable due to the high incidence of menstrual irregularity with lactation.

EMERGENCY OR POST COITAL CONTRACEPTION

It is the use of methods to prevent pregnancy after an unprotected intercourse has occurred whenever no method has been previously used, or a method did not function properly, such as a torn condom, or a missed pill.

Options for Emergency Contraception

IUD Insertion within 24-48 hours of unprotected intercourse

OCPs: started immediately after intercourse 4 tablets (2 tablets /12 hrs).

- ***POP high dose pills regimen:*** Each oral tablet contains 0.75 mg of levo-norgestrel. The first tablet should be taken within 72 hours after unprotected intercourse, and the 2nd dose tablet is taken 12 hours after the first one.
- ***COCs regimen:*** Each dose should contain at least 0.1 mg of EE + 0.5 mg of levo-norgestrel (i.e.; 4 tablets of the standard low-dose COCs taken together). First dose must be taken within 72 hours after unprotected intercourse, with a repeat dose 12 hours after first dose.
  - Low-dose COCs = 4 pills per dose
  - High-dose COCs= 2 pills per dose

- **Side Effects:** include, nausea, vomiting, headaches, dizziness, fatigue, breast tenderness, irregular bleeding and spotting.



15 BENIGN CONDITIONS OF THE VULVA AND VAGINA

BENIGN CONDITIONS OF THE VULVA
- *Pruritus Vulvae*
- *Epithelial disorders of the vulva*
- *Vulval ulcers*
- *Vulvar swellings*

BENIGN CONDITIONS OF THE VAGINA
- *Vaginal discharge*
- *Vaginal infections (vaginitis)*
- *Vaginal swellings*

OVERVIEW

Most women will present to the gynaecologic clinic, once or more in their lives, complaining from different diseases and conditions affecting the vulva and the vagina. Among these the common- est are diseases affecting the skin all over the body, infections, and non neoplastic cysts. Benign neoplasms and premalignant lesions are less common, while malignant tumours of the vulva and vagina are among the rarest in the female genital tract.

BENIGN CONDITIONS OF THE VULVA

Pruritus vulvae, pain, discharge, and swelling are common manifestations of vulvar diseases. Proper diagnosis of many vulvar conditions is often delayed because of a tendency for most physi-cians to treat the symptoms without reaching a specific diagnosis which requires;

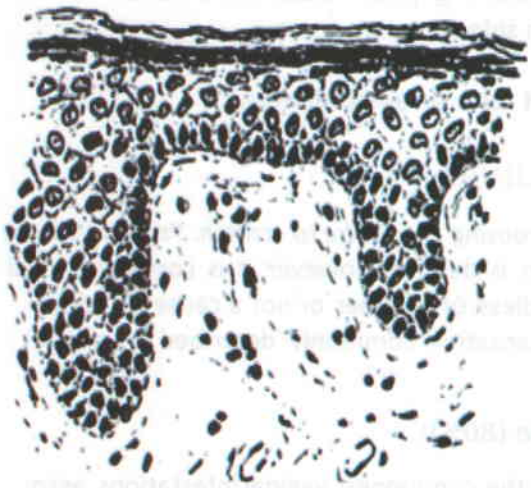

Normal vulva

Fig. 15-1:

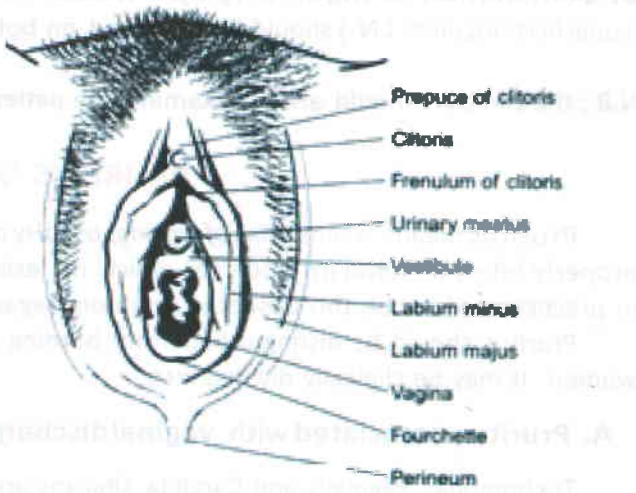

Fig. 15-2:

A. Careful history taking for:

- The use of topical irritants; as soaps, perfumes, local cream or gel, and nylon tight-fitting underclothing, especially in patients with known allergy to other conditions
- Medical disease that may manifest by vulvar conditions; as with diabetes mellitus, Chron's disease, atopic sensitivity, and psoriasis.
- Urinary conditions; as genito-urinary fistula (GUF) that may cause continuous dribbling of urine through the vagina.
- Faecal fistula; following a complete perineal tear, episiotomy, or intra-vaginal irradiation.
- Previous or recurrent vulval condition; and its response to previous medications, or therapeutic measures

B. Proper examination of the vulva:

1. Inspection of the vulva with the patient in the *lithotomy* position, with *proper exposure, good light,* and sometimes with a hand held *magnifying lens* for smaller lesions.
2. Vaginal speculum examination; in cases with vulvitis secondary to vaginal discharge, or in lesions that may extend into the vagina and cervix as with HPV.

C. Special investigations:

- Biopsies from suspicious lesions obtained using Keye's punch biopsy under local anesthesia, and subjected to histopathologic examination.
- Colposcopy with 5% acetic acid or toluidine blue may be an aid to localize best sites for biopsy.

D. Examination of Inguinal lymph nodes: The draining lymph nodes of the vulva (superficial inguinal LN.) should be examined on both sides.

N.B.; the clinician should always examine the patient for a systemic disease

PRURITUS VULVAE

Pruritus means a *sensation of itching, usuaHy arousing the desire to scratch.* Pruritus vulvae properly refers to vulval irritation for which no lesion is defined, however it is commonly used in practice to describe this upsetting symptom regardless of whether or not a cause is found.

Pruritus should be distinguished from burning sensation commonly described by many women. It may be clinically divided into;

A. Pruritus associated with vaginal discharge (80%):

Trichomonas vaginalis and Candida albicans are the commonest vaginal infestations associated with pruritus. They account for at least 80 per cent of all cases.

B. Pruritus without vaginal discharge (20%):

- *Generalized pruritus:* as in cases of Jaundice, diabetes mellitus and Uraemia.
- *Allergy and drug sensitivity:* Skin sensitivity to various chemical constituents of toilet preparations such as soaps, bath salts and antiseptics may explain some cases. Rarely idiosyncrasy to chemical or rubber contraceptives is present.
- ***Skin diseases not specific to the vulva:*** as scabies and seborrhoeic dermatitis.
- ***Chronic epithelial dystrophies:*** as lichen sclerosus.

- ***Parasitic infestations of the rectum:*** oxyuris worms may migrate forward to cause vulval itching.
- ***Rectal incontinence:*** may also cause intense pruritus.
- ***Urinary incontinence:*** True urinary incontinence as in VVF and UVF with continuous dribbling of urine may cause severe vulvitis and pruritus in long standing cases.
- *Carcinoma of the vulva*
- *Psychogenic* (neurodermatitis)
- *Idiopathic pruritus.*

EPITHELIAL DISORDERS OF THE VULVA

A variety of terms have been applied to disorders of the vulvar epithelium that produce a number of non-specific gross changes. The term vulvar dystrophy has been replaced by the classification proposed by the international society for the study of vulvar disease (ISSVD)

The Terminology Committee presented a new classification of the benign,non-infectious vulvar dermatoses

The table below summarizes the most recent terminology changes *(2014)*

ISSVD 1986	ISSVD 2004	LAST 2012
VIN 1	Flat condyloma or HPV effect	LSIL
VIN 2	VIN, usual type a.VIN, warty type b.VIN, basaloid type c.VIN, mixed (warty/basaloid) type	HSIL
VIN3		
Differentiated VIN	VIN, differentiated type	

NON-NEOPLASTIC EPITHELIAL DISORDERS OF THE VULVA

A. LICHEN SCLEROSUS ET ATROPHICUS:

Incidence: This is the commonest condition found in the elderly women complaining of vulval itching but may also be seen in children and younger women.

Aetiology: The cause is not known but it is associated with autoimmune disorders.

Symptoms: Itching is prominent or is the main presenting complaint

Signs: In early lesions the skin may be reddish or of normal colour, later on it looks thin with a wrinkled surface and white shiny plaques. If left untreated the contour of the vulva slowly disappears and labial fusion may occur.

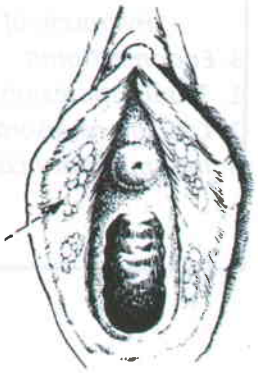

Fig 15-3:

Microscopically: there is hyperkeratosis, flattening of the rete pegs, and a zone of a homogenized pink staining collagenous appearing tissue beneath the epithelium. Lichen sclerosus is often associated with foci of both hyperplastic epithelium and atrophic changes.

Premalignant potential: It is uncertain if lichen sclerosus leads to vulvar cancer. VIN and lichen sclerosus can coexist in the same patient. Approximately 4% of women with lichen sclerosus develop invasive cancer.

Treatment: Topical application of corticosteroid creams or ointment offers the best results.

B. SQUAMOUS CELL HYPERPLASIA:

The term is applied to lesions of epithelial thickening and hyperkeratosis with no specific cause. The lesion may have a dusky red appearance when the degree of hyperkeratosis is slight. At other times well defined white plaques may be seen. Lichenification is seen frequently, while fissures and excoriation, as a result of chronic scratching, may be present. Hyperplastic lesions are best treated by local application of corticosteroids.

VULVAR ULCERS

Most vulvar ulcers are benign however any persistent ulcer should be biopsied to exclude malignancy. Vulvar ulcers may be:

- *Traumatic* e.g. infected tear or episiotomy
- *Syphilitic* ulcer (painless)
- *Tuberculous* ulcer (painful)
- *Herpetic* ulcer (multiple and very painful)
- *Chancroid, lymphogranuloma venerum, and granuloma inguinale* are rarely encountered ulcers related to infection with STDs.
- *Behcet's disease;* (multiple recurrent vulval and oral ulcers)
- *Carcinoma* ulcer (everted edges, indurated base and floor with necrotic tissues)

VULVAR SWELLINGS

A swelling or a mass of the vulva should be differentiated from a mass protruding from the vulva, as cystocoele, rectocele, uterine prolapse, large fibroid polyp, inversion of the uterus, and Gartner cyst. Vulvar swellings may be non neoplastic, or neoplastic (benign or malignant).

Classification of vulvar swellings

Non neoplastic swellings	Neoplastic swellings
1. *Congenital* 2. *Retention cysts* – *Bartholin duct cysts* – *Sebaceous cyst* – *Epidermal inclusion cyst* – *Hydrocele of the canal of Nuck* 3. *Endometrioma* 1. *Traumatic lesions* 2. *Circulatory disorders* 3. *Inflammatory conditions*	*1.Benign tumours* *a. Cystic tumours* b. *Solid tumours* – *Lipoma* – *Fibroma* – *Squamous cell papilloma* – *Hydradenoma* – *Nevus* – *Caruncle* – *Granulomatous caruncle* – *Others: neurofibroma* *2.Malignant tumours*

NON-NEOPLASTIC SWELLINGS OF THE VULVA

1. Congenital: Hypertrophy of the clitoris
2. Retention cysts: These are the result of blockage of ducts of glands:

A. Bartholin's duct cyst: Bartholin cyst is the *commonest vulvar swelling.* It is actually a cyst of the duct and not of the gland. It contains mucoid fluid and is lined by transitional epithelium.

Clinically it appears as a cystic swelling of variable sizes in the posterior part of the labium rnajus. Secondary infection leads to a painful Bartholin abscess, which is tense, tender, sur- rounded by vulvar redness, swelling, and oedema.

Treatment is by marsupialization to create a new opening between the duct wall and the skin. This line of treatment is preferable to excision as it is easier, associated with less bleeding and shorter convalescence, together with preservation of the function of the gland. A penrose drain or a small word catheter may be left for a few days to guard against closure of the tract and recurrence of the cyst.

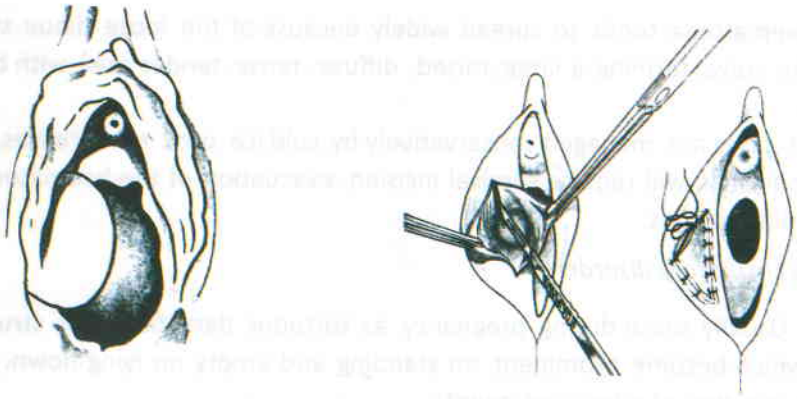

Bartholin duct cyst **Marsupiaalization of the cyst**

Fig 15-4:

B. Sebaceous cyst: sebaceous cysts usually present on the hairy region of the labium majus, as multiple small cysts that contain whitish cheesy sebaceous material. The cyst may become infected and cause pain. If painful they can be surgically removed.

C. Epidermal inclusion cyst:

- *Traumatic inclusion cysts;* may occur from viable stratified squamous epithelium buried beneath either skin or mucosa, which will proliferate and desquamate forming an inclusion cyst. They are commonly seen following episiotomy scars and rarely with circumcision scar (clitoridal cyst).
- *Congenital inclusion cysts;* may rarely originate from embryonic tissue destined to become epithelium which remains in the dermis, or from pilosebaceous ducts that become occluded.
- *Treatment:* Small asymptomatic cysts may need no treatment, but if they are large annoying to the patient or become infected they can be removed surgically under local anaesthesia.

D. Hydrocele of the canal of Nuck: During development, the round ligament (which is inserted in the labia majora) is normally accompanied by a peritoneal pouch called the canal of Nuck which will be normally obliterated later on. Rarely if not obliterated, a cystic collection of serous fluid will accumulate in this pouch forming cystic mass.

Clinically: it forms an elongated translucent swelling in the upper part of the labium majus and may extend to the inguinal canal. Sometimes it can be emptied by pressure on lying down if it communicates with the peritoneal cavity and it may be associated with inguinal hernia.

Treatment: Excision of the sac and dealing with any inguinal hernia.

E. Endometrioma: An endometrioma may arise from either a metaplastic change, or through an embolic origin from the uterus.

Clinically: It is small bluish cyst containing altered blood and lined by endometrial epithelium that increases in size and becomes tender during menstruation.

Treatment: If painful or annoying it may be surgically excised.

F. Traumatic Vulvar haematomas: Vulvar haematomas may occur secondary to vaginal birth trauma associated with extensive vulval and perineal injury in absence of proper ligation of the bleeding vessels. It can also occur due to direct trauma as in car accidents or fall from a height, or following female circumcision.

Clinically; the haematoma tends to spread widely because of the loose tissue structure at the region of the vulva, forming a large, raised, diffuse, tense, tender area with bluish red discolora- tion.

Treatment: Mild cases are managed conservatively by cold ice pack compresses, while large extending haematomas will require surgical incision, evacuation of the haematoma, and ligation of the bleeding vessels.

G. Swelling due to circulatory disorders:

Varicose veins: Usually occur during pregnancy as tortuous dark blue soft structures in one or both labia, which become prominent on standing and empty on lying down. Treatment is by ex- cision or injection of sclerosing agents.

Oedema: It can be the result of a wide variety of systemic and local causes such as nephritic syndrome heart failure and allergic reactions Oedema is usually diffuse and characterized by pallor of the skin and pitting on pressure with the finger.

H. Inflammatory conditions:

Non specific inflammatory vulvitis; results in a diffuse swelling that surrounds the area of the inflammation due to congestion and oedema.

Specific inflammatory conditions; may result in localized lesions, such as Bartholinitis, Bilharzia!

condyloma, syphilitic condyloma lata, or viral condyloma accuminata (HPV).

BENIGN NEOPLASMS OF THE VULVA

A) Cystic tumours

Benign cystic tumours of the vulva are very rare, and are always benign. If large they are removed by simple surgical excision.

B) Solid tumours

- ***Lipoma:*** is found rarely. It arises from the subcutaneous tissues of the vulva and usually becomes pedunculated and dependent with growth. Treatment is by excision.

- ***Fibroma:*** is also uncommon but present as a pedunculated tumour like a lipoma but is firmer. It arises from the fibrous tissue of the round ligament and the vulvar connective tissue. Treatment is by excision. These tumours on occasion become sarcomatous.

- ***Squamous cell papilloma*** is usually a single small lesion, formed of papillae of stratified squamous epithelium, covering a core of vascular connective tissue the clinician has to differentiate it from: condylomata accuminata caused by HPV virus which are usually multiple, fibroepithelial polyps which are small, sessile, or pedunculated pieces of redundant skin, and Bilharzial papillomata.

- ***Hydradenoma:*** It is an unusual lesion that originates from the apocrine sweat glands. It appears as a small nodule on the labium or the interlabial sulcus. Diagnosis and treatment is by exci- sional biopsy. The Hydradenoma is not malignant, although on histologic examination the papillary nature of the tumour may be mistaken for an adenocarcinoma.

- ***Nevus:*** Pigmented nevi occur on the vulva as they do else where, but functional activity, which carries a risk for subsequent malignant transformation is more common in this location. Excisional biopsy should be performed on all pigmented lesions on the vulva so that tissue can be sent for histologic evaluation. These lesions should not be treated by cryosurgery or laser therapy as histologic examination is essential.

- ***Caruncle:*** A small tumour arising from the posterior part of the lower end of the urethra. It is composed of a very vascular stroma, almost like a haemangioma, usually infected and covered with squamous or transitional epithelium. The caruncles are red in colour because of their vas- cularity and are extremely sensitive. The patient is usually an elderly woman complaining of dysuria and bleeding. Treatment is by excision and histological examination although malignant change is rare. The base of the tumour on the urethral mucosa should be cauterised.

- ***Granulomatous caruncle:*** It is a chronic infection of the periurethral tissue. It is called a caruncle but it is not neoplastic and is often symptomless. Granulomatous caruncle is often seen, while a true caruncle is uncommon. Treatment if needed is by cautery and there is a tendency to recurrence. Infection in this area must involve the paraurethral gland network and complete cure is difficult. A search should be made for a vaginal or bladder source of the infection.

- ***Other tumours*** include haemangioma and neurofibroma.

VAGINAL CYSTS

1. Cysts of vestigial structures:

   Wolffian (Mesonephric duct): The majority of vaginal cysts arise from Gartner's duct. They lie on the lateral or anterolateral wall of the vagina from the lateral fornix downwards. They are variable in size. The lining is a single layer of cuboidal epithelium.

   Mullerian (Para-mesonephric duct): Rare, may be up near the cervix

2. Endometriotic cysts
3. Epidermoid cyst; implantation dermoid mainly due to obstetric laceration or episiotomy.

BENIGN VAGINAL NEOPLASMS

Benign Neoplasms of the vagina are rare. Some are paravaginal rather than vaginal, in that they arise in tissues in the paracolpos.

- Common vaginal neoplasms include: Papilloma, Angioma, Fibroma, and Lipoma.
- Clinically they may be sessile or pedunculated.
- Diagnosis; is by digital vaginal examination and naked eye speculum examination. Pelvic ultrasound, CT scan and MRI can all also diagnose larger swelling if vaginal examination is not accessible (example in virgins)
- Treatment; surgical excision if large or infected.

KEY POINTSEY POINTS

- *Leucorrhea is a term that describes excessive normal vaginal discharge.*
- *Infected discharge may be mucopurulent, purulent, or sanguinous. It may occur secon-*
- *dary to vaginitis, cervicitis, endometritis, or tumours of the cervix, vagina or endometrium.*
- *Vulval itching is the most common vulval complaint. It is most commonly secondary to vulvo-vaginal Candidiasis, Trichomonal infections, or lichen sclerosus et atrophicus.*
- *Pruritus vulvae refer to the intractable vulval itching in absence of a defined lesion, strong steroid creams are effective in relieving the symptoms*

16 PELVIC ORGAN PROLPASE AND UTERINE DISPLACEMENTS

- Utero-vaginal Prolapse
- Uterine Displacements
- Uterine Inversion

PELVIC ORGAN PROLPASE (POP)

- **Pelvic organ prolapse (POP)** refers to descent of one or more of the pelvic organs below their normal anatomical positions, downwards through the vagina.
- **POP** occurs in nearly **12-30%** of women, however the incidence significantly increases by both age and repeated vaginal deliveries, due to progressive weakness of pelvic supports.
- **The anteverted anteflexed position** of the uterus results in a **forward tilt** towards the symphysis pubis that helps in preventing it's downwards descent during increased intra-abdominal pressure (as during straining, chronic cough, and constipation, etc...).

SUPPORTS OF THE PELVIC ORGANS

The uterus and other pelvic organs are kept in normal anatomical positions by their surrounding fascia, ligaments, and muscles. The main supports of pelvic organs include:

A) **Endopelvic Fascia:** including vaginal, cervical, perivesical, and rectal fascia.

B) **Pelvic Ligaments:** condensations of the endopelvic fascia into strong ligaments attached to the cervix form the **main support** of the uterus and pelvic organs.

- *The Mackenrodt's ligaments:* the most important support of the uterus. It spreads from the lateral pelvic walls, passes medially to be inserted in the supravaginal part of the cervix and upper vaginal vault (see anatomy).
- *The uterosacral ligaments:* spread from the sacrum posteriorly to the back of the supravaginal part of the cervix.
- *The pubocervical ligament:* spreads from the back of symphysis pubis anteriorly to the front of the supravaginal part of the cervix.

C) **Pelvic floor muscles:** most important are **the levators ani muscles** with its 3 parts;

- *The pubo-coccygeus:* the most important part of the muscle support
- *The ischio*-coccygeus
- *The Ilio*-coccygeus

D) **Additional support of pelvic organs** is also provided by the perineal body, perineal muscles and their innervations.

N.B.: *See anatomy of pelvic fascia and ligaments Chapter 2 for figures and details*

TYPES OF PROLPASE

A) VAGINAL PROLAPSE:

1. Anterior compartment:

- Urerthrocele: descent of urethra + uppermost 2-3 cm of attached vagina
- Cystocele: descent of the urinary bladder + upper 2/3 of anterior vaginal wall
- Cysto-urothrocele: full vaginal length + bladder and urethra

2. Posterior compartment:

- Rectocele: middle 1/3 of posterior vaginal wall + rectum
- Enterocele: upper 1/3 of posterior vaginal wall + small bowel loops

3. Central compartment (Apical):

- Utero-vaginal prolapse: uterine descent wit inversion of the vaginal apex
- Vault prolapse: descent of the blind ended vaginal apex after hysterectomy

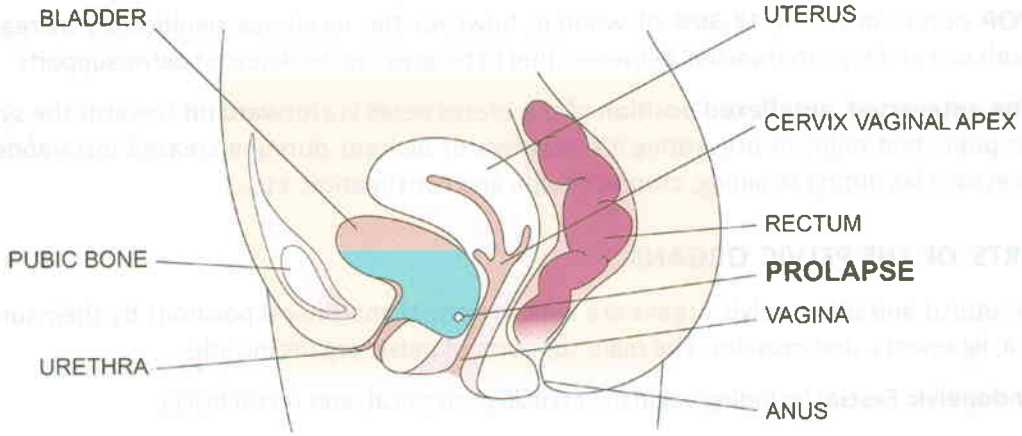

Fig 16-1: Cystocele

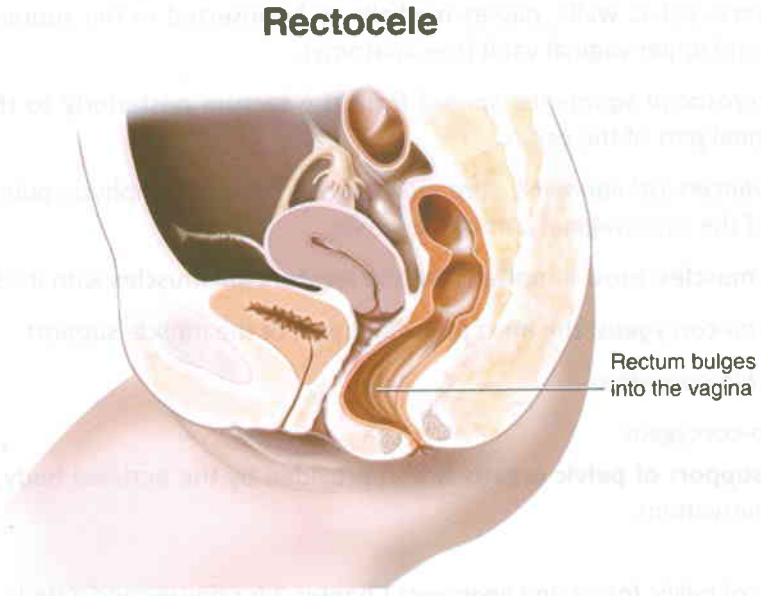

Fig 16-2: Rectocele

B) UTERINE PROLAPSE

In uterine prolapse descent of the uterus is judged by the level of the cervix, where the external cervical os normally lies at the level of the ischial spines.

- **1st Degree:** The cervix descends downwards through the vagina, but the external os does not reaching the introitus (hymenal ring).
- **2nd Degree:** The external os reaches or slightly protrudes outside the introitus
- **3rd Degree:** The whole uterus except the fundus descends outside the introitus
- **Procidentia:** The whole uterus including the fundus descends outside the introitus.

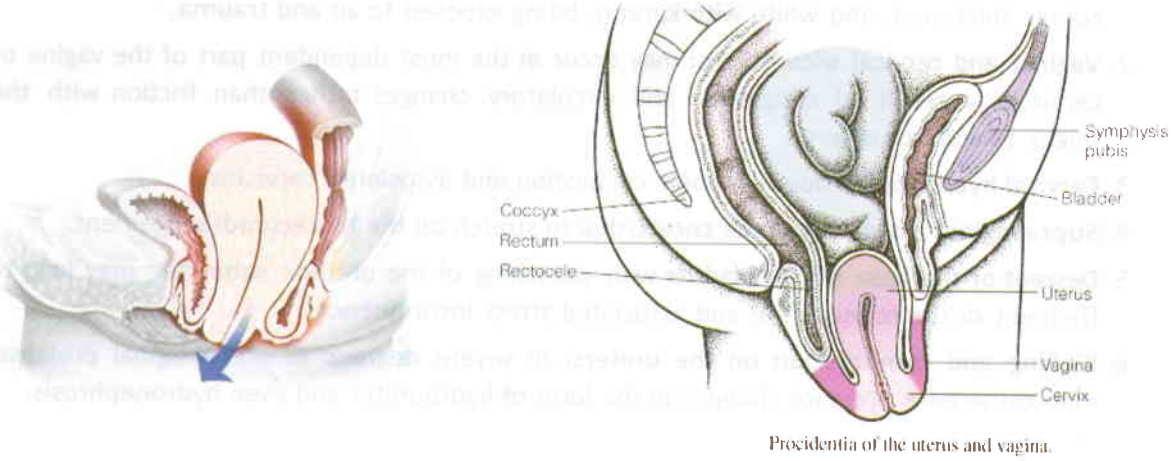

Fig 16-3: Degrees of uterine prolapse

RISK FACTORS FOR POP

Weakness of the pelvic organs support (fascia, ligaments and muscles), is the main predisposing factor for POP. Risk factors for weak pelvic organ support include;

A) CHILDBIRTH TRAUMA:

Damage to the pelvic supports during vaginal birth trauma is the most frequently encountered risk factor for POP. This might be due to overstretch of the cellular tissue and damage to the muscular innervations. It is aggravated by the following conditions;

- *Difficult labour* with oversized fetus and/or prolonged 2nd stage
- *Short interval successive deliveries* without appropriate involution periods.
- *Direct pelvic floor injury* as in perineal lacerations without prompt repair

B) MENOPAUSAL ATROPHY:

Older menopausal women are at higher risk for POP due to degenerative changes in pelvic supports secondary to prolonged oestrogen deficiency. Risk increases by increased age.

C) CONGENITAL WEAKNESS:

POP may occur in some women in a young age and in absence of childbirth trauma. This will mostly attributed to congenital weakness in pelvic fascia, ligaments, and muscles. It may be associated with poor innervations (as in spina bifida), or generally poor mesenchyme with associated abdominal wall hernia, rectal prolapse, and or visceroptosis.

D) IATROGENIC WEAKNESS:

This might be induced by improper technique for supporting vaginal vault during abdominal or vaginal hysterectomy, hence increasing the risk for vaginal vault prolapse.

N.B: Precipitating Factors: chronically increased intra-abdominal pressure as occurring in chronic cough and constipation may act as an important precipitating factor for POP, especially in elderly high risk women. And unless properly managed it will act as a major cause for recurrence of the prolapse after surgical treatment.

ANATOMICAL CHANGES ASSOCIATED WITH LONG STANDING PROLAPSE

1. **Vaginal skin Keratinization:** everted vaginal skin in cases of prolonged vaginal prolapse becomes thickened, and white with keratin, being exposed to air and trauma.
2. **Vaginal and cervical ulcerations:** may occur at the most dependent part of the vagina or cervix as a result of congestion and circulatory changes rather than friction with the thighs (decubitus ulcers).
3. **Cervical hypertrophy:** due to chronic congestion and associated cervicitis.
4. **Supravaginal elongation of the cervix;** due to stretch on the Mackenrodt's ligament.
5. **Descent of the base of the bladder** with stretching of the urethral sphincter; may lead to frequent desire to micturate and associated stress incontinence.
6. **Kinking and compression on the ureters;** in severe degrees of utero-vaginal prolapse, may cause back pressure changes in the form of hydroureter and even hydronephrosis.

CLINICAL PICTURE OF GENITAL PROLAPSE

A) COMMON SYMPTOMS

In general **mild cases** with **minimal degrees** of utero-vaginal prolapse are **asymptomatic.** The **more severe degrees** of POP may be associated with one or more of the following symptoms;

1. **Sensation of pelvic heaviness;** especially towards the end of the day that improves or disappears by rest.
2. **A mass filling the vagina or protruding from the introitus;** that may be felt by the patient on straining or squatting, and disappears by lying down on the back, or by reduction.
3. **Low backache;** is common in cases of *uterine prolapse*. Pain is dull aching, or dragging, that radiates to the thighs and legs. It is stimulated by prolonged walk, hard work, or heavy weight lifting. Pain is usually relieved or decreased by rest and lying down on the back. Pain is explained by marked traction on uterosacral ligaments by the prolonged uterine descent.
4. **Urinary symptoms:** are common in the presence of a *cystocele*, as;
   - *Frequency of micturition by day;* due to mechanical irritation of the trigone.
   - *Frequency may develop by night (nocturia);* due to residual urine cystitis.
   - *Stress urinary incontinence SUI* (escape of urine during cough or straining).
   - *Inability to complete micturition* unless the anterior vaginal wall is reduced upwards and supported by the patient's fingers, to empty residual urine in a bladder pouch.
5. **Rectal symptoms:** as heaviness and difficulty when trying to defecate in cases of *rectocele*.
6. **Pelvic congestion symptoms:** in the form of *Dysmenorrhoea* and *Leucorrhoea:*

B) SIGNS ON CLINICAL EXAMINATION

1. GENERAL EXAMINATION

Chest and Abdominal examination are essential to rule out causes for chronic increase in intra-abdominal pressure, as chronic cough, hepato-splenomegaly,ascites, pelvic masses, etc...

2. LOCAL EXAMINATION:

Local examination of the prolapsed mass is performed with the patient in the lithotomy position while maximum straining:

A) Inspection: to detect

- Type of prolapse (vaginal, or utero-vaginal)
- Degree of uterine prolapse if present (1st, 2nd, or 3rd degree or procidentia).
- Presence of skin changes or decubitus ulcers
- Associated patulous introitus

B) Digital Palpation:

- PR examination to test for extent of rectal involvement in rectocele
- Test for levators ani function and strength by pressing index and middle fingers on perineal body muscles.
- Test for complete procidentia by being able to approximate the index and thumb fingers above the fundus of prolapsed uterus

C) Diagnosis of associated conditions; as

- *Supravaginal elongation of the cervix:* using a uterine sound measure
- *Stress Urinary Incontinence (SUI):* by asking the patient to cough during examination to detect involuntary escpe of urine through urethra (see SUI chapter)
- *Test for enterocele;* via eliciting impulse on cough, and or gurgle sensation at the vaginal vault. Combined PV & PR examination may add to accuracy of diagnosis.

DIFFERENTIAL DIAGNOSIS OF POP

A. *Cystocele and Rectocele:* are differentiated from cysts of anterior and posterior vaginal walls, as inclusion dermoid cysts, which are usually small in size, cystic, tense, slightly tender, and non-compressible or reducible.

B. *Urethrocele:* should be differentiated from urethral diverticulum, which on compression will lead to discharge of urine or pus via external urethral meatus

C. *Uterine prolapse:* should be differentiated from swellings protruding from the vulva as; large fibroid polyp, and chronic inversion of the uterus.

PREVENTION OF POP

- Adequate spacing of deliveries to allow proper involution.
- Avoid marked obesity and excessive rapid weight gain
- Avoid bearing down in the 1st stage of labour before full cervical dilatation
- Avoid difficult and prolonged labour especially in the 2nd stage
- Avoid damage to perineal muscles and pelvic fascia by proper episiotomy performance, when indicated, and proper technique of repair
- Proper treatment of chronic cough and constipation, with prompt management of pelvi-abdominal swellings.

MANAGEMENT OF POP

The choice of treatment for genital prolapse depends on several factors including;

- Type and degree of prolapse
- Desire for future pregnancies
- Need for preservation of coital function.
- Acceptance and readiness for surgical treatment.



A) NON SURGICAL MEASURES

- *Pelvic floor exercise (Kegel exercises):* may delay the need for surgery in mild cases.
- *Pessary treatment:* is only a temporary option aiming at temporary reduction of the prolapsed organs until the patient is ready for surgery, or in cases where surgical intervention poses unacceptable risks on the patient's health.



Fig 16-4: Pessary treatment for uterovaginal prolpase

SURGICAL TREATMENT FOR POP

Surgical treatment is the only curative approach for moderate and severe cases.

1. ANTERIOR COLPORRHAPHY:

- For repair of the anterior vaginal wall and associated **cystocele**.
- The anterior vaginal wall is opened and vesicovaginal fascia dissected.
- The bladder is pushed upwards to its normal position
- The fascial defect is repaired and plicated by interrupted delayed absorbable sutures.
- Excess vagina is removed and vagina packed with gauze for compression haemostasis
- *Associated urethrocele* is managed by extending vaginal dissection to periurethral fascia and its plication
- Associated stress urinary incontinence is managed by either;
  - Periurethral fascia plication using Kelly's sutures, or
  - Tension Obturator Tape (TOT) plication.

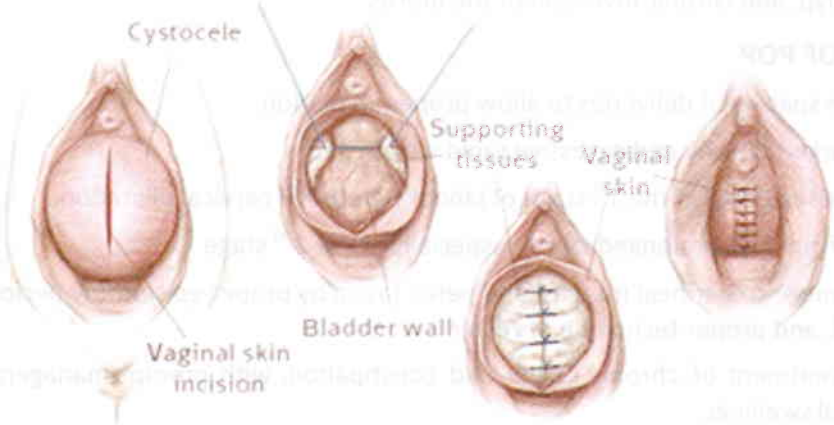

Fig 16-5: Anterior colporrhaphy for cystocele

2) POSTERIOR COLPOPERINEORRHAPHY

- For repair of posterior vaginal wall prolapse and associated **rectocele**
- The posterior vaginal wall is opened and rectovaginal fascia dissected
- The rectum is pushed downwards to its normal position.
- The fascial defect is repaired and closed by interrupted delayed absorbable sutures
- The Perineal body is reconstructed and pubococcygeus muscle approximated at the four-chette.
- Excess vagina is removed and vagina is packed with gauze for compression haemostasis

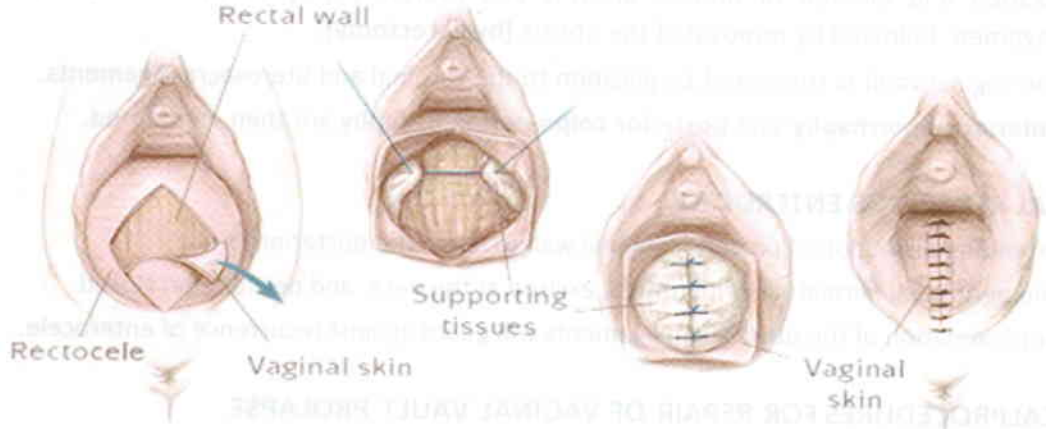

Fig 16-6: Posterior colpoperineorrhaphy

3. CLASSICAL REPAIR

- Cases of **cysto-rectocele** are best managed by anterior colporrhaphy + posterior colpoperineorrhaphy.
- Associated 1st degree uterine prolapse is managed by **shortening of Mackenrodt's ligament** and their plication infront of the cervix.

4. MANCHESTER (FOTHERGILL'S) OPERATION

- Cases of 2nd degree uterine prolapse with marked **supravaginal elongation of the cervix** are best managed by **amputation of the vaginal portion of the cervix** and **shortening of the Mackenrodt's ligament**.
- Associated cystorectocele is managed by classical repair.

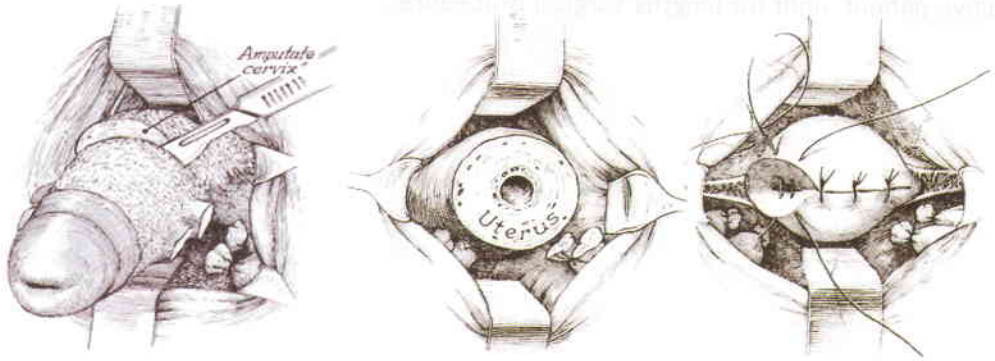

Fig 16-7: Manchester operation

5. VAGINAL HYSTERCTOMY AND FASCIAL REPAIR

1. Indicated in perimenopausal and postmenopausal patients with marked uterovaginal prolapse.
2. A circumferential incision is performed around the cervix at cervico-vaginal junction.
3. Dissection of the anterior and posterior vaginal walls from the surrounding fascia
4. Clamping the uterosacral and mackenrodt's ligaments
5. Ligation and division of uterine arteries and ovarian artery at the infunbulo-pelvic lihgamen, followed by removal of the uterus **(hysterectomy).**
6. The vaginal vault is supported by plication to the cardinal and uterosacral ligaments.
7. **Anterior colporrhaphy** and **posterior colpo-perineorrhaphy** are then completed.

SURGICAL REPAIR FOR ENTEROCELE

1. Extending dissection of posterior vaginal wall to reach the posterior fornix
2. The peritoneal hernial sac is identified, excised at the neck, and peritoneum closed.
3. Approximation of the uterosacral ligaments will guard against recurrence of enterocele.

SURGICALPROCEDURES FOR REPAIR OF VAGINAL VAULT PROLAPSE

1. **Abdominal sacro-colpopexy:** The vaginal vault is sutured **posteriorly** to the sacral promontory using non absorbable suture material, via a laparotomy incision.
2. **Vaginal sacrospinous ligament fixation:** The vaginal vault is sutured to the sacrospinous ligament at one side via vaginal approach.
3. **Vaginal Mesh repairs:** recurrence of prolapse after surgical correction may occur with up to 30% of cases requiring a second operation within 5 years. Recurrence may be due to the weak connective tissue even before the original operation was performed. Mesh augmented pelvic floor repair is gaining more interest recently aiming at improving tissue strength and support.
4. **Le Fort's operations:** The procedure aims at obliteration of the vagina, except for two small channels on either side through which the normal cervical discharges can escape. Rectangular flaps are excised from the anterior and posterior vaginal walls the raw areas are sutured together. The procedure is reserved for the very old, flail, non sexually active patient, unfit for lengthy surgical procedures.

RETROVERSION FLEXION OF THE UTERUS (RVF)

ANATOMICAL CONSIDERATIONS:

- **Anteversion:** The uterus is almost at right angle to the vagina, with a slight forward curve.
- **Anteflexion:** The body of the uterus is bent forwards upon the axis of the cervix.
- **Retroversion:** The longitudinal axis of the uterus is directed backwards.
- **Retroflexion:** The body of the uterus is curved backwards upon the axis of the cervix

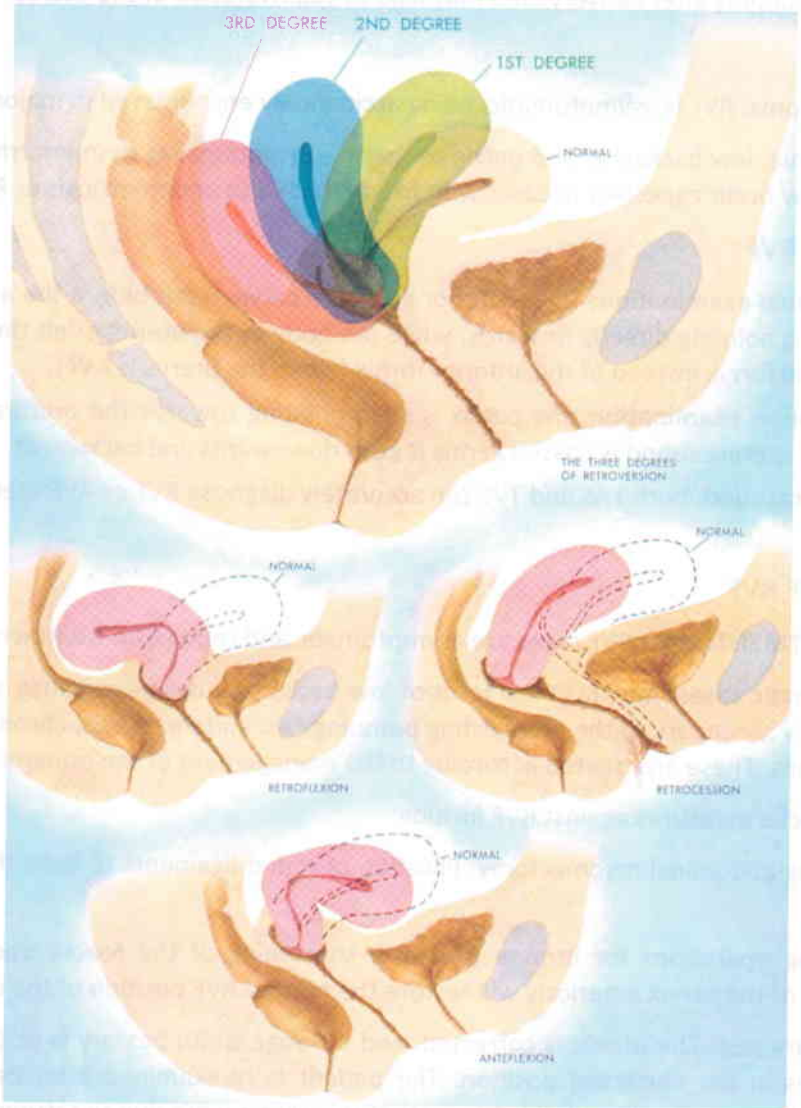

Fig. 16-8: RVF uterus

AETIOLOGY OF RVF

A. **Congenital RVF:** Is the most common type, normally present in about 10-20% of women. It gives no symptoms and requires no treatment. The uterus is usually mobile RVF.

B. **Acquired RVF:** may occur secondary to a large fundal myoma pushing the uterus backwards, pelvic adhesions as in endometriosis or chronic PID pulling the fundus posteriorly. The uterus is usually fixed RVF

C. **Puerperal retroversion;** may occur due to increased weight of the uterus and laxity of pelvic ligament support after delivery, and may lead to subinvolution of the uterus.

SYMPTOMS

1. **No symptoms:** RVF is asymptomatic, being accidentally encountered in majority of cases.
2. Dyspareunia, low backache, and pelvic congestive symptoms (as dysmenorrhoea and leucorrhoea) may occur especially in cases with fixed RVF due to endometriosis or PID.

DIAGNOSIS OF RVF

a. **On bimanual examination:** The posterior lip of the cervix is felt before the anterior, with the external os pointing directly forwards, while the body of the uterus is felt through the posterior vaginal fornix instead of the anterior fornix (when the uterus is AVF).

b. **On speculum examination:** the cervix is seen pointing towards the urethra and symphysis pubis. If a uterine sound is passed gently it goes downwards and backwards.

c. **Pelvic ultrasound:** both TAS and TVS can accurately diagnose RVF or AVF uterus

TREATMENT OF RVF

1. **NO TREATMENT:** most RVF cases are asymptomatic and require no treatment.
2. **Symptomatic cases:** mostly in the form of low back ache, dysmenorrhoea and dyspareunia, are usually secondary to the pre-existing pathology as; endometriosis, chronic PID, and cervical erosions. These are treated according to the management of the primary cause.
3. **Prophylactic measures** against RVF include:
   - During abdominal myomectomy: Plication of round ligaments to keep the fundus anteriorly.
   - During operations for uterine prolapse; shortening of the Mackenrodt's ligaments in front of the cervix anteriorly will restore the normal AVF position of the uterus.
   - Pessary test: The uterus is corrected, and a Hodge smith pessary is inserted to keep the uterus in the corrected position. The patient is re-examined after one month, if her symptoms were relieved, this means that symptoms were due to retroversion.

INVERSION OF THE UTERUS

Inversion of the uterus is a very rare condition in which the uterus is partially or completely turned inside out. It may be either;

- Acute **puerperal inversion;** may be encountered as a complication of the 3rd stage of labour due to forcible traction on the placenta *(see obstetrical complications of 3rd stage of labour).*
- Chronic **inversion;** may occur as a sequel of a neglected or overlooked acute puerperal inversion, or secondary to dragging of the uterine fundus by a submucus myoma.

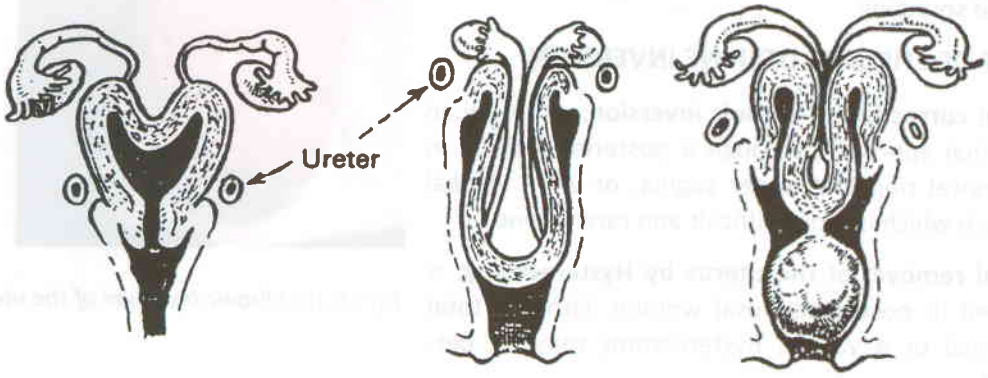

Fig 16-9: Inversion of the uterus

Pathogenesis and degrees:

Inversion of the uterus starts with a depression or cupping of the uterine fundus which does not reach the cervix (1st degree). It then continues downwards to reach, or protrudes from, the cervical canal (2nd degree). Finally the whole uterus is inverted and may protrude through the introitus (3rd degree).

Symptoms: cases may present with deep pelvic pain associated with vaginal bleeding or bloody discharge, with or without a mass filling the vagina

Signs: Bimanual pelvic examination may reveal fundal cupping and a mass protruding through cervix. Speculum examination may show a red mass is seen in the vagina resembling a fibroid polyp. Ultrasonography may help confirm the diagnosis

Differential Diagnosis

1. A fibroid polyp protruding through the cervix. Here the uterus is felt normally bimanually (no cupping), there is an external os and a uterine sound can be introduced normally.
2. A mass protruding in the vagina e.g. uterine Prolapse or sarcoma or a cauliflower cancer cervix Differentiated by the presence of the cervix; bimanual examination and sounding.

TREATMENT OF CHRONIC UTERINE INVERSION

- **Surgical correction of chronic inversion**; either by an abdominal approach, through a posterior incision in the cervical ring and upper vagina, or via a vaginal approach which is more difficult and rarely done.
- **Surgical removal of the uterus by Hysterectomy;** is indicated in postmenopausal women. Either a total abdominal or a vaginal hysterectomy may be performed.



Fig 16-10: Chronic Inversion of the uterus

Key points in POP

- *The genital organs are kept in their normal anatomical positions by the pelvic ligaments, fascia, and pelvic floor muscles.*
- *The primary cause of genital prolapse is weakness of the supporting structures of the uterus and vagina, usually as a result of childbirth trauma.*
- *POP could be either vaginal, or uterovaginal prolapse, and may include other organs as the bladder, rectum, or bowel.*
- *Symptoms of prolapse are generally non specific. Cystocele and Urethrocele are commonly associated with urinary symptoms. Rectocele has less marked symptoms.*
- *Uterine prolapse is mostly associated with backache towards the end of the day, aggravated by activity and relieved by lying down and rest.*
- *Clinical examination reveals a mass filling or protruding from the vagina on straining*
- *In mild cases conservative approaches may be sufficient*
- *Pessary treatment is only a temporary approach for relief of symptoms until surgery becomes feasible, or in the extremely morbid patient at very high risk for surgery.*
- *Surgical treatment by repair of the fascia and restoration of uterine position is the mainstay of treatment in moderate and severe cases.*
- *The choice of the surgical procedure and sound surgical techniques are crucial for the success of primary surgery and for avoiding recurrences.*

17 PERINEAL LACERATIONS FOECAL INCONTINENCE AND RECTOVAGINAL FISTULA

- *Perineal lacerations*
- *Old complete perineal tear*
- *Rectovaginal fistula*

PERINEAL LACERATIONS

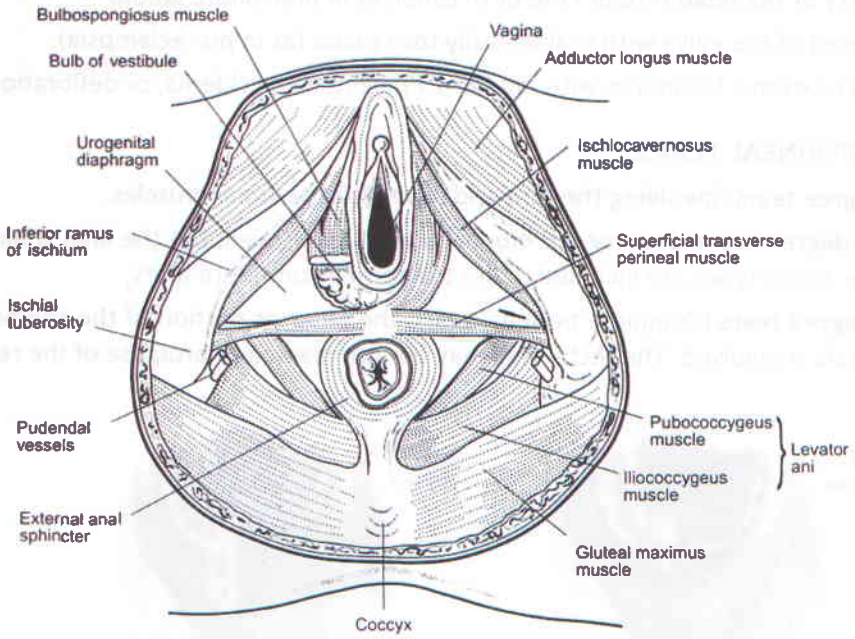

Fig. 17-1: Anatomy of the Perineal Body

ANATOMY OF THE PERINEAL BODY

The perineal body is the pyramidal shaped mass of tissue wedged in be-tween the vagina and the lower part of the rectum. It is composed of the following layers from without inwards.

1. Skin and Subcutaneous fat
2. Superficial perineal muscles: the external anal sphincter, the bulbocavernosus (sphincter vaginae), the transversus perinei, and the ischiocavernosus. All except the ischiocavernosus have one insertion in the central part of the perineal body.
3. The decussation of the levator ani muscles (deep perineal muscles) be-tween the vagina and rectum forms the apex of the perineal body.

CAUSES OF PERINEAL LACERATION

A) Bad management of the 2nd stage of labour: (the commonest causes)

- Allowing premature extension of the foetal head before crowning.
- Lack of adequate perineal support during delivery of the foetal head.
- Instrumental delivery without an adequate episiotomy

B) Inadequately performed episiotomy in association with;

- Delivery of malpositions and malpresentations associated with larger diameters of the delivered head, as in cases of direct occipito posterior (face to pubis), face mento-anterior, and after-coming head in breech deliveries.
- The use of instrumental delivery as the forceps or the vacuum extractor.
- Rigid perineum (as elderly primigravidas, and previous perineal scars)
- Narrow subpubic angle (displacing the head posteriorly with excessive perineal stretching)

C) Rapid delivery of the head through the birth canal; as in precipitate labour

D) Severe oedema of the vulva with friable easily torn tissue (as in pre-eclampsia).

E) Rarely; Direct external trauma as with fall from a height, car accidents, or defloration injuries.

DEGREES OF PERINEAL TEARS:

1. **First degree tears: involving the *skin* and *superficial perineal muscles*.**
2. **Second degree tears**: ***Levator ani muscle*** is involved as well, but the anal sphincter is intact. Both the above types are included under the term incom-plete tears.
3. **Third degree tears** (Complete perineal tear): the anterior portion of the sphincter ani externus muscle is involved. The rectal wall may be torn leading to prolapse of the rectal mucosa.

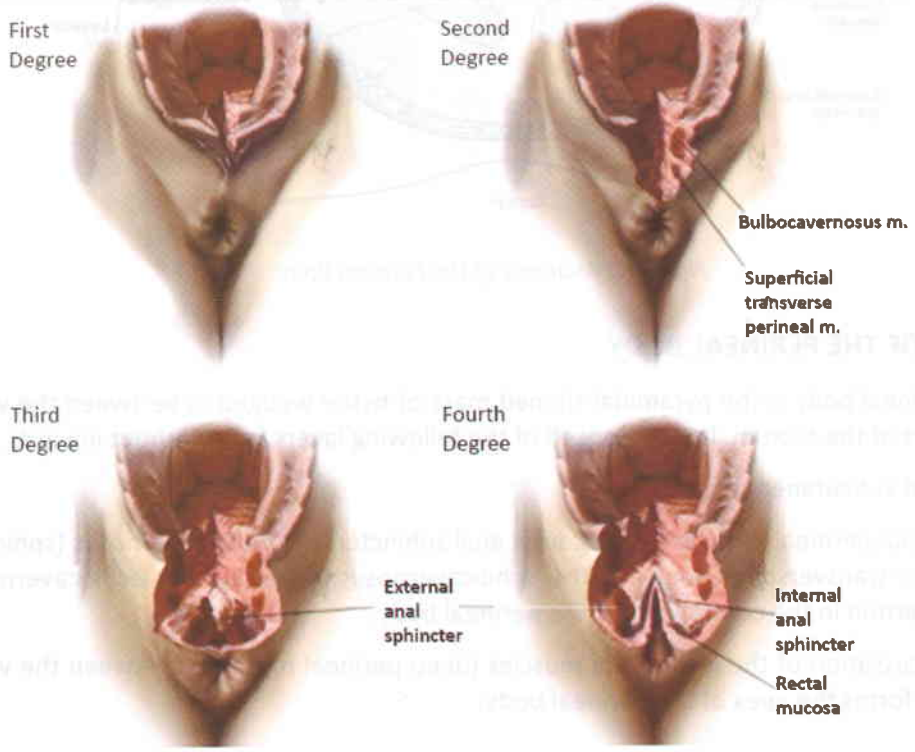

Fig. 17-2: Degrees of Perineal Tears

COMPLICATIONS OF PERINEAL TEARS:

1. Postpartum haemorrhage, due to bleeding from lacerations.
2. Infection may occur in the laceration site (puerperal sepsis).
3. Patulous vaginal introitus with unsatisfactory sexual function.
4. Incomplete tears; may predispose to genital prolapse (due to loss of pelvic floor support).
5. Complete tears may lead to Incontinence to stools and flatus due to division of the sphincter ani muscle. After sometime, some patients will learn to contract the levator muscles and can control the passage of solid faecal matter, but remains incontinent to liquid stools and flatus.
6. Residual rectovaginal fistula.
7. Dyspareunia from a tender scar in the vagina.

PREVENTION OF PERINEAL LACERATIONS

1. Proper management of 2nd stage of labour, by maintaining flexion of the foetal head until crowning occur, then allowing for slow delivery of the head in between uterine contractions.
2. Episiotomy, when the perineum threatens to tear and routinely with instrumental delivery.

MANAGEMENT OF PERINEAL LACERATIONS

Every perineal tear, however, small, should be repaired. Primary suture is possible if done within the first 24 hours If the case is seen later than that, it is considered as a septic wound, and left to heal by granulat-ion, Repair in such cases is postponed until all signs of infection have disappeared, usually 3-6 month later.

The post-operative care after perineorrhaphy will be described later. It aims at keeping the wound DRY AND CLEAN to encourage healing by primary intention.

A) Recent 1st and 2nd degree perineal lacerations:

1. The levator ani is approximated by at least three interrupted sutures.
2. Superficial perineal muscles and fascia are approximated with interrupted sutures.
3. The vagina and skin are finally sutured as in an episiotomy repair.

B) Recent 3rd degree perineal lacerations

- ***The rectal wall;*** is sutured in 2 layers by delayed absorbable type of sutures, first continuous then interrupted sutures *not* going through the rectal mucosa. The sutures should extend well above the apex of the laceration.
- ***The anal sphincter;*** the cut ends of the anal sphincter are identified and sutured

OLD COMPLETE PERINEAL TEAR

Definition and aetiology:

An old complete perineal tear is a 3rd degree perineal laceration that has occurred usually during childbirth but was missed at the time of delivery or improperly sutured and repaired.

Symptoms and clinical presentation:

- The wound will heal by granulation tissue leaving an ugly scar with a weak anal sphincter leading in some cases to incontinence for stools or flatus or both.
- Many patients will be able to regain control over the passage of hard stools, but remain incontinent to flatus, and usually complain of persistent leucorrhoea.

Signs on clinical examination:

a. *A defect is noted in the perineal body*, extending to the anal opening.
b. *If the rectal wall is also torn*, the bright red colour of the rectal mucosa is apparent in the lower part of the defect.
c. *On each side of the anus* a small shallow pit is seen in the skin. These two dimples indicate the site of the cut retracted ends of the anal sphincter.
d. *Absence of the normal corrugations around the anus*, except posteriorly.
e. *A finger introduced in the anus* will confirm absence of sphincter control if the patient is asked to contract her muscles.

Pre-operative Preparation

The patient is admitted to hospital ***3 days before the operation,*** during which:

1. A purge is given to empty the bowel, with daily cleansing enema and vaginal douches.
2. The patient is kept on a non-residue fluid diet (free of milk).
3. Intestinal antiseptics (as neomycin or streptomycin) are started orally 3 days preoperatively.

Operation for old complete perineal tear:

- An H-shaped incision is made in the skin, with the horizontal limb of the H at the junction of the rectum with the vagina and the two vertical limbs; at the site of the two dimples.
- The incision is deepened to expose the **various** structures of the perineal body, and the vagina is separated from the rectum.
- The rectal wall and the cut ends of the anal sphincter are repaired as mentioned before in the management of recent 3rd degree perineal laceration
- A posterior colpo-perineorrhaphy is then performed following the steps described in treating rectocele. The vagina is packed tightly, and a urinary catheter is inserted until the pack is removed.

Postoperative After-care:

- The vulva is regularly washed with antiseptic solutions then dried (at least 3 times daily).
- The low residue diet is continued, as well as the intestinal antiseptic.
- Antibiotics against wound infection (systemic and possibly local creams or gel).
- The vaginal pack is removed after 24 hours.
- On the fifth night the patient is given oral purgative solutions (as 50 ml. castor oil) in order to lubricate the stools. After that the patient is given daily oral laxatives and stool softeners to avoid constipation.

N.B.; *in the event of subsequent pregnancy, a postero-lateral episiotomy should be done before delivery of the head to avoid recurrence of the laceration*

RECTO-VAGINAL FISTULA

AETIOLOGY

1. **Congenital** recto-vaginal fistulae are very rare.
2. **Traumatic** RV fistula:
   a. ***Obstetric trauma:*** the commonest cause of a recto-vaginal fistula is badly healed, complete perineal tear: the lower part of the tear heals satisfactorily, but the upper part breaks down due to sepsis or bad technique in suturing, resulting in a communication between the two passages.
   b. ***Surgical trauma:*** as injury to the rectum during posterior colpo-perineorrhaphy (in treatment of a rectocele), or during vaginal hysterectomy.
   c. ***Other rare causes***; include defloration injuries, and ulceration of an ill-fitting neglected pessary.
3. **Inflammatory** conditions: as following rupture of a peri-rectal or peri-anal abscess.
4. **Malignant** RV fistula may occur due to direct extension of malignant disease from the cervix, vagina, or anterior rectal wall.
5. **Post-irradiation** fistulae are frequently seen as complications of radium treatment. They are always associated with symptoms of severe proctitis.

SYMPTOMS

a. Large RV-fistulae: are associated with loss of voluntary control over passage of faeces and flatus, in addition to persistent leucorrhoea, due to the associated 2ry vaginitis.
b. Small RV-fistula: the patient's may complain only of involuntary escape of flatus, which she feels as coming from the vagina

TREATMENT

The treatment of non malignant RV-fistulae is **essentially surgical**. Preoperative and postoperative care of the patient are crucial for the success of the procedure, and they generally follow same rules as that described for old complete perineal tears.

A) Fistulas in the lower third of the vagina:

- Are managed by cutting the remaining bridge of tissue below the fistula, thus converting the fistula into a complete peri-neal tear ***(Lawson Tait's operation)***. The tear is now sutured in layers, in the same manner and order described under repair of complete tears.

B) Fistulas in the middle third of vagina:

- May be closed in the same manner for dealing with vesico-vaginal fistulae (see chapter).
- An alternative procedure is to start the operation as in perineorrhaphy for rectocele and to extend the dissection of the recto-vaginal septum upwards above the fistula. The hole in the rectum is then closed, and the operation continued as a perineorrhaphy.

C) Fistulas in the upper third:

- High recto-vaginal fistulas are usually surrounded by dense fibrosis, and are difficult to close vaginally. They are usually best dealt with by an abdominal (trans-peritoneal) operation

18 URINARY INCONTINENCE

- *Anatomy of the urinary bladder*
- *Control of micturition*
- *Urethral incontinence*

Genito-urinary fistula
- *Vesico-vaginal fistula*
- *Uretro-vaginal fistula*

ANATOMICAL CONSIDERATIONS

- **The detrusor muscle** of the urinary bladder is composed of a meshwork of muscle fibres that allows for reduction in all of its diameters when it contracts. It has a rich cholinergic parasympathetic supply (S: 2, 3, 4).
- **The urethra** is a 3-5 cm long thin-walled muscular tube that opens in the vestibule of the vagina. The urethral smooth muscle fibres are innervated by sympathetic fibres (T10, 11, 12).
- **The internal urethral sphincter** (involuntary) is formed by a thickening of the detrusor muscle at the vesico-urethral junction.
- **The external urethral sphincter** (voluntary) is a skeletal muscle that surrounds the urethra as it passes through the urogenital diaphragm.
- **The urogenital diaphragm** is part of the muscular portion of the pelvic floor that provides a stable base on which the bladder neck and proximal urethra rest

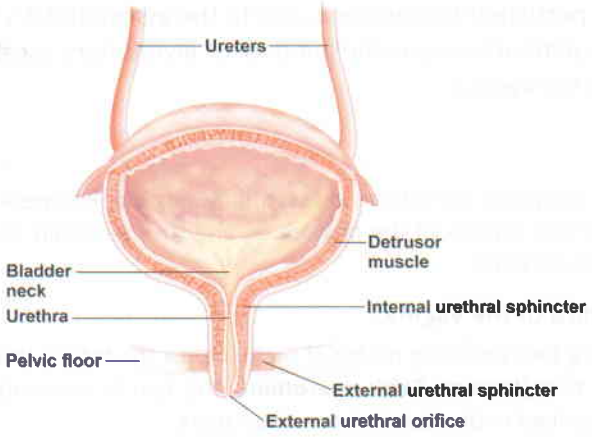

Fig 18-1: anatomy of the urinary bladder

CONTROL OF MICTURITION

- During rest accumulation of urine in the bladder activates stretch receptors in its wall causing reflex relaxation of the detrusor muscle and contraction of the external urethral sphincter.
- When about 200 ml of urine have accumulated, impulses are sent to the brain and one begins to feel the urge to urinate.
- Activation of the micturition center in the pons signals parasympathetic neurons that stimulate contraction of the detrusor muscle and relaxation of the internal urethral sphincter

URINARY INCONTINENCE

DEFINITIONS

- **Continence of urine;** is the ability to hold urine at all times except during voiding. To achieve this intra-urethral pressure **(IUPR)** is normally always kept higher than intra-vesical pressure **(IVPR).**
- **Incontinence of urine;** is the involuntary leakage of urine that is objectively demonstrable.

CLASSIFICATION AND TYPES OF FEMALE URINARY INCONTINENCE

A) Urethral incontinence:

1. Stress urinary incontinence **(SUI)**
2. Urge incontinence (detrusor over activity **DO**)
3. Retention with overflow
4. Nocturnal enuresis
5. Urethro-vaginal fistula

B) Extra-urethral incontinence:

- Genito-urinary fistulas **(GUF),** apart from urethro-vaginal type

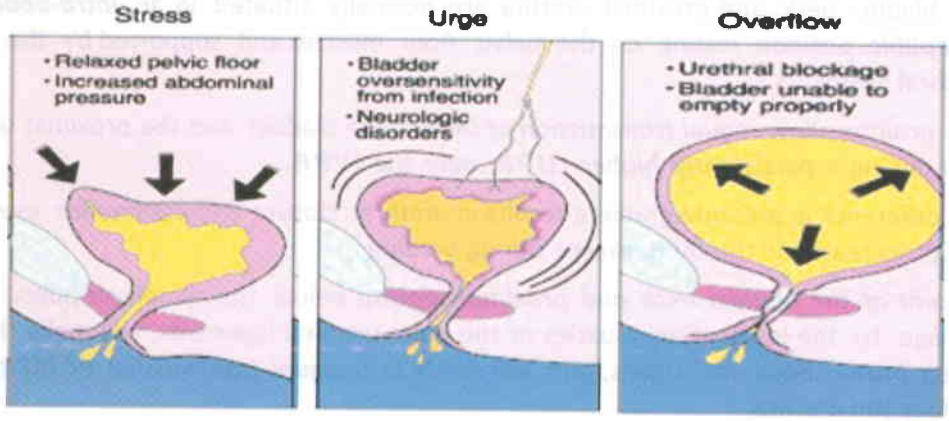

Fig 18-2: Types of urinary incontinence

STRESS URINARY INCONTINENCE (SUI)

DEFINITIONS AND INCIDENCE

- **SUI** describes the **involuntary** escape of urine through the **urethra** during **suddenly increased** intra-abdominal pressure, as during cough, sneeze, or laughter.
- It may be encountered in around;
  - **5%** of females **< 45** years,
  - **10%** of females between **45 - 60** years,
  - **> 30%** in women over **65** years of age.
- **Urodynamic stress incontinence UDSI:** is the term used when SUI is confirmed with objective urodynamic testing.
- **Temporary incontinence** may sometimes occur in some conditions as;
  - Following vaginal delivery, especially if difficult with prolonged second stage.
  - During long periods of immobilization as in old bed-ridden patients
  - In association with severe urinary tract infection (UTI)
  - As a side effect of some medications

AETIOLOGY AND RISK FACTORS

a) Weakness of pelvic floor muscles and supports:

- *Congenital (rare):* occurring in young and nulliparous women with no risk factors.
- *Childbirth trauma:* due to overstretching of the pelvic floor muscles and the endopelvic fascia, with damage to its nerve supply, especially after prolonged and difficult deliveries.
- *Postmenopausal:* due to atrophic changes affecting pelvic fascia 2ry to ***oestrogen deficiency***.

b) Anterior vaginal wall prolapse: due to descent of the bladder neck and proximal urethra.

c) Chronic increase in IAPR: marked obesity, chronic lung disease, or chronic constipation, may precipitate the condition in women with weak pelvic floor musculature and or vaginal prolapse.

PATHOPHYSIOLOGY OF SUI

- The bladder neck and proximal urethra are normally situated in an ***intra-abdominal retropubic position*** resting on the pelvic floor muscles and supported by the **pubo-urethral** ligaments.
- This position allows ***equal transmission of IAPR*** to the bladder and the proximal urethra, maintaining a ***persistently higher IUPR over the IVPR.***
- This difference in pressure gradient results in urethral closure and continence even with abrupt increases in the IAPR, except during voiding.
- ***Descent of the bladder neck and proximal urethra*** below the symphysis pubis, due to damage to the levators ani muscles or the pubo-urethral ligaments, will make them no longer intra- abdominal organs, and will result in ***unequal transmission of IAPR*** to the bladder and urethra.
- ***During sudden increase in IAPR*** the IVPR will exceed IUPR and urine will involuntary escape through the urethra leading to SUI, which is limited to the period of increased IAPR, as during cough, sneezing, or laughing.
- ***The patient neither the desire to void nor the control on voiding.***

SYMPTOMS

1. Involuntary leakage of urine through the urethra during coughing or sneezing, etc...
2. Symptoms of associated prolapse as heaviness and mass filling vagina may be present.

SIGNS AND TESTS ON CLINICAL EXAMINATION

1) Cough stress test: eliciting involuntary escape of urine through the urethra during cough while the bladder is partially filled and the patient in an erect or better lithotomy position.

2) Bonney's test:

- With the patient in lithotomy position, perform a cough stress test to elicit a positive SUI.
- The bladder neck is then elevated gently by the index and middle fingers of the examiner's hand, placed in the vagina on each side of the urethra without compressing it (as if trying to correct mild vaginal and bladder neck descent).

- The patient is asked to cough or strain again;
  - ➢ If **no urine escapes** during cough; then bladder neck descent is the cause, and surgical repair will be successful.
  - ➢ If **urine escapes** during increased IAPR then weakness of bladder neck will be the cause.

3) The Q-tip test: to detect mobility of the urethro-vesical junction on straining (see Fig. 17:4). More than 30 degree mobility during straining indicates a hyprmdolie urthrove si-caljuctuin

4) Presence of genital prolapse: should be always excluded in cases of SUI



Fig 18-3: Bonney's test

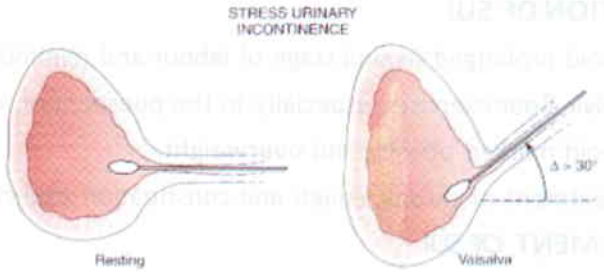

Fig 18-4: Q-tip test

URODYNAMIC TESTS FOR DIAGNOSIS OF SUI

A special catheter with a sensor probe is introduced to the bladder through the urethra to allow performing **cystometry, uroflowmetry, and urethral pressure profile**.

Parameters of Normal Bladder Function on Cystometry and Uroflowmetry
– *Detrusor pressure filling: < 15 cm H20*
– *Absence of detrusor contractions*
– *First desire to void: 150-200 ml*
– *Capacity: strong desire 400-600 ml*
– *No leakage during cough*
– *Uroflowmetry: rate of urine flow through urethra; N =15 ml/sec*
– *Residual urine after voiding: < 50 ml*

- **Uretheral pressure profile:** traces intraurethral pressure along urethral length, and allows tracing urine leakage during IAPR changes. It can confirm presence of SUI in cases where clinical examination is not reassuring.

DIAGNOSIS OF SUI BY URODYNAMIC TESTS

1. Cystometry: will reveal

- involuntary leakage of urine through the urethra during increased IAPR
- Absence of detrusor contractions during filling cystometry.

2. Urethral pressure profile: will reveal

- increased **IVPR > IUPR** during straining
- Decreased functional urethral length (length of urethra closed by IUP).

- **N.B.;** After confirmation with urodynamic studies the term urodynamic stress incontinence UDSI will be used instead of the clinical term SUI.

PREVENTION OF SUI

a. Avoid prolonged second stage of labour and minimize child birth trauma.
b. Pelvic floor exercises especially in the puerperium, or after pelvic surgery
c. Avoid marked obesity and overweight.
d. Treatment of chronic cough and constipation especially in the post menopausal period

MANAGEMENT OF SUI

A. CONSERVATIVE MEASURES for Mild cases:

Mild SUI may show some improvement via;

1. Pelvic floor muscles strengthening exercise:

- Active pelvic floor muscle training (PFMT) known as Kegel exercises
- Passive electrical pelvic floor muscle stimulation.

2. Scheduled voiding: to minimize amounts of urine in the bladder.

3. Oestrogen therapy: vaginal cream in cases of menopausal atrophy may improve urethral blood flow and increase alpha adrenergic receptor sensitivity.

4. Pessary treatment: in some cases of vaginal prolapse may improve associated SUI.

B. SURGICAL TREATMENT for Moderate and Severe Cases:

Surgery is the **gold standard** in treatment of **USI.** The aim of surgery is the permanent correction of proximal urethral and bladder neck descent, by their elevation back to their normal retropubic intra-abdominal position, thus restoring the balance between IVPR and IUPR.

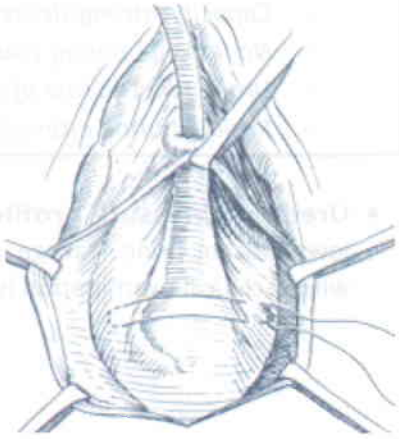

Fig 18-5: Kelly's sutures

1.KELLY'S PERIURETHRAL FASCIAL PLICATION SUTURES:

- It is a **vaginal procedure** in which periurethral plication of fascia is performed along the course of a cysto-urethrocele repair via anterior colporrhaphy procedure (see genital prolapse).
- It is a simple procedure associated with a 60-70% success rate but unfortunately will fall to only 30% after 5 years

2. BURCH COLPOSUSPENSION OPERATION:

- It is an **abdominal procedure** in which the upper vagina, (at the level of the urethrovesical junction and upper third of the urethra), is plicated on each side to the iliopectineal ligament (Cooper ligament) by 2-3 interrupted non absorbable sutures.
- Burch colposuspension is considered the **gold standard** procedure with success rates of **95%** after **1 year**, and nearly 75% after 15 years follow up.
- Recently the procedure has been performed laparoscopically.

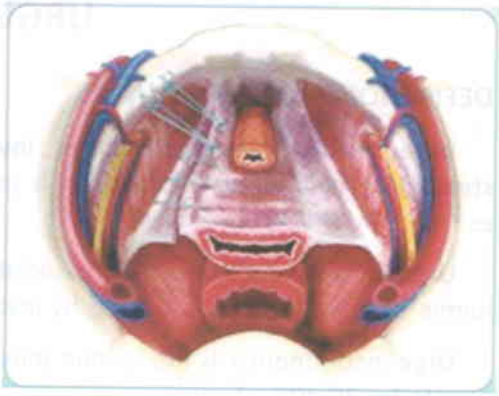

Burch procedure and paravaginal repair suspend the urethra and bladder to correct stress incontinence and cystocele

Fig 18-6: Burch Colposuspension

3. THE SLING PROCEDURES.

a) Tension-free Vaginal Tape (TVT):

- TVT is performed using synthetic mesh like tape introduced vaginally, on each side of the proximal urethra, passing just below it acting as a sling, then each end of the tape is pushed upwards to be pulled out through the abdominal wall to which it is finally fixed.
- TVT has a high success rate up to 90%, with the advantage of a simple technique that requires a shorter stay in the hospital (1 day), and can be performed under local anesthesia.

b) Trans-Obturator Tape (TOT):

- TOT is performed using a synthetic mesh-like tape (similar to TVT), introduced vaginally, passing from one obturator foramen to the other, piercing the obturator diaphragm, and forming a sling below the proximal urethra, with the distal tape pulled out through small groin incisions at the level of clitoris.
- TOT is simpler than TOT with less complications, performed with regional anesthesia as an outpatient procedure, with success rates approaching TVT.

4. PERIURETHRAL INJECTION OF COLLAGEN.

- This is a short term treatment because long term success results are < 30% after 5 years

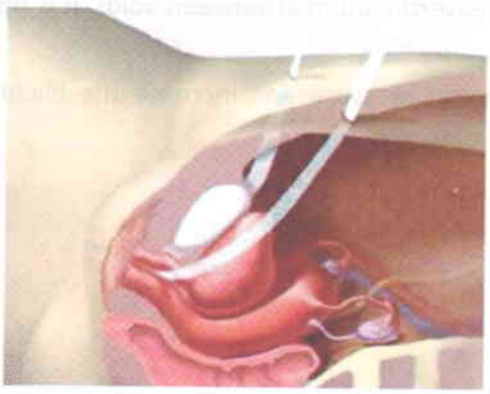

Fig 18-7: TVT

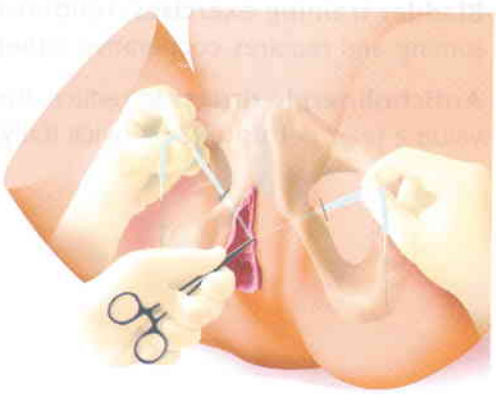

Fig 18-8: TOT

URGE INCONTINENCE

DEFINITIONS AND INCIDENCES

Urge incontinence describes **involuntary** leakage of urine through the urethra ***before starting to void*** when the bladder is partially full, posing difficulty in postponing urination urges.

Urge incontinence is usually associated with detrusor overactivity **(DO),** which is an urodynamic observation characterized by involuntary detrusor contractions during the bladder filling.

Urge incontinence is the second most common cause of female urethral incontinence, and accounts for 30-40% of cases.

AETIOLOGY

- Idiopathic (most common).
- Local bladder irritation (e.g. infection, stone, ulcer, polyps).
- In association with a neuropathy as in; DM, DS, spinal cord or brain lesions.

CLINICAL SYMPTOMS

- **Urgency:** sudden desire to void.
- **Frequency:** urination 7 or more times a day.
- **Nocturia:** awaking from bed more than once at night to void.

INVESTIGATIONS for DIAGNOSIS of DO

1. **Cystometry:** to measure IVPR and trace detrusor systolic filling contractions. **DO** will be diagnosed whenever studies reveal *detrusor pressure filling > 15 cm H20* due to increased systolic contractions with failure to inhibit detrusor contractions during cystometry.
2. **Midstream Urine Examination:** to exclude cystitis and to perform culture and sensitivity if pus cells are high.
3. **Cystoscopy and IVP:** may be needed to exclude intravesical pathology (stone, polyp, etc.)

TREATMENT

a. **Bladder training exercises;** tends to increase the interval between voids. It is time consuming and requires cooperative patients.

b. **Anticholinergic drugs:** to reduce the vesical pressure and increase the bladder volume (e.g.; detrusitol 2mg twice daily)

GENITO-URINARY FISTULAS

Genitourinary fistulas are **abnormal communications** between the **urinary organs** (bladder, ureter, and urethra), and the **genital organs** (uterus, cervix, and vagina). They are usually associated with continuous leakage of urine through the vagina (true incontinence).

ANATOMIC CLASSIFICATION OF GENITOURINARY FISTULAS

GENITAL ORGANS	URINARY TRACT		
	Ureter	***Bladder***	***Urethra***
Vagina	*Uretro-vaginal*	*Vesico-vaginal*	*Urethro-vaginal*
Cervix	*Uretro-cervical*	*Vesico-cervical*	*Urethro-cervical*
Uterus	*Uretro-uterine*	*Vesico-uterine*	*Urethro-uterine*

OVERVIEW AND INCIDENCES:

The **incidence** of GUF has been **sharply declining** in the last 3 decades due to effective **preventive approaches**.

Necrotic fistulas, related to childbearing trauma, are now considered **rare**, so as **necrotic fistulas** occurring 2ry to pelvic irradiation.

Traumatic fistulas have also declined due to better training and better surgical techniques, although are still more common than necrotic fistulas nowadays.

In general vesico-vaginal fistulas **(VVF)** and uretro-vaginal fistula **(UVF)** are the **most common** types of GUF encountered in gynaecologic practice. Other types are extremely rare.

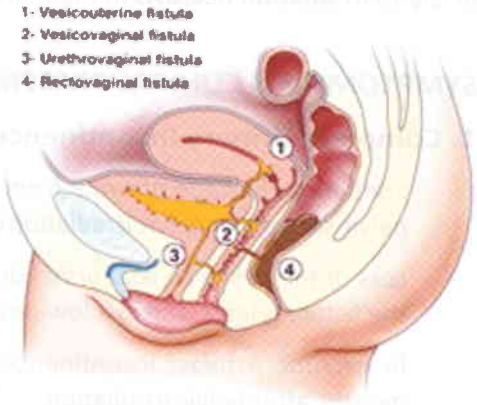

Fig 18-9: Common types of GUF

AETIOLOGY OF GUF

a. **Traumatic fistulas:** due to direct injury to urinary organs, as that occurring during pelvic surgery, crash accidents, or rarely the use of certain obstetric instruments during delivery.

b. **Necrotic fistulas:** 2ry to ischaemic necrosis to parts of urinary organs as that occurring with prolonged and obstructed labour, pelvic malignancies, and pelvic irradiation therapy.

VESICO-VAGINAL FISTULA (VVF)

OVERVIEW AND AETIOLOGY

VVF have long been considered as the **commonest type of GUF** encountered in gynaecologic practice. In the majority of cases it occurred due to **ischaemic necrosis** 2ry to **prolonged compression** of the foetal head against the bony pelvis, in cases with undiagnosed **cephalopelvic disproportion** (CPD).

The **incidence** of **necrotic VVF** has markedly **declined** due to **better obstetric practice** with more liberal use of cesarean section (CS) operation in cases with CPD replacing difficult instrumental delivery.

VVF may still occur due to **direct traumatic injury** during CS and hysterectomy operations, as well as the faulty use of the obstetric forceps procedures.

VVF may rarely occur due to **invasion** of vaginal and bladder walls in **gynaecologic malignancy**, or 2ry to **irradiation necrosis** in the management of vaginal, cervical, or endometrial cancer.

SYMPTOMS and CLINICAL PRESENTATION

1. Complete Urinary Incontinence:

- *Continuous leakage of urine from the vagina* in a patient with a history of a recent delivery, pelvic surgery, or pelvic irradiation is the main presenting symptom.
- *Loss of the desire to void urine,* due to absence of bladder filling, is the rule especially when the fistula is large and in a low position.
- *In necrotic fistulas;* Incontinence may present days or weeks after a difficult delivery, or months after pelvic irradiation.
- *In traumatic fistulas;* leakage of urine starts almost immediately after gynaecologic pelvic surgery, CS, or urologic procedures.

2. Partial Urinary Incontinence:

- *Interrupted leakage of urine* with *occasional desire to micturate;* may occur in some cases with a small VVF situated high in the bladder, enabling the patient to retain some of the urine in her bladder. This type should be differentiated from UVF.

3. Pruritus and vulvitis:

These may occur secondary to prolonged irritation of vulval and vaginal skin with the continuously leaking urine.

4. Cystitis & UTI:

UTI may complicate prolonged or neglected cases, due to ascending infection from the vulva. Pyelonephritis is a serious complication which may be the major cause for morbidity in such cases.

SIGNS ON CLINICAL EXAMINATION

a. With the patient in Sims' position:

Inspection of the anterior vaginal wall is performed using Sims' vaginal speculum, to visualize fistulous opening and detect urine leakage from VVF orifice.

b. With the patient in lithotomy position:

Digital palpation of the anterior vaginal wall is performed to detect the site, size, of VVF and surrounding scarring and fibrosis.

SPECIAL INVESTIGATIONS

1. Retrograde coloured dye injection into the bladder:

Retrograde injection of 200 ml. of coloured dye (methylene blue or indigo carmine) into the bladder is performed via a urethral catheter. Coloured dye will be seen dribbling from the fistulous opening at the anterior vaginal wall using Sim's speculum.



Fig 18-10: Sims' position for examination of GUF

2. ***Intravenous pyelography (IVP):***

IVP is helpful to evaluate the amount of residual urine the bladder, delineate the course of the ureters, and exclude ureteric fistulae. Cysto-urethrography helps to exclude urethral fistulas and delineate he fistulous track to the vagina

3. Cystoscopy & Urethroscopy:

- *Cystoscopy:* visualizes VVF and determines their relation to the ureteric openings in the bladder. It can also exclude multiple VVF, ureteric fistula, and can reveal any associated bladder pathology.
- *Urethroscopy:* may exclude associated urethrovaginal fistula



Fig 18-11: Sims' speculum

PREVENTION OF VVF:

a. Avoid prolonged and obstructed labour by prompt diagnosis of CPD.
b. Use of CS instead of difficult forceps procedures.
c. Proper surgical technique in pelvic surgery to avoid bladder or ureteric injuries.
d. Immediate intraoperative repair of bladder or ureteric injuries once diagnosed .

MANAGEMENT OF VESICO-VAGINAL FISTULA

A. CONSERVATIVE MANAGEMENT

- In case of a **necrotic fistula**, detected few days after a difficult labour, an indwelling silicone catheter is introduced through the urethra and left for a period of 4-6 weeks, to divert the flow of urine away from the fistula, prevent bladder distension, and allow wound healing.
- Surgical repair is usually postponed for 3-6 months until oedema subsides and tissue involution is complete, where surgery becomes easier and safer, allowing for better dissection and healing.
- Spontaneous closure of a small VVF may be achieved in some cases with complete healing of the tear, or failing this, it will be left much smaller in size.

B. SURGICAL TREATMENT

- Surgical anatomical repair is the **gold standard** in management of VVF.
- The **first attempt** for fistula repair carries the **best prognosis**. Repeated trials for repair are less successful due to the extensive fibrosis left after each attempt.
- Proper postoperative bladder drainage is crucial to success of surgery

Pre-operative Preparation

- Proper assessment of the site and size of the fistula, with exclusion of multiple sites, or associated ureteric fistula via performance of cystoscopy and IVP.
- Protection of the skin of vulva and vagina from continuous irritation by dribbling urine, via use of indwelling catheters, vaseline or zinc oxide ointments.
- Culture and sensitivity of urine is done and if pathogenic organisms are found, the patient is given the appropriate antibiotic until the urine is sterile.

OPERATIONS FOR VISCO-VAGINAL FISTULA

1. VAGINAL Flap-splitting operation (dedoublement):

- This approach is suitable for *low fistulas accessible vaginally*
- *A circular incision* is made around the margin of the fistula
- *Dissection and mobilization of the vaginal wall from the bladder* over an area 2.0 cm around the fistulous opening.
- *Closure of the bladder* in 2 layers of interrupted sutures going through the muscle wall only, not piercing the mucous membrane making the closure water-tight.
- *Closure of the vagina* by interrupted sutures going through its whole thickness.
- *Drainage of the bladder;* via insertion of a rubber urethral catheter to avoid bladder distension, which will strain the stitches.

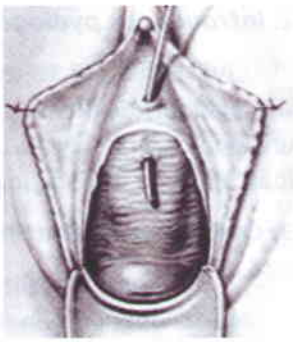

Fig 18-12: Small VVF

2. ***ABDOMINAL Repair of VVF:***

- *High and recurrent fistulas* may be better approached by **abdominal repair** through a transverse suprapubic incision, and a retroperitoneal approach.
- This approach may also be more suitable in cases with large fistulas especially those near the ureteric orifices.

Post-operative Care:

1. The bladder should be kept constantly empty to avoid any tension on the sutures, via ensuring a patent catheter and avoid its occlusion by debris or blood clots.
2. The catheter is never removed before 10-14 days.

N.B.: In cases with successful repair of VVF, pregnancy should be avoided for a period of 1 year after operation, and at full term delivery by CS is mandatory to avoid complications of vaginal delivery on pelvic floor and recurrence of fistula.

URETERO-VAGINAL FISTULA

This variety of fistula **nearly always** occurs as a result of **injury to the ureter** during gynaecologic operations as hysterectomy but may also develop following a difficult delivery by C.S.

Symptoms:

- **Incomplete urinary incontinence;** the bladder fills normally from the intact ureter, and the patient voids normally with a **preserved** sensation of bladder filling and **desire to micturate**, while the urine continuously **dribbles through the vagina** from the affected ureter at the site of UVF.

Inspection by Sims' speculum:

- **The fistula** is always **small** and situated **high** up in the vagina lateral to the cervix.

Investigations:

- **UVF** can be **differentiated** from **VVF** by the **methylene blue test**.
- **Cystoscopy** shows a normal bladder with presence of the **ureteric efflux on only one side**.

Prevention:

- Preoperative identification of ureteric course through an **IVP**.
- Preoperative placement of **ureteric catheters** in cases with abnormal ureteric course or large pelvic tumours
- Intra-operative proper **anatomical identification** of the ureter during pelvic surgery.

Surgical treatment:

- **Abdominal re-implantation** of the ureter into the bladder.

URETHRO-VAGINAL FISTULA

This **rare** type of fistula may be caused by obstetric childbirth trauma or gynaecologic surgical trauma (as in procedures for correction of vaginal prolapse or SUI).

Symptoms:

- The patient will be **continent** all through, with normal sensation of bladder filling and preserved desire to micturate
- **During voiding;** splashing or double stream of urine through the urethra and vagina occurs.

Diagnosis:

- **Direct visualization** by passage of a urethral catheter through the defect, or
- **Urethroscopy.**

Treatment:

- **Insert a catheter** splinting the urethra once injury detected and leave it for 2 weeks for spontaneous healing with excellent results.
- **Surgical reconstruction** of the urethra and closure of the defect in old cases.

Key points

- *Urinary incontinence is a stressful condition that has a negative impact on the patient's life style*
- *Urethral incontinence in the form of SUI or DO may affect up to 20% of female population, and is nowadays far more common than extra-urethral incontinence caused mainly by GUF.*
- *Diagnosis of SUI is based mostly on clinical data although exclusion of or differentiating from DO is best achieved through urodynamic studies.*
- *The definitive treatment of moderate or severe cases of SUI (or UDI) is essentially surgical, using either Burch fixation procedure, or more recently Tape Colposuspension with high rates of success (>90%for the first 5 years). Recurrence rates are relatively low.*
- *DO is usually managed through physiotherapy, bladder training, and anticholinergic medications.*
- *Extraurethral incontinence is mainly caused by GUF, occurring mostly due to either obstetric or gynaecologic complications. The most common forms include VVF and UVF.*
- *The diagnosis of GUF is essentially a clinical one, based on proper history taking, vaginal examination (using Sims' speculum), and performing special investigations to locate the site of the fistula and its relation to the bladder or ureters.*
- *Surgery is the mainstay in the management of GUF. It can be performed as a primary repair at the time of occurrence, or postponed for 8-12 weeks until resolution of tissue oedema.*
- *VVF is surgically treated through removal of the fistulous tract, debridement, and closure of the bladder and vaginal walls in layers by interrupted sutures without tension. UVF will require implantation of the cut ureteric end into the bladder wall.*
- *In GUF the 1st attempt at surgical repair always gives the best prognosis. Recurrent fistula is more diffi-*

19 ABNORMAL UTERINE BLEEDING
DUB AND ENDOMETRIAL HYPERPLASIA

- Menorrhagia
- Metrorrhagia
- Contact bleeding
- Postmenopausal Bleeding
- Dysfunctional Uterine Bleeding
- Management of AUB

The **normal** menstrual cycle is characterized by **cyclic** shedding of the endometrium that occurs every **21-35** days (mean **28** days), with a **duration** of **3-5** days and an average **blood loss** of **30-50** ml/cycle.

Abnormal uterine bleeding **(AUB)** describes abnormal patterns of uterine bleeding other than that occurring in a normal menstrual cycle.

PATTERNS OF AUB

- **Menorrhagia (**Heavy Menstrual Bleeding **HMB):** excessive bleeding during menstruation
- **Metrorrhagia (**intermenstrual Bleeding **IMB):** significant bleeding in between cycles
- **Meno-metrorrhagia:** bleeding includes both **HMB** and **IMB** (acyclic irregular bleeding)
- **Postmenopausal Bleeding (PMB):** vaginal bleeding after menopause.
- **Contact bleeding (CB):** bleeding on touching the cervix (e.g.: post-coital bleeding)
- **Other abnormal bleeding patterns** of the menstrual cycle:
  - ***Hypomenorrhoea:*** scanty menstrual flow usually of short duration
  - ***Oligomenorrhoea:*** infrequent menstrual cycles (duration > 35 days between cycles)
  - ***Oligohypomenorrhoea:*** infrequent cycles with scanty flow or short duration
  - ***Polymenorrhoea:*** frequent menstrual cycles recurring every < 21 days (normal flow)
  - ***Polymenorrhagia:*** frequent HMB recurring every < 21 days

CAUSES OF AUB (FIGO 2011)

A. STRUCTURAL CAUSES: referred to as **PALM**

1. **P**regnancy complications: as abortion, ectopic pregnancy, and hydatidiform mole
2. **P**olyps: endometrial and endocervical polyps
3. **A**denomyosis: myometrial myohypertrophy due to intramyometrial endometriosis
4. **L**eiomyomas: benign myometrial tumours
5. **M**alignancies: endometrial and cervical carcinomas, and functioning ovarian tumours

B. NON STRUCTURAL CAUSES: referred to as **COEIN**

1. **C**oagulation disorders: as ITTP and Von-Willebrand disease
2. **O**vulatory dysfunction: as chronic anovulation in PCOS
3. **E**ndometrial hyperplasia: see later
4. **I**atrogenic causes; as anticoagulant therapy, IUD induced bleeding and OCP break through bleeding
5. **N**on-classified aetiology: as systemic hypertension, capillary fragility, severe thyroid disorders, chronic liver disease and renal failure.

CLASSIFICATION OF AUB ACCORDING TO AGE GROUPS

1. Childhood and Adolescence bleeding
2. Childbearing period bleeding
3. Perimenopausal bleeding
4. Postmenopausal bleeding

MENORRHAGIA

Menorrhagia also known as heavy menstrual bleeding **(HMB),** is the term used to describes excessive blood loss **during** menstruation that exceeds > **80** ml in **amount** and/ or > **7** days in **duration**, or both. **HMB** occurs more frequently in association with **benign** rather than malignant conditions.

COMMON CAUSES OF MENORRHAGIA (HMB):

- *Leiomyomas:* especially larger intramural and submucus leiomyomas (see leiomyomas)
- *Adenomyosis:* in association of symmetrical uterine enlargement and myoypertrphy
- *Endometrial polyps:* due to increased surface area of endometrium
- *Endometrial hyperplasia (EH):* especially mild forms of simple EH (Dysfunctional menorrhagia)
- *Intrauterine contraceptive device (IUD):* non-hormonal and Cu IUDs
- *Systemic disease* and *coagulation disorders:* as hypertension & ITTP.

EVALUATION OF THE AMOUNT OF MENSTRUAL BLEEDING:

1. Number of blood soaked diapers changed daily
2. Duration of menstrual bleeding
3. Presence of large blood clots and associated anaemia
4. Affection of the patient's general condition and her life style.

- **N.B.:** A scoring system is available to evaluate the amount of bleeding within each diaper or tampoon changed daily, being light, moderate or completely soaked. The amount of blood loss can be more accurately calculated using such scoring symptoms.

METRORRHAGIA

Metrorrhagia describes significant intermenstrual bleeding (IMB) occurring spontaneously not in relation to the time of menstruation.

Significant **IMB** may be associated with various **benign** conditions, but is more also commonly associated with **hormonal** disturbances, **premalignant** lesions, and **malignancies** of the uterine body and cervix.

COMMON CAUSES OF METRORRHAGIA (IMB)

- *Non hormonal IUD:* one of the commonest causes in childbearing period (Cu T).
- *Combined OCPs* (COCCs), and *Gestagen only pills* (POPs): may cause breakthrough bleeding and intermittent spotting.
- *Leiomyomas:* ulcerated submucus fibroid polyps
- *Hyperplastic adenomatous endometrial polyp*
- *Endometrial* and *endocervical carcinomas*, and oestrogen producing *ovarian tumours*

PERIMENOPAUSAL BLEEDING

Perimenopausal bleeding describes **AUB** occurring in **elderly** women, commonly > 40 years of age, before their actual menopause. It may occur in the form of Menorrhagia, Metrorrhagia, or Meno-metrorrhagia.

Although the underlying aetiology is usually functional or benign, yet malignant neoplasms should be thoroughly excluded, before treatment is initiated.

COMMON CAUSES OF PERIMENOPAUSAL BLEEDING

- *Anovulatory DUB* is the most common cause (see later)
- *IUCD or OCPs induced bleeding*
- *Leiomyomas and Adenomyosis*
- *Endometrial and endocervical polyps*
- *Endocervical carcinoma*, and less commonly endometrial cancer and functioning ovarian tumours.

POSTMENOPAUSAL BLEEDING

Postmenopausal bleeding (PMB) describes vaginal bleeding that occurs ij menopausal women after complete cessation of menstruation. Women are usually > 45 years of age, with high serum FSH levels >30 mIU/ml. In PMB bleeding may be uterine, cervical, vaginal, or vulvar, i.e.: not only limited to AUB

PMB is always **abnormal**, and although in most cases the underlying etiology is **benign**, yet **premalignant** and **malignant** lesions should be thoroughly looked for and **excluded** in every case.

COMMON CAUSES OF PMB:

- *Iatrogenic:* as with hormone replacement therapy in menopause (HRT)
- *Benign conditions:* atrophic vaginitis, atrophic endometritis, vulvar dystrophies, endometrial and endocervical polyps (most common causes).
- *Premalignant lesions:* EH, and high grade CIN lesions
- *Gynecologic malignancies:* endometrial, cervical, vaginal, and vulvar cancers, and oestrogen producing ovarian tumors (most serious causes).
- *Systemic disease as hypertension and ITTP*

CONTACT BLEEDING

Contact bleeding (CB) describes bleeding that occurs on touching the cervix. It usually presents as post coital bleeding that can occur also following PV or speculum examination.

In **most** cases the underlying cause is a **benign**, **inflammatory**, or **traumatic** lesions, however CB in perimenopausal and postmenopausal women is largely related to **cervical cancer,** and should thoroughly looked for and excluded in such age groups, and even in younger high risk population (see cancer cervix).

COMMON CAUSES OF CB:

- Benign cervical lesions: mucous polyps and cervical erosion (most common)
- Premalignant cervical conditions: High grade CIN lesions (common in high risk cases)
- Vaginal causes: severe Trichomonas vaginitis, or menopausal atrophic vaginitis.
- Vaginal trauma: as friction and defloration injuries.

DYSFUNCTIONAL UTERINE BLEEDING

Dysfunctional uterine bleeding **(DUB)** describes **AUB** that occurs in absence of recognizable pelvic pathology, systemic disease, blood dyscrasias, or pregnancy. It is a diagnosis made by exclusion more commonly occurring in Perimenopausal women and in late childbearing period.

DUB occurs most commonly in association with chronic **anovulatory disturbances** causing endometrial hyperplasia **(EH)** in response to continuous oestrogen **(E2)** effect on the endometrium unopposed by progesterone **(PRG)**.

EFFECT OF ANOVULATION ON ENDOMETRIAL VASCULAR HOMEOSTASIS:

The **secretory** endometrium in **ovulatory** cycles contains **high** levels of the potent vasoconstrictor prostaglandin F2 ∞ **(PGL F2 ∞)** which causes endometrial ischemia on PRG withdrawal allowing for complete sloughing of the superficial and intermediate layers of the endometrium, and control of the amount and duration of blood loss during menstruation.

In cases with **anovulation,** continuous estrogen **(E2)** stimulation in absence of PRG will cause the **proliferative** endometrium to outgrow its blood supply, breaks down, and sloughs resulting in irregular bleeding. The associated **low** levels of **PGL F2 ∞** will make the endometrium less efficient in controlling the amount and duration of menstrual bleeding.

In cases with **chronic anovulation,** as in PCOS, prolonged estrogenic effect on the endometrium unopposed by PRG will predispose to endometrial hyperplasia **(EH)** which will result in excessive irregular type of AUB, and may predispose to endometrial carcinoma **(EC)**.

ENDOMETRIAL HYPERPLASIA (EH)

Endometrial hyperplasia (EH) is a pathologic entity that describes an **increase** in **size** and **number** of irregularly proliferating **endometrial glands**, leading to abnormal endometrial **thickness** and increased tendency for bleeding. This condition has long been known as **metropathia haemorrhagica.**

Hyperplasia of the endometrium occurs in response to prolonged **oestrogenic** effect on the endometrium in **absence of** an adequate counteracting progestational effect. It occurs more frequently in;

- Chronic **anovulation:** as in PCOD and delayed menopause
- **Obesity:** due to peripheral conversion of androgen (Androstendione) into oestrone (E1)
- Exogenous **oestrogen** therapy: as in menopausal oestrogen replacement therapy ERT
- Oestrogen secreting **ovarian tumours:** as feminizing granulosa theca cell tumours.

- **N.B.:** EH are commonly associated with leiomyomas, adenomyosis, and endometrial carcinoma

PATHOLOGIC TYPES OF EH

A. ***Simple EH:*** cystic endometrial glandular dilatation with **disparity** in **size** (oestrogen effect) and no evidence of secretory activity (PRG effect), giving it a *Swiss cheese* appearance microscopically.

B. ***Complex EH:*** new endometrial glands will be formed with resulting **increase in number** and **crowding** with minimal intervening stroma *(back to back arrangement* microscopically*)*.

MALIGNANT POTENTIAL FOR EH

The presence of **nuclear atypia** (abnormal mitosis, hyperchromatosis, and increased nuclear cytoplasmic ratio) will raise the malignant potential of EH, especially in complex EH, and increases the risk for progression to endometrial adenocarcinoma as follows;

1. ***Simple EH without atypia: < 1%***
2. ***Complex EH without atypia: < 3%***
3. ***Simple EH with atypia: 8% (rare)***
4. ***Complex EH with atypia > 25%***

EVALUATION AND MANAGEMENT OF A CASE OF AUB

- ***Careful History:*** for exclusion of pregnancy, medical disorders, endocrine disorders, systemic disease, and iatrogenic causes as use of OCP, IUD, and anticoagulant therapy.
- ***Bimanual pelvic examination:*** to exclude uterine leiomyomas, adenomyosis, and adnexal masses
- ***Speculum examination:*** to exclude cervical polyp, erosion, ulcer, mass, or associated vaginal pathology.
- ***PAP smear test:*** to exclude high grade intracervical lesions (CIN)
- ***Pelvic US:*** to exclude uterine, endometrial and adnexal pathology.

- ***Laboratory tests and hormonal assays:*** for exclusion of suspected liver disease, endocrine disorders, and blood dyscrasias (as ITP, & von Willebrand disease).
- ***Office hysteroscopy:*** is beneficial for diagnosis of small endocervical and endometrial lesions
- ***D&C biopsy:*** is the gold standard in diagnosis of endometrial hyperplasia (EH) in cases with DUB
- ***MRI & CT scan:*** are beneficial in presence of an adnexal mass or suspected malignancy

KEY POINTS IN DIAGNOSIS OF AUB:

- **Menorrhagia:** is usually caused by benign conditions as leiomyomas, adenomyosis and DUB.
- **Metrorrhagia:** is mostly associated with SMF polyps, endometrial polyps, EH, and uterine malignancies
- **DUB:** occurs in absence of clinically detectable pathology hence endometrial biopsy is mandatory for exclusion of **EH**. TVS will usually reveal abnormal endometrial thickness.
- **PMB:** TVS will pick up cases with endometrial thickness **> 5 mm** with higher risk of EH or EC
- **In CB:** speculum examination, PAP smear, colposcopy and biopsy from suspicious lesions are mandatory to exclude cervical cancer in suspicious and high risk cases

TREATMENT OF A CASE OF AUB

Treatment of AUB is a **treatment of the cause**. It starts by controlling the primary attack of bleeding, then identifying the possible primary cause, followed by immediate treatment of the specific underlying etiology.

In many cases of more than one aetiology may be present, as with leiomyomas, adenomyosis, EH, CIN, and suspicious adnexal masses, in such cases treatment starts by the most probable primary cause.

Treatment of anemia, systemic diseases, endocrine disorders, and blood dyscrasias, should be initiated once diagnosis of any of these conditions is established.

Treatment will largely depend on the severity of AUB, weather primary or recurrent, previous treatment if present, together with the patient's age her desire for further fertility, and the final diagnosis of the primary aetiology.

A) DURING AN ACUTE ATTACK: control of an attack of HMB can be achieved via;

- ***Antifibrinolytics***: as Tranexamic acid, 500 mg t.d.s. orally, can control heavy bleeding by converting plasminogen into plasmin, to inhibit fibrinolysis, and stabilize clots.
- ***Non-Steroidal Anti-inflammatory Drugs (NSAIDs)***: as Mefanimic acid 500 mg two to three times daily orally, decrease amount of menstrual flow by up to 50% through decreased PGL synthesis, leading to decreased vascular dilatation and restoration of endometrial homeostasis. They also minimize pain and help to control bleeding.
- ***D&C operation:*** to stop bleeding and obtain endometrial biopsy to exclude EH

B) HORMONAL TREATMENT:

Hormonal treatment aims at correction of unopposed oestrogenic effect of anovulation and inducing timed endometrial shedding to induce regular cycles of average amount of bleeding.

1. ***Cyclic Combined oestrogen / progesterone:*** e.g.; OCP for 21 days /month (day 3-24 of the cycle). These regulate endometrial ripening and shedding inducing regular cycles with reduced menstrual flow. Treatment is usually extended for 3 successive cycles.
2. ***Cyclic Gestagens:*** oral tablets 10 mg daily for 14 days /month (day 10-24 in each cycle for 3 cycles).
3. ***Progesterone impregnated IUD (LNG-IUD):*** continuous slow release of low dose gestagen from an IUD is an effective method for inducing hypomenorrhoea in cases of severe recurrent DUB in absence of large myomata, complex EH, and EC.

HOW DO GESTAGENS CONTROL AUB and CORRECT ENDOMETRIAL HYPERPLASIA

a. Counteract oestrogen induced mitotic effect on DNA level, thus preventing EH.
b. Stabilize the endometrium and prevents its overgrowth, so that an organized sloughing will occur after PRG withdrawal.
c. Improves PGL imbalance restoring endometrial homeostasis (see DUB).
d. Restores cyclic endometrial shedding leading to cyclic controlled bleeding.

C) SURGICAL TREATMENT:

- **D&C** for control of acute attack, and obtaining biopsy to exclude EH and EC. It is indicated in cases with severe bleeding especially in presence of abnormal endometrial thickness or suspected polyp by TVS
- **Cauterization** of an endocervical polyp or a cervical erosion
- **Cervical Conization (LEEP procedures):** in cases of CB with high grade intraepithelial lesions (HG IL)
- **Endometrial ablation:** in some cases with recurrent DUB and failed hormone therapy in absence of EH
- **Abdominal Myomectomy** for larger myomata causing AUB in young women desiring to preserve fertility. It is usually performed via laparotomy, but can also be performed by laparoscopy in selected cases
- **Hysteroscopic Myomectomy or Polypectomy** for small submucus leiomyomas, and/or endometrial polyps
- **Hysterectomy:** abdominal, vaginal, or laparoscopic hysterectomy should be reserved only for cases with;
  - PMB in presence of any type of EH or suspicious uterine or adnexal pathology
  - Premenopausal AUB in presence of atypical complex EH, large leiomyomas, high grade cervical lesion (CIN 3), suspicious adnexal masses or failed hormonal; therapy.
  - Recurrent AUB in multiparous women in their childbearing period in presence of large leiomyomas, large adnexal masses, marked pelvic organ prolapse (POP), or failed hormone therapy.

ENDOMETRIAL ABLATION:

Endometrial ablation is a procedure that aims at destroying the majority of endometrium, thus controlling blood loss. It carries an overall 90% success rates in reduction of HMB. The majority of cases will experience a state of hypomenorrhoea or even 2ry amenorrhea, however 10-20% of cases may experience irregular spotting or recurrent AUB.

The procedure may be appropriate for cases with persistent DUB in premenopausal women with failed HT, in absence of EH, large myomata, uterine malignancy, or suspicious adnexal pathology.

Endometrial Ablation can be performed via Hysteroscopic endometrial resection, Hysteroscopic laser ablation, or intrauterine hydrothermal balloon. Cases with recurrent AUB after ablation are best managed by hysterectomy.

Key Points in AUB

- *AUB is the commonest cause of genital tract bleeding in the females*
- *AUB is usually secondary to an identifiable pelvic organic lesion or systemic disease summarized in the abbreviation **PALM COEIN***
- *Bleeding may be in the form of Menorrhagia, Metrorrhagia, Contact bleeding, and Postmenopausal bleeding,*
- *Diagnosis of AUB is based on thorough history, physical examination, and special investigations as: US, Ct/MRI, Hysteroscopy, laparoscopy, and Laboratory tests*
- *DUB describes AUB in absence of an identifiable organic lesion or systemic disease.*
- *DUB mostly occurs in post-pubertal and premenopausal periods and is commonly associated with chronic anovulation*
- *DUB is diagnosed only after exclusion of all organic and systemic causes of AUB*
- *Treatment of AUB includes:*
- *Medical treatment: haemostatic drugs & NSAIDs, to control acute bleeding*
- *Hormonal treatment: Estrogen/PRG/LNG-IUD, to induce regular cycles*
- *Surgical treatment: Polypectomy, Myomectomy, hysterectomy, and endometrial ablation in selected cases*
- *In PMB all efforts should be made to exclude premalignant or malignant lesions in FGT.*

20 UTERINE LEIOMYOMAS

– *Uterine Leiomyomas* – *Uterine polyps*

UTERINE LEIOMYOMAS

OVERVIEW

Uterine **leiomyomas** are the commonest **benign** tumours of the female genital organs. They arise from a single muscle cell within the **myometrium,** and are popularly known as *myomas* or *fibroids*.

Myomas are detectable in almost **20%** of women in the *child bearing period*, and in up to **50%** of uteri examined at *autopsy.*

Tumours usually **grow slowly** in size over many years, and have a very **low** malignant potential. They will mostly pass **unnoticed,** due to their slowly progressive course, and will be diagnosed only when they reach a **large size** or produce significant **symptoms**, or discovered **accidentally** during routine gynaecologic examination.

Small leiomyomas with no or mild symptoms are commonly managed **conservatively** through careful follow up, and regular observation.

Large and **symptomatizing** leiomyomas are usually managed by **surgical removal** whether alone, or together with the uterus, according to the patient's age, her need for fertility preservation, tumour size, and the severity of associated symptoms.

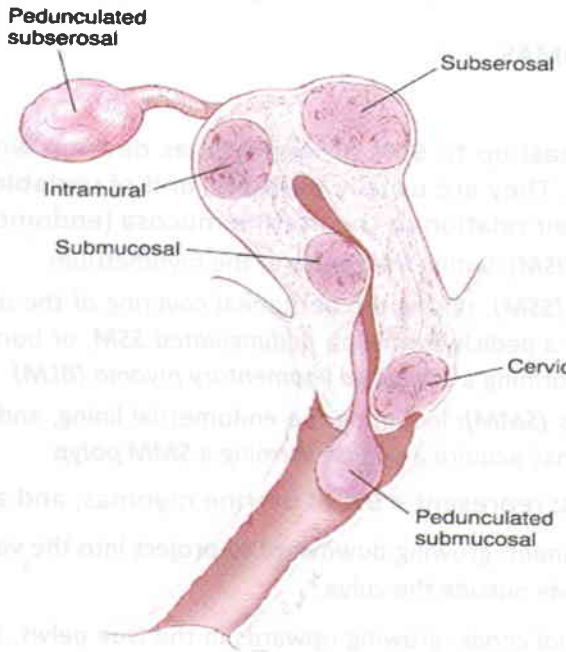

Fig 20-1: Sites of Leiomyomas

RISK FACTORS

1. *Parity:* more common in nulliparous and low parity women.
2. *Hereditary factors:* more in women with positive family history (mother & sister).
3. *Racial factors:* more common in dark races than in white and yellow races.
4. *Obesity:* more common in women with higher body mass index (BMI).

Commonly associated conditions:

- *Follicular cysts* of the ovary
- *Endometriosis* and *adenomyosis*
- *Endometrial hyperplasia (EH)* and rarely *endometrial carcinoma (EC).*

AETIOLOGIC FACTORS: (exact etiology is unknown)

A. Abundant Oestrogen Environment: Leiomyomas are oestrogen dependent as evidenced by;

- Leiomyomata appear only in the childbearing period.
- No new tumours develop before puberty or after menopause.
- Increase in size occurs during pregnancy as well as during oestrogen therapy.
- Decrease in size and atrophy occur in conditions of oestrogen deficiency as during menopause, or during GnRH agonist therapy.
- Commonly associated with endometrial hyperplasia and or endometriosis.

B. Growth Factors:

- Increased production of Epidermal Growth Factor (EGF).
- Decreased production of Growth Inhibiting Factor (GIF).
- N.B.: both may act synergistically with E2 to induce growth of myoma.

C. Genetic Factors:

- Forty percent of leiomyomas show cytogenetic abnormalities, suggesting a genetic role in the pathogenesis of leiomyomas due to gene mutation

PATHOLOGY OF LEIOMYOMAS

1. Site Of Myomas:

a. Corporeal Leiomyomas: up to **95%** of leiomyomas develop within the myometrium of the uterine body. They are usually **multiple**, and of **variable size**. They are classified according to their relation to the uterine mucosa (endometrium) into:

- *Interstitial Myomas **(ISM):*** within the centre of the myometrium
- *Subserosal Myomas **(SSM):*** raising the peritoneal covering of the uterus, the serosa, externally. It may acquire a pedicle forming a *pedunculated **SSM***, or burrow within the leaves of the broad ligament forming a *2ry broad ligamentary myoma **(BLM)***
- *Submucosal Myomas **(SMM):*** indenting the endometrial lining, and encroaching on the endometrial cavity. It may acquire a pedicle forming a ***SMM polyp***

b. Cervical Leiomyomas: represent **< 5%** of uterine myomas, and are usually solitary.

- *From the portio-vaginalis:* growing downward to project into the vagina, and may reach the introitus, and protrude outside the vulva.
- *From the supravaginal cervix:* growing upwards in the true pelvis, in relation to the urinary bladder, ureters, rectum, and broad ligament.

c. Broad-ligament Myomas (BLM): rare, representing < 1% of leiomyomas.

- *1ry BLM:* or true BLM, arising from muscle fibres within the broad ligament and not connected to the uterus
- *2ry BLM:* SSM that grow externally from the side of the uterus to burrow within the anterior and posterior leaves of the broad ligament. The myoma is thus connected to the uterus either directly or through a pedicle.

2. ***Size:*** variable size, ranging from size of a pea-nut to that of foetal head.

3. ***Shape:*** rounded or spherical in shape

4. ***Number:*** corporeal myomas are usually multiple, whereas cervical and BLM are usually single

5. ***Consistency:*** firm except of degenerated where it may become soft, cystic, or hard (see later)

6. ***Cut Section:*** Leiomyomas are well circumscribed tumours characterized by;
   - *Whorled appearance:* due to interlacing bundles of muscle cells with fibrous tissue
   - *Paler than rest of myometrium:* due to poorer vascularity.
   - *Pseudo-capsule:* myomas are surrounded by a false capsule formed of compressed normal myometrium (capsule does not belong to the tumour).
   - *The blood vessels:* lie in the capsule and send radial branches towards the centre. This explains why calcifications occur in the periphery, while degeneration occurs at the centre (poorer blood supply).
   - *Fibroid polyp:* when a submuous fibroid attains a pedicle and protrudes into the cavity forming a SMF polyp, the capsule usually ruptures and retracts. The fibroid polyp receives blood supply from vessels in the pedicle.



Fig 20-2: Cut section in hysterectomy specimen



Fig 20-3: SMF Polyp

7. ***Microscopic appearance:***
   - Leiomyomas consist of smooth muscle cells arranged in bundles, intermixed with fibrous connective tissue.
   - Vascular structures are few, and mitosis is rare.
   - ***Cellular leiomyomas*:** are tumours with **mitotic counts** of 5-10 per 10 consecutive high power field (HPF) that lack cytological atypia. They are not considered malignant.

PATHOLOGIC CHANGES IN MYOMAS

1. Atrophy:
- It is the *commonest* change occurring in the *menopause*.
- It occurs due to decreased blood supply 2ry to *oestrogen deficiency*.
- Also occurs during puerperium, and during long term treatment with GN-RH agonists.
- *Clinically:* atrophy is associated with diminished size which is usually silent and *painless*.

2. Hyaline degeneration:
- This is the *commonest* change in the *child bearing period*.
- It mostly occurs in the *centre* of the tumour due to *diminished vascularity*.
- *Microscopically:* the whorled appearance is lost, and the tumour tissue is replaced by homogenous structureless material staining pink with eosin.
- *Clinically:* tumours become generally *soft* in consistency, however if increase in size occurs it may render the myoma *tense cystic* rather than soft. These changes may be associated with mild to *moderate dull aching pain*.

3. Cystic degeneration:
- Cystic changes in myomas are only *rarely* encountered in clinical practice
- It occurs due to the absorption of liquefied hyaline material at the *centre* of myoma
- *Microscopically:* The cavity is lined by remnants of unabsorbed hyaline material.
- *Clinically:* the tumour becomes soft and cystic, with *mild dull aching pain*.

4. Red degeneration: (Necro-biosis):
- It is the commonest change during pregnancy, possibly due to;
  - The tumour may outgrow its blood supply, **or**
  - Kinking of the blood vessels due to rotation resulting from rapid uterine growth, **or**
  - Increased tendency to thrombosis associated with pregnancy.
- It reflects a state of *incomplete necrosis* from which the tumour is capable of *recovery*.
- Thrombosis of capsular vessels results in *ischemia* and release of a lipoid *toxin*, leading to intravascular *haemolysis* and diffusion of blood pigments giving the tumour a red colour.
- *Clinically;* myomas become enlarged, tender, with *acute pelvic pain* and mild *pyrexia*.
- *Management:* is essentially *conservative* by rest and analgesics as NSAIDs.

5. Fatty degeneration: Deposition of fat within the muscle cells. It is a precursor of calcification.

6. Calcification:
- Calcification is common in *long standing myomas* and in menopause.
- It occurs due to deposition of calcium phosphate and carbonate along the blood vessels
- It is either *peripheral* giving an "egg shell" or *diffuse* giving a "womb stone" appearance on plain X-ray or U.S.

7. **Necrosis:**
- Commonly occurs at the tip of a SMF polyp due to poor blood supply.
- It also occurs following torsion of pedunculated SSM.

8. Infection:
- Occurs at necrosed tip of SMF polyp projecting into the uterine cavity, cervix or vagina.
- May occur during puerperium, or as spread from nearby infected organ as appendicitis.

COMPLICATIONS OF LEIOMYOMAS

A. ***Torsion*** *of a pedunculated SSM,* or rarely torsion of the whole uterus.
B. ***Rupture*** *of a surface vein of SSM* leading to intraperitoneal heamorrhage.
C. ***Incarceration*** *or impaction of a SSM* in the pelvis especially during pregnancy.

MALIGNANT TRANSFORMATION INTO LEIOMYOSARCOMA:

- *Incidence*: Leiomyosarcoma is very rare occurring in only **0.2% - 0.5%** of myomas.
- *Malignancy is suspected whenever:*
  - Tumours that elicit a rapid growth without evidence of degeneration
  - Tumours that first appear , or increase in size, in the menopause
  - Tumours that present with postmenopausal bleeding (PMB)
  - Tumours that rapidly recur after surgical excision
- *Macroscopically:* during surgery, the tumour is yellowish in colour, friable, with areas of haemorrhage and capsular invasion leading to difficult enucleation (non-encapsulated).
- *Microscopically:* diagnosis is based on a mitotic count (10 mitotic figures per 10 HPF), with frequent cellular atypia and coagulative necrosis.

EFFECTS OF LEIOMYOMAS on the uterus and pelvic organs

- *Uterine enlargement;* which may be symmetrical or asymmetrical according to its site.
- *Distortion of the endometrial cavity;* in cases of SMM and SMF polyp.
- *Displacement in uterine position;* in large myomas (fundal, BLM and cervical myomas).
- *Increased vascularity and venous congestion;* occur with multiple and large myomas.
- *Pressure on urinary bladder;* leading to frequency of micturition.
- *Overstretching on urethra;* by large cervical myoma may cause retention of urine.
- *Compression on the ureters; by* large cervical and BLMs may cause ureteric, back-pressure with associated hydroureter and hydronephrosis.

CLINICAL PICTURE

- **Age:** Leiomyomas are more prevalent among age groups ranging **35-45** years
- **Parity:** more prevalent among infertile patients, nulliparous and low parity population
- **NO SYMPTOMS:**
  - The majority of *solitary and small fibroids are asymptomatic*, especially SSM and ISM.
  - The nearer the fibroid to the endometrial cavity, the more will be the chances of being symptomatic, even if they are relatively small (as in small SMM and SMF polyp).

SYMPTOMS OF LEIOMYOMAS

One or more of the following symptoms may be present in multiple or large fibroids;

1) Abnormal Uterine Bleeding (AUB)

a. Menorrhagia: this is the commonest presentation for myomas in almost 30% of cases. It occurs mostly with SMM and large multiple ISM. Excessive bleeding may be due to;

- Increased surface area of the endometrium.
- Mechanical interference with uterine contraction.
- Associated EH, and/or hormonal imbalance due to chronic anovulation.
- Increased myometrial vascularity; including venous congestion and engorgement.

b. Metrorrhagia: may be due to

- Sloughing in the tip of a SMF polyp
- Associated disturbed pregnancy
- Sarcomatous changes in a myoma or coincidental uterine carcinoma.



Fig 20-4: Engorged tip of SMF polyp

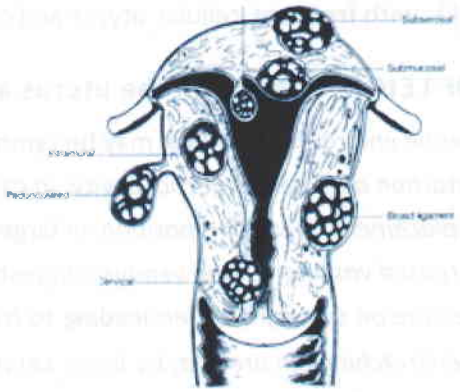

Fig 20-5: Different sites of uterine myomas (cancelled)

2) PELVIC PAIN

Fibroids are **painless unless complicated,** types of pain include:

- *Dull aching pain:* as hyaline degeneration and infection of SMF polyp.
- *Acute abdominal pain:* in red degeneration, and torsion of a pedunculated SSM
- *Colicky pelvic pain:* as with extrusion of a SMF polyp through the cervix
- *Dysmenorrhoea;* congestive or spasmodic dysmenorrhoea: as with SMF and SMF polyp.
- Pain due to common *associated conditions:* as endometriosis.

3) PRESSURE SYMPTOMS

- *Frequency of micturition and dysuria* due to pressure on the urinary bladder
- *Retention of urine* due to stretching and pressure on the urethra by large cervical myoma
- *Referred back and thigh pain,* 2ry to pressure of myomas on pelvic nerves.

4) INFERTILITY

Uterine leiomyomata are an associated cause for infertility in only **5-10%** of cases, and are reported as a sole cause for infertility in **< 3%** of cases. Mechanisms that may cause infertility include:

- Interference with implantation due to distortion of uterine cavity; as in SMM.
- Tubal obstruction may be caused by multiple ISM and/or bilateral cornual fibroids.
- Interference with sperm motility via the cervical canal: as in large cervical myomas.

5) OTHER SYMPTOMS

- ***Pregnancy Complications***

  Recurrent pregnancy loss (RPL), preterm labour (PTL), dysfunctional labour, malpresentations, obstructed labour and post partum haemorrhage.

- ***Leucorrhoea***

  Due to pelvic congestion, or infected fibroid polyp (associated foul discharge)

- ***Progressive Abdominal Enlargement***

  Huge myomas will arise in the pelvis and rise gradually above the pelvic brim, when the patient may present with progressive abdominal enlargement, with or without pressure symptoms.

SIGNS ON CLINICAL EXAMINATION

No specific signs on general examination except for those of pallor if anemia is present

A) ABDOMINAL EXAMINATION:

- Large myomas will be felt abdominally if the uterus enlarges above the pelvic brim, as a central firm mass, with bossy irregular contour, that is usually non tender, of limited mobility, and dull on percussion.
- The upper border is felt by the ulnar border of the examiner's left hand. It may sometimes reach up to the umbilicus, or higher.
- The lower border is not usually felt by the examiner's other hand as the mass is pelviabdominal.

B) LOCAL EXAMINATION:

- ***PV examination;*** may detect cervical myomas and SMF polyp protruding through the cervix
- ***Bimanual examination;*** will detect uterine enlargement, which may be firm with bossy contour, non tender, and with restricted mobility.
- ***Speculum examination;*** may visualize cervical myomas and SMF polyp protruding through the cervix.

DIFFERENTIAL DIAGNOSIS (DD):

- *Large fibroid* must be differentiated from other causes of pelviabdominal swellings.
- *SMM or ISM* from other causes of symmetrical enlargement of the uterus.
- *Calcified myoma;* from other causes of a calcified pelvic shadow on plain X-ray.
- *SMF polyp;* from other causes of a mass protruding from the cervix uteri.

SPECIAL INVESTIGATIONS

1. **Ultrasonography (U.S.)**:

U.S. is considered the ***gold standard*** in the diagnosis of ***uterine leiomyomata***.

- Assessment of the site, size, number, and relation of myomas to the endometrial cavity.
- It is also valuable in detecting adnexal pathology and excluding pregnancy complications.
- Saline infusion sonography (SIS), is sensitive in diagnosis of SMM and SMF polyps.

2. **MRI and CT scan:**

Both MRI and CT scan are diagnostic but are not superior to US, which is cheaper, easier, and more readily available.

3. **Hysterosalpingography (HSG):**

HSG is valuable in diagnosis of *SMM* that appears as a filling defect. It is also important for testing tubal patency in patients complaining of ***infertility.***

4. **Hysteroscopy**:

Hysteroscopy is considered the *gold standard* in diagnosis of small *endometrial polyps, SMF polyps, and SMM*.

5. **Laparoscopy:**

Laparoscopy is a valuable tool in differential diagnosis of complex *adnexal masses*.

MANAGEMENT OF UTERINE LEIOMYOMAS

1. **Conservative Approach:** regular follow up without treatment
2. **Medical treatment** of associated symptoms: to control pain and bleeding
3. **Hormonal treatment:** to control amount of bleeding and size of leiomyomas
4. **Minimally invasive** procedures in selected cases: to avoid surgical approach
5. **Definitive Surgical treatment:**
   a. *Myomectomy:* via laparotomy, laparoscopy, or hysteroscopy
   b. *Hysterectomy:* via laparotomy, laparoscopy, or vaginal route

1. CONSERVATIVE APPROACH:

- ***Periodic follow up:*** every 6 – 12 months is appropriate for asymptomatic small leiomyomas
- ***During pregnancy:*** myomata are managed conservatively until delivery as a rule.
- ***During CS:*** some leiomyomas can be removed during CS especially those at the site of the uterine incision
- ***Rarely torsion*** of a moderate size pedunculated subserous leiomyoma during pregnancy may cause acute abdomen necessitating urgent laparotomy and myomectomy, regardless the gestational age.

  - **N.B.:** Conservative approach is abandoned whenever a leiomyoma reaches a large size or results in severe uncontrollable symptoms as severe pain, pressure symptoms or severe bleeding.

2. MEDICAL TREATMENT:

To control moderate **bleeding** and **pain** through oral or IM drugs as;

a. ***Nonsteroidal Anti-inflammatory drugs (NSAIDs):*** these drugs act by inhibiting PGL synthesis and restoration of PGL / Prostacyclin ratio. They are used to minimize menstrual pain and bleeding.

b. ***Haemostatic drugs*** as Tranexamic acid: that act as fibrinolytic agents to control AUB.

c. ***Venotonic drugs*** as Daflon 500: that act by improving vascular tone and decrease pelvic venous congestion.

N.B.: Medical treatment has no place in cases with severe AUB that affects the patient's general condition and causes severe anaemia that requires parenteral iron therapy or blood transfusion.

3. HORMONAL TREATMENT:

To **minimize** menstrual blood flow and **regulate** withdrawal bleeding or induce 2ry **amenorrhoea**

a. ***Gestagens:*** as oral norethisterone acetate 5 mg 2-3 times daily for 2 weeks throughout days 10-24 of the cycle to induce **regular** cycles every 28 days with **minimal** pain and **bleeding** (see mode of action and doses in AUB, DUB and endometrial hyperplasia).

b. GnRH Agonists: Long acting GnRH agonists (e.g. Leuprolide acetate 3.75 mg IM on **monthly** intervals for 3-6 months), results in suppression of pituitary gonadotropins inducing a state of severe oestrogen deficiency (medical menopause), leading to **2ry amenorrhoea**, with reduction in the size and vascularity of leiomyomas. Hormonal treatment is only **temporary** as it is expensive, induces unpleasant menopausal like symptoms, and finally leiomyomas return to pretreatment size within 6 months of stopping GnRH therapy. GnRH therapy may help preparing the patient for further more definitive treatment.

N.B.: Medical and hormonal treatment are commonly used in combination with each other.

4. MINIMALLY INVASIVE PROCEDURES

Several modalities have emerged in dealing with intermediate size symptomatizing leiomyomas in an attempt to avoid a definitive surgical intervention as myomectomy and hysterectomy. Improved results of treatment are achieved with more use of such modern techniques that require advanced equipment, proper training and above all proper selection of cases suitable for such less invasive modalities.

A. Uterine Artery Embolization (UAE)

B. Laparoscopic Myolysis

C. MRI-guided High frequency Ultrasound (HIFU)

5. DEFINITIVE SURGICAL TREATMENT

Surgical removal of leiomyomas is the only definitive treatment for these benign tumours.

- **Myomectomy**: removal of leiomyomas with preservation of the uterus
- **Hysterectomy:** removal of the uterus including leiomyomas

1. Uterine Artery Embolization (UAE)

- *The procedure:* The uterine artery or its branches are occluded by injection of gel foam pledgets, through a catheter introduced via the femoral artery, thus depriving the tumour from its main feeding vessels leading to shrinkage in size, atrophy and necrosis of leiomyomas.
- *Advantages:* The procedure is relatively safe. It results in 60% reduction in size of myomas, with control of menorrhagia in up to 90% of cases within 8-12 weeks from performing the procedure.
- *Disadvantages*: The main disadvantage is significant postoperative pain (like red degeneration), the need for skilful trained radiology team, and limitations related to the size and number of myomata that could be managed successfully by this procedure. UAE may not be also suitable for patients seeking future fertility.

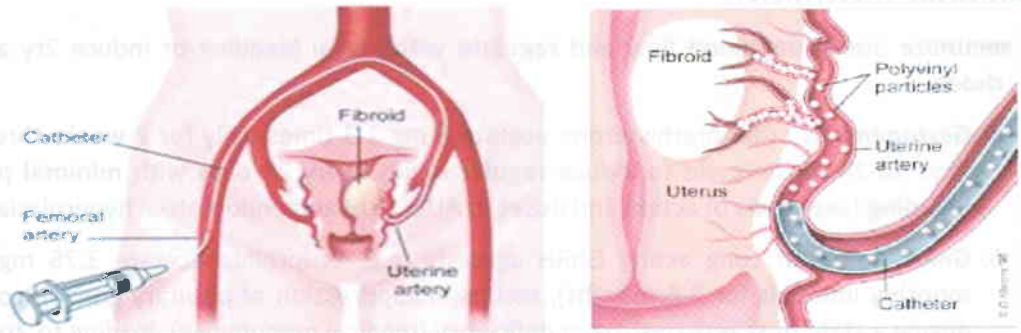

Fig 20-6: Uterine Artery Embolization

2. Laparoscopic Myolysis

- *The procedure:* Laparoscopic myolysis using laser or coagulation current, or cryomyolysis using a -180 C probe.
- *Advantages:* persistent decrease in size of myomas
- *Disadvantages:* effective only in small and SSM which are mostly non symptomatizing. More studies are needed to substantiate its role in management of leiomyomas, patient selection and long term adverse effects.

3. MRI-guided High frequency Ultrasound (HIFU)

- *The procedure:* This is a relatively new treatment option that uses ultrasound generated heat to cause cell death. Fibroids are localized by MRI and heat from a phased array ultrasound transducer is directed towards the myoma to produce protein denaturation.
- *Advantages:* decrease in size and improvement in symptoms may occur in up to 60% of cases.

INDICATIONS OF SURGICAL REMOVAL OF LEIOMYOMAS

a. Large size leiomyomas > 14 weeks pregnancy forming a pelviabdominal mass
b. Leiomyomas causing severe AUB affecting the patient's general condition
c. Leiomyomas causing recurrent abortion, infertility, or interfering with a planned ICSI procedure
d. Any growth in size of a leiomyoma during menopause (suspicious of malignancy)
e. Rapid growth of leiomyomas or rapid recurrence after myomectomy (suspicious of malignancy)
f. Submucus fibroid polyp protruding from the cervix (1ausing excessive bleeding and foul odor discharge)
g. Cervical and broad ligament leiomyomas of intermediate size that may cause ureteric compression

MYOMECTOMY

Myomectomy is performed whenever surgical removal of leiomyomas is mandatory while the patient is young in age, desirous for further fertility, or seeking preservation of her menstrual cycle.

a. **Abdominal myomectomy:** the standard procedure performed via laparotomy to remove large size myomata, especially if multiple in number or recurrent.
b. **Laparoscopic myomectomy:** for removal of intermediate size leiomyomas of limited number (< 5)
c. **Hysteroscopic myomectomy or polypectomy:** for removal of SMF polyp or solitary small submucus leiomyomas < 5 cm in size totally projecting in the endometrial cavity.

- For details on indications, contraindications, technique and complications of myomectomy see gynaecologic operations and procedures chapter 32

HTSTERECTOMY

Hysterectomy is performed whenever surgical removal of leiomyomas is mandatory in presence of multiple or large tumours are present in an elderly patient that has completed her family and not desirous for further childbearing, or whenever malignancy is suspected or patient is menopausal.

a. **Abdominal hysterectomy:** the standard procedure performed via laparotomy, suitable for cases with multiple large myomata, or whenever malignancy is suspected.
b. **Vaginal hysterectomy:** suitable in cases with intermediate size leiomyomas with associated uterine and pelvic organ prolapse (POP)
c. **Laparoscopic Hysterectomy:** is gaining increased popularity in cases with benign intermediate size tumours, whenever proper equipment and training skills are available.

- **N.B.:** for details on indications, contraindications, techniques, and complications of hysterctomy, see gynaecologic procedures and operations chapter 31.

KEY POINTS IN LEIOMYOMATA

- *Fibroids are the commonest benign tumours of the female genital tract, they are usually multiple, and run a very gradual progressive course, being clinically detectable in almost 20% of women.*
- *The aetiology of leiomyomata is unknown. However its growth is oestrogen dependent.*
- *Myomata are liable to 2ry pathological changes that may affect their clinical presentation including; hyaline, cystic, fatty, and red degeneration. In addition to calcification, atrophy, necrosis and malignant changes.*
- *Very small myomas are not clinically detectable, and are usually non-symptomatizing, being incidentally discovered during routine pelvic U.S. scan. They usually require no treatment.*
- *Larger myomas are usually symptomatic, and are diagnosed clinically during a bimanual pelvic examination and confirmed by pelvic ultrasonography.*
- *Large symptomatic fibroids are surgically treated by hysterectomy or myomectomy according to the patient's age and parity, her desire for future fertility, and according to the size and number of myomata and their risk for recurrence or malignant transformation.*
- *Alternative endoscopic techniques for hysterectomy and myomectomy (via laparoscopy and hysteroscopy), myolysis, and selective uterine artery embolization, are generally reserved to carefully selected cases, whenever the skills and experience with such procedures are available.*
- *Some special types of myomata as cervical and broad ligamentary myomata, and uterine polypi, are associated with somewhat different clinical presentation and may require further investigations and different types of treatment*





21 ENDOMETRIOSIS AND ADENOMYOSIS

- *Endometriosis*
- *Adenomyosis*

ENDOMETRIOSIS

OVERVIEW

Endometriosis is the presence of **endometrial glands** and stroma **outside** the endometrial cavity. It is a **chronic disease** that affects women of different ethnic and social groups.

It is estimated to be present in almost **10%** in women in their childbearing period, in around **20%** of women with chronic pelvic pain, and in almost **30%** of women with infertility.

Like the true endometrium, it responds to cyclic hormonal changes and **bleeds at menstruation** producing pelvic **pain**, and in some cases pelvic adhesions causing **subfertility**.

The severity of symptoms does not necessarily correlate with the extent of the endometriosis. Advanced lesions may be sometimes silent while mild disease may cause significant pain.

Laparoscopy is the **gold standard** for **diagnosis**, and is the only method for **staging** the disease in order to plan treatment.

Management of endometriosis is **individualized** for each case based on the extent of the disease, the severity of symptoms, and the need for preservation of fertility.

Management includes **conservative** approach, **medical** and **hormonal** therapy, and finally **surgical** interventions which may be either conservative or extirpative.

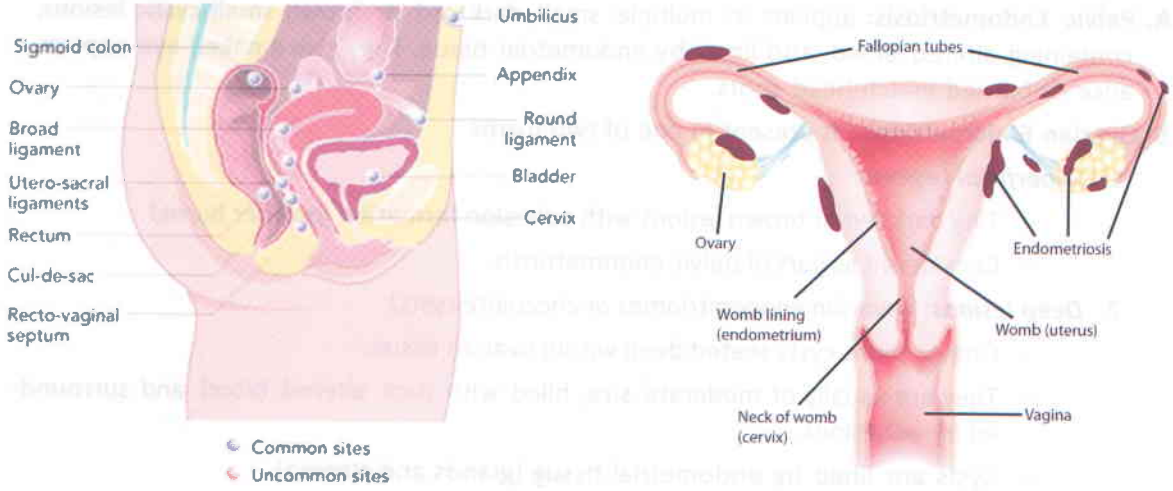

Fig 21-1: Sites of Pelvic Endometriosis

RISK FACTORS:

- Women with higher socioeconomic standard
- Women in their mid reproductive period age 25-35 years
- Women with Infertility, nulliparity, and low parity
- Women with family history of endometriosis in the mother or sister

SITES OF ENDOMETRIOSIS

a. ***Pelvic (Common sites):*** the ovaries, pelvic peritoneum, fallopian tubes, and uterosacral ligaments

b. ***Extra pelvic (Rare sites):*** anywhere in the body as far as the lungs, brain, breast, and umbilicus.

THEORIES FOR AETIOLOGY AND PATHOGENESIS

Several theories have been proposed about the etiology of endometriosis, but no one theory can explain its occurrence in multiple different sites.

1. ***Sampson's theory of Retrograde Menstruation:*** suggests that viable endometrial tissue is transported through the fallopian tubes during menstruation, resulting in intra-abdominal pelvic implants. This theory *explains only pelvic endometriosis*
2. ***Halban's theory of Lymphatic Spread:*** proposes that endometrial tissue is transported via lymphatic system to various intraperitoneal sites, where it grows ectopically. It *does not explain distant sites of endometriosis* as the diaphragm, breast, lungs and brain.
3. ***Meyer's theory of Coelomic Metaplasia:*** proposes that multipotential cells in peritoneal tissue undergo metaplasia transformation into functional endometrial tissue.
4. ***Theory of Altered Immune Response:*** women with endometriosis may have an altered immune response that makes them less likely to recognize an attack of ectopic endometrial implants, leading to reduction in immunologic clearance of viable endometrial cells from the pelvic cavity (reduced natural killer cells and macrophage activity).

PATHOLOGY

A. Pelvic Endometriosis: appears as multiple small dark red or brown small cystic lesions, containing altered blood, and lined by endometrial tissue. They give a naked eye appearance of burned match-head spots.

B. Ovarian Endometriosis: is present in one of two forms

1. ***Superficial Lesions:***
   - Tiny dark red or brown lesions with adhesion formation *(powder burns)*
   - Considered as part of pelvic endometriosis
2. ***Deep lesions:*** *(ovarian endoemtriomas or chocolate cysts):*
   - One or more cysts seated deep within ovarian tissue.
   - They are usually of moderate size, filled with dark altered blood and surrounded by adhesions.
   - Cysts are lined by endometrial tissue (glands and stroma)
   - Histologic examination reveals haemosiderin laden cells and endometrial stroma, that characterize the lesions as endometriosis.

- **N.B.** Free endometriotic implants; grow on surface epithelium supported by endometrial stroma with or without glands, and are usually sensitive to hormonal stimulation and suppression.

CLINICAL PICTURE

Many cases may remain **asymptomatic** for a long period of time, until accidentally discovered during **laparoscopy or laparotomy** performed for different indications not related to endometriosis.

SYMPTOMS IN ENDOMETRIOSIS

- Symptoms when present are only **suggestive** as they are not specific to endometriosis.
- Symptoms do not necessarily correlate with the **severity or extent** of the disease;
  - ➢ Marked pelvic disease may be silent
  - ➢ Small endometriotic pelvic implants may produce significant symptoms.
  - ➢ The same applies for ovarian endometriomas.
- The 2 major clinical presentations of endometriosis are **pain** and/or **infertility**

A) PAIN:

- **Dysmenorrhoea:**
  - 2ry dysmenorrhoea is one of the commonest clinical presentations.
  - Pain starts few years after a period of normal non painful menstrual cycles.
  - It starts during menstruation, and increases rapidly due to distension of ectopic endometrial glands with blood without having an exit.
  - Pain decreases gradually towards the end of the cycle due to absorption of blood within the endometriotic implants.
- **Chronic pelvic Pain:**
  - Diffuse or localized chronic pelvic pain, > 6 months, is strongly suggestive of endometriosis although does not often correlate with the severity of the disease.
- **Dyspareunia:**
  - Deep dyspareunia may be secondary to endometriotic implants of the uterosacral ligaments, pouch of Douglas, ovarian endometriomas, or due to associated fixed RVF uterus.

Mechanism of pain in Endometriosis

- ➢ Distension of ectopic endometrial glands by active bleeding within a closed space.
- ➢ Release of inflammatory mediators (PGLs and Cytokines) from superficial lesions.
- ➢ Irritation of pelvic nerves, or involvement by adhesions in deep lesions.

B) INFERTILITY:

Endometriosis will be discovered at laparoscopy in up to 30% of infertile females, however in many cases it may be an association rather than a cause.

- **Moderate to severe endometriosis;** may compromise fertility through creating pelvic adhesions, which may be peritubal or periovarian, impairing ovum pick up.
- **Mild endometriosis;** may affect fertility through inducing luteal phase defect, and increased tubal phagocytic macrophage activity on the sperms

C) OTHER SYMPTOMS:

- **GIT symptoms:** pain during defecation, intestinal cramps, and rarely cyclic rectal bleeding
- **Urinary symptoms:** dysuria, frequency, and rarely cyclic haematuria
- **Distant metastases:** symptoms according to organ involved (brain, lungs, and umbilicus)

SIGNS IN ENDOMETRIOSIS

- **General Examination:** no general specific signs for endometriosis
- **PV and Bimanual Examination:** only in extensive endometriosis
  - The uterus may be fixed in AVF or RVF position
  - Tender palpable nodules on uterosacral ligaments and pouch of Douglas
  - Endometriomas (chocolate cysts); may be palpated as tender tense cystic fixed adnexal masses in non obese patients

SPECIAL INVESTIGATIONS

A) Laparoscopy:

- Diagnostic Laparoscopy is the **gold standard** in **diagnosis** and **staging** of endometriosis.
- Laparoscopy is indicated in cases of chronic pelvic **pain**, **infertility**, and unresolved adnexal **masses**.
- Laparoscopy allows **direct visualization** of endometriotic implants, and performing **biopsies** for confirming visual diagnosis.
  - **Typical lesion:** endometriotic implants appear as brown or black pigmentations (powder burn lesions) on peritoneal surfaces, surrounded by adhesions.
  - **Atypical lesions:** clear vesicular, white opacified, or red haemorrhagic polypoid excrescences.

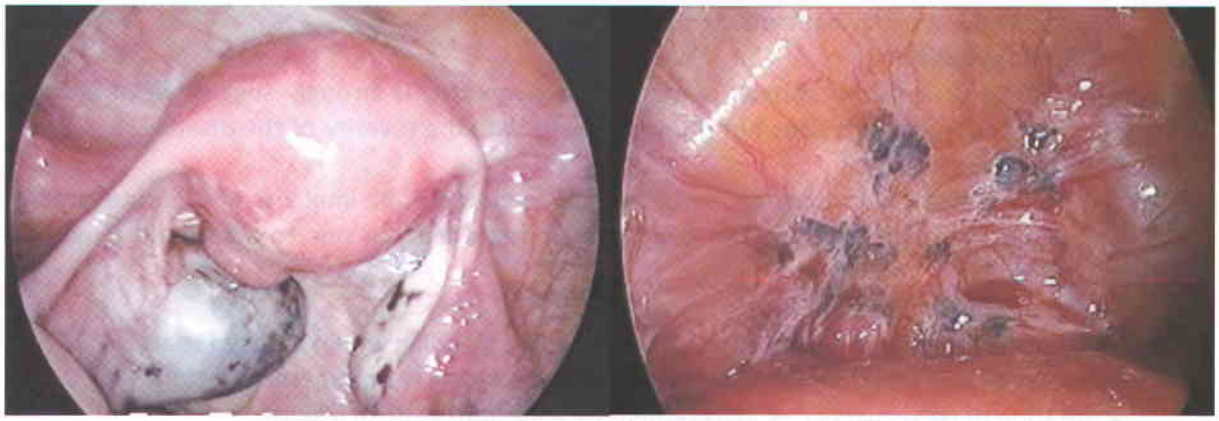

Fig 21-2: Pelvic endometriosis by Laparoscopy

B) **Ultrasonography and MRI**

- Small endometriotic lesions are not visualized with pelvic US
- MRI may detect larger implants and deep seated ones
- Both US and MRI are sensitive in diagnosis of endometriomas even if small in size

C) CA-125

- CA-125 is a cell surface antigen found on coelomic epithelium (Normal 5-35 u/ml)
- It shows slight to moderate increase in levels in many cases of endometriosis, but is not a specific marker
- It is a useful marker for response to treatment in cases with initially elevated levels

Classification of Endometriosis

During laparoscopy the extent of classic lesions, ovarian involvement, and presence of adhesive disease is classified and graded according to the American Society of Reproductive Medicine (ASRM).

Differential Diagnosis

a. Causes of chronic pelvic pain; PID, Irritable bowel syndrome, ureteric pain, etc...
b. Endometriomas from other causes of adnexal masses: haemorrhagic ovarian cyst, dermoid cyst, tubo-ovarian complex, pelvic malignancy

Course of the Disease

- The disease is usually progressive in 30-60% of cases.
- Prolonged periods of amenorrhea are associated with remarkable improvement of symptoms.
- During pregnancy, lesions tend to enlarge during the first trimester then regress.
- Recurrence of endometriosis after surgical excision will recur in up to 20% of cases. Recurrence is less after extirpative surgery, and also with postoperative periods of amenorrhoea as during pregnancy or GnRH therapy

MANAGEMENT OF ENDOMETRIOSIS

Management of endometriosis is planned according to several factors including; age of the patient, severity of symptoms, future reproductive plans, and extent of the disease at laparoscopy.

EXPECTANT MANAGEMENT:

Expectant management is appropriate for young patients, with **minimal symptoms** and **minimal signs**. The goal of expectant management is;

- Effective control of pain, using **NSAIDs**.
- Follow up for growth of lesions (endometriotic implants or endometriomas)

MEDICAL TREATMENT:

Medical treatment is indicated in cases with **marked symptoms** and **minimal signs**. Treatment is based on the observation that symptoms of endometriosis improve during pregnancy and menopause.

1. **Combined Oral Contraceptive Pills (COCs):**
   - *Aim:* induces amenorrhoea with a pseudo pregnancy state
   - *Mechanism:* amenorrhoea, pseudo-decidualization, and atrophy of ectopic endometrium.
   - *Dose:* continuous COCs once daily for 4-6 months
   - *Disadvantages:* side effects of hormone therapy as weight gain, bloating, headache, etc..
2. **Synthetic Progesterone (Gestagens):**
   - *Aim:* induces amenorrhoea with a pseudo pregnancy state
   - *Mechanism:* pseudo-decidualization, followed by atrophy of ectopic endometrium
   - *Doses:* continuous gestagen treatment for a 6-9 months course
     - *Nor- ethisterone acetate :* 5.0 mg orally, 2-3 times daily.
     - *Dienogest:* 2.0 mg oral tablets, once daily, effectively controls pain.
     - *Depot Medroxy Progesterone acetate (DMPA):* 150 mg IM injections, every 3 months
   - *Disadvantages:* side effects as bloating, weight gain, headaches, and breakthrough bleeding.
3. **Long acting Gn RH agonists**
   - *Aim:* induces amenorrhoea with a pseudo menopause state.
   - *Mechanism:* menopause like hyopo-oestrogenic state, with atrophy of ectopic endometrium. It starts with an initial FSH stimulation, followed by down regulation of receptors with suppression of FSH and LH, and consequently decreased oestrogen levels.
   - *Doses:* Depot forms given IM monthly or every 3 months for 6-9 months

– *Disadvantages:* hot flushes, vaginal dryness, and accelerated bone loss
– Adverse effects may be minimized by the use of low dose oestrogen (add back therapy)

N.B.: Danazol a testosterone derivative that produces high androgen, low oestrogen environment and 2ry amenorrhoea is no more in use due to its marked irreversible androgenic side effects on prolonged use.

C) SURGICAL TREATMENT OF ENDOMETRIOSIS:

Surgery is the best choice in cases with pelvic adhesions and / or larger endometriomas.

1. **CONSERVATIVE SURGERY:**
   - Excision, fulguration, or laser ablation of all visible lesions
   - Lysis of pelvic peritubal and periovarian adhesions.
   - Excision of sizable endometriomas (> 4.0 cm)

Conservative surgery can be achieved via either;

a. ***Laparoscopy:*** is the gold standard for conservative surgical approach. It is suitable for the infertile patients aiming to restore normal anatomy with creating minimal postoperative adhesions.

b. ***Laparotomy:*** is reserved for the severe cases with extensive adhesions or large endometriomas.

- **N.B.:** Preoperative hormonal treatment by a 3-months course of GnRH may reduce vascularity and nodular size, facilitating surgery and improving the prognosis.

2. EXTIRPATIVE SURGERY:

– ***TAH & BSO*** is the procedure usually performed in elderly patients, with extensive disease, and no desire for fertility. It has limited place and limited indications.
– Oestrogen replacement therapy (ERT) is recommended in the relatively young patient to relieve associated menopausal symptoms.
– ERT carries only a small risk of inciting growth of small residual endometriosis while if the ovaries were preserved recurrence rate will be high with a 15-40% chance to reoperate.

- ***Summary for Treatment Options for a case of Endometriosis:***
  - Minimal lesion + desire for fertility: conservative surgery + assisted reproduction
  - Endometrioma > 4.0 cm: Excision and laser ablation via laparoscopy, or laparotomy
  - Extensive lesion + no desire for fertility+ elderly: TAH-BSO + excision and ablation of implants

MANAGEMENT OF Endometriosis Associated Infertility

a. ***Conservative laparoscopic surgery:***
   – Diagnosis and staging of endometriosis
   – Ablation of endometriotic implants, and lysis of adhesions
   – Excision of larger sized endometriomas > 4.0 cm.
   – Evaluation of tubal and peritoneal factors of infertility

b. ***Suppression of menses:*** using GnRH agonists for 6 months postoperative, **OR**

c. ***Active management of infertility***: via;
   – Controlled ovarian stimulation
   – Assisted reproductive techniques (ART) including; IUI and ICSI procedures.

ADENOMYOSIS

Adenomyosis is the presence of endometrial glands and stroma deep within the myometrium. It has been formerly considered as internal endometriosis however it is now looked upon as a separate pathological entity, affecting primarily multiparous women in their late thirties and early forties.

AETIOLOGY

The aetiology of adenomyosis is **unknown**

- Theories postulate that it may be due to growth of endometrial glands deeply between muscle fibers of the myometrium in presence of abundant oestrogen environment.
- Adenomyosis is associated with smooth muscle hypertrophy around the ectopic glands.

PATHOLOGY

A. Diffuse type: the uterus is symmetrically enlarged, globular in shape, with a firm consistency reflecting myometrial thickening generally affecting the fundus but may also involve either or both uterine walls.

B. Localized type: adenomyosis may be localized at an area very similar to uterine leiomyomata, which may coexist in the same uterus (adenomyoma). Unlike the myoma localized adenomyosis is not encapsulated

- ***The cut surface*** may have a whorl-like or granular trabecular pattern with small yellow or brown cystic spaces containing fluid or blood.

CLINICAL PICTURE

A) SYMPTOMS

Severely increasing **2ry dysmenorrhoea** and /or **Menorrhagia** are the chief symptoms.

- **Spasmodic dysmenorrhoea**: is due to contractions provoked by premenstrual swelling and menstrual bleeding
- **Menorrhagia** is due to increased uterine size and endometrial surface area

B) SIGNS on BIMANUAL EXAMINATION

- **Symmetrically enlarged uterus** which is sometimes tender especially in the premenstrual period (Halban's sign).

C) SPECIAL INVESTIGATIONS

- **Ultrasonography (TAS/TVS/3DUS):** will reveal thickened myometrium, sometimes associated with localized areas of different echogenicity somewhat similar to leiomyomas.
- **Magnetic resonance imaging (MRI);** gives excellent images of the myometrium with areas of adenomyosis and is being regarded as the *investigation of choice*.

TREATMENT OPTIONS:

- ***Dysmenorrhoea*** can be managed by *NSAID* (see endometriosis).
- ***Menorrhagia*** can be managed by
  - *Antifibrinolytics* as tranexamic acid and *venotonics* as Diosmin.
  - *Gestagens* as norethisterone acetate 5 mg t.d.s. for 2 weeks / month
  - *Combined oestrogen/progesterone* as COCs & Cycloprogynova 21 days/month
  - *LNG IUD* (Mirena) effective in control of bleeding within 3 months of insertion (see AUB)
- ***Hysterectomy*** is the treatment of choice in cases of severe perimenopausal bleeding not responding to medical or hormonal treatment. Hysterectomy is also the only way to establish the diagnosis with certainty.

Key points in Endometriosis

- *Endometriosis is present in almost 10 % of women in their child bearing period, but is more prevalent in cases of severe dysmenorrhoea, chronic pelvic pain and infertility.*
- *Severe forms may result in adhesive disease forming peritubal adhesions or may affect the ovary resulting in endometriomas*
- *Clinical examination is usually inconclusive however in severe cases it may reveal an adnexal swelling, a fixed RVF uterus and or tender nodules in pouch of Douglas.*
- *Laparoscopy is the gold standard for diagnosis and staging of endometriosis*
- *Elevated CA-125 may act as a marker for follow up rather than for primary diagnosis*
- *Management is according to severity of the disease and its effect on fertility. It may be either; expectant, medical, surgical, or combined.*
- *Medical therapy does not dissolve adhesions or eliminate endometriomas, it is therefore not suitable for cases presenting with infertility*
- *Laparoscopic adhesiolysis, fulguration of endometrial implants, and excision of endometriomas, is the treatment of choice for infertile cases.*
- *Adjuvant postoperative medical therapy may by used including ovarian stimulation to assist ovulation in mild cases, or ovarian suppression to induce periods of amenorrhea in severe cases, leading to alleviation of symptoms and atrophy of ectopic implants.*

22 SCREENING FOR PREMALIGNANT LESIONS FEMALE LOWER GENITAL TRACT

- *Cervical Intraepithelial Neoplasia (CIN)*
- *Vaginal Intraepithelial Neoplasia (VAIN)*
- *Vulvar Intraepithelial Neoplasia (VIN)*

CERVICAL INTRAEPITHELIAL NEOPLASIA (CIN)

BENIGN SQUAMOUS METAPLASIA:

Both the **squamous cells** (covering the ectocervix) and the **columnar cells** (lining the endocervix) come from **immature reserve cells** present at the **squamo-columnar junction SCJ** (the junction between the ectocervical squamous epithelium and endocervical glandular epithelium).

The **immature reserve cells** at the **SCJ** continuously generate both squamous cells and columnar cells by **metaplasia** throughout the female's life.

The **SCJ** changes its place by age, moving slowly continuously towards the internal cervical os;

- *During childhood;* it is at the outer edge of the external os
- *During the reproductive life;* it moves slightly inwards few millimeters within the external os
- In postmenopausal women; it moves further inwards to be placed inside the cervical canal.

The Transformation Zone (TZ): is the **area where squamous metaplasia occurs. It lies between original SCJ and the new SCJ.**

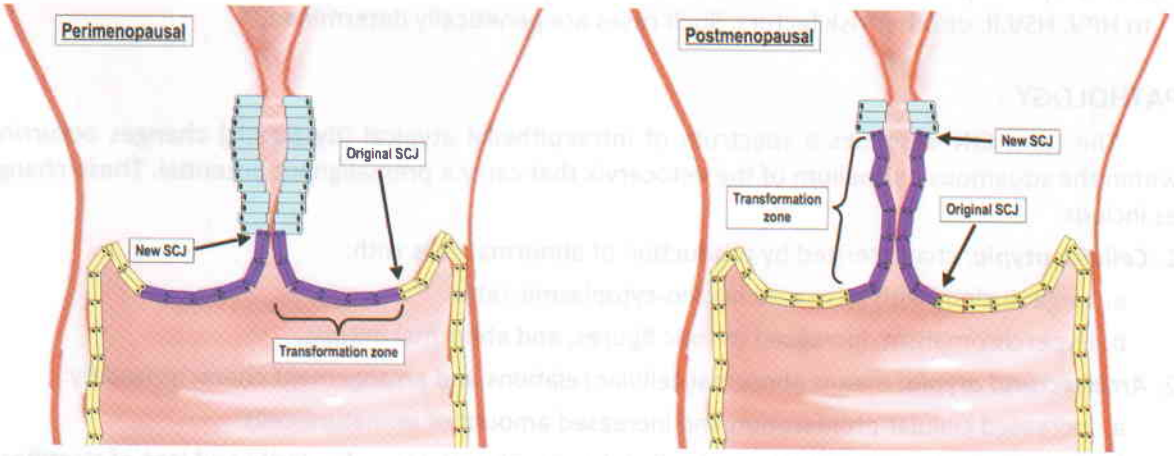

Fig 22-1: Transformation zone TZ

ABNORMAL METAPLASIA AND CIN

Continuous exposure of **reserve cells** at the **TZ** to **carcinogenic factors**, as **viral DNA** may lead to the production of **atypical cells** (through atypical metaplasia) or **dysplasia** (disordered growth) which might progress by time to **preinvasive** or **invasive** cervical **cancer**.

- **Cervical Intraepithelial Neoplasia (CIN):** describes the presence of **atypical cells** inside the cervical epithelium **without invasion** of the basement membrane.

RISK FACTORS FOR CIN:

1. Abnormal sexual activity:

- Early age at first sexual intercourse (the transformation zone being near to external os).
- Multiple sexual partners (subject cervical epithelium to variable foreign proteins).

2. Viral sexually transmitted diseases:

A. Human Papilloma Virus (HPV):

- High-risk HPV types include 16, 18, 31, 33, 35, 45, & 58, and account for nearly 95% of precancerous lesions worldwide.
- In almost 70-80% of women exposed to genital HPV, the infection is transient, and cleared by the immune system in 1-2 years.
- If the virus remains present for several years, in patients with low immunity and repeated exposures, cervical intraepithelial neoplasia (CIN) may develop.

B. ***Herpes Simplex Virus type II (HSV-2):***

- HSV-2 DNA and messenger RNA sequences have been found in cervical cancer cells.
- They may also increase the likelihood of HPV infection.

3. Low socioeconomic standards and **poor hygiene (chronic irritation).**

4. Cigarette smoking. (By-products in cigarettes may concentrate in cervical epithelium, with depletion of Langerhan's cells that assist in cell mediated immunity).

5. **Immuno-suppression** (HIV infection, or immunosuppressant drugs used in organ transplant).

6. **Genetic predisposition:** some cases, which develop cervical cancers, have never been exposed to HPV, HSV II, or other risk factors. Such cases are genetically determined.

PATHOLOGY:

The term **CIN** describes a spectrum of intraepithelial atypical (dysplastic) changes occurring within the squamous epithelium of the ectocervix that carry a premalignant potential. These changes include:

1. ***Cellular atypia:*** characterized by production of abnormal cells with:
   a. Large nucleus with increased nucleo-cytoplasmic ratio.
   b. Hyperchromatism, increased mitotic figures, and abnormal mitosis.
2. ***Architectural atypia:*** means abnormal cellular relations and arrangement characterized by:
   a. Increased cellular proliferation and increased amount of immature cells.
   b. Disparity in the size and shape of cells (pleomorphism), Loss of polarity and loss of stratification.

Histological Grading of CIN (according to its premalignant potential);

- ***CIN 1:*** dysplastic cells occupy the basal one third (1/3) of the thickness of the squamous epithelium. Cells of the upper 2/3 show normal stratification and maturation.
- ***CIN II:*** dysplastic cells occupy one half (1/2) of the thickness of squamous epithelium. Cells of the upper 1/2 show normal stratification and maturation.
- ***CIN III:*** dysplastic cells occupy the full thickness of the squamous epithelium, without invasion of the basement membrane. CIN III & in situ carcinoma are grouped in one category.

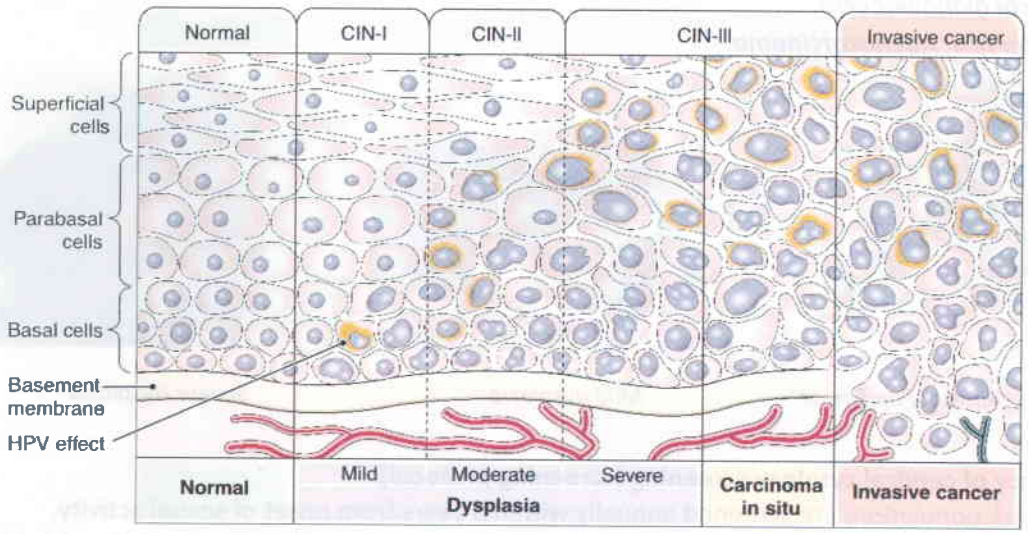

Fig 22-2: Histologic grading of CIN

Natural History of CIN

If untreated, CIN-1 may undergo **spontaneous regression**, remain **stationary**, or will **slowly progress** (throughout a period of 7-10 years) through grades II, III, preinvasive cancer, or finally invasive cervical cancer.

DIAGNOSIS OF CIN

- **CIN** usually affects women in **younger age** groups (25-45 years).
- It is usually **asymptomatic.**
- **Diagnosed** through routine screening of high risk women by the **Pap smear** test (see later).
- Suspicious Pap smears are **confirmed** by **colposcopy** and **biopsies** from abnormal areas (see later).

1. CERVICAL PAP SMEAR Test:

- The Pap smear test is based on cytologic examination of cells shed from both the ectocervix and endocervix.
- It is performed using a **cytobrush** to wipe cells from the endocervical canal and from the surface of the TZ of the ectocervix.
- Cells obtained are spread on a glass slide fixed by ethyl alcohol and stained by **Papanicolaou stain.**
- The test is done as an office procedure with an accuracy rate up to 95%.

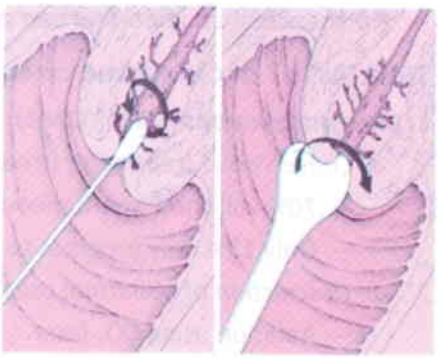

Fig 22-3: Pap smear test

- **Interpretation of a Pap smear:**
  1. ***Negative*** (no atypical cells).
  2. ***ASCUS*** *(Atypical squamous cells of undetermined significance);* this indicates cells that are suggestive but do not fulfil the criteria for squamous intra-epithelial lesions **(SIL)**. For its evaluation, testing for HPV, repeat cytology, and colposcopy, are required.
  3. ***LSILs*** *(Low grade squamous intra-epithelial lesions)* concomitant with **CIN I**.
  4. ***HSILs*** *(High grade squamous intra-epithelial lesions)* concomitant with **CIN II & CIN III**.
  5. ***Squamous cell carcinoma.***
  6. ***Atypical*** *glandular cells.*
  7. *Endocervical* ***Adenocarcinoma.***



Fig 22-4: Normal Pap Smear *Mild dysplasia* *Severe Dysplasia*

- **Frequency of cervical cytology screening (screening protocol):**
  - High risk population; are screened annually within 3 years from onset of sexual activity.
  - Low risk population; (age of >30, with 3 consecutive annual negative pap smears) should be screened every 3 years.
  - Low risk women over the age of 70; (with 3 negative Pap smears in the last decade) can consider discontinuation of Pap testing at the physician's advice.

COLPOSCOPY:

- Colposcopy allows **inspection** of the **TZ** with a magnification up to 20 times after applying 3%-5% acetic acid solution.
- Colposcopic directed **biopsies** are performed from areas of abnormal epithelium (aceto-white areas, punctuation, mosaicism, leukoplakia, and Schiller's iodine negative areas) with accuracy of 85%- 95%.
- Endocervical curettage is performed to rule out dysplasia when the TZ in the cervical canal is not properly visualized in presence of an abnormal pap smear.

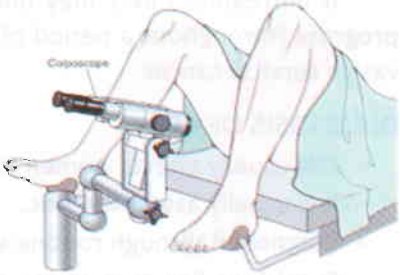

Fig 22-5: Colposcopic examination of the cervix

TREATMENT of CIN (based on colposcopic obtained biopsies);

1. Low grade lesions (LSILs - CIN 1):

a. *Conservative treatment;* (treat infection and repeat smear within 12 weeks);
   - 70% will show spontaneous regression
   - Only 15% may progress to high grade abnormality.

b. Destruction of abnormal cells at TZ if the lesion persists in repeated smears;
   - Ablation using CO_2 laser.
   - Cauterization by heat or electro-cautery.

2. *High grade lesions (HSILs - CIN II-III):*

HSILs are managed by **excision of abnormal cells at the TZ** since they are more likely to progress to preinvasive or invasive cancer if neglected or inadequately treated. Excision is performed via;

a. *Cold knife conization:* is the gold standard as it yields an adequate pathologic specimen with clean margins. However postoperative bleeding, infection, cervical stenosis, and cervical incompetence, are major complications of this simple procedure.

b. *Loop Electrosurgical Excision Procedure (LEEP):* a hot metal wire loop is used to excise a wedge of cervical tissue at transformation zone (TZ}. It has the drawback of yielding a smaller pathologic specimen with charred margins, but is associated with less postoperative complications than cold knife conization.

c. *Total abdominal hysterectomy (TAH)* in older patients with resistant disease and those not desiring fertility.

Follow Up After Treatment: Despite the efficacy of techniques in treating CIN yet recurrence is still common and follow up by annual Pap smears is recommended for around 10 years.

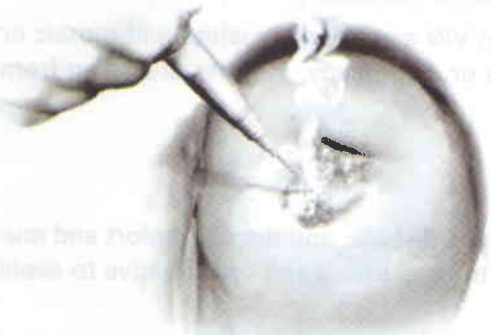

Fig 22-6: Diathermy destruction of CIN

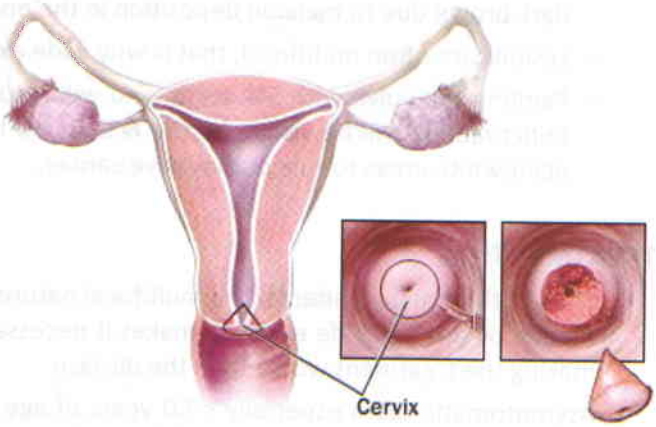

Fig 22-7: Cold knife excision of TZ

VAGINAL INTRAEPITHELIAL NEOPLASIA (VAIN)

It is an uncommon premalignant lesion of the vagina which is usually asymptomatic. It may be associated with neoplasia at other genital tract sites as VIN and CIN.

Diagnosis:

- Pap smear; showing abnormal vaginal epithelial cells.
- Diagnosis is confirmed by colposcopic examination of the vaginal epithelium with guided biopsies from suspicious areas.

Treatment: individualized weather through;

1. Laser destruction (ablation) of the affected area under colposcopic guidance, or
2. Local surgical excision of suspicious area, or
3. Topical chemotherapy using 5-flurouracil vaginal cream for multifocal lesions.

VULVAR INTRAEPITHELIAL NEOPLASIA (VIN)

VIN is defined like CIN as presence of atypical (dysplastic) cells within the vulvar epithelium without invasion of the basement membrane.

VIN is classified after the International Society for the Study of Vulvar Diseases (ISSVD) 1986 into three degrees namely; VIN I, II, and III (like CIN). In 2012 terms were changed into **LSIL** and **HSIL** like CIN.

Although VIN seems to have low malignant potential. It commonly occurs in younger age where almost half of the cases are younger than 41 years. Spontaneous regression of VIN I & II is well reported.

DIAGNOSIS:

Symptoms: 1/3 of cases are asymptomatic, however VIN often presents as pruritus vulvae.

Signs:

- Lesions are often raised above the surrounding skin with a rough surface.
- Colour is variable: whitish due to hyperkeratinization, red due to thinning of epithelium, or dark brown due to melanin deposition in the epithelial cells.
- Lesions are often multifocal, that is why wide excision is mandatory.
- Painting the vulva with 5% acetic acid will result in VIN areas turning white and mosaic or punctuations will be visible by the N.E., hand lens or colposcopy. Biopsies are taken from acetowhite areas to rule out invasive cancer.

TREATMENT:

- The youth of many patients, the multifocal nature of the disease, and the discomfort and mutilation of surgical wide excision, makes it necessary to be cautious and conservative to avoid making the treatment worse than the disease.
- Asymptomatic cases especially < 50 years of age are managed conservatively, with repeated biopsies to exclude progression of the disease.
- Symptomatic cases are treated by topical steroids for 3-6 months to relieve symptoms.
- If the lesion is small; excision biopsy is enough (both diagnostic and therapeutic).
- Wide and multifocal lesions: skinning vulvectomy with or without skin graft is performed.
- Follow up and re-biopsy are essential to detect invasive disease among those who relapse. Repeated treatments are commonly required.

N.B: Paget's disease: (adenocarcinoma in situ):

- It is an uncommon condition similar to that found in the breast. In almost 1/3 of cases there is an associated adenocarcinoma in the apocrine gland, and in 20% concomitant cervical cancer may be present.
- Pruritus is the presenting complaint.
- Often presents as a red crusted plaque with sharp edges.
- Biopsy is confirmatory.
- Treatment: is by very wide local excision usually including total vulvectomy, because unlike VIN III the histologic extent of Paget's disease is frequently beyond the visible lesion.

23 ENDOMETRIAL CARCINOMA AND UTERINE SARCOMA

- *Endometrial Carcinoma*
- *Sarcoma of the Uterus*
- *Gestational Choriocarcinoma*

ENDOMETRIAL CARCINOMA

OVERVIEW

Endometrial carcinoma (EC) is now considered the **most common** gynaecologic malignancy. The rise in the incidence of EC, noted in the last decades, is expected to continue due to the **prolonged life span** of women in general, together with the more liberal use of **hormone therapy** in the management of menopause.

EC is also described as the **most curable** gynaecologic cancer owing to the fact that most cases are diagnosed at an **early stage**, and when offered the proper treatment women with **stage I** disease will have a **5 year** survival rate exceeding **85%**.

Oestrogen induced endometrial hyperplasia **(EH),** unopposed by **PRG** forms the most important background in development of **EC**.

Non oestrogen dependant EC is a much less common type of the disease, but is more aggressive and carries poorer prognosis than oestrogen dependant type.

RISK FACTORS FOR EC

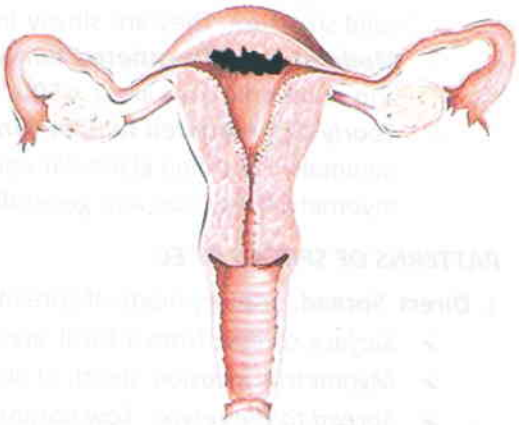

Fig 23-1: Endometrial carcinoma

- ***Nulliparity*** (absent periods of amenorrhoea during pregnancy and lactation)
- ***Late menopause*** age > 55 years (long period of anovulatory premenopausal cycles)
- ***PCOS*** (chronic anovulation results long periods of E2 unopposed by PRG)
- ***Marked Obesity*** (increased peripheral conversion of androgen to E1 in adipose tissue)
- ***Unopposed oestrogen therapy*** (as oestrogen replacement therapy in menopause ERT)
- ***Long term Tamoxifen therapy*** (in treatment of oestrogen receptor positive breast cancer)
- ***Atypical endometrial hyperplasia EH*** (see DUB)
- ***Oestrogen producing ovarian neoplasm*** (e.g.; granulosa theca cell tumour)

N.B.: Long term use of **OCPs** is usually associated with a **decreased risk** of EC by nearly **50%**, due to the effect of Gestagens in protection from endometrial hyperplasia (EH).

Premalignant potential of various types of EH (WHO classification)

Type of EH	Progression to EC
• *Simple EH*	*1 %*
• *Complex EH*	*3 %*
• *Simple EH with atypia*	*8 %*
• *Complex EH with atypia*	*29 %*

PATHOLOGY OF ENDOMETRIAL CARCINOMA

A. Gross Pathology

- ***Localized type:*** localized area of endometrial affection in the form of **nodule** or **polyp**.
- ***Diffuse type:*** diffuse endometrial thickening or multiple endometrial polyps.

B. Microscopic Histopathology

- ***Adenocarcinoma:*** is the commonest pathologic type of EC, and carries best prognosis.
- ***Adenoacanthoma:*** is an **adenocarcinoma** with areas of **benign squamous** metaplasia. It carries same prognosis as adenocarcinoma.
- ***Adenosquamous:*** is an **adenocarcinoma** with areas of **malignant squamous** carcinoma. It carries poorer prognosis than adenocarcinoma and adenoacanthoma.
- ***Primary squamous cell carcinoma, papillary serous carcinoma and clear cell carcinoma*** are particularly aggressive but fortunately **very rare** types of endometrial carcinoma.

C. GRADING OF THE TUMOUR

Tumour grade is determined by both the degree of abnormality of the glandular architecture, and the degree of nuclear atypia.

- ***Well differentiated tumour (Grade I):*** normally looking glandular epithelium with **< 5%** solid structure. They are slowly invasive and carry the **best prognosis**.
- ***Moderately differentiated tumour (Grade II);*** glandular structure admixed with papillary and occasional solid areas **< 50%**. It is more aggressive and carries **intermediate prognosis**.
- ***Poorly differentiated tumour (Grade III));*** the structure becomes predominantly solid, with minimally identified glandular epithelium. The tumour is highly aggressive with early deep myometrial invasion and generally **poor prognosis**.

PATTERNS OF SPREAD OF EC

1. **Direct Spread:** primary mode of spread
   - *Surface spread;* from a focal area to the rest of endometrial surface.
   - *Myometrial invasion:* depth of invasion correlates directly with prognosis of EC.
   - *Spread to the cervix:* Low corporeal EC cancer may spread directly to the cervix.
   - *Direct spread to ovaries:* may occur when exfoliated malignant cells pass through the fallopian tubes and implant on the ovaries, omentum, and peritoneal surfaces
2. **Lymphatic Spread:** Occurs later than direct spread

The risk of LN involvement increases with increased **grade** of tumour, **depth** of myometrial invasion and **stage** of the disease. Spread occurs through;

- *Para-aortic nodes:* draining the fundus.
- *Inguinal nodes:* draining the cornu
- *Para-cervical nodes:* draining the isthmus and lower body.
- *Ovaries and vault of vagina:* may be involved by lymphatic spread, in cases with deep myometrial invasion.

3. **Vascular Spread:** occurs late usually with higher grade tumours.
   - Metastases to nearby intra-pelvic organs
   - Distant extra-pelvic metastases rarely occurs (liver, lung, brain & bones).

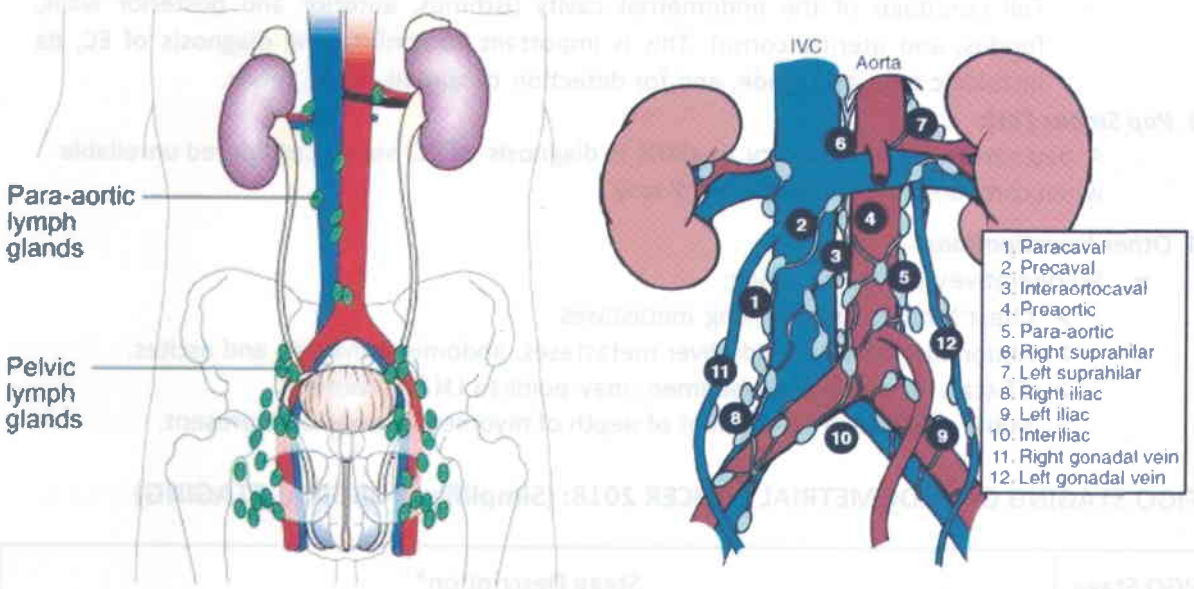

Fig 23-2: Lymphatic spread of EC

CLINICAL PICTURE

EC usually presents as **AUB** in **postmenopausal** women, with added risk to those who are nulliparous, obese, diabetic and hypertensive.

SYMPTOMS:

1. ***Post-menopausal bleeding;*** is the commonest presenting symptom in cases with EC.
2. ***Metrorrhagia:*** perimenopausal women present with **AUB**, which is recurrent and profuse even after medical or hormonal treatment.
3. ***Other symptoms:*** offensive vaginal discharge, menstrual cramps, and deep pelvic pain.

SIGNS ON LOCAL EXAMINATION:

a. Bimanual Examination:
- The uterus may be normal or slightly symmetrically enlarged in size
- Consistency is usually softer than expected in a menopausal uterus.
- The adnexae may be free, or may show a solid ovarian neoplasm, or metastases.

b. Speculum examination: is important to exclude;
- Cervical mass or ulcer (in cases of cervical involvement)
- Foul odor cervical discharge (in cases of pyometra)

SPECIAL INVESTIGATIONS

1. ***Transvaginal Sonography (TVS):***
   - *Increased endometrial thickness* in postmenopausal women above the cut-off value of 5.0 mm is strongly suspicious of EH. Thicker endometrium > 10 mm correlates with EC.
   - *Associated uterine lesion* as myomas, polyps, haematometra, or pyometra.
   - *Associated adnexal masses:* as ovarian neoplasms

2. Fractional Curettage (FC):

- **FC** the **gold standard** method for diagnosis of **EC**.
- An endocervical biopsy is first obtained before cervical dilatation
- Full curettage of the endometrial cavity (isthmus, anterior and posterior walls, fundus, and uterine cornu). This is important to confirm the diagnosis of EC, its histologic type and grade, and for detection of spread to the cervix.

3. ***Pap Smear Test:***

- A pap smear has an accuracy of **<50%** in diagnosis of EC, hence considered unreliable when compared with endometrial biopsy.

4. ***Other Investigations:***

- Preoperative work Up including;
  - Chest X-ray to exclude lung metastases.
  - Abdominal US to exclude liver metastases, abdominal masses, and ascites.
  - CT scan for pelvis and abdomen, may point to LN involvement
  - MRI is sensitive in assessment of depth of myometrial invasion if present.

FIGO STAGING OF ENDOMETRIAL CANCER 2018: (Simplified SURGICAL STAGING)

FIGO Stage	Stage Description*
I	**The cancer is growing inside the uterus.**
IA	The cancer is in the endometrium (inner lining of the uterus) and may have grown less than halfway through the myometrium
IB	The cancer has grown from the endometrium into the myometrium. It has grown more than halfway through the myometrium.
II	**The cancer has spread from the body of the uterus and is growing into the cervical stroma. But it has not spread outside the uterus.**
III	**The cancer has spread outside the uterus.**
IIIA	The cancer has spread to the outer surface of the uterus (the serosa) and/or to the fallopian tubes or ovaries (the adnexa).
IIIB	The cancer has spread to the vagina or the parametrium
IIIC1	The cancer is growing in the body of the uterus. It has also spread to pelvic lymph nodes, but not to para-aortic lymph nodes
IIIC2	The cancer is growing in the body of the uterus. It has also spread to the para-aortic lymph nodes.
IV	**The cancer has spread to other organs**
IVA	The cancer has spread to the inner lining of the rectum or urinary
IVB	The cancer has spread to inguinal (groin) lymph nodes, the upper abdomen, the omentum, or to organs away from the uterus, such as the lungs, liver, or bones

FIGO: *International Federation of Gynaecology and Obstetrics*
N.B.: Endocervical glandular involvement is considered stage I disease

MANAGEMENT OF ENDOMETRIAL CARCINOMA

Following **surgical staging** the treatment will depend upon several factors including; the **stage** of the disease, which is the most important factor, the **histologic type** and **grade** of the tumour, and the patient's **age** and **general health**.

STAGE I:

A. Surgery

- An exploratory **laparotomy** with total abdominal hysterectomy and bilateral salpingo-oophorectomy **(TAH-BSO)** is the gold standard treatment, performed in all patients, unless there are absolute medical contraindications.
- Peritoneal **washings** are taken with normal saline for cytological examination.
- Pelvic **lymphadenectomy** is performed on **high risk** cases including those with serous, clear cell, or grade 3 histology tumours, and in cases with stage IB (either outer half myometrial involvement or cervical glandular extension).

B. Radiation Therapy

- Cases of **adenocarcinoma** stage **Ia** or **b**, grade **1&2**, can be followed **without** adjuvant radiotherapy.
- High risk cases, with **serous** or **clear cell** carcinoma, any **grade 3** tumour, or with **one positive** pelvic node, should receive **external beam pelvic radiation**.
- Cases with **multiple** pelvic LNs of **para-aortic** LN involvement should receive **extended field radiation** (pelvic and abdominal)
- Patients medically unfit for surgery may receive radiation therapy alone. A combination of intracvitary plus external beam radiation, with an overall 5-year survival rates 20% lower than those treated with TAH-BSO.

C. Hormone Therapy

- EC rarely occurs in women < 40 years of age. These tumours are usually early stage, and low-grade, and there is frequently a desire to preserve fertility and avoid hysterectomy.
- High dose medroxyprogesterone acetate (200 mg twice daily) for 3-6 months will reverse the changes in about 2/3 of cases. Recurrences are common.

STAGE II:

- When the cervix is involved, a radical hysterectomy with pelvic lymphadenectomy will be the procedure of choice in surgically fit patients (see cancer cervix).

MANAGEMENT OF ADVANCED STAGES (stage III & IV):

For advanced disease treatment should be individualized. It may include a combination of;

- ***TAH-BSO*** if possible as palliative therapy for bleeding, pain, & other pelvic symptoms.
- ***Radiation therapy:*** extended external beam irradiation
- ***Chemotherapy:*** combination of Cisplatin and Doxorubicin has been recently studied either alone or in combination with radiotherapy with encouraging results.

RECURRENT DISEASE

- More than 80% of recurrences occur within the first two years of treatment.
- The vaginal vault is the primary site for recurrent disease
- Other sites include; the pelvis, upper abdomen, or distant metastases.

- The Treatment of recurrent disease depends on the site and extent of recurrence.

- ***Progestagens*** may help only in well differentiated tumours containing oestrogen receptors.
- ***Radiotherapy*** and/or ***chemotherapy*** may be tried in less differentiated tumours.
- ***Limited surgery*** is rarely indicated for residual disease.

SARCOMA OF THE UTERUS

LEIOMYOSARCOMA

Leiomyosarcoma is rare tumour that usually arise in the uterine myometrium, grows rapidly even in the menopause, invades into the myometrium, or through the capsule of leiomyoma and spreads rapidly directly to adjacent organs, or early via blood stream metastases to reach distant organs.

- Malignant transformation in a benign leiomyomas is rare occurring in < 0.2%.
- Endometrial stromal sarcoma; is rare, arising in the stroma of the endometrium.

- **Macroscopically:** cut surface shows areas of hemorrhages and necrosis.
- **Microscopically:** Spindle shaped or rounded cells, many of them being pleomorphic, with little stroma and primitive blood vessels.
- **Histological diagnosis of malignancy** depends on the number of mitoses per high power field (HPF). Patients with >10 mitosis per 10 HPF are regarded as having malignant disease.

CLINICAL PICTURE:

- **Symptoms:** AUB especially in perimenopausal or menopausal women.
- **Signs:** No specific signs, where most cases are diagnosed accidentally only after surgical removal at hysterectomy. Leiomyosarcoma is highly suspected in the following situations;
  - Rapid growth of myomas at any age
  - Any growth of myomas after menopause
  - Rapid recurrence after myomectomy
  - Absence of plane of cleavage during myomectomy.

TREATMENT

- **TAH BSO** is the treatment of choice, followed in many cases by external radiotherapy.
- In general the prognosis is poor, except for early cases of leiomyosarcoma arising in a myoma without associated blood stream spread.

GESTATIONAL CHORIOCARCINOMA

Choriocarcinoma is a rarely occurring yet highly malignant tumour arising from trophoblastic epithelium, invading the endometrium and myometrium of the body of the uterus. It is characterized by its early metastases to the lungs, liver, and brain.

- **Gestational Trophoblastic Neoplasia (GTN):** is the term that collectively describes a spectrum of interrelated trophoblastic tumours, including:

  a. **Benign lesions:** as complete and partial hydatidiform moles,

  b. **Invasive mole:** a benign lesion that invades and metastasize

  c. **Malignant lesion:** gestational choriocarcinoma.

- Most **GTN** cases will run a benign course with their disease remitting spontaneously.
- Malignant and even metastatic disease can be effectively cured with chemotherapy.
- Serum B-hCG is a sensitive tumour marker for GTN which allows accurate diagnosis, risk classification, and follow up assessment during and after treatment.

N.B.: **Non-gestational choriocarcinoma** are exceedingly rare occurring as a part of ovarian germ cell neoplasms that do not arise in the uterus (see ovarian neoplasms).

INCIDENCE:

- ***Gestational choriocarcinoma*** exhibits a geographic distribution similar to that of hydatidiform mole with an incidence of 1in 30,000 to 1 in 50,000 pregnancies in the UK and USA, being 10 times more common in south east Asia, especially in older women with low socioeconomic standards.
  - **50%** of cases will develop following evacuation of a molar pregnancy
  - **25%** following abortion and
  - **25%** following term pregnancy
  - **5%** following an ectopic gestation.

PATHOLOGY:

- **Gross Pathology:**
  - The tumour appears as a friable haemorrhagic nodular mass arising in the body of the uterus, first invading the endometrium, projecting into its cavity, then extending to invade the myometrium.
  - The ovaries may be enlarged showing multiple theca-lutein cysts
- **Microscopic pathology:**
  - The tumour is comprised of sheets of anaplastic cytotrophoblasts and syncytiotrophoblast cells with prominent haemorrhage, necrosis, and vascular invasion.
  - Unlike molar disease, *chorionic villi are characteristically absent in choriocarcinoma.*

SPREAD OF CHOROIOCARCINOMA:

- **Haematogenous spread:** early and widespread blood borne metastases to various sites, namely to the lungs (80%), the vagina (30%), liver (10%), CNS and brain (10%)
- **Direct spread:** Malignant cells may directly invade the myometrium.

DIAGNOSIS:

- **Symptoms:**
  - Persistent vaginal bleeding that continues for > 6 weeks following molar evacuation, abortion or term pregnancy.
- **Signs:**
  - Bimanual vaginal examination may reveal a slightly symmetrically enlarged uterus that may be soft in consistency.
  - In cases with vaginal metastases, a soft haemorrhagic nodule may be seen within the vagina.

SPECIAL INVESTIGATIONS:

1. **Elevated serum B-hCG levels:**
   - Persistently **high B-hCG** levels after evacuation of a molar pregnancy, in absence of a new pregnancy, is the **gold standard** in diagnosis of gestational choriocarcinoma.
   - Biopsy is **not needed** to establish diagnosis and start treatment, in presence of such a highly specific tumour marker.
   - Cases are **classified** as **high risk** or **low risk** cases primarily according to the serum B-hCG level, hence treatment is planned based on such levels.
2. **TVS may show the following:**
   - Slightly symmetrically **enlarged** uterus with absence of intrauterine gestational sac.
   - A small **mass** within the endometrial cavity that may extend to the myometrium.
   - Colour **Doppler** indices to the mass may be suggestive of malignancy (low RI and high diastolic flow due to associated neo-vascularization)
   - Bilateral **theca lutein cysts** of the ovaries in association with elevated B-hCG levels
3. **MRI:** confirms the lesion and help in evaluation of intramyometrial **invasion** if present
4. **C.T. scan** may be required to exclude metastases in lungs, liver, and brain.
5. **D&C Biopsy operation:**
   - Biopsy will reveal anaplastic trophoblastic tissue with absence of villous pattern.
   - Histological diagnosis of choriocarcinoma is **not essential** to confirm diagnosis or to start chemotherapy, in presence of a specific tumour marker as B-hCG

CLASSIFICATION OF PATIENTS PRIOR TO TREATMENT

Risk Classification is based on several factors including;

- Patient's **age** and **B-hCG** levels
- Type of antecedent **pregnancy** (hydatidiform mole, abortion, or term pregnancy},
- Tumour size, site of **metastases**, number of metastatic lesions.
- Prior response to **chemotherapy** if previously given.

Patients are classified after investigations completed into 2 categories;

a. Non metastatic choriocarcinoma

b. Metastatic choriocarcinoma; which is further divided into;

- *Low risk cases*
- *High risk cases*

TREATMENT OF CHORIOCARCINOMA:

A. CHEMOTHERAPY:

Chemotherapy is indicated in all cases of gestational choriocarcinoma. It is considered the mainstay of treatment even in cases which may require surgical treatment (see later).

1. Single Agent Chemotherapy:

- ***Methotrexate (MTX);***
  - MTX is single agent drug of choice for *non metastatic* and *metastatic low risk* cases, with complete remission rates of 60-80%.
  - MTX is given as 50 mg dose IM every 48 hours / 4 doses.
  - MTX / Folinic acid regimen: where folinic acid is taken orally 30 hours after MTX injection, to minimize side effects of MTX
  - Cycle regimen is repeated after 14 days till a negative B-hCG is obtained.
  - Side effects of MTX include; nausea and vomiting, stomatitis and GIT ulcers, myelosuppression, hepatotoxicity, nephrotoxicity, and alopecia.
- **Actinomycin:** is also an effective single agent chemotherapy

2. Combined Agents Chemotherapy:

- **MTX, Etoposide, and Actinomycin:** is the combination of choice for *metastatic high risk cases,* and for cases *resistant to MTX* single agent chemotherapy.
- **Follow up after Chemotherapy:**

Follow up by repeated serum B-hCG is recommended after chemotherapy is completed until **negative B-hCG** levels are achieved for **3-6** months.

B. SURGICAL TREATMENT:

Surgery via a **TAH** in choriocarcinoma is reserved only for selected cases including;

- Elderly, multiparous, high risk cases (> 40 years age).
- Cases **resistant to combination chemotherapy** (failure of achieving negative B-hCG)
- Cases complicated by **severe haemorrhage**, **perforation**, or **infection**
- TAH is usually preceded and followed by **chemotherapy** : MTX 10 mg given at day of operation and continued postoperatively for 4 to 5 days to prevent the risk of dissemination and development of distal metastases.
- There is **no need** to remove the ovaries as ovarian metastases is rare and can effectively be treated with **MTX**.

PLACENTAL SITE TROPHOBLASTIC TUMOUR

- It is an uncommon variant of choriocarcinoma
- It consists predominantly of intermediate trophoblasts
- Human placental lactogen (HPL) is the tumour marker
- They are insensitive to chemotherapy
- Hysterectomy is the most efficient treatment for conformed cases

KEY POINTS

- *Endometrial cancer is the most common and most curable gynaecologic cancer.*
- *More than 75% of cases are adenocarcinoma occurring in postmenopausal women, mean age 60 years.*
- *Prolonged exposure to unopposed oestrogen is the most common risk factor.*
- *Other important risk factors include obesity, chronic anovulation, late menopause, ERT, and EH.*
- *Postmenopausal bleeding is the most common presenting symptom, which may be associated with offensive vaginal discharge.*
- *Premenopausal metrorrhagia is the second most common presentation.*
- *Screening for EC using PAP smears will miss>25% of cases.*
- *TVS showing an abnormally increased endometrial thickness especially in the menopause is a good predictor for the disease.*
- *The gold standard for diagnosis of EC is an endometrial biopsy obtained by FC under GA, which defines the pathological type and grade of the tumour present.*
- *The extent of the disease, the prognosis, and the need for adjuvant radiotherapy are all determined upon surgical staging of the disease.*
- *The gold standard treatment is surgery via TAH-BSO.*
- *Associated pelvic lymphadenectomy may improve the prognosis and survival rates in cases with deeper myometrial invasion.*
- *The overall 5 year survival is > 80% in stage I and >80% of recurrences occur within the first 3 years.*



24 INVASIVE CANCER OF THE CERVIX

- *Pre-invasive carcinoma*
- *Invasive carcinoma*
- *Cervical stump carcinoma*
- *Recurrent cervical cancer*

OVERVIEW

Carcinoma of the cervix is the **second most common** cancer of the female genital tract (after endometrial carcinoma), and is also the **most preventable** one.

The introduction of the Papanicolaou screening test **(Pap smear)** resulted in early diagnosis of increasing number of cases with premalignant lesions **(CIN)**, with a concomitant decline in occurrence of preinvasive and **Invasive disease**.

A further decline is expected to occur in the coming decades with the introduction of efficient **vaccination** against genital **HPV**, which is considered the primary premalignant condition predisposing to invasive cervical cancer.

Racial, ethnic, geographic and socioeconomic factors play important roles in the **prevalence** of this disease. **Sexual** and **hygienic** habits are also important factors.

The slow progression of cervical cancers from precancerous lesions **(CIN III)**, to invasive cancer provided the rationale for the preventive and early treatment strategies to control the disease.



Fig 24-1: Cervical cancer

PREMALIGNANT LESIONS

- Persistent infection with human papilloma virus **(HPV)** has been identified as the primary cause in almost all cervical cancers.
- There are **15 high risk HPV** types of which types **16 & 18** are responsible for over **70%** of cases. Persistent **high risk HPV** infection will provide **DNA** material by which immature cells in the transformation zone (TZ) may produce cervical intraepithelial neoplasia **(CIN),** via **abnormal squamous metaplasia**.

Natural History of CIN

- Low grade squamous intraepithelial lesions **(LGSIL or CIN I)** will undergo spontaneous regression in the majority of cases.
- Some **LGSIL** cases may progress to high grade lesions **(HGSIL , CIN II and CIN III)** within few years
- At least **35%** of patients with **HGSIL (CINIII)** develop invasive cervical cancer within **10 years**.

(See chapter on premalignant epithelial lesions of female genital tract CIN)

INVASIVE CARCINOMA OF THE CERVIX

INCIDENCE AND AETIOLOGY

Invasive cervical cancer has significantly declined in the last 3 decades, owing to the effective screening programs using the Pap smear test.

The age incidence for cancer cervix is commonly between 45-55 years which is almost 10 years younger than that for endometrial carcinoma, and 10 years older than that for CIN lesions.

RISK FACTORS: same as for CIN including;

- Early exposure to **first intercourse**, especially with multiple sexual partners
- Viral agents as **HPV** & HSV II,
- Untreated **HSILs** which may gradually progress to invasive cancer.
- Cigarette smoking due to hypoxia of endocervical cells

PATHOLOGY

A. Squamous cell carcinoma of the Ectocervix (> 80%):

- Origin:

- Arise from *squamous* epithelium covering the ectocervix
- May rarely arise as metaplasia of *glandular epithelium* at the TZ.

- N.E. appearance:

- Friable necrotic mass easily bleeding on touch, or
- Deep ulcer with everted and indurated edges, or
- Indurated nodule that may break forming an ulcer.

- Microscopically:

- The tumor is formed of cell nests with or without keratin.
- The cells are commonly large with malignant criteria but may be small undifferentiated.

B. Adenocarcinoma of the Endocervix (15%):

- Origin:

Arise from the *columnar epithelium* lining the endocervix. Being within the endocervix, it is more difficult to be detected by naked eye.

- N.E. appearance:

They may distend the cervix giving it a barrel-shaped appearance. By the time it appears at the external os, the carcinoma has often spread extensively outside the cervix.

- **Microscopically:**

The cells are malignant columnar cells arranged in glandular pattern with malignant criteria. In poorly differentiated tumors, the glandular pattern is replaced with unarranged cell nests.

HISTOLOGICAL GRADING:

a. ***Well differentiated (grade I);*** the majority of cells resemble the normal squamous epithelium of the cervix. They grow slowly and are less likely for early spread.

b. ***Moderate and poorly differentiated (grade 2 & 3);*** cervical carcinoma is predominantly of the moderate or poorly differentiated type. Abnormal cells predominate; they are more likely for rapid growth and early spread.

SPREAD: early direct and lymphatic spread.

1. **Direct spread:** To adjacent tissues including the body of the uterus, parametrium, upper and lower vagina, and uterosacral ligaments. Later spread may involve the bladder and rectum. Spread to the parametrium may lead to ureteric obstruction with subsequent development of renal failure (most common cause of death).
2. **Lymphatic spread:** Usually follows direct spread, but may coincide with it. It involves;
   a. *Primary groups:* include spread from the cervical lymphatics along to the paracervical LNs, to the obturator and external iliac nodes, and occasionally backwards to the internal iliac group.
   b. *Secondary groups:* involve drainage into the common iliac and lateral sacral groups. Ultimately the common iliac group drains into the para-aortic lymph nodes.
3. **Blood stream spread:** Least common, usually in late or advanced cases. Metastases may occur to distant organs as to the liver, lungs, brain and bone.

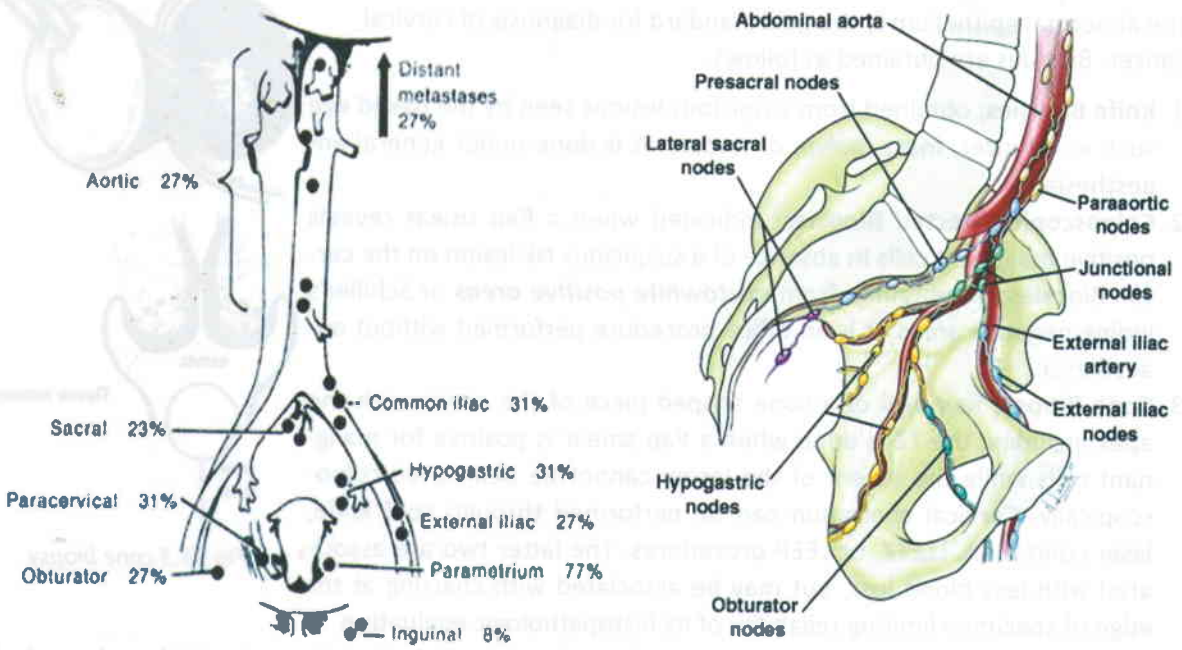

Fig 24-2: Lymphatic drainage and spread of cancer cervix

CLINICAL PICTURE

A) SYMPTOMS:

- *Contact bleeding;* is the commonest presentation (postcoital bleeding or bleeding on touch).
- *Metrorrhagia*, or *postmenopausal bleeding*, is the second most common presentation.
- *Vaginal discharge* which is excessive bloody or malodorous.
- *Pain;* deep pelvic pain and loin pain may be associated with advanced disease

B) SIGNS:

1. General examination:

- Early stages do not affect the patient's general condition.
- Advanced stages are associated with; chronic blood loss, urinary manifestations and ureteric obstruction which may lead to severe anaemia, uraemia and cachexia.

2. Palpation by digital vaginal examination (PV):

- Early stages: mass or ulcer that bleeds profusely when touched by the finger due to friability.
- Later stages: as the disease progresses, the cervix loses its mobility, becomes fixed, and the surrounding parametrium becomes tender and indurated.

3. Bimanual pelvic examination:

- The uterus is usually normal in size
- Symmetrical uterine enlargement may occur if pyometra develops.

4. Inspection via a speculum vaginal examination:

- Early stages: small friable warty mass, nodule, or an ulcer that bleeds on touch.
- Later stages: mass or ulcer extending to the vaginal walls obliterating the vaginal fornices.

5. Rectal examination (PR):

- For detecting parametrial extension and uterosacral involvement

DIAGNOSTIC PROCEDURES

Histopathologic examination of **cervical tissue biopsies** containing the abnormal epithelium is the gold standard for diagnosis of cervical cancer. Biopsies are obtained as follows;

1. **Knife Biopsies;** obtained from suspicious lesions seen by the naked eye such as an ulcer, mass, polyp, or nodule. It is done under general anaesthesia.
2. **Colposcopic Directed Biopsies;** Indicated when a Pap smear reveals positive malignant cells in absence of a suspicious NE lesion on the cervix. Biopsies are obtained from ***acetowhite positive areas*** or Schiller's iodine negative areas. It is an office procedure performed without anaesthesia.
3. **Cone Biopsy:** Removal of a cone shaped piece of the cervix with the apex including the TZ is done when a Pap smear is positive for malignant cells while the extent of the lesion cannot be delineated colposcopically. Cervical conization can be performed through cold knife, laser conization, LLETZ, or LEEP procedures. The latter two are associated with less blood loss, but may be associated with charring at the edge of specimen limiting reliability of its histopathologic evaluation

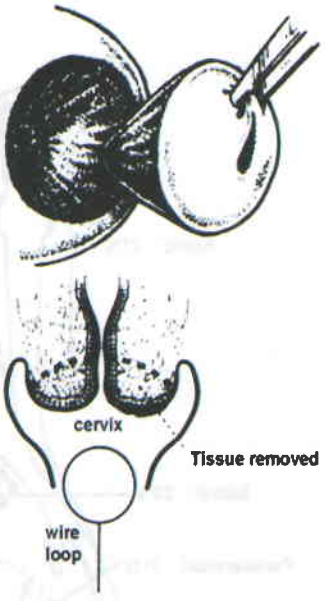

Fig 23:3 cone biopsy

4. **Fractional Curettage (FC):** to obtain tissue from the endocervix thus diagnosing high endocervical lesions together with obtaining separate endometrial biopsies to exclude the spread of cervical cancer to the endometrium and body of uterus. (See of FC in gynaecologic operation).

CLINICAL STAGING AND PREOPERATIVE PREPARATION:

Before starting treatment, clinical staging of the disease should be complete. It requires;

a. **Examination under anaesthesia (EUA):** done during performing cervical biopsies to test for cervical mobility and to define the presence and extent of parametrial infiltration through PV and PR examination.
b. **Cystoscopy:** to exclude bladder wall invasion which if present will shift staging from stages I & II, in which treatment is curable, to stage IV in which treatment is palliative.
c. **Intravenous pyelography (IVP):** to exclude ureteric compression if parametrial infiltration is present.
d. **Chest X-ray & Abdominal U.S.: to exclude distant metastases in advanced cases.**

Both, staging and grading, help to decide on the most appropriate treatment, and to predict the possible prognosis of the case. The FIGO clinical staging classification is based on findings on EUA, IVP, cystoscopy, and cervical biopsies. Staging does not change after surgery.

FIGO STAGING OF CARCINOMA OF THE CERVIX UTERI 2018. (Simplified Clinical Staging)

FIGO Stage	Stage Description*
I	**The carcinoma is strictly confined to the cervix**
IA	Invasive carcinoma that can be diagnosed only by microscopy, with maximum depth of invasion <5 mm
IB	Invasive carcinoma with measured deepest invasion ≥5 mm NB: involvement of the uterus is considered stage I
II	**The carcinoma causes local spread, beyond the cervix and uterus**
IIA	Involvement limited to the upper two-thirds of the vagina without the lower one third and without parametrial involvement.
IIB	With parametrial involvement but not reaching the lateral pelvic wall
III	**The carcinoma causes more local spread and/or lymph node involvement**
IIIA	Carcinoma involves the lower third of the vagina, with no extension to the pelvic wall
IIIB	Extension to the lateral pelvic wall and/or hydronephrosis or renal failure
IIIC	Involvement of pelvic and/or paraaortic lymph nodes, irrespective of tumor size and extent
IIIC2	The cancer is growing in the body of the uterus. It has also spread to the para-aortic lymph nodes.
IV	**The carcinoma has extended beyond the true pelvis**
IVA	Spread of the growth to adjacent organs as mucosa of the bladder or rectum
IVB	Spread to distant organs

PREVENTION OF CANCER CERVIX:

Invasive cancer cervix is the most preventable female genital cancer. It is achieved via;

A. **SECONDARY PREVENTION:** early detection and proper management of CIN lesions

- *Regular screening* (Pap smears) for asymptomatic high risk patients, with colposcopy and colposcopic directed biopsies performed to cases with abnormal Pap smears.
- *Treatment of CIN lesions* by ablation or excision, and regular follow up after treatment.

N.B.; Regular screening resulted in a significant decrease in the incidence of invasive cancer cervix, and a 10 fold decrease in mortality compared to unscreened population.

B. PRIMARY PREVENTION:

- **An HPV vaccine** has been approved for prevention of HPV infection especially types 6, 11, 16 & 18 which account for 70% of all cervical cancers, and almost 90% of cases of genital warts.
- The vaccine appears to be over **95% effective** in preventing HPV 16, 18, related cervical cancers.
- The vaccine is effective when given in age groups from 9-26 years, in non-previously infected population. It is not effective in treatment of already pre-existing infections.

TREATMENT OF INVASIVE CANCER CERVIX

- **Stage IA1:**
  - Young patient/family not complete (needs to retain the uterus) = Therapeutic conization.
  - Old patient/family completed = Simple extrafascial hysterectomy.
- **Stage IA2, IB, IIA =** Radical/Wertheim hysterectomy + Concurrent chemoradiation
- **Stage IIB – IV =** Concurrent chemoradiation.

It should be noted that:

- Stage IA2, IB, IIA are both radiosensitive and operable but operation is preferred due to:
  - Preservation of the ovary and ovarian function.
  - Preservation of the vagina for coitus.
  - Psychologically better for the female.
- Cervical cancer almost never spread to the ovary, therefore ovarian removal is not a must.

SURGICAL TREATMENT OF CERVICAL CANCER:

- **Wertheim's radical hysterectomy:**
  - This is the standard surgical procedure for invasive carcinoma of the cervix.
  - It involves a TAH-BSO + pelvic lymphadenectomy + removal of parametrial tissue and 2-3 cm from the upper vaginal cuff.
  - Pelvic lymphadenectomy: includes removal of the external, internal, and common iliac nodes, together with obturator and presacral nodes.
  - Patients in which surgery results in removal of the whole tumour, with a free safety margin of healthy tissue, and negative LNs, do not need further postoperative radiotherapy.
  - Patients with positive LN affection or non-free safety margin are best offered adjuvant radiotherapy treatment.
  - The ovaries may be preserved in younger women to benefit for their hormonal function.

- **Schauta's vaginal hysterectomy and lymphadenectomy:**
  It is rarely resorted to owing to the limited access to pelvic nodes via such procedure ending in incomplete lymphadenectomy.

Complications of Surgery:

Beside all known complications of general surgery, the principal complication of radical hysterectomy is related to;

- Some degree of bladder dysfunction due to division of the parasympathetic nerve supply to the bladder that runs within the uterosacral ligaments.
- Ureteric injury whether direct or indirect (i.e. necrotic due to devascularization or as a result of extensive dissection).

■ **Five years survival rates** after surgery alone ranges 75%-100% in stages from IA to IIA.

RADIOTHERAPY IN CANCER CERVIX

- All stages of cervical cancer are radiosensitive.
- In early stages (I-IIA) cure rates are comparable to those for surgery.
- In more advanced stages (IIB-IV) cancer will not be curable by surgery alone, and radiotherapy becomes the preferred first line of treatment. It may be given alone, or in combination with surgery or chemotherapy.

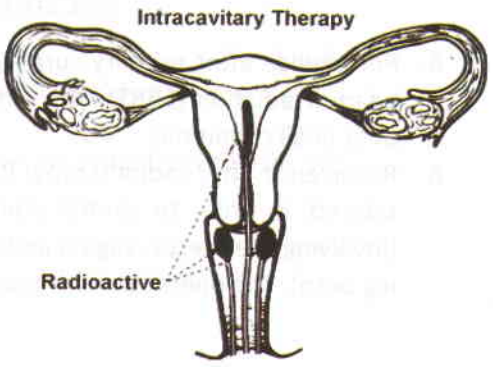

Fig 24-4:

■ **Types of radiotherapy:**

a. *Primary therapy;* usually involves external beam radiotherapy (EBRT) to the pelvis followed by intracavitary treatment or brachytherapy.

b. *Adjuvant therapy;* administered after radical hysterectomy to high risk cases (positive safety margins, and or positive nodal involvement)

■ **Survival rates after radiotherapy**

- The five years survival rates for radiotherapy alone are comparable for survival with surgery alone for stages IA-IIA disease.
- **For advanced stages** localized within the pelvis, 5- years survival ranges from 50%-80%.
- For metastatic disease outside the pelvis, survival is less than 15%.

■ **Complications of radiotherapy** include:

- Radiation induced menopause
- Variable degrees of vaginal narrowing and fibrosis, few weeks post treatment
- Rarely radiation vesico-vaginal fistulas may occur and are difficult to deal with.

CHEMOTHERAPY IN CANCER CERVIX

Chemotherapy has proved to play a role as a radiation sensitizer (chemoradiation) in cases of cancer cervix (e.g.; weekly I.V. Cisplatin), with a nearly 10% increase in cure rates.

PROGNOSIS IN CANCER CERVIX

- **Stage IA;** cure rates may reach up to 95%
- **Stage IB;** 5 year survival rates may reach up to 85% whether with surgery or radiotherapy.
- **Stage II;** drops sharply to a 5 years survival of 50%.
- **Sages III and IV;** 5 years survival may be as low as 25% and 5% respectively. The treatment in these stages is therefore only palliative.

CARCINOMA OF THE CERVICAL STUMP (after subtotal hysterectomy)

Cancer cervix may develop in the stump of the cervix left after subtotal hysterectomy performed for benign indications as leiomyomata, and DUB.

Surgery (radical cervicectomy and lymphadenectomy) is complicated by presence of adhesions and abnormal anatomic relations induced by the previous hysterectomy.

Radiotherapy: EBRT may be the best option as internal irradiation is compromised by the absence of the uterus as a container for intrauterine applicators, while vaginal irradiation may not deliver the sufficient dose without risk of damage to the bladder and rectum.

RECURRENT CERVICAL CANCER

A. Recurrence after primary surgery (more than 6 months); is treated by palliative external beam irradiation (EBRT). The aim is to control bleeding, pain, and infection. Prognosis is poor in all conditions.

B. Recurrence after radiotherapy; Palliative surgery through pelvic exenteration may be considered, in order to control pain, bleeding, and infection. Exenteration may be anterior (involving the uterus, vagina and bladder, or posterior involving the rectum, or total involving both). The operation carries very high morbidity and mortality, and is rarely resorted to.

KEY POINTS

- *Cervical cancer is highly correlated with HPV infection and less commonly HSV type II*
- *Regular PAP smears done annually for young sexually active females and those with previous +ve CIN smears will allow prevention and early detection of most lesions.*
- *A positive smear warrants repetition and Colposcopic guided biopsies if confirmed.*
- *Contact bleeding is the most common presenting symptom for invasive cancers*
- *Biopsy from a suspicious cervical lesion (ulcer, or a friable mass) is the gold standard for diagnosis.*
- *Stage IA1 in young patient/family not complete (needs to retain the uterus) is treated by therapeutic conization.*
- *Stage IA1 in old patient/family completed is treated by simple extrafascial hysterectomy.*
- *Stage IA2, IB, IIA are treated by radical/Wertheim hysterectomy + Concurrent chemoradiation*
- *Stage IIB – IV are treated by concurrent chemoradiation.*
- *Although early stages are radiosensitive, surgery is preferable.*





25 MALIGNANCIES OF THE VULVA AND VAGINA

Cancer of the vulva
- *Squamous cell carcinoma*
- *Staging*
- *Treatment*

VAIN
Vaginal Cancer
- *Secondary tumours*
- *Primary tumours*

Vaginal Adenosis

INVASIVE CANCER OF THE VULVA

Malignant tumours of the vulva are generally rare, although a gradual rise in its incidence has been observed throughout the past two decades reaching up to 8% of malignancies of the female genital tract.

This increase is both attributed to the continued rise in average age of female population, and to the larger prevalence of VIN in the younger population. No race is spared and neither parity nor gravidity is involved.

Aetiology and pathogenesis:

A. Carcinoma occurring in **younger patients**; this type is rare, it is related to HPV infection and smoking, and is commonly associated with vulvar intraepithelial neoplasia (VIN). Carcinoma in situ of the vulva (VIN-III) appears to carry a significant risk of progression to invasive cancer if left untreated.

B. Carcinoma occurring in **elderly patients;** this is the more common type, it is unrelated to smoking or HPV infection, and concurrent VIN is uncommon.

Pathologic types

- ***Squamous cell carcinomas*** is the **commonest** type representing almost **92%** of tumours
- Melanomas, adenocarcinomas, basal cell carcinomas, and sarcomas, are much less frequently encountered.

Methods of spread:

- *Direct extension* to adjacent structures, such as the vagina, urethra, and anus.
- *Lymphatic permeation* to regional *lymph nodes* (common).
- *Haematogenous spread* to distant sites, including the lungs, liver, and bones (rare).

SQUAMOUS CELL CARCINOMA OF THE VULVA

Squamous cell carcinoma of the vulva occurs mainly in postmenopausal women, and the mean age at diagnosis is 65 years. A history of chronic vulvar itching is common.

- **Symptoms:** Patients generally present with long standing pruritus, before a vulvar lump is detected. Other common symptoms include vulvar pain, bleeding, and discharge.
- **Signs on examination:**
  - The lesion may be raised, ulcerated, pigmented, or warty in appearances. Most lesions occur on the labia majora; the labia minora are the next most common sites. Less commonly, the clitoris or perineum is involved. Approximately 5% of cases are multifocal.
  - The groin lymph nodes should be evaluated carefully and a complete pelvic examination should be performed.
  - Colposcopic examination of the cervix and vagina should be considered to exclude the common association with other intraepithelial squamous neoplasia of the lower genital tract (CIN & VAIN).

- **Diagnosis:** Definitive diagnosis requires ***biopsy*** from the lesion under local anaesthesia.
- **Lymphatic spread pathways:** Initial lymphatic spread reaches the ***superficial inguinal lymph nodes***, then to the ***femoral nodes*** (located along the femoral vessels). From the inguino-femoral nodes spread occurs to the deep ***pelvic nodes***, particularly the external iliac group. *(N.B.: Cloquet's node is situated beneath the inguinal ligament, and is the most cephalad of the femoral node group).*
- The incidence of lymph node metastases in vulvar cancer is approximately 30%. It is related to the size of the lesion and the stage of the disease.
- **Haematogenous spread** usually occurs late in the disease and rarely occurs in the absence of lymphatic spread.
- **Clinical Staging:** Staging was based on a clinical evaluation of the primary tumour and regional lymph nodes with a limited search for distant metastases.

FIGO STAGING OF CARCINOMA OF THE VULVA 2009 (Simplified SURGICAL STAGING)

FIGO Stage	Stage Description*
I	**Tumor confined to the vulva**
IA	Lesions ≤2 cm in size, confined to the vulva or perineum and with stromal invasion ≤1.0 mma, no nodal metastasis
IB	Lesions >2 cm in size or with stromal invasion >1.0 mma, confined to the vulva or perineum, with negative nodes
II	**Tumor of any size with extension to adjacent perineal structures (lower third of urethra, lower third of vagina, anus) with negative nodes**
III	**Tumor of any size with or without extension to adjacent perineal structures (lower third of urethra, lower third of vagina, anus) with positive inguinofemoral nodes**
IV	**Tumor invades other regional (upper 2/3 urethra, upper 2/3 vagina), or distant structures**
IVA	Tumor invades any of the following: upper urethral and/or vaginal mucosa, bladder mucosa, rectal mucosa, or fixed to pelvic bone, orfixed or ulcerated inguinofemoral lymph nodes
IVB	Any distant metastasis including pelvic lymph nodes

MANAGEMENT OF INVASIVE CANCER VULVA:

- **Surgical treatment** via a **Radical vulvectomy** and **bilateral en bloc groin dissection**, with or without **pelvic lymphadencetomy** has long been considered the *standard treatment for all operable patients*. However such extensive surgery had a very high morbidity affecting the quality of life after the procedure.

- **Modifications to minimize morbidity of standard surgical treatment includes;**

1. ***Separate incisions*** are used for groin dissection; instead of the traditional large butterfly vulvo inguinal incision, to decrease post operative wound breakdown (i.e. wide deep local vulvectomy + separate incision for bilateral groin LN dissection).
2. ***Postoperative pelvic and groin external radiation therapy;*** has eliminated the need for routine pelvic lymphadenectomy unless metastases is documented in the inguinal node area.
3. ***Uunilateral lesions*** on one of the labia majora can be managed by unilateral inguino-femoral lymphadencetomy without contralateral groin node dissection. However in midline lesions invading more than 1 mm bilateral groin dissection is necessary.
4. ***Very early tumours*** in which the depth of penetration is less than 1 mm, *groin dissection may be eliminated*, where a wide and deep local excision (radical local excision) is as effective as radical vulvectomy in preventing local recurrence.
5. ***In advanced vulvar cancer*** involving the proximal urethra, anus, or rectovaginal septum many centres have been using preoperative radiation or chemo radiation to shrink the primary tumour followed by more conservative surgical excision.
6. ***Prognosis:*** The 5-year survival rates ranges from nearly 90% for stage 1 to 15% for stage IV. Patients with nodal involvement have a 5 year survival rate 50% whereas those with no nodal involvement have a 5 year survival rate of about 90%.

MALIGNANT NEOPLASMS OF THE VAGINA

1. ***Secondary Tumours:*** Malignant neoplasms of the vagina are usually secondary to a primary growth elsewhere. Spread may occur as **a) direct spread;** from primary malignant tumour in the vulva, cervix, urethra, bladder and rectum, or **b) via blood and Lymph spread;** as occurs secondary to a choriocarcinoma, or **c) as seeding;** from adencarcinoma of the body of the uterus.
2. ***Primary Tumours:*** Primary malignant tumours of the vagina are rare. They occur mainly in post menopausal patients.

- **Pathology:** Squamous cell carcinoma occurs in > 90% of cases. Other rare types include; clear cell carcinoma, melanomas, rhabdomyosarcomas and endodermal sinus tumours.
- **Spread:**
  - Direct spread to local and near by organs is the main route.
  - Lymphatic spread, is less common. When the growth in the upper vagina the lymphatic spread is the same as cancer cervix; if it is situated in the lower vagina, the vulval lymphatics are involved.
- **Clinical presentation:**
  - The main presentations are vaginal discharge.
  - Vaginal bleeding and occasionally post coital bleeding.

- In more advanced cases a malignant ulcer or fungating growth are detected .
- A malignant fistula may develop either in the rectum or the bladder.

- **Treatment:** will depend on the site and stage of the tumour.
  - A stage I in the upper vagina can usually be treated by radical hysterectomy with radical vaginectomy and pelvic lymphadenectomy.
  - Radiotherapy can be offered to more advanced cases.

Key Points

- *VIN is difficult to treat as disease is commonly multifocal*
- *Vulval cancer is very rare, and mostly found in the elderly postmenopausal patients.*
- *Surgical treatment is effective especially in early disease with no nodal metastases.*
- *In the recent years, extensive radical surgery has been replaced by more limited but complete surgery with adjuvant radiotherapy and sometimes chemotherapy.*
- *Vaginal cancers are among the rarest in the female genital tract affecting the older females.*
- *Early vaginal cancer may be treated by surgery or internal brachytherapy, while more advanced stages are better treated with radiotherapy.*

26 NON NEOPLASTIC OVARIAN SWELLINGS

- *Follicular Cysts*
- *Endometriotic Cysts*
- *Inflammatory Cysts*
- *Corpus Luteum cysts*
- *Theca Lutein Cysts*
- *Germinal inclusion cysts*

Ovarian swellings usually present by an adnexal mass which may be either; neoplastic or non-neoplastic, cystic or solid, benign or malignant, unilateral or bilateral.

Non neoplastic ovarian swellings, also described as **functional cysts** of the ovary, represent almost 24% of all adnexal masses encountered in gynaecologic practice.

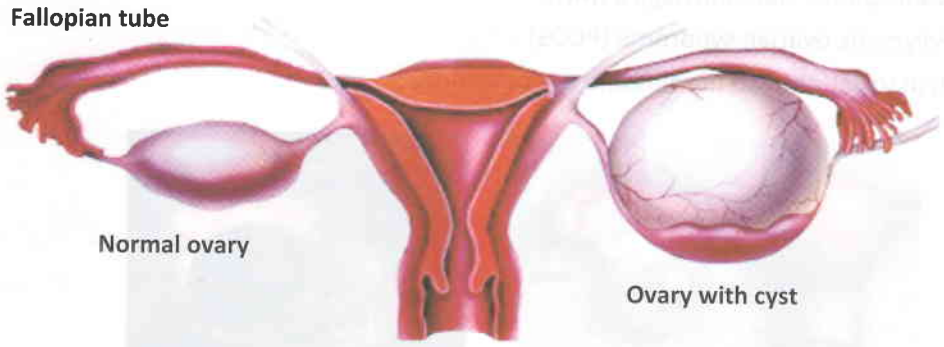

Fig 26-1: Normal ovary & Cystic ovarian swelling

CLASSIFICATION OF NON NEOPLASTIC OVARIAN SWELLINGS, according to their origin:

1. Follicular cysts
2. Corpus luteum cysts
3. Endometriotic cysts
4. Theca lutein cysts
5. Inflammatory cysts (ovarian and tubo-ovarian)

GENERAL FEATURES OF NON NEOPLASTIC OVARIAN SWELLINGS

a. **Age incidence:** They occur in the child bearing period mostly at extremes of age as in post pubertal period, young childbearing age, and in the perimenopause.

b. **Bilaterality:** usually unilateral, except for theca lutein and some endometriotic cyst.

c. **Size:** small in size (3-6 cm in diameter, rarely exceed 7 cm)

d. **Fate:** spontaneous regression in few weeks is the rule, except for endometriomas which will continue a slowly progressive course (see later).

e. **Complications:** functional ovarian cysts rarely undergo torsion, hameorrhage, or rupture

f. **Management:** functional cysts of the ovary are managed conservatively except if they reach considerably large size, or become complicated where surgical treatment, usually via laparoscopy, becomes mandatory

1. FOLLICULAR CYSTS

Follicular cysts are the **commonest non neoplastic** cysts of the ovary. They usually arise from cyctic over-distension of an atretic follicle, or due to unruptured dominant ovarian follicle. They mostly occur in younger women in their early childbearing period, and in the perimenopause.

Most follicular cysts will undergo spontaneous regression without treatment unless complicated by torsion, haemorrhage, or rupture.

PATHOLOGY

- Cysts are usually unilateral, unilocular, small in size (3-7cm), containing *clear fluid*.
- The cyst wall is thin, lined by **granulosa cells** that may continue to produce oestrogen causing menstrual disturbance.
- Follicular cysts of the ovary are commonly encountered with;
  - Metropathia Haemorrhagica (MH)
  - Polycystic ovarian syndrome (PCOS)
  - In association with fibroids and endometriosis.

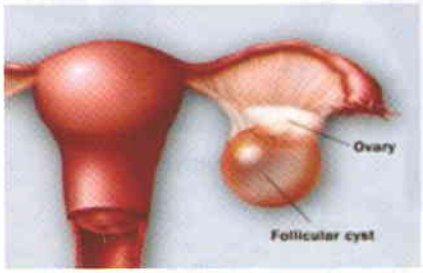

Fig 26-2: Follicular cyst of the ovary



Fig 26-3: Follicular cyst by US

CLINICAL PICTURE AND DIAGNOSIS

A) Symptoms:

1. *Asymptomatic:* most follicular cysts are only accidentally discovered.
2. *Menstrual disorders:* in the form of *delayed cycles* or *intermenstrual spotting* may occur due to persistent oestrogen production by granulose cells
3. *Pain:* mild pelvic pain is not uncommon. Rarely pain may be severe and acute in cases when the cyst is large, rapidly growing, or complicated by haemorrhage or rupture.

B) Signs on bimanual pelvic examination:

- Tenderness may be elicited at the ovarian point (above the mid inguinal ligament).
- Fullness at one of the vaginal fornices, associated with mild tenderness.
- A small cystic mass may be felt in thin patients

C) Special Investigation:

1. Pelvic TAS or TVS is the ***gold standard in diagnosis***, showing a unilateral, unilocular, thin walled cyst, < 7.0 cm size, filled with clear fluid, with no internal echoes.
2. Laparoscopy is diagnostic whenever diagnosis is in doubt, or cyst complicated

2. CORPUS LUTEUM CYSTS

Corpus luteum (CL) cysts are the **second most common non neoplastic cysts** of the ovary. They arise from excessive haemorrhage inside the CL during the stage of vascularization. They mostly occur during the child bearing period, and may occur in association with early pregnancy.

As with follicular cysts most CL will undergo spontaneous regression without treatment unless complicated by torsion or rupture.

PATHOLOGY:

- Cysts are usually unilateral, unilocular, small in size (3-7 cm), containing haemorrhagic fluid.
- The cyst wall is lined by **luteinized granuloza cells** continue to secrete progesterone causing menstrual disturbance.



Fig 26-4: Corpus luteum cyst



Fig 26-5: Haemorrhage in CL cyst by US

CLINICAL PICTURE AND DIAGNOSIS

a) Symptoms:

1. *Asymptomatic* in most cases.
2. *Menstrual disturbance:* in the form of short delay in cycles or intermenstrual spotting may occur due to persistent progesterone (PRG) production.
3. *Pain:* acute lower abdominal pain may be present at one iliac fossa if the cyst is complicated with haemorrhage or rupture, and may be misdiagnosed as appendicitis.

b) Signs on bimanual pelvic examination:

- Tenderness is commonly elicited at the mid-ovarian point at one iliac fossa
- Tenderness and fullness at one of the vaginal fornices
- A tender cystic adnexal mass may be felt in thin patients.

c) Special Investigations:

1. Pelvic TAS or TVS is the **gold standard** in diagnosis showing a unilateral, unilocular, cyst , < 7 cm, filled with blood that appears as fine particles within clear fluid.
2. laparoscopy is conclusive whenever diagnosis is in doubt or cyst complicated

DIFFERENTIAL DIAGNOSIS:

- From follicular cyst and simple serous cyst.
- Other causes of pain in right iliac fossa (as appendicitis, renal colic, & ectopic pregnancy)

3. THECA LUTEIN CYSTS

Theca lutein cysts of the ovary usually develop in response to abnormally high levels of pituitary gonadotrophins (FSH & LH), or chorionic gonadotrophins (hCG). It may be either;

a. **Spontaneous:** due to excessive amounts of natural hCG in circulation as in cases of hydatidiform mole, choriocarcinoma, and multifetal pregnancy.

b. **Iatrogenic:** due to large doses of HMG/hCG in ovulation induction protocols

PATHOLOGY

- Cysts are *multilocular,* commonly *bilateral, bluish in colour, thin walled,* containing *clear fluid*. They may reach a large size > 10 cm as with ovarian hyperstimulation (OHSS).
- Cyst wall is lined by **luteinized theca cells**.

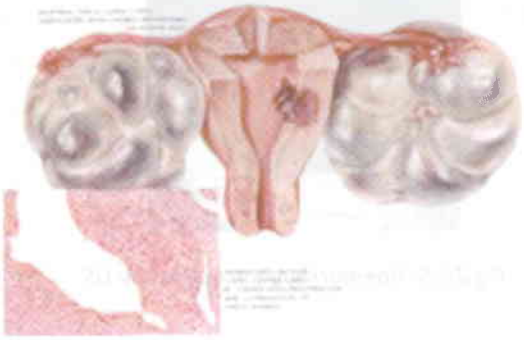

Fig 26-6: Theca lutein cysts



Fig 26-7: Germinal inclusion cysts

CLINICAL PICTURE AND DIAGNOSIS

a. **History:** drugs for induction of ovulation, multifetal pregnancy, or hydatidiform mole

b. **Symptoms:** Pelvic pain which may be severe resembling acute abdomen

c. **Signs on abdominal and bimanual examination:**

- Large theca lutein cyts may be felt suprapubically. They are usually tender with restricted mobility.
- Abdominal distension and ascites may be present in Grade 3 and 4 OHSS.

d. **Special investigations:**

- US is the gold standard for diagnosis
- Serum B-hCG shows very high levels in molar pregnancies and choriocarcinoma

4. ENDOMETRIOTIC CYSTS

Endometriotic cysts (also known as endometriomas), occur due to presence of functioning ectopic endometrium within ovarian stroma. In many cases they may occur in association with pelvic endometriosis.

PATHOLOGY

- Endometriotic cysts represent haemorrhagic cysts lined by functioning endometrial tissue (glands and stroma).
- Blood accumulates within the cyst wall concomitant with time of menstruation
- By time, absorption of the serous element of the retained blood occurs leaving behind RBCs in a thick dark material giving it a liquid chocolate colour and appearance (chocolate cysts).
- Cysts rarely undergo torsion as they are usually fixed to surrounding structures by dense adhesions, secondary to inflammatory reactions associated with minor fluid leaks.
- Cysts rarely rupture spontaneously due to its thick wall due to a local inflammatory reaction



Fig 26-8: Endometrioma by laparoscopy

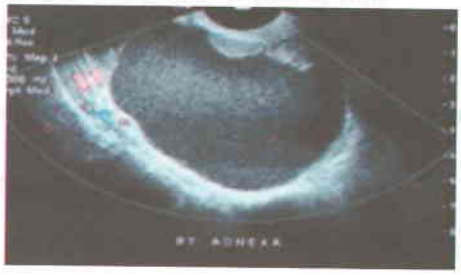

Fig 26-9: Endometrioma by US

CLINICAL PICTURE AND DIAGNOSIS

a. **History of infertility:** is encountered in a significant group of patients.
b. **Symptoms:** Dull aching chronic pelvic pain usually associated with dysmenorrhoea.
c. **Signs on bimanual pelvic examination:**
   - Adnexal mass which is markedly tender and almost fixed
   - Nodules and tenderness over the uterosacral ligaments may be present
d. **Special investigations:**
   - TVS will reveal an adnexal mass with thick wall and turbid contents
   - CA 125 may be elevated in most cases but not to very high levels
   - Laparoscopy: is both diagnostic and therapeutic when surgical intervention is indicated.

5. INFLAMMATORY CYSTS

Inflammatory cysts may occur in the form of ovarian or Tubo-ovarian cysts or abscess, as a result of specific or non specific infection.

Infection may reach the ovary either by lymphatic spread, or by direct spread from a nearby infected organ.

Inflammatory cysts of the ovary are usually bilateral.

CLINICAL PICTURE AND DIAGNOSIS

a. **History;** of recent abortion, delivery, or IUD insertion

b. **Symptoms:**
   - Fever, headache, malaise and generalized bony aches
   - Dull aching pelvic pain stimulated by movement
   - Deep dyspareunia

c. **Signs on bimanual pelvic examination:**
   - Marked fullness and extreme tender adnexae
   - Mass if felt is fixed with exquisite tenderness
   - Tenderness on moving the cervix uterii

d. **Special investigations:**
   - CBC showing stigmata of inflammation (leucocytosis, shift to left, & toxic granules)
   - Elevated C reactive protein (CRP) and erythrocyte sedimentation rate (ESR)



Fig 26-10: Tubo-ovarian mass



Fig 26-11: Tubo-ovarian complex by US

Treatment: (see chronic PID, tubo-ovarian cyst & abscess).

6. GERMINAL INCLUSION CYSTS

They are microscopic cysts, that result from invagination of the germinal epithelium into the substance of the ovary, near or after menopause. Previously they were considered of no clinical importance, but now they are regarded as forerunners for ovarian epithelial cancers.



Fig 26-12: Epithelial cells from the fimbria are released and implant on the denuded surface of the overy at the site of ovulation. B& C subsequenyly, an inclusion cyst is formed

MANAGEMENT OF NON NEOPLASTIC OVARIAN SWELLINGS

A) CONSERVATIVE MANAGEMENT

- **Small non complicated** functional cysts of the ovary are managed conservatively since spontaneous regression is the rule in most of these cysts.
- During the few weeks of follow up **US** is used to monitor complete cyst resolution.

B) MEDICAL TREATMENT

- **Gestagens and OCP** may accelerate regression of *follicular, CL, and theca lutein cysts*
- **GnRH agonists, Gestagens, and OCPs** may help minimizing rate of growth of *endometriotic cysts* thus prolonging the period of conservative management and avoiding or delaying the need for surgical intervention.
- **Antibiotics** with specific regimens according to CDC recommendations will allow shrinkage in size of ***inflammatory cysts*** to control the symptoms and size, and avoid the need for surgical intervention.

C) SURGICAL TRAETMENT

Large cysts > 7.0 cm, **complicated** cysts (by haemorrhage or torsion), and persistently **growing** ones (like endometriomas) are managed surgically from the start or after an adequate interval of trying conservative approach and/or medical treatment.

- **Laparoscopy** is the preferable approach suitable for most cases. Operations include;
  1. Undoing torsion of a cyst before it becomes ischaemic and gangrenous
  2. Ovarian cystectomy for cysts that reached large size or starting complication
  3. Ovariotomy (removal of the ovary) is rarely an option, only in cases with severe haemorrhage or gangrene in which ovarian preservation becomes impossible.

Key points in functional cysts of the ovary

- *Functional cysts account for about 24% of all ovarian cysts.*
- *They are usually small in size and rarely exceed 7.0 cm in diameter*
- *The majority are discovered incidentally during routine pelvic examination or US*
- *They are sometimes associated with temporary menstrual disorders*
- *Their fate is generally spontaneous resolution within few weeks of diagnosis*
- *Surgical intervention, usually via laparoscopy is seldom resorted to in large and complicated cysts*





27 BENIGN OVARIAN NEOPLASMS

Classification
Pathology
- *Epithelial ovarian tumours*
- *Germ cell tumours*
- *Sex cord stromal tumours*

Complications
Clinical picture
Treatment

CLASSIFICATIONS OF OVARIAN NEOPLASMS

The ovary is a common site for various types of neoplasms that are usually described according to different classifications which include the following:

A) PATHOLOGIC CLASSIFICATION: Ovarian neoplasms are classified pathologically into ***benign*** and ***malignant*** tumours. Benign neoplasms are much more common than malignant ones.

B) CLINICAL CLASSIFICATION: Ovarian neoplasms are clinically divided into ***cystic*** and ***solid*** tumours. Cystic tumours are more common and are mostly benign, while solid tumours are much less common and are mostly malignant.

C) HISTOGENETIC CLASSIFICATION: The most internationally accepted classification is the WHO histogenetic classification based on the cell of origin of the tumour, either from:

- ***Surface epithelium*** (epithelial tumours)
- ***Ovarian germ cells*** (germ cell tumours)
- ***Ovarian stroma*** (sex cord and stromal cell tumours).

1. EPITHELIAL TUMOURS OF THE OVARY

These tumours originate from the ***surface epithelium*** which embryologically develops into Mullerian and Wolffian epithelium, and can thus differentiate into different types of epithelia. Epithelial tumours are by far the ***commonest*** tumours of the ovary, and are classified into;

a. **Serous cystadenoma:** lined by cells resembling tubal epithelium.
b. **Mucinous cystadenoma:** lined by cells resembling cervical epithelium
c. **Endometrioid tumours:** lines by cells resembling endometrial lining.
d. **Brenner tumour** has epithelial component similar to transitional epithelium of the urinary tract.

2. GERM CELL TUMOURS

These tumours originate form ***totipotent germ cells*** that may show either;

a. Differentiation into Embryonic tissue: this will give various forms of **teratoma**, which contains elements of the three germ layers (ectoderm, endoderm, and mesoderm). This is the most common germ cell tumour.

b. Differentiation into Extraembryonic tissue: this will give either;

- Trophoblastic tissue; with development of **choriocarcinoma**, or
- Yolk sac tissue: with development of **yolk sac tumour** (Endodermal sinus tumour).

c. No differentiation of germ cells occur: this will result in the development of **dysgerminoma**.

3. SEX CORD STROMAL TUMOUR

These are the least commonly encountered tumours, originating from 2 gonadal elements;

The primitive sex cord; which developmentally gives origin to granulosa cells in the ovary, or sertoli cells in the testicle. It may give rise to malignant tumours either **Granulosa cell tumour or Androblastoma** (also known as Sertoli-Leydig cell tumour).

The stroma of the gonad; which differentiates into theca cells in the ovary or Leydig cells in the testicle. It may give rise to either **Fibroma** or **Thecoma**

PATHOLOGY OF BENIGN OVARIAN NEOPLASMS

I. EPITHELIAL OVARIAN TUMOURS

Epithelial tumours are the commonest ovarian neoplasms constituting almost 60-70% of all ovarian tumours. They are essentially benign but could be either border line or malignant.

A. SEROUS CYSTADENOMA

This is the *commonest benign ovarian neoplasm* representing nearly 10-15% of all tumours of the ovary. They are bilateral in up to 30% of cases, usually of moderate sizes (ranging 10-15 cm) when first detected it may present in one of the following three types.

1. Simple serous cysts: The commonest type of serous cysts. They are unilocular, thin walled, and filled with thin clear serous fluid. Simple serous cysts have the lowest malignant potential in all epithelial tumours.

2. Multilocular serous cyst: serous cysts may be multilocular, usually with only few locules.

3. Papillary serous cysts: Characterized by the presence of papillary growths that may be present either inside the cyst cavity (endophytic) or outside the external surface (exophytic). The cyst is usually multilocular. They have the highest malignant potential in all benign cysts (up to 50% risk of malignant transformation.

Microscopically:

- Cyst wall is lined by cuboidal cells which may be ciliated or non ciliated (tubal like epithelium).
- **Psammoma bodies:** These represent calcifications within the core of some of the papillae due to obstruction at the neck and accumulation of secretions. They occur occasionally in benign serous cystadenoma, but more frequent in well differentiated serous cystadenocarcinoma. They have no clinical significance, but may appear as calcified radio-opaque shadows in pelvic X-ray.



Fig 27-1: Simple serous cyst



Fig 27-2: Papillary serous cyst

B. MUCINOUS CYSTADENOMA



Fig 27-3: Mucinous cyst

These are the ***second most common benign*** ovarian neoplasms. They are usually unilateral, having a bluish or yellowish transparent colour. Although essentially benign mucinous cystadenomas may have a very low malignant potential (<5%)

- **Cut section:** Mucinous cystadenomas are characterized by being **multilocular** with plenty of locules containing thick gelatinous like mucin material. They are known to reach huge sizes sometimes filling the entire abdominal cavity.
- **Microscopically:** Cyst wall is lined by *tall columnar epithelium* with basally situated nuclei similar to endocervical epithelium, rich in Goblet cells.
- **Pseudomyxoma peritonii:**

This is a rare condition, in which huge amounts of gelatinous mucin material are found free in the peritoneal cavity. Most cases occur in association with rupture of a pre-existing mucinous cyst, but may occur rarely secondary to; peritoneal epithelial metaplasia, rupture of mucocele of the appendix, or in association with cancer of the colon.

Diagnosis is seldom made before laparotomy, and prognosis is poor even after surgery, as re-accumulation of gelatinous material after removal is the rule. The 5 years survival is around 50%.

Treatment: Chemotherapy (radioactive intraperitoneal colloid installation), after surgical removal of the tumour and contents is evacuated.

C. BRENNER TUMOUR

These are **rare** tumours that account for only **1-2%** of all ovarian neoplasms. They probably arise from Wolffian metaplasia of the surface ovarian epithelium, and are bilateral in only 10-15% of cases, being more prevalent in women > 40 years. The majority of tumours are **benign**, but border line or malignant tumours have been reported.

- Brenner tumours are **solid** in consistency, usually of **small** (< 2 cm) **to moderate size**, and about half are incidental findings discovered only by the pathologist on examining specimens.
- **Microscopically:** the tumour is characterized by ***epithelial cell nests*** with characteristic **coffee bean** nuclei.
- **Hormonal function:** occasionally some of Brenner tumours may secrete oestrogen and may even present by vaginal bleeding (i.e.; functioning Brenner tumour).



Fig 27-4: Brenner tumour

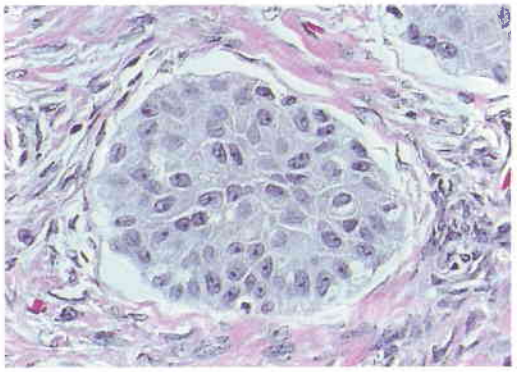

Fig 27-5: Coffee bean appearance by microcopy

II. GERM CELL TUMOURS

Germ cell tumours constitute almost 20-30% of all ovarian neoplasms, occurring mostly in the younger women < 30 years age. They are generally benign tumours.



Fig 27-6: Bilateral dermoid cysts



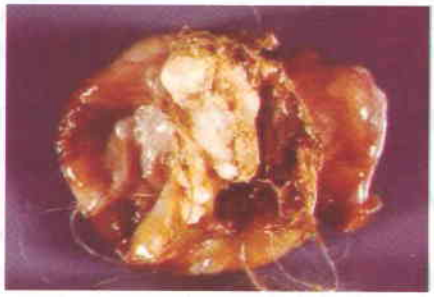

Fig 27-7: Cut section in dermoid cyst with hair and cartilage

A. BENIGN CYSTIC TERATOMA (BCT)

BCT, also known as dermoid cysts, is the only germ cell tumour which is common. They represent almost 50% of ovarian neoplasms occurring in young females ***below 20 years*** of age. BCT is also the commonest ovarian neoplasm encountered during the ***childbearing*** *period* and especially ***during pregnancy***.

BCT are bilateral in up to 12% of cases. They are usually of moderate size (5-10 cm) when first discovered and rarely reach huge sizes. Most cysts have a long pedicle that makes them more liable to complications as torsion.

- **Cut section:** Cysts are greyish in colour**,** mostly unilocular, but may contain few small locules, with one larger locule containing a **mamilla** (a small solid knob < 2cm), and variable tissue contents including hair, teeth, bone, and cartilage, mixed in a sebaceous material.
- Teratomas are derived from **toti-potent** germ cells and can differentiate into all three embryonic germ cell layers (ectoderm, mesoderm, and endoderm). It is thought that this may occur via *parthenogenesis*; a form of asexual reproduction in which the ovum develops without fertilization.
  - ***Ectoderm:*** skin, hair, sweat and sebaceous glands (most predominant tissue).
  - ***Mesoderm:*** bone, cartilage and smooth muscle.
  - ***Endoderm:*** thyroid, bronchus, and intestinal tissue
- **Microscopically:** cyst wall is lined by *stratified squamous epithelium* with sebaceous glands.
- BCT have **very low** malignant potential <1% (squamous cell carcinoma).

N.B.: Most tumours are asymptomatic, incidentally discovered, unless complicated by torsion, rupture or infection.

B. STRUMA OVARII

Rarely a teratoma may be composed of a single tissue, in which the term monodermal teratoma is used. Struma ovarii is an example of a monodermal teratoma that is composed of hormonally active ***thyroid tissue***. They comprise only 1-4% of cystic teratomas, with only 5% capable of producing sufficient thyroid hormone to produce symptoms. Some 5-10% of tumours develop into carcinoma.

C. GONADOBLASTOMA

A **benign solid** tumour composed of germ cells mixed with other cells resembling granulosa and sertoli cells. Although gonadoblastoma is initially benign, half of these tumours may predispose to development of Dysgerminoma or other malignant germ cell tumours. Almost all patients with a gonadoblastoma have an abnormal gonad, with a Y chromosome in 90% of cases.

N.B.: Prophylactic gonadectomy should be performed in patients with dysgenetic gonad, particularly with a Y chromosome for fear of future development of malignant neoplasms.

III. BENIGN SEX CORD STROMAL TUMOURS

These tumours represent < 4% of all ovarian neoplasms. They are almost always benign.

A. FIBROMA:

Fibromas are **rare** tumours derived from stromal cells, seen mostly in women around age of 50 years. They are **benign**, **solid**, tumours, **unilateral** in >90% of cases, usually mobile with a long pedicle and a lobulated glistening white surface.

Ascites may occur with many of the **larger** fibromas giving the picture of **Meig's syndrome** in only 1% of cases. (Meig's syndrome is the association of ovarian Fibroma with ascites and right side pleural effusion that disappears on removal of the tumour).

B. THECOMA (THECA CELL TUMOUR):

Theca cell tumours are **rare**, with the majority occurring in post menopausal women. Almost all are **benign**, **solid**, and **unilateral**.

Many thecomas are **functioning** tumours, producing **oestrogen** in sufficient amounts to cause, endometrial hyperplasia, postmenopausal bleeding and rarely endometrial carcinoma.

- **Microscopically;** tumour is formed from cells resembling theca interna cells.

COMPLICATIONS OF BENIGN OVARIAN NEOPLASMS

Benign ovarian tumours are liable to several complications that may form the main presenting clinical picture in many cases. These include; **torsion, haemorrhage, rupture, infection, incarceration,** and **malignant transformation.**

1. TORSION:

It is the commonest complication. Torsion may be gradual or sudden, incomplete or complete and it may be initiated by a sudden movement of the patient.

- *Gradual incomplete torsion;* leads to congestion, enlargement of the tumour and thrombosis.
- *Sudden complete torsion;* causes sudden occlusion of the arterial blood supply leading to necrosis and gangrene of the cyst.

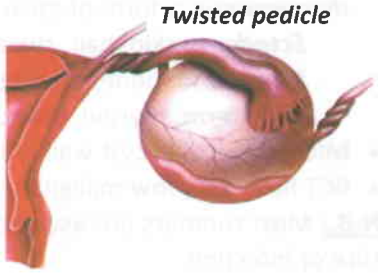

Fig 27-8: Torsion ovarian cyst

- **Factors predisposing to torsion:**

1. *Moderate size tumours with long pedicle of the cyst:* BCT is the commonest tumour to undergo torsion due to its long pedicle and fat content, another common example is simple serous cyst. Large tumours cannot usually undergo rotation.
2. *Free mobility with absence of surrounding adhesions;* facilitate torsion, whereas fixed tumours do not undergo rotation.
3. *Pregnancy and puerperium:* Due to displacement of the tumour by pregnancy and laxity of abdominal wall after delivery.

- **Clinical picture:** is that of ***acute abdomen***, where the tumour is tense and tender on palpation.
- **Treatment:**
  a. Ovariotomy (removal of the entire ovary), usually via laparotomy, is the treatment of choice in a gangrenous cyst, in absence of viable healthy ovarian tissue.
  b. Ovarian cystectomy: untwisting of the pedicle and removal of the cyst with preservation of the ovary has a place if there is still adequate healthy ovarian tissue present.

2. HAEMORRHAGE:

Haemorrhage in a cyst may occur as a result of torsion, trauma to the abdomen or may occur spontaneously especially during pregnancy.

- **Clinical picture**: is that of ***acute abdomen***, where the tumour is tense and tender on palpation.
- **Treatment**: Ovariotomy usually via laparotomy.

3. RUPTURE:

Rupture of an ovarian cyst may occur as a result of torsion or haemorrhage, or may be traumatic, during labour or due to rough vaginal examination.

- **Clinical picture:**
  a. Severe pain with picture of acute abdomen (abdominal wall rigidity, tenderness, and rebound tenderness)
  b. Internal haemorrhage may occur with the picture of hypovolaemic shock (tachycardia, hypotension, and oliguria). Palpation reveals dullness in the flanks with shifting dullness.
  c. Rupture of a dermoid cyst may lead to severe chemical peritonitis, while rupture of a mucinous cystadenoma may lead to pseudomyxoma peritonii.
- **Treatment:**
  a. Sedatives to alleviate pain
  b. Resuscitation of the patient to restore the B.P., by IV fluids or blood transfusion, etc...
  c. Ovariotomy done as an emergency procedure usually via laparotomy, and peritoneal lavage performed to remove contents of the cyst.

4. INFECTION:

Ovarian cyst may be infected either;

- In the **puerperium** (following abortion or labour), or
- From a nearby **infected organ** (as appendicitis or pyosalpinx), or
- Following **torsion** (due to adhesions).

- **Clinical picture:**
  - General picture of infection as general malaise, fever, tachycardia, tachypnea, etc...
  - Bimanual examination shows a fixed, tender tumour with rapid increase in size.
- **Treatment:**
  - Antibiotics to control infection (broad spectrum + anaerobic types)
  - Ovariotomy, via laparotomy for removal of the whole ovary.

5. INCARCERATION:

Ovarian cyst may be impacted in Douglas pouch, particularly in large size tumours.

- **Clinically:** it may cause pressure symptoms on bladder and rectum. During pregnancy it may cause obstructed labour.
- **Treatment** is by surgical removal of the tumour by ovariotomy or cystectomy, once incarcerated.

6. MALIGNANT TRANSFORMATION:

- Potential of malignancy is higher in solid rather than cystic tumours.
- Papillary serous cystadenoma has malignant potential up to 50%.
- Mucinous cystadenoma has a 5% incidence of malignant transformation.
- Benign cystic teratoma carries less than 1% risk of malignancy.

CLINICAL PICTURE OF BENIGN OVARIAN NEOPLASMS

A) SYMPTOMS:

1. **Asymptomatic:** many of the benign ovarian tumours are discovered only incidentally during a routine clinical pelvic or gynaecologic examination, or during ultrasonography.
2. **Abdominal swelling:** may be felt by the patient only if the tumour is large.
3. **Lower abdominal pain:** and ***heaviness*** over the site of the tumour, may be;
   - Acute pain; if the tumour is complicated by torsion, rupture, haemorrhage, or infection.
   - Chronic dull aching pain; in large-sized swellings as in mucinous cystadenoma.
4. **Pressure symptoms:** if the tumour is huge or incarcerated.
   - Abdominal pressure symptoms; Epigastric pain, dyspnoea and palpitation.
   - Pelvic pressure symptoms: Frequency of micturition, retention of urine.
5. **Menstrual disorders:** ovarian neoplasms are usually not associated with menstrual disturbances, except in rare functioning tumours (theca cell tumour & functioning Brenner).

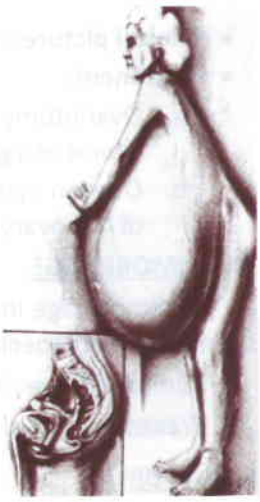

Fig 27-9:

B. PHYSICAL SIGNS: These will depend largely on the size of the tumour.

1. **Small tumours:** are only detected on ***bimanual pelvic examination***, felt on one side of the uterus, as rounded, smooth, mobile, usually cystic (rarely solid) mass, separate from the uterus (the movement of the mass is not transmitted to the cervix).
2. **Large tumours:** can be detected by ***abdominal examination***
   - ***Inspection:*** symmetrical abdominal enlargement.
   - ***Palpation:*** abdominal mass that may be central or to one side of the midline, with a well defined upper and lateral border, smooth or lobulated surface, usually tense, commonly mobile from above downwards.
   - ***Percussion:*** central dullness is elicited on the mass, with resonant flanks (except if associated with marked ascites, where flanks become dull with shifting dullness).

- **N.B.:** in excessively large cyst *ovarian cachexia* may occur due to the rapidly growing tumour.

C. SPECIAL INVESTIGATIONS:

Ovarian swellings can be suspected clinically but always need further confirmation by:

1. **Ultrasonography:** This is the gold standard in diagnosis of ovarian swellings.
   - U.S. is important to diagnose the ovarian origin of the swelling and differentiate between benign and malignant tumours.
   - Smaller tumour are best detected by TVS, while larger ones by TAS
   - Both TAS and TVS can differentiate between unilateral and bilateral tumours, cystic and solid ones, unilocular or multilocular cysts, and suspicions for malignancy (heterogeneous echogenicity of the tumour, low resistance Doppler indices, presence of ascites, etc....).

2. Tumour markers: to exclude malignancy

- CA-125 is significantly elevated in epithelial ovarian cancer, however it may be also elevated in benign conditions as endometriosis and endometriomas
- CEA and CA 19-19 are peculiarly elevated with mucinous carcinoma

3. Laparoscopy:

May be indicated if ultrasonography was inconclusive in evaluation of an adnexal swelling as in differentiating between;

- Ovarian cyst and tubal or tubo-ovarian cystic masses, or
- Solid ovarian fibroma and pedunculated subserous myoma SSM.)

4. I.V.P.: may be beneficial in **larger tumours to delineate the course of ureter.**

TREATMENT OF BENIGN OVARIAN NEOPLASMS

The **aim of treatment** in benign ovarian neoplasms is **surgical removal** of the tumour, with or without the affected ovary, for fear of complications as; torsion, rupture, and malignant transformation. The type of operation depends upon the age of the patient, her desire for future pregnancies, together with the size and type of the tumour, and whether complicated or not.

1. OVARIAN CYSTECTOMY:

It consists of ***shelling out*** or ***enucleation*** of the cyst with ***preservation of the ovary***. It is indicated in young patients and particularly with bilateral cysts of small size as in dermoid cysts. Ovarian cystectomy may be done either by ***laparotomy*** or by ***laparoscopy***.

- Laparoscopic ovarian cystectomy is best reserved for the young women (< 35 years) with small sized cyst. Cyst fluid may be sent for cytological examination.
- Dermoid cysts (BCT) are better removed by laparotomy rather than laparoscopy as laparoscopic surgery may carry the risk of dissemination of its irritant contents.
- Larger cysts are better treated by oophorectomy (see later), because of difficulty in enucleation of the cyst without rupture and dissemination of its contents, together with absence of adequate healthy residual ovarian tissue to be left. Fear of malignancy is also an additional factor especially in larger, bilateral, and solid tumours.

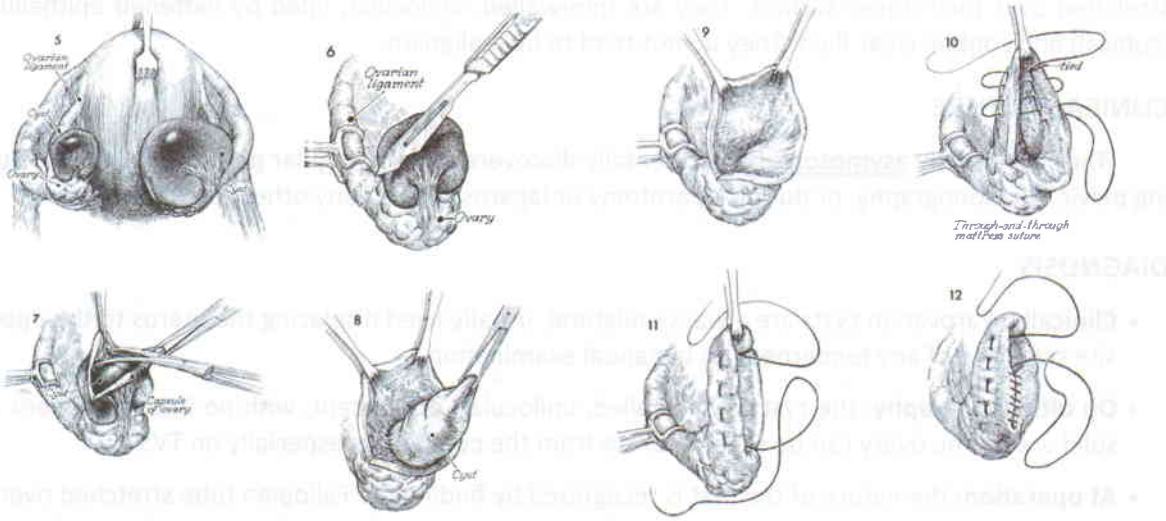

Fig 27-10: Ovarian cystectomy operation (enucleation of the cyst and closure of the bed)

2. OOPHORECTOMY:

It consists of ***removal of the whole tumour together with the ovary***. The word **ovariotomy** is a synonym still used by tradition to describe the same procedure however; oophorectomy is the more correct term. Both the **infundibulopelvic ligament**, (lateral to the tumour and contains the ovarian vessels, nerves & lymphatics), and the **ovarian ligament** (medial to the tumour and attached to the uterus), are clamped and double ligated. The mesovarium can be clamped separately

Oophorectomy can be performed via ***laparotomy*** in all kinds of ovarian tumours. ***Laparoscopic oophorectomy*** can be safely established only in smaller neoplasms. Removal of larger cysts by laparoscopy remains controversial over the issue of dissemination of the cyst contents including irritant fluid as in dermoid cyst, papillae, mucinous material, and possibly malignant cells. Any ascitic fluid detected should be aspirated and sent for cytology.

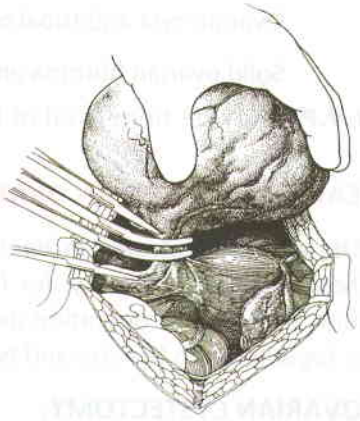

Fig 27-11: ovariotomy

3. PAN HYSTERECTOMY:

If the patient is premenopausal, and has completed her family, total abdominal hysterectomy with bilateral salpingo-oophorectomy **(TAH BSO)** is usually indicated. This is considered as a preventive step against the future development of ovarian cancer by advance of age.

PAROVARIAN CYSTS

Parovarian cysts are not ovarian in origin. They arise from cystic dilatation in the Wolffian ducts remnants in a tubule of the Epoophoron between the layers of the broad ligament just below the fallopian tube.

PATHOLOGY

Parovarian cysts are usually small to moderate in size rarely exceeding over ten centimetres in diameter. Cysts are covered by peritoneum, with the fallopian tube being characteristically stretched over their upper surface. They are thin-walled, unilocular, lined by flattened epithelium (cubical) and contain clear fluid. They do not tend to be malignant.

CLINICAL PICTURE

They are usually **asymptomatic**, incidentally discovered during regular pelvic examination, during pelvic ultrasonography, or during laparotomy or laparoscopy for any other condition.

DIAGNOSIS

- **Clinically:** Parovarian cysts are always unilateral, usually fixed displacing the uterus to the opposite side, free of any tenderness on bimanual examination.
- **On ultrasonography:** the cyst is thin walled, unilocular, echolucent, with no internal echoes or solid areas. The ovary can be seen separate from the cystic mass especially on TVS.
- **At operation:** the nature of the cyst is recognised by finding the Fallopian tube stretched over it and by the fact that the ovary is separate from the cyst, usually attached at a point on the posterior surface of the cyst.

TREATMENT

Surgical excision of the cyst by **enucleation** after incising the overlying peritoneum is the only treatment of parovarian cysts. The cavity left is obliterated by sutures and complete haemostasis is ensured to prevent haematoma formation.

The procedure can be performed both by laparotomy or laparoscopy according to tumour size and surgical facilities.

In the case of large cysts burrowing deeply in the pelvis care is required not to injure the ureter or uterine artery.

Key points in benign ovarian tumours

- *Ovarian neoplasms are classified according to their cell of origin into epithelial, germ cell, and sex cord stromal tumours*
- *Benign epithelial ovarian tumours (serous, mucinous, and papillary cysts) are the commonest tumours encountered, regardless women's age.*
- *Germ cell tumours are generally rare except for BCT, which is the commonest germ cell tumour, and is the commonest ovarian neoplasm in young and pregnant females.*
- *Benign cystic tumours include; serous, mucinous, papillary cystadenomas, and BCT.*
- *Benign solid tumours include; Brenner tumour, struma ovarii, gonadoblastoma, fibroma, and thecoma. They are generally rare compared to cystic tumours*
- *Clinically most ovarian neoplasms are silent and asymptomatic except if large size, or if presenting with a complication as; torsion, haemorrhage , rupture, infection, incarceration, and malignant transformation*
- *Clinically large tumours can be palpated by abdominal examination, intermediate and smaller size tumours can be felt through bimanual vaginal examination except in the obese patient.*
- *Pelvic ultrasonography whether TAS or TVS is the gold standard in diagnosis of ovarian swellings. US can also give accurate data about the nature of the tumour, its bilaterality, its consistency, unilocular or multilocular, its malignant nature, and associated ascites, uterine, or adnexal masses.*
- *Tumour markers, Laparoscopy, IVP, CT and MRI may be of help in certain cases, especially if malignancy is suspected.*
- *Treatment of benign ovarian neoplasms is always through surgical excision or enucleation of the cyst alone (ovarian cystectomy) or with the entire ovary (ovariotomy, ovariectomy, or oophorectomy), usually via laparotomy or sometimes via laparoscopy in selected cases.*
- *Abdominal hysterectomy, whether total or subtotal, is reserved only to the larger tumours, in the older or the menopausal patients, especially if the tumour was solid or bilateral, as prophylaxis against future threat of malignancy.*

28 MALIGNANT OVARIAN NEOPLASMS

- *Classification*
  - *Epithelial ovarian cancer*
  - *Malignant germ cell tumours*
  - *Malignant sex-cord stromal tumours*
- *Patterns of spread*
- *Staging of ovarian cancer*
- *Clinical picture*
- *Special investigations*
- *Surgical treatment*
- *Chemotherapy*
- *Radiation therapy*

INTRODUCTION AND OVERVIEW

Ovarian cancer is the third most common malignancy of female genital organs, after cancer of endometrium and cervix, but is the most lethal of them all. More women die from ovarian cancer than from carcinoma of the cervix and body of the uterus combined.

Most malignant ovarian tumours are epithelial in origin, non epithelial ovarian cancer (germ cell and sex-cord tumours) are much less common. Ovarian cancer is generally rare before 35 years of age but significantly increase by advancing age especially with a peak at 50-70 year old age group.

Unfortunately the majority of cases with ovarian cancer are discovered after the disease has already spread beyond the ovary giving generally poor prognosis.

Surgery is the mainstay in treatment both for staging and therapy. Adjuvant chemotherapy has a major role following surgery in more advanced stages as the majority of tumours, especially epithelial, show good response to chemotherapy. Some malignant germ cell tumours show good response to treatment by radiotherapy.

HISTOGENETIC CLASSIFICATION OF MALIGNANT OVARIAN TUMOURS

1. Epithelial ovarian cancer

a. Serous adenocarcinoma
b. Mucinous adenocarcinoma
c. Endometrioid adenocarcinoma
d. Undifferentiated adenocarcinoma

2. Germ cell tumours

a. Dysgerminoma
b. Endodermal sinus tumour
c. Choriocarcinoma
d. Malignant teratoma

3. Sex cord stromal tumours

a. Granulosa cell tumour
b. Androblastoma: Sertoli-Leydig cell tumour
c. Gynandroblastoma

4. Metastatic tumours

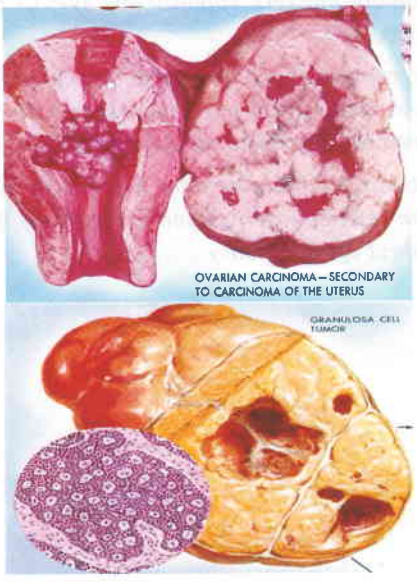

Fig 28-1: malignant ovarian tumour

EPITHELIAL OVARIAN CANCER

Epithelial ovarian cancers are the **commonest** malignant neoplasms arising from the ovary and constitute almost **60-70%** of all **ovarian cancers**. They are either *serous, mucinous,* or *endometrioid adenocarcinomas.*

Epithelial ovarian cancers usually occur at **older ages** near to menopause. They grow rapidly, usually without significant symptoms, leading to a delay in their diagnosis with almost 2/3 of cases being **first diagnosed at stage 3** (tumour has spread outside the capsule of the ovary with associated ascites and peritoneal implants), giving an over all **poor prognosis**.

Epithelial ovarian cancer is usually associated with markedly elevated levels of **CA-125** which is considered an important **tumour marker** that correlates with the stage of the disease. Most tumours are **chemosensitive**, showing good response to adjuvant chemotherapy after primary surgery.

AETIOLOGY

The aetiology of epithelial ovarian cancer is unknown. Possible aetiologic factors include:

1. Reproductive Factor:

Nulliparous women, and women with low parity, have a higher risk than parous women to develop epithelial ovarian cancer. This may be related to the continuous, repeated, minor trauma of the surface epithelium of the ovary caused by uninterrupted ovulation. Evidence to this postulation includes:

a. ***Prolonged suppression of ovulation:*** as that occurring during pregnancy, lactation, and prolonged use of OCP is associated with decreased incidence of epithelial ovarian cancer.

b. ***Prolonged and repeated use of drugs for induction of ovulation:*** as in treatment of anovulatory infertility or ovarian super-ovulation protocols in ICSI & IVF procedures, has been associated with a slightly increased risk of ovarian cancer after several years of cessation of treatment.

2. Hereditary 'Genetic' factor:

Five to 10% of epithelial ovarian cancer will occur in women with ***hereditary predisposition*** i.e. two or more relatives had ovarian or breast cancer. A woman with a single first-degree relative with ovarian cancer has a relative risk of approximately 3.6 for developing ovarian cancer compared with the general population. Three types of familial ovarian cancer are identified:

a. Site specific ovarian cancer syndrome (15%)

b. Hereditary breast / ovarian cancer syndrome (75%)

c. Hereditary non polyposis colorectal cancer syndrome with endometrial, breast, or ovarian cancer (10%, Lynch type II).

- A particular feature of ***familial cancer*** is that it tends to occur at a ***younger*** age group.
- ***Genetic predisposition*** to epithelial ovarian cancer is due to gene mutations in the breast -ovarian cancer tumour suppressor genes **BRCA1** and **BRCA2**. These genes account for most cases of familial breast and ovarian cancer

RISK FACTORS FOR EPITHELIAL CANCER

1. **Age:** Increasing age is the strongest patient-related risk factor. The mean age at diagnosis is 59 years and the risk of malignancy increases with advancing age.
2. **Nulliparity & infertility**; are associated with increased risk, compared to multipara.
3. **White race:** have more prevalence compared to black and African women.
4. **Prior history of endometrial or breast cancer** in the same patient.
5. **Family history of ovarian cancer** in first degree relatives.

N.B: Multiparity, prolonged lactation, and prolonged use of OCP seem to have a relatively protective effect against epithelial ovarian cancer.

PATHOLOGY OF EPITHELIAL OVARIAN CANCER

A. Macroscopic appearance:

Most epithelial ovarian cancers have both cystic and solid elements, with marked variation in the tumour size and consistency. The substance of the tumour is the seat of extensive haemorrhage and necrosis.

At laparotomy, in early stage disease the tumour is usually unilateral with intact capsule. In advanced stages, the tumour may be bilateral, the capsule may be ruptured, and the tumour may be fixed to adjacent structures as the uterus, bladder, colon, etc...

B. Microscopic picture:

- **Histological types** include **adenocarcinomas** of the ***Serous, Mucinous, or Endometrioid***, types.
- **Tumour grading:** each histologic type is graded according to cell differentiation into;
  1. ***Well differentiated tumours (Grade I);*** showing malignant cells with a preserved glandular pattern
  2. ***Moderately differentiated tumours (Grade II);*** showing sheets of highly malignant cells with presence of limited glandular pattern.
  3. ***Undifferentiated tumours (Grade III);*** showing only sheets of highly malignant cells with absence of a well defined glandular pattern.
- Serous cystadenocarcinoma: involve both ovaries in over 50% of cases and usually have both cystic and solid components. Psammoma bodies, concentrically laminated concretions, are a frequent histologic finding.
- Mucinous cystadenocarcinoma: are multilocular, bilateral in only 20% of cases, and contain mucinous fluid with solid and cystic components. They may reach huge size, and in <5% of cases concomitant pseudomyxoma peritonii may be present.
- Endometrioid tumours: are usually malignant, and closely mimic endometrial cancer in histologic appearance. In around 30% of cases there is a coexistent second primary in the endometrium.

BORDER LINE EPITHELIAL TUMOURS

These are epithelial tumours with cellular features of malignancy, but **no** invasion of the stroma. These are tumours of ***low malignant*** *potential* as it is confined to the ovary. Tumours are mostly ***serous*** or ***mucinous***, they occur in younger age, and usually have a better prognosis.

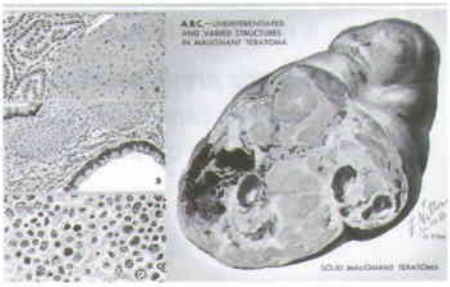

Fig 28-2:

MALIGNANT GERM CELL TUMOURS

Germ cell tumours are derived from **primordial germ cells** of the ovary, and comprise **20-25%** of all ovarian tumours. Only **5%** of germ cell tumours are **malignant**, they include *dysgerminoma, endodermal sinus tumour, (yolk sac tumour), choriocarcinoma,* and *malignant teratoma.*

SPECIAL FEATURES OF MALIGNANT GERM CELL TUMOURS

Malignant germ cell tumours differ from epithelial ovarian cancer in the following;

a. **Age incidence:** Malignant germ cell tumours occur at a generally **younger age** group of women accounting for more than 2/3 of all malignant ovarian neoplasms in women < 30 years of age. They should be suspected whenever a unilateral solid tumour is diagnosed by US in a young female.
b. **Associated tumour markers:** Most germ cell tumours produce substances in the circulation that can be used as **specific markers**, including lactic dehydrogenase (LDH), human chorionic gonadotrophins (hCG), and alpha feto protein (AFP).
c. **Association with abnormal gonads:** Germ cell tumours are the commonest tumours occurring in patients with abnormal gonads and in sex chromatin negative females.
d. **Sensitivity to irradiation and chemotherapy:** In contrast to epithelial ovarian cancers, many of the malignant germ cell tumours are **radiosensitive** giving a good response to postoperative radiotherapy, while others give better response to chemotherapy.
e. **The place for conservative surgery:** Unilateral salpingo-oophorectomy is an appropriate treatment option in stage **1a** tumours when the patient is young and desirous for further fertility preservation (Fig 28-3).

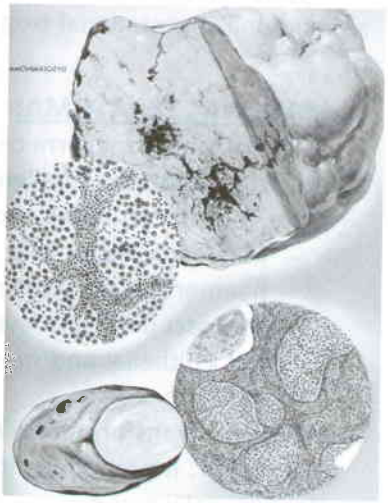

Fig 28-3:

A) DYSGERMINOMA:

Dysgerminoma is the **commonest** malignant germ cell tumour although it represents only **1-3%** of all ovarian cancers. It occurs predominantly in **young** females aged **10-30** years. In **5%** of cases it occurs in patients with **abnormal gonads**, as in gonadal dysgenesis, or testicular feminization syndrome. In such cases dysgerminoma may arise in a gonadoblastoma. A dysgerminoma may secrete *LDH*, which may serve as specific **tumour marker**.

PATHOLOGY:

- **Macroscopically:** It is a *solid* ovarian tumour, usually of *small* or *moderate size*, bilateral in only 10% of cases. Its colour is greyish with lobulated surface. On cut section there is tendency to haemorrhage and necrosis. Dysgerminoma is more liable to *early lymphatic spread* to pelvic and para aortic nodes
- **Microscopically:** It consists of gem cells arranged in alveoli or nests separated by fibrous tissue septa. The cells are rounded, large, with abundant cytoplasm and large vesicular nucleus. A *lymphocytic infiltration* of the stroma is a characteristic feature.

B) ENDODERMAL SINUS TUMOUR "EST":

EST or yolk sac tumour is the **second most common** malignant germ cell tumour of the ovary, but comprises only **1%** of all ovarian cancers. The tumour is prevalent in **young** women with a median age of 19 years, and rarely affects women over 40 years.

Most EST are associated with elevated serum levels of ***alpha-fetoproteins*** that are used as a **tumour marker**. Coexistent teratomas are found in 20% of patients.

PATHOLOGY:

- **Macroscopically:** Small solid tumours which are almost always unilateral.
- **Microscopically:** characterized by ***Shiller-Duval bodies,*** which are cystic spaces in which projects glomerulous-like structure with a central vascular core.

C) CHORIOCARCINOMA:

These tumours are *very rare*.

- Macroscopically: it is usually a *unilateral, solid*, tumour.
- Microscopically: it reveals sheets of malignant cytotrophoblasts and syncitiotrophoblasts

They secrete hCG and may present with precocious pseudo-puberty. They have poor prognosis, and unlike gestational trophoblastic choriocarcinoma they do not respond well to chemotherapy.

D) MALIGNAT TERATOMA:

This rare malignant germ cell tumour may occur in one of two forms;

1. **Immature teratoma (malignant solid teratoma);** is rare and accounts for 1% of all ovarian teratomas. It characteristically occurs in children under 15 years of age.
   - Macroscopically; it is usually a unilateral solid tumour. The cut section showing areas of haemorrhage and necrosis.
   - Microscopically; it reveals predominance of immature (i.e. embryonic type) of neural tissue but epithelial and mesenchymal tissue may be also detected. It does not produce AFP or hCG.
2. **Malignant transformation in a benign cystic teratoma (dermoid cyst);** is very rare occurring in <1% of BCT. It predominantly changes into squamous cell carcinoma, and usually occurs in postmenopausal women.

MALIGNANT SEX-CORD STROMAL TUMOURS

Malignant sex cord stromal tumours may arise from functioning or non functioning stroma

1. **Functioning sex–cord tumours** may give rise to:
   - ***Granulosa cell tumour;*** with oestrogenic activity.
   - ***Sertoli-leydig cell tumour;*** with androgenic activity
   - ***Gynandroblastoma;*** a rare tumour with both oestrogenic and androgenic effect.
2. **Non- functioning stroma** may very rarely give rise to ***fibrosarcoma*** of the ovary.

A) GRANULOSA CELL TUMOURS:

These are **functioning low grade** cancers that account for around **5%** of ovarian malignancies. They are **slowly growing** and generally confined to the ovary when they first present; therefore they usually carry a **good prognosis**. 75% of granulosa cell tumours secrete hormones namely ***oestrogen***, while others appear to secrete ***inhibin***.

Oestrogen secreting tumours may lead to pseudo-precocious puberty in prepubertal girls. It may cause irregular menstrual bleeding, or postmenopausal bleeding depending on the age of the patient at presentation. In **25%-50%** of cases, granulosa cell tumours are associated with endometrial hyperplasia, and in **5%** with endometrial carcinoma especially in postmenopausal patients.

- **Macroscopically:** Tumours are usually unilateral, solid, yellow or yellow-grey in colour.
- **Microscopically:** The tumour is formed of granulosa cells arranged in different patterns. ***Call-Exner bodies*** are pathognomonic, but are present in only **50%** of cases. These are cystic spaces surrounded by granulosa cells arranged in a rosette like shape.

B) SERTOLI-LEYDIG CELL TUMOURS:

These are among the **rarest** of all ovarian tumours comprising < 0.2% of such tumours, which are of ***low grade malignancy*** occurring mostly in young women 20-30 years of age.

The majority of Sertoli-Leydig tumours are **androgenic**, and in 75% of cases they will cause a state of ***defeminisation*** at first, followed later by ***virilizing effects*** in the form of acne, hirsutism, clitoromegaly, deepening of voice, and increased muscle bulk. Rarely some tumours may produce **oestrogen**.

- **Macroscopically:** tumours are almost always unilateral, solid, small or moderate in size.
- **Microscopically:** they contain either Sertoli or Leydig cells, and in the case of the latter may be accompanied by stroma derived fibroblasts.

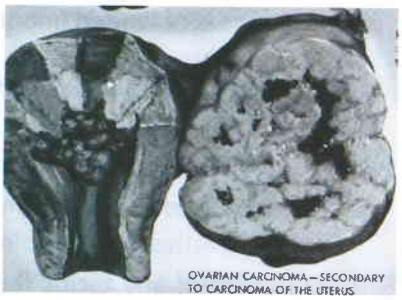

Fig 28-4:

METASTATIC OVARIAN CANCER

Metastatic ovarian cancer forms about 5-6 % of all ovarian tumours. The primary may arise from **genital tumours;** from cancers of the endometrium, tube, contra lateral ovary, and very rarely from the cervix, or **extra genital tumours;** from cancers of the breast, GIT (as stomach, colon, & biliary tract), or the thyroid gland.

Pathologically it is classified into **2** types;

A. **Typical metastatic cancer;** which resembles the primary cancer
B. **Atypical metastatic cancer;** e.g. Krükenberg tumour (see below)

KRÜKENBERG TUMOUR:

It accounts of **30-40%** of metastatic cancer to the ovary. The primary is usually in the pylorus of the stomach, less commonly in the colon, breast or biliary tract.

- **Macroscopically:** Krukenberg tumours are **bilateral** solid ovarian tumour retaining the shape of the ovary. The main interest is in its histogenesis; the most acceptable theory is that malignant cells reached both ovaries by *retrograde lymphatic spread*.
- **Microscopically:** characteristic microscopic feature is the ***signet ring cells*** in which the nucleus is pushed aside by abundant cytoplasm.

Prognosis is bad, where most patients die within one year because most of the lesions are not discovered until the primary disease is advanced.

PATTERNS OF SPREAD OF OVARIAN CANCER

1. **Direct extension** to adjacent organs such as tube, uterus, colon and bladder.
2. **Trans-coelomic spread**, by exfoliation of surface cells into the **peritoneal cavity**, giving deposits in the pouch of Douglas (felt as nodules on PV examination), right paracolic gutter, surface of the right lobe of liver, right hemi-diaphragm and surface of intestine or omentum forming an omental cake (pathway of peritoneal fluid).
3. **Lymphatic spread** mainly to para-aortic lymph nodes.
4. **Haematogenous spread** is always late and uncommon. This would be to vital organs such as the liver parenchyma, lung, brain and bones.

STAGING OF OVARIAN CANCER

Surgical staging for ovarian cancer **via laparotomy** is the **only standard method** for staging, since attempts at staging the disease based on data obtained on clinical examination and special investigations is of limited importance in affecting the prognosis and line of treatment.

SURGICAL STAGING OF PRIMARY OVARIAN CANCER:

This is performed through an **exploratory laparotomy**, via a **mid line subumbilical suprapubic** abdominal wall **incision** in which the following is performed:

1. *Exploration* of the pelvic and peritoneal cavity to asses whether the tumour is confined to one or both ovaries, or extending to other pelvic or abdominal organs.
2. *Aspiration* of any ascitic fluid present (or perform saline peritoneal washings if no ascites present) for cytologic examination to detect malignant cells in the peritoneal cavity.
3. *Performing* a TAH-BSO, together with Infracolic omentectomy, and pelvic and para-aortic lymph node sampling, whenever possible.

Resection of any visible enlarged nodules or masses in pelvic or abdominal cavities, or any pelvic or extrapelvic tumour masses >2.0 cm (debulking or cytoreductive surgery).

FIGO STAGING OF OVARIAN CANCER 2018: (Simplified SURGICAL STAGING)

FIGO Stage	Stage Description*
I	**The cancer is only in the ovary (or ovaries)**
IA	The cancer is in one ovary, and the tumor is confined to the inside of the ovary. No cancer cells are found in the fluid (ascites) or washings from the abdomen and pelvis.
IB	The cancer is in both ovaries. No cancer cells are found in the fluid (ascites) or washings from the abdomen and pelvis.
IC	The cancer is in one or both ovaries. Cancer cells are found in the fluid (ascites) or washings from the abdomen and pelvis.
II	**The cancer is in one or both ovaries and has spread to other organs (such as the uterus, bladder, the sigmoid colon, or the rectum) within the pelvis.**
IIA	The cancer has spread to or has invaded (grown into) the uterus or the fallopian tubes.
IIB	The cancer is on the outer surface of or has grown into other nearby pelvic organs such as the bladder, the sigmoid colon, or the rectum.
III	**The cancer is in one or both ovaries. It has spread to the retroperitoneal (pelvic and/or para-aortic) lymph nodes only.**
IV	**Distant spread to far organs**
IVA	Cancer cells are found in the fluid around the lungs (called a malignant pleural effusion) with no other areas of cancer spread such as the liver, spleen, intestine, or lymph nodes outside the abdomen.
IVB	The cancer has spread to the inside of the spleen or liver, to lymph nodes other than the retroperitoneal lymph nodes, and/or to other organs or tissues outside the peritoneal cavity such as the lungs and bones.

DIAGNOSIS OF OVARIAN CANCER

This is a disease of late decade of life: 55–65 years of age in the majority of cases, with a very insidious onset and misleading non specific symptoms in the majority of cases.

SYMPTOMS

A. Early stage disease: is usually **asymptomatic**.

B. Later stages may be associated with;

- Non specific GIT symptoms; in the form of dyspepsia, indigestion, and anorexia
- Dull aching pelvic pain and heaviness
- Pressure symptoms; as urinary frequency and constipation may be present
- Abdominal swelling, pain, and cachexia
- Abnormal uterine bleeding, especially postmenopausal bleeding in oestrogen producing ovarian tumours.

N.B; Because symptoms are commonly non specific and mild, most tumours will be diagnosed late, usually at stage II or III disease.

PHYSICAL SIGNS

The most important physical sign is the ***palpation of a pelvic mass***. In early stages of the disease this may be accidentally discovered during routine gynaecologic examination for check up. In late cases a large ***pelvic or pelviabdominal mass*** may be palpated with features suggestive of malignancy as being bilateral, solid, fixed, associated with ascites, unilateral LL oedema, and rapid growth (see later).

FEATURES SUGGESTING MALIGNANCY in ovarian tumours

1. History and symptoms:

- Tumours discovered at older age (postmenopause) are highly suspicious for malignancy.
- Tumours discovered in women with family history of breast, colonic, or ovarian cancer.
- Tumours associated with rapid weight loss, rapid progressive abdominal enlargement, and persistent GIT symptoms.
- Functioning tumours with feminizing or virilizing effects.

2. General examination:

- Malignant cachexia (with marked and rapid weight loss and dehydration)
- Palpable supraclavicular lymph nodes especially on the left side, (Virchow's glands).
- Pleural effusion, however it may be present in Meig's syndrome.
- Presence of an associated breast mass on breast examination
- Unilateral lower limb oedema (unilateral pressure by tumour with venous and lymphatic obstruction).

3. Abdominal Examination:

- ***Inspection:*** Abdominal enlargement, over lying skin showing peau d'orange.
- ***Palpation:*** Tumour which is solid (or partially solid), fixed especially if bilateral.
- ***Percussion:*** Presence of ascites (except with ovarian fibroma in Meig's syndrome).

4. Pelvic examination:

1. Nodules in Douglas pouch in the presence of a non tender adnexal mass.
2. Bilateral, especially if solid adnexal masses are very presumptive.
3. Fixed pelvic masses especially if amulgamated with pelvic organs (frozen pelvis).

5. At Laparotomy:

- Presence of ascites, especially if altered blood stained ascites.
- Bilaterality, fixation, and invasion of the capsule.
- Extracystic papillae and adhesions to surrounding structures.
- Peritoneal nodules or secondary deposits in omentum, intestine, liver, or lymph nodes
- Variable consistency with a cut section of the tumour shows haemorrhage and necrosis.

SPECIAL INVESTIGATIONS in ovarian cancer

Aim: To diagnose presence of an ovarian swelling, to suspect malignancy within the tumour, to exclude a hidden primary cancer elsewhere, and to determine spread of disease (stage).

1. Pelvic ultrasound:

- *TAS & TVS* are the gold standard diagnostic tool that can accurately detect pelvic masses of variable size and suggest their ovarian origin.
- *Sonographic features suggesting malignancy include;* heterogenous echopattern, intracystic and extracystic papillae, bilaterality, presence of ascites, and low resistance Doppler flow of the tumour vessels.

2. Chest X-Ray: for detection of pleural effusion and/or secondaries in the lungs.

3. Plain X-Ray abdomen: can detect calcification in dermoid cysts and Psammoma bodies.

4. CT & MRI: useful in detection of spread to liver and or lymph nodes (not mandatory).

5. Barium meal/enema: to exclude primary cancer in the stomach or colon (or spread).

6. Upper/lower G.I. Endoscopy: to detect a primary in the stomach or colon (or spread)

7. I.V.P.; to evaluate the course of the ureters and to exclude back pressure on the kidneys.

8. Paracentesis: needle aspiration of ascetic fluid for cytologic examination.

9. Endometrial curettage: In cases of abnormal uterine bleeding to exclude a primary or spread to the uterus.

10.Tumour markers:

- **CA 125**; commonly elevated in epithelial ovarian cancers (Normal< 35 u/ml). It may be slightly elevated in benign conditions as endometriosis and chocolate cysts of the ovary. It can be used also to monitor response to chemotherapy (decreasing levels denote good response).
- **Other markers** include; serum B-hCG (choriocarcinoma), serum alpha fetoprotein (EST), and serum lactic acid dehydrogenase (dysgerminoma), CA 19-9 (mucinous cyst), and carcin-embryonic antigen (CEA).

DIFFERENTIAL DIAGNOSIS of ovarian masses:

- *Pelvic masses:* as adnexal masses, uterine enlargement (myomata & pregnancy), colonic masses, retroperitoneal masses (pelvic kidney, retroperitoneal sarcoma, ...)
- *Abdominal masses* as liver or pancreatic tumour, and tense ascites.

SCREENING for Ovarian Cancer: (The aim is early diagnosis of ovarian cancer)

- Routine yearly pelvic examination in premenopausal and postmenopausal women. A palpable post menopausal ovary must always call for further investigation.
- Periodic TVS coupled with a serum CA-125 in those with an enlarged ovary have been proposed for screening of ovarian cancer (risk of malignancy scoring system).
- Genetic screening; testing for BRCA1 or BRCA2 mutation carriers in women with strong family history of breast and ovarian cancer.

PREVENTION OF OVARIAN CANCER

1. Surgical removal of an benign ovarian tumour
2. Prophylactic gonadectomy in patients with dysgenetic gonad particularly with a Y chromosome
3. In patients who are BRCA1 or BRCA2 mutation carriers, prophylactic oophorectomy is advisable after completion of childbearing by the age of 35 years.

EXPLORATORY LAPAROTOMY in ovarian cancer

The final diagnosis of ovarian cancer can only be made at exploratory laparotomy, which will serve not only for **diagnosis** but also for **surgical staging** and **primary surgical treatment**.

SURGICAL TREATMENT OF OVARIAN CANCER

A) EARLY STAGE OVARIAN CANCER:

In cases where there is no gross evidence for extension of the disease beyond the ovary;

1. **TAH-BSO and Infracolic omentectomy** is the standard treatment for patients with disease limited to the ovary (stages **I-IIa**). Surgical staging is completed via peritoneal wash and lymph node sampling for microscopic assessment of the extent of the disease.
2. **Unilateral salpingo-oophorectomy** may be occasionally offered to selected cases of **stage Ia** (tumour confined to one ovary, with capsule intact, and –ve peritoneal cytology), only when the patient is young and preservation of fertility is desired. Such conditions are mostly met with in;
   a. Malignant germ cell tumours (dysgerminoma and EST)
   b. Malignant sex cord stromal tumours (granulosa and Sertoli Leydig cell tumours).
   c. Borderline epithelial ovarian tumours

B) ADVANCED STAGE OVARIAN CANCER:

In cases with tumour extension beyond the ovaries:

1. **Initial Debulking (*Primary Cytoreductive surgery*):**

   The aim of initial surgery is to remove *all primary cancer* and if possible *all metastatic disease* within the *pelvic and abdominal peritoneal cavities* (leaving only residual small tumour deposits no more than 1.0 cm in diameter is acceptable).

   - Debulking surgery includes a **TAH-BSO** + omentectomy + excision of pelvic masses and peritoneal deposits >1-2.0 cm + segmental bowel resection if involved within the tumour mass.
   - Advantages of initial debulking surgery:
     a. It Improves *survival* in patients with advanced disease
     b. It Improves *response to chemotherapy*, when residual tumour implants left are less than 1-2.0 cm in size

2. Interval Debulking:

Chemotherapy prior to debulking surgery is sometimes applied to minimize tumour bulk and control ascites to allow for subsequent more complete radical surgery.

Second-look Surgery in ovarian cancer:

Second look laparotomy or laparoscopy, have been advocated to asses residual tumour within the abdominal cavity after primary surgery and chemotherapy, to decide on further adjuvant therapy needed.

Nowadays modern imaging technique, as spiral CT & MRI, together with serum CA125 tests have largely nullified the need for second look surgery. At the present state its only place is when a tumour marker is rising apart from negative imaging for tumour residues.

CHEMOTHERAPY IN OVARIAN CANCER

Chemotherapy whether single or multiple agents has a major role in the management of ovarian cancer especially in advanced disease, and mostly with epithelial ovarian cancer:

1. **Early stage disease:** It has a ***limited place*** only with poor prognostic factors as in poorly differentiated tumours, ruptured capsule, or +ve peritoneal wash (even in stage I cases).
2. **Advanced stage disease:** Chemotherapy is indicated in ***all cases*** of stage **II-IV** disease.
   A. As adjuvant therapy in all cases after primary cytoreductive debulking surgery
   B. Palliative therapy in patients with irresectable tumours, or with recurrent disease.

Types of chemotherapy used:

Chemotherapy is usually recommended as soon as possible after surgery, and is given for five or six cycles at 3-4 weekly intervals.

The most frequently used chemotherapeutic agents include: **Cisplatin** or **Carboplatin** alone or in combination with **Paclitaxel** (Taxol).

Toxicity from chemotherapy:

Chemotherapeutic agents are highly toxic at therapeutic doses, and therefore need close monitoring during treatment cycles. Toxicity includes; nausea, vomiting, myalgia and arthralgia. In severe cases renal damage, peripheral neuropathy, hearing loss, dehydration and electrolyte imbalance may occur.

RADIATION THERAPY IN OVARIAN CANCER

Radiation therapy has ***little place*** in epithelial ovarian cancer. It may be used as an adjuvant therapy following cytoreductive surgery in patients who refuse or are not good candidates for chemotherapy, and in some radiosensitive germ cell tumours.

Even in cases of a dysgerminoma in a young age patient in which the tumour is radiosensitive, radiotherapy has been replaced by chemotherapy as fertility is likely to be more preserved in the latter.

- Forms of radiotherapy used:
  1. Intraperitoneal radioactive colloids or
  2. Whole external beam abdominal radiation.

PROGNOSIS IN OVARIAN CANCER

FACTORS AFFECTING PROGNOSIS:

- *Histopathologic type of ovarian cancer;* epithelial ovarian cancers generally carry poorer prognosis than non epithelial ovarian cancer (germ cell and sex cord stromal tumours)
- *Histologic grading of the tumour;* Well differentiated tumours carry the best prognosis, while poorly differentiated and clear cell carcinomas carry the worst prognosis.
- *Stage of ovarian malignancy:* the best prognosis is in stage Ia.
- *Optimal versus suboptimal primary surgery;* (TAH BSO + omentectomy, versus debulking).
- *Response of the tumour to adjuvant therapy*; epithelial tumours show good response to chemotherapy, while germ cell tumours are more radiosensitive).

The 5-year survival rate in epithelial ovarian is estimated to reach; **85-90%** in stage I and up to **80%** in stage II. It then sharply declines to only 15-20% in stage III, and no more than 5% in stage IV disease.

Key points in ovarian cancer

- *Epithelial ovarian cancer is the commonest type of ovarian cancer encountered*
- *Diagnosis is based on history, clinical examination, ultrasound findings, and tumour marker assessment. Other investigations as abdominal US, chest X-ray, C.T. scan, MRI, IVP, Barium follow through, upper and lower endoscopy, are of help in defining the extent of the disease prior to surgery.*
- *Important criteria of malignancy in an ovarian tumour includes; solid or mixed solid and cystic consistency, bilaterality, fixation, presence of ascites and extracystic papillae.*
- *Tumour markers including; CA 125 in epithelial cancers, LDH in dysgerminoma, hCG in malignant teratoma, and AFP in EST, are of help both in diagnosis and in follow up after surgery.*
- *Tumours of stage 1 carry the best prognosis, however unfortunately most ovarian cancers will be diagnose at stage II or III disease, due to the absence of specific symptoms in early disease, leading to a generally poor prognosis.*
- *A staging laparotomy is indicated in every malignant ovarian tumour regardless its clinical staging.*
- *During laparotomy removal of the main tumour bulk is performed together with peritoneal fluid cytology, omentectomy, and Lymph node sampling in order to assess the extent of the disease, the prognosis and the need for adjuvant therapy.*
- *Standard surgical approach entails performing a TAH BSO and Infracolic omentectomy.*
- *Primary cytoreductive surgery in advanced disease aims at removal of maximum tumour bulk leaving tumour residues less then 2.0 cm to facilitate postoperative chemotherapy*
- *The vast majority of malignant ovarian tumours will require adjuvant post operative chemotherapy. Some cases may benefit also from radiotherapy.*
- *Malignant germ cell tumours can be managed conservatively by unilateral salpingo-oophorectomy in cases with stage 1a disease, to preserve fertility, as most tumours are unilateral, occurring in young patients.*

29 IMAGING TECHNIQUES IN GYNAECOLOGY

X-RAY RADIOGRAPHY:

1. Plain X-ray films of the pelvis to diagnose large tumours, calcifications in pelvic tumours, dermoid cyst and renal stones.
2. X-ray chest for:

A. Preoperative assessment B. Diagnose of metastases C. Suspected T.B.

3. I.V.P. (intravenous pyelography) for:

A. Assessment of renal function. B. Diagnosis of urinary stones C. Diagnosis of genito-urinary fistula

4. Hysterosalpingography (HSG)

HYSTEROSALPINGOGRAPHY

This consists of the injection of radio-opaque substance into the uterine cavity & fallopian tubes using a special cannula introduced into the cervical canal & an x-ray film is taken after the injection & another film could be taken after 24 hrs (in case of infertility) to show spill of the dye from the tubes to study tubal & peritoneal factors.

The dye used is either oil soluble e.g. Lipiodol (40% organic iodine in poppy seed oil) or water soluble e.g. Urographin or renographin (in which situation the second film is taken just 20 minutes after removal of the cannula as they are rapidly absorbed)

Timing: during the first week after menstruation

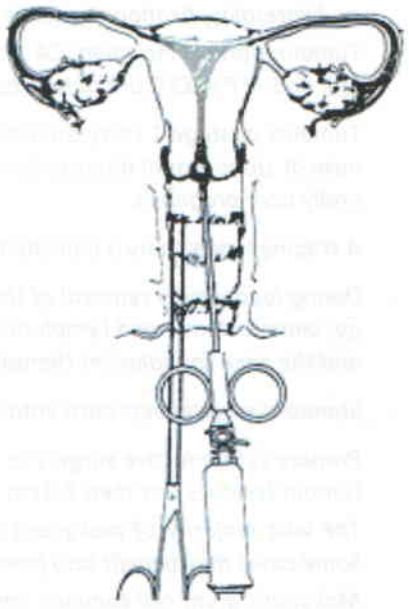

Fig 29-1:

Contraindications:

1. Pelvic infection
2. Suspicion of pregnancy
3. Allergy to iodine
4. During menstruation or uterine bleeding

Indications:

1. Infertility; to study uterine tubal and peritoneal factors.
2. To determine size, shape and anomalies of the uterus.
3. In cases of uterine fibroids to detect a submucous fibroid & to detect condition of the tubes before and after myomectomy.
4. Before & after tubal surgery in cases of infertility
5. Irregular uterine bleeding to exclude organic lesions.
6. Recurrent abortions to determine shape of the isthmus (isthmography) and to detect other possible uterine causes.
7. Study of the uterine scar after a previous C.S.
8. Missed IUCD.
9. Intrauterine adhesions
10. May diagnose pelvic T.B.

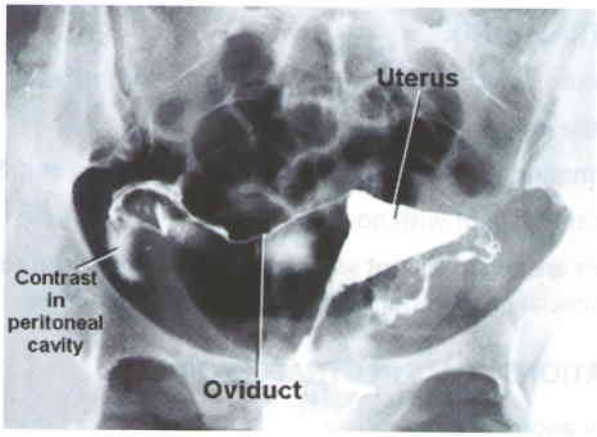

Fig 29-2:

Complications of H.S.G.:

1. Shock.
2. Oil embolism.
3. Disturbance of an undiagnosed pregnancy
4. Flaring up or introduction of infection.
5. Iodine allergic reactions.
6. Intravasation (the oil passes into the uterine vessels during injection which is mainly lymphatic & rarely venous)

NEW IMAGING TECHNIQUES:

The advances in cross-sectional imaging have dramatically changed the practice of gynaecology. Ultrasound, computed tomography (CT) and magnetic resonance imaging (MRI) are tomographic techniques that enable visualisation of organs and tissues previously unseen with standard plain film radiography.

ULTRASOUND:

Normally, the human ear can pick up sounds with a frequency between 20 and 20 thousands hertz (cycle/second). Sounds with a frequency higher than that are termed ultrasound. In medicine we use sounds with high frequencies (more than million cycles/second i.e. Mhz). Ultrasound machines emit sound with high frequency from a part of the machine called the probe (or transducer), which transforms electricity into sound. This emitted sound has 2 properties; penetration and reflection, both of them depends on tissue density, with increased tissue density e.g. bones, penetration will be less and reflection will be more. The reverse will occur with less dense tissues e.g. muscles, fluids etc.

The returning echoes will be perceived by the probe which will transform it into electric impulse which will be analysed by the machine & displayed on the monitor as grades of the grey colour so a view of the different organs studied will be seen (the bones will be seen white, the fluids black while muscles and other tissues in between as different grades of grey). The examination can be done either transabdominally or transvaginally.

Doppler ultrasound is a mode of ultrasound used to study blood flow in different blood vessels.

ADVANTAGES OF ULTRASOUND:

1. Non-invasive procedure, which avoids the ionizing radiations of x-ray.
2. Can be done with little preparation of the patient
3. Can give rapid information which can be interpreted with no great difficulty
4. Can be explained to the patient with no much effort.
5. Ultrasound machines are relatively not so expensive in comparison to other diagnostic machines & needs no special preparations of the place of examination.

DIAGNOSTIC APPLICATIONS OF U.S IN GYNAECOLOGY:

1. Evaluation of genital anomalies.
2. Evaluation of pelvic masses
3. Evaluation of lower abdominal pain & inflammatory processes especially in patients with muscular guarding or rigidity.
4. Monitoring of follicular growth as part of infertility workup.
5. Localisation of I.U.C.D. (either post insertion or in occasions of missed device)
6. Diagnosis of abnormal uterine bleeding
7. Diagnosis and evaluation of uterine fibroids (number, size, site, type, relation to the cavity)
8. Measuring endometrial thickness.
9. Diagnosis of ovarian cysts and neoplasms.
10. Diagnosis of ectopic pregnancy
11. Evaluation of urinary incontinence and residual urine volume.
12. Sonohysterography for tubal patency
13. Can differentiate between benign and malignant conditions with a reasonable degree of efficacy.



Fig 29-3:

POSSIBLE THERAPEUTIC APPLICATIONS OF U/S IN GYNAECOLOGY:

1. U/S-guided follicular aspiration as a part of IVF programs.
2. U/S-guided aspiration of simple cysts
3. U/S- guided drainage of ascites

POSSIBLE USES OF U/S IN OBSTETRICS:

1. During the first trimester:

a. Diagnosis of pregnancy.
b. Exclusion of extrauterine pregnancy
c. Diagnosis of unhealthy pregnancy
d. Determination of number of embryos
e. Determination of gestational age
f. Early diagnosis of some congenital anomalies and some chromosomal abnormalities e.g. Nuchal thickness in Down syndrome
g. Cervical measurements to exclude cervical incompetence
h. Guide for chorionic villous sampling
i. Helpful in conservative management of ectopic pregnancy.

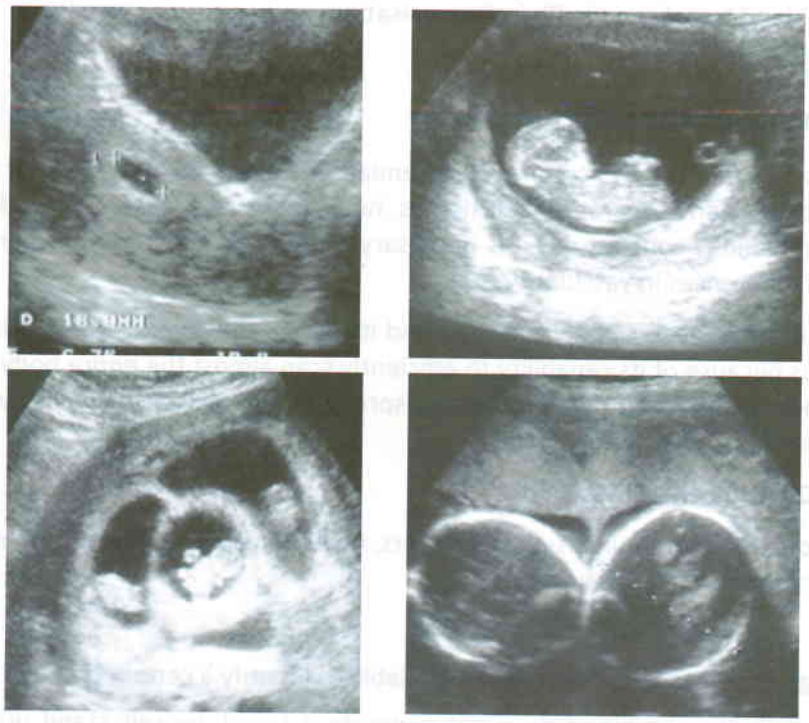

Fig 29-4:

2. Uses of U/S after the first trimester:

a. Diagnosis of multiple pregnancy
b. Diagnosis of lie, presentation & position.
c. To exclude IUFD.
d. Estimation of gestational age
e. Estimation of foetal weight
f. Diagnosis of congenital anomalies
g. Assessment of fetal well-being through biophysical profile (gross fetal movements, breathing movements, tone, and amount of liquor amnii) & through Doppler study of placental, umbilical and fetal BVs
h. Placental location and exclude placental separation (accidental haemorrhage)
i. Amount of liquor amnii
j. Assessment of fetal lung maturity

U/S guided procedures during pregnancy:

1. Chorionic villous sampling
2. Amniocentesis: either diagnostic (chromosomal study - bilirubin level -immunoglobulins in infections ..) Or therapeutic.
3. Cordocentesis.
4. Intrauterine blood transfusion in Rh isoimmunisation .

COMPUTED TOMOGRAPHY (CT)

CT depends on tissue differences in x-ray attenuation. Calcium, water, fat & air having different coefficients are thus clearly separated. Soft tissues, however usually have only subtle density differences, hence intravenous contrast often is necessary to improve separation of normal and abnormal by means of differences in vascularity.

CT is helpful in diagnosis of pelvic masses and its origin. However its main value is to demonstrate metastases because of its capability to efficiently scan almost the entire body so it is useful in staging cancer body, cervix and ovary (assessing spread to the pelvic side walls, lymph nodes and distant metastases)

MAGNETIC RESONANCE IMAGING (MRI)

This technique relies on four tissue parameters; hydrogen content (in fat or water), T1 and T2 (tissue magnetic relaxation times) and blood flow.

Advantages:

1. A wide range of contrast differences are available to identify a certain tissue or disease
2. Because rapidly flowing blood does not generate a signal, vessels stand out from adjacent structures obviating the need for IV contrast administration .
3. MRI is biologically safe because the energies involved are so small

Disadvantages of MRI:

1. The magnetic field used is many times that of the earth's gravity, patients with pacemakers, implanted electronic devices & certain types of cerebral aneurysm clips cannot undergo MRI
2. Long scanning time
3. High cost.

Values of MRI in gynaecology:

1. Differentiating ovarian from uterine masses
2. Evaluation of uterine fibroids to depict the size, number, location, presence of degeneration and large feeding vessels, especially in infertile patients before myomectomy & also to follow response to treatment.
3. Distinguish between uterine myomata and adenomyosis
4. Diagnosis of different uterine developmental variants
5. Diagnosis of uterine hypoplasia
6. Particularly useful in diagnosis of Dermoid cyst & endometriomas (since fat and blood have characteristic appearance on MRI.
7. Used to follow the response of endomtriomas to treatment (after diagnosis & staging by laparoscopy)
8. Pelvic floor assessment with dynamic evaluation
9. Assessment of different pelvic malignancies.

30 ENDOSCOPY IN GYNAECOLOGY

LAPAROSCOPY

Laparoscopy is a procedure which allows direct inspection of the peritoneal cavity and pelvic organs by introduction of an optic lens through the umbilicus after properly insufflating the peritoneum with CO_2 gas. The procedure also allows the performing of variable types of pelvic surgery.

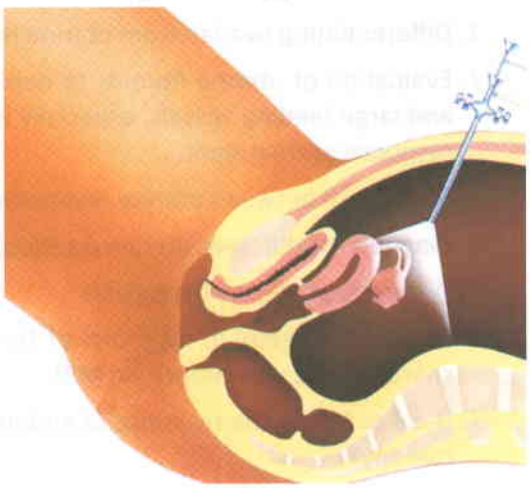

Fig 30-1:

INDICATIONS:

A. Diagnostic laparoscopy:

1. Infertility whether primary or secondary.
2. Chronic pelvic pain.
3. Diagnosis of pelvic endometriosis.
4. Diagnosis of some undiagnosed pelvic masses.
5. Assessment of congenital anomalies of uterus & tubes.
6. Follow up after radical surgery for malignancy.

B. Operative laparoscopy:

1. **Tubal surgery:**
   a. Management of tubal obstruction and adhesion by adhesolysis, salpingostomy , fimbrial dilatation and salpingectomy .
   b. Management of ectopic pregnancy.
   c. Removal of hydrosalpinx or pyosalpinx.
   d. Tubal sterilization.
2. **Ovarian surgery:**
   a. Selective removal of ovarian masses with no or minimal risk for malignancy by cystectomy, ovariotomy or oophorectomy.
   b. Drilling of polycystic ovarian disease in cases resistant to medical treatment.
3. **Uterine surgery:**
   a. Myomectomy for myomas of small number <3 myomas and moderate size < 9 cm.
   b. Hysterectomy whether total or subtotal is feasible in selective cases.
4. **Endometriosis:**
   Variable procedures can be performed including laser ablation, fulguration and diathermy cauterization of endometriotic foci, pelvic adhesiolysis, endometrioma excision and adnexal removal and hysterectomy.
5. **Pelvic floor relaxation.**
6. Some selective **radical procedures** for malignancy.
7. Omental and intestinal **adhesiolysis** to relieve variable degrees of pain resulting from adhesion of previous surgery.

THE PROCEDURE:

Anaesthesia:

General anaesthesia is usually needed; however, diagnostic procedure may occasionally be performed by local anaesthesia associated with adequate sedation and analgesics.

Patient positioning:

The patient is put in a steep; head-down (Trendelenberg) position with the legs semi flexed at the knee level. This allows the abdominal viscera to slip to the upper abdomen giving clear view of the pelvis.

Procedure:

After properly sterilizing the patient and proper drappings, the patient is catheterized using an indwelling catheter and intrauterine manipulating cannula is put in place. The abdomen is inflated using CO_2 through the umbilicus using a thin needle (Verus' needle) to a pressure of 15 mmHg using 3-5 liters of CO_2. An umbilical port is then passed through a 1 cm umbilical incision through which a rigid fibroptic lens connected to a high power light source and a high resolution camera and monitor is passed to the abdomen for proper inspection of the abdomen and pelvis. The abdomen and pelvis are then inspected systemically and patency of the fallopian tubes is tested by injecting suitable amounts of colour dye through the transvaginally inserted intrauterine cannula.

To perform variable types of pelvic surgeries, 2-3 other ports are being made along a line 3 cm above the symphysis pubis, each of these ports are being 1/2-1 cm. A large scope of endoscopic instruments e.g. scissors, graspers, diathermy coagulating instruments, needle holders and morcellators exist for variable procedures.

At the end of procedure, haemostasis is checked, irrigation of the pelvis with lactated ringer solution is done with suction and repeated rinsing. After final inspection the CO_2 is evacuated from the abdomen and all the ports are removed and their entry sites are occluded.

Complications

Laparoscopic surgery is a variant of regular surgery with special features therefore a patient undergoing laparoscopic surgery will be exposed to same complications with a variable degree (more or less), in addition to special risks related to laparoscopy

1. Anaesthetic and cardiopulmonary complications, more especially CO_2 embolism, arrhythmias, gastric reflux, hypotension.
2. Extraperitoneal insufflation due to malposition of insufflation needle will result in cutaneous surgical emphysema.
3. Electrosurgical complication:
   These can result in diathermy burns to important structures such as the bowel, nerves, uterus and blood vessels and may end in fatalities if they are not recognized during surgery.
4. Haemorrhagic complications:
   a. The most serious of these are injuries to the great vessels as the aorta and IVC. This can happen during introduction of insufflation needle or the trocar.
   b. Injury to the cutaneous abdominal wall vessels specially the inferior epigastric.
   c. Injury to an intraperitoneal vessel by any type of surgery.

5. Gastrointestinal complications:
   a. Injury by an insufflations needle or a trocar especially in patients with previous abdominal surgery.
   b. Injury during dissection or by the diathermy current.
6. Urologic injury:
   Injury to the bladder or ureter may happen secondary to mechanical dissection or thermal trauma.
7. Neurological injury:
   Peripheral nerve injury is usually related either to poor positioning of the patient. Nerve injury may also occur as a result of surgical dissection or diathermy injury.
8. Incisional hernia and wound dehiscence
9. Infection: wound infection, crepitus, pelvic cellulites and pelvic abscess are rare happening.

Advantage of operative laparoscopy:

- Minimal hospital stay and early return to work.
- Minimal patient discomfort.
- Minimal patient adhesion and therefore minimal iatrogenic infertility.
- Better cosmetic results.
- Rare wound complications.
- Allow proper inspection and excludes the need for what is called exploratory laparotomy.

HYSTEROSCOPY

The procedure of hysteroscopy entails the introduction of lens inside the uterine cavity through the cervix after distending the uterine cavity with suitable medium (CO_2-saline-glycine 1.5%) to visualize the endometrial cavity and perform variable intrauterine operative procedures.

INDICATIONS:

A. Diagnostic:

1. Infertility. Variable findings may be occasionally found such as polyps, synechiae, submucous myoma, congenital anomalies e.g. septate uterus.
2. Habitual and recurrent abortions.
3. Irregular uterine bleeding.

B. Operative:

1. Polypectomy.
2. Resection of uterine septae.
3. Resection of a submucous myoma.
4. Division of intrauterine synchiae.
5. Removal of a missed IUD.
6. Resection or coagulation of the endometrium.
7. Intrauterine tubal catheterization for corneal obstruction.
8. Sterilization by injecting a sclerosing agent or a plug to the cervix.

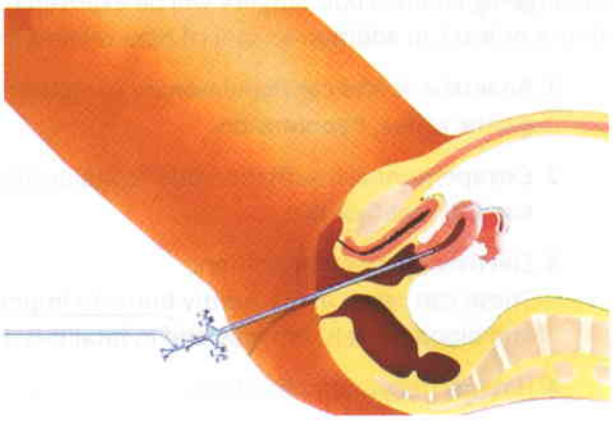

Fig 30-2:

THE PROCEDURE:

1. Place of the procedure
   The procedure can be performed as office procedure unless operative intrauterine surgery may be needed.
2. Position of the patients: Modified dorsal lithotomy position.
3. Anaesthesia
   No anaesthesia, local paracervical block or general anaesthesia may be needed.
4. Cervical dilatation
   For diagnostic procedure; the cervix may be dilated to 4 mm where as for the operative procedure the cervix has to be dilated to 10 mm.
5. Uterine distension:
   For diagnostic procedure; CO_2, saline or glycine 1.5% may be used. However, if electric current is to be used in operative procedure a non conductive medium e.g. glycine 1.5% is a must.
6. Imaging:
   The endoscope is introduced, good illumination must be available together with a camera head transmitting the picture to a suitable monitor.
7. Operative procedures can be performed using cold scissors, electrosurgical equipment or laser equipment.

Complications:

1. Anaesthesia complications.
2. Perforation of the uterus.
3. Bleeding due to myometrial vascular trauma.
4. Thermal trauma to adjacent structures.
5. Complications related to distending media:
   a. CO_2 can result in embolization.
   b. Low viscosity fluids (e.g. glycine 1.5%) can result in fluid overload with serious electrolyte imbalance that rarely may be fatal.

31 DIFFERENTIAL DIAGNOSIS IN GYNAECOLOGY

- Uterine polypi
- Pelvi-abdominal Mass
- Mass in the pouch or douglas
- DD of Pelvic pain

UTERINE POLYPI

A) CORPOREAL POLYPS:

1. Adenomatous Endometrial Polyp:

- *Origin:* from the endometrium, either as a single adenoma or multiple in association with marked endometrial hyperplasia (EH).
- *Symptoms:*
  - Abnormal uterine bleeding AUB: menorrhagia, metrorrhagia, and postcoital bleeding.
  - Leucorrhoea: the polyp may be associated with excessive vaginal discharge.
- *Signs:* if it protrudes through the cervix, speculum examination will reveal the polyp as a tongue like projection, soft in consistency, with a rather flat compressed tip.
- *Diagnosis:* TAS, TVS, SIS, 3D US, and hysteroscopy are all efficient in diagnosis.
  - *Treatment:* polypectomy followed by hormonal treatment. Polypectomy is performed via;
  - Hysteroscopic guided polypectomy (gold standard treatment).
  - Dilatation, Polypectomy, and Curettage (D&C), if hysteroscopy not available
  - N.B.: histopathologic examination of the polyp to confirm diagnosis

2. SMF Polyp:

- *Origin:* from the myometrium of the body of the uterus, as a SMM that attains a pedicle and protrudes into the endometrial cavity
- *Symptoms:* AUB, menorrhagia, metrorrhagia, and foul discharge
- *Signs:* if it protrudes through the cervix, speculum examination will reveal a rounded mass, firm in consistency, with necrosed infected tip and long pedicle
- *Treatment:*
  - Hysteroscopic guided polypectomy is the gold standard treatment.
  - Occasionally a large SMF polyp > 6 cm will require abdominal myomectomy in young patients, or hysterectomy in the perimenopause.

3. Placental Polyp:

- Origin: accumulated blood clots over the surface of a retained placental fragment.
- Symptoms: persistent bleeding after labour or abortion.
- Signs: subinvolution of the uterus, with softer consistency
- Diagnosis: TVS, TAS, SIS, 3D US, and hysteroscopy are all efficient in diagnosis.
- Treatment:
  - Hysteroscopic guided polypectomy is the gold standard treatment
  - D&C polypectomy can be performed if hysteroscopy is not available

N.B.: Microscopic examination should be performed to exclude choriocarcinoma.

4. **Malignant Polyp:**
   - Carcinoma, sarcoma or chorionepithelioma.

B) CERVICAL POLYPI:

1. Mucous Polyp:

- *Origin:* one or more reddish soft polyp seen within the endocervix.
- *Aetiology:* hyperplasia of the endocervical epithelium due to chronic cervicitis.
- *Diagnosis:* speculum examination reveals the lesion by the naked eye, or hysteroscopy.
- *Treatment:* polypectomy followed by treatment of chronic cervicitis.
- *N.*B.: Any polyp removed should be examined histologically to exclude malignancy.

2. **Fibro-Adenomatous Polyp:** It is a mucous polyp in which the stroma is dense and fibrous.

3. **Fibroid Polyp:** Rare and appears as a firm polyp with necrosed tip attached to the cervix by a short pedicle and treated by vaginal polypectomy.

4. **Malignant Polyp:** Either carcinoma, sarcoma or the rare highly malignant grape-like sarcoma of children which, is a mixed cell sarcoma characteri-sed by rapid invasion and formation of grape- like mass of soft pinkish oedematous polyp which fill the upper vagina.

5. **Bilharzia! Papilloma:** Usually develop from the vaginal surface of the cervix. They may be single or multiple, sessile or pedunculated, of variable sizes, firm in consistency, usually rough and covered by intact greyish pink mucous membrane.

D.D. OF PELVI-ABDOMINAL SWELLINGS

A) Uterine Causes

1. Normal pregnancy: (The commonest cause in the reproductive period).

The patient is in the childbearing period with history of amenorrhea, morning sickness and breast' signs. The uterus is soft and intermittent contractions are felt. Detection of the foetal parts or foetal heart sounds are sure signs. Ultrasonography and pregnancy test are diagnostic.

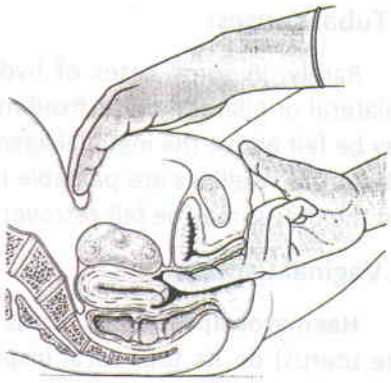

Fig 31-1:

N.B.: Abnormal pregnancy as vesicular mole or hydramnios will alter the clinical picture and should be kept in mind. Ultrasonography helps in the diagnosis.

2. Fibroids:

The patient is usually over 35 years and commonly nullipara. Menorrhagia is the com-monest symptom. The tumour is usually firm with knobby surface, mobile from side to side and not tender and during vaginal examination, movement of the tumour is transmitted to the cervix,

3. Large haematometra:

This occurs due to congenital or acquired atresia at or below the cervix. There are amenorrhea, and abdominal pain recurring every month; but if the condition is neglected, the abdominal pain becomes persistent due to the irritation of the peritoneum by the blood passing through the; Fallopian tubes. The symmetrical swelling felt represents the distended uterus due to the accumulated menstrual blood inside it.

5. Large pyometra:

This occurs due to the presence of uterine infection accompanied by obstruction of the cervical canal. Lower abdominal pain and fever (that may be intermittent) are present. There is intermittent purulent discharge, which stops after a period. There is symmetrical tender, cystic pelvi-abdominal swelling, which represents the distended uterus. The passage of a uterine sound (if possible) will be followed by a discharge of pus.

B) Ovarian Causes:

1. Ovarian cysts and solid ovarian tumours:

Painless central enlargement of the abdomen without any menstrual irregularities. The swelling is cystic or solid in consistency, with smooth or lobulated surface and is mobile. On percussion there is central dull-ness and resonant flanks.

On bimanual examination, the uterus is felt separate from the swelling. Menstrual irregularities are encountered only in functioning tumours.

It may be impossible to differentiate a solid ovarian tumour from pedunculated subserous fibroid. Ultrasonography, CT, and MRI may help in the diagnosis.

2. Malignant ovarian tumour

See clinical picture suggesting malignancy.

C) Tubal Causes:

Rarely, in some cases of hydrosalpinx or pyosalpinx, a unilateral or bilateral cystic fixed mass with ill-defined margin may be felt above the inguinal ligaments. On bimanual examination, the swellings are palpable in the region of the adnexa and the uterus may be felt retroverted and fixed.

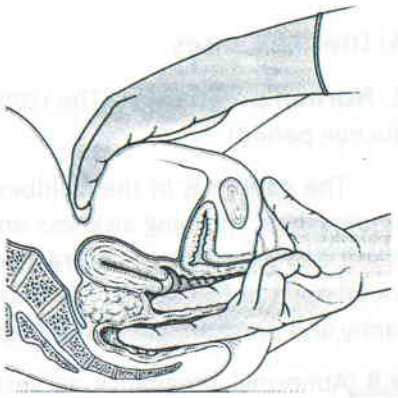

Fig 31-2:

D) Vaginal Causes:

Haematocolpos: Cystic mass with a small firm nodule (the uterus) on its top. Local inspection reveals imperforate hymen or vaginal septum, and rectal examination will detect the cystic mass formed by the distended vagina.

E) Other Extragenital Swellings:

1. **The distended bladder:** The swelling disappears after catheterisation of the bladder.
2. **Large hydronephrosis:** An oval swelling that extends into the loin. It is dull with a band of resonance over it corresponding to the colon. Intravenous pyelography settles the diagnosis.
3. **Mesenteric and pancreatic cysts:** Do not rise from the pelvis and cannot be pushed down into it. There are areas of reso-nance over the mass due to superimposition of the intestine.

4. **Retro-peritoneal tumours:** A fixed swelling, which is resonant on percussion due to the overlying intestine.

N.B.: All pelvi-abdominal swellings must be differentiated from ascites, pseudocyesis, obesity and flatulence which cause abdominal enlargement.

SWELLINGS OF THE BROAD LIGAMENT

1. Broad ligament cyst:

Sometimes it is large enough to be felt per abdomen. The cyst is of limited mobility and bimanually it is lateral to the uterus, which is displaced to the opposite side.

2. Broad ligament haematoma:

This may occur due to rupture of tubal pregnancy in the broad ligament or due to rupture of a varicose vein in the broad ligament or it may occur in cases of incomplete rupture of the uterus where a cervical laceration on either side extends upwards to the part of the lower seg-ment between the two layers of the broad ligament. It may be also due to improper haemostasis after abdominal operations on the pelvic organs especially operations done to remove a broad liga-ment cyst or tumour. There is a cystic swelling to one side of the uterus displacing it to the opposite side, associated with the clinical picture of internal haemorrhage.

CAUSES OF CYSTIC ADNEXAL SWELLINGS

1. Tubal: hydrosalpinx, pyosalpinx and haematosalpinx.

2. Ovarian: non-neoplastic and neo-plastic cysts and haemorrhage in the ovary.

3. Broad ligament: cyst, hematoma or abscess (suppuration of parametritis).

D.D. OF A MASS FELT IN THE POUCH OR DOUGLAS

A) Uterine Masses:

1. Retroverted uterus: The body of the uterus is felt through the posterior fornix continuous with the cervix and moves with it. The external os is directed forwards and upwards.

2. Posterior wall fibroids: The tumour is rounded and firm and moves with the cervix.

B) Tubal Masses:

1. Hydrosalpinx and pyosalpinx: Bilateral, cystic, tender, fixed swellings postero-lateral to the uterus, and the uterus may be retroverted and fixed.

2. Tubal pregnancy: Amenorrhea, pain and bleeding. The uterus is slightly enlarged and soft and pain is felt on one side on moving the cervix. Unilateral, firm, tender swelling is felt postero-lateral to the uterus and pulsations may be felt at the swelling. Aspiration of the pouch of Douglas reveals blood.

C) Ovarian Masses and Swellings:

- Non-neoplastic cysts.
- Small cystic or solid ovarian tumours (benign or malignant).
- Very rarely ovarian ectopic pregnancy (see Obstet-rics).

N.B.: An Ovarian swelling is usually cystic (but may be solid), rounded, mobile (except if it is fixed by adhesions or malignant infiltration), separate from the uterus, and its movement is not transmitted to the cervix.

D) Extra Genital Masses In the Pouch of Douglas:

1. Pelvic haematocele and Pelvic abscess.
2. Encysted tuberculous peritonitis.
3. Nodules felt in the Douglas pouch: May be due to either T.B., endometriosis or secondaries from malignant ovarian tumour.
4. Inflammatory mass as appendicular mass, or peridiverticulitis.
5. Rectal masses; as faecal mass (indentable), endometriosis of the rectovaginal septum, and carcinoma of the rectum.
6. Retroperitoneal tumours; as ectopic kidney.

N.B.: In all cases with a mass felt in the pouch of Douglas do rectal examination to determine the relation of the swelling to the rectal wall

CAUSES OF HAEMATOSALPINX

1. Disturbed tubal pregnancy.
2. Haemorrhage in a hydrosalpinx or pyosalpinx.
3. Some cases of marked acute inflammation of the Fallopian tubes.
4. Endometriosis.
5. Malignant tumours of the Fallopian tube.
6. Congenital cervical atresia and rarely some cases of imperforate hymen or transverse vaginal septum (accumulation of blood causes haematometra then haematosalpinx) .
7. In the very rare cases of torsion of a Fallopian tube.

CAUSES OF SYMMETRICAL ENLARGEMENT OF THE UTERUS

1. Pregnancy
2. Metropathia haemorrhagica
3. Single submucous or single interstitital fundal fibroid
4. Diffuse adenomyosis
5. Subinvolution of the uterus (in the puerperium)
6. Malignant tumours: as adenocarcinoma, sarcoma or choriocarcinoma:
7. Pyometra and haematometra: In pyometra, there is lower abdominal pain and fever. The uterus is, tender and cystic. In haematometra there is amenorrhea, recurrent lower abdominal pain every month, atresia at or below the cervix.

CAUSES OF ENLARGEMENT OF THE CERVIX

1. Chronic cervicitis.
2. Congestion of the cervix (e.g. in pregnancy and prolapse).
3. Congenital elongation of the portio vaginalis.

5. Cervical tumours whether benign (e.g. fibroid) or malignant (e.g. carcinoma).
6. Distension of the cervix by an extruded uterine polyp.
7. Some specific inflammations e.g. tuberculosis, biliarziasis and syphilis.
8. Cervical abortion.
9. Cervical ectopic pregnancy.
10. Endometriosis of the cervix.

D.D. OF A MASS PROTRUDING FROM THE CERVIX

1. Any type of cervical polypi.
2. Uterine and endometrial polypi. The mass is not fixed to the cervix and is hanging by a long pedicle.
3. Inevitable and incomplete abortion.
4. Inversion of the uterus: The uterus is not felt in its normal position and the length of the uterine cavity is reduced when measured by a sound.

GYNAECOLOGICAL CAUSES OF ACUTE ABDOMINAL PAIN

1. Disturbed ectopic pregnancy.
2. Acute salpingitis.
3. Torsion, rupture or haemorrhage in an ovarian cyst.
4. Red degeneration in a fibroid or torsion of a pedunculated subserous fibroid.
5. Haemorrhage in a corpus luteum or rupture of a corpus luteum cyst.

The above mentioned gynaecological causes should be differentiated from the non-gynaecological causes of acute lower abdominal pain e.g. acute appendicitis, acute pyelitis, diverticulitis etc... Acute upper abdominal pain may be due to cholecystitis, pancreatitis etc...

GYNAECOLOGICAL CAUSES OF CHRONIC PELVIC PAIN

1. Chronic pelvic inflammatory disease e.g. chronic salpingo-oophoritis
2. Pelvic adhesions
3. Pelvic endometriosis
4. Displacements e.g. prolapse and fixed retroversion
5. Pelvic con-gestion syndrome (vascular congestion of the uterus and varicosities in the veins of the broad ligament. Careful clinical examination, and special investigations e.g. laparoscopy are needed to reach the diagnosis.

CAUSES OF LOW BACKACHE

(A) Causes in the genital tract:

1. Uterine prolapse (especially in the early stages). The low backache increases towards the end of the day.

2. Some cases of retroversion.
3. Chronic cervicitis.
4. Endometriosis.
5. Impacted tumours in the pelvis or malignant tumours of the genital organs.
6. Pelvic congestion.

Backache caused by gynaecological lesions is characterized by:

1. It is diffuse (cannot be indicated with a finger point).
2. Situated in the mid-line or it is bilateral.
3. Its level is sacral or lumbosacral.
4. No local tenderness.

N.B.: After gynaecological operations with prolonged use of the lithotomy position or after prolonged lying on a flat table with relaxed muscles, the patient may complain of low backache.

(B) Extragenital causes

N.B.: During pregnancy, the patient frequently complains of low backache due to increased lumbar lordosis and relaxation of the ligaments.

CONTACT BLEEDING

It is bleeding following contact of the cervix, for example, after vaginal examination, sexual intercourse or douching.

Causes: It may be due to:

1. Some cases of cervical erosion (especially papillary type as it is usually vascular).
2. Carcinoma of the cervix. .
3. Ulcers of the cervix.
4. Polypi of the cervix.

Investigations:

1. Clinical examination including careful vaginal and speculum examination.
2. Special investigations to exclude early malignancy, as vaginal and cervical smears, Schiller's iodine test, colposcopy and cervical biopsy, which should be done in every case.

Treatment: According to the cause.

UTERINE CASTS

1. **Decidual casts:** Passed in cases of abortion or disturbed tubal pregnancy; but in the latter case, no chorionic villi are detected.
2. **Membranous casts:** in cases of membranous dysmenorrhoea.
3. **Blood casts:** made up of red and white blood corpuscles in fibrinous network, may be passed during severe general infections.

32 OPERATIVE GYNAECOLOGY AND POST OPERATIVE COMPLICATIONS

SOUNDING OF THE UTERUS

The uterine sound is made of malleable metal and its tip is blunt. It is graduated in inches or centimetres. It is slightly curved near the tip so that it can adapt to the angle of uterine flexion.

Before introducing the uterine sound, the uterus is palpated during the bimanual examination, the cervix is exposed by a vaginal speculum and the anterior lip of the cervix is grasped by a volsellum.

The sterile sound is introduced until resistance is felt at the internal os to measure the length of the cervical canal and then it is pushed past the resistance until it reaches the fundus to measure the length of the uterine cavity.



Fig 32-1:

Uses of the uterine sound:

1. Degree of supravaginal elongation of the cervix in cases of prolapse.
2. Diagnosis of uterine hypoplasia (the uterine length is subnormal and there is alteration in the ratio between length of the cervix and body).
3. Measurement of the length of the uterine cavity preliminary to dilatation.
4. Measurement of the uterine length before introduction of I.U.C.D.
5. Diagnosis of the direction of the uterus.
6. Diagnosis of cervical stenosis (inability to introduce the sound).
7. Abnormality inside the uterus as polyp or septum.
8. Differentiation between chronic inversion and fibroid polyp bulging through the cervix. In the latter case, the uterine length is normal.
9. Detection of retained I.U.C.D.
10. Diagnosis of endocervical carcinoma.

Dangers of using the uterine sound:

1. Perforation.
2. Infection.
3. Abortion.

DILATATION OF THE CERVIX

Types of dilators:

1. Hegar: uniform thickness.
2. Fenton: tapers gradually towards the tip.

N.B.: The number of the dilator indicates the diameter in millimetres.

Indications:

A) Dilatation alone:



Fig 32-2:

1. Spasmodic dysmenorrhoea.
2. Cervical stenosis.
3. Drainage of pyometra or haematometra.

B) Dilatation preliminary to another operation:

1. Operations on the cervix: as trachelorrhaphy, amputation (including Fothergill's operation) and cautery in nullipara.
2. Operations on the uterus: as curettage, evacuation, polypectomy and introduction of radium into the uterus.
3. Operations on the tubes: as Rubin test if a large cannula is used.

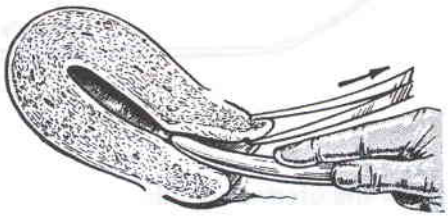

Fig 32-3:

Steps of the operation:

1. *Anaesthesia:* (usually general I.V.or spinal /epidural).
2. *Position:* the patient lies in the lithotomy position.
3. *Asepsis:* the vulva, vagina, and surrounding skin are painted with an antiseptic. Sterile towels are applied leaving the operation area exposed.
4. *The bladder is evacuated* by a catheter.
5. *Bimanual examination* under anesthesia to detect the size, position, shape and consistency of the uterus and also to detect any other abnormality.
6. *The cervix is exposed* by a self-retaining posterior vaginal speculum and the anterior lip is grasped by a volsellum. **(N.B.:** multiple teeth volsellum is less liable to cause cervical laceration than single tooth volsellum).
7. *The cervix is painted* with iodine solution and a sound is passed to determine the length and direction of the uterus.
8. *The cervical canal is gradually dilated* by introduction of the dilators starting with the smallest size (Number 3). The chief resistance will be met at the internal os. The dilator is held like a pencil with the index finger at the supposed length to enter the uterus and steady pressure is applied until the resistance is overcome and the dilator enters the body of the uterus. The slight curve in the dilator should confirm with the direction of the uterus.
9. *Each dilator is left in the uterus for 1 minute* to allow the circular fibres to relax. It is then removed and the next larger size is introduced until the required dilatation is obtained (e.g. No. 8-10 for curettage, and No. 14 in spasmodic dysmenorrhoea and No. 12 before doing amputation of the cervix).

Complications:

1. *Perforation of the uterus* (It is detected when the sound or dilator can be introduced more than the expected length of the uterine cavity. The patient is kept under observation and antibiotics are given, but if there are signs of internal haemorrhage or injury to abdominal organs, laparotomy is necessary.
2. *Lacerations of the cervix* are more liable to occur if the cervix is dilated over number 12, especially if the dilatation is done very rapidly. Severe bleeding if the lacerations extend laterally to involve the cervical branch of uterine artery. Lacerations may become infected leading to chronic cervicitis. Incompetent isthmus and habitual abortion may occur later on.
3. *Infection.*
4. *Shock* is liable to occur if dilatation is carried out without anaesthesia or with improper anaesthesia.
5. *Anaesthetic complications.*

CURETTAGE

Types of curettes:

1. The loop curette: either sharp or blunt or combined. Blunt curette is used in cases of recent pregnancy or suspected malignancy as the uterus is easily perforated.
2. Blunt flushing curette: used to curette the decidua when evacuation is done.
3. Fundal curette: has a tapering tip to curette the fundus and angles.
4. Biopsy curette: used without anaesthesia as its introduction through the cervix needs no dilatation due to its small diameter. It is not used to diagnose diseases or malignancy of the endometrium as it removes only a small strip of endometrium. It is used-to detect the hormonal effect on the endometrium *as* in detection of ovulation and in research purposes.

Indications of curettage:



Fig 32-4:

(A) Diagnostic (endometrial biopsy):

1. Detection of ovulation.
2. Detection of the endometrial pattern in hormonal disorders e.g. amenorrhea
3. To determine the cause of uterine bleeding and to differentiate between dysfunctional bleeding and bleeding due to organic cause.
4. Diagnosis of malignant diseases of the endometrium or endocervix.
5. Diagnosis of diseases of the endometrium as tuberculous endometritis.

(B) Therapeutic:

1. Post-abortive and puerperal bleeding due to retained products.
2. Endometrial and cervical polypi.
3. Dysfunctional uterine bleeding.

Technique of dilatation and curettage:

Under anaesthesia, the cervix is dilated up to No. 10-12 Hegar (see before). The curette is introduced and the whole endometrium is scraped in long strokes from above downwards starting with the anterior than the posterior wall. The fundus, angles and lateral walls are scraped using the fundal curette. Curettage is continued until n grating sensation is felt, and the material obtained is preserved in diluted formaline solution. The cervical canal and uterine cavity are then painted with iodine solution.

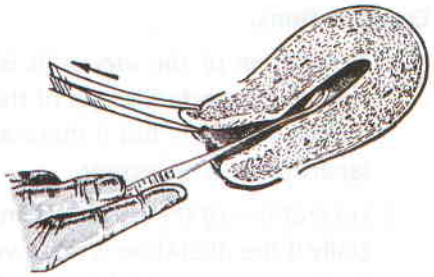

Fig 32-5:

Dangers and complications:

In addition to the dangers of dilatation (see before), a rare complication is overcurettage (specially for a pregnant uterus) leading to permanent amenorrhea due to removal of the basal pans of the endometrial glands or more commonly due to the formation of intrauterine synechiae (adhesions) which is liable 10 occur with heavy curettage specially in the presence of infection (Asherman's syndrome).

Perforation of the uterus during dilatation and curettage

Causes: The uterus may be perforated by the sound, the dilator or the curette. Perforation is more liable to occur if the uterus is soft (pregnancy), friable (malignancy), in cases of pyometra (the uterine wall is thin and the infection makes the uterine wall more liable to be perforated, if the uterine wall is thin (due to postmenopausal atrophy or due to marked distension), or in cases of marked retroversion flexion and acute anteflexia of the uterus (cochleate uterus which is C-shaped with the concavity to the anterior side).

Dangers: Haemorrhage, infection, injury to the intestine or omentum, and rupture of the scar in subsequent pregnancies.

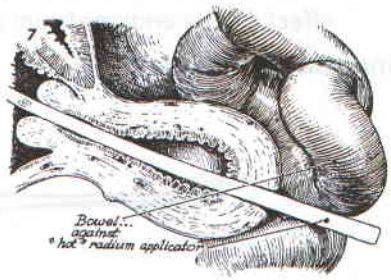

Fig 32-6: Perforation of the uterus

Diagnosis:

1. Sudden release of the resistance
2. Vaginal bleeding
3. The sound or dilator can be introduced more than the expected length of .the uterine cavity
4. If the perforation is very large, the intestine or omentum may be protruded.

Prevention:

1. Pre-operative assessment of the size, direction and consistency of the uterus
2. Measurement of the length of the cervical canal and uterine cavity, before dilatation
3. In cases with marked retroversion-flexion or acute anteflexion, we try to straighten the uterus by applying traction on the cervix with the volsellum
4. Proper holding of the dilator and proper technique of dilatation and avoid the use of great force.

Management:

1. Observation: In the majority of cases the perforation is small and no interference is needed. The operation should be stopped and the patient is observed for the pulse, temperature, blood pressure and evidence of internal haemorrhage. Antibiotics are given.

2. Laparotomy is indicated in the following conditions:

a. If the abdominal contents prolapse through the perforation.

b. In cases of septic abortion or pyometra.

c. In cases of malignancy.

d. If the uterus still contains products of conception (in such cases we may do laparoscopy at first and if the bleeding in the peritoneal cavity is slight, we may continue evacuation of the uterus under laparoscopic vision).

e. If there is evidence of internal haemorrhage.

f. In cases of excessive vaginal bleeding.

g. During laparotomy, the uterus is repaired or removed according to the circumstances. The intestine, omentum and bladder should be inspected for any injury.

HYSTERECTOMY

Hysterectomy may be done abdominally or vaginally. Vaginal hysterectomy is usually done for some cases of uterine prolapse.

Indications of hysterectomy:

(A) Obstetrical:

1. Rupture of the uterus.
2. Uncontrollable postpartum haemorrhage.
3. Couvelaire's uterus.
4. Placenta accreta.

(B) Gynaecological:

1. Inflammatory as some cases of genital tuberculosis.
2. Neoplastic:
   a. Benign: some cases of fibroids and benign ovarian tumours in old patients,
   b. Malignant tumours of the cervix, body and ovaries.
3. Displacements: some cases of uterine prolapse or chronic inversion.
4. Some cases of endometriosis.
5. Some cases of dysfunctional uterine bleeding.

Abdominal hysterectomy (AH)

1. Subtotal AH: We remove the body and leave the cervix. It is usually done in some cases of post-partum haemorrhage and rupture of the uterus, or if there is extensive adhesions around the cervix.
2. Total AH: We remove the body and cervix and it is better than the subtotal.
3. Panhysterectomy: Total hysterectomy and bilateral salpingo-oophorectomy.
4. Radical hysterectomy: Wertheim's operation.
5. Ultraradical hysterectomy: Pelvic excenteration.

In anterior pelvic excenteration, we remove the bladder in addition to the structures removed in Wertheim's operation and we may implant the ureters at various sites e.g. the colon or skin. In posterior excenteration, we remove the rectum and we do colostomy. In total excenteration, we remove the bladder and rectum and we may implant the ureters in the colon before the opening of colostomy.

Advantages of subtotal hysterectomy:

1. It is easier and quicker than total hysterectomy.
2. There is less danger of injuring the ureters and bladder.
3. There is less danger of pelvic infection, as the vagina is not opened.

4. The cervix left behind acts as a support for the vaginal vault.
5. The cervical discharge lubricates the vagina.

Advantages of total hysterectomy:

1. If avoids the risk of carcinoma developing in the cervical stump left after subtotal hysterectomy. The incidence of stump carcinoma is about 1%
2. It provides better drainage of the operation area (through the opened vagina) and therefore there is less risk of a pelvic haematoma developing after the operation.
3. If the cervix is lacerated or infected, the source of irritant discharge is removed. For these reasons total hysterectomy is the operation of choice.

Steps of total abdominal hysterectomy:

- Clamp and cut the round ligament, then the broad ligament on both sides.
- Clamp and cut the infundibulo-pelvic ligament.
- Dissect the bladder downwards.
- Clamp and cut the uterine arteries, then the parametrium on both sides.
- Open the upper vagina and remove the uterus.

N.B.: In subtotal hysterectomy, remove the body leaving the cervix after clamping and cutting the uterine arteries.

Vaginal Hysterectomy

Indications of Vaginal Hysterectomy:

1. Some cases of uterine prolapse or chronic inversion.
2. some cases of (DUB), some cases of small fibroids and occasionally in some cases of cancer body. However, the uterus should be normal in size or only slightly enlarged and is not surrounded by any adhesions.
3. Schauta operation is a radical vaginal hysterectomy, which may be done in cases of cancer cervix, but it has the disadvantage that the lymph nodes cannot be removed.

Advantages of vaginal hysterectomy:

1. Absence of an abdominal scar.
2. Lower incidence of intestinal complications and peritonitis.
3. An associated genital prolapse can be treated at the same time.

Disadvantages:

1. It is unsafe and difficult in the presence of pelvic adhesions.
2. The ovaries cannot be removed in some cases.
3. It cannot be done if the size of the uterus is larger than a 14 weeks pregnant uterus (unless the uterus is bisected before removal).
4. Vault prolapse is more likely to occur than after abdominal hysterectomy.

Steps of vaginal hysterectomy:

Circular incision around the cervix. Dissect the bladder up-wards. Open the peritoneum of the Douglas pouch, and the peritoneum of the vesico-uterine pouch, clamp and cut the Mackenrodt's ligaments, then the Uterine arteries, then the broad ligaments, when the uterus will be removed.

MYOMECTOMY

Myomectomy is the surgical procedure in which myomas are enucleated from their bed in the myometrium, while preserving the whole uterus for further menstruation and childbearing. The procedure is more appropriate for **young** patients, with **infertility** or **low parity**.

Contraindications to Myomectomy:

1. *During pregnancy:* increased uterine vascularity and poor contractility will predispose to excessive bleeding and increased risk for abortion (torsion in a pedunculated SSM is an exception that may call for emergency myomectomy).
2. *After menopause:* myomas that present by increase in size or PMB are highly suspicious for malignancy, in such cases hysterectomy is the only choice whenever surgery is indicated.
3. *Suspicion of sarcomatous changes* (see Complications of leiomyomas)
4. *Multiparous perimenopausal women:* No point for preserving the uterus with chances of recurrence
5. *Multiple huge myomas regardless age and parity;* where myomectomy is difficult and associated with marked blood loss that might endanger the life of the patient.

Types of Myomectomy:

Myomectomy could be performed via the following routes;

- Abdominal Myomectomy
- Vaginal Myomectomy
- Laparoscopic Myomectomy
- Hysteroscopic Myomectomy

A. Abdominal Myomectomy: (The commonest approach)

- Abdominal myomectomy is the operation of choice for *multiple and large leiomyomas*.
- *Laparotomy* may be performed via a transverse suprapubic or longitudinal midline skin incision according to the size, site, and number of myomas to be removed.
- *The anterior rectus sheath* is opened by sharp dissection, the *rectii muscles* separated laterally, and the *peritoneum* is entered by blunt or sharp dissection, with care not to injure intestine.
- *The myometrial incision* is best planned at the midline of anterior uterine wall, according to the site and number of myomas (to avoid injury to the tubes and ovaries, and to avoid postoperative adhesions posteriorly that may interfere with tubal function and oocyte pick up mechanism).
- *Enucleation of myomas:* is performed after cutting through its false capsule (intracapsular).
- *Obliteartion of the tumour bed:* interrupted sutures to avoid haematoma formation.
- *Opening the endometrial cavity* might be necessary for complete removal of a SMF. This can be assessed preoperatively by saline infusion TVS, HSG, or office hysteroscopy.
- *Reconstruction of the uterus* is performed after removal of all myomas
- *Closure of the abdominal wall;* the abdominal wall is finally closed in layers

N.B.: *Opening the uterine cavity in ISM is considered a risk factor for future uterine rupture, and therefore is an indication for caesarean section in subsequent pregnancies.*

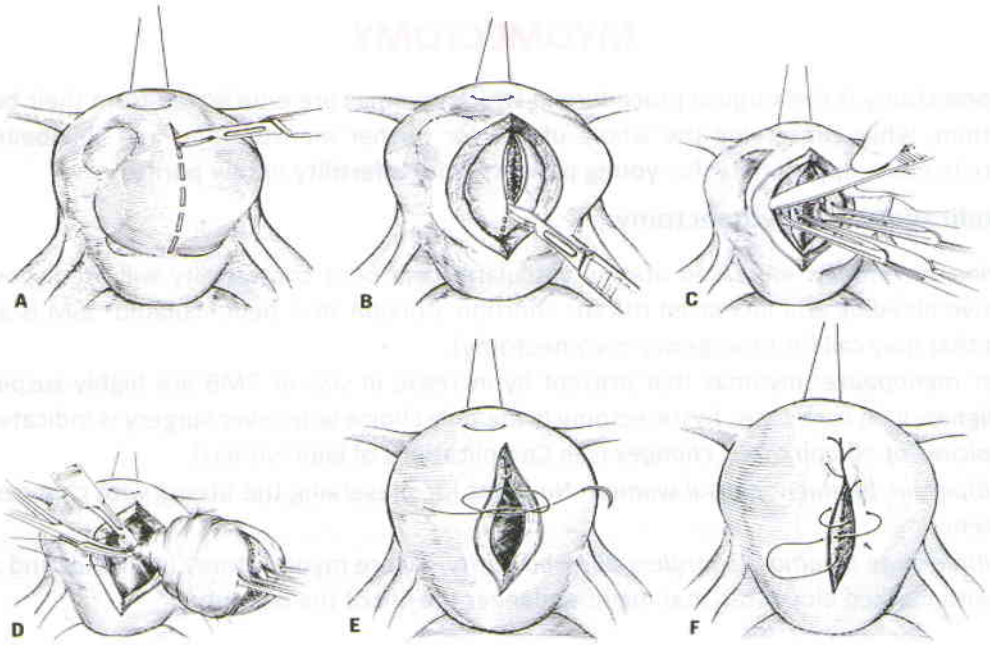

Fig 32-7: Myomectomy

B. Vaginal Myomectomy:

- For pedunculated SMF polyp in the endometrial cavity, or protruding through the cervix.
- The pedicle of the tumour is ligated or coagulated by diathermy.
- Cervical myomas arising from the portio-vaginalis can also be easily removed vaginally.

C. Hysteroscopic Myomectomy:

- For removal of small SMM <5.0 cm diameter which protrude >50% in uterine cavity.
- Diathermy, or laser resection, are better preceded by LH- RH agonist preparation to decrease vascularity and diminish the size of myomas.
- The procedure is associated with minimal pain and bleeding with short recovery.

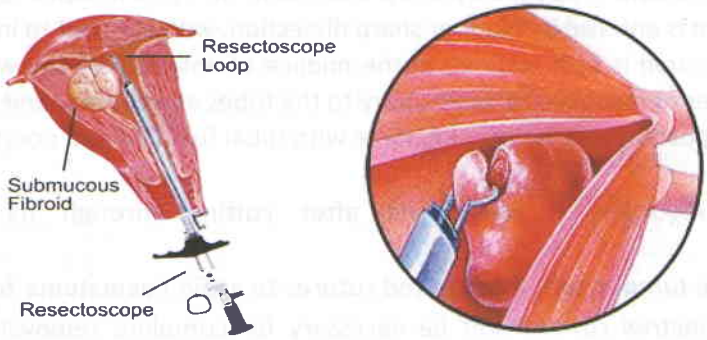

Fig 32-8: Hysteroscopic Myomectomy

D. Laparoscopic Myomectomy:

Myomectomy can be performed via laparoscopy when myomas are limited to <4 in number, < 6 cm in size, mainly SSM (rarely ISM), provided the uterus is < 16 weeks size. It has the advantage of less postoperative pain, shorter and better postoperative recovery period, and the disadvantage of having limited indications, longer operative time, need for advanced instruments and well trained team. It is not proven if it is associated with less postoperative adhesions.

Complications of Myomectomy:

1. Immediate Complications:

- *Excessive blood loss during operation:* due to increased vascularity and inadequate haemostasis. This can be minimized through the use of intra-operative tourniquet (to compress the uterine and ovarian vessels), or injection of intra-myometrial vasopressin (to induce vasoconstriction) or the use of GnRH agonists 3-6 months preoperatively (to induce diminished size and vascularity of myomas).
- *Increased incidence of postoperative* low grade fever, anaemia, pain and ileus.

2. Delayed Complications:

- *Persistent symptoms:* as menorrhagia, dysmenorrhoea, and infertility, especially in cases of large myomas and associated adenomyosis.
- *Recurrence of fibroids:* may occur in up to 27% of cases.
  - More common after removal of multiple and large myomas in younger patients
  - More common in high risk population (dark races, African women, +ve family history)
  - More common with incomplete removal of leiomyomas at primary surgery leaving seadling small myomas to grow by time especially in young patients.
- *Postoperative pelvic and peritubal adhesions:* leading to tubal factor of infertility, and rarely intestinal obstruction.
- *Rupture uterine* scar during labour, or rarely during pregnancy.

POSTOPERATIVE COMPLICATIONS OF ABDOMINAL OPERATIONS (HYSTERECTOMY & MYOMECTOMY)

1. **Shock.**
2. Haemorrhage (primary (reactionary or secondary).
3. Infection, Intestinal complications as acme gastric dilatation, paralytic ileus or adhesions (those lead to vomiting and distension) and Injuries to abdominal organs.
4. Pulmonary complications e.g.: (a) bronchitis, bronchopneumonia or lobar pneumonia. (b) pulmonary collapse, (c) pulmonary embolism (resulting from phlebothrombosis of the deep veins in the calf muscles).
5. Others (depending on the type of the operation) e.g. (a) Venous thrombosis: It may be superficial (occurring in the superficial veins of the lower limbs) OR deep (occurring in the deep veins of the lower limbs e.g. the femoral vein or in the pelvic veins). It may be either phlebothrombosis (without inflammation of the vessel wall) and the thrombus can "be detached easily leading to pulmonary embolism, or thrombophlebitis (associated with inflammation in the vessel wall) and the thrombus is more firmly attached to the vessel wall and less liable to be detached, (b) Wound infection and burst abdomen, (c) Urinary complications e.g. incontinence of urine (which may be due to bladder or ureteric injury, or due to retention with overflow), cystitis, retention of urine, suppression of urine (due to bilateral ligation of ureters or renal failure), (d) Fecal and rectovaginal fistula.
6. Postoperative anaesthetic complications e.g. postoperative cyanosis, postoperative vomiting, pulmonary complications (collapse or infection after inhalation of vomitus).

7. Remote complications e.g.
   a. Complications of the abdominal scar as keloid formation and incisional hernia,
   b. Vaginal discharge due to infection at the vaginal vault.
   c. Vaginal vault prolapse after hysterectomy
   d. Dyspareunia. after hysterectomy (either due to a tender scar in the vaginal vault or an adherent ovary to the vaginal vault.
   e. Low backache either due to prolonged lying on a flat table during the operation or due to persistent chronic pelvic cellulitis.
   f. Menopausal symptoms following bilateral oophorectomy in a young patient.

CAUSES OF POST-OPERATIVE VOMITING

1. Effect of anaesthesia. 2. Acute gastric dilatation. 3. Paralytic ileus.

4. Peritonitis. 5. Intestinal obstruction.

Treatment of No. (2), (3), (4), (5) is by adequate fluid and electrolyte replacement, continuous suction by Ryle tube in No. (2) and Miller Abott tube in the rest, antibiotics if there is infection, and laparotomy and dealing with the cause in No.(5).

CAUSES OF POST-OPERATIVE DISTENSION

1. Mild distension may occur on the 2nd post-operative day.

2. Acute gastric dilatation. 3. Paralytic ileus.

4. Peritonitis. 5. Intestinal obstruction.

POSTOPERATIVE THROMBO-EMBOLISM

Femoropopliteal or calf deep venous thrombosis may occur after major gynaecological operations. The risk increases with age, presence of malignancy, use of oral contraceptives, prolonged bed rest, obesity, varicose veins and it is higher with abdominal rather than vaginal operations. A detached thrombus results in pulmonary embolism.

Diagnosis: Local pain, leg swelling, rise of temperature, local tenderness, use of local Doppler ultrasound, radioisotope labelled fibrinogen and ascending venogram.

Prophylaxis: Subcutaneous heparin 5000 units 2 hours before surgery and then repeated 12 -hourly unit the patient is mobile.

Treatment: Heparin 10000 units I.V. every 6 hours for 48 hours, with 10 mg warfarin in the 1st day and 5 mg in the 2nd day. Subsequently the daily dose of warfarin is adjusted according to the prothrombin time. Patients who develop recurrent non-fatal pulmonary embolism are treated by placement of inferior vena cava filter or by ligation of the inferior vena cava.

POSOPERATIVE HAEMORRHAGE AFTER VAGINAL SURGERY

I. Primary Haemorrhage

Occurs during the operation. Either due to bad surgical technique or bad choice of patient (presence of local infection causing hyperaemia and con-gestion) or bad choice of timing of operation (presence of unsuspected pre-gnancy or operating in the premenstrual period). Treatment is mainly pro-phylactic.

II. Reactionary Haemorrahge

After operation, when the effect of the anaesthetic goes off, the blood pressure is raised and returns to its original pre-operative level. If a vessel is left unligatured or loosely ligatured, is going to bleed. This type of haemorrhage occurs within the first 24 hours after the operation, that is why routine vaginal packing for 24 h. (to cover the period of possi-ble reactionary haemorrhage) is highly recommended. If it occurs treat shock, if present, at first, then transfer the patient to the theatre, suture any bleeding vessel then insert a tight vaginal pack.

III. Secondary Haemorrhage

This occurs on the 10th post operative day due to sepsis. Sepsis might have been present pre-operatively (trophic ulcer), induced during the opera-tion (septic instruments), or sepsis resulted after the operation (septic dressings). If occurs, treat shock and then transfer the patient to theatre. Do not take any sutures in the friable septic tissues as this will encourage further bleeding. Do im-mediate tight vaginal pack and give parenteral broad spectrum anti-biotics.










Publisher
University Book Centre
SAYED MAHMOUD
103 Matahaf El Manyal, Cairo
Tel: 002 - 01091111168 - 01223698600