12 A 5-year-old boy has a history of recurrent urinary tract infections. Urine cultures have grown *Escherichia coli, Proteus mirabilis,* and *Enterococcus.* Physical examination now shows an abnormal constricted opening of the urethra on the ventral aspect of the penis, 1.5 cm from the tip of the glans penis. There also is a cryptorchid testis on the right and an inguinal hernia on the left. What term best describes the child's penile abnormality?

A Balanitis
B Bowen disease
C Epispadias
D Hypospadias
E Phimosis

13 A 19-year-old man has worsening local pain and irritation with difficult urination over the past 3 years. He has become more sexually active during the past year and describes his erections as painful. Physical examination shows that he is not circumcised. The prepuce (foreskin) cannot be easily retracted over the glans penis. What is the most likely diagnosis?

A Bowenoid papulosis
B Epispadias
C Genital candidiasis
D Paraphimosis
E Phimosis

14 A 46-year-old man with a history of poorly controlled diabetes mellitus has had painful, erosive, markedly pruritic lesions on the glans penis, scrotum, and inguinal regions of the skin for the past 2 months. Physical examination shows irregular, shallow, 1- to 4-cm erythematous ulcerations. Scrapings of the lesions are examined under the microscope. Which of the following microscopic findings in the scrapings is most likely to be reported?

A Atypical cells with hyperchromatic nuclei
B Budding cells with pseudohyphae
C Eggs and excrement of mites
D Enlarged cells with intranuclear inclusions
E Spirochetes under dark-field examination

15 A 23-year-old, sexually active man has been treated for *Neisseria gonorrhoeae* infection 6 times during the past 5 years. He now comes to the physician because of the increasing number and size of warty lesions slowly enlarging on his external genitalia during the past year. On physical examination, there are multiple 1- to 3-mm sessile, nonulcerated, papillary excrescences over the inner surface of the penile prepuce. These lesions are excised, but 2 years later, similar lesions appear. Which of the following conditions most likely predisposed him to development of these recurrent lesions?

A *Candida albicans* infection
B Circumcision
C Human papillomavirus infection
D *Neisseria gonorrhoeae* infection
E Paraphimosis
F Phimosis

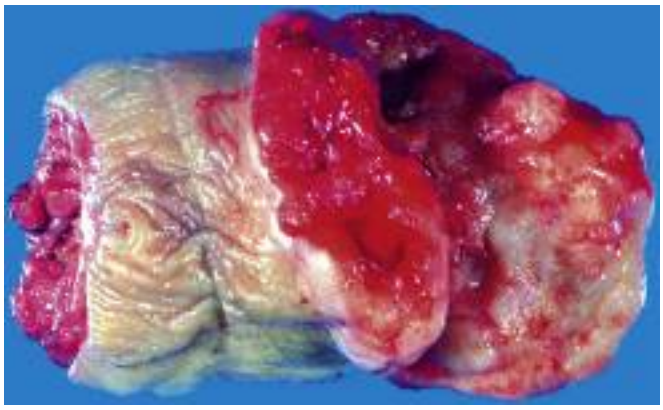

16 A 56-year-old man from Fortaleza, Brazil, has noted increasing size of a penile lesion for the past 18 months. Physical examination reveals the appearance shown in the figure, following resection. What is most likely to be seen on microscopic examination?

A Acute and chronic inflammation with budding cells and pseudohyphae
B Dysplastic urothelium above the basement membrane
C Hyperkeratotic, acanthotic, squamous epithelium overlying ectatic blood vessels
D Infiltrating, pleomorphic, poorly differentiated squamous cells
E Invasive glands with tall columnar mucinous epithelium

17 A 48-year-old man has noticed a reddish area on the penis for the past 3 months. On physical examination, there is a solitary 0.8-cm, plaquelike, erythematous area on the distal shaft of the penis. A routine microbiologic culture with a Gram-stained smear of the lesion shows normal skin flora. Microscopic examination of a biopsy specimen of the lesion shows dysplasia involving the full thickness of the epithelium. What is the most likely diagnosis?

A Balanitis
B Bowen disease
C Condyloma acuminatum
D Primary syphilis
E Soft chancre

18 An 18-year-old man comes to his physician for a routine health maintenance examination. On physical examination, there is no left testis palpable in the scrotum. The patient is healthy, has had no major illnesses, and has normal sexual function. Which of the following complications will you tell this man is most likely to occur?

A Carcinoma
B Heritability
C Infection
D Infertility
E No sequelae

tahir99 - UnitedVRG
vip.persianss.ir

19 A 64-year-old man noted pain with burning on urination a week ago. He has had discomfort in his scrotum for the past 2 days. On examination, the right testis is swollen and tender. Which of the following organisms is most likely to cause this man's illness?

A *Escherichia coli*
B Human papillomavirus
C Mumps virus
D *Mycobacterium tuberculosis*
E *Treponema pallidum*

20 A 36-year-old man and his 33-year-old wife have tried to conceive a child for 12 years, and now they are undergoing an infertility work-up. On physical examination, neither spouse has any remarkable findings. Laboratory studies show that the man has a sperm count in the low-normal range. On microscopic examination of the seminal fluid, the sperm have a normal morphologic appearance. A testicular biopsy is done. The biopsy specimen shows patchy atrophy of seminiferous tubules, but the remaining tubules show active spermatogenesis. Which of the following disorders is the most likely cause of his findings?

A Failure of normal testicular descent
B Hydrocele formation with compression
C Klinefelter syndrome
D Past mumps virus infection
E Prior radiation exposure



21 A 23-year-old, previously healthy man suddenly develops severe pain in the scrotum. The pain continues unabated for 6 hours, and he goes to the emergency department. On physical examination, he is afebrile. There is exquisite tenderness of a slightly enlarged right testis, but there are no other remarkable findings. The gross appearance of the right testis is shown in the figure. Which of the following conditions is most likely to cause these findings?

A Hemorrhagic choriocarcinoma
B Lymphatic obstruction
C Mycobacterial infection
D Obstruction of blood flow
E Previous vasectomy

22 A 33-year-old man has noted asymmetric enlargement of the scrotum over the past 4 months. On physical examination, the right testis is twice its normal size and has increased tenderness to palpation. The right testis is biopsied. The epididymis and the upper aspect of the right testis have extensive granulomatous inflammation with epithelioid cells, Langhans giant cells, and caseous necrosis. Which of the following infections is the most likely cause of these findings?

A Chancroid
B Gonorrhea
C Mumps
D Syphilis
E Tuberculosis

23 A study of testicular carcinomas in adults is performed. These neoplasms have a high frequency of karyotypic abnormalities, particularly i(12p). Pathologic findings include focal intratubular germ cell neoplasia adjacent to the malignancies. Which of the following is the most likely risk factor for these carcinomas?

A Gonadal dysgenesis
B Human papillomavirus infection
C Hydrocele
D Syphilis
E Torsion



24 A 29-year-old man complains of a vague feeling of painless heaviness in the scrotum for the past 5 months. He is otherwise healthy. Physical examination shows that the right testis is slightly larger than the left testis. An ultrasound scan shows a solid, circumscribed, 1.5-cm mass in the body of the right testis. The representative gross appearance of the mass is shown in the figure. A biopsy is done, and microscopic examination of the mass shows uniform nests of cells with distinct cell borders, glycogen-rich cytoplasm, and round nuclei with prominent nucleoli. There are aggregates of lymphocytes between these nests of cells. Which of the following features is most characteristic of this lesion?

A Association with 46,X(fra)Y karyotype
B Association with 46,XXY karyotype
C Response to radiation therapy
D Extensive pulmonary metastases
E Elevation of human chorionic gonadotropin level
F Elevation of α-fetoprotein level

tahir99 - UnitedVRG
vip.persianss.ir

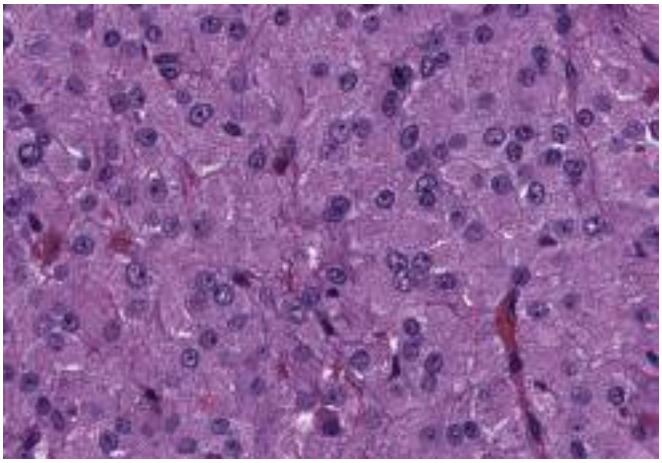

25 A 37-year-old man has noticed bilateral breast enlargement over the past 6 months. On physical examination, both breasts are enlarged without masses. His right testis is firm and 1.5 times larger than his left testis. His serum estrogen is increased. An ultrasound scan shows a circumscribed 2-cm mass in the body of the right testis. A right orchiectomy is performed, and grossly the mass has a uniform, brown cut surface. The microscopic appearance is shown in the figure. With electron microscopy the cells have rod-shaped crystalloids of Reinke. What is the most likely diagnosis?

A Choriocarcinoma
B Embryonal carcinoma
C Gonadoblastoma
D Leydig cell tumor
E Seminoma
F Teratoma
G Yolk sac tumor

26 A 28-year-old man has noticed increasing enlargement and a feeling of heaviness in his scrotum for the past year. On physical examination, the right testis is twice its normal size, and it is firm and slightly tender. An ultrasound examination shows a 3.5-cm solid right testicular mass. Abdominal CT scan shows enlargement of the para-aortic lymph nodes. Multiple lung nodules are seen on a chest radiograph. Laboratory findings include markedly increased serum levels of chorionic gonadotropin and α-fetoprotein. Which of the following neoplasms is the most likely diagnosis?

A Choriocarcinoma
B Large diffuse B-cell lymphoma
C Leydig cell tumor
D Metastatic prostatic adenocarcinoma
E Mixed germ cell tumor
F Pure spermatocytic seminoma

27 A 32-year-old man has noticed an increased feeling of heaviness in his scrotum for the past 10 months. On physical examination, the left testis is three times the size of the right testis and is firm on palpation. An ultrasound scan shows a 6-cm solid mass within the body of the left testis. Laboratory studies include an elevated serum α-fetoprotein level. Which of the following cellular components is most likely to be present in this mass?

A Cytotrophoblasts
B Embryonal carcinoma cells
C Leydig cells
D Lymphoblasts
E Seminoma cells
F Yolk sac cells

28 A 26-year-old man has occasionally felt pain in the scrotum for the past 3 months. On physical examination, the right testis is more tender than the left, but does not appear to be enlarged. An ultrasound scan shows a 1.5-cm mass within the right testis. A right orchiectomy is performed, and gross examination shows the mass to be hemorrhagic and soft. A retroperitoneal lymph node dissection is done. In sections of the lymph nodes, a neoplasm is found with extensive necrosis and hemorrhage. Microscopic examination shows that areas of viable tumor are composed of cuboidal cells intermingled with large eosinophilic syncytial cells containing multiple dark, pleomorphic nuclei. Immunohistochemical staining of syncytial cells is most likely to be positive for which of the following?

A α-Fetoprotein
B Carcinoembryonic antigen
C CD20
D Human chorionic gonadotropin
E Testosterone
F Vimentin

29 The mother of a 2-year-old boy notices that he has had increasing asymmetric enlargement of the scrotum over the past 6 months. On physical examination, there is a well-circumscribed, 2.5-cm mass in the left testis. A left orchiectomy is performed, and histologic examination of this mass shows sheets of cells and ill-defined glands composed of cuboidal cells, some of which contain eosinophilic hyaline globules. Microcysts and primitive glomeruloid structures also are seen. Immunohistochemical staining shows α-fetoprotein (AFP) in the cytoplasm of the neoplastic cells. What is the most likely diagnosis?

A Choriocarcinoma
B Leydig cell tumor
C Seminoma
D Teratoma
E Yolk sac tumor

30 A 32-year-old man has noticed increased heaviness with enlargement of the scrotum over the past 9 months. On physical examination, there is an enlarged, firm left testis, but no other remarkable findings. An ultrasound scan shows a 5-cm solid mass within the body of the left testis. An orchiectomy of the left testis is performed. Microscopic examination of the mass shows areas of mature cartilage, keratinizing squamous epithelium, and colonic glandular epithelium. Laboratory findings include elevated levels of serum human chorionic gonadotropin (hCG) and α-fetoprotein (AFP). Despite the appearance of the cells in the tumor, the surgeon tells the patient that he probably has a malignant testicular tumor. The surgeon's conclusion is most likely based on which of the following factors?

A Age of the patient at diagnosis
B Elevation of hCG and AFP levels
C Location of the mass in the left testis
D Presence of colonic glandular epithelium
E Size of the tumor

tahir99 - UnitedVRG
vip.persianss.ir

31 A 59-year-old man notices gradual enlargement of the scrotum over the course of 1 year. The growth is not painful, but produces a sensation of heaviness. He has no problems with sexual function. Physical examination shows no lesions of the overlying scrotal skin and no obvious masses, but the scrotum is enlarged, boggy, and soft bilaterally. The transillumination test result is positive. What is the most likely diagnosis?

A Elephantiasis
B Hydrocele
C Orchitis
D Seminoma
E Varicocele

32 A 54-year-old man has had dysuria with increased frequency and urgency of urination for the past 6 months. He has sometimes experienced mild lower back pain. On physical examination, he is afebrile. There is no costovertebral angle tenderness. The prostate gland feels normal in size; no nodules are palpable. Laboratory studies show that expressed prostatic secretions contain 30 leukocytes per high-power field. What is the most likely diagnosis?

A Acute bacterial prostatitis
B Chronic abacterial prostatitis
C Prostatic adenocarcinoma
D Prostatic hyperplasia
E Syphilitic prostatitis

33 A 65-year-old man has had multiple, recurrent urinary tract infections for the past year. *Escherichia coli* and streptococcal organisms have been cultured from his urine during these episodes, with bacterial counts of more than 10^5/mL. He has difficulty with urination, including starting and stopping the urinary stream. Over the past week, he has again developed burning pain with urination. Urinalysis now shows a pH of 6.5, and specific gravity of 1.020. No blood or protein is present in the urine. Tests for leukocyte esterase and nitrite are positive. Microscopic examination of the urine shows numerous WBCs and a few WBC casts. Which of the following is the most likely condition predisposing him to recurrent infections?

A Epispadias
B Nodular prostatic hyperplasia
C Phimosis
D Posterior urethral valves
E Prostatic adenocarcinoma
F Vesicoureteral reflux

34 A clinical trial of two pharmacologic agents compares one agent that inhibits 5α-reductase and diminishes dihydrotestosterone (DHT) synthesis in the prostate with another agent that acts as an α_1-adrenergic receptor blocker. The subjects are 40 to 80 years old. The study will determine whether symptoms of prostate disease are ameliorated in the individuals who take these drugs. Which of the following diseases of the prostate is most likely to benefit from one or both of these drugs?

A Acute prostatitis
B Adenocarcinoma
D Chronic prostatitis
C Leiomyoma
E Nodular hyperplasia

35 A 72-year-old man has had increasing difficulty with urination for the past 10 years. He now has to get up several times each night because of a feeling of urgency, but each time the urine volume is not great. He has difficulty starting and stopping urination. On physical examination, the prostate is enlarged to twice its normal size, but is not tender to palpation. One year ago, his serum prostate-specific antigen (PSA) level was 6 ng/mL, and it is still at that level when retested. Which of the following drugs is most likely to be effective in treatment of this man?

A Estrogen (hormone)
B Finasteride (5α-reductase inhibitor)
C Mitoxantrone (chemotherapy agent)
D Nitrofurantoin (antibiotic)
E Prednisone (corticosteroid)

36 A 71-year-old, previously healthy man comes to his physician for a routine health examination. On palpation, there is a nodule in his normal-sized prostate. Laboratory studies show a serum prostate-specific antigen (PSA) level of 17 ng/mL. A routine urinalysis shows no abnormalities. Which of the following histologic findings is most likely to be found in a subsequent biopsy specimen of his prostate?

A Acute prostatitis
B Adenocarcinoma
C Chronic abacterial prostatitis
D Nodular hyperplasia
E Prostatic intraepithelial neoplasia

37 An 85-year-old man has experienced urinary hesitancy and nocturia for the past year. He has had increasing back pain for the past 6 months. On digital rectal examination, there is a hard, irregular prostate gland. A bone scan shows increased areas of uptake in the thoracic and lumbar vertebrae. Laboratory studies show a serum alkaline phosphatase level of 300 U/L, and serum prostate-specific antigen (PSA) level of 72 ng/mL. The blood urea nitrogen concentration is 44 mg/dL, and the serum creatinine level is 3.8 mg/dL. Transrectal biopsy specimens of all lobes of the prostate are obtained. Microscopic examination shows that more than 90% of the tissue has a pattern of cords and sheets of cells with hyperchromatic pleomorphic nuclei, prominent nuclei, and scant cytoplasm. Which of the following is the best classification for this patient's disease?

	Stage	Gleason Grade
A	A	1, 1
B	B	2, 2
C	B	3, 3
D	C	4, 4
E	D	5, 5

tahir99 - UnitedVRG
vip.persianss.ir

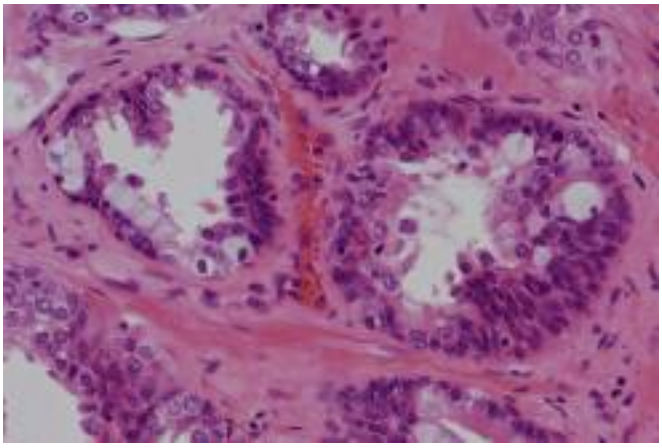

38 A 71-year-old African American man visits his physician for a checkup because he is worried about his family history of prostate cancer. Physical examination does not indicate any abnormalities. Because of the patient's age and family history, his prostate-specific antigen (PSA) level is measured and is 8 ng/mL. Six months later, the PSA level is 10 ng/mL. A urologist obtains transrectal biopsy specimens, and microscopic examination shows multifocal areas of glandular hyperplasia and the appearance shown in the figure. Which of the following statements applies best to this clinical and pathologic scenario?

A Associated with increased risk for invasive cancer
B Chronic inflammation from urinary tract obstruction
C Normal microscopic finding of the peripheral zone
D Related to an inherited tumor suppressor gene mutation
E Responsive to 5α-reductase inhibitor therapy

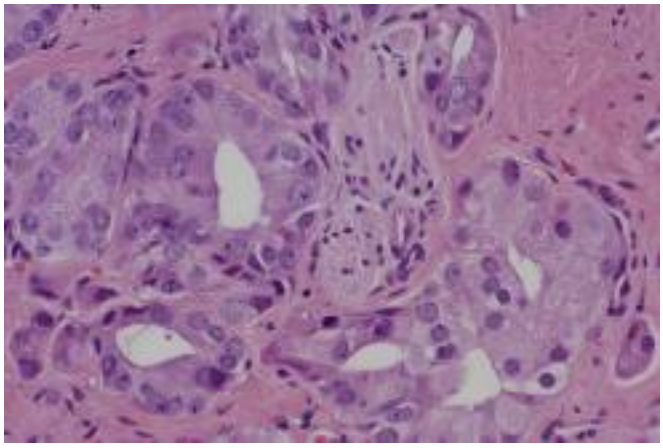

39 A 45-year-old man comes to the physician for a routine health maintenance examination. On physical examination, there are no remarkable findings. Laboratory findings include serum creatinine, 1.1 mg/dL; urea nitrogen, 17 mg/dL; glucose, 76 mg/dL; alkaline phosphatase, 89 U/L; and prostate-specific antigen (PSA), 16 ng/mL. Prostate biopsies are performed and the high power microscopic appearance of a biopsy specimen is shown in the figure. Which of the following is the most likely risk factor for his disease?

A Epigenetic hypermethylation of *GSTP1* gene
B Exposure to naphthylamine compounds
C Overproduction of dihydrotestosterone
D Prolonged use of smoking tobacco
E Recurrent bacterial urinary tract infections

tahir99 - UnitedVRG
vip.persianss.ir

CHAPTER

22 Female Genital Tract

PBD9 Chapter 22 and PBD8 Chapter 22: The Female Genital Tract

BP9 Chapter 18 and BP8 Chapter 19: Female Genital System and Breast

1 A 31-year-old, sexually active woman has had a mucopurulent vaginal discharge for 1 week. On pelvic examination, the cervix appears reddened around the os, but no erosions or mass lesions are present. A Pap smear shows numerous neutrophils, but no dysplastic cells. A cervical biopsy specimen shows marked follicular cervicitis. Which of the following infectious agents is most likely to produce these findings?

A *Candida albicans*
B *Chlamydia trachomatis*
C *Gardnerella vaginalis*
D Herpes simplex virus
E Human papillomavirus
F *Neisseria gonorrhoeae*
G *Trichomonas vaginalis*

2 A 31-year-old woman has had vulvar pruritus along with a thick, whitish, odorless, globular vaginal discharge for the past week. On pelvic examination, the cervix appears erythematous, but there are no erosions or masses. A Pap smear shows budding cells and pseudohyphae. No dysplastic cells are present. Which of the following infectious agents is most likely to produce these findings?

A *Candida albicans*
B *Chlamydia trachomatis*
C *Neisseria gonorrhoeae*
D *Trichomonas vaginalis*
E *Ureaplasma urealyticum*

3 A 17-year-old sexually active girl has had pelvic pain for 1 week. A pelvic examination shows mild erythema of the ectocervix and pain on palpation of right adnexa. A Pap smear shows many neutrophils, but no dysplastic cells. A cervical culture grows *Neisseria gonorrhoeae.* If the infection is not adequately treated, she will be at increased risk for which of the following complications?

A Cervical carcinoma
B Dysfunctional uterine bleeding
C Ectopic pregnancy
D Endometrial hyperplasia
E Endometriosis
F Placenta previa

4 A 25-year-old woman has experienced discomfort during sexual intercourse for the past month. On physical examination, there are no lesions of the external genitalia. Pelvic examination shows a focal area of swelling on the left posterolateral inner labium that is very tender on palpation. A 3-cm cystic lesion filled with purulent exudate is excised. In which of the following structures is this lesion most likely to develop?

A Bartholin gland
B Gartner duct
C Hair follicle
D Urogenital diaphragm
E Vestibular bulb

5 A 53-year-old postmenopausal woman is concerned about pale areas on her labia that have been slowly enlarging for the past year. The areas cause discomfort and become easily irritated. Physical examination shows pale gray to parchment-like areas of skin that involve most of the labia majora, labia minora, and introitus. The introitus is narrowed. A biopsy specimen is taken and microscopically shows thinning of the squamous epithelium, a dense band of upper dermal hyaline collagen, and scattered upper dermal mononuclear inflammatory cells. What is the most likely diagnosis?

A Extramammary Paget disease
B Human papillomavirus infection
C Lichen sclerosus et atrophicus
D Pelvic inflammatory disease
E Vulvar intraepithelial neoplasia

6 A 40-year-old woman has noted pruritic patches on her vulva for the past 4 months. On physical examination there are multiple 1.5- to 3-cm white, scaly plaques on the vulva. A biopsy of one lesion is taken, and on microscopic examination, it shows epidermal thickening with hyperkeratosis and intense dermal inflammation. Mitoses are seen in keratinocytes, but they exhibit no atypia. What is the most likely diagnosis?

A Condyloma acuminatum
B Contact dermatitis
C Psoriasis
D Squamous cell hyperplasia
E Vulvar intraepithelial neoplasia

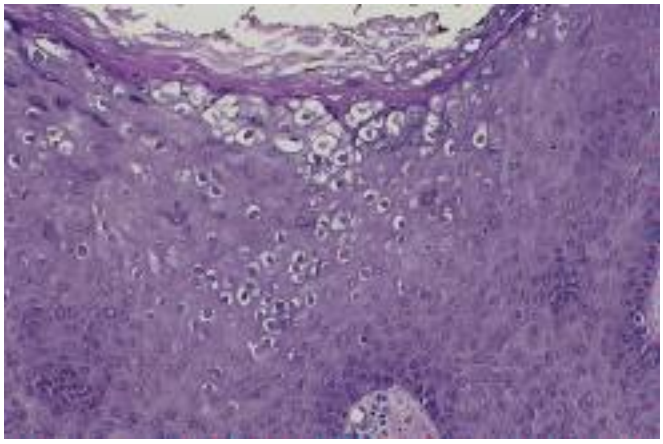

7 A 36-year-old sexually active woman has noticed that warty vulvar lesions have been increasing in size and number over the past 5 years. On physical examination, there are multiple 0.5- to 2-cm, red-pink, flattened lesions with rough surfaces present on the vulva and perineum. One of the larger lesions is excised; its microscopic appearance is shown in the figure. Which of the following infectious agents is most likely to produce these lesions?

A *Candida albicans*
B *Chlamydia trachomatis*
C *Haemophilus ducreyi*
D Human papillomavirus
E *Treponema pallidum*

8 A 57-year-old woman recently noticed a pale area of discoloration on the labia. Pelvic examination shows the presence of a 0.7-cm flat, white area on the right labia majora. A biopsy specimen is obtained and on microscopic examination shows dysplastic cells that occupy half the thickness of the squamous epithelium, with minimal underlying chronic inflammation. In situ hybridization shows human papillomavirus type 16 DNA in the epithelial cells. What is the most likely diagnosis?

A Chronic vulvitis
B Condyloma acuminatum
C Lichen sclerosus et atrophicus
D Squamous hyperplasia
E Vulvar intraepithelial neoplasia

9 A 52-year-old woman has noted increasing size of a red, pruritic lesion on her left labium over the past 7 months. On physical examination, this rough, scaly lesion is 0.4 × 0.9 cm. The perineum appears normal; there is no lymphadenopathy, and there are no rectal lesions. A Pap smear shows no abnormal findings. The lesion is excised and on microscopic examination shows large atypical cells lying singly or in small clusters within the epidermis. These cells have abundant cytoplasm that stains with periodic acid–Schiff (PAS). What is the most likely diagnosis?

A Condylomata acuminata
B Extramammary Paget disease
C Lichen sclerosus et atrophicus
D Lichen simplex chronicus
E Vulvar intraepithelial neoplasia

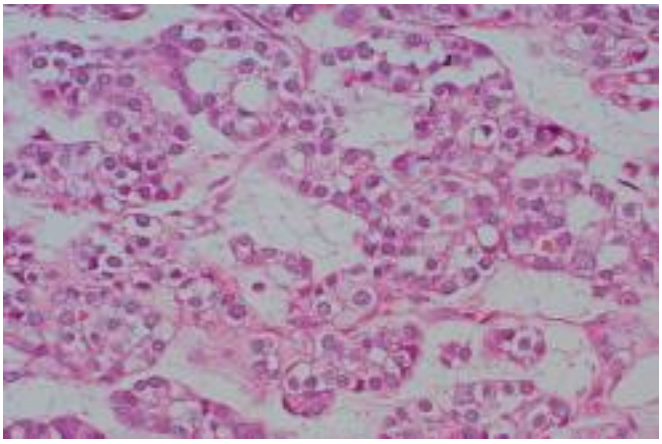

10 An 18-year-old sexually active woman has had dyspareunia followed by vaginal bleeding for the past month. On pelvic examination, a red, friable, 2.5-cm nodular mass is seen on the anterior wall of the upper third of the vagina. The microscopic appearance of a biopsy specimen is shown in the figure. Which of the following conditions is likely to have contributed most to the origin of this neoplasm?

A Congenital adrenal hyperplasia
B Diethylstilbestrol (DES) exposure
C Human papillomavirus infection
D Polycystic ovary syndrome (PCOS)
E *Trichomonas* vaginitis

11 A 4-year-old girl is brought to the physician by her parents, who noticed bloodstained underwear and "something" protruding from her external genitalia. On physical examination, there are polypoid, grapelike masses projecting from the vagina. Histologic examination of a biopsy specimen from the lesion shows small, round tumor cells, some of which have eosinophilic straplike cytoplasm. Immunohistochemical staining shows desmin, vimentin, and myogenin in these cells. What is the most likely diagnosis?

A Clear cell carcinoma
B Infiltrating squamous cell carcinoma
C Neuroblastoma
D Sarcoma botryoides
E Vulvar intraepithelial neoplasia

12 A healthy 30-year-old woman comes to the physician for a routine health maintenance examination. No abnormalities are found on physical examination. A screening Pap smear shows cells consistent with a low-grade squamous intraepithelial lesion (LSIL). Subsequent cervical biopsy specimens confirm the presence of cervical intraepithelial neoplasia (CIN) I. Which of the following risk factors is most likely related to her Pap smear findings?

A Diethylstilbestrol (DES) exposure
B Multiple sexual partners
C Oral contraceptive use
D Prior treatment for a malignancy
E Vitamin B_{12} (cobalamin) deficiency

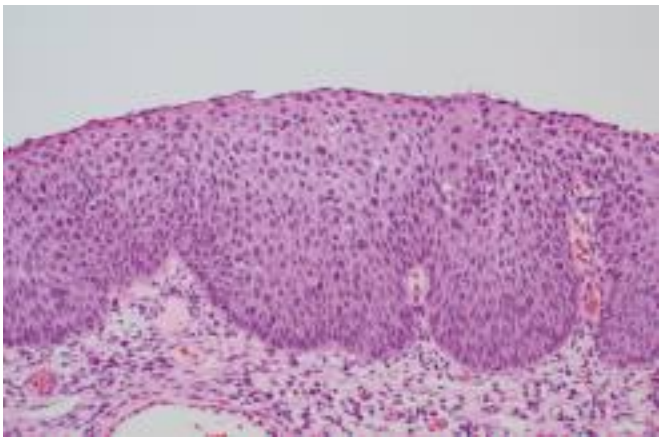

13 A 33-year-old woman comes to her nurse practitioner for a routine health maintenance examination. On physical examination, there are no abnormal findings. A Pap smear shows abnormalities; colposcopy and a biopsy are performed. The figure shows the microscopic appearance of the biopsy specimen. Which of the following is the best strategy to prevent the development of this lesion?

A Avoidance of tobacco products
B Consumption of a diet rich in vegetables
C Maintenance of an ideal body weight
D Use of oral contraceptives
E Vaccination for human papillomavirus

14 A 42-year-old woman has a Pap smear as part of a routine health maintenance examination. There are no remarkable findings on physical examination. The Pap smear shows cells consistent with a high-grade squamous intraepithelial lesion (HSIL) with human papillomavirus type 18. Cervical biopsy specimens are obtained, and microscopic examination confirms the presence of extensive moderate dysplasia (CIN II) along with intense chronic inflammation with squamous metaplasia in the endocervical canal. What is the most likely explanation for proceeding with cervical conization for this patient?

A Her reproductive years are over
B HPV infection cannot be treated
C Perimenopausal state
D Presence of chronic cervicitis
E Risk for invasive carcinoma

15 A 28-year-old sexually active woman comes to her physician's assistant for a routine health maintenance examination. There are no abnormal findings on physical examination. She has been taking oral contraceptives for the past 10 years. A Pap smear shows a high-grade squamous epithelial lesion (HSIL), also termed *moderate dysplasia,* or *cervical intraepithelial neoplasia* (CIN) II. What is the most likely molecular pathogenesis for this finding?

A Estrogenic stimulation of cell proliferation
B Inheritance of a tumor suppressor gene mutation
C Recurrent gonococcal cervicitis
D Up-regulation of antiapoptosis genes
E Viral inactivation of the *RB1* gene product

16 A 34-year-old woman has a routine Pap smear for the first time. The results indicate that dysplastic cells are present, consistent with a high-grade squamous intraepithelial lesion (HSIL), also called *cervical intraepithelial neoplasia* (CIN) III. She is referred to a gynecologist, who performs colposcopy and takes multiple cervical biopsy specimens that all show CIN III. Conization of the cervix shows a focus of microinvasion at the squamocolumnar junction. Based on these findings, what is the next most likely step in treating this patient?

A Bone scan for metastatic lesions
B Course of radiation therapy
C No further therapy
D Pelvic exenteration
E Vaginal hysterectomy

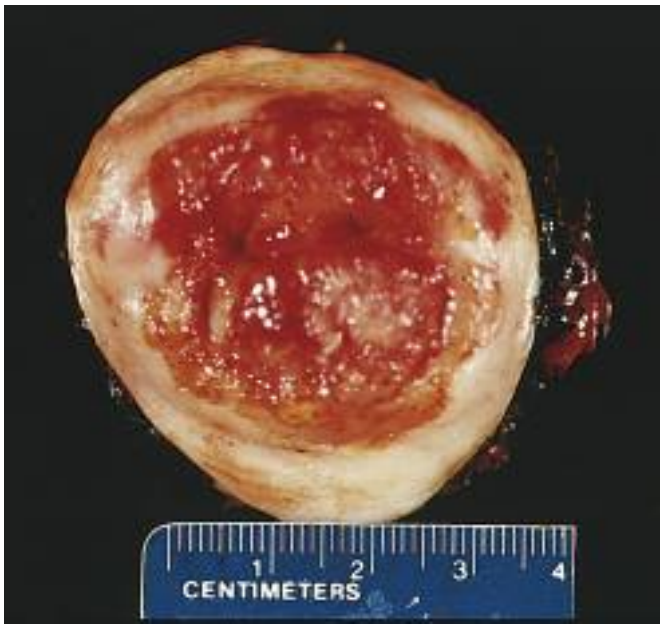

17 A 45-year-old woman has had a small amount of vaginal bleeding and a brownish, foul-smelling discharge for the past month. On pelvic examination, there is a 3-cm lesion on the ectocervix, shown in the figure. Microscopic examination of the lesion is most likely to show which of the following?

A Adenocarcinoma
B Cervical intraepithelial neoplasia
C Chronic cervicitis
D Clear cell carcinoma
E Extramammary Paget disease
F Squamous cell carcinoma

18 A 43-year-old woman has had postcoital bleeding for 6 months. She experienced menarche at age 11 years and has had 12 sexual partners during her life. She continues to have regular menstrual cycles without abnormal intermenstrual bleeding. Pelvic examination shows a focal, slightly raised area of erythema on the cervix at the 5 o'clock position. A Pap smear shows a high-grade squamous intraepithelial lesion (HSIL), also termed *severe cervical intraepithelial neoplasia* (CIN III). Analysis of cells from the cervix shows the presence of human papillomavirus type 16. Which of the following malignancies is she at greatest risk of developing if the lesion is not treated?

A Clear cell carcinoma
B Immature teratoma
C Krukenberg tumor
D Leiomyosarcoma
E Sarcoma botryoides
F Squamous cell carcinoma

19 A 13-year-old girl began menstruation 1 year ago. She now has abnormal uterine bleeding, with menstrual periods that are 2 to 7 days long and 2 to 6 weeks apart. The amount of bleeding varies from minimal spotting to a very heavy flow. On physical examination, there are no remarkable findings. A pelvic ultrasound scan shows no abnormalities. Which of the following is most likely to produce these findings?

A Anovulatory cycles
B Ectopic pregnancy
C Endometrial carcinoma
D Endometrial polyp
E Uterine leiomyomata

20 A 41-year-old G5, P5 woman has noticed lower abdominal pain with fever for the past 2 days. She delivered a normal term infant 1 week ago. On examination, she has a temperature of 37.4° C. There is a foul-smelling vaginal discharge. Which of the following pathologic findings is she most likely to have?

A Cervical intraepithelial neoplasia
B Endometrial neutrophilic infiltrates
C Myometrial smooth muscle neoplasm
D Ovarian endometrioma
E Tubal granulomatous inflammation
F Vaginal trichomoniasis

21 A 35-year-old woman presents with infertility. She has had dysmenorrhea, dyspareunia, and pelvic pain on defecation for 4 years. Laparoscopic examination reveals red-blue nodules on the surface of the uterus and extensive adhesions between ovaries and the fallopian tubes. Histologic examination of a biopsy from one of the nodules shows hyperplastic endometrial glands and hemorrhage in the stroma. Molecular analysis of the biopsy material reveals hypomethylation of the promoter regions of the genes that encode steroidogenic factor 1 and estrogen receptor beta. There are no mutations in the *PTEN*, *KRAS*, and *MLH1* genes. Which of the following is an appropriate treatment modality in this case?

A Aromatase inhibitors
B Chemotherapy
C Estrogen
D Antitubercular therapy
E Total abdominal hysterectomy

22 A 36-year-old woman has had menorrhagia and pelvic pain for six months. She had a normal, uncomplicated pregnancy 10 years ago but has failed to conceive since then. She has been sexually active with one partner for the past 20 years and has had no dyspareunia. On pelvic examination she has a symmetrically enlarged uterus, with no apparent nodularity or palpable mass. A serum pregnancy test result is negative. What is the most likely diagnosis?

A Adenomyosis
B Chronic endometritis
C Endometrial hyperplasia
D Endometriosis
E Leiomyoma

23 A 32-year-old woman has cyclic abdominal pain that coincides with her menses. Attempts to become pregnant have failed over the past 5 years. There are no abnormal findings on physical examination. Laparoscopic examination shows numerous hemorrhagic 0.2- to 0.5-cm lesions over the peritoneal surfaces of the uterus and ovaries. Which of the following ovarian lesions is most likely to be associated with her findings?

A Fibroma
B Brenner tumor
C Endometriotic cyst
D Krukenberg tumor
E Metastatic choriocarcinoma
F Mucinous cystadenocarcinoma

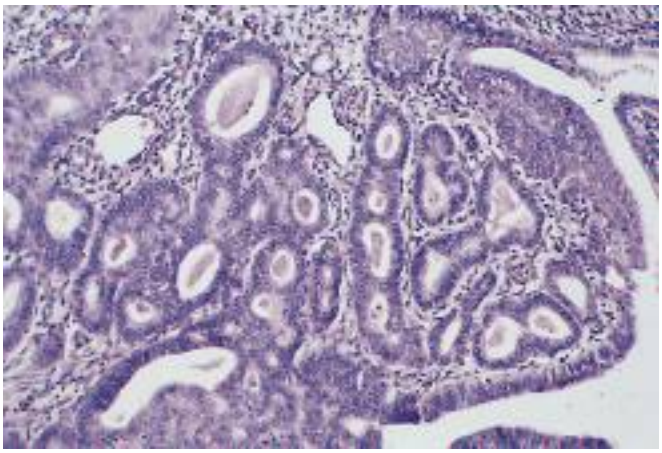

24 A 49-year-old perimenopausal woman has had menometrorrhagia for the past 3 months. On physical examination, there are no remarkable findings. The microscopic appearance of an endometrial biopsy specimen is shown in the figure. The patient undergoes a dilation and curettage, and the bleeding stops, with no further problems. What condition is most likely to produce these findings?

A Chronic endometritis
B Ovarian mature cystic teratoma
C Pregnancy with missed abortion
D Repeated failure of ovulation
E Use of oral contraceptives

25 A 52-year-old perimenopausal woman has had vaginal bleeding for a week. She has no medical problems and takes no medications. Hysteroscopy is performed and there is a single, 2-cm, smooth, soft mass protruding into the endometrial cavity. Biopsies are taken. What is microscopic examination of this lesion most likely to show?

A Endocervical glands with squamous metaplasia
B Endometrial glands resembling stratum basalis
C Papillae with marked cellular atypia
D Smooth muscle cells in bundles
E Tubular glands lined by clear cells with glycogen

26 A 42-year-old woman has had menometrorrhagia for the past 2 months. She has no history of prior irregular menstrual bleeding, and she has not yet reached menopause. On physical examination, there are no vaginal or cervical lesions, and the uterus appears normal in size, but there is a right adnexal mass. An abdominal ultrasound scan shows the presence of a 7-cm solid right adnexal mass. Endometrial biopsy shows hyperplastic endometrium, but no cellular atypia. What is the most likely lesion that underlies her menstrual abnormalities?

A Corpus luteum cyst
B Endometrioma
C Granulosa-theca cell tumor
D Mature cystic teratoma
E Metastasis
F Polycystic ovarian syndrome

27 A 62-year-old childless woman noticed a blood-tinged vaginal discharge twice during the past month. Her last menstrual period was 10 years ago. Bimanual pelvic examination shows that the uterus is normal in size, with no palpable adnexal masses. There are no cervical erosions or masses. Her body mass index is 33. Her medical history indicates that for the past 30 years she has had hypertension and type 2 diabetes mellitus. An endometrial biopsy specimen is most likely to show which of the following?

A Adenocarcinoma
B Choriocarcinoma
C Leiomyosarcoma
D Malignant müllerian mixed tumor
E Squamous cell carcinoma

28 A study of patients with postmenopausal uterine bleeding reveals that some of them have malignant neoplasms that arise from prior atypical hyperplastic lesions. The peak incidence is between 55 and 65 years of age in women who have obesity, hypertension, and/or diabetes mellitus. Molecular analysis reveals mutations of the *PTEN* tumor suppressor gene in most of them. Their malignancies tend to remain localized for years before spreading to local lymphatics. Which of the following neoplasms is most likely to have these characteristics?

A Clear cell carcinoma
B Endometrioid carcinoma
C Leiomyosarcoma
D Müllerian mixed tumor
E Serous carcinoma
F Stromal sarcoma

29 A 62-year-old obese, nulliparous woman has an episode of vaginal bleeding, which produces only 5 mL of blood. On pelvic examination, there is no enlargement of the uterus, and the cervix appears normal. A Pap smear shows cells consistent with adenocarcinoma. Which of the following preexisting conditions is most likely to have contributed to the development of this malignancy?

A Adenomyosis
B Chronic endometritis
C Endometrial hyperplasia
D Human papillomavirus infection
E Use of oral contraceptives

30 A 40-year-old nulliparous woman has had menorrhagia for the past 6 months. On physical examination, her blood pressure is 154/93 mm Hg, there are no cervical lesions or adnexal masses, and the uterus is normal in size. She is 155 cm (5 feet 1 inch) tall and weighs 74.5 kg (body mass index 38). A Pap smear shows atypical glandular cells of uncertain significance. Hemoglobin A_{1c} concentration is 9.8%. Endometrial biopsy shows complex hyperplasia with atypia; molecular analysis detects loss of *PTEN* gene heterozygosity and enhanced AKT phosphorylation. Which of the following metabolic pathways is most likely to be activated in this tumor?

A Decreased glucose uptake
B Decreased prostaglandin synthesis
C Increased aerobic glycolysis
D Increased glycogen storage
E Increased oxidative phosphorylation



31 A healthy 59-year-old woman has had a feeling of pelvic heaviness for the past 11 months. There is no history of abnormal bleeding, and her last menstrual period was 8 years ago. Her physician palpates an enlarged nodular uterus on bimanual pelvic examination. A Pap smear shows no abnormalities. Pelvic CT scan shows multiple solid uterine masses; there is no evidence of necrosis or hemorrhage. A total abdominal hysterectomy is performed. Based on the gross appearance of the mass shown in the figure, what is the most likely diagnosis?

A Adenomyosis
B Endometriosis
C Leiomyomas
D Metastases
E Tuberculosis

32 A 53-year-old woman whose last menstrual period was 3 years ago notes vaginal bleeding for a week. On physical examination, her uterus is markedly enlarged, but there are no adnexal masses. CT imaging reveals an irregular 8-cm mass in the body of the uterus. A total abdominal hysterectomy is performed, and microscopic examination of the soft, hemorrhagic mass shows spindle cells with atypia and numerous mitoses. There is coagulative necrosis of tumor cells. Which of the following is the most likely cell of origin for this mass?

A Cytotrophoblastic cells
B Endometrial glandular cells
C Germ cells
D Smooth muscle cells
E Squamous epithelial cells

33 A 69-year-old woman has passed blood per vagina for a month. On pelvic examination no abnormal findings are noted. Which of the following diagnostic procedures should be performed next?

A Endometrial biopsy
B Magnetic resonance imaging
C Microbiologic culture
D Pap smear
E Pregnancy test

34 A 28-year-old woman has had fever, pelvic pain, and a feeling of pelvic heaviness for the past week. Pelvic examination shows a palpable painful left adnexal mass. Laparoscopy shows an indistinct left fallopian tube that is part of a 5-cm circumscribed, red-tan mass involving the left adnexal region. Which of the following infectious agents is most likely to produce these findings?

A *Chlamydia trachomatis*
B *Haemophilus ducreyi*
C Herpes simplex virus
D *Mycobacterium tuberculosis*
E *Treponema pallidum*

35 A 19-year-old woman has the sudden onset of abdominal pain. On physical examination, there is pelvic pain on palpation. Her stool is negative for occult blood. The serum and urine pregnancy tests are negative. Transvaginal ultrasound shows no intrauterine gestational sac, and uterus and adnexa are normal in size. Culdocentesis yields a small amount of blood-tinged fluid. Which of the following has most likely led to these findings?

A Ectopic pregnancy
B Endometriosis
C Follicle cyst
D Invasive mole
E Pelvic inflammatory disease



36 A 21-year-old woman experienced menarche at age 14 years and had regular menstrual cycles for the next 3 years. For the past year, she has had oligomenorrhea and has developed hirsutism. She has noticed a 10-kg weight gain in the past 4 months. On pelvic examination, there are no vaginal or cervical lesions, the uterus is normal in size, and the adnexa are prominent. A pelvic ultrasound scan shows that each ovary is twice normal size, whereas the uterus is normal in size. Magnetic resonance imaging is shown in the figure. Which of the following conditions is most likely to be present in this woman?

A Immature teratomas
B Krukenberg tumors
C Ovarian cystadenocarcinomas
D Polycystic ovarian syndrome
E Tubo-ovarian abscesses

37 A 35-year-old woman has had increasing abdominal enlargement for the past 6 months. She states that she feels like she is pregnant, but results of a pregnancy test are negative. On physical examination, there is abdominal distention with a fluid wave. A pelvic ultrasound scan shows bilateral cystic ovarian masses, 10 cm on the right and 7 cm on the left. The masses are surgically removed. On gross examination, the excised masses are unilocular cysts filled with clear fluid, and papillary projections extend into the central lumen of the cyst. Microscopic examination shows that the papillae are covered with atypical cuboidal cells that invade underlying stroma. Psammoma bodies are present. What is the most likely diagnosis?

A Endometrioid tumor
B Cystadenocarcinoma
C Dysgerminoma
D Granulosa cell tumor
E Mature cystic teratoma
F Sertoli-Leydig cell tumor



38 A 40-year-old woman has noticed progressive enlargement of the abdomen over the past 5 months, although her diet has not changed, and she has been exercising more. Physical examination shows no palpable masses, but a fluid wave is present. Paracentesis yields 500 mL of slightly cloudy fluid. Cytologic examination of the fluid shows malignant cells. An abdominal ultrasound scan shows a 15-cm multilobular mass that involves the right adnexal region. The uterus is normal in size. The mass is surgically removed; the figure shows the gross features of a section of the excised mass. What is the most likely diagnosis?

A Choriocarcinoma
B Dysgerminoma
C Granulosa cell tumor
D Mucinous cystadenocarcinoma
E Teratoma with malignant transformation

39 A 56-year-old woman has had weight loss accompanied by abdominal enlargement for the past 5 months. There is a family history of breast and ovarian carcinoma. On physical examination, there are no lesions of the cervix, and the uterus is normal in size, but there is a left adnexal mass. An abdominal ultrasound scan shows a 10-cm cystic mass in the left adnexal region, with scattered 1-cm peritoneal nodules, and ascites. Cytologic studies of peritoneal fluid show malignant cells. Which of the following mutated genes is most likely a factor in the development of this neoplasm?

A *BRCA1*
B *ERBB2* (*HER2*)
C *MYC*
D *KRAS*
E *RB1*

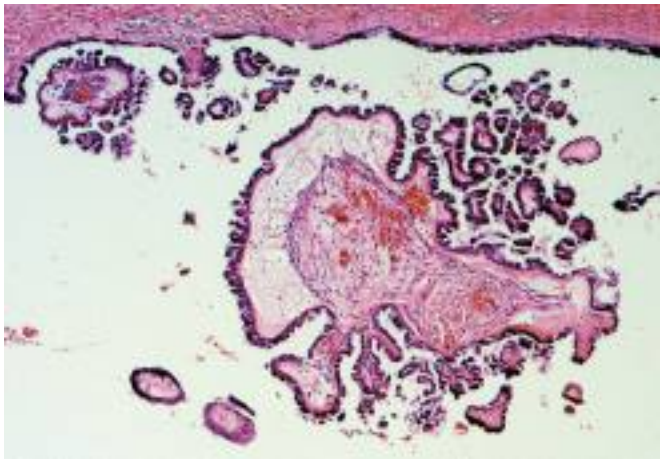

40 A 42-year-old woman has noted dull lower abdominal pain for the past year. She reports no abnormal bleeding. On physical examination there is a large left adnexal mass. The pregnancy test is negative. Transvaginal ultrasound shows a right adnexal 10-cm cystic mass filled with fluid. The mass is removed and has the microscopic appearance shown in the figure. Which of the following is most likely to be associated with this lesion?

A Brain metastases
B Endometrial hyperplasia
C Masculinization
D Peritoneal implants
E Sarcomatous transformation



41 A 33-year-old woman has had dull, constant abdominal pain for 6 months. On physical examination, the only finding is a right adnexal mass. CT scan of the pelvis shows a 7-cm circumscribed cystic mass on the right ovary, and it contains irregular calcifications. The right fallopian tube and ovary are surgically excised. The gross appearance of the ovary, which has been opened, is shown in the figure. Microscopic examination of this lesion is most likely to show which of the following?

A Mature squamous epithelium
B Papillary structures with psammoma bodies
C Primitive neuroepithelium
D Rhabdomyoblasts in a cellular stroma
E Sheets of trophoblasts and syncytial cells

42 A 23-year-old woman has had pelvic discomfort for 4 months. On pelvic examination, there is a large, nontender, right adnexal mass. An abdominal CT scan shows the 11-cm mass to be solid and circumscribed. On surgical removal, the mass is solid and white, with small areas of necrosis. Microscopically, it contains mostly primitive mesenchymal cells along with some cartilage, muscle, and foci of neuroepithelial differentiation. What is the most likely diagnosis?

A Brenner tumor
B Dysgerminoma
C Granulosa cell tumor
D Immature teratoma
E Leiomyosarcoma
F Malignant müllerian mixed tumor

43 A 52-year-old woman has had dull pain in the lower abdomen for the past 6 months and minimal vaginal bleeding on three occasions. Her last menstrual period was 2 years ago. Pelvic examination shows a right adnexal mass, and the uterus appears normal in size. An abdominal ultrasound scan shows an 8-cm solid mass, a small amount of ascites, and a right pleural effusion. A total abdominal hysterectomy is performed, and the mass is determined to be an ovarian fibrothecoma. Which of the following additional lesions is most likely to be found in the excised specimen?

A Bilateral chronic salpingitis
B Cervical condylomata acuminata
C Endometrial hyperplasia
D Metastases to the uterine serosa
E Partial mole of the uterus

44 A clinical study of women diagnosed with ovarian neoplasms reveals that 1 in 200 develop masculinizing signs and symptoms, including hirsutism, acne, breast atrophy, and amenorrhea. These women are found to have well-circumscribed, lobulated, firm, yellow mass lesions averaging 5 cm. Microscopically they have plump pink cells that show positive immunohistochemical staining for inhibin. Which of the following neoplasms are most likely to have these features?

A Brenner tumor
B Dysgerminoma
C Endometrioid carcinoma
D Granulosa-theca cell tumor
E Sertoli-Leydig cell tumor

45 A 17-year-old girl missed a menstrual period, and her pregnancy test is positive. A month later, she notes suprapubic pain and passing blood clots from her vagina. She passes a small amount of tissue 3 days later. Pathologic examination of this tissue shows products of conception. Which of the following is the most likely cause for her pregnancy loss?

A Bifid uterus
B Group B streptococcus infection
C Polycystic ovarian syndrome
D Preeclampsia
E Smoking cigarettes
F Fetal trisomy 16

46 A 36-year-old woman has had an uneventful pregnancy for the past 37 weeks. Over the past 12 hours, she has developed lower abdominal pain. On examination, there is suprapubic tenderness. Her temperature is 37.4° C. Pelvic examination reveals a purulent cervical discharge. The infant is delivered 12 hours later. Which of the following organisms is most likely responsible for her premature labor?

A Group B streptococcus
B Herpes simplex virus
C Rubella virus
D *Toxoplasma gondii*
E *Treponema pallidum*

47 A 22-year-old woman experiences sudden onset of severe lower abdominal pain. Physical examination shows no masses, but there is severe tenderness in the right lower quadrant. A pelvic examination shows no lesions of the cervix or vagina. Bowel sounds are detected. An abdominal ultrasound scan shows a 4-cm focal enlargement of the proximal right fallopian tube. A dilation and curettage procedure shows only decidua from the endometrial cavity. Which of the following laboratory findings is most likely to be reported for this patient?

A Cervical culture positive for *Neisseria gonorrhoeae*
B Detection of human chorionic gonadotropin in serum
C 69,XXY karyotype on decidual tissue cells
D Pap smear showing pseudohyphae of *Candida*
E Positive result of serologic testing for syphilis

48 A 36-year-old primigravida develops peripheral edema late in the second trimester. On physical examination, her blood pressure is 155/95 mm Hg. Urinalysis shows 2+ proteinuria, but no blood, glucose, or ketones. At 36 weeks, she gives birth to a normal viable but low-birth-weight infant. Her blood pressure returns to normal, and she no longer has proteinuria. Which of the following pathologic findings is most likely to be found on examination of the placenta?

A Chorioamnionitis
B Chronic villitis
C Hydropic villi
D Multiple infarcts
E Partial mole

49 A 35-year-old primigravid woman at 30 weeks' gestation develops worsening headaches along with a 3-kg weight gain over 1 week. This morning she had a generalized seizure. On physical examination, she is afebrile, but her blood pressure is 190/115 mm Hg (it was 120/80 mm Hg at a prenatal visit 1 month ago). She has peripheral edema involving her head and all extremities. Fetal heart tones of 140/min and fetal movement are present. Laboratory studies show hemoglobin, 12.5 g/dL; hematocrit, 37.6%; MCV, 92 μm^3; platelet count, 199,000/mm^3; serum creatinine, 1 mg/dL; potassium, 4.2 mmol/L; and glucose, 101 mg/dL. Urinalysis shows 2+ proteinuria, but no hematuria, RBCs, WBCs, or casts. Which of the following is the most likely underlying factor in the causation of her disease?

A Adrenal cortical hyperplasia
B Disseminated intravascular coagulation
C Gestational trophoblastic disease
D Ovarian neoplasm producing estrogen
E Placental ischemia
F Uncontrolled gestational diabetes



50 A 21-year-old G2, P1 woman is in the early second trimester. She has noted a small amount of vaginal bleeding for the past week and has had marked nausea and vomiting for 3 weeks. On physical examination, the uterus measures large for dates. An ultrasound examination shows intrauterine contents with a "snowstorm appearance," and no fetus is identified. The gross appearance of tissue obtained by dilation and curettage is shown in the figure. Which of the following substances is most likely to be greatly increased in her serum?

A Acetylcholinesterase
B α-Fetoprotein
C Estradiol
D Human chorionic gonadotropin
E Human placental lactogen

51 A 23-year-old woman, G3, P2, has a spontaneous abortion at 15 weeks' gestation. The male fetus is small for gestational age and is malformed, with syndactyly of the third and fourth digits of each hand. The placenta also is small, and shows 0.5-cm grapelike villi scattered among morphologically normal villi. Chromosomal analysis of placental tissue is most likely to show which of the following karyotypes?

A 45,X
B 46,XX
C 47,XXY
D 47,XY,+18
E 69,XXY

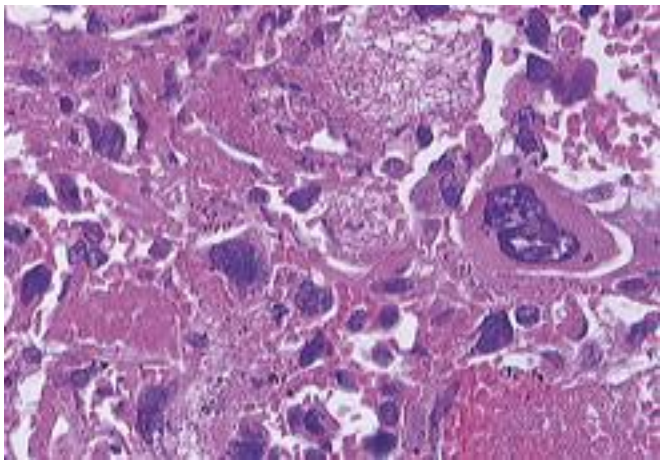

52 A 23-year-old woman suddenly notices a bloody, brownish vaginal discharge. The next day she has shortness of breath. On physical examination, a 3-cm, red-brown mass is seen on the lateral wall of the vagina. A chest radiograph shows numerous 2- to 5-cm nodules in both lungs. Laboratory studies show that her serum human chorionic gonadotropin levels are markedly elevated. A biopsy specimen of the vaginal mass is obtained and shown in the figure. Chromosome analysis of these cells shows a 46,XX karyotype. Which the following cells is most likely present in this mass lesion?

A Amnionic
B Rhabdomyoblast
C Serous epithelial
D Smooth muscle
E Syncytiotrophoblast

53 A 26-year-old woman delivered a normal neonate a month ago following an uncomplicated pregnancy. She now has vaginal bleeding. Hysteroscopy shows a nodule in the uterine fundus. Laboratory studies show hCG level of 200 mIU/mL. She is given chemotherapy but the lesion does not regress. Hysterectomy is performed. Microscopic examination of the nodule shows intermediate trophoblast cells. Immunostaining for which of the following proteins is most likely to yield positive results in this nodule?

A α-Fetoprotein
B Chromogranin
C Desmin
D Human placental lactogen
E Neuron-specific enolase

CHAPTER 23

The Breast

PBD9 Chapter 23 and PBD8 Chapter 23: The Breast

BP9 Chapter 18 and BP8 Chapter 19: Female Genital System and Breast

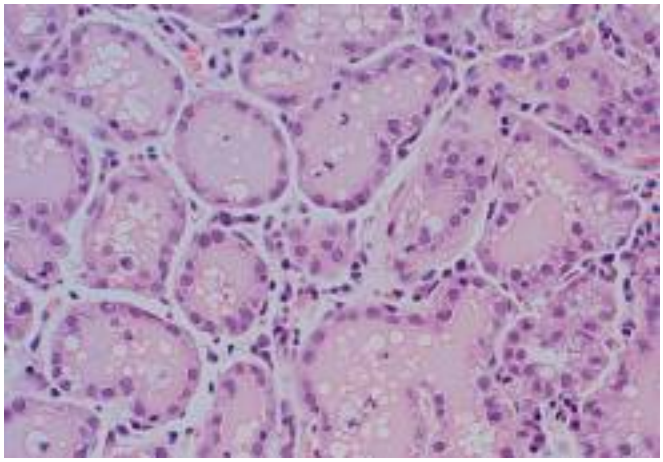

1 A 21-year-old woman delivered a normal term infant a week ago and is now nursing the infant. She now notes a lump in her right axilla that has increased in size over the past week. On physical examination there is a rubbery, mobile, 1.5-cm mass beneath the skin at the right anterior axillary line. The mass is excised and the microscopic appearance is shown in the figure. Which of the following hormones most likely produced the greatest effect upon this tissue?

A Cortisol
B Growth hormone
C Oxytocin
D Prolactin
E Testosterone

2 A 24-year-old woman is breastfeeding 3 weeks after giving birth to a normal term infant. She notices fissures in the skin around her left nipple. Over the next 3 days, a 5-cm region near the nipple becomes erythematous and tender. Purulent exudate from a small abscess drains through a fissure. Which of the following organisms is most likely to be cultured from the exudate?

A *Candida albicans*
B *Lactobacillus acidophilus*
C *Listeria monocytogenes*
D *Staphylococcus aureus*
E Viridans streptococci

3 A 30-year-old woman sustained a traumatic blow to her right breast. Initially, there was a 3-cm contusion beneath the skin that resolved within 3 weeks, but she then felt a firm, painless lump that persisted below the site of the bruise 1 month later. What is the most likely diagnosis for this lump?

A Abscess
B Fat necrosis
C Fibroadenoma
D Inflammatory carcinoma
E Sclerosing adenosis

4 A study of mammographic findings on women of reproductive years is performed. The study identifies mammograms showing 1- to 5-cm cysts with focal microcalcifications and surrounding densities. Subsequent fine-needle aspiration yielded turbid fluid with few cells. Which of the following microscopic changes is most likely to be present in these lesions?

A Apocrine metaplasia
B Ductal carcinoma in situ
C Fat necrosis
D Papillomatosis
E Sclerosing adenosis

5 A 27-year-old woman feels a lump in her right breast. She has normal menstrual cycles, she is G3, P3, and her last child was born 5 years ago. On examination a 2-cm, irregular, firm area is palpated beneath the lateral edge of the areola. This lumpy area is not painful and is movable. There are no lesions of the overlying skin and no axillary lymphadenopathy. A biopsy specimen shows microscopic evidence of an increased number of dilated ducts surrounded by fibrous connective tissue. Fluid-filled ducts with apocrine metaplasia also are present. What is the most likely diagnosis?

A Fibroadenoma
B Fibrocystic changes
C Infiltrating ductal carcinoma
D Mammary duct ectasia
E Traumatic fat necrosis

6 A 47-year-old woman has a routine health examination. There are no remarkable findings except for a barely palpable mass in the right breast. A mammogram shows an irregular, 1.5-cm area of density with scattered microcalcifications in the upper outer quadrant. A biopsy specimen from this area is obtained and microscopically shows ductal hyperplasia. Which of the following is the most appropriate option for follow-up of this patient?

A Cessation of smoking cigarettes
B Continued screening for breast cancer
C Performing a simple mastectomy
D Testing for the *BRCA1* oncogene
E Prescribing broad-spectrum antibiotic therapy

7 A 34-year-old woman has noticed a bloody discharge from the nipple of her left breast for the past 3 days. On physical examination, the skin of the breasts appears normal, and no masses are palpable. There is no axillary lymphadenopathy. She has regular menstrual cycles and is using oral contraceptives. Excisional biopsy is most likely to show which of the following lesions in her left breast?

A Acute mastitis
B Fibroadenoma
C Intraductal papilloma
D Phyllodes tumor
E Sclerosing adenosis

8 A 57-year-old man has developed bilateral breast enlargement over the past 2 years. On physical examination, the enlargement is symmetric and is not painful to palpation. There are no masses. He is not obese and is not taking any medications. Which of the following underlying conditions best accounts for his findings?

A ACTH-secreting pituitary adenoma
B Choriocarcinoma of the testis
C Chronic glomerulonephritis
D Diabetes mellitus
E Micronodular cirrhosis
F Rheumatoid arthritis

9 A 58-year-old woman sees her naturopathic health care provider for a routine health examination. There are no remarkable findings on physical examination. A screening mammogram shows a 0.5-cm irregular area of increased density with scattered microcalcifications in the upper outer quadrant of the left breast. Excisional biopsy shows atypical lobular hyperplasia. She has been on postmenopausal estrogen-progesterone therapy for the past 10 years. She has smoked 1 pack of cigarettes per day for the past 35 years. Which of the following is the most significant risk factor for the development of lobular carcinoma in patients with such lesions?

A Atypical cytologic changes
B History of smoking
C Hormone replacement therapy
D Postmenopausal age
E Underlying *BRCA1* gene mutation

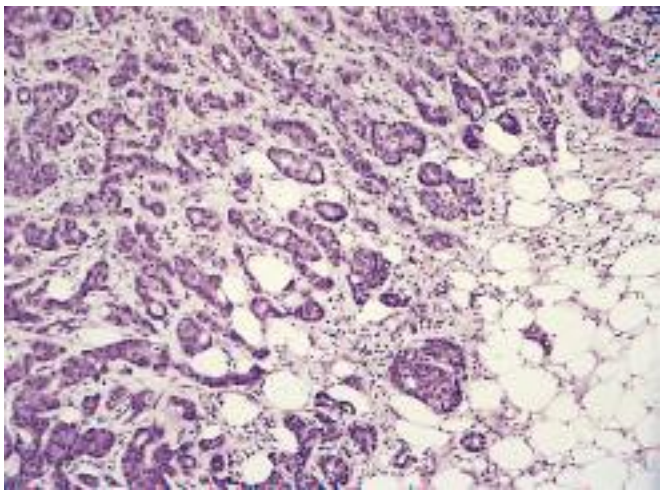

10 A 25-year-old Jewish woman sees her physician after finding a lump in her right breast. On physical examination, a 2-cm, firm, nonmovable mass is palpated in the upper outer quadrant. No overlying skin lesions and no axillary lymphadenopathy are present. The figure shows an excisional biopsy specimen. The family history indicates that the patient's mother, maternal aunt, and maternal grandmother have had similar lesions. Her 18-year-old sister has asked a physician to determine whether she is genetically at risk of developing a similar disease. A mutated gene encoding for which of the following is most likely to be found in her sister?

A *BRCA1*
B Estrogen receptor *(ER)*
C *HER2/neu*
D *TP53*
E Progesterone receptor *(PR)*
F *RB1*

11 A clinical study is performed on postmenopausal women living in Paris, France, who are between the ages of 45 and 70 years. All have been diagnosed with infiltrating ductal carcinoma positive for estrogen receptor (ER) and progesterone receptor (PR), but negative for *HER2* expression, which has been confirmed by biopsy and microscopic examination of tissue. None has the *BRCA1* or *BRCA2* mutation. Which of the following is most likely to indicate the highest relative risk of developing the carcinomas seen in this group of women?

A Age at menarche older than 16 years
B Age at menopause younger than 45 years
C First-degree relative with breast cancer
D Multiparity
E Prior diagnosis of mastitis

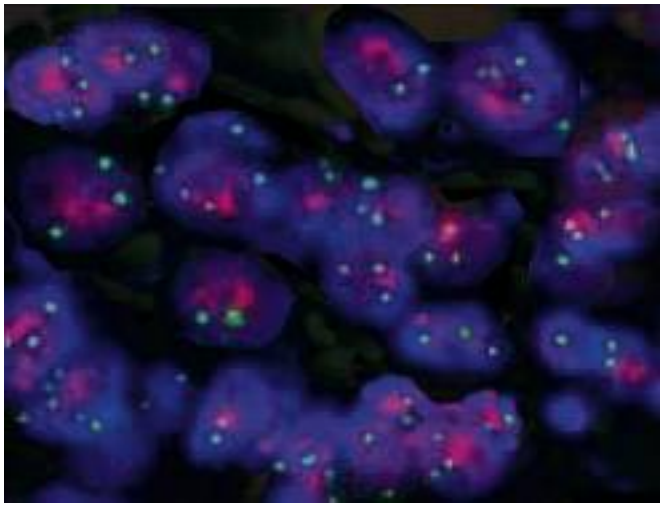

12 A 54-year-old woman feels a lump in her left breast. On examination there is a firm, irregular mass in the lower outer quadrant. A mammogram shows a 2-cm density with focal microcalcifications. Excisional biopsy shows intraductal and invasive carcinoma. Immunohistochemical staining is negative for estrogen receptor (ER). FISH analysis (green = *HER2*; red = chromosome 17 centromere) shows the findings in the figure. When combined with doxorubicin, which of the following drugs is most likely to be useful in treating this patient?

A Hydroxyurea
B Letrozole
C Raloxifene
D Tamoxifen
E Trastuzumab

13 A 66-year-old nulliparous woman received hormone replacement therapy for 7 years following menopause at age 53 years. Her BMI is 33. She now undergoes screening mammography, and an irregular mass is identified in the right breast. An excisional biopsy yields a 1.5-cm mass that microscopically has invasive cells that are positive for estrogen receptor but negative for *HER2,* with low proliferation markers and mutated *PIK3CA* gene. Following surgical removal of the mass, which of the following clinical courses will most likely occur over the next year?

A Detection of cancer in the left breast
B Need for chemotherapy
C Very low likelihood of recurrence
D Need for treatment with trastuzumab
E Occurrence of widespread metastases

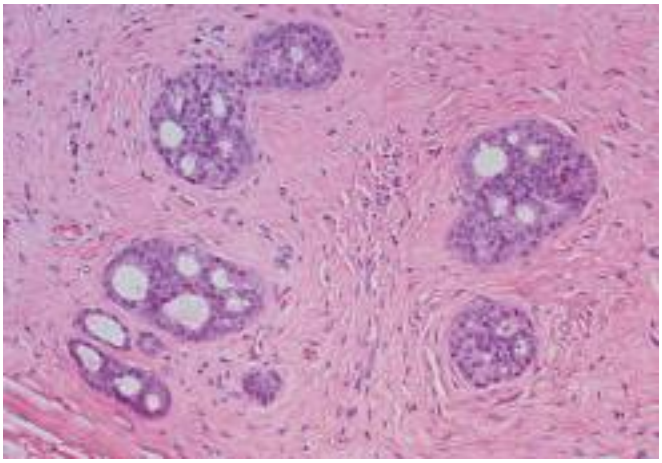

14 A 63-year-old woman has a screening mammogram that shows an irregular density with microcalcifications. On physical examination, there are no lesions of the overlying skin, and there is no axillary lymphadenopathy. An excisional biopsy specimen shows no mass on sectioning. Microscopic examination shows the findings in the figure. What is the most likely diagnosis?

A Colloid carcinoma
B Ductal carcinoma in situ
C Infiltrating ductal carcinoma
D Infiltrating lobular carcinoma
E Medullary carcinoma
F Papillary carcinoma

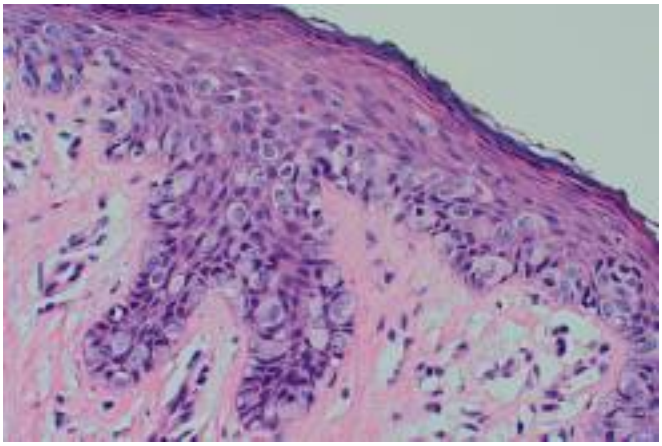

15 A 48-year-old woman has noticed a red, scaly area of skin on her left breast that has grown slightly larger over the past 4 months. On physical examination, there is a 1-cm area of eczematous skin adjacent to the areola. The figure shows the microscopic appearance of the skin biopsy specimen. What is the most likely diagnosis?

A Apocrine metaplasia
B Fat necrosis
C Inflammatory carcinoma
D Lobular carcinoma in situ
E Paget disease of the breast

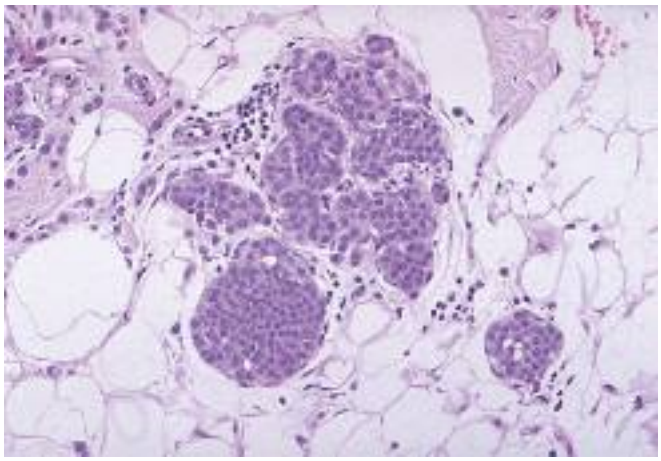

16 A 54-year-old woman noticed a lump in her right breast. On examination, she has an ill-defined, 1-cm mass in the upper outer quadrant. The mass is cystic on ultrasound. An excision is done, and microscopically the mass shows predominantly fibrocystic changes, but the lesion shown in the figure also is present. Fine-needle aspirates of both breasts reveal additional foci of similar cells. Which of the following breast lesions is most likely to produce these findings?

A Infiltrating ductal carcinoma
B Lobular carcinoma in situ
C Malignant phyllodes tumor
D Medullary carcinoma
E Mucinous (colloid) carcinoma

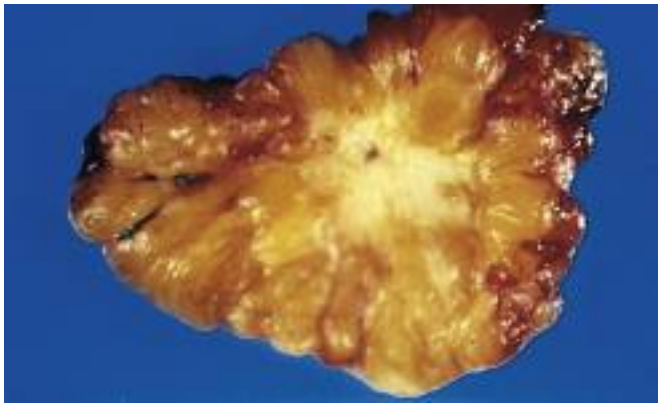

17 A 49-year-old woman felt a lump in her left breast 1 week ago. On examination, a firm, irregular mass is palpable in the upper outer quadrant of her left breast. There are no overlying skin lesions. The gross appearance of the excisional biopsy specimen is shown in the figure. Which of the following additional findings is she most likely to have on physical examination?

A Axillary lymphadenopathy
B Bloody discharge from the nipple
C Chest wall tenderness
D Cushingoid facies
E Mass in the opposite breast

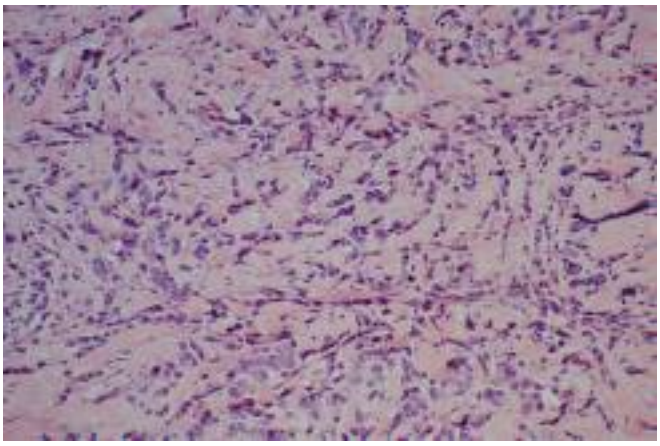

18 A 57-year-old woman has felt a lump in her left breast for 4 months. She has had new onset headaches associated with nausea for the past month. Her physician palpates a firm but irregular 2-cm mass in her left breast. CT imaging of her brain shows leptomeningeal enhancement. A lumpectomy with axillary node sampling is performed. Immunohistochemical staining of these cells shows absence of E-cadherin and HER2, but presence of estrogen receptor (ER) and progesterone receptor (PR). An H and E stained section is shown in the figure. No nodal metastases are present. Which of the following is the most likely diagnosis?

A Lobular carcinoma
B Medullary carcinoma
C Metaplastic carcinoma
D Metastatic glioblastoma
E Phyllodes tumor

19 A 39-year-old woman has noticed an enlarging mass in her left breast for the past 2 years. The physician palpates a 4-cm firm mass. Following biopsy, a simple mastectomy is performed with axillary lymph node sampling. On gross sectioning, the mass has a soft, tan, fleshy surface. Histologically, the mass is composed of large cells with vesicular nuclei and prominent nucleoli. There is a marked lymphocytic infiltrate within the tumor, and the tumor has a discrete, noninfiltrative border. No axillary node metastases are present. The tumor cells are triple negative, for HER2, estrogen receptor (ER), and progesterone receptor (PR). What is the most likely diagnosis?

A Colloid carcinoma
B Infiltrating ductal carcinoma
C Infiltrating lobular carcinoma
D Medullary carcinoma
E Papillary carcinoma
F Phyllodes tumor

20 An epidemiologic study is conducted with male subjects who have been diagnosed with breast carcinoma. Their demographic data, medical histories, family histories, and laboratory data are examined to identify factors that increase the risk of cancer. Which of the following factors is most likely to be associated with the greatest number of male breast carcinomas?

A Age older than 70 years
B Asian ancestry
C *ATM* gene mutation
D Chronic alcoholism
E Gynecomastia

21 A study of women with breast carcinoma is done to determine the presence and amount of estrogen receptor (ER) and progesterone receptor (PR) in the carcinoma cells. Large amounts of ER and PR are found in the carcinoma cells of some patients. These receptors are not present in the cells of other patients. The patients with positivity for ER and PR are likely to exhibit which of the following traits?

A Greater immunogenicity
B Greater likelihood of metastases
C Greater risk of familial breast cancer
D Higher response to therapy
E Higher tumor stage
F Higher tumor grade

22 A 26-year-old woman has felt a breast lump for the past month and is worried because she has a family history of early onset and bilateral breast cancers. On physical examination, there is a firm, 2-cm mass in the upper outer quadrant of her left breast. A biopsy is done, and the specimen microscopically shows carcinoma. Genetic analysis shows that she is a carrier of the *BRCA1* gene mutation, as are her mother and sister. Which of the following histologic types of breast carcinoma has the highest incidence in families such as hers?

A Lobular carcinoma
B Medullary carcinoma
C Metaplastic carcinoma
D Papillary carcinoma
E Tubular carcinoma

23 A 79-year-old, previously healthy woman feels a lump in her right breast. The physician palpates a 2-cm firm mass in the upper outer quadrant. Nontender right axillary lymphadenopathy is present. A lumpectomy with axillary lymph node dissection is performed. Microscopic examination shows that the mass is an infiltrating ductal carcinoma. Two of 10 axillary nodes contain metastases. Flow cytometry on the carcinoma cells shows a small aneuploid peak and high S-phase. Immunohistochemical tests show that the tumor cells are positive for estrogen and progesterone receptor (ER/PR), negative for *HER2/neu* expression, and positive for cathepsin D expression. What is the most important prognostic factor for this patient?

A Age at diagnosis
B DNA content in the carcinoma
C Estrogen receptor positivity
D Expression of stromal proteases in the carcinoma
E Histologic subtype of carcinoma
F Lack of *HER2/neu* expression in the carcinoma
G Presence of lymph node metastases

24 A study of gene expression profiling involving breast biopsies showing invasive carcinoma of no specific type (NST) is performed. A subset of these cases, comprising about 15% of all cases, has the following characteristics: estrogen receptor (ER) and progesterone receptor (PR) negative, *HER2/neu* negative, basal keratin positive, flow cytometry showing aneuploidy and high proliferation rate, and association with *BRCA1* mutations. Which of the following therapies is most likely to be effective in women with this subset of NST breast cancer?

A Chemotherapy
B Radiation
C Surgery alone
D Tamoxifen
E Trastuzumab

25 A 51-year-old woman has noticed an area of swelling with tenderness in her right breast that has worsened over the past 2 months. On physical examination, the 7-cm area of erythematous skin is tender with a rough, firm surface resembling an orange peel. There is swelling of the right breast, nipple retraction, and right axillary nontender lymphadenopathy. Excisional biopsy of skin and breast is most likely to show which of the following lesions?

A Acute mastitis
B Atypical epithelial hyperplasia
C Fat necrosis
D Infiltrating ductal carcinoma
E Sclerosing adenosis

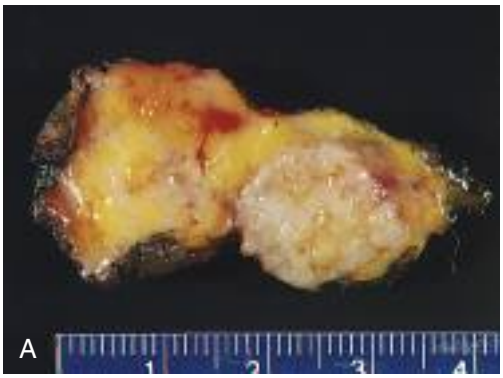

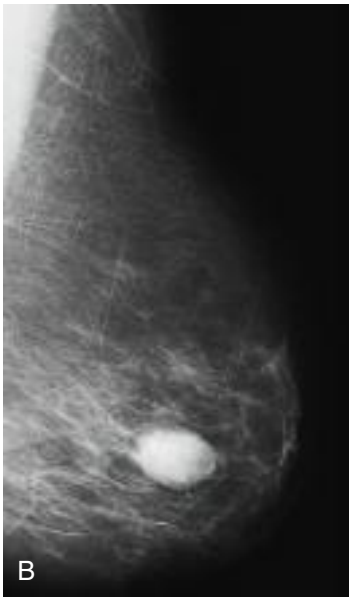

26 A 26-year-old woman has noticed a lump in her right breast for the past year. A 2-cm, firm, circumscribed, movable mass is palpated in the lower outer quadrant. The figure shows the excised mass (*A*) and the mammogram (*B*). What is the most likely diagnosis?

A Fat necrosis
B Fibroadenoma
C Fibrocystic changes
D Infiltrating ductal carcinoma
E Mastitis
F Phyllodes tumor

27 A 27-year-old woman in the third trimester of her third pregnancy discovers a lump in her left breast. On physical examination, a 2-cm, discrete, freely movable mass beneath the nipple is palpable. After the birth of a term infant, the mass appears to decrease in size. The infant is breastfed without difficulty. What is the most likely diagnosis?

A Fibroadenoma
B Intraductal papilloma
C Lobular carcinoma in situ
D Medullary carcinoma
E Phyllodes tumor

28 A 24-year-old woman notes a lump in her right breast for the past month. She is concerned because her sister was diagnosed with a poorly differentiated "triple negative" breast cancer at age 31. Ultrasonography of the breast shows a solid mass. Fine needle aspiration is attempted but no diagnostic cells are obtained. Mammography is performed and there is a single 1-cm density with small clustered calcifications in the right breast but no lesions of the opposite breast. Which of the following is the best course of action for this patient?

A Biopsy to obtain tissue from the lesion
B Continued monthly breast self-examination
C Genetic testing for *BRCA1* mutations
D Hormonal therapy with tamoxifen
E Radiologic imaging to detect metastases

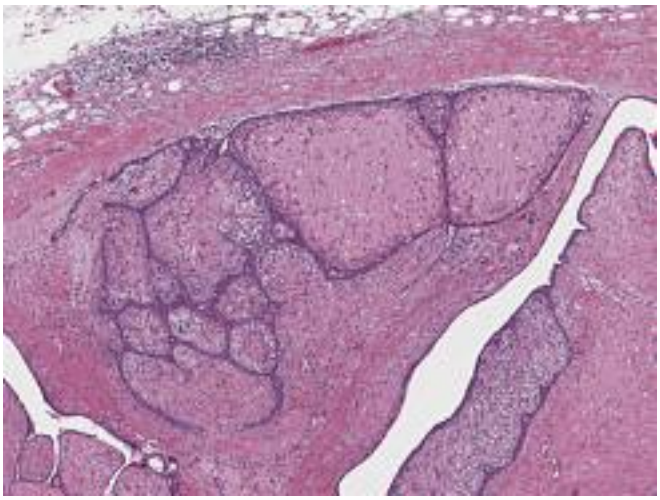

29 A 48-year-old woman has felt a poorly defined lump in her right breast for the past year. On examination, she has a nontender, firm, 6-cm mass in the upper inner quadrant of her right breast. There are no lesions of the overlying skin and no axillary lymphadenopathy. A biopsy is performed, and microscopic examination of the specimen shows the findings in the figure. The mass is excised with a wide margin, but recurs 1 year later. After further excision, the lesion does not recur. What is the most likely diagnosis?

A Fibroadenoma
B Fibrocystic changes
C Lobular carcinoma
D Phyllodes tumor
E Tubular carcinoma

Patho Repro

1. Which of the following statements is true about seminoma:

a) It is a benign tumor of the seminiferous tubules
b) It is a radio-resistant tumor
c) It is type of teratoma.
d) All of the above
e) None of the above

2. Which of the following statements is true about benign prostatic hypertrophy:

a) it predominantly affects the peripheral prostatic zone
b) it very commonly changes into prostatic carcinoma
c) May lead to bilateral hydronephrosis
d) All of the above
e) None of the above

3. Which of the following statements is true about prostatic carcinoma

a) Most cases are oestrogen dependent tumors
b) Most cases arise in the peripheral prostatic zone
c) Gleason's combined grade 2+3 (score 5) means a high grade tumor
d) All of the above
e) None of the above.

4. Which of the following statements is true for prostatic adenocarcinoma

a) It arises in association with gynecomastia
b) It commonly arises from the central periurethral zone of the prostate
c) PSA is a useful marker for diagnosis and follow up
d) All of the above
e) None of the above

5. Which of the following viruses is related to carcinoma of cervix and tongue:

a) Ebstein-Barr virus
b) Cytomegalovirus
c) Human immunodeficiency virus (HIV)
d) Human papilloma virus
e) All of the above

6. Which of the following is the most common microscopic type of cervical cancer:

a) Adenocarcinoma
b) Squamous cell carcinoma
c) Undifferentiated carcinoma
d) Adenosquamous carcinoma
e) Adenoacanthoma

Hothifa Read

Patho Repro

7. Which of the following statements is true about cervical carcinoma:

a) The endophytic types have better prognosis than the exophytic types.
b) The risk of cancer development is higher in virgins than in non-virgins.
c) The patients may die of renal failure.
d) All of the above
e) None of the above

8. Which of the following statements is true about cervical-erosion:

a) This is superficial ulceration representing an early manifestation of cervical cancer.
b) This is cervical mucosal inflammation associated with epithelial damage and bleeding.
c) This is cervical ulceration as a result of puerperal sepsis
d) This is eversion of the cervix as a result of inflammation and fibrosis
e) None of the above

9. Which of the following statements is true about puerperal sepsis:

a) This is postmenopausal septic inflammation of the endometrium
b) The uterus becomes shrunken due to severe fibrosis.
c) The condition is strongly precancerous
d) All of the above
e) None of the above.

10. Which of the following statements is true about endometriosis:

a) Endometrial tissue may occur in the umbilicus.
b) Peritoneal adhesions may complicate endometriosis
c) The ovaries may become cystic
d) All of the above
e) None of the above

11. Which of the following statements is true about endometrial hyperplasia:

a) It is most common in females using contraceptive pills.
b) The type known as "cystic hyperplasia" has the highest premalignant potential.
c) The condition predisposes to endometriosis.
d) All of the above
e) None of the above

12. Which of the following ovarian tumors can be bilateral:

a) Mucinous cystadenoma
b) Krukenberg tumor
c) Ovarian carcinoma
d) All of the above
e) None of the above

Hothifa Read

Patho Repro

13. Which of the following statements is true about vesicular mole:

a) Pregnancy test is often negative
b) Fetus is always detected
c) The condition predisposes to choriocarcinoma
d) All of the above
e) None of the above.

14. Which of the following conditions is true about mammary sclerosing adenosis:

a) It is a type of fibrosis following suppurative mastitis.
b) It is a type of mammary hyperplasia
c) It is a benign capsulated tumor of the breast
d) All of the above
e) None of the above

15. Which of the following mammary neoplasms is most liable for a malignant behavior:

a) Fibroadenoma
b) Lipoma
c) Phylloides tumor
d) Hemangioma
e) None of the above

16. Which of the following mammary neoplasms has the highest incidence of bilaterality.

a) lobular carcinoma
b) Medullary carcinoma
c) Paper's disease
d) Mucoid carcinoma
e) Apocrine carcinoma

17. Which of the following types of mammary carcinoma may have a good prognosis:

a) Juvenile secretory carcinoma
b) Medullary carcinoma with lymphocyte-rich stroma
c) Tubular or mucoid carcinoma occurring in a pure form (not mixed with other types.
d) All of the above
e) None of the above

18. Which of the following conditions does not indicate poor prognosis of breast carcinoma

a) Inflammatory carcinoma.
b) Skin invasion & ulceration
c) Microcalcifications
d) Cancer en cuirasse
e) Invasion of pectoral muscle.

Hothifa Read

Patho Repro

19. Which of the following is not a risk factor for mammary carcinoma:

a) Multiparity
b) Obesity
c) Late menopause
d) Positive family history.
e) Early menarche

20. Which of the following sites shows the highest incidence of breast cancer involvement

a) Lower outer quadrant of the breast.
b) Upper outer quadrant of the breast.
c) Lower inner quadrant of the breast.
d) Upper inner quadrant of the breast.
e) Central compartment of the breast.

21. Which of the following mammary lesions is most liable to be mistaken histologically to carcinoma:

a) Phylloides tumor
b) Sclerosing adenosis
c) Gynecomastia
d) Fibrocystic disease
e) Mammary duct ectasia

22. All of the following lesions are reliably diagnosed on endometrial curettage except:

a) Low grade endometrial stromal sarcoma
b) Endometrial hyperplasia
c) Endometrial carcinoma
d) Hydatidiform mole
e) Malignant mixed mesodermal tumor.

23. Uterine serous carcinoma:

a) Is histologically dissimilar from the ovarian counterpart
b) Manifests a metastatic pattern more like usual endometrioid endometrial adenocarcinoma than ovarian papillary serous carcinoma
c) Is unrelated to unopposed estrogen
d) Is frequently diagnosed on pap smear.
e) None of the above

24. Paget's disease of the vulva frequently recurs after excision. This is most likely due to:

a) The microscopic lesion frequently extends beyond the grossly visible lesion.
b) It is associated with an underlying skin adnexal malignancy in over 75% of cases.
c) The use of laser surgery activates the disease at the margins.
d) Invasive Paget's disease is frequently underdiagnosed.
e) None of the above

Hothifa Read

Patho Repro

Male

1. 25-year-old man has been unable to father children. He and his wife undergo an infertility workup. His wife's reproductive function is normal. On physical examination he has normal descended testes that appear normal in size. A testicular biopsy is performed and on microscopic examination only Sertoli cells are present in the seminiferous tubules on biopsy. Which of the following laboratory test findings is he most likely to have?

a) Decreased sperm count
b) Elevated serum human chorionic gonadotrophin
c) Decreased serum luteinizing hormone
d) Increased serum testosterone
e) Decreased plasma muellerian inhibiting substance
f) Increased serum alpha-fetoprotein

2. A 30-year-old man has had a feeling of heaviness in his left testis for the past 6 months. Physical examination reveals enlargement of the left testis, while the right testis appears normal. There is a palpable left inguinal lymph node. An ultrasound reveals a 4 cm solid mass within the body of the left testis. Laboratory findings included a serum beta-HCG of 5 IU/L and alpha-fetoprotein of 2 ng/mL. The left testis is removed and with gross examination on sectioning reveals a firm, lobulated light tan mass without hemorrhage or necrosis. He receives radiation therapy. Which of the following neoplasms is he most likely to have?

a) Choriocarcinoma
b) Embryonal carcinoma
c) Seminoma
d) Yolk sac tumor
e) Leydig cell tumor

3. A 35-year-old man goes to his physician for a routine examination. On physical examination there is a left inguinal mass. The right testis is palpated in the scrotum and is of normal size, but a left testis cannot be palpated in the scrotum. An ultrasound scan shows that the inguinal mass is consistent with a cryptorchid testis. Which of the following approaches is most appropriate to deal with this patient's testicular abnormality?

a) Put it into the scrotum surgically
b) Remove it along with the opposite testis
c) Remove it
d) Put the patient on testoterone therapy
e) Perform a chromosome analysis

Hothifa Read

Patho Repro

4. A 70-year-old healthy man goes to his physician for a routine check-up. On physical examination there is a firm nodule palpable in the prostate via digital rectal examination. Prostate biopsies are performed and on microscopic examination show small, crowded glands containing cells with prominent nucleoli in the nuclei. Which of the following is the most likely diagnosis?

a) Adenocarcinoma of the prostate
b) Benign prostatic hyperplasia
c) Chronic prostatitis
d) Metastatic urothelial carcinoma
e) Recent infarction of prostate

5. An epidemiologic study is performed to determine potential risk factors for development of penile squamous intraepithelial neoplasia. It is observed that persons who develop this disease are elderly men. The medical histories of these men are reviewed. Which of the following diseases is most likely to be found to preceed development of penile neoplasia in these men?

a) Phimosis
b) Herpes simplex virus infection
c) Lichen simplex chronicus
d) Balanitis xerotica obliterans
e) Epispadias

6. A clinical study is performed with male subjects diagnosed with sexually transmitted diseases. The clinical and laboratory findings in their medical records are analyzed. It is observed that in some cases there is ulceration of the male external genitalia while in others no ulceration is observed on physical examination. Which of the following organisms is most likely to result in non-ulcerated lesions?

a) Chlamydia trachomatis
b) Human papillomavirus
c) Calymmatobacterium granulomatis
d) Treponema pallidum
e) Hemophilus ducreyi

7. A 23-year-old healthy man has been unable to father a child. He and his wife have a workup for infertility. His wife's reproductive function is normal. On physical examination both his testes are palpable in the scrotum and the testes and scrotum are normal in size, with no masses palpable. However, the spermatic cord on the left has the feel of a "bag of worms". Laboratory studies show oligospermia. Which of the following conditions is this man most likely to have?

a) Hydrocele
b) Testicular torsion
c) Spermatocele
d) Varicocele
e) Seminoma

Hothifa Read

Patho Repro

8. A 72-year-old man gets up several times during a football match to go to the restroom to urinate, even though he has had only one beer. This is a problem that has plagued him for several years. When he visits his physician for a checkup, on physical examination he has an enlarged, nodular prostate palpated on digital rectal examination. Laboratory studies show his serum prostate specific antigen is 5 ng/mL. Which of the following pathologic findings is most likely to be present on prostate biopsy in this man?

a) Adenocarcinoma
b) Acute inflammation
c) Multiple infarctions
d) Nodular hyperplasia
e) Granulomatous inflammation

9. A 19-year-old university student notes the sudden onset of severe discomfort in his scrotum late one evening. No position is comfortable for him to sit or lie down. Aspirin and a can of beer have no effect. He has a friend drive him to the emergency room. On physical examination his vital signs include temperature 37 C, respirations 22/minute, pulse 80/minute, and blood pressure 100/65 mm Hg. His left testis is slightly enlarged and exquisitely tender. There is no inguinal adenopathy. A doppler ultrasound scan shows decreased blood flow in the left testis. Which of the following conditions is he most likely to have?

a) Choriocarcinoma of the testis
b) Varicocele
c) Ureteral lithiasis
d) Spermatic cord torsion
e) Hydrocele

10 A 20-year-old university student has noted a penile discharge with some pain on urination for the last 2 days. On physical examination there is a small amount of whitish exudate that can be expressed from the urethral meatus. Laboratory studies with culture of the penile discharge reveal Neisseria gonorrheae. If untreated, which of the following complications is he most likely to develop as a consequence of his disease?

a) Aortitis
b) Balanitis
c) Epididymitis
d) Orchitis
e) Sacroiliitis

Hothifa Read

Patho Repro

11. A 31-year-old man has had a feeling of heaviness in his scrotum for over 6 months. The examining physician notes an enlarged right testis. An ultrasound reveals a solid 5 cm mass in the body of the right testis. Laboratory studies show a serum alpha-fetoprotein (AFP) of 81 ng/mL and human chorionic gonadotrophin (HCG) of 15 IU/L. A right orchiectomy is performed, and on gross examination the testicular mass is soft and reddish brown. Microscopic examination shows cords and sheets of primitive cells with large nuclei. Which of the following is the most likely diagnosis?

a) Teratoma
b) Embryonal carcinoma
c) Mumps orchitis
d) Leydig cell tumor
e) Squamous cell carcinoma
f) Choriocarcinoma

12. A 77-year-old man has a routine check-up by his physician. The only physical examination finding is slight nodularity of his prostate on digital rectal examination. Laboratory studies show a serum prostate specific antigen of 5 ng/mL. A prostate biopsy is performed and on microscopic examination shows prostatic intraepithelial neoplasia (PIN). Which of the following is the best medical care option to offer this man?

a) Radical prostatectomy
b) Multiagent chemotherapy
c) Transurethral prostate resection
d) Monitoring of PSA levels
e) Nothing

13. a 27-year-old man has complained of continuing "jock itch" for the past year. On physical examination there are small whitish scaling patches on the skin of his perineum. A scraping from the lesion shows Trichophyton rubrum organisms. Which of the following lesions is he most likely to develop?

a) Condyloma acuminatum
b) Chancre
c) Bowen's disease
d) Angiokeratoma
e) Lichen simplex chronicus

14. A clinical study is performed with subjects who are sexually active 30- to 45-year-old men. A subset of these subjects are found to have a history of pelvic pain with enlarged, tender prostates on digital rectal examination. However, routine microbiologic cultures from prostatic secretions in this subset of men show no growth. Which of the following infectious agents is most likely to produce the condition seen in this subset of subjects?

a) Human papillomavirus
b) Herpes simplex virus
c) Human immunodeficiency virus
d) Chlamydia trachomatis

Hothifa Read

e) Candida albicans

15. A 30-year-old sexually active man has experienced a burning pain with urination for the past 5 days. On physical examination there is a scant pale yellowish urethral discharge. He is afebrile. He is most likely to be infected with which of the following organisms?

a) Herpes simplex virus
b) Treponema pallidum
c) Chlamydia trachomatis
d) Mumps virus
e) Hemophilus ducreyi

16. A 22-year-old G2 P1 woman gives birth following an uncomplicated pregnancy to a term male infant weighing 2850 gm. On physical examination he has incomplete development of the dorsal aspect of the penile urethra, with the defect extending to the bladder, which is open on the lower abdominal wall. Which of the following is the most likely diagnosis?

a) Hypospadias
b) Bowen disease
c) Balanoposthitis
d) Epispadias
e) Paraphimosis

17. A 35-year-old healthy man desires a permanent form of contraception. He has a vasectomy performed. He is advised of the potential complications of this procedure. Which of the following is most likely to result from prior vasectomy?

a) Varicocele
b) Orchitis
c) Hydrocele
d) Testicular torsion
e) Sperm granuloma

18. An autopsy study is conducted to document testiclar abnormalities in adult male patients who had an accidental manner of death. In some of these cases, the patients had grossly normal testes but microscopic examination showing a patchy pattern of atrophy of testicular tubules. Review of their medical histories showed that they were fertile. Which of the following infections is most likely to produce the findings seen in these men?

a) Human papillomavirus
b) Chlamydia trachomatis
c) Neisseria gonorrheae
d) Mumps virus
e) Herpes simplex virus

Patho Repro

19. A 21-year-old sexually active man is notified by the health department that his last sexual contact 3 weeks prior has a positive serologic test for syphilis. He goes to see his physician that day. Which of the following findings in this man is most likely to be indicative of his acquisition of this infection?

a) Positive VDRL in the CSF
b) Testicular gumma on biopsy
c) Mucocutaneous rash
d) Penile chancre
e) Genital condyloma lata

20. A 40-year-old man has noted gradual enlargement of his scrotum, more on the right side, for the past 2 years. There is no associated pain, but the size is becoming uncomfortable. Physical examination reveals that the right side of the scrotum is enlarged to three times the size of the testis palpable on the left. This mass transilluminates. There is no tenderness on palpation. There is no inguinal lymphadenopathy. An ultrasound reveals a 5 cm thin-walled cystic fluid-filled area in the region of the right testis. Which of the following is the most likely diagnosis?

a) Seminoma
b) Torsion
c) Hydrocele
d) Varicocele
e) Syphilitic orchitis

21. A healthy 17-year-old adolescent has a routine check of his health status. On physical examination pearly penile papules are noted at the edge of the glans penis. He is circumcised. There is no erythema or urethral discharge. He is not sexually active. Which of the following is the most likely diagnosis?

a) Bowen disease
b) Human papillomavirus infection
c) Normal variation
d) Balanitis with Staphylococcus aureus
e) Phimosis

22. A 55-year-old man has experienced pain with urination for the past week. On physical examination his prostate is slightly enlarged and mildly tender to palpation on digital rectal examination. His temperature is 37.6 C. Laboratory studies show is WBC count is 12,910/microliter. Urine culture grows >100,000 Escherichia coli. His serum prostate specific antigen is 6 ng/mL. He receives antibiotic therapy and improves. This condition recurs 5 times in the next 6 months. Which of the following diseases is he most likely to have?

a) Nodular prostatic hyperplasia
b) Prostatic adenocarcinoma
c) Chronic bacterial prostatitis
d) Urothelial carcinoma of urethra
e) Prostodynia

Hothifa Read

Patho Repro

23. A clinical study is performed using subjects diagnosed with testicular neoplasia. The laboratory findings of these subjects are reviewed. A subset of these subjects is found to have had an elevated serum alpha-fetoprotein. Which of the following types of testicular neoplasm is this subset of men most likely to have had?

a) Seminoma
b) Embryonal carcinoma
c) Leydig cell tumor
d) Choriocarcinoma
e) Teratoma

24. A clinical study is performed to determine the optimal means for diagnosis of sexually transmitted diseases (STDs). The clinical and laboratory findings in subjects diagnosed with STDs are reviewed. A group of subjects is found to have Chlamydia trachomatis infection. Which of the following labortory methods is most likely to be useful in diagnosis of C. trachomatis in these subjects?

a) Darkfield microscopic examination of exudate or secretions
b) Cytologic smear
c) Tissue biopsy
d) Enzyme immunoassay
e) Microbiologic culture

25. A 30-year-old G3 P2 woman gives birth at term following an uncomplicated pregnancy to a male infant. On physical examination he has an abnormal opening of the urethra onto the ventral surface of the penis for a distance of 0.3 cm. Which of the following is the most likely diagnosis?

a) Hypospadias
b) Exstrophy
c) Phimosis
d) Epispadias
e) Cryptorchidism

26. A 45-year-old man complains of dysuria for the past week. On physical examination he is uncircumcised and has erythema and edema of the glans penis, with inability to retract the foreskin over the glans penis. Which of the following infectious agents is most likely to be associated with these findings?

a) Human papillomavirus
b) Staphylococcus aureus
c) Herpes simplex virus
d) Treponema pallidum
e) Sarcoptes scabiei

Hothifa Read

Patho Repro

27. A pathologic study is performed in male subjects ranging from 50 to 100 years of age who had serum prostate specific antigen levels above 15 ng/mL and who underwent prostatectomy following biopsies in which there was adenocarcinoma on microscopic examination. The resected prostates were examined pathologically and the sites of the adenocarcinomas mapped within the prostate. In which of the following regions of the prostate are these adenocarcinomas most likely to arise?

a) Anterior fibromuscular stroma
b) Central zone
c) Peripheral zone
d) Periurethral zone
e) Transitional zone

28. A 21-year-old man notes the presence of a lesion on his penis for the past week. On physical examination there is a solitary 0.7 cm diameter circumscribed area of ulceration on the dorsal aspect of his penis just proximal to the glans. This ulcer has a firm erythematous base containing minimal grey exudate. Which of the following is the most cost effective method for laboratory diagnosis of this man's lesion?

a) Darkfield microscopy
b) Cytologic smear
c) Tissue biopsy
d) Enzyme immunoassay
e) Microbiologic culture

29. A clinical study is conducted to determine the survival following treatment for testicular neoplasms utilizing subjects recorded into a hospital tumor registry. Treatments included surgery, chemotherapy, and radiation therapy. The patient records are reviewed to determine the pathologic diagnosis and the 5 year survivals for these patients. Which of the following types of testicular neoplasm is most likely to have responded best to radiation therapy?

a) Choriocarcinoma
b) Embryonal carcinoma
c) Seminoma
d) Teratoma
e) Yolk sac carcinoma

30. A 35-year-old man has a routine check of his health status. On physical examination the prepuce cannot be fully retracted from the glans of his penis. No other abnormalities are noted. Which of the following is the most likely diagnosis?

a) Balanoposthitis
b) Epispadias
c) Exstrophy
d) Hypospadias
e) Phimosis

Hothifa Read

Patho Repro

31. A double blind study is conducted involving men who have been symptomatic from urinary frequency and hesitancy for 5 or more years. One group men receive a pharmacologic agent designed to reduce the synthesis of dihydrotestosterone in prostatic stromal cells. Another group receives a placebo. The group receiving the drug has a statistically significant decrease in symptoms. Which of the following enzymes is this pharmacologic agent most likely to block?

a) 5-alpha-reductase
b) Aromatase
c) 17-alpha-hydroxylase
d) Desmolase
e) 11-beta-hydroxylase

32. A 2-year-old boy is brought to the physician because his mother has observed that his scrotum is no longer symmetrical (she is a geometry teacher). On physical examination the child has enlargement of the left testis. An ultrasound scan shows a 2 cm solid mass within the body of the testis. Laboratory studies show a serum alpha-fetoprotein of 226 ng/mL. Which of the following neoplasms is this child most likely to have?

a) Leydig cell tumor
b) Neuroblastoma
c) Rhabdomyosarcoma
d) Teratoma
e) Yolk sac tumor

33. A 43-year-old man has noted a lesion on his penis for the past year. On physical examination there is a 0.9 cm diameter rough, tan, firm, slightly raised area at the right lateral base of the glans. He is uncircumcised, and there is difficulty in retracting the foreskin. Which of the following is the most likely diagnosis?

a) Angiokeratoma
b) Balanitis xerotica obliterans
c) Bowen disease
d) Hard chancre
e) Lichen simplex chronicus
f) Paraphimosis

34. A 32-year-old has noted bilateral breast enlargement over the past 7 months. On physical examination there is bilateral gynecomastia without tenderness or masses. His external genitalia appear normal. An ultrasound scan reveals a 1 cm solid mass within the body of the right testis. Laboratory studies show a serum testosterone of 550 ng/dL and estradiol of 36 pg/mL. His serum alpha-fetoprotein is 9 ng/mL and HCG non-detectable. Which of the following neoplasms is this man most likely to have?

a) Choriocarcinoma
b) Embryonal carcinoma
c) Leydig cell tumor
d) Seminoma
e) Yolk sac tumor

Hothifa Read

Patho Repro

Female

1. A 33-year-old woman has been on oral contraceptives for a year. She has noted vaginal bleeding for the past 5 weeks. The bleeding is not severe, but it occurs nearly every day. On pelvic examination, there is a 0.7 cm polypoid mass noted to extend outward from the endocervical region. The ectocervix appears normal. The uterus is normal in size. The adnexae have no palpable masses. A biopsy of this lesion is peformed. Which of the following pathologic findings is most likely to be found on microscopic examination of this lesion?

a) Endocervical adenocarcinoma
b) Clear cell adenocarcinoma
c) Microglandular hyperplasia
d) Sarcoma botryoides
e) Endocervical polyp
f) Follicular cervicitis

2. A 48-year-old woman has noted a small amount of irregular vaginal bleeding for the past 2 months. She has a pelvic examination that reveals no cervical lesions, and a Pap smear that shows no abnormal cells. Next, an endometrial biopsy is performed, and there is microscopic evidence for endometrial hyperplasia. An abdominal ultrsound reveals a right ovarian mass. Which of the following neoplasms is this woman is most likely to have?

a) Mature cystic teratoma
b) Choriocarcinoma
c) Sertoli-Leydig cell tumor
d) Fibrothecoma
e) Krukenberg tumor

3. A 44-year-old perimenopausal woman has had vaginal bleeding for the past 6 months. On physical examination she has an enlarged, nodular uterus. A hysterectomy is performed. The surgeon notes several 0.2 to 1 cm translucent, smooth-surfaced, thin-walled, fluid-filled cysts near the fimbriated end of the right fallopian tube. Which of the following is the most likely diagnosis for these cysts?

a) Gartner duct cysts
b) Krukenberg tumors
c) Parovarian cyst
d) Pelvic inflammatory disease
e) Mucinous cystadenomas

Hothifa Read

Patho Repro

4. A 36-year-old woman has had episodes of lower abdominal and pelvic pain for the past 10 years. A bimanual pelvic examination reveals no abnormalities. A Pap smear is negative. She has an abdominal ultrasound scan that reveals no abnormalities. Finally, she undergoes laparoscopy, and her physician notes the presence of several 0.2 to 0.5 cm brown lesions located over the serosal surfaces of the uterus, fallopian tubes, and appendix. These lesions are excised. Which of the following microscopic findings is most likely to be present in these lesions?

a) Endometrial glands and stroma
b) Mesothelioma
c) Metastatic carcinoma
d) Small capillary proliferation
e) Caseating granulomas

5. A 47-year-old woman has noted a pressure sensation, but no pain, in her pelvic region for the past 5 months. On physical examination there is a right adnexal mass. An ultrasound scan shows a 10 cm fluid-filled cystic mass in the right ovary. A fine needle aspirate of the mass is performed and cytologic examination of clear fluid aspirated from the mass reveals clusters of malignant epithelial cells surrounding psammoma bodies. Which of the following neoplasms is she most likely to have?

a) Endometrial adenocarcinoma
b) Ovarian serous cystadenocarcinoma
c) Mesothelioma
d) Ovarian mature cystic teratoma
e) Adenocarcinoma of fallopian tube

6. A representative of the law firm of Flotsam, Flotsam & Jetsam enters your office one day and serves you wtih a subpoena. The subpoena requires you to appear in regard to litigation by one of your former patients, a 31-year-old woman who is claiming that your malpractice led to medical expenses, pain, and suffering because she developed invasive cervical carcinoma. She was last seen in your office 10 years ago. She had been your patient for 5 years, receiving Pap smears in 4 of those 5 years. Your records indicate that she had no abnormal Pap smears. After discussion with your malpractice carrier's attorney, which of the following conclusions is most appropriate?

a) The patient should have continued to return for yearly Pap smears
b) You are at fault in this case and should avoid a trial
c) The laboratory to which the Pap smears were sent is at fault for missing abnormal cells
d) Nothing anyone could have done would have prevented this carcinoma
e) The patient's health insurer is at fault for not covering the full cost of Pap smear testing

Hothifa Read

Patho Repro

7. A quality assurance (QA) project is done by a group of physicians staffing an outpatient clinic to study rates of false negative Pap smears. The QA project reveals that one physician has accounted for half of all the false negative Pap smears collected by the group over the prior year, when compared to follow-up testing. The physician's collection techniques are analyzed. Of the following procedures practiced, which is the only one that is appropriate?

a) Wrote the patient's name on the slides
b) Air-dried the slides prior to shipping
c) Used lubricant on the speculum during collection
d) Scheduled the patient visit during the menstrual phase of her cycle
e) Advised the patient to douche the day prior to the appointment

8. A 30-year-old infertile woman has had episodic lower abdominal and pelvic pain for 2 years. A physical examination, including pelvic exam, reveals no abnormalities. A Pap smear shows only a few trichomonads and no dysplastic cells. A laparoscopy is performed, and the gynecologist notes the presence of several blue to red 0.2 to 0.4 cm slighted raised lesions scattered on the pelvic peritoneum in the cul-de-sac and broad ligaments. Which of the following is the most likely diagnosis?

a) Metastatic adenocarcinoma
b) Neisseria gonorrheae infection
c) Endometriosis
d) Candidiasis
e) Leiomyomata

9. A 43-year-old woman has noted menstrual periods that have been exceptionally heavy, lasting 6 to 8 days, for 4 months. She has also noted minor intermenstrual bleeding. On physical examination her uterine cervix appears normal, and a Pap smear shows no abnormal cells. Pelvic examination reveals that the uterus is enlarged to twice normal size and is nodular. There are no adnexal masses. Which of the following is the most likely diagnosis?

a) Endometrial carcinoma
b) Leiomyomata
c) Ectopic pregnancy
d) Endometriosis
e) Secondary syphilis

Patho Repro

10. A 50-year-old woman has noted increasing abdominal enlargement for the past year. On physical examination, there is a fluid wave, but no tenderness. Bowel sounds are present. She has no vaginal bleeding. An abdominal ultrasound reveals bilateral 10 and 7 cm adnexal masses. At surgery there are bilateral mass lesions of the ovaries. A total abdominal hysterectomy is performed. Pathologic examination of the ovarian masses reveals that they are unilocular, filled with watery fluid, and covered with papillary excresences on all surfaces. Which of the following neoplasms is this woman most likely to have?

a) Granulosa-theca cell tumors
b) Mature cystic teratomas
c) Fibrosarcoma with metastases
d) Serous cystadenocarcinomas
e) Clear cell carcinomas

11. A 28-year-old woman goes to her physician for a routine examination. She is sexually active. Pelvic examination reveals no abnormalities. A Pap smear is obtained. The cytopathology report indicates the presence of severely dysplastic cells. A biopsy of the cervix is performed, and on microscopic examination shows cervical intraepithelial neoplasia III (CIN III). Infection with which of the following organisms is most likely to cause her disease?

a) Herpes simplex virus infection
b) Epstein-Barr virus
c) Candida albicans
d) Human papillomavirus
e) Trichomonas vaginalis

12. A 23-year-old woman is admitted to the hospital with a one day history of increasing obtundation. On physical examination her temperature is 37.3 C, pulse 85/minute, respirations 16/minute, and blood pressure 90/45 mm Hg. A culdocentesis yields no blood. Laboratory studies show a positive pregnancy test. Her CBC shows a WBC count of 11,400/microliter, Hgb 10.6 g/dL, Hct 31.1%, MCV 95 fL, and platelet count 26,400/microliter. Schistocytes are noted on the peripheral blood smear. Her protime is 44 sec, partial thromboplastin time 61 sec, and D-Dimer 16 microgm/mL. A urinalysis dipstick examination shows no blood, protein, or glucose. Which of the following problems is most likely to explain her condition?

a) Placental infarction
b) Eclampsia
c) Amniotic fluid embolus
d) Retained dead fetus
e) Ruptured tubal ectopic

Hothifa Read

Patho Repro

13. A 22-year-old woman passed grape-like masses of tissue per vagina in the 16th week of her first pregnancy. She had not felt any fetal movement at any time. On physical examination she measured 18 weeks in size. A D&C is then performed, yielding about 1000 cc of 0.5 to 1.5 cm fluid-filled vesicles. Microscopic examination of this tissue shows large avascular villi along with trophoblastic proliferation. Which of the following is the best method to employ for her follow-up?

a) Chest radiograph
b) Serum beta-HCG
c) Endometrial biopsy
d) Pelvic ultrasound
e) Pap smear

14. A 23-year-old woman goes to the emergency room because of the sudden onset of lower abdominal pain. Pelvic examination reveals a normal sized uterus and normal appearing cervix and vagina. However, there is marked tenderness upon palpation of the left adnexal region. A transvaginal ultrasound demonstrates no intrauterine gestational sac, but there is a 2 cm left adnexal mass. Culdoscocentesis yields bloody fluid. Which of the following is most useful procedure to perform at this point for the patient?

a) Serum complement determination
b) Urinalysis with microscopic examination
c) Pap smear
d) Serum beta-HCG
e) Endometrial biopsy

15. A 20-year-old woman has had irregular menstrual bleeding for the past 6 months. On physical examination there are no abnormal findings. Laboratory studies show a negative pregancy test. A D&C is performed and microscopic examination shows dyssynchronous endometrial glands and stroma of anovulatory cycles. Following the procedure she ceases to have menstrual bleeding. Which of the following is the most likely diagnosis?

a) Endometriosis
b) Asherman syndrome
c) Prolactinoma
d) Ovarian failure
e) Oral contraceptive use

16. A 15-year-old girl has had pelvic pain for the past 3 months. She refuses physical examination. She has not had any sexual activity. She has not had a menstrual period. Which of the following is the most likely diagnosis?

a) Cervical condyloma
b) Endometriosis
c) Cervical gonorrhea
d) Imperforate hymen
e) Ruptured Bartholin's cyst

Hothifa Read

Patho Repro

17. A 64-year-old woman has had itching with irritation of the vulvar region, along with vaginal dryness, for the past 8 months. On physical examination there are pale grey patches from 1 to 2 cm in size on the vulva. Biopsy of one lesion is performed and on microscopic examination shows epithelial thinning, dermal fibrosis, and perivascular chronic inflammation. Which of the following is the most likely diagnosis?

a) Squamous cell carcinoma
b) Lichen sclerosus
c) Condyloma acuminatum
d) Adenosis
e) Extramammary Paget's disease

18. For the past year, a 50-year-old woman has noted that her menstrual periods have been exceptionally heavy, lasting 7 to 9 days. She has noted occasional minor intermenstrual bleeding. For the past 3 months, she has been taking supplemental dietary iron for iron deficiency anemia. On pelvic examination, the uterine cervix appears normal, but the uterus is enlarged to twice normal size. Transvaginal ultrasound reveals the presence of a 9 cm solid mass in the uterus. A hysterectomy is performed, and on gross inspection with sectioning the uterus a reddish-tan mass is found with a fleshy cut surface. Microscopically the mass is highly cellular, with spindle cells having hyperchromatic nuclei and 10 to 20 mitoses per high power field. Which of the following is the most likely diagnosis?

a) Endometrial polyp
b) Adenomyosis
c) Leiomyoma
d) Ectopic pregnancy
e) Leiomyosarcoma
f) Malignant mixed mullerian tumor

19. A 31-year-old G3 P2 woman is at 14 weeks gestation, but has noted a small amount of vaginal bleeding for the past 2 weeks. Laboratory studies show an HCG level of 650,000 U/L. An ultrasound shows a "snowstorm" for intrauterine contents but no identifiable fetus. A D&C is performed with evacuation of 500 mL of grape-like vesicles. A month later her vaginal bleeding persists and her serum beta-HCG is 35,000 U/L. Which of the following pathologic abnormalities is most likely to be present in this woman?

a) Pulmonary metastases
b) Tubal ectopic pregnancy
c) Endometritis
d) Placental site trophoblastic tumor
e) Invasive mole

Hothifa Read

Patho Repro

20. A 33-year-old woman and her husband have wanted a child, but she has been unable to conceive for the past 10 years. She has mild pelvic pain. She has regular menstrual cycles. On physical examination the cervix and vagina appear normal. The uterus and adnexal regions are normal on palpation. A pelvic ultrasound shows no lesions. A Pap smear is normal. Her husband's sperm count is normal. Which of the following is most likely to be the cause for her infertility?

a) Adenomyosis
b) Prolactinoma
c) Pelvic inflammatory disease
d) Teratoma
e) Chronic cervicitis

21. A 39-year-old woman had noted intermenstrual spotting of blood for the past 3 months. On pelvic examination, she is found to have a nodular 2 x 3 cm mass in the upper vagina. Biopsy of the mass is performed and on microscopic examination shows a clear cell carcinoma. Which of the following risk factors probably preceded development of this carcinoma?

a) Human papilloma virus infection
b) Previous endometriosis
c) Irregular menstrual cycles
d) Exposure to diethylstilbesterol in utero
e) Precocious pseudopuberty

22. A 19-year-old woman has noted the increasing size and number of warty lesions on her external genitalia for the past 5 years. On physical examination she has several pink-tan rounded 1 to 2 cm slightly raised lesions on the perineum and vulva. Biopsy of one of the lesions is performed and on microscopic examination demonstrates acanthosis of the squamous epithelium along with koilocytosis. Which of the following is the most appropriate interpretation of these findings?

a) The lesions are usually cystic.
b) Most often they occur in the endometrium.
c) There is an association with Candida infection.
d) She may develop a squamous cell carcinoma.
e) This condition is commonly seen in prepubertal males.

23.A 40-year-old woman has experienced pelvic discomfort for over a month, along with a 4 kg weight loss, nervousness, and diaphoresis. A pelvic examination reveals a large left adnexal mass that, on transvaginal ultrasound, appears as a discrete 10 cm cystic mass. The uterus appears normal in size. A Pap smear is normal. The mass is removed and on gross pathologic examination is filled with hair and sebum, along with solid tan areas next to the smooth-surfaced outer wall. Which of the following laboratory test findings is most likely to have been present just prior to her surgery?

a) Thyroxine of 11.3 microgm/dL
b) HCG of 45,000 IU/L
c) Potassium of 2.9 mmol/L
d) Estradiol of 1700 pg/mL
e) Cancer antigen 125 of 540 U/mL

Hothifa Read

Patho Repro

24. A 32-year-old G3 P2 pregnant woman goes for a routine prenatal check at 12 weeks. On physical examination she is found to be large for dates, and no fetal heart tones are audible. An ultrasound is performed and revealed that no fetus was present, only many echogenic cystic areas within the uterus. Which of the following is the most likely diagnosis?

a) Invasive mole
b) Partial hydatidiform mole
c) Placental site trophoblastic tumor
d) Choriocarcinoma
e) Complete hydatidiform mole

25. A 38-year-old woman goes to her physician for a routine examination. On physical examination there are no abnormal findings. A Pap smear is taken and cytologically there are dysplastic cells present. A cervical biopsy is performed. Microscopic examination shows dysplasia involving the full thickness of the cervical epithelium. Which of the following is the most likely diagnosis?

a) Cervical intraepithelial neoplasia III
b) Severe chronic cervicitis with Herpes simplex
c) Previous diethylstilbesterol (DES) exposure
d) Endocervical adenocarcinoma
e) Extramammary Paget disease

26. Two weeks following delivery of a term infant boy following an uncomplicated pregnancy, a 25-year-old woman still has a vaginal discharge consisting of dark brown, foul-smelling material. Her temperature is 37.7 C. On pelvic examination, the uterus is slightly enlarged and she has pelvic tenderness. Laboratory studies show her serum beta-HCG is negative. Which of the following conditions is she most likely to have?

a) Invasive mole
b) Degenerating leiomyoma
c) Sheehan syndrome
d) Endometriosis
e) Retained products of conception

27. A 39-year-old woman has had dysmenorrhea for 7 months. On pelvic examination, there are no adnexal masses, and the cervix appears normal, but the uterus is three times normal size. The uterus appears to be symmetrically enlarged on abdominal ultrasound, with no masses present and an endometrial cavity that is nearly normal in size. A Pap smear is normal. Her serum pregnancy test is negative. A total abdominal hysterectomy is performed. Which of the following microscopic findings is most likely to be present in her uterus?

a) Atypical glands invading through the uterine wall
b) Large avascular villi with trophoblastic proliferation
c) Hyperchromatic and pleomorphic smooth muscle cells
d) Extensive acute inflammation
e) Endometrial glands and stroma in the myometrium

Hothifa Read

Patho Repro

28. A 15-year-old girl has had irregular menstrual cycles for 5 months. She had menarche at age 13. There are no abnormal physical examination findings. An endometrial biopsy is taken on post-ovulatory day 9 and shows proliferative phase endometrium. Which of the following is the most likely diagnosis?

a) Adenomyosis
b) Anovulatory cycles
c) Endometrial adenocarcinoma
d) Leiomyomata
e) Oral contraceptive use
f) Ovarian thecoma

29. A 29-year-old woman has had dyspareunia for the past 2 months. She has had only one sexual partner--her husband. She is G2 P2. On physical examination there are no abnormal findings except for a small but slightly tender 1.5 cm mass located in the right lateral wall of her vagina. The lesion is excised. On gross examination this mass is cystic and fluid filled. On microscopic examination the cyst is lined by a cuboidal epithelium. Which of the following is the most likely etiology for this lesion?

a) Diethylstilbesterol exposure
b) Embryologic remnant
c) Gonoccocal infection
d) Metastatic adenocarcinoma
e) Oral contraceptive use

30. A 55-year-old woman has lower abdominal pain for the past 6 months. She had a simple hysterectomy performed 25 years before. On pelvic examination, she has a vagina that ends in a blind pouch, and a large left adnexal mass is palpable and is non-tender. At laparotomy, there is a 9 cm mass involving the left ovary. Microscopic examination reveals malignant glands resembling endometrial glands. What pathologic abnormality was her hysterectomy specimen most likely to have shown?

a) Endometriosis
b) Adenomyosis
c) Malignant mixed mullerian tumor
d) Chronic endometritis
e) Endometrial hyperplasia

Patho Repro

31. A 25-year-old woman is G2 P1. Her first pregnancy resulted in a normal term birth. Now at 15 weeks gestation, a prenatal checkup reveals that she has a blood pressure of 140/90 mm Hg. An ultrasound is performed that reveals no fetal cardiac motion. Misoprostil induction is performed for termination of the pregnancy. Examination of the malformed stillborn fetus reveals that it is small for gestational age and has 3,4 syndactyly bilaterally, an indented nasal bridge, and a two vessel cord. The placenta is small for gestation and has scattered 0.5 cm grape-like villi. A chromosome analysis performed on the placental tissue will most likely demonstrate which of the following karyotypes?

a) 46, XX
b) 69, XXY
c) 45, X
d) 47, XX, +18
e) 23, X
f) 47, XYY
g) 47, XXX

32. A 16-year-old girl has not begun menstruation. Physical examination reveals that she has breast development, but a short vagina and no palpable uterus or adnexae, only bilateral inguinal masses. She appears otherwise normal. Which of the following laboratory tests would be most appropriate to order on this girl?

a) Chromosome analysis
b) Serum estrogen
c) Assay for luteinizing hormone
d) Serum cortisol
e) Serum testosterone

33. A 38-year-old healthy woman has had a white, curd-like vaginal discharge for the past week. There is no bleeding. A Pap smear demonstrates normal appearing squamous epithelial cells along with scattered neutrophils and budding cells with pseudohyphae. Which of the following infectious agents is most likely to be present in this woman?

a) Treponema pallidum
b) Neisseria gonorrhea
c) Chlamydia trachomatis
d) Herpes simplex
e) Escherichia coli
f) Gardnerella vaginalis
g) Trichomonas vaginalis
h) Candida albicans

Patho Repro

34. A 35-year-old woman has had dull pelvic pain for 4 months. A pelvic examination reveals a normal appearing cervix, a normal sized uterus, and a large tender right adnexal mass. Ultrasound reveals an 8 cm mass cystic, fluid-filled mass involving the right adnexal region. At laparotomy, there are many filmy fibrous adhesions in the pelvis. The mass is excised and on gross examination is found to have a thin wall and is filled with purulent exudate. Microscopically, there are thin remnants of fallopian tube and ovary comprising the wall of the mass, with numerous neutrophils filling the lumen. Which of the following infectious agents is most likely to have produced these findings?

a) Human papillomavirus
b) Mycobacterium tuberculosis
c) Trichomonas vaginalis
d) Candida albicans
e) Neisseria gonorrheae

35. Abnormal uterine bleeding for several months prompts a 62-year-old woman to see her physician. She has never been pregnant and went through menopause 15 years previously. On physical examination her BMI is 33. An endometrial biopsy is performed and on microscopic examination shows a well-dffierentiated endometrial adenocarcinoma. Which of the following ovarian neoplasms is she most likely to have?

a) Papillary serous cystadenocarcoma
b) Krukenberg tumor
c) Mucinous cystadenoma
d) Granulosa cell tumor
e) Immature teratoma

36. A 28-year-old woman develops the sudden onset of severe lower abdominal pain. On physical examination there is tenderness to palpation of the right lower quadrant. Laboratory studies show her serum pregnancy test is positive. An ultrasound scan does not reveal a gestational sac in the uterus, but there is a right adnexal mass. The development of these findings is most closely related to past infection with which of the following organisms?

a) Treponema pallidum
b) Human papillomavirus
c) Neisseria gonorrheae
d) Candida albicans
e) Group B Streptococcus

Patho Repro

37. A 45-year-old woman has had irregular menstrual periods for the past 9 months. On physical examination she has an enlarged uterus. An ultrasound scan shows a 9 cm solitary, solid mass in the uterus. A total abdominal hysterectomy is performed. Gross examination of the irregular reddish-tan mass located in the myometrium shows bundles of smooth muscle cells along with heterogenous elements of pleomorphic cartilagenous cells. There are also areas with poorly differentiated gland formation. Mitotic figures are frequent. Which of the following neoplasms is she most likely to have?

a) Leiomyosarcoma
b) Sarcoma botyroides
c) Malignant mixed mullerian tumor
d) Endolymphatic stromal myosis
e) Leiomyoma

38. A 72-year-old woman has been feeling tired for the past year. She has had episodes of vaginal bleeding during this time. On physical examination there are no abnormal findings. Laboratory studies show Hgb 9.1 g/dL, Hct 26.5%, MCV 72 fL, platelet count 158,000/microliter, and WBC count 7150/microliter. An endometrial biopsy is performed and on microscopic examination shows atypical adenomatous hyperplasia. Which of the following is the most likely risk factor for development of her disease?

a) Human papillomavirus infection
b) Long term use of an intrauterine contraceptive device
c) Chronic endometritis
d) Pelvic inflammatory disease
e) Unopposed estrogenic stimulation

39. A 56-year-old G0 P0 woman reports vaginal bleeding in the past 2 months. Her last menstrual period was 9 years ago. On physical examination there are no abnormal findings. Which of the following procedures is most appropriate to perform on this woman?

a) Endometrial biopsy
b) Pap smear
c) Vaginal culture
d) Colposcopy
e) CT scan

40. A 50-year-old woman has experienced mild pelvic discomfort for 3 months. On physical examination there are bilateral adnexal masses. A pelvic CT scan reveals irregular unilocular cystic, bilateral mass lesions in the region of the ovaries. One is 10 cm and the other is 8 cm in size. Which of the following types of neoplasm is most likely to be present in this woman?

a) Mature cystic teratoma
b) Serous cystadenocarcinoma
c) Endometrioid carcinoma
d) Fibrothecoma
e) Mucinous cystadenoma

Hothifa Read

Patho Repro

41. A 35-year-old woman has been bothered by chronic pelvic pain for the past 5 years. On physical examination there are no abnormal findings. A laparoscopy is performed and there are many filmy fibrous adhesions among the fimbriated end of the fallopian tube, adjacent ovary, and adjacent loops of small bowel. A year later she has the sudden onset of severe lower abdominal pain and a culdocentesis yields blood. A pregnancy test is positive. Which of the following diseases is most likely to cause her findings?

a) Adenocarcinoma
b) Adenomyosis
c) Gonorrhea
d) Molar pregnancy
e) Human papillomavirus infection

42. A 46-year-old woman has had irregular menometrorrhagia for the last 2 months. Pelvic examination reveals a normal-sized uterus and a normal-appearing cervix. A Pap smear shows no abnormal cells. An endometrial biopsy is performed and on microscopic examination shows a fragment of a polypoid mass covered by columnar cells and containing cystically dilated endometrial glands. Which of the following is the most likely diagnosis?

a) Adenomatous hyperplasia
b) Endometritis
c) Adenocarcinoma
d) Endometrial polyp
e) Adenomyosis

43. A 30-year-old has a workup for infertility; she has never undergone menarche. On physical examination she is at the 5th %ile in height. She has a broad, shield-like chest, poor breast development, and short fourth metacarpals. She has a loud pansystolic heart murmur. Pulses are stronger in her upper extremities than her lower extremities. A pelvic CT scan shows small, elongated ovaries. Which of the following is the most likely diagnosis?

a) Sheehan syndrome (postpartum pituitary necrosis)
b) Prolonged contraceptive use
c) Polycystic ovaries (Stein-Leventhal syndrome)
d) Pituitary adenoma secreting prolactin
e) Monosomy X (Turner syndrome)

44. A 61-year-old woman has had increasing nausea and vomiting for 6 months accompanied by a 6 kg weight loss. On physical examination she appears cachectic. An upper GI endoscopy is performed and there is a 3 x 5 cm mass located on the lesser curvature of the stomach. Which of the following ovarian neoplasms is she most likely to have?

a) Krukenberg tumor
b) Endometrioid carcinoma
c) Serous cystadenocarcinoma
d) Clear cell carcinoma
e) Mucinous cystadenocarcinoma

Hothifa Read

Patho Repro

45. A 35-year-old woman has had amenorrhea for the past year. She has not lost or gained more than 1 kg during that time. Her voice has gotten deeper. On physical examination she has prominent facial hair growth. Her breasts are atrophic. There is a palpable left adnexal mass. A Pap smear shows no dysplastic cells, but the maturation pattern is prepubertal. She is taking no medications. Which of the following ovarian neoplasms is she most likely to have?

a) Brenner tumor
b) Endometrioid carcinoma
c) Fibroma
d) Mucinous cystadenoma
e) Serous cystadenocarcinoma
f) Sertoli-Leydig cell tumor
g) Teratoma

46. A 27-year-old woman has noted intermenstrual spotting of blood in the past month. She has a history of vaginal yeast infections in the past, but does not currently have a vaginal discharge. She has a history of multiple sexual partners, is nulliparous, and is currently taking oral contraceptives. A pelvic examination reveals a 1 cm polypoid mass protruding from the endocervical canal. The uterus is normal in size and no adnexal masses are palpable. A biopsy of the mass reveals microglandular endocervical hyperplasia. A Pap smear shows no evidence for dysplasia. Which of the following risk factors is most likely to have led to development of her endocervical mass?

a) Oral contraceptive use
b) Candidiasis
c) Douching
d) Human papillomavirus infection
e) Spontaneous abortion

47. A 31-year-old woman who works as a banking executive is hampered by episodes of pelvic pain that always seem to occur when there is an important committee meeting. On physical examination there are no abnormal findings. A Pap smear is normal. She undergoes laparoscopy and there are groups of reddish blue to brownish 1 to 5 mm nodules scattered on the serosal surfaces of the uterus, fallopian tubes, and bladder. Which of the following is the most likely diagnosis?

a) Pelvic inflammatory disease from Neisseria gonorrheae
b) Asherman syndrome
c) Choriocarcinoma with metastases
d) Serous cystadenocarcinoma
e) Endometriosis

Hothifa Read

Patho Repro

48. A 35-year-old woman has never had a menstrual period. On physical examination she is short with almost no breast development. She has a "web neck". An abdominal CT scan shows "streak" ovaries and a small uterus. On chromosome analysis, which of the following karyotypes is she most likely to have?

49. A 29-year-old woman is in the 16th week of her first pregnancy when an ultrasound examination reveals that a small for gestational age fetus is present. The fetus is stillborn at 20 weeks. The placenta shows findings of a partial hydatidiform mole. On chromosome analysis, which of the following fetal karyotypes is most likely to be present?

a) 45, X 48
b) 46, XY
c) 46, XX
d) 47, XXY
e) 47, XXX
f) 69, XXY 49
g) 92, XXXX

50. A 64-year-old woman has had vaginal bleeding for the past week. On physical examination her uterus is enlarged. An abdominal CT scan shows a circumscribed 7 cm myometrial mass. A total abdominal hysterectomy is performed. On gross examination the mass has a soft, reddish tan cut surface. On microscopic examination it is composed of spindle cells. Which of the following neoplasms is she most likely to have?

51. A 5-year-old girl was noted to have vaginal bleeding yesterday. On physical examination she is normally developed. There is a palpable vaginal mass. On ultrasound scan there is a solid 3 cm upper vaginal mass. Which of the following neoplasms is she most likely to have?

a) Leiomyosarcoma 50
b) Adenosarcoma
c) Malignant mixed mullerian tumor
d) Malignant teratoma
e) Sarcoma botryoides 51

Hothifa Read

Patho Repro

52. A 30-year-old woman has had lower abdominal pain for the past 3 years, but no vaginal bleeding, and her menstrual cycles are regular. On physical examination the uterus and adnexae are normal in size. A Pap smear is normal. Laparoscopy is performed and there are dark brown lesions ranging in size from 0.1 to 0.5 cm seen on the uterine serosa. A biopsy of one lesion is taken and on microscopic examination shows endometrial glands and stroma. Which of the following is the most likely diagnosis?

53. A 40-year-old has had metrorrhagia for the past 6 months. On physical examination the cervix appears normal but an enlarged, nodular uterus is felt on bimanual examination. Which of the following is the most likely diagnosis?

a) Adenomyosis
b) Endometriosis 52
c) Endocervical polyp
d) Leiomyomata 53
e) Endometritis

54. A 31-year-old woman has had discomfort with intercourse for the past 5 months. On physical examination there is a tender nodule palpated beneath the vaginal mucosa just inside the vestibule on the left. An ultrasound scan shows a discrete cystic 2 cm lesion. It is drained of mucoid fluid and does not recur. Which of the following is the most likely diagnosis?

a) Accessory breast
b) Bartholin cyst
c) Epidermal inclusion cyst
d) Gartner duct cyst
e) Nabothian cyst

55. A 53-year-old woman has noted vaginal bleeding and pelvic discomfort for the past 9 months. On physical examination there is a bulky, polypoid uterine mass protruding from the vagina. The uterus appears enlarged. An ultrasound scan shows the mass is solid. Which of the following neoplasms is she most likely to have?

a) Malignant teratoma
b) Clear cell carcinoma
c) Sarcoma botryoides
d) Malignant mixed mesodermal tumor
e) Endometrial carcinoma
f) Squamous cell carcinoma

Patho Repro

56. A 40-year-old woman had a thyroidectomy for follicular carcinoma. Despite not taking thyroid hormone replacement medication, she does not become hypothyroid. Which of the following ovarian neoplasms is she most likely to have?

a) Choriocarcinoma
b) Brenner tumor
c) Mucinous cystadenoma
d) Serous cystadenocarcinoma
e) Struma ovarii

57. A 31-year-old woman is in the second trimester of her first pregnancy. On physical examination she is large for dates. No fetal heart tones are noted. On ultrasound scan no fetus is present. Four liters of soft tan grape-like tissue are evacuated via D & C from Cytogenetic analysis of this tissue is most likely to show which of the following karyotypes?

a) 47, XXY
b) 69, XXY
c) 46, XX
d) 47, XY, +18
e) 23 X

58. A 46-year-old woman has had irregular menses for 6 months. Pelvic examination is normal, and an abdominal ultrasound reveals no mass lesions, and the uterus appears normal in size. An endometrial biopsy is performed and on microscopic examination shows a proliferative pattern. Which of the following is the most likely diagnosis?

a) Anovulatory cycles
b) Asherman syndrome
c) Adenomyosis
d) Ectopic pregnancy
e) Gonorrheal infection

59. A 59-year-old woman has noted scant vaginal bleeding for the past 2 months. On physical examination her BMI is 34. Her blood pressure is 160/100 mm Hg. An endometrial biopsy is performed and on microscopic examination shows atypical adenomatous hyperplasia. Which of the following conditions is most likely to promote the development of her disease?

a) Unopposed estrogenic stimulation
b) Human papillomavirus infection
c) Long term oral contraceptive use
d) Chronic endometritis
e) Pelvic inflammatory disease

Patho Repro

60. A 53-year-old woman has had marked abdominal enlargement over the past year. On physical examination the abdomen is distended but not painful to palpation. It is not possible to palpate a specific structure. An abdominal CT scan shows a large 12 cm diameter mass that is multiloculated that fills the pelvis. There is marked fluid accumulation in the peritoneal cavity. Which of the following ovarian neoplasms is she most likely to have?

a) Endometrioid carcinoma
b) Brenner tumor
c) Mucinous cystadenoma
d) Serous cystadenocarcinoma
e) Dysgerminoma

61. A 19-year-old woman goes to the clinic because of burning pain on urination. On physical examination there are no abnormal findings. A Pap smear is taken. A urethral culture grows Chlamydia trachomatis. The cytologic report of the Pap smear shows minimal dysplasia. A cervical biopsy is performed, and there are dysplastic cells located in the upper third of the cervical epithelium. Which of the following is the most likely diagnosis?

a) Inflammatory atypia
b) Cervical intraepithelial neoplasia I
c) Cervical intraepithelial neoplasia II
d) Cervical intraepithelial neoplasia III
e) Squamous cell carcinoma

62. A clinical study is performed with subjects who are women with normal menstrual periods and not taking oral contraceptives. Endometrial biopsies are obtained on each day of their menstrual cycle. This is done over a 3 year period. The biopsies are examined microscopically, and the pattern of changes is recorded. Analysis of the data shows that there is one part of the menstrual cycle that tends to be the same length in all of the women, regardless of variations in total length of the menstrual cycle among these women. Which part of the cycle is most likely to be constant?

a) Early proliferative phase
b) Late proliferative phase
c) Secretory phase
d) Ovulatory phase
e) Menstrual phase

63. A 22-year-old woman has experienced pain in her genital region for the past week. On physical examination there are 5 sharply demarcated shallow 0.2 to 0.4 cm diameter ulcerations of her vulva which are erythematous and extremely tender. Which of the following pharmacologic agents is most likely to be effective in treating this woman?

a) Acetaminophen
b) Acyclovir
c) Amphotericin B
d) Aspirin
e) Azithromycin

Hothifa Read

Patho Repro

64. A 63-year-old woman has been bothered by an area of iching, red skin on her vulva for the past 4 years. She has used topical corticosteroid-containing creams with no relief. On physical examination, there is a 1 x 3 cm area of the left labia with an erythematous, eczematous appearance. A biopsy is taken and shows clusters of large cells within the squamous epithelium. These cells have clear nuclei and abundant clear cytoplasm which is PAS positive. Which of the following is the most likely diagnosis?

a) Condyloma acuminata
b) Lichen sclerosus
c) Paget disease
d) Syphilis
e) Vulvar intraepithelial neoplasia

65. A 36-year-old woman has noted intermenstrual spotting of blood during the past week. On physical examination there are no lesions of the external genitalia or the vagina. The ectocervix has a 1 cm diamter area at 5 o'clock that is roughened and erythematous. She has no lymphadenopathy. A Pap smear shows dysplastic cells. The lesion is excised and on microscopic examination shows full thickness dysplasia and microinvastion beneath the basement membrane for 1 mm. The margins are clear. Which of the following is the most likely 5-year survival for this woman?

a) 30%
b) 55%
c) 70%
d) 85%
e) 100%

66. A 28-year-old woman is 3 weeks postpartum but notes lower abdominal pain. On physical examination there are no abnormal findings except for tenderness on movement of the uterus. An endometrial biopsy is performed and on microscopic examination shows a non-secretory pattern of endometrium with stromal and glandular infiltration by lymphocytes, plasma cells, and macrophages. Laboratory studies show her HCG level is <4 U/L. Which of the following is the most likely diagnosis?

a) Invasive hydatidiform mole
b) Mycobacterium tuberculosis infection
c) Pelvic inflammatory disease
d) Retained products of conception
e) Sheehan syndrome

Hothifa Read

Patho Repro

67. A 36-year-old G1 P1 woman has noted abdominal discomfort with a feeling of heaviness for the past 5 months. On physical examination there is a pelvic mass. An abdominal ultrasound scan shows a 15 cm cystic mass in the region of the right ovary. A peritoneal washing reveals no abnormal cells. A right oopherectomy is performed. On gross examination the mass has a thin wall and is lined by atypical cuboidal epithelium, some ciliated, forming a few small papillations with stratification of the epithelium. Ocasional psammoma bodies are present. Rare mitoses are seen. There is no stromal invasion. Which of the following neoplasms does this woman most likely have?

a) Borderline serous tumor
b) Cystadenocarcinoma
c) Dysgerminoma
d) Endometrioid carcinoma
e) Immature teratoma

Hothifa Read

Patho Repro

Brest

1. A 52-year-old woman has noted a lump in her breast for the past 2 months. On physical examiantion there is a firm 2 to 3 cm mass palpable in the upper outer quadrant of the right breast. There are no palpable axillary nodes. A lumpectomy with axillary node dissection is performed. The breast lesion is found to have positive immunohistochemical staining for HER2/neu (c-erb B2). Staining for estrogen and progesterone receptors is negative. Which of the following additional treatment options is most likely to be efficacious in this woman?

a) Radical mastectomy
b) Tamoxifen
c) Traztuzumab
d) St. John's wort
e) Vancomycin

2. A 47-year-old woman undergoes routine mammographic screening and has an abnormal mammogram with multiple small areas of increased density, though a single distinctive mass lesion is not detectable either by palpation or by mammography. A fine needle aspiration biopsy of a suspicious area reveals cells suspicious for a malignancy. An excisional breast biopsy yields a diagnosis of lobular carcinoma in situ of the breast. Which of the following is the most likely finding associated with this woman's carcinoma?

a) This neoplasm will remain localized.
b) The opposite breast may also be involved.
c) A family history of breast cancer is unlikely.
d) Paget disease of the nipple probably preceded this lesion.
e) Estrogen receptor assay of this neoplasm will probably be negative.

3. A 15-year-old healthy girl of normal height and weight for age is concerned because her right breast has developed to twice the size of her left breast since the onset of puberty at age 12. On physical examination both breasts have a similar consistency on palpation, and there is no tenderness. The nipples and areolae appear normally formed. Which of the following is the most likely cause for these findings?

a) Cystosarcoma phyllodes
b) An ovarian tumor
c) Virginal hypertrophy
d) Fibrocystic disease
e) Infiltrating ductal carcinoma

Hothifa Read

Patho Repro

4. A 20-year-old woman notes a mass in her right breast after following the directions for breast self-examination provided by her health clinic. Her physician palpates a firm, 1 to 2 cm mass. There is no nipple discharge and no pain. No axillary adenopathy is present. The overlying skin of the breast appears normal. Her right breast is slightly larger than the left, a condition she says has been present since puberty. Her urine pregnancy test is negative. Mammography confirms the presence of an rounded density, which has no microcalcifications, and reveals no lesions of the opposite breast. Which of the following is the most likely diagnosis?

a) Focus of fat necrosis
b) Fibroadenoma
c) Intraductal papilloma
d) Infiltrating ductal carcinoma
e) Cystosarcoma phyllodes

5. A 19-year-old woman gave birth to a healty male infant at term following an uncomplicated pregnancy. She has now been breast feeding the baby for a month, but notes that her left breast has gradually become swollen and painful to touch over the past week. On physical examination her temperature is 38.2 C. Which of the following is the most likely diagnosis?

a) Acute mastitis
b) Fibrocystic disease
c) Fat necrosis
d) Intraductal papilloma
e) Galactocele

6. A 35-year-old woman has noted a palpably firm, irregular mass in her right breast for the past 3 months. On physical examination there is no tenderness or swelling. By mammography there is an irregular 2 cm density that demonstrates scattered microcalcifications. Biopsy of this mass reveals extensive fat necrosis. Which of the following is the most likely cause for this breast lesion?

a) Pregnancy
b) Prolactinoma
c) Trauma
d) Fibrocystic changes
e) Lobular carcinoma in situ

7. A 29-year-old woman has been taking oral contraceptives for the past 12 years. She now has a palpable "lump" in the left breast that has persisted for the past 3 months. Which of the following breast lesions is most likely to be associated with her oral contraceptive use?

a) Acute mastitis
b) Fat necrosis
c) Galactocele
d) Hypertrophy
e) Cyst formation

Hothifa Read

Patho Repro

8. A 49-year-old woman notes increasing size to her right breast over the past year. This breast is not painful, but the heaviness causes some discomfort. On physical examination the overlying skin and nipple appear normal. There is no nipple discharge. There is no axillary lymphadenopathy. Mammography reveals a solid 12-cm circumscribed mass. The mass is biopsied, and on microscopic examination shows a cellular stromal component along with an epithelial component. Which of the following is the most likely diagnosis?

a) Fibroadenoma
b) Phyllodes tumor
c) Sclerosing adenosis
d) Hamartoma
e) Medullary carcinoma

9. A 46-year-old woman has a silicone breast implant placed following a right mastectomy for treatment of an infiltrating ductal carcinoma a year ago. She is advised of potential complications, including leakage of the silicone breast implant. Which of the following is most likely to be caused by breast implant leakage?

a) Cystosarcoma phyllodes
b) Scleroderma
c) Breast abscess
d) Infiltrating ductal carcinoma
e) Pain and contracture

10. A 52-year-old woman feels a lump in her right breast on self-examination and goes to her physician. On physical examination the 4 cm mass is not freely movable and feels quite hard. A fine needle aspirate is performed and cytologic examination shows cells are present consistent with carcinoma. Which of the following features of this carcinoma is most likely to suggest a worse prognosis?

a) Estrogen receptor positivity
b) Family history of breast carcinoma
c) Presence of an in-situ component
d) Axillary lymph node metastases
e) Lack of aneuploidy

11. A 45-year-old woman feels a "lump" in her left breast. Her physician palpates a 2 cm irregular area in the upper outer quadrant. A biopsy is performed and microscopic examination shows no evidence for carcinoma. Which of the following microscopic findings in this biopsy is most likely to suggest an increased risk for subsequent development of breast carcinoma?

a) Lobular epithelial hyperplasia
b) Sclerosing adenosis
c) Fat necrosis
d) Galactocele
e) Multiple cysts

Hothifa Read

Patho Repro

12. A 20-year-old woman give birth to a term girl infant following an uncomplicated pregnancy. She breast feeds the infant. Six weeks later, her left breast becomes painful and slightly swollen. On physical examination there is a tender 3-cm mass in the left breast beneath a nipple that shows several painful fissures. Which of the following pathologic findings is most likely to be present in this breast?

a) Infiltrating ductal carcinoma
b) Numerous plasma cells
c) Sclerosing adenosis
d) Staphylococcus aureus infection
e) Fat necrosis

13. A 25-year-old woman palpates a left breast "lump" on self-examination. Her physician palpates an ill-defined mass. There is no pain or tenderness. No axillary lymphadenopathy is noted. Fine needle aspiration is performed and cytologic examination shows cells that appear benign. The lesion persists, and 6 months later another biopsy is taken and shows ductal epithelial proliferation with ductal apocrine metaplasia, stromal fibrosis, and sclerosing adenosis. Which of the following is the most likely diagnosis?

a) Fat necrosis
b) Ductal carcinoma in situ
c) Lobular carcinoma in situ
d) Fibrocystic changes
e) Intraductal papilloma

14. A 39-year-old woman has noted red, scaling area on her breast for 3 months. On physical examination there is an eczematous 1 cm diameter area on the skin of the right breast areola. There is no palpable lump in this breast. Biopsy of the skin lesion is performed and on microscopic examination shows large cells at the dermal-epidermal junction that stain positively for mucin. Which of the following is the most likely diagnosis?

a) Nipple discharge
b) Paget disease of breast
c) Intraductal carcinoma
d) Dermatophyte infection
e) Inflammatory carcinoma

15. A 39-year-old woman has noted a bloody nipple discharge from the right breast for the past 5 week. On physical examination there is no palpable mass or tenderness. The skin of this breast shows no lesions. A small amount of bloody fluid can be expressed from the right nipple. Which of the following is the most likely diagnosis?

a) Mastitis
b) Intraductal papilloma
c) Trauma
d) Infiltrating ductal carcinoma
e) Tuberculosis

Hothifa Read

Patho Repro

16. A 61-year-old woman has noted a rough, reddened appearance increasing in size over the skin of her right breast for the past 5 months. This persists despite application of a corticosteroid cream. On physical examination the skin over the right breast is indurated, roughened, and reddish-orange. There is nipple retraction. A firm, irregular 5 cm mass is palpable in this breast. Which of the following is the most likely risk factor for this woman's condition?

a) She is a smoker
b) She has fibrocystic disease
c) Her pregnancy history is G5 P4 Ab1
d) Her mother had the same condition
e) She has human papillomavirus infection

17. A 41-year-old woman has felt a large breast lump that has increased slowly in size for the past 3 years. On physical examination there is a 9 cm firm, movable mass present in her left breast. The overlying skin appears normal; there is no axillary lymphadenopathy. The mass is exccised and grossly appears soft and fleshy. On microscopic examination this mass has a lymphoid stroma with little fibrosis surrounding sheets of large vesicular cells with frequent mitoses. Which of the following is the most likely diagnosis?

a) Infiltrating ductal carcinoma
b) Paget disease of breast
c) Medullary carcinoma
d) Lobular carcinoma
e) Cystosarcoma phyllodes

18. A clinical study is peformed involving subjects who are women ranging in age from 15 to 45 years who palpated breast "lumps" on self-examination. The presence of breast mass lesions in these subjects was subsequently confirmed by physical examination and by mammography. All subjects had a biopsy or excision of their lesion performed, with a definitive pathologic diagnosis made. Which of the following diagnoses is likely to be the most frequent in these subjects?

a) Abscess
b) Fibroadenoma
c) Fibrocystic changes
d) Lobular carcinoma in situ
e) Infiltrating ductal carcinoma

19. A pathologic study is made of phyllodes tumor and fibroadenoma in the breast. The demographic findings in the patients, the mammographic findings, and the gross and microscopic pathologic appearances are analyzed. Which of the following features is most likely to have a greater frequency in the phyllodes tumor than the fibroadenoma?

a) Stromal cellularity
b) Size of the tumor
c) Patient age
d) Location within the breast
e) Mammographic appearance

Hothifa Read

Patho Repro

20. A 30-year-old woman has felt a mass in her right breast for 6 months. On physical examination there is a 5 cm right breast mass and firm, non-tender lymphadenopathy. A fine needle aspiration is performed and cytologic examination shows carcinoma cells. A right mastectomy with axillary lymph node dissection is performed. Microscopic examination shows a poorly differentiated carcinoma that is negative for estrogen and progesterone receptors, but is positive for HER2/neu. One axillary lymph node demonstrates micrometastases. Her 32 year old sister is found to have a similar lesion. Which of the following is the most likely risk factor for this woman's breast cancer?

a) BRCA-1 mutation
b) Late menarche
c) Positive antinuclear antibody test
d) Exposure to hydrocarbon compounds
e) Prior fibrocystic changes

21. A 45-year-old woman has noted a mass in her right breast for 7 months. On physical examination there is a 5 cm diameter right breast mass. A biopsy of the mass is performed and on microscopic examination a carcinoma is present. Which of the following pathologic findings suggests a better prognosis for this woman?

a) Lack of estrogen receptor positivity
b) A solitary axillary lymph node metastasis
c) Tumor size
d) Aneuploidy by flow cytometry
e) An intraductal histologic pattern

22. A 51-year-old healthy man has noted bilaterally enlarged breasts for the past 35 years. On physical examination his breasts are enlarged to 3 times normal size, with no masses present, no tenderness, and no axillary lymphadenopathy. Which of the following conditions is most likely to cause his breast enlargement?

a) History of antidepressant drug therapy
b) 47, XXY karyotype
c) Increased risk for breast carcinoma
d) Seminoma of the testis
e) Increased testosterone levels

23. Which of the following patients is most likely to have a breast lesion consisting of a solitary well-circumscribed 1 cm firm nodule palpated in the lower outer quadrant on physical examination:

a) 62-year-old woman with enlarged, firm axillary lymph nodes
b) 20-year-old man with bilateral breast enlargement
c) 22-year-old woman who is asymptomatic
d) 45-year-old woman with bloody nipple discharge
e) 5-year-old girl with precocious puberty

Hothifa Read

Patho Repro

24. A 49-year-old woman goes to her physician for a routine health maintenance examination. A screening mammogram is performed and shows a 3 cm area in her left breast that has microcalcifications and irregular densities. A needle biopsy of this area shows ducts containing solid sheets of malignant cells, with central necrosis and calcification. There is no invasion. A lumpectomy with wide excision to clear margins is performed along with axillary lymph node sampling that shows no metastases. Immunohistochemical staining of the tumor cells shows them to be estrogen receptor and HER2 (c-erb B2) negative. She receives radiation therapy. Which of the following is the most likely outcome for this woman?

a) Recurrence in the opposite breast
b) Cure with no further therapy
c) Response to therapy with tamoxifen
d) Development of inflammatory carcinoma
e) Her children will inherit a BRCA-1 mutation

25. A 69-year-old woman has a screening mammogram that shows an irregular 1 to 2 cm density in her right breast. She has no axillary lymphadenopathy. A needle biopsy is performed and on microscopic examination shows malignant cells floating in mucinous lakes. The nuclei show minimal pleomorphism and no mitoses are seen. The cells are positive for estrogen receptor and negative for HER2 (c-erb B2). A chest x-ray shows no abnormal findings. A bone scan is negative. What is the most likely designation for grade and stage of this neoplasm?

a) Grade I, Stage T1 M0 N0
b) Grade I, Stage T2 M1 N1
c) Grade II, Stage T3 M0 N0
d) Grade II, Stage T2 M0 N1
e) Grade III, Stage T3 M0 N1