# CARDIOVASCULAR INVESTIGATIONS

اول صورة جبيت

1-PLAIN FILMS

2-ULTRASOUND & echo.

3-ISOTOPE SCANNING

4-CT

5-MRI

6-ANGIOGRAPHY



*Hand mit Ringen* (Hand with Rings): print of Wilhelm Röntgen's first "medical" X-ray, of his wife's hand, taken on 22 December 1895 and presented to Ludwig Zehnder of the Physik Institut, University of Freiburg, on 1 January 1896

## [1] X-ray

* X-ray in cardio is the first modality of imaging the heart. & the body in general.

* Why X-ray ?

1- widely Avaliable.

2- Cost effective

3- give important info include

↳ size of heart, chambers, calcification in valves, status of the main vessels

status of the lung (lung congestion, pleural effusion, hyperemia, ... )

## [2] US

* mainly used as echocardiography

* highly avaliable

* But it requires a professional physician (operator dependent)

# Disadvantage #

* not reproducable.

الدكتور يمكن يكون بده view

وختلف لازمك الرصيد

من جديد

[3]

# ISOTOPE SCAN

(1) Cardiac imaging

(2) Bone scaning for metz & Fracture

(3) Thyroid & Parathyroid metz

(4) ...



① The mc radiopharma used in isotope scan is Tegnisum ?

"Common Precursor"

- it's labeled
- could be matched ∞ other materials like

Biphosphonate, RBCs, DTPA, DMSA, MAG3

حسب الاستخدام الأول.

# Selectivity of Tegnisum

# الهدف من ال matching هو زيادة ال

مثال: بدور ع Bleeding بدل matching بعيد

| | |
|---|---|
| Tegnisum & RBCs | Cardiac Output |
| & RBCs | Brain imaging |
| & HMPAO | Function of kidney |
| & DTPA | Structure of kidney |
| & DMSA | Bone imaging |
| & Diphosphonate | Renal Imaging |
| & MAG 3 | |

② * other radiopharma can be used is (Iodine)

↳ $I^{123}$ for Thyroid Function

↳ $I^{131}$ for Thyroid Function & Therapy

③ Gallium

- To detect the source of infla or site of Tumor

④ Thalium$^{201}$

- one of the mc used radiopharma.
- used in cardiac imaging.

⑤ Xenon

- used in lung ventilation Function (VQ Scan) = ventilation perfusion Scan

& Brain

# ISOTPE SCAN

- Rest isotope scan using thallium ( Ti201) injection.
- Dual-isotope imaging is a hybrid protocol that combines a resting thallium injection and subsequent scan with the injection of either Tc-99m sestamibi or tetrofosmin during stress.
- Adenosine stress test if patient cant physically do exercise (Pharmaceutical **stress** is used to increase blood flow to the heart muscle) .



| Radionuclide | Symbol | Physical half-life | Chemical form | Diagnostic use |
|---|---|---|---|---|
| Chromium | $^{51}Cr$ | 27.8 days | Sodium chromate | Red blood cell volume and survival |
| | | | Albumin | Gastrointestinal protein loss |
| Cobalt | $^{57}Co$ | 270 days | Cyanocobalamin (vitamin $B_{12}$) | Vitamin $B_{12}$ absorption |
| Fluorine | $^{18}F$ | 110 min | Fluorodeoxyglucose | Oncology and myocardial hibernation |
| Gallium | $^{67}Ga$ | 77 hr | Gallium citrate | Inflammatory process and tumor imaging |
| Indium | $^{111}In$ | 67.4 hr | DTPA | Cerebrospinal fluid imaging |
| | | | Ibritumomab tiuxetan | Localization of tumor |
| | | | OctreoScan (pentetreotide) | Neuroendocrine tumors |
| | | | ProstaScint (capromab-pendetide) | Prostate cancer |
| | | | Oxine | White blood cell/abscess imaging |
| Iodine | $^{123}I$ | 13.3 hr | Sodium iodide | Thyroid function and imaging |
| | | | Human serum albumin | Plasma volume |
| | $^{131}I$ | 8 days | Sodium iodide | Thyroid function, imaging, and therapy |
| | | | Hippurate | Renal function |
| Nitrogen | $^{13}N$ | 10 min | Ammonia | Myocardial perfusion |
| Rubidium | $^{82}Rb$ | 75 sec | Rubidium chloride | Cardiovascular imaging |
| Technetium | $^{99m}Tc$ | 6 hr | Sodium pertechnetate | Imaging of brain, thyroid, scrotum, salivary glands, renal perfusion, and pericardial effusion; evaluation of left-to-right cardiac shunts |
| | | | Sulfur colloid | Imaging of liver and spleen and renal transplants, lymphoscintigraphy |
| | | | Macroaggregated albumin | Lung imaging |
| | | | Sestamibi | Cardiovascular imaging, myocardial perfusion |
| | | | DTPA | Brain and renal imaging |
| | | | DMSA | Renal imaging |
| | | | MAG3 | Renal imaging |
| | | | Diphosphonate | Bone imaging |
| | | | Pyrophosphate | Bone and myocardial imaging |
| | | | Red blood cells | Cardiac function imaging |
| | | | HMPAO | Functional brain imaging and white blood cell/abscess imaging |
| | | | Iminodiacetic derivations | Liver function imaging |
| | | | Neurolite (Bicisate) | Brain imaging |
| | | | Myoview (Tetrofosmin) | Myocardial perfusion |
| | | | CEA-scan (Arcitumomab) | Gastrointestinal tract |
| | | | Cardiolite (Sestamibi) | Myocardial perfusion |
| | | | Apcitide (AcuTect) | Acute venous thrombosis |
| Thallium | $^{201}Tl$ | 73.5 hr | Thallous chloride | Myocardial imaging |
| Xenon | $^{133}Xe$ | 5.3 days | Xenon gas | Lung ventilation imaging |



# PET Scan



* الجهاز له (2 Detectors) بلفوا حول المريض لاعطاء صورة 3D
لتحديد مكان (العضو) ال (Activity).

(SPECT) ←

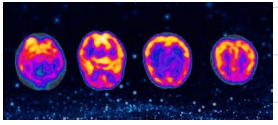

S : Single
P : Photon
E : Emission
C : Computed
T : Tomography

* Disadvantage of isotope : Doesn't give a clear anatomical view.

# isotope is an imaging of function #

- Concentration of Certain Radiopharma
- Excretion of kidney
- Uptake by tumor

* نفس كفاية ال PET Scan ، لذلك الشركات دوجت PET/CT or PET/MRI

PET/CT: Function, Ana.
PET/MRI: Function, Anatomy



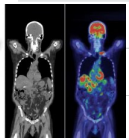



# Myocardial Perfusion Imaging

## *SPECT*




- Indications
  - Detects presence/location/extent of myocardial ischemia in patients with R/O ACS.
  - Risk stratification after ACS.
  - Identify fixed defects, evaluate EF and viability.
  - CP with abnormal EKG's.
  - Equivocal ETT.
  - Inability to exercise (pharmacological stress).

Thalium 201 Vs Tegnisum 999

- Produced in 70's
- $t_{\frac{1}{2}} = 73$ h/s

- never
- Has labels to many substances
- $t_{\frac{1}{2}} = 6-7$ h/s

فضل أكثر lower dose ع الإصدار

- Better imaging

* Uses of isotope in myocardial perfusion?

1- Detect ischemia

2- Detect Abnormalities of Cardiac muscle.

3- Distinguish ischemia from infarction

↓ decreased BI supply ↓ necrosis of muscles

4- Was the 1st method to evaluate the EF (ejection Fraction) of the heart. & Component of the heart chambers.

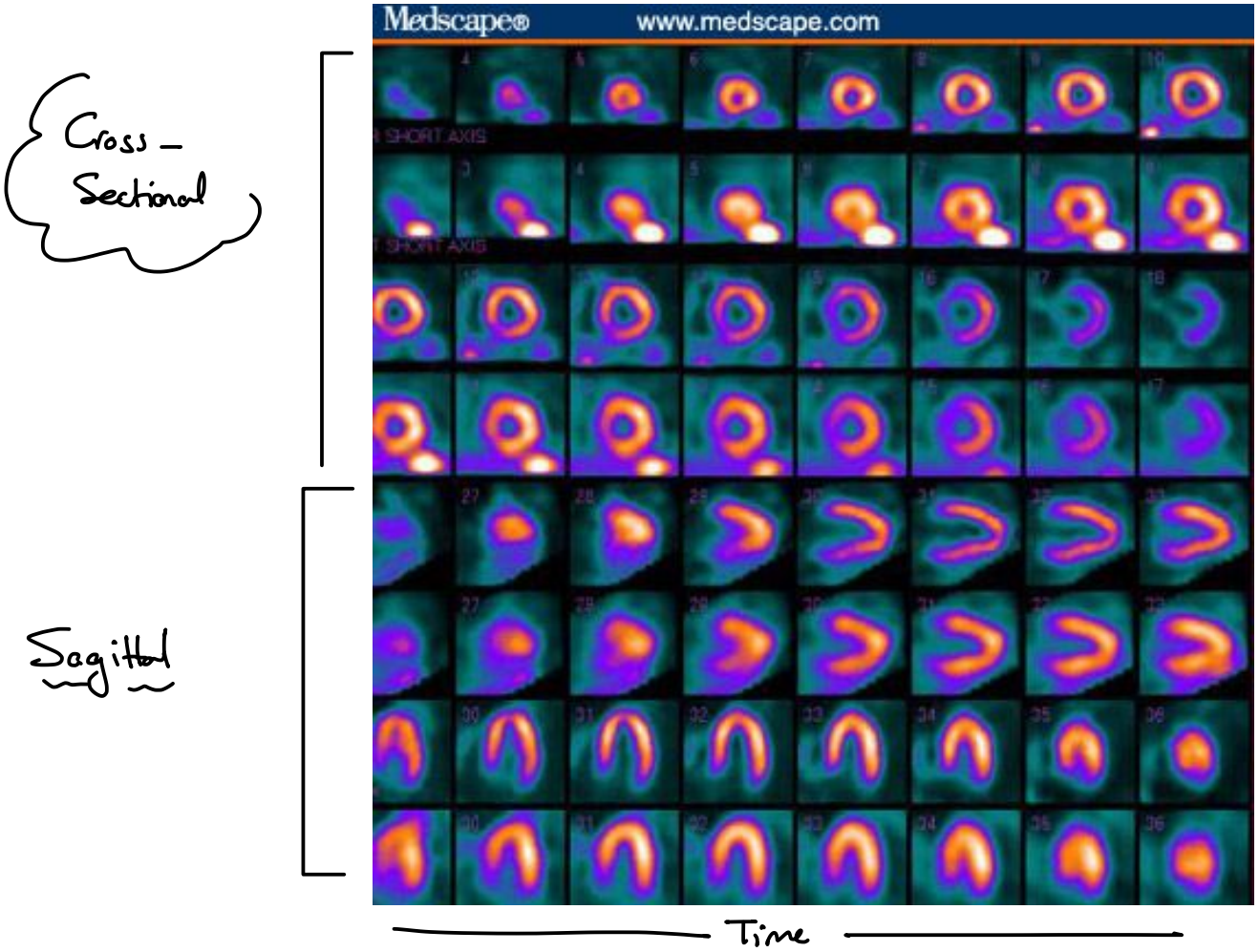


Stress $^{99m}$Tc-tetrofosmin/rest $^{201}$Tl images in a patient with a low likelihood of CAD. The first and third rows are stress short-axis slices from apex to base. The second and fourth rows are matching rest slices. The fifth and sixth rows are the stress and rest vertical-long-axis slices, while the seventh and eighth rows are the stress and rest horizontal-long-axis slices.

* The study is done in Rest & Stress Phases ...

Rest ↓ نحقن ال Radiopharma

Stress ↓ more common

المريض بصير يجري

وعايتعب المريض يتم

حقن ال Radioph. حل عنا مناطق لا

بعد ذلك بنعمل يوجد لها Perfusion

① scan after 1 hr.

② scan after 4 hrs.

* To evaluate the function of the heart, the material is injected (MASADA) ع المطاولة

# من زي ال (Stress Test) #

# بتم حساب ال Function من خلال الجهاز #

↓

including EF (ejection fraction)

Cross - sectional of LV

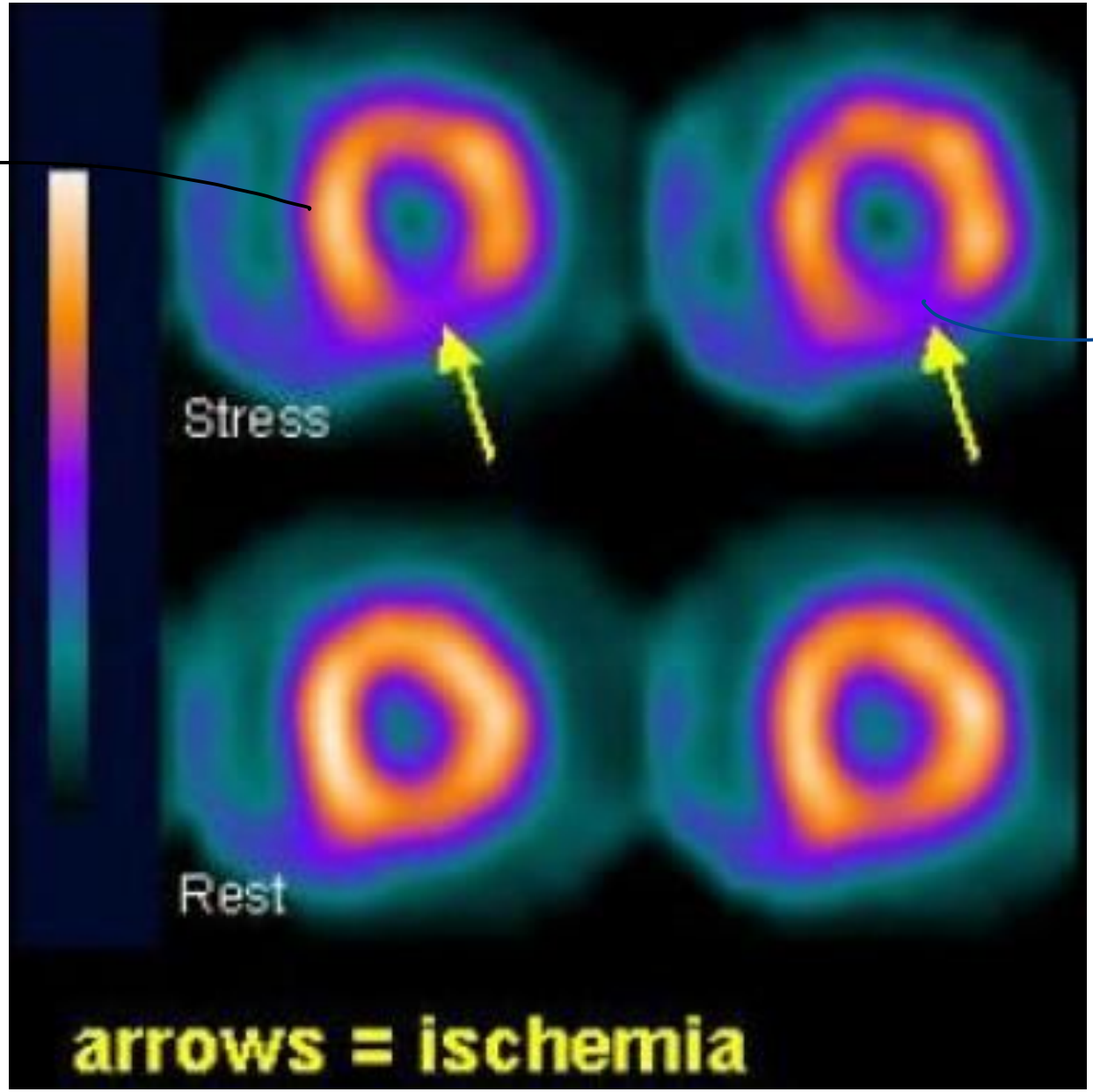


مش ماخدة Radiophorm خلال ال Stress معناها خلال الاجهاد بقل ال Bl Supply لهادي المنطقة

# Area of Ischemia

لو كان ال Defect في ال Rest & Stress بكون (inlaction)

## Fig 1. **Myocardial perfusion imaging: irreversible ischaemia**

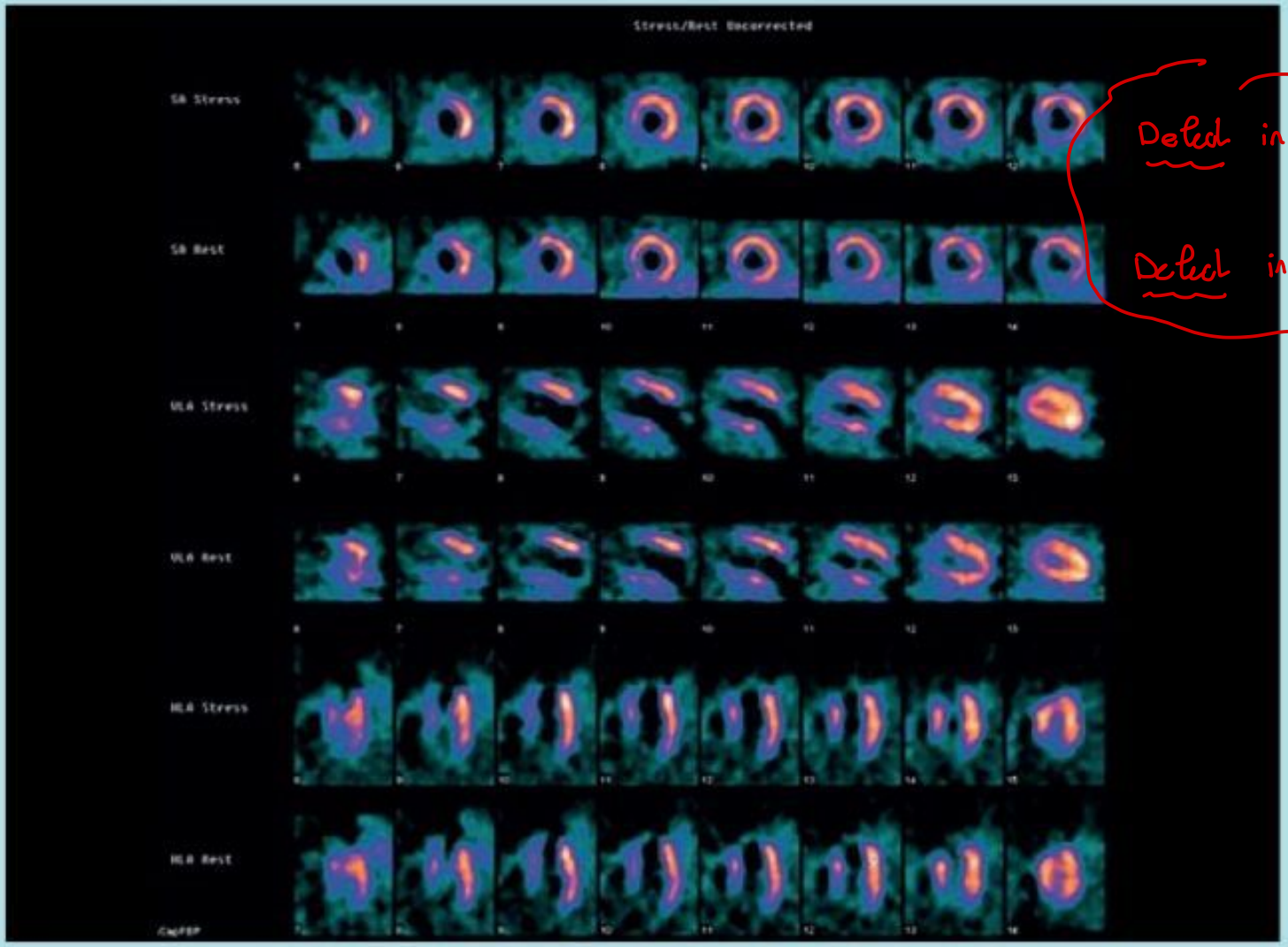


Defect in Stress

Defect in Rest

= irreversible ischemia or infarction

Absent/reduced counts in anteroapical segments, including apex and inferior apical segments. Shows full-thickness infarction. No reversible ischaemia, evidence of myocardial infarction.

Area of decreased Activity

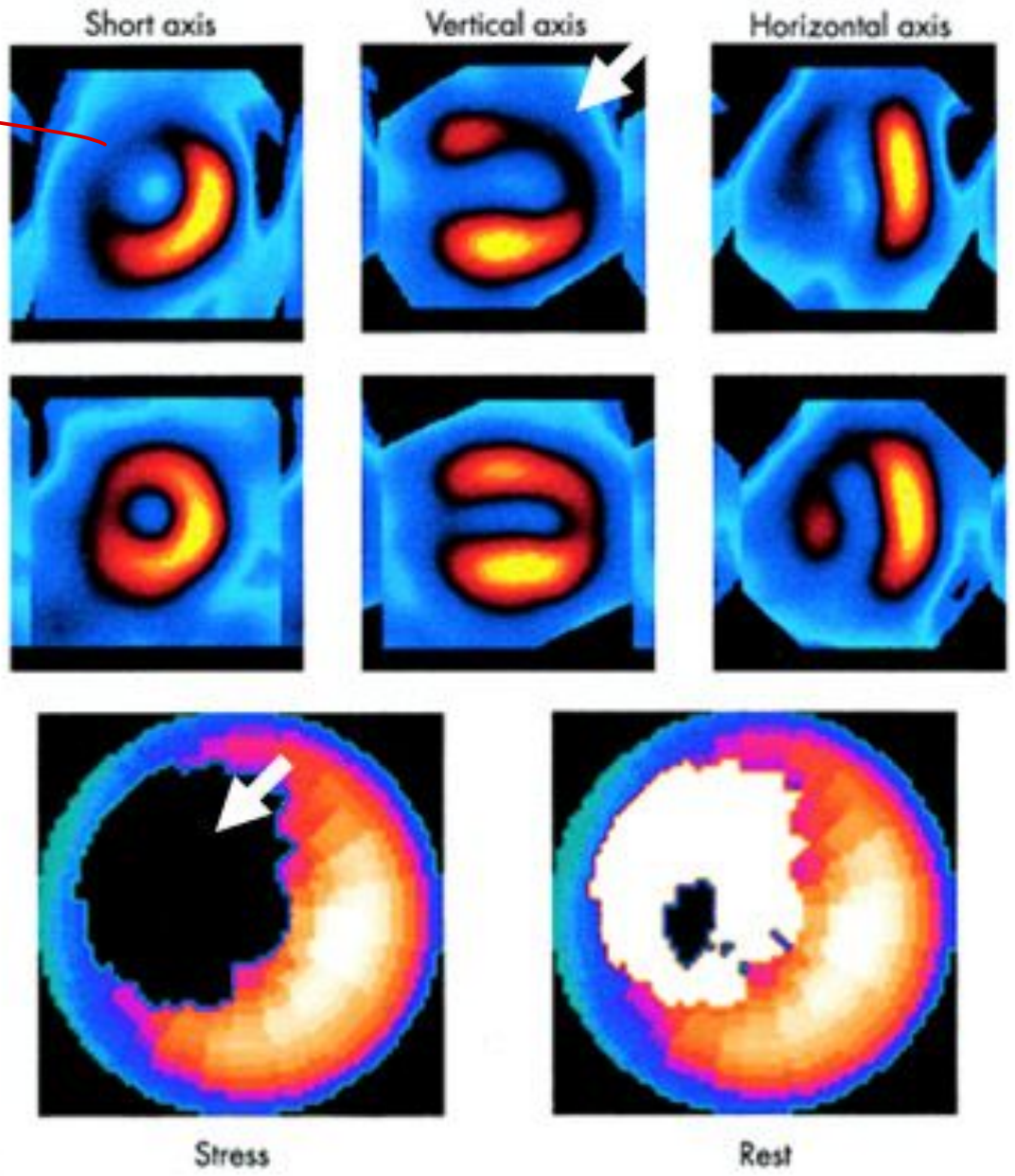


# (ischemia)

* ما الذي يجعل ال Isotope مميز عن ال CC Echo

① It's not an operator dependant

بحسب كل أشعة الحالة.

② Determine the viability of the muscles

(indirect indicator of coronary vessels status)

حالات ال Ischemia من الهم جداً عمل قسطرة لهم ولكن حالات ال Infarction للاسف لا تفيد #

* ischemic pt → Angioplasty or stenting

* infarction → Nothing can be done

الا اذا عنده مناطق ischemia تعامل معها

* To image the coronary vessels directly ...

# for stenosis or occlussion #

① Conventional Angiography أفضل شيء

② CT أفضل من MRI

③ MRI

# Coronary CT

↳ need contrast بديهي

↳ for low → intermediate risk pt.

* يعني لو المريض MI ما بنفعه CT

بصير waste of time بلزم

↳ invasive managment (Cath Lab)

or medical mangment.

حالياً بالدول المتطورة ، ال

Cath lab combined ∞ CT

والوقت 10 دقائق أو ماشان

وسريعة في أخذ الصور

↳ general idea if there's

disection, occlusion, thromboris of coronary ar.

وهذا يوجه الجراح للتعامل مع هذا ال vessel

# What is needed?

- Good CT scanner ( 64 detector or more).
- Patient cooperation.
- Stable heart rate , heart rate around 60p/m.
- Regular CT Contrast injection ( iodin) at high rate .
- ECG gating.

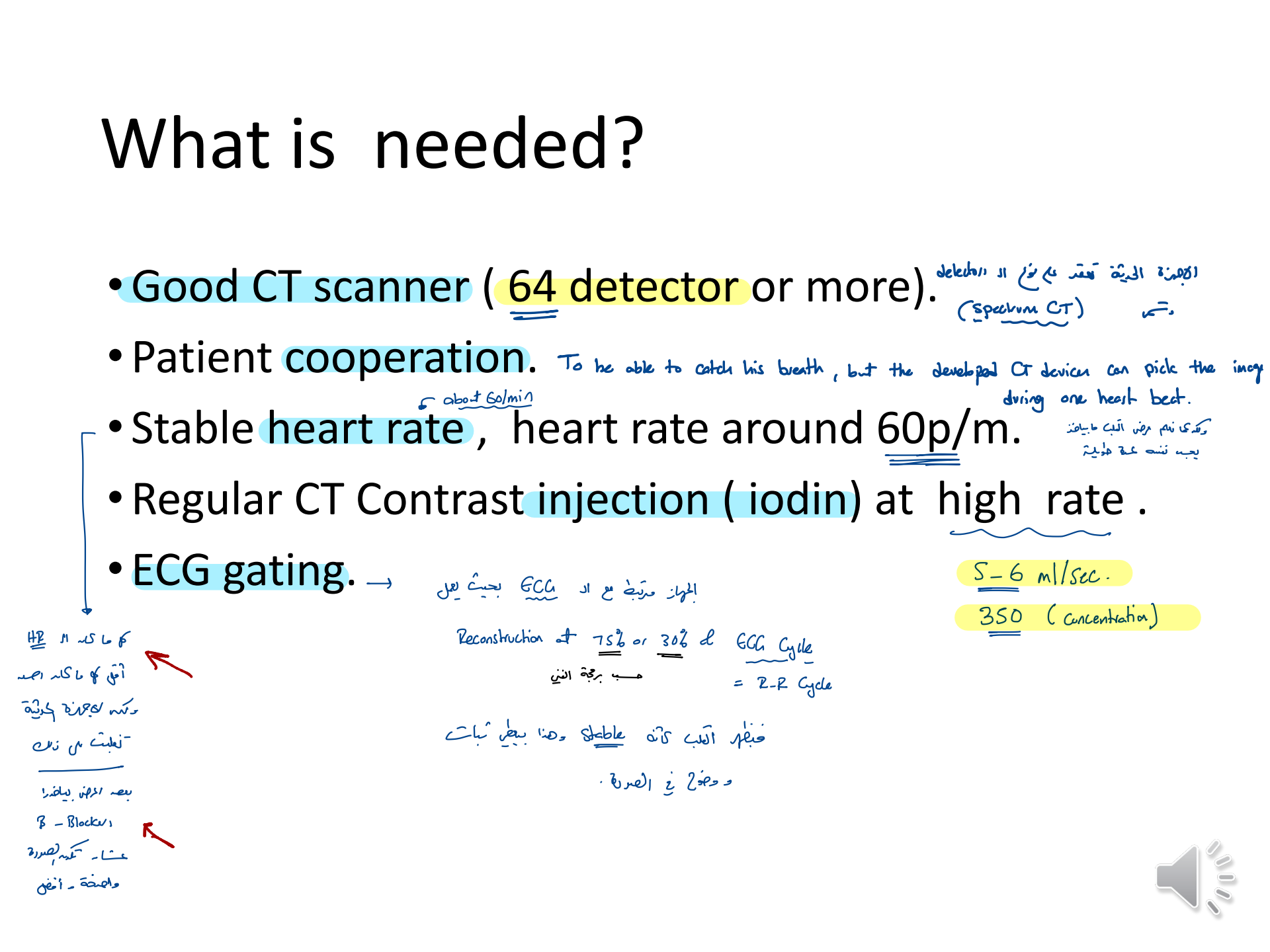

# Cardiac Ct assess:

- Coronary vessels. ( Congenital Anomaly, Stenosis, occlussion, bridging .... ) داخل من ال myocardium
- Aorta . ( Direction, Dilation )
- Functional ( thrombus , EF , contractility,....) + Aneurysm → Rem CT isn't operator dependent
- Muscles viability ( dual source/spectra CT).
- Valves ( Calcification, thickening )

وبالي هو مجال ال isotope

عشان نشوف هل الفصلة

infarcted ولا لا ...

# الفكرة انه المريض مابروح بالمل CT

عشان ال viability & contrac

ولكن هو جاي عشان ال Coronary Aorta Valves

وطالما اخذ الصبغة , تصور بنشوف

هادي الأمور بطريقنا .

# Usage , limitation :

- Mainly used for low- intermediate risk patients .
- Not indicated for high risk paints except in some advanced centers.
- In case of heavy coronary vessels calcification , it has low resolution.
- high heart rate , Arrhythmia and irregular heart rate is limitation for some type of CT scanners.
- Used to assess complex cardiac congenital anomaly.

# Ca score

- Used for risk stratification for coronary , valve and aortic calcification.
- low , intermediate risk patients.
- Not used in case of previous bypass surgery or coronary stenting.
- With /without ECG gating , but not affected by heart rate and arrhythmia.

* Results of $Ca^{++}$ Score – very accurate (not operator dependant) – no need for contrast.

NB $Ca^{++}$ Score indicates the status of the pt in relation to coronary dz, however cardiac consultation is essential

ما بزبط اتجاهل دور الطبيب المختص واعتمد

على هذا التحليل أو ال imaging

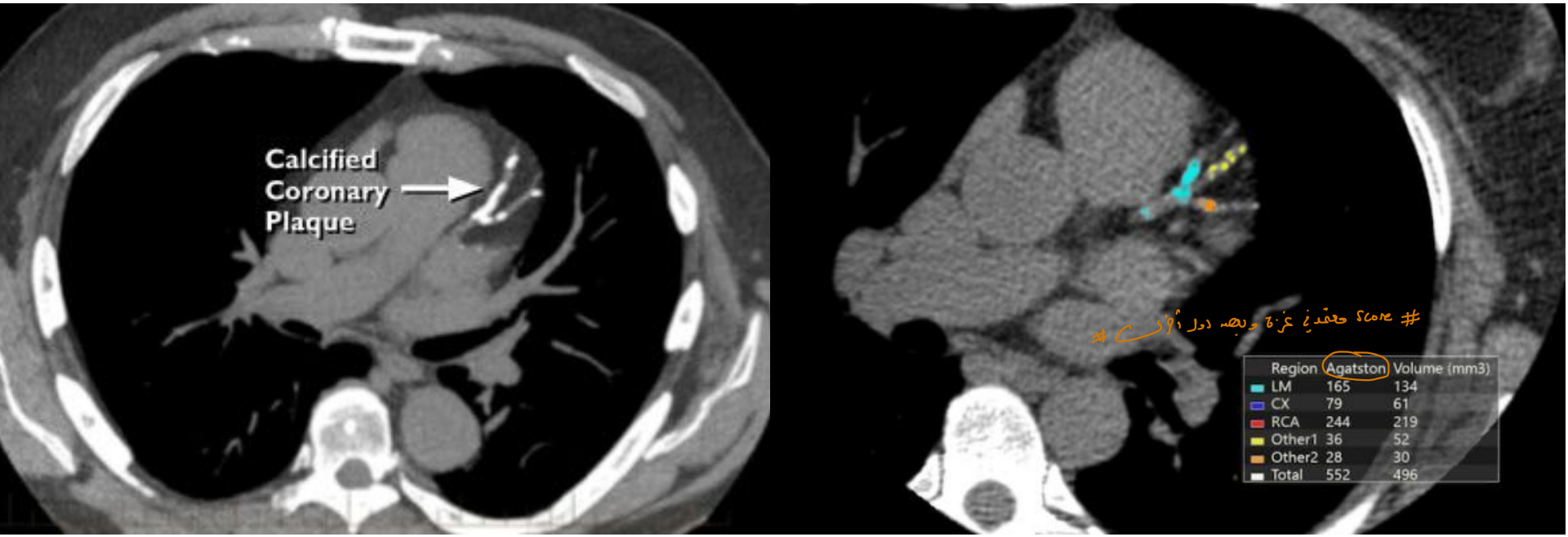


* الجهاز بحدد كل vessel قديش متراكم فيه كلس (Calcification)

* ممكن يكون في خلل معين في Calculations الجهاز، الطبيب بعدل هذا الكلام.

***The result of the test is usually given as a number called an Agatston score. The score reflects the total area of calcium deposits and the density of the calcium.***

Ca Score | Risk of CAD
+ clinical assessment
0 | very low
100 – 300 | intermediate
> 300 | high risk (need further evaluation)

- A score of zero means no calcium is seen in the heart. It suggests a low chance of developing a heart attack in the future.
- When calcium is present, the higher the score, the higher your risk of heart disease.
- A score of 100 to 300 means moderate plaque deposits. It's associated with a relatively high risk of heart attack or other heart disease over the next three to five years.
- A score greater than 300 is a sign of very high to severe disease and heart attack risk.

الدراسات الحديثة بتقول
انه
earlier detection of
CAD Risk can
be done by
iliac vessels
& femoral vessels
Ca Score
وحالياً بعض المراكز
تقوم بهذا ال
(evaluation)
تتأثر بال atherosclerosis
بشكل اسرع من ال
Coronary vessels

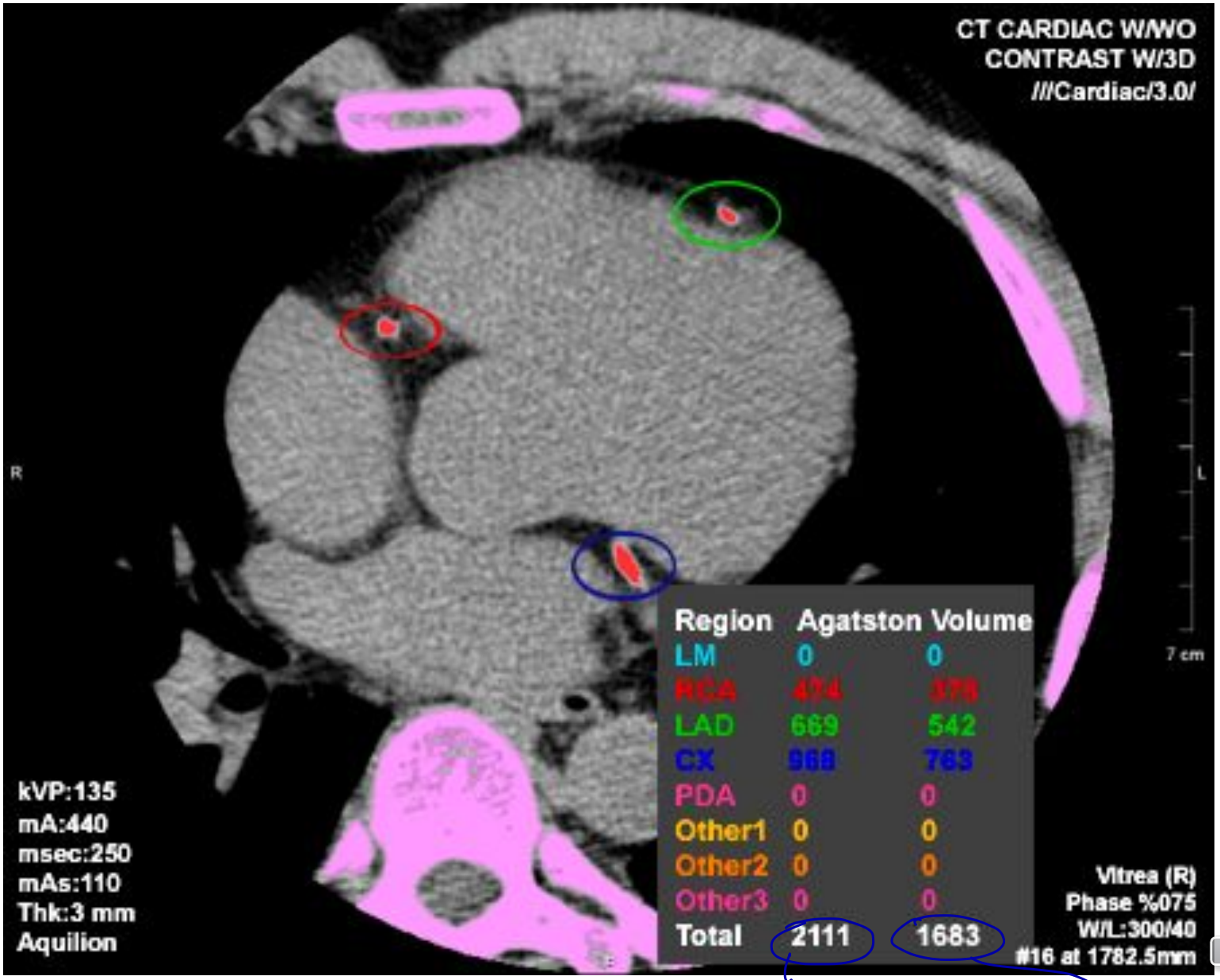


>300 = high risk of CAD

volume or number of plugs.

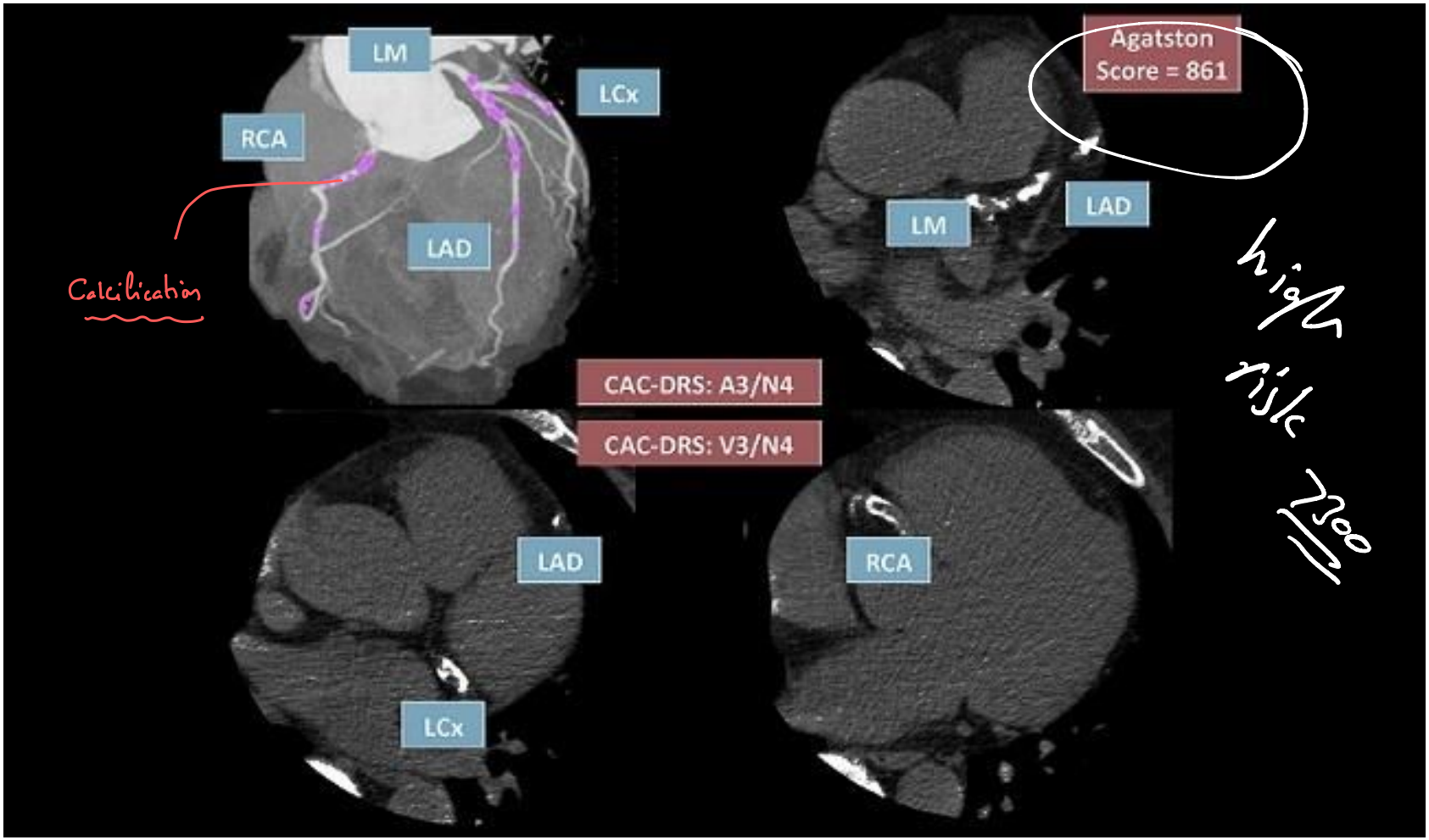
LM
LCx
RCA
LAD
Calcification
Agatston
Score = 861
LM
LAD
high risk
CAC-DRS: A3/N4
CAC-DRS: V3/N4
LAD
RCA
LCx

***According to the American College of Cardiology and the American Heart Association guidelines, a heart scan may not be recommended for the following people:***

= Ca Score is not needed in...

- Men under age 40 and women under age 50, because it's unlikely calcium can be detected at younger ages

they may have thrombotic dz.
اهم أمور detection غير → disection
ولسا " Ca ما تراكم عندهم.

- People who have a very low risk, because detectable calcium is highly unlikely if you don't have a family history of heart attacks at an early age

& asymptomatic

- People who already have a known high risk (especially heavy smokers or those with diabetes or very high cholesterol), because the heart scan will likely not provide any additional information to guide treatment

منتا عارف انه هو
very high risk pt
شو الفايدة من
عمل (Ca Score)

- People with symptoms or a diagnosis of coronary artery disease, because the procedure won't help doctors better understand the disease progression or risk

ادخل ع امور اهم الله.
زي القسطرة.

- People who already had an abnormal coronary calcium heart scan

شخص عمل Ca Score قبل شهر ، اعيده ليش؟ مافي داعي.

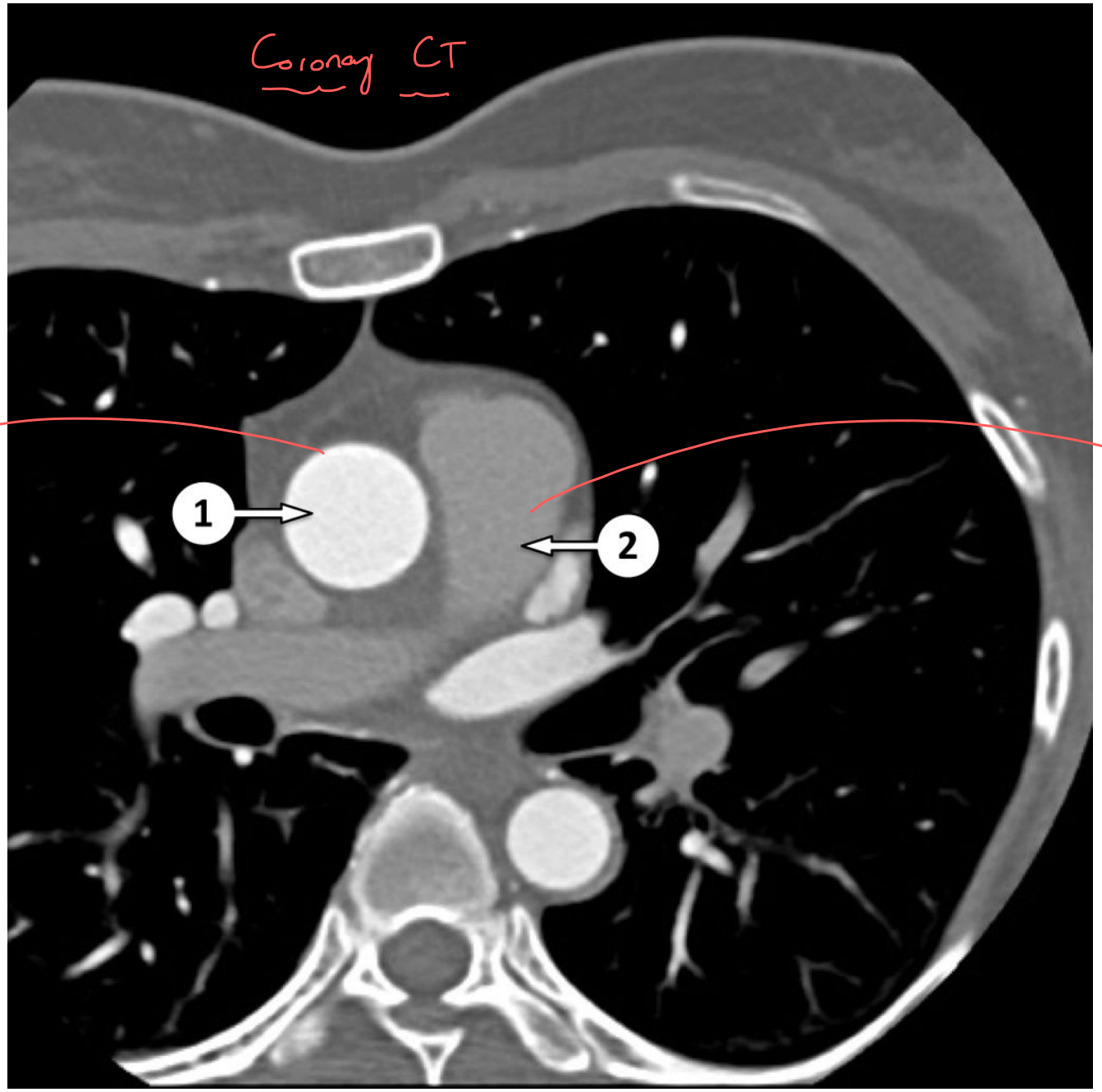


ascending aorta

الفني بحدد للجهاز

1 + 2

وبحط ال trigger

ع ال Asc. Aorta

والجهاز ببدا تصوير

اوتوماتيك لما يوصل ال

ال Contrast

(Asc. Aorta)

Pulmon. Ar.

# Reconstruction & images.

reconstruction at 75% of RR interval.

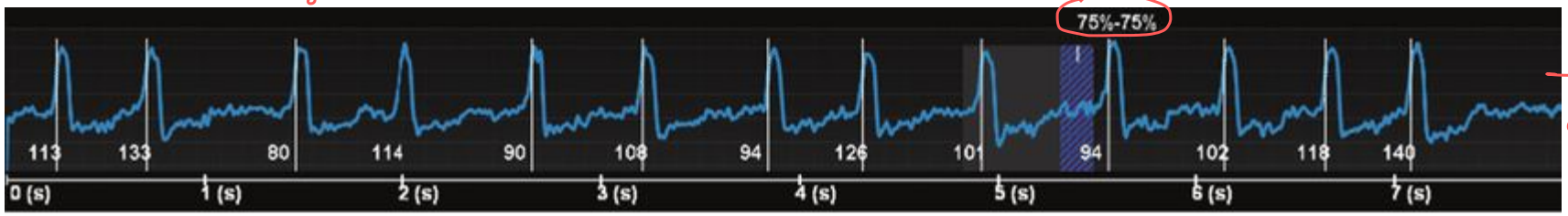


ECG Gating

a.




b.




c.

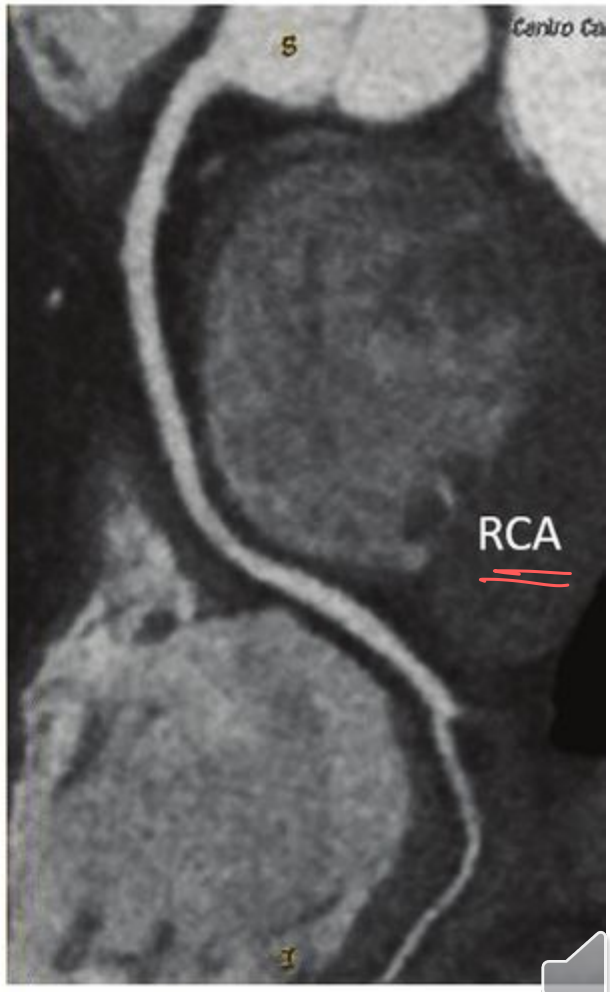


d.

# MPR images "multiplanar reformation" or "multiplanar reconstruction"

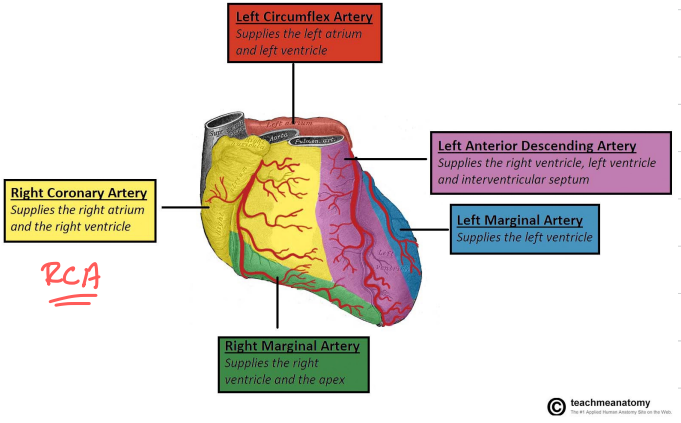
Left Circumflex Artery
Supplies the left atrium and left ventricle
Left Anterior Descending Artery
Supplies the right ventricle, left ventricle and interventricular septum
LAD
Right Coronary Artery
Supplies the right atrium and the right ventricle
RCA
Left Marginal Artery
Supplies the left ventricle
Right Marginal Artery
Supplies the right ventricle and the apex
teachmeanatomy

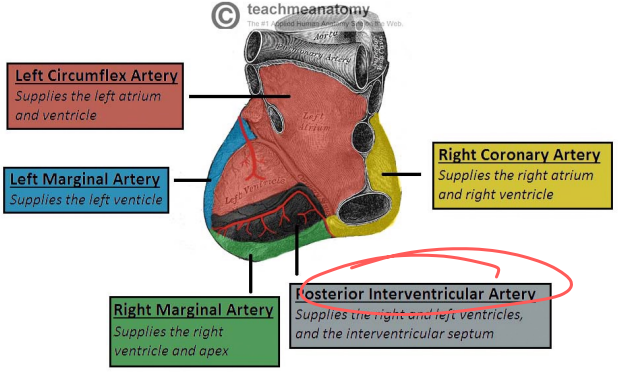
teachmeanatomy
Left Circumflex Artery
Supplies the left atrium and ventricle
Left Marginal Artery
Supplies the left venticle
Right Coronary Artery
Supplies the right atrium and right ventricle
Posterior Interventricular Artery
Supplies the right and left ventricles, and the interventricular septum
Right Marginal Artery
Supplies the right ventricle and apex

# VR image ( volume rendered ) 3D



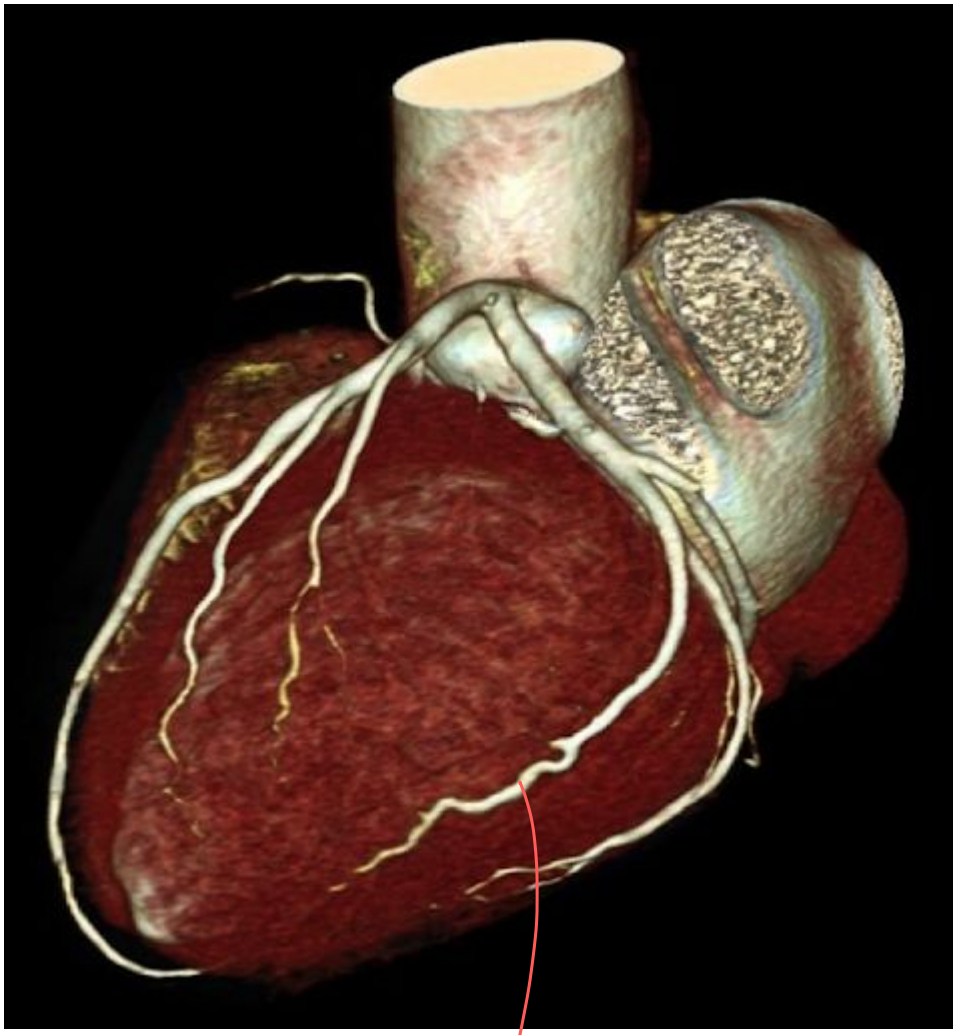

اذا في أي Abnormality بشوفها بوضوح

(no abnormalities)

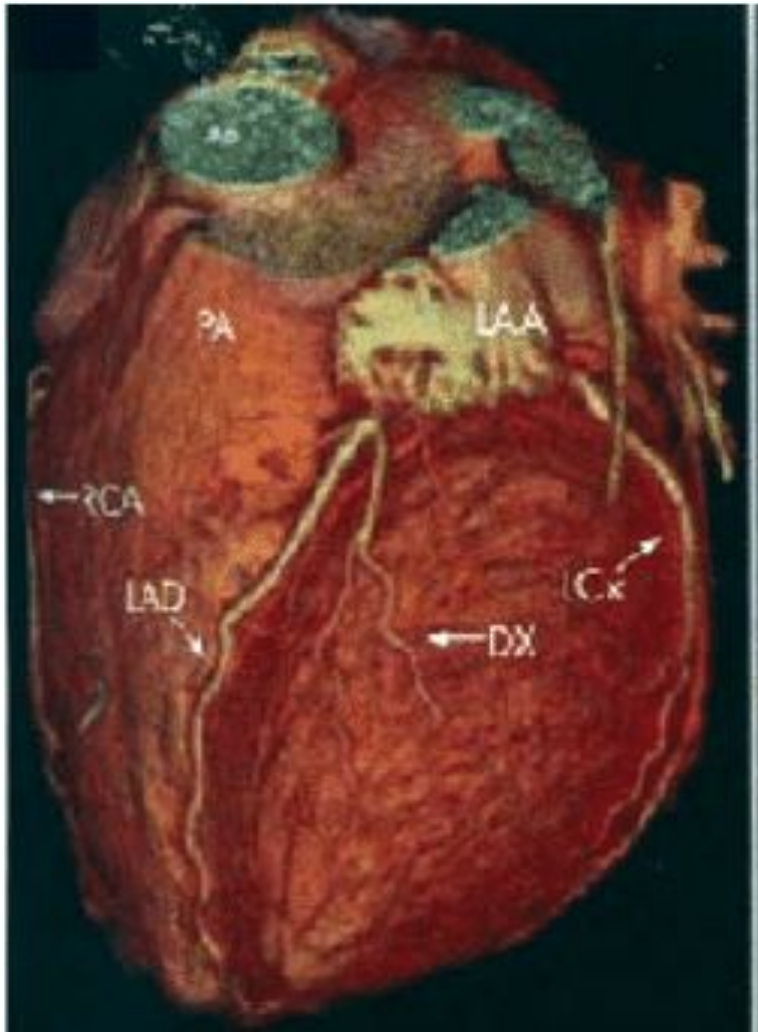





#VR#

#maximum intensity projection#

#MPR #

severe stenosis in Proximal LAD & near occlusion due to soft Atheroma or calcification #

Severe stenosis or some calcification

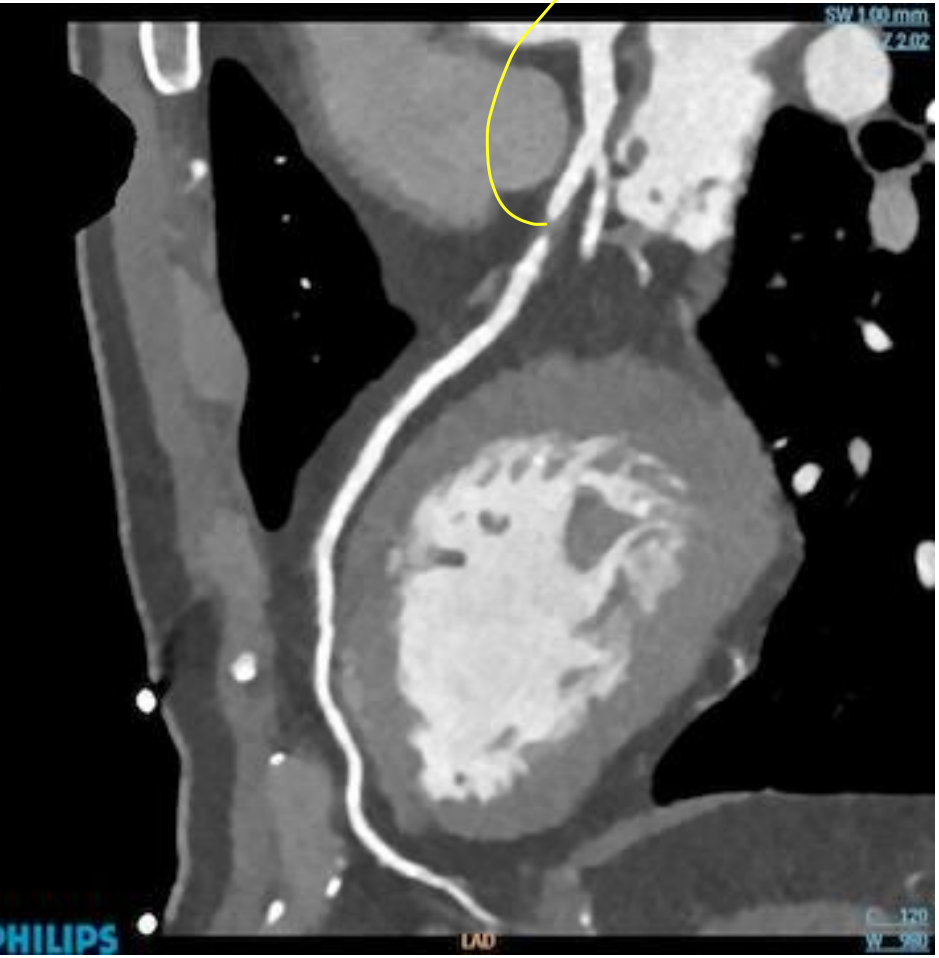


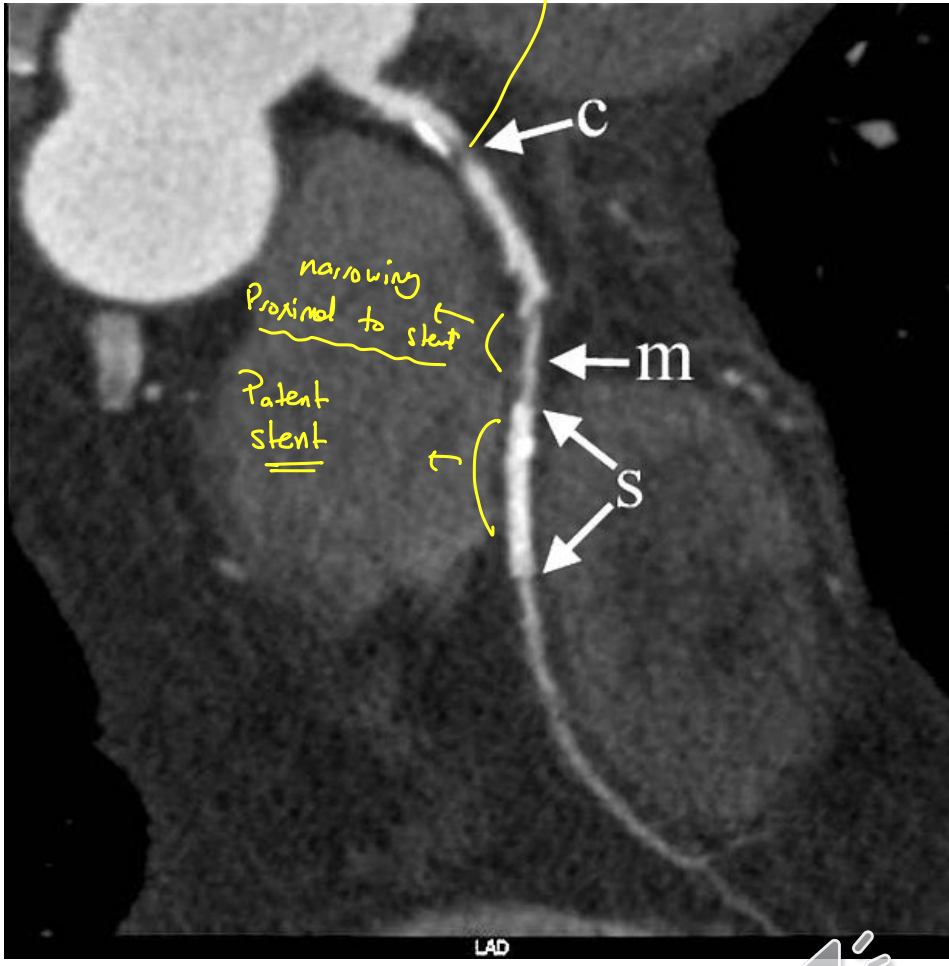

# MYOCRDAIL ENHANCEMENT AND VIABILITY ASSESSMENT

myocardial enhancement

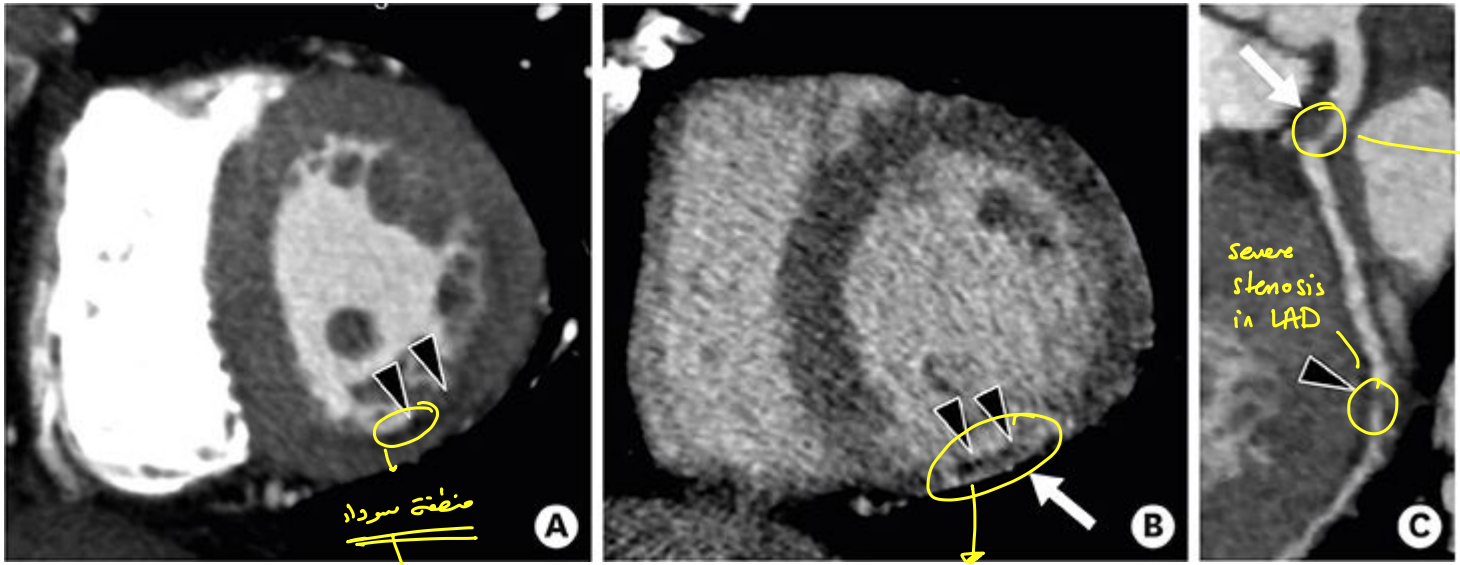


Severe stenosis in Lt main trunk at the bifurcation of LAD

مش ماخدة حبلة زيه باقي ال muscles

= ↓ BI supply = infarction

① ↓BI supply = infarction

② thin myocardium due to previous MI

myocardial viability

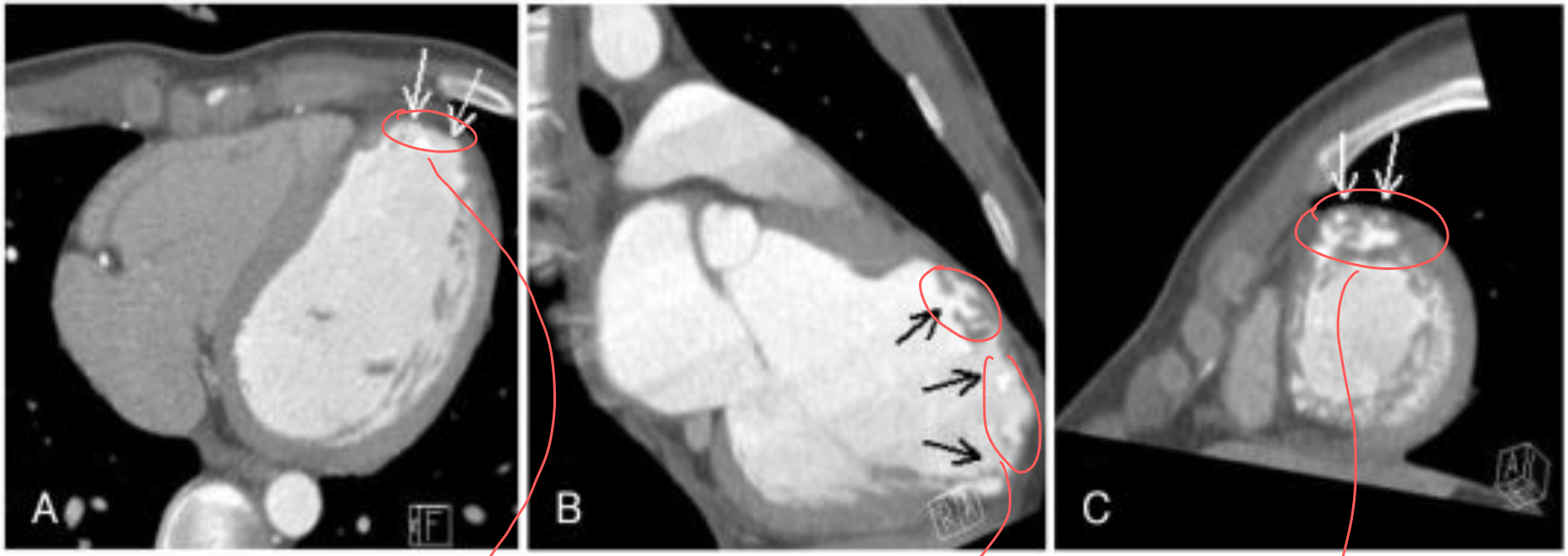


LV Apex

Gray area (↓ enhancement)

(لون النقطة أقل بياضاً من باقي ال muscles)

thin papillary muscles
thin myocardium
} ↓ enhancement due to MI

نفسها بس هاد
(cross-section)

# Coronary vessels calcification & stenosis ...

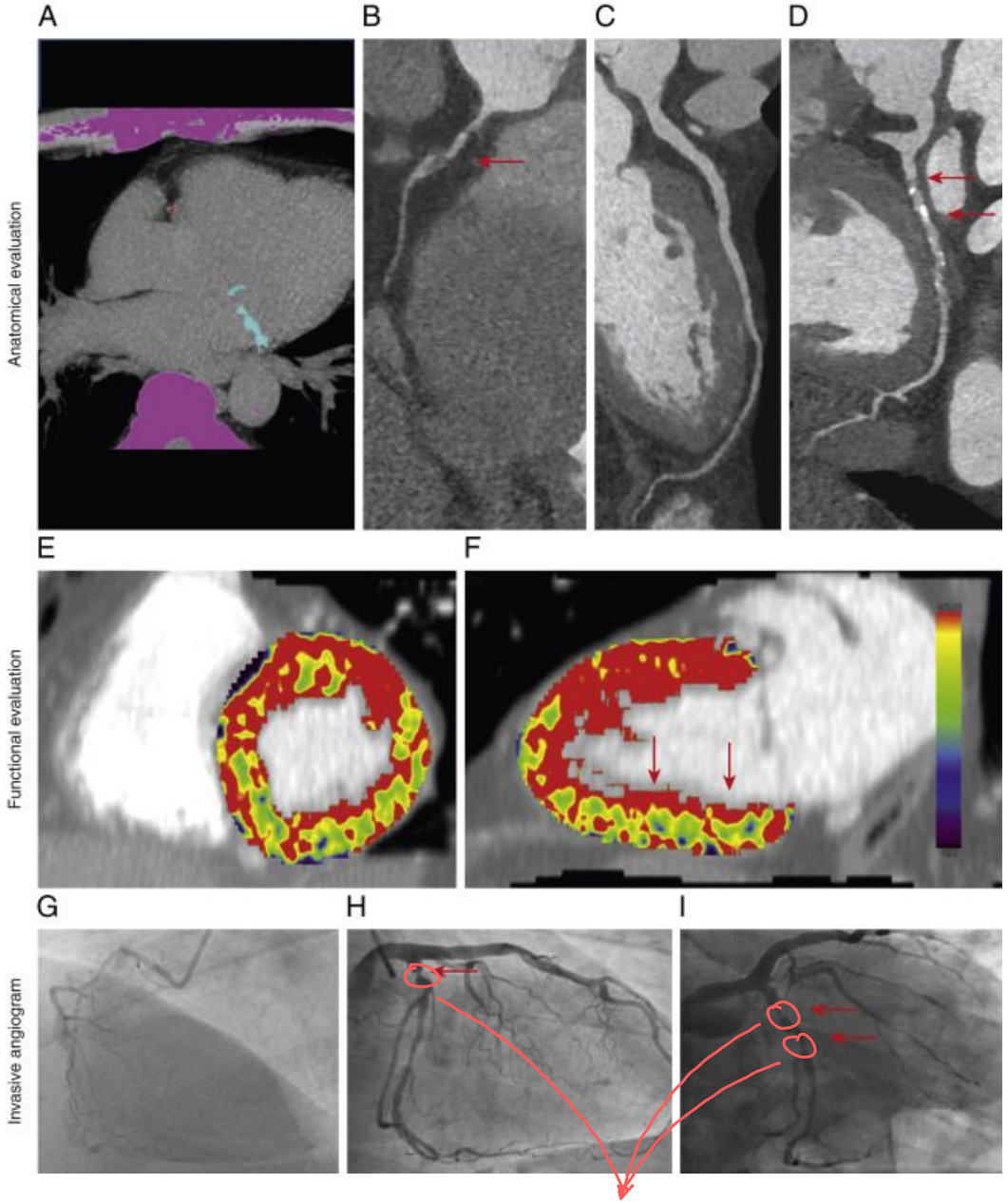


# Functional evaluation

- color-coded

# Conventional- angiography

رافع (Stenosis)

# Cardiac CT functional assessment

* 3D images of chambers

end diastole & end systole images.

بحسب الفرق وبيعطي

( ejection fraction )

* muscle contractility بحسب

# ماتنسى انه الـ MRI ادق من CT

في هذا الموضوع ...

# ماتنسى انه نادراً ما يتم ارسال المريض لـ CT

من اجل Cardiac CT Functional Assess

هو بروح عشان Coronary vessels وبالمرة بعملوا

الـ Functional Analysis

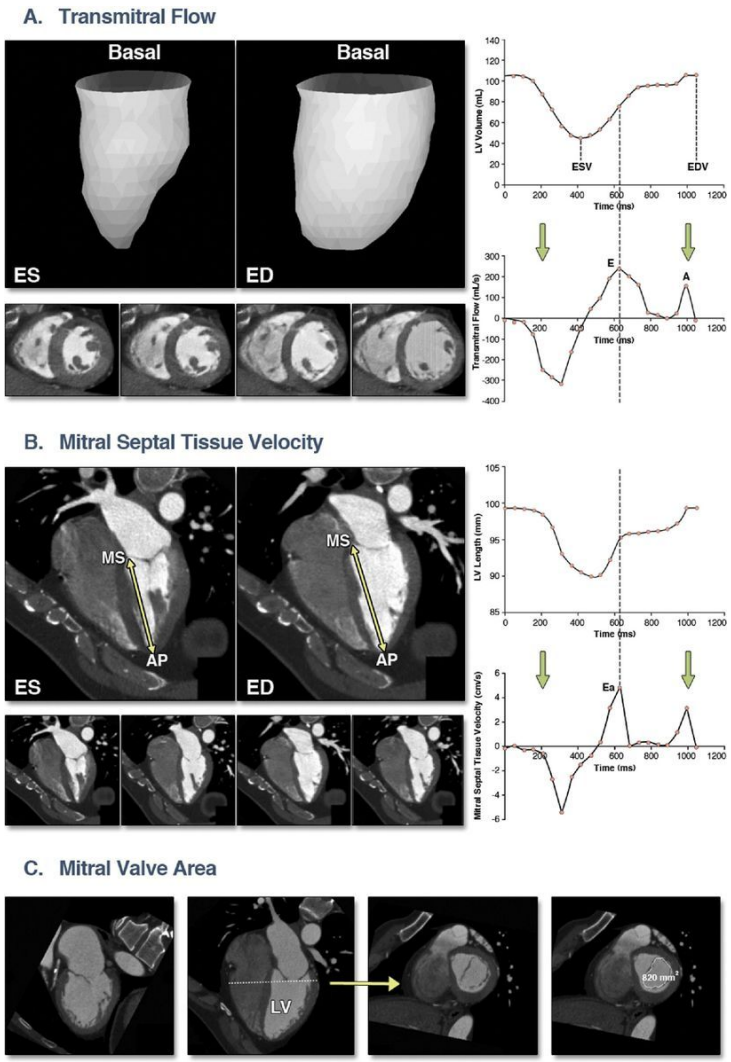


$$\text{Transmitral Velocity} = \frac{\text{Transmitral Flow (mL/s)}}{\text{Mitral Valve Area (mm}^2\text{)}} = \frac{\text{cm}^3/\text{s}}{\text{cm}^2} = \frac{\text{cm}}{\text{s}}$$

By CT

يعتمد الـ software

↑↑ sensitivity & specificity

" not operator dependent "

By CT

# LV apex thrombus

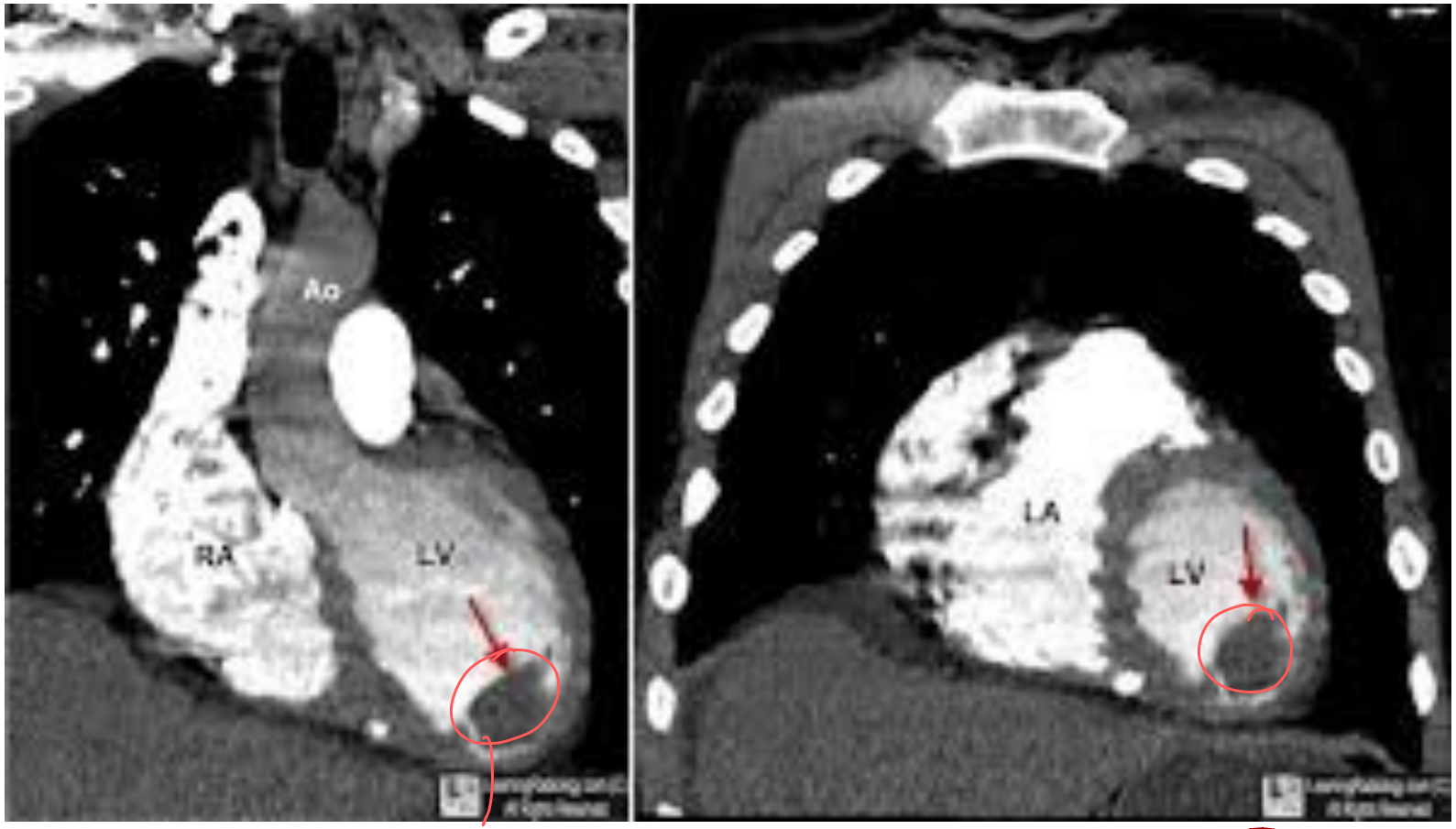


Filling defect

= ↓ enhancement (↓ density than muscles) → بيميزه ال muscles

لو كان Tumor

بياخد enhancement

easily detected by Cardiac CT

# Myxoma LT atrium ( most common location)

Filling defect in Lft near to the atrial septum ∞ some calcification ∞ took some enhancement

(mainly Tumor)



# Cardiac MRI.

Rem
1. Cardiac Isotope
2. Cardiac CT
3. Cardiac MRI

- Patient cooperation ( long study).
- ECG & respiratory gating .
- Specialized technician and physician( skill demanding).

+ very expensive study

some sequences in MRI require Breath hold



بدون استخدام صبغة حتى وادرك ال CT بكثير

# Cardiac MRI used for:

MRI detect
- infarction
- Fibrosis
- Amyloidosis
- Deposition etc. in the muscles

# أفضل لاعب

وبدت تتفوق ع isotope في ال viability

زمان كان ال isotope ودخل الخط ← CT & MRI قبل ← اضعف لاعب

MRI >>> CT

حتى x contrast — MRI >>> CT — لازم contrast

- Muscle viability , masses, thrombus , contractility .
- Functional assessment . (Contractility)
- Used to assess complex cardiac congenital anomaly.
- Coronary vessels.

CT can be used also

بس النيال بضله غالي

MRI >>> CT

من جديد دخلت ال MRI ع الخط

# The gold standard is Cath lab then CT

وحاليا دخلت ال MRI عشان تفيدنا أكثر في موضوع ال Calcification وغيره...

MRI
- Chambers
- relation to the major vessels
- septa.
- valve status

# MRI → m. viability needs MRI Contrast (like CT)

Contrast is not required in Functional Studies

schematic diagram

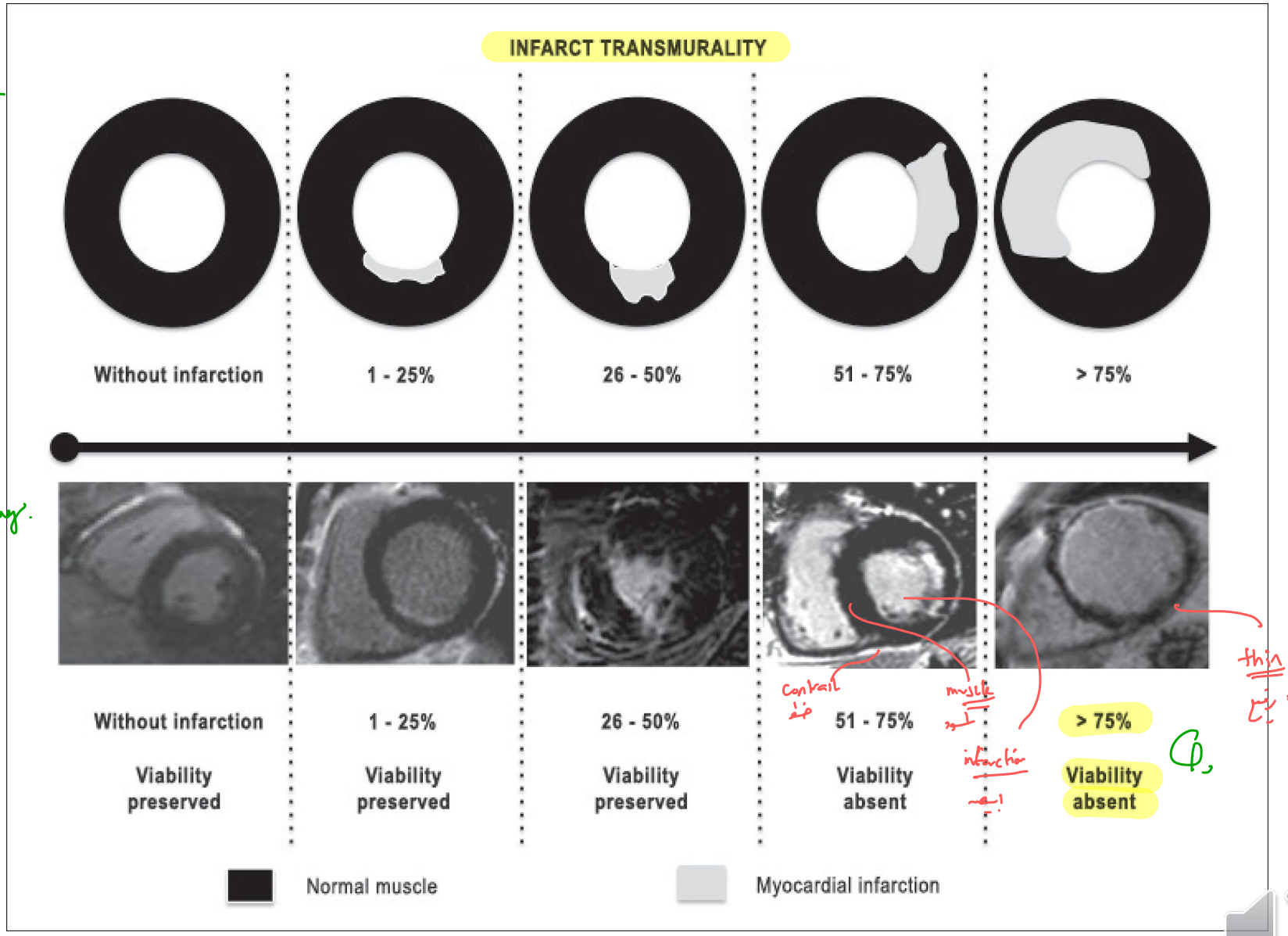


cardiac imaging.

↑ thinning of muscles

↑ ischemia

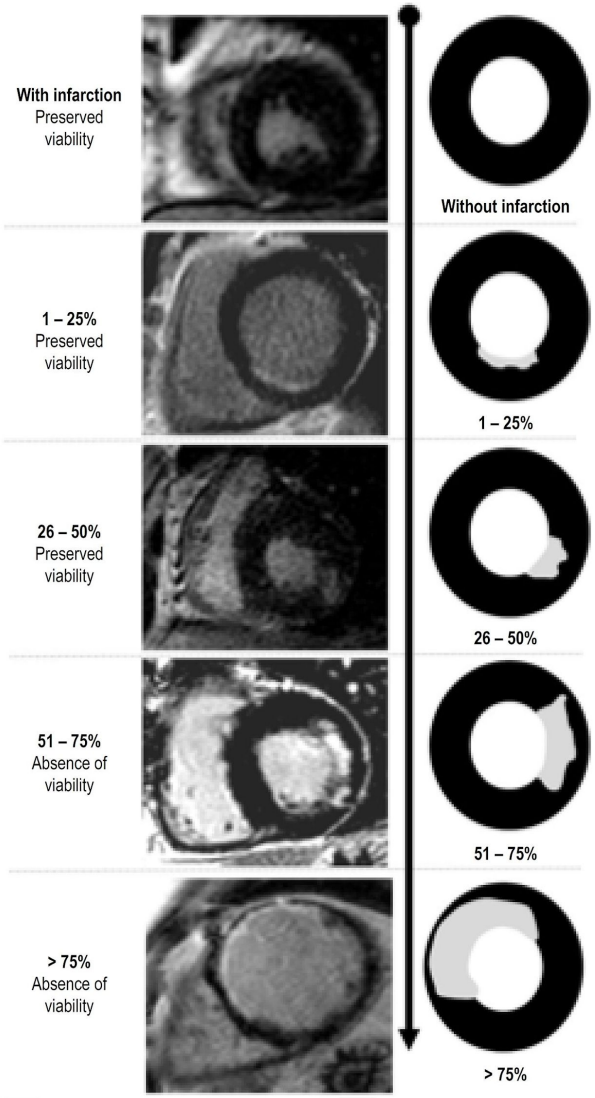

Another Application for MRI is Myocardial Mass in Hypertrophic Myopathy.

echo

MRI دخلت ع الساحة بقوة

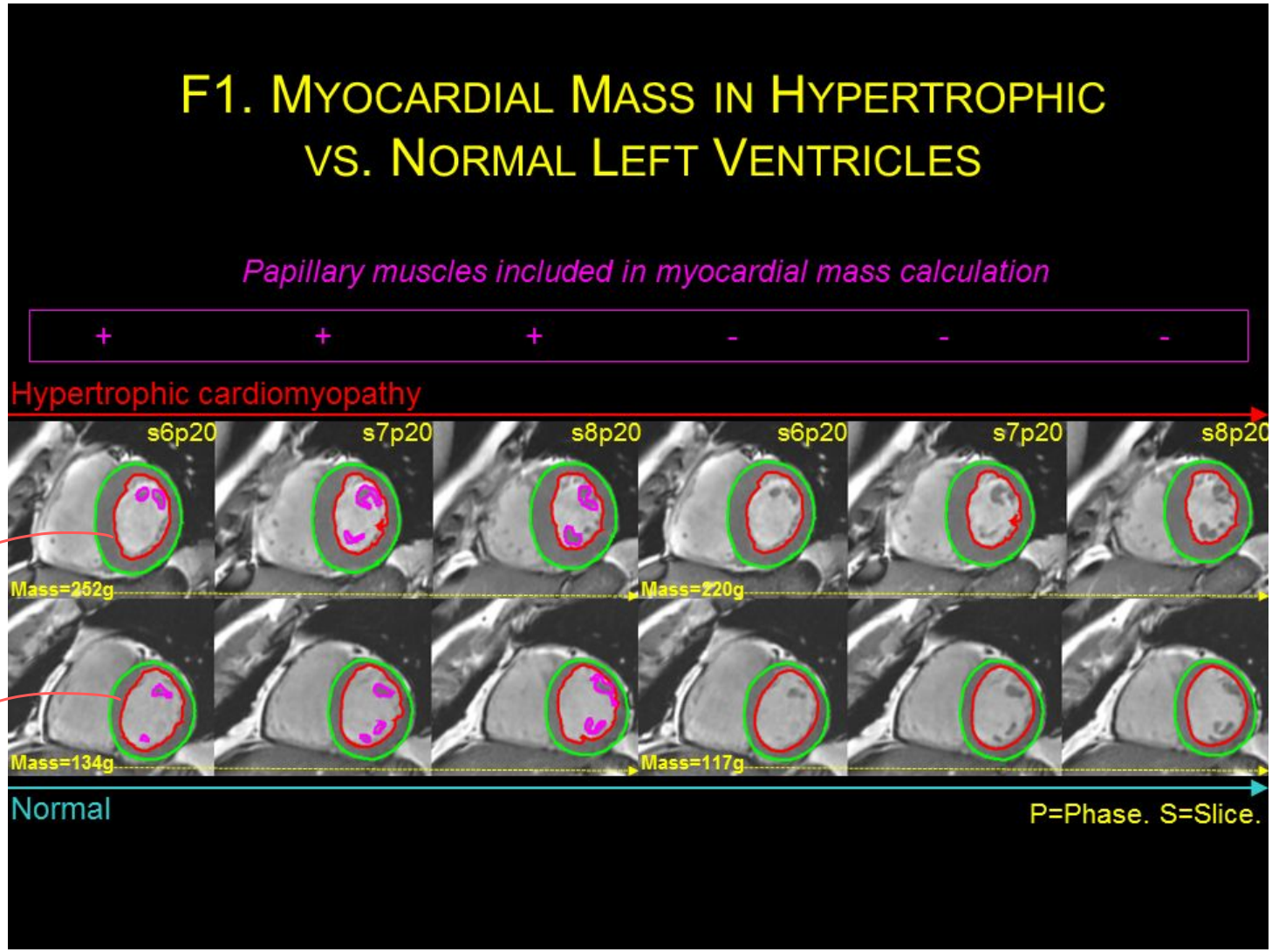


أحيانا بيجأوا انهم يعملوا

Debulking of muscles by surgery

↑ muscles

normal ال

بحدد ال mass بالذات بالربط كل جزء من القلب ع كل level in cross section

# Cardiac MRI ∝ Contrast

LV Apex

thinning of muscle

ولون ال muscle
صار ابيض ولكن
باقي ال muscle
اسود

وهذا نتيجة

① thinning

② MI

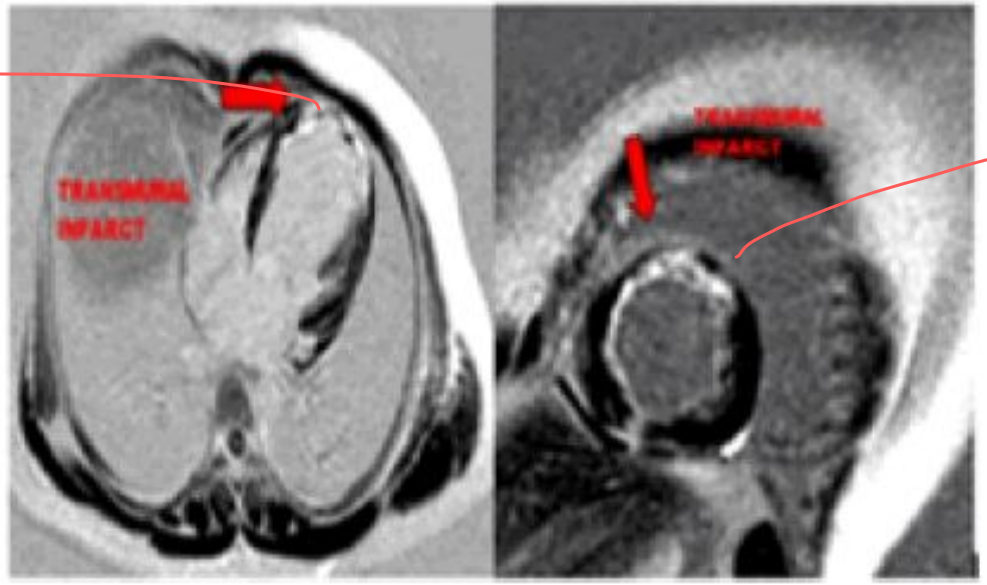


**Figure 2a:** Cardiac MRI short and horizontal axis showing transmural infarct (arrows) involving the apical, apical anterior, antero-septal segments.

Subendocardial enhancement & upper part of the muscle is white now due to MI

# Time Interval Images

Acute Phase (w1)

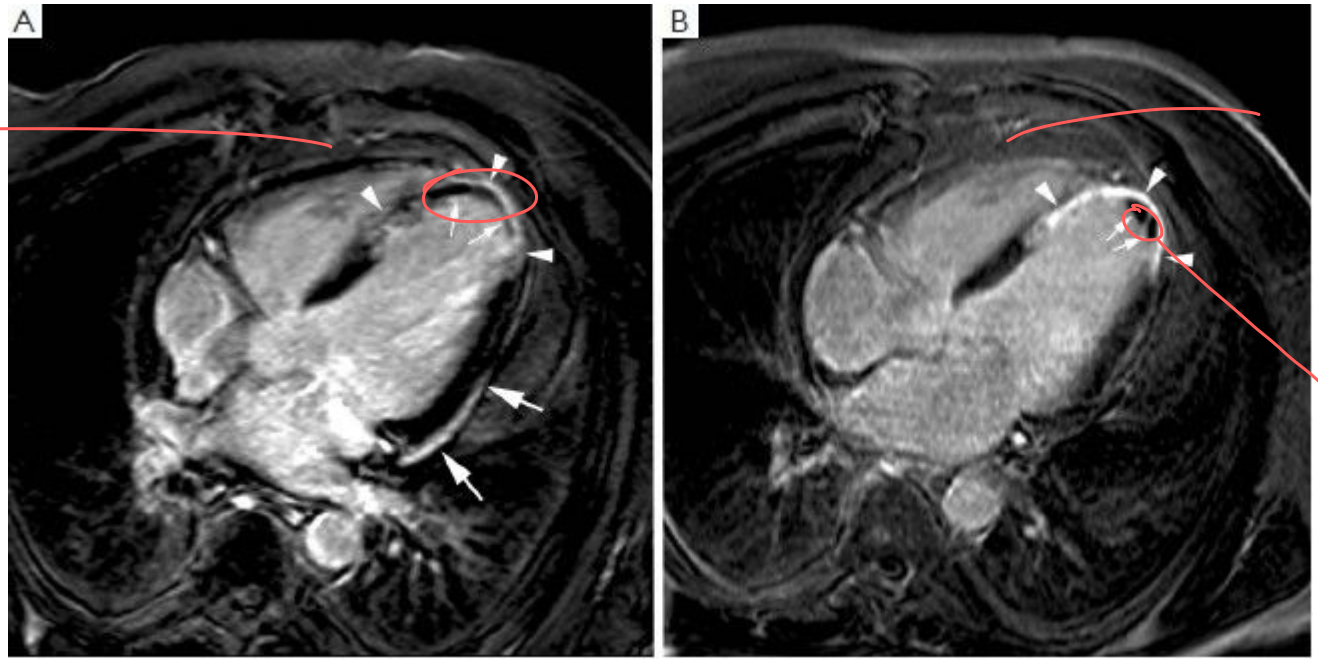


(4M)

Thrombus

* Thinning
  status of myocardium
* Enhancement

Late gadolinium imaging in horizontal image plane at 1 week (A) and 4 months (B) after the acute event. At 1 week, presence of diffuse enhancement of the apical part of the ventricular septum and LV apex (arrowheads, A) with large area of microvascular obstruction (small arrows, A). Note the presence of some pericardial enhancement over the laterobasal part of the LV (arrows, A). At 4 month follow-up, the infarct has thinned and strongly enhances (arrowheads, B). Note the presence of a small mural thrombus in LV apex (arrows, B)

No need for Contrast in MRI
Contrast is req. in CT

# LV ventricle apex thrombus

ميزة ال MRI عند ال CT
هنا

Thrombus in Apex

MRI




Echo

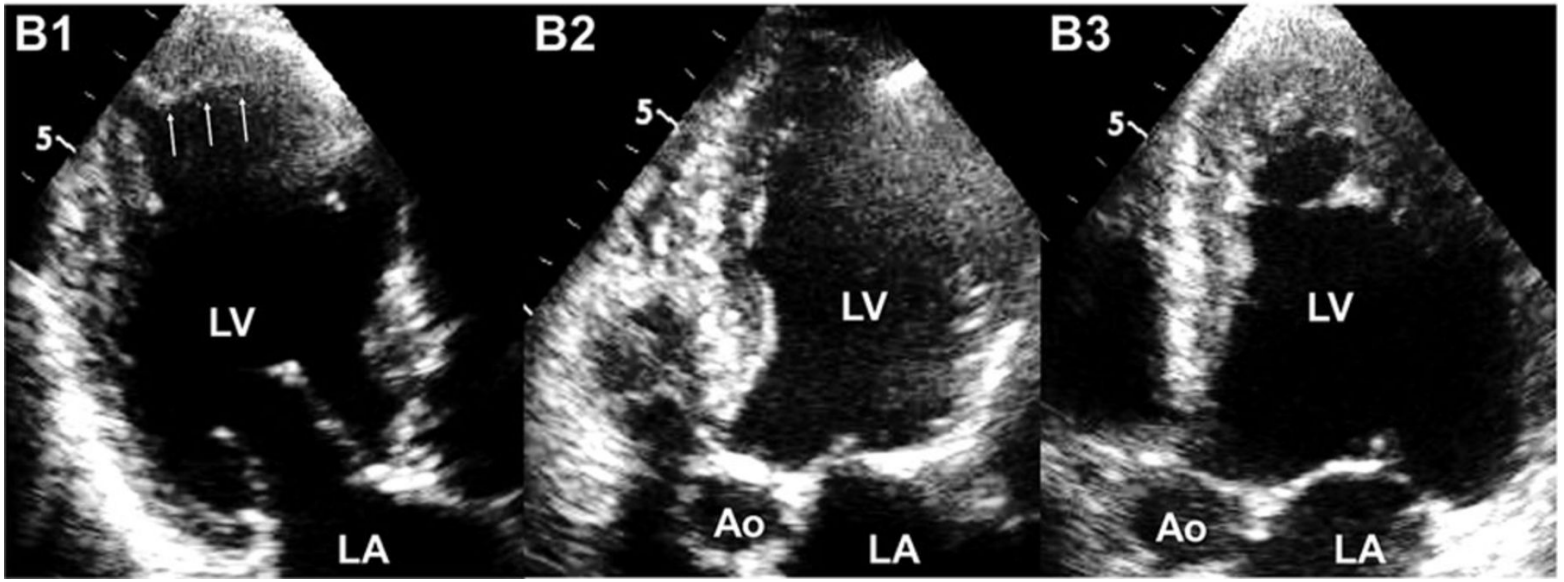

x contrast in MRI
✓ contrast in CT

# Myxoma at RT atrium bulging inside the RT ventricle.

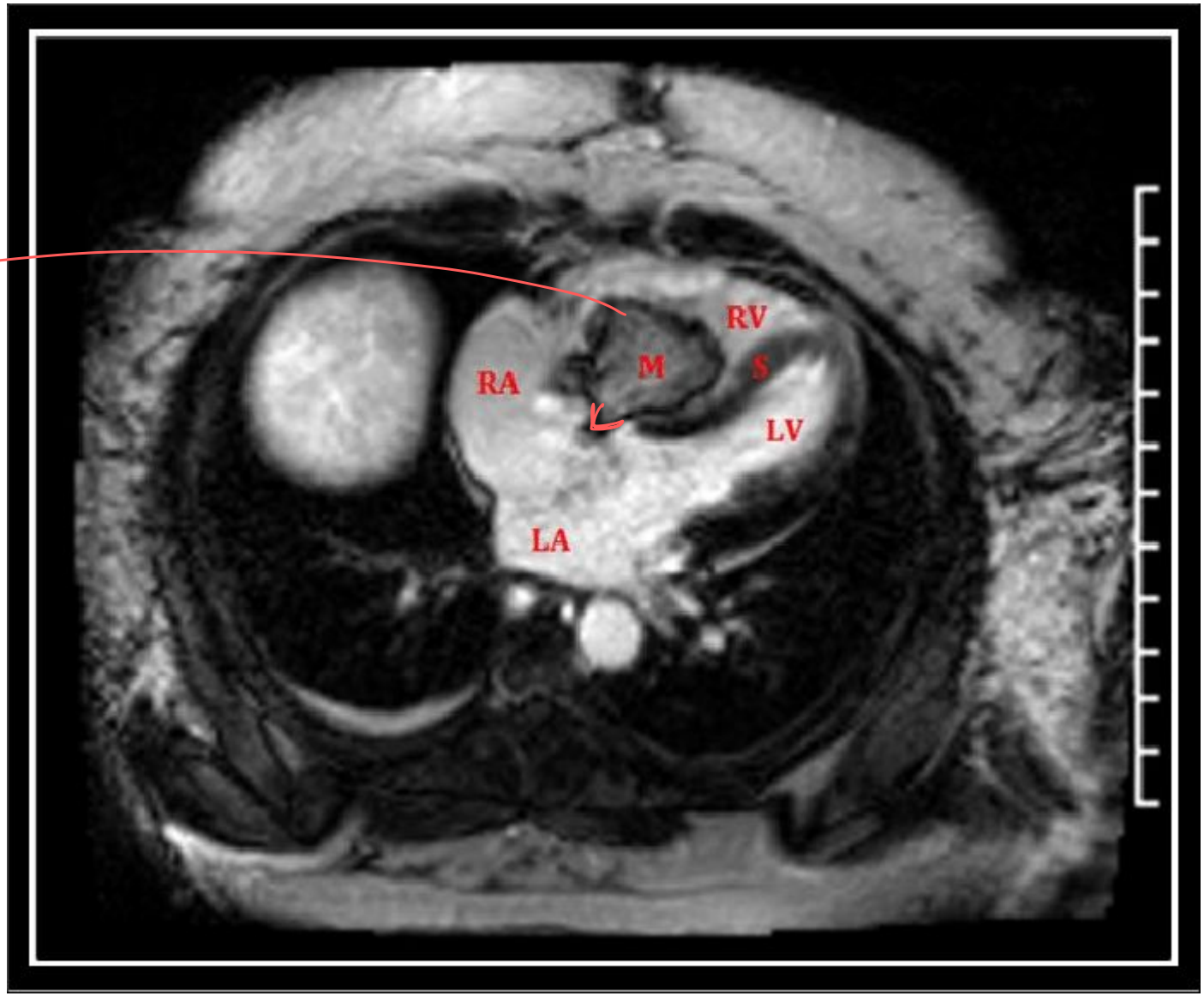


myxoma

Pulging though the valve

Filling defect

signal معطية

مثل ال muscles in T1 & T2 & other MRI sequences

وبالتالي ما في داي للصفتر #

ممكن اعطيه صبغة لتأكيد بعض الامور

other application for MRI

→ deposition dz in muscles — Amyolodosis

→ muscle dystrophy

وهكذا ...

→ Functional Assessment

بتتفرع كل شيء ثاني

(time consuming) * المشكلة الوحيدة

(high cost)

Echo US لذلك ممكن نستخدم

في امور متعددة مثل "

# Functional Analysis #