CARDIAC IMAGING
X-RAY

DR. MOHAMAD MATAR



X ray → the most imp modality fo, Heat & chest

1. highly available, can be done at any department.
2. can be evaluated by any medical profession.
3. Cheap
4. can be done in a short time

Borders of the heat ...

* Lt border — LV wall (middle & lower part)

Superior to it (LA Appendage) not the LA

ما بكون عامل Pulge على الأعلى

لفوق شوية عنا

Pulmonary trunk

ثم ال Aortic knob

إلي بيعطينا ال Des. Aorta

* Rt. border (RA)

NB. RV lied on the diaphragm

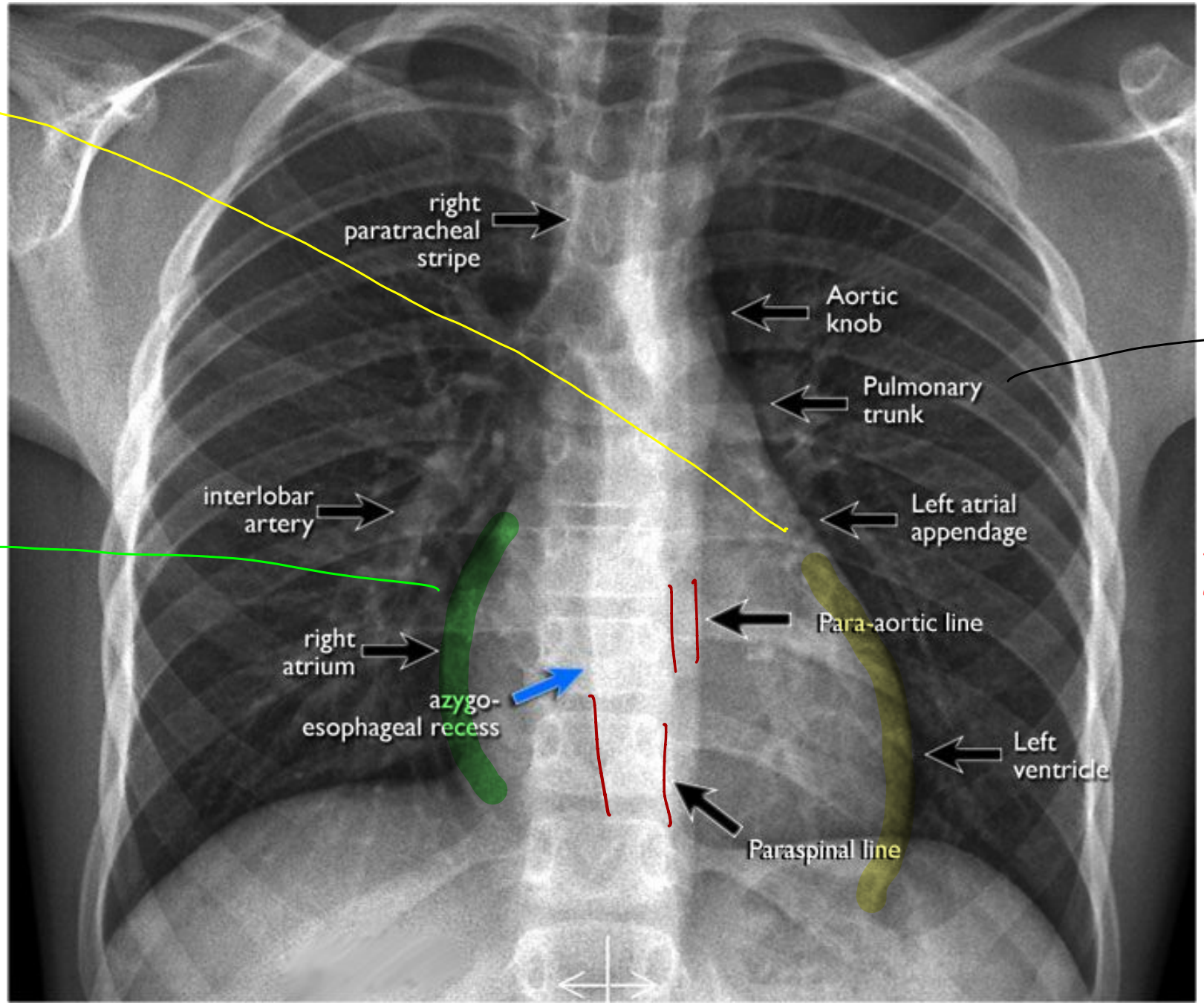

2 important lines ...

① Paraaortic line

② Paraspinal line

+ Pulmonary Ar < Rt / Lt.

القلب مبين بهذا الجمال لأنه ال

↓ lung density (air)

↑ heat density

لو ما في اختلاف في ال density

"Silhouette Sign"

ببطل قادر لميز القلب عن الرئتين

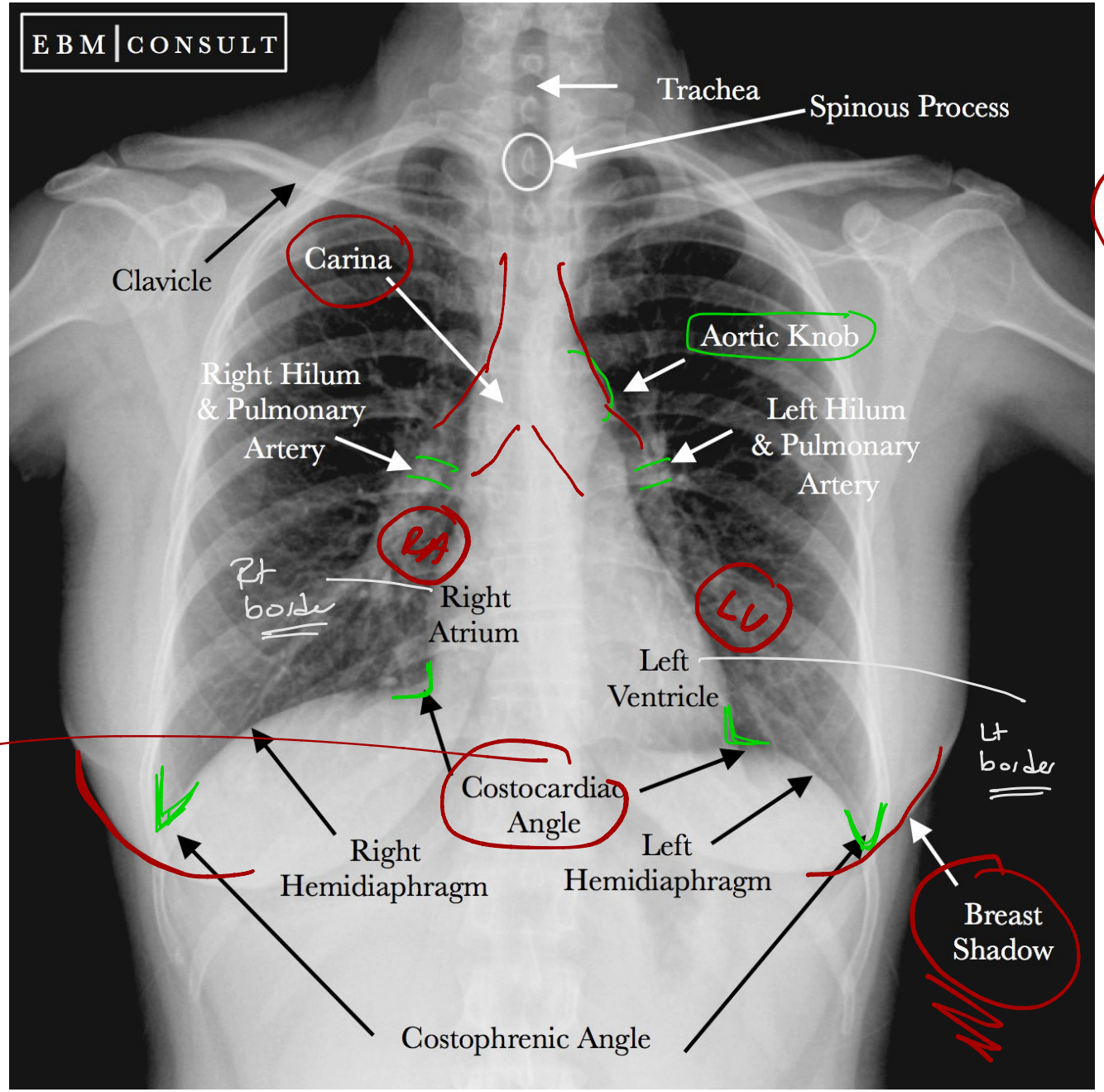
EBM | CONSULT
Trachea
Spinous Process
Clavicle
Carina
Aortic Knob
Right Hilum & Pulmonary Artery
Left Hilum & Pulmonary Artery
Right Atrium
Left Ventricle
Costocardiac Angle
Right Hemidiaphragm
Left Hemidiaphragm
Breast Shadow
Costophrenic Angle

LV RAmi

Left border Rt. border

RV LA

Face dia متجي

Post.

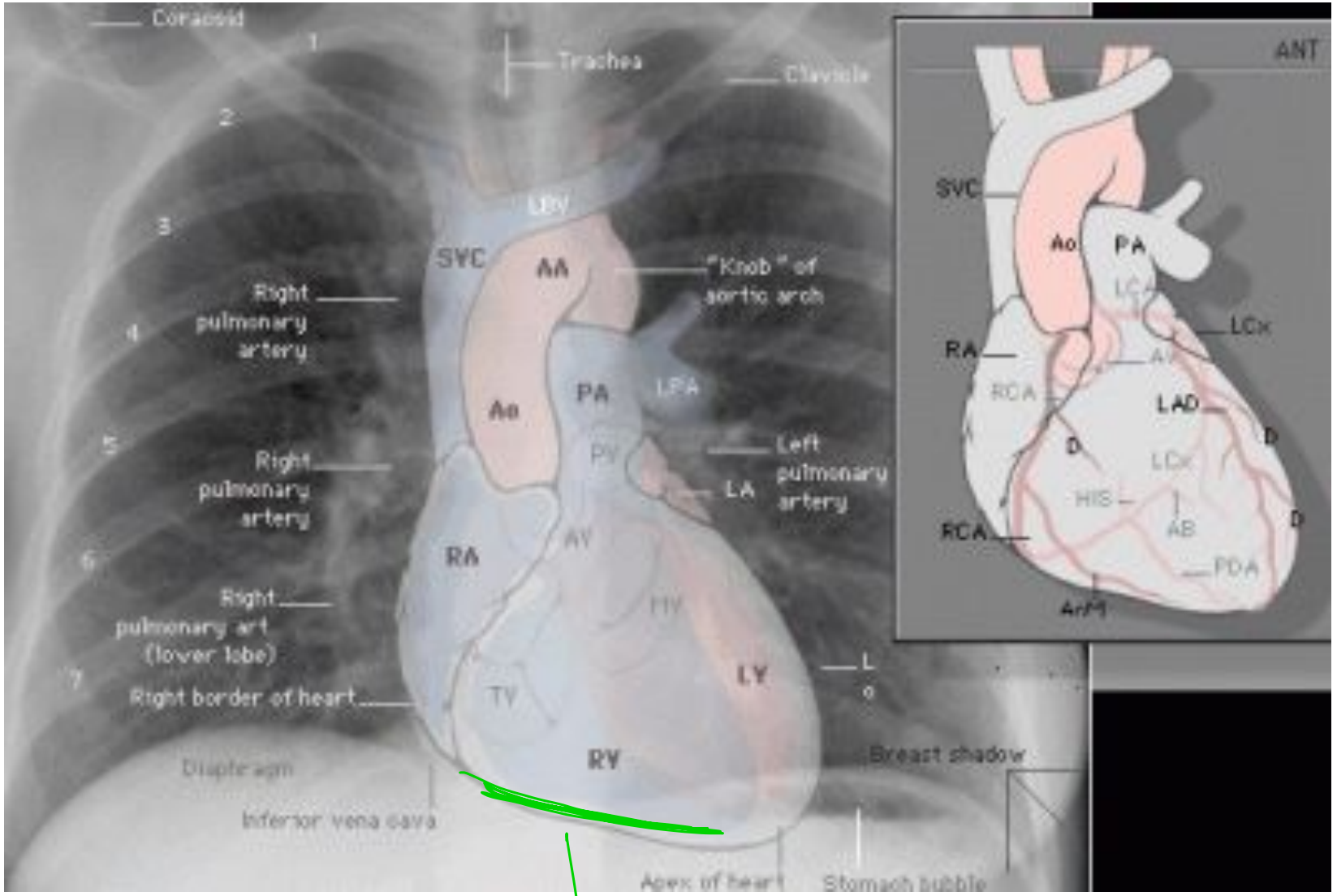

RV face the diaphragm. & the LA is Posterior

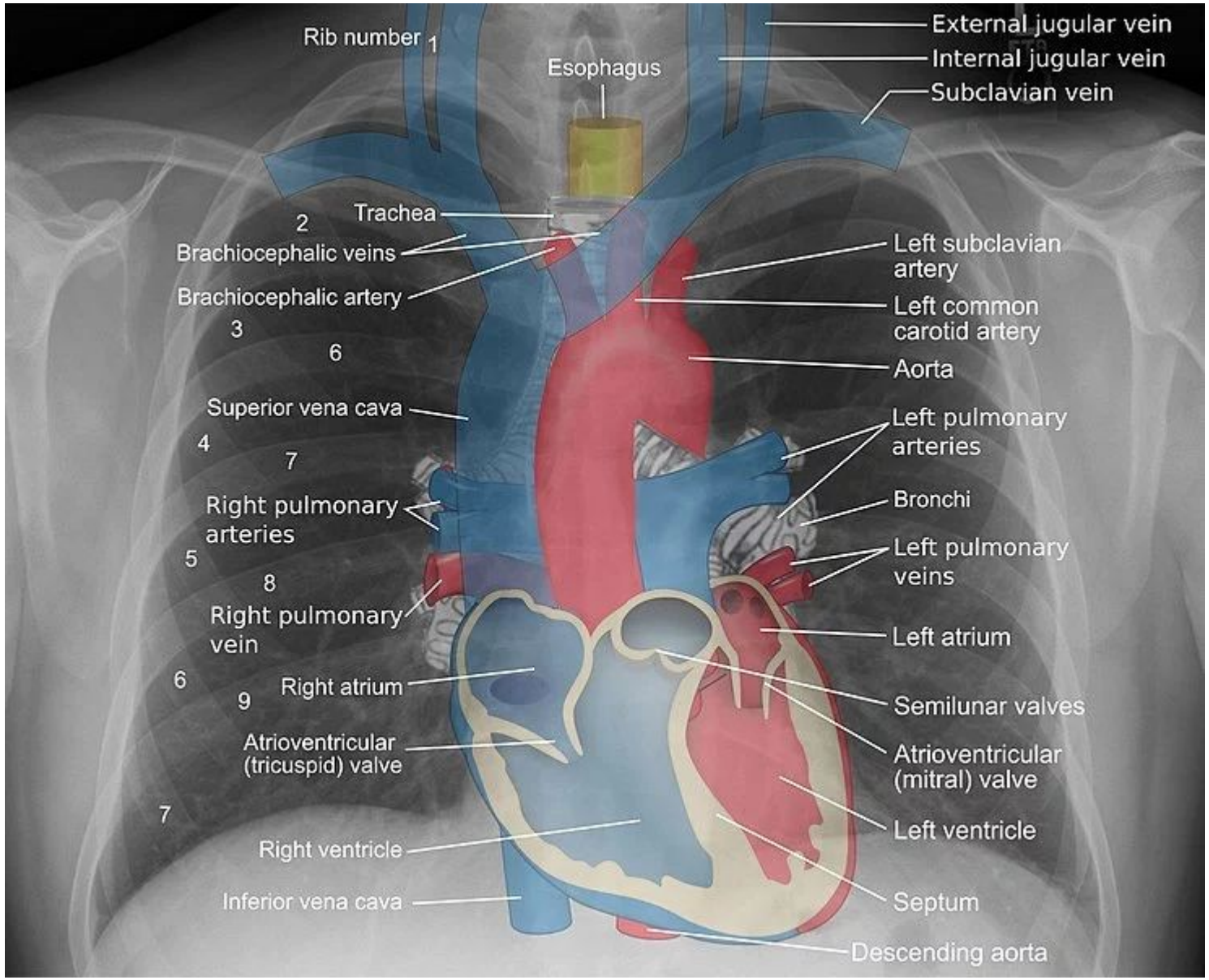

orientation of valve

بدلني ع ~~ast~~

In CXR,

- can count 6-7 Ant Ribs

8-10 Post Ribs

* Transverse Position
* Posterior

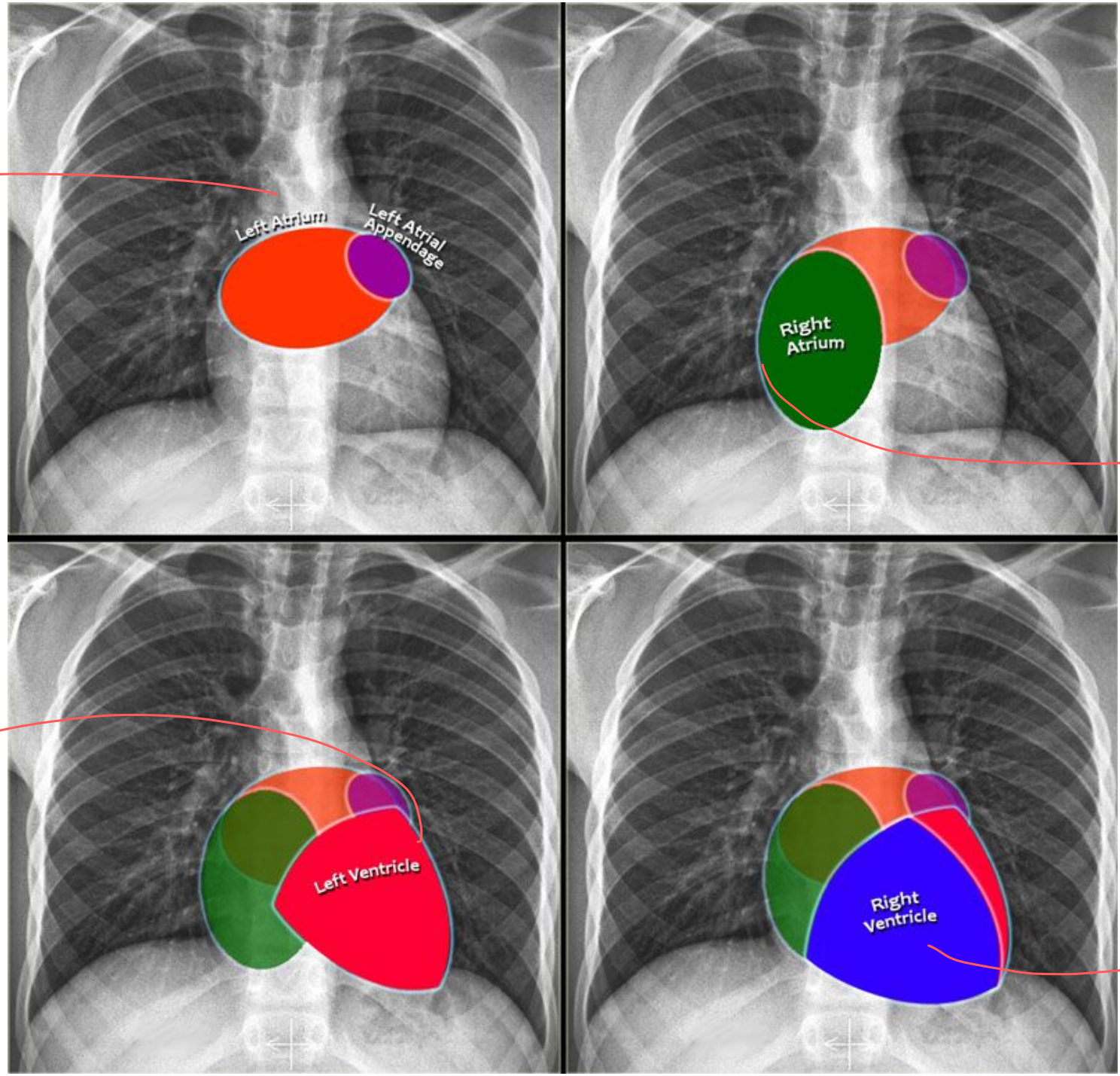

Rt border

Lt. border

inferior

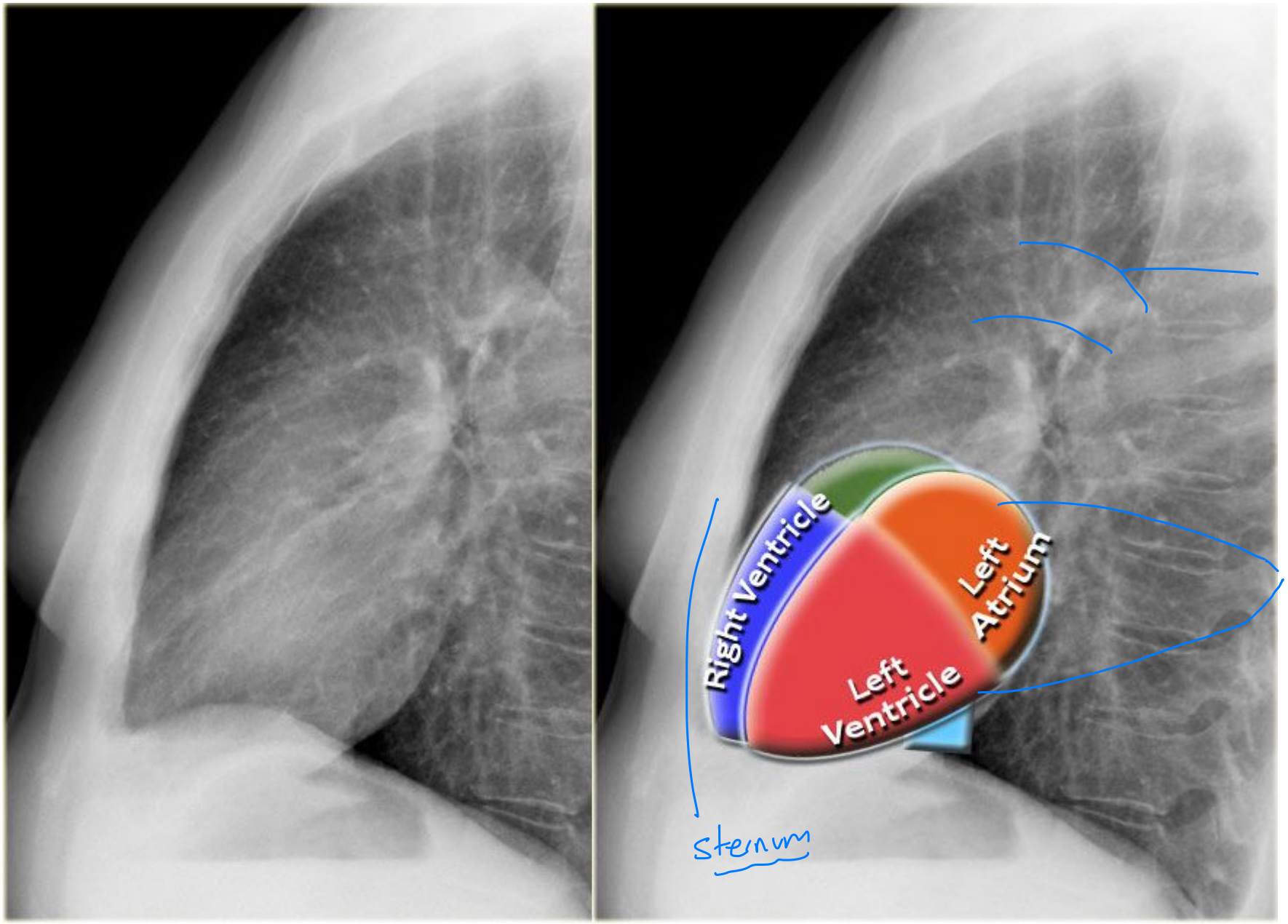

Aortic Arch

LA & LV

→ Posterior Part of Heart

RV → Ant. Border of heart opposing the sternum.

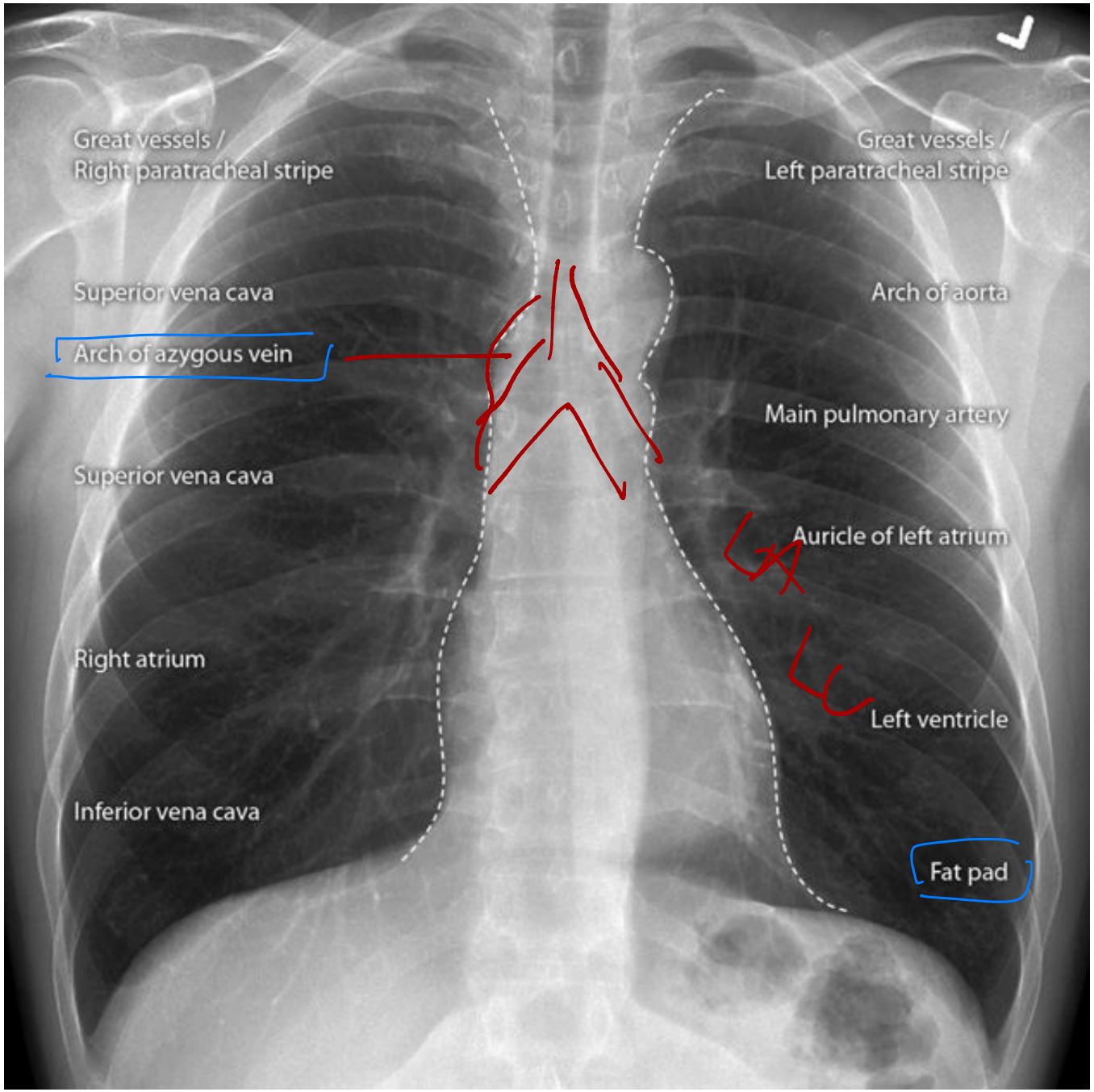
Great vessels /
Right paratracheal stripe
Great vessels /
Left paratracheal stripe
Superior vena cava
Arch of aorta
Arch of azygous vein
Main pulmonary artery
Superior vena cava
Auricle of left atrium
Right atrium
Left ventricle
Inferior vena cava
Fat pad

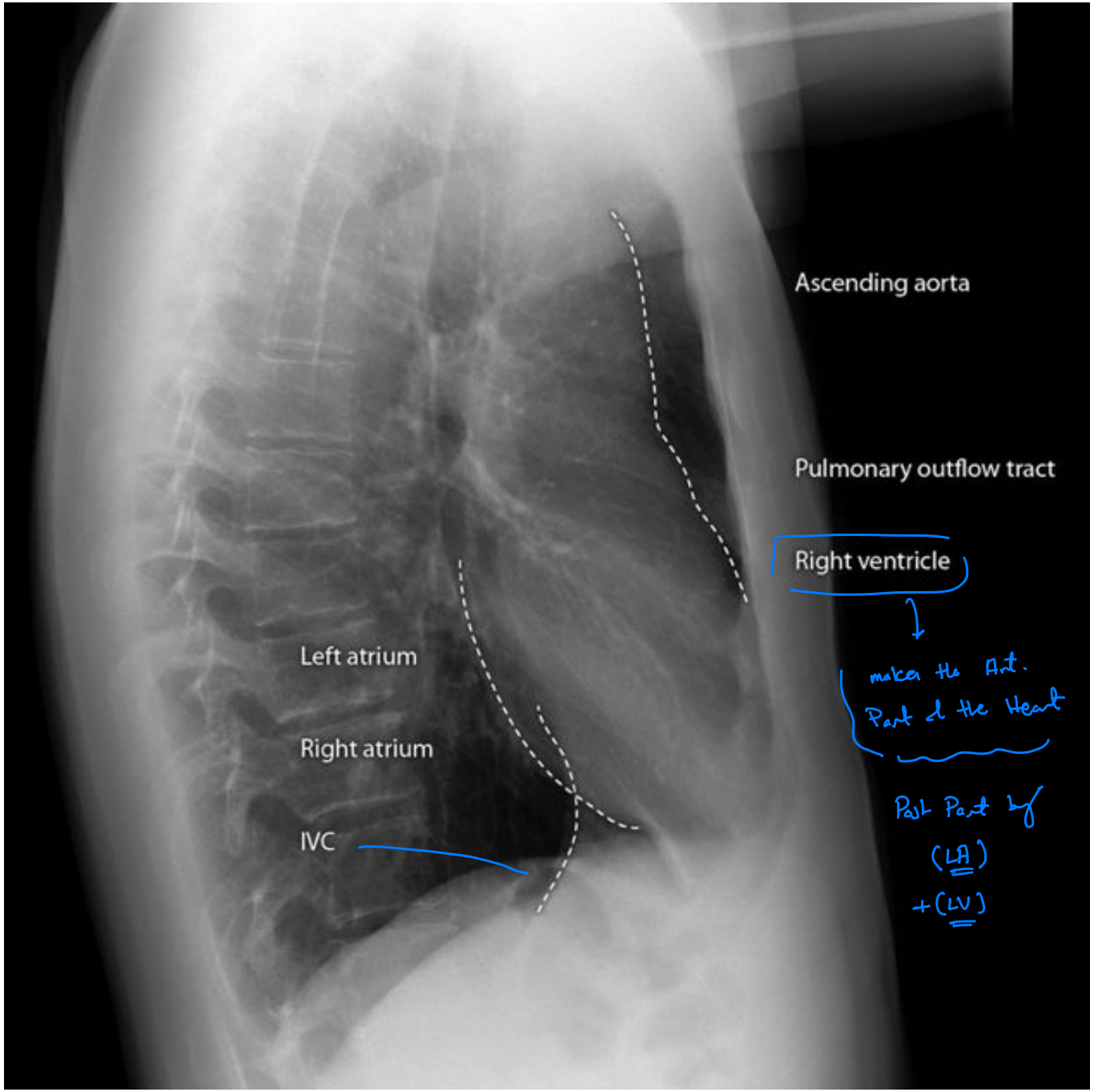
Ascending aorta
Pulmonary outflow tract
Right ventricle
Left atrium
Right atrium
IVC
makes the Ant.
Part of the Heart
Post Part by
(LA)
+(LV)

RV → main pul ar

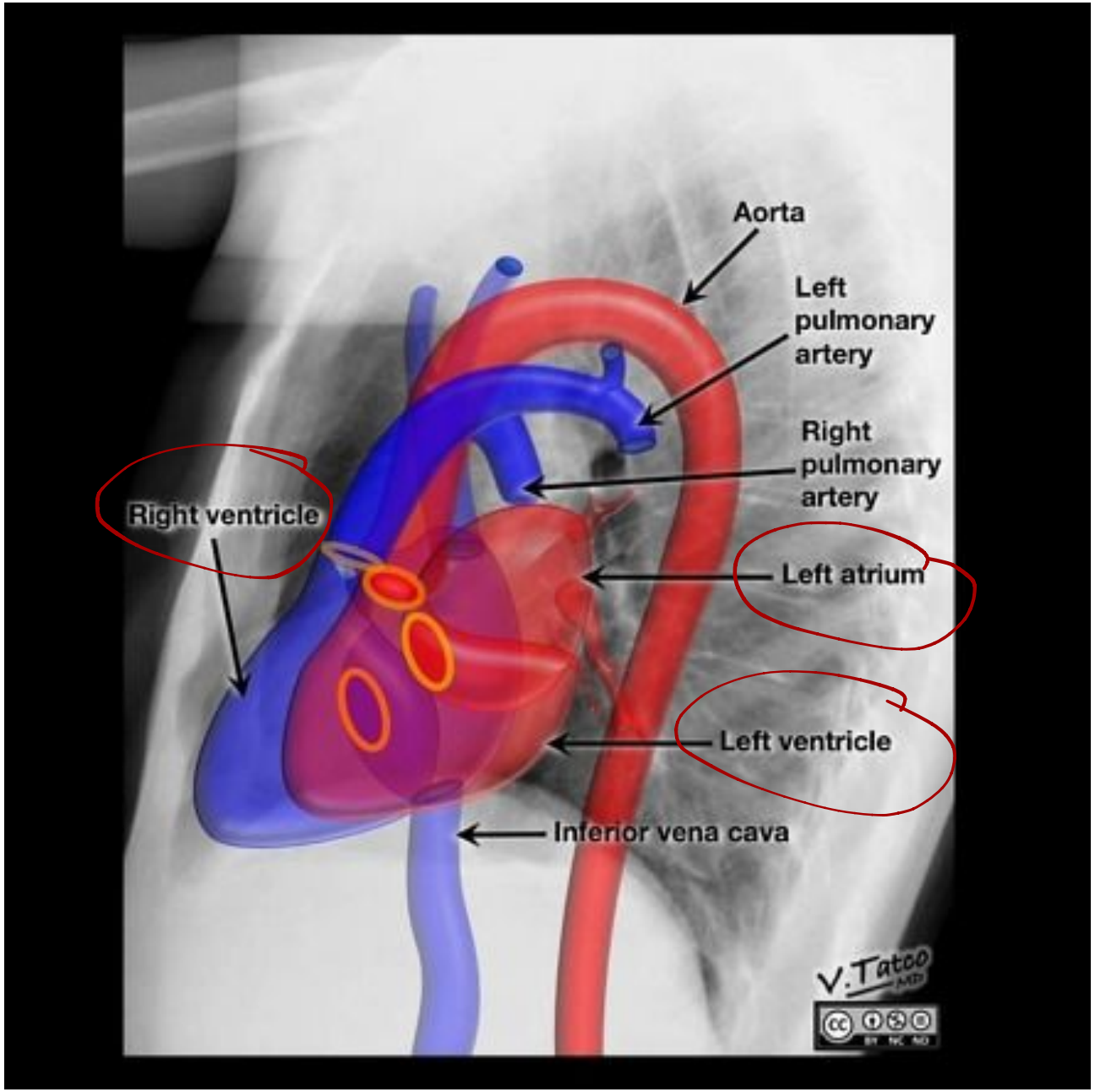

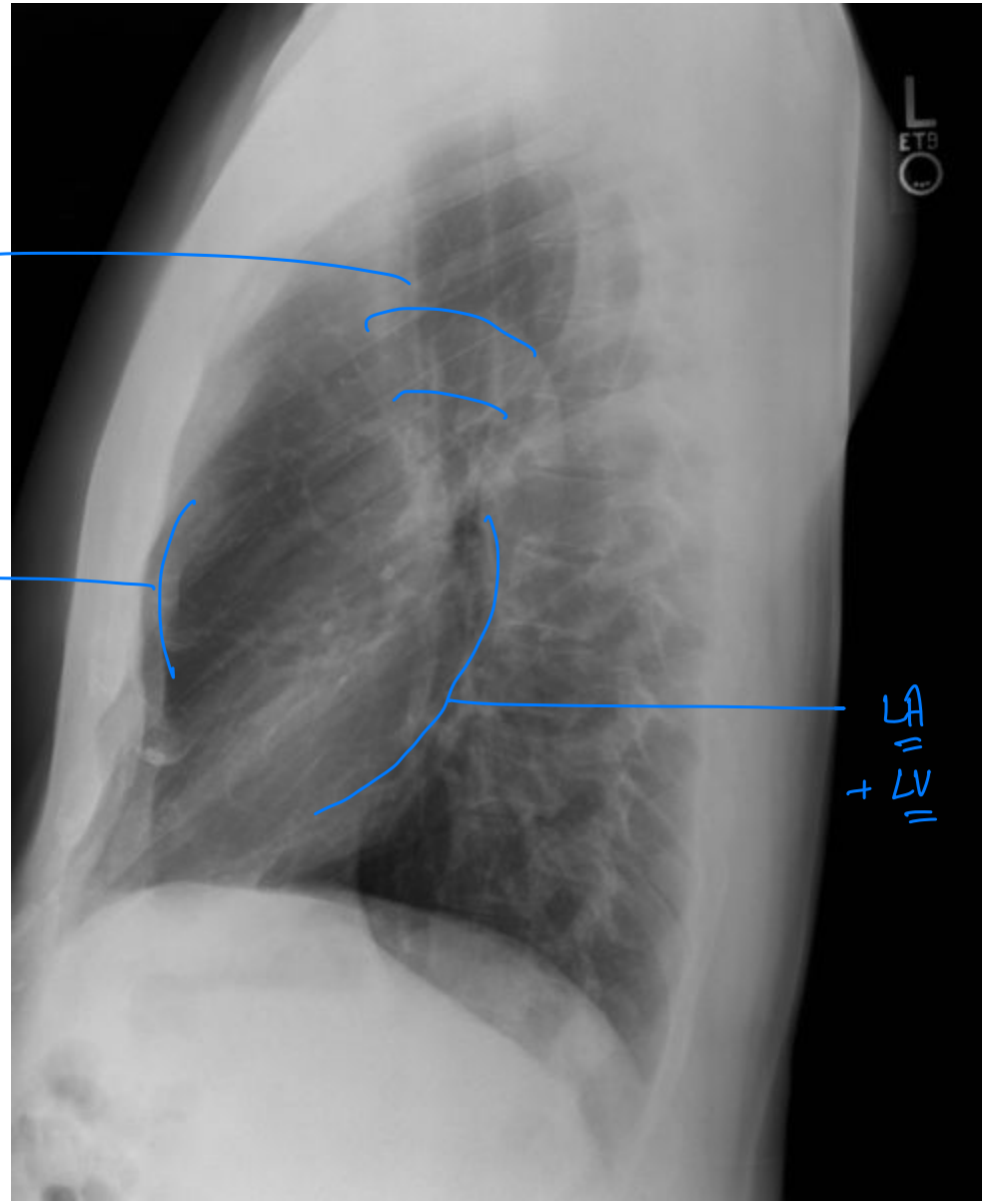
Aortic Arch
RV
LA
+ LV

CARDIOMEGALY

* you have to know the status of the film

weather it's

① supine / PA ← [illegible]

② full / not full inspiration

③ ✓ × Rotation of the Pt

NB. in Pediatric CXR is AP not PA

عشان اهله يمسكوه

NB. the film has to be in standing position & PA Film.

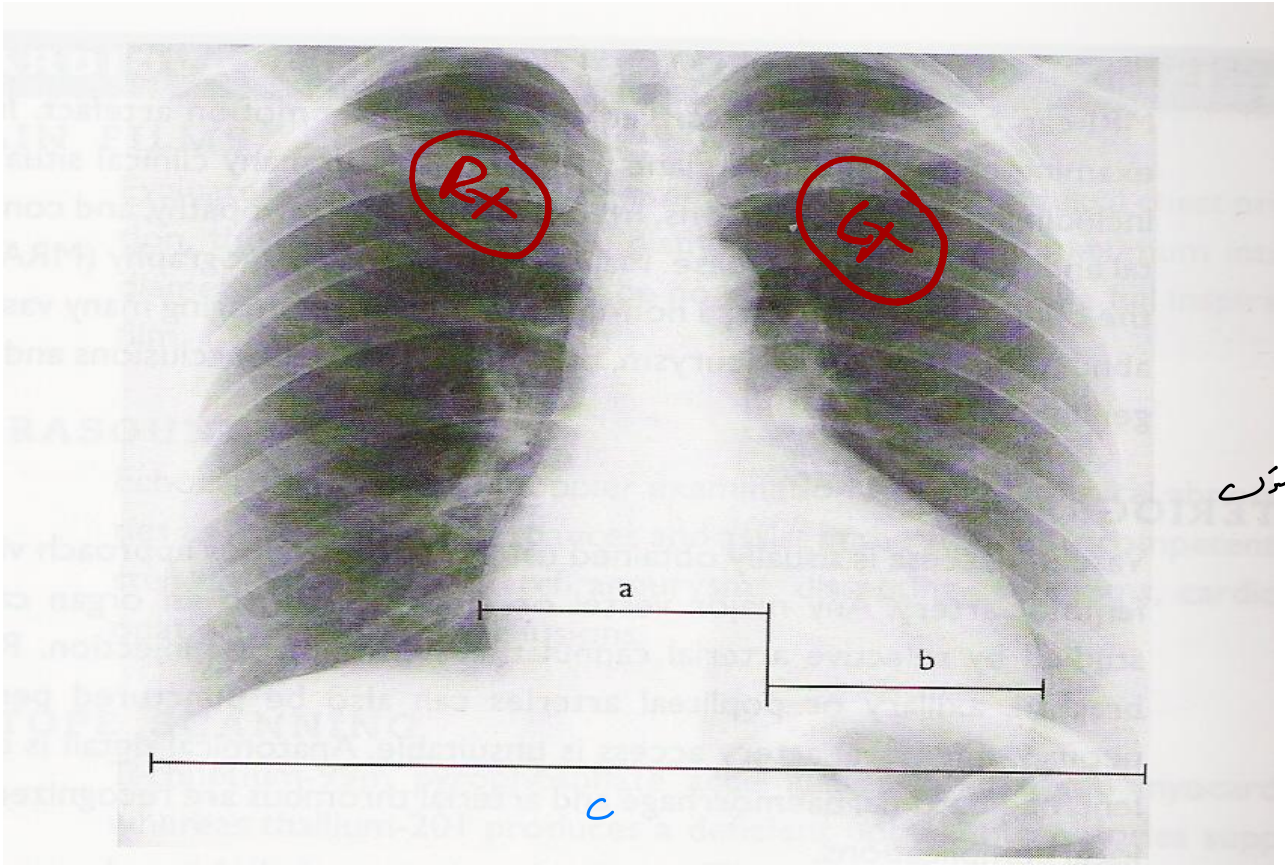

Cardiothoracic index

$$\left[\frac{A+B}{C}\right]$$

& costophrenic Angle.

ليش بنقسم ع C لانه A/B مش ع نفس المستوى



normal Cardiothoracic Index < 50% in adults & < 55% in pediatric

أكثر من هيك

Cardiomegaly

1

LT ATRIUM ENLARGEMENT

* NB. Global Cardiomegaly is measured by Cardiothoracic index indicates any cardiac abnormality in general.

* Causes of Cardiomegaly
  - mitral stenosis / regurgitation
  - Tricuspid Abnormality
  - Aortic Valve Abnormality
  - Any other cardiac dz.

→ These can be distinguished via (X-ray)

يمكن من ال X-ray تحديد

سبب ال (enlargement)

Causes of LA Enlargement...



- acquired
  - mitral stenosis ↑P. in LA → ↑dilation & size of LA
  - mitral regurgitation or insufficiency (in the late stage) NB. in early stage of M. regurg. → no LA enlargement.
  - left ventricular failure due to ↑P from the LA
  - left atrial myxoma lead to → ↑size of the Atrium
- congenital or due to valve abnormality → LA myxoma
  - ventricular septal defect (VSD) (common)
  - patent ductus arteriosus (PDA)



Direct visualisation of the enlarged atrium includes:

Signs of LA Enlar. — Direct / Indirect

السبب انه ال LA enlarges posteriorly
↳ dilation
→ shadow on the Lt. side

Double density sign = Double Border Sign. on the left side.

when the right side of the left atrium pushes into the adjacent lung, and becomes visible superimposed or even beyond the normal right heart border (known as atrial escape)

a similar appearance can be caused by the right superior pulmonary vein in patients without atrial enlargement .

oblique measurement : of greater than 7cm measured from mid point of left main bronchus to the right border of the left atrium (this requires a double density sign of course)

this is thought to be the most reliable sign on chest radiography

convex left atria appendage:

normally the left heart border just below the pulmonary outflow track should be flat or slightly concave

Indirect signs include:

- splaying of the carina, with increase of the tracheal bifurcation angle to over 90 degrees
  - This refers to both the inter-bronchial angle (i.e angle formed by the central axis of the left and right main bronchi) and the subcarinal angle.
  - Both are inaccurate and dependent on radiographer technique, inspiration and body habitus
  - The mean and range of both measurements vary widely in normal individuals.
    - interbronchial angle: normal mean 67-77° (with a range 34-109°)
    - subcarinal angle: normal mean 62-73° (range 34-90°)
- posterior displacement of the left main stem bronchus on lateral radiograph
  - right and left bronchi therefore do not overlap, but rather form an upside down 'V', sometimes referred to as the walking man sign [5] = reversed V sign .#
- superior displacement of the left main stem bronchus on frontal view
- posterior displacement of a barium filled esophagus or nasogastric tube

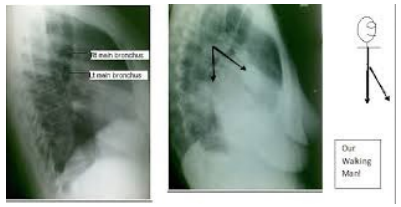

Carinal angle

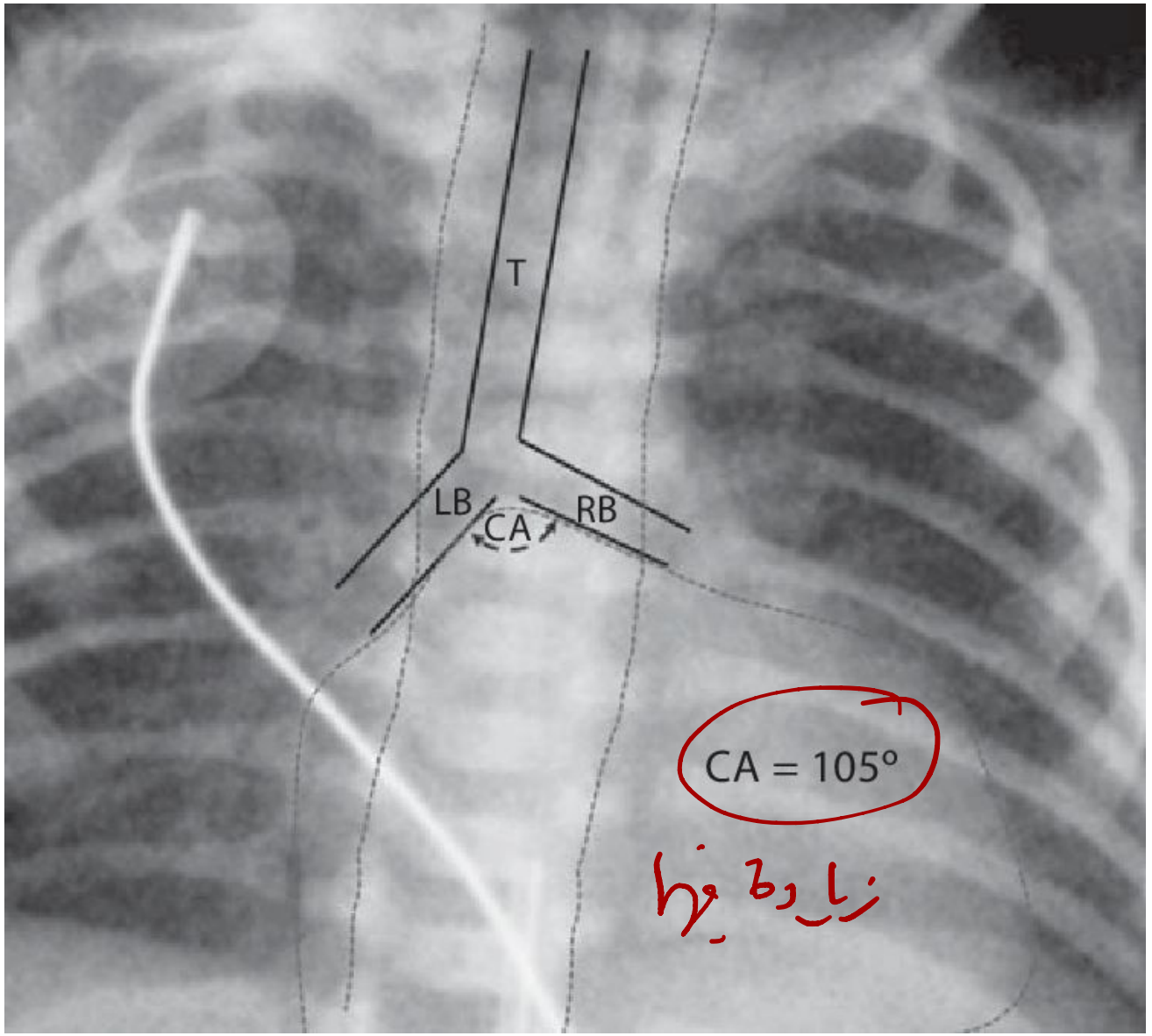

زيادة فيها

normal

62-73

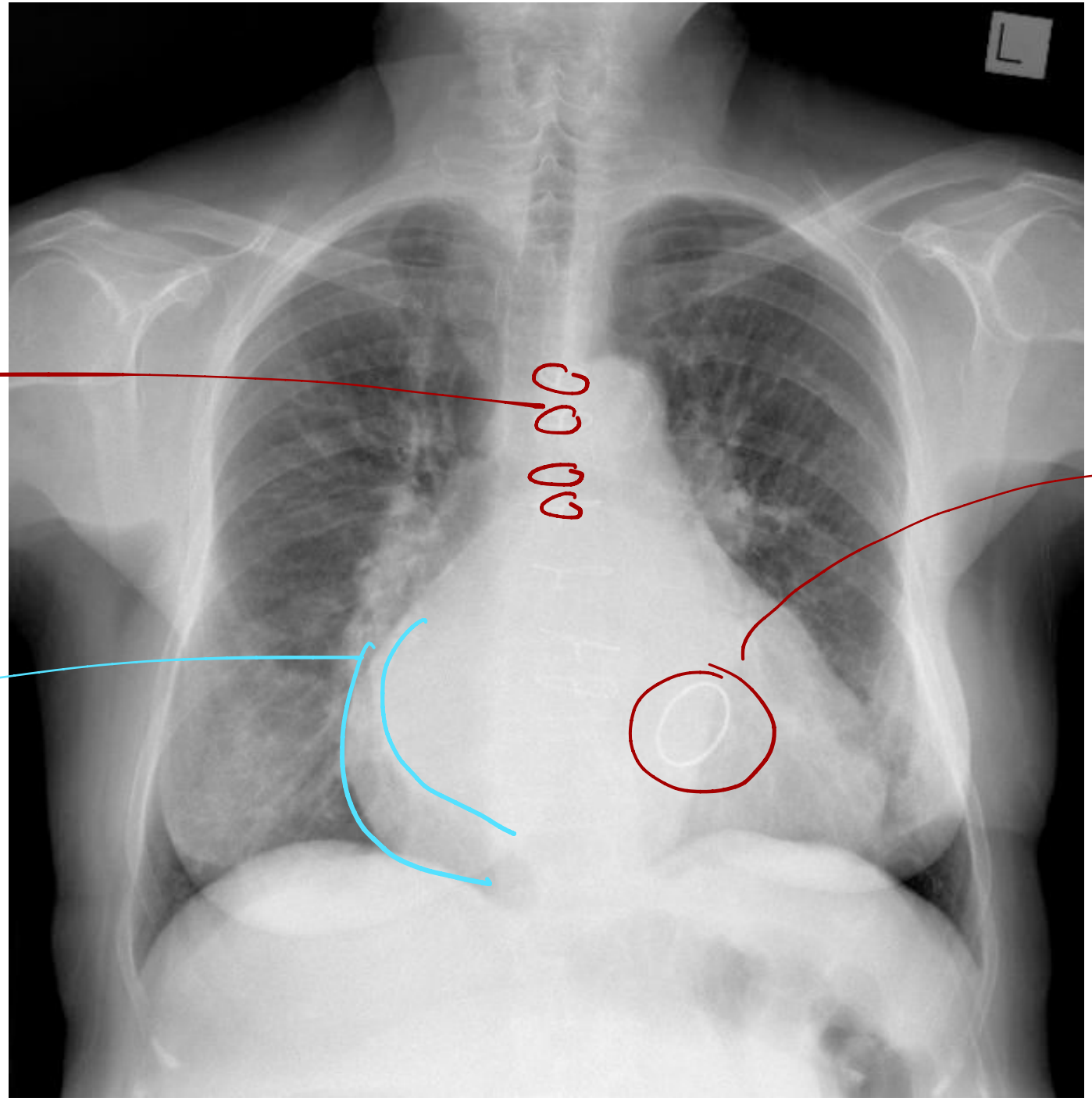

→ Open heart surgery (surgical clips)

Double Border sign

diffuse cardiomegaly.

mitral valve replacement (metal)

Double Border sign

= Double density sign

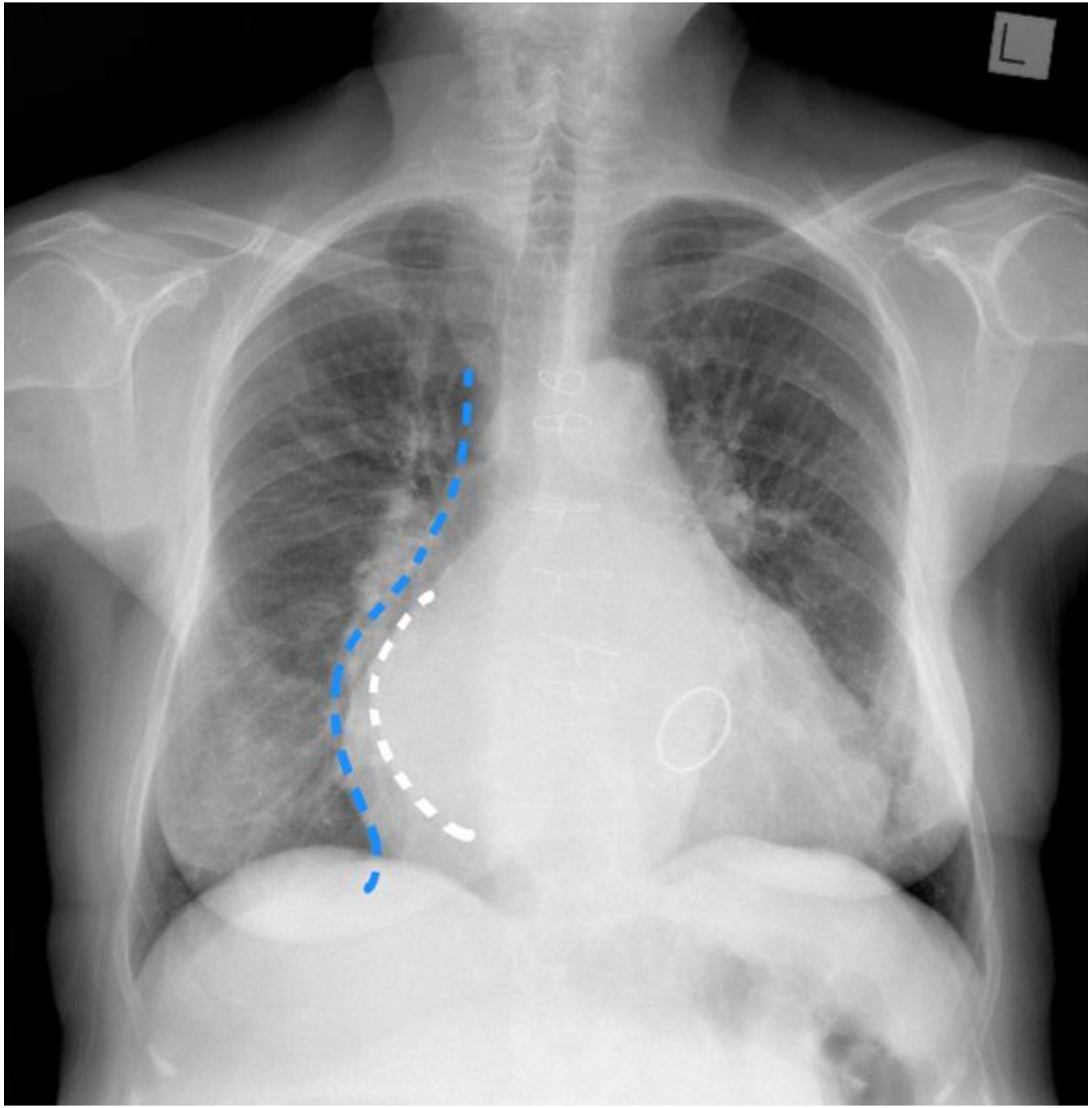

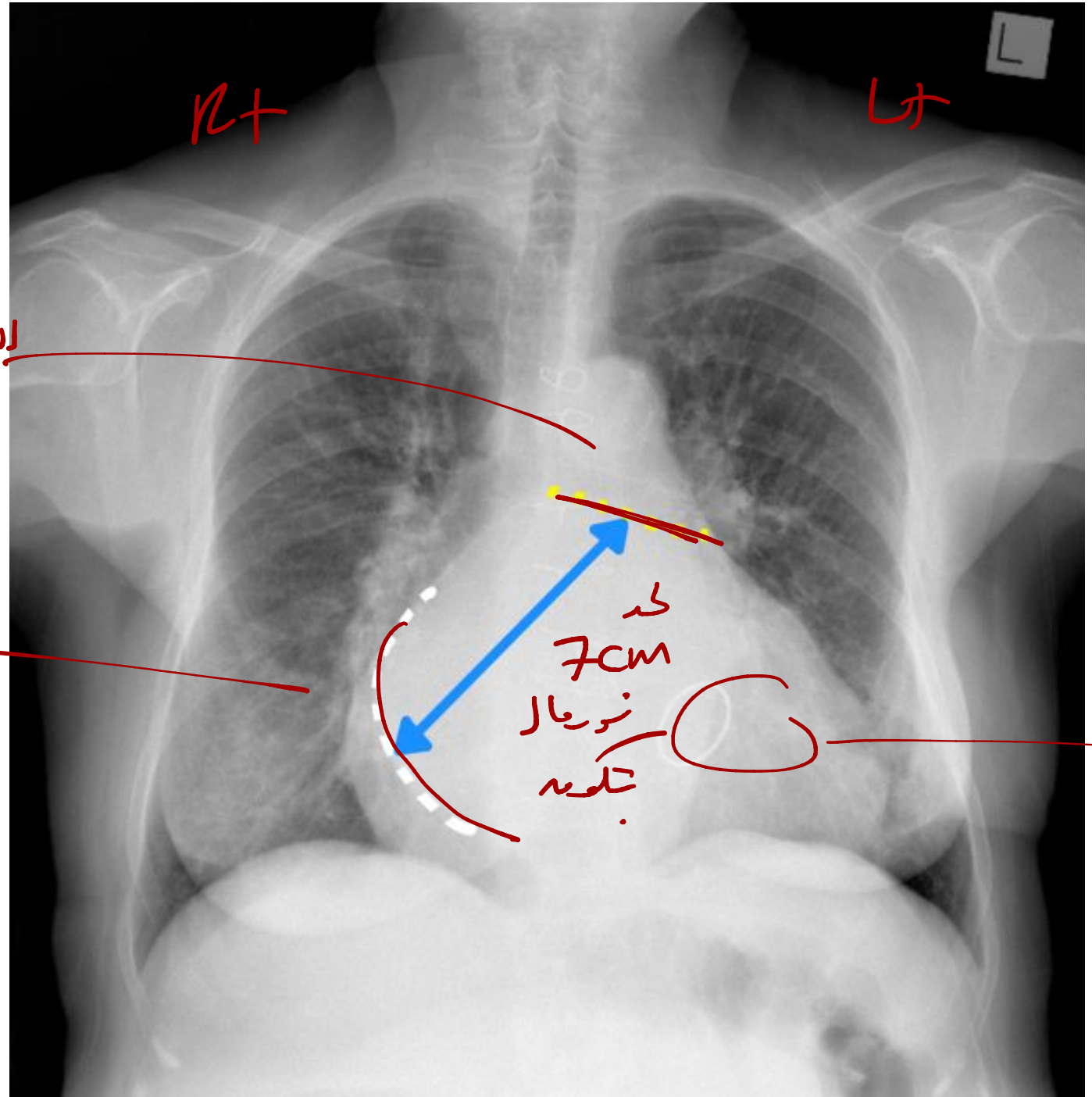
Rt
Lt
L
midpoint
Lt. main Bronchus
Rt. Border of the LA
7cm
metalic mitral valve

Carinal angle

62 - 75°

نورمال

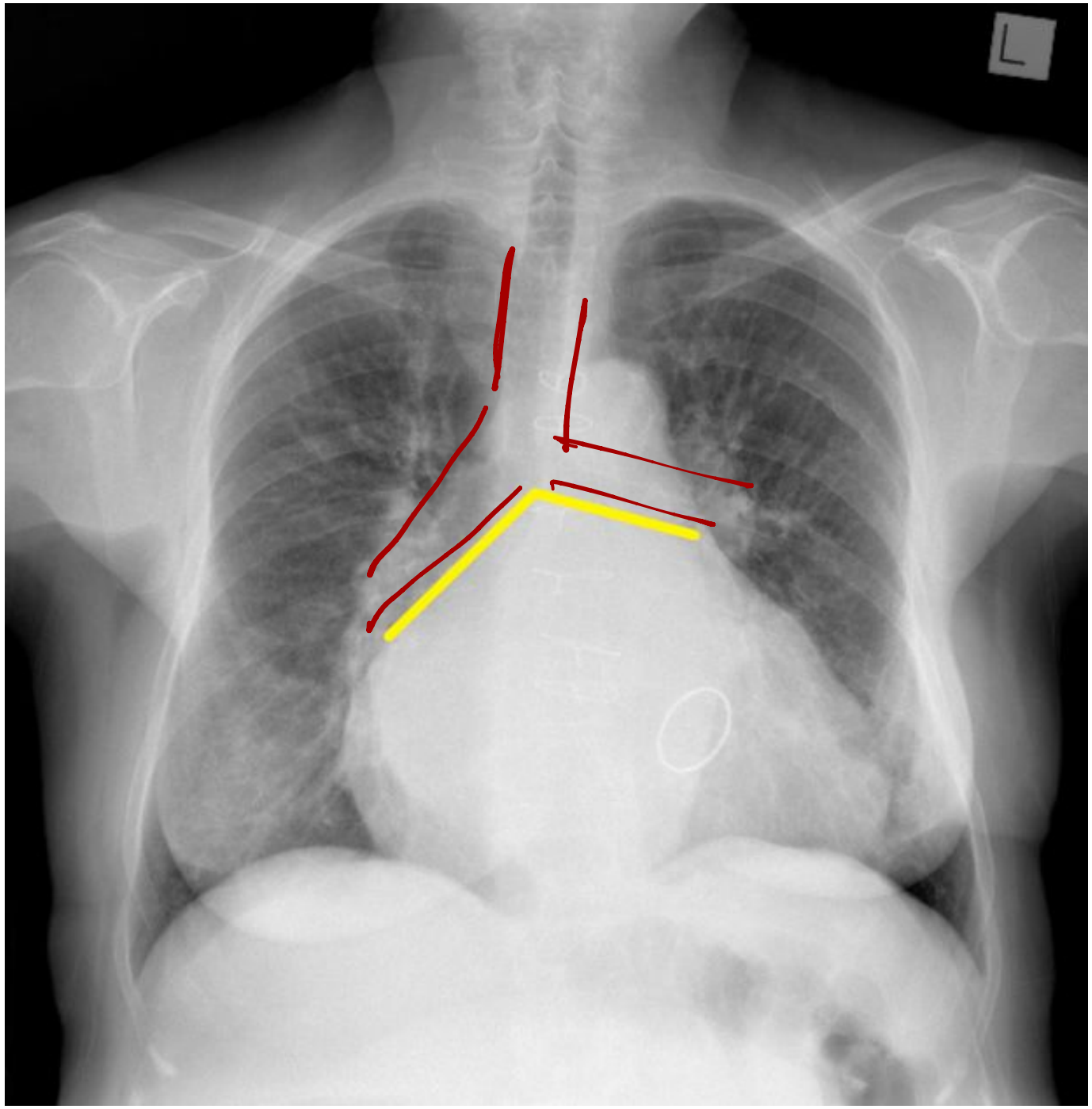

1–2 signs are enough to Dx. LA enl

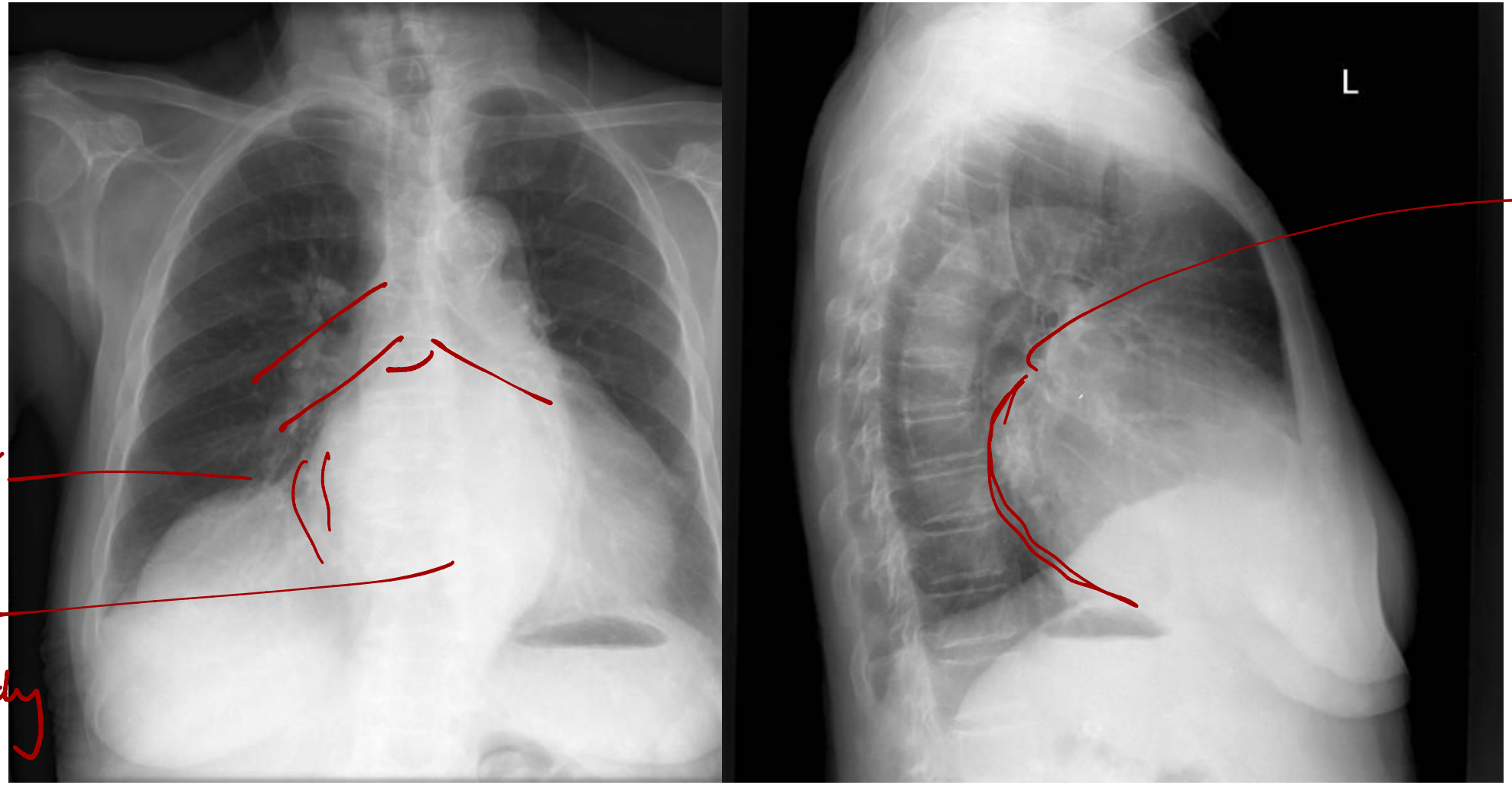

wide carinal angle

Faint double Border

diffuse cardiomegaly

Post shadow due to LA enlargement

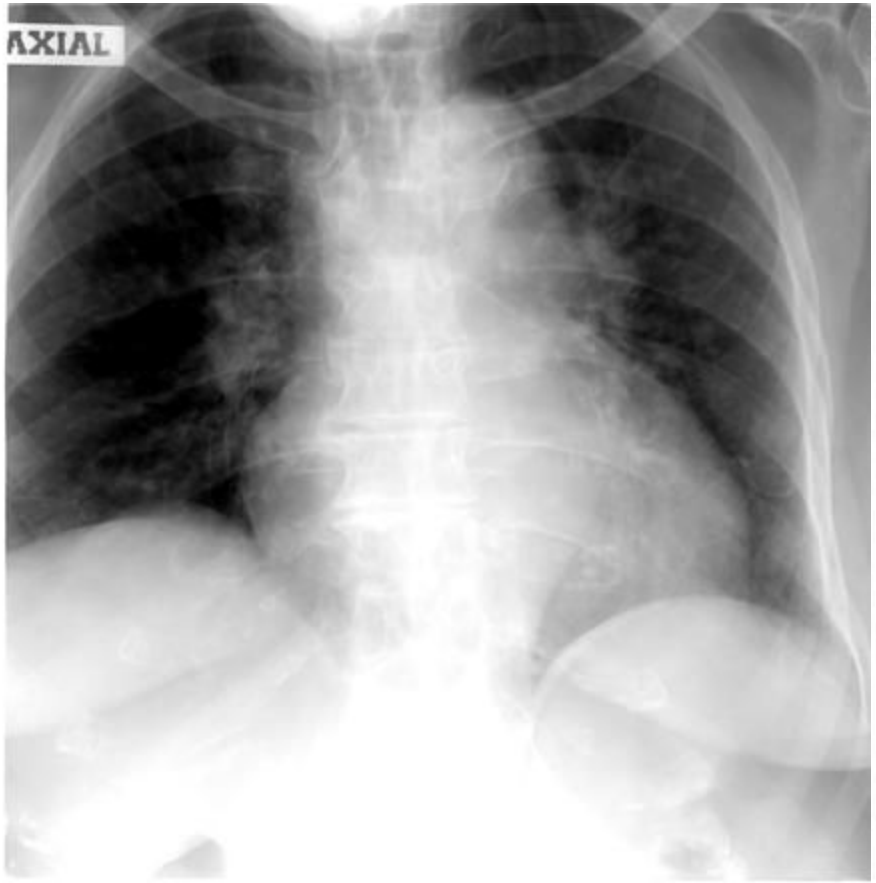

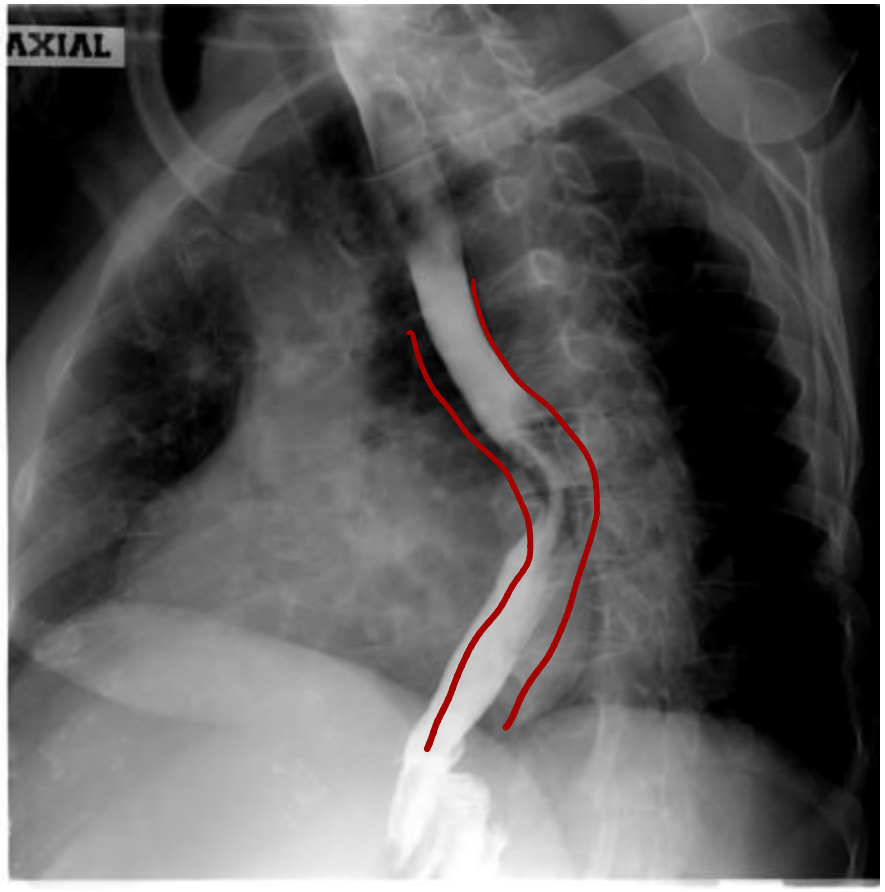

Post. shifting of erophagus
in Bravinn Study (LA enl)

LT ATRIAUM

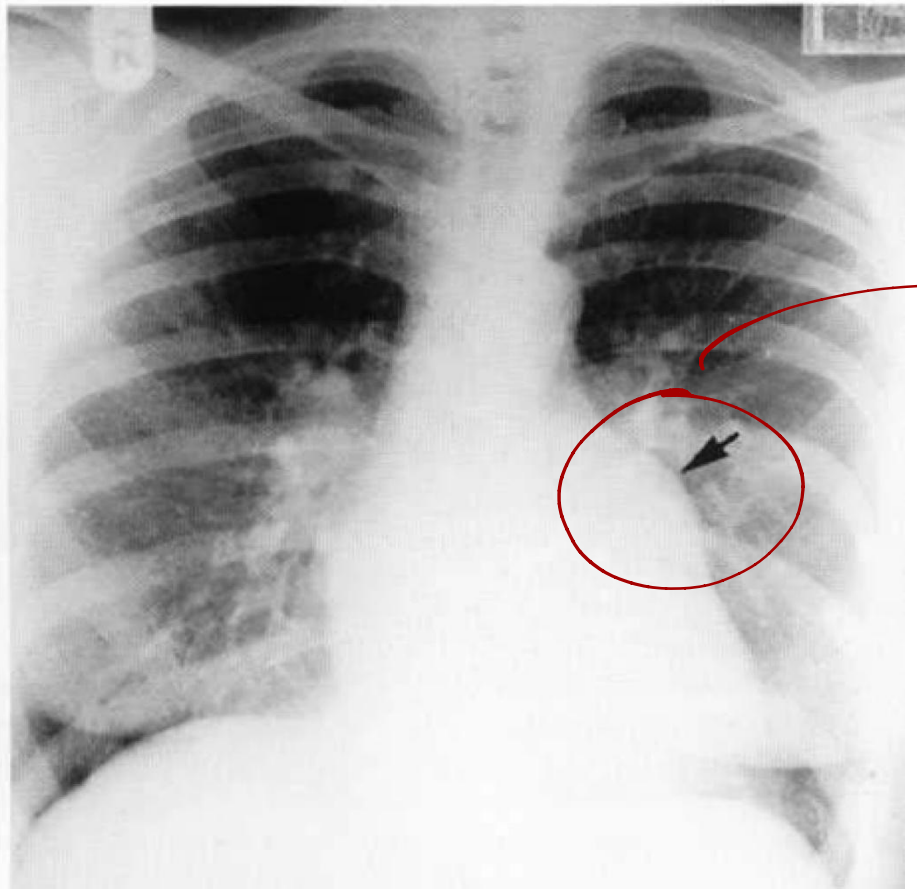

Convexity of appendage.
the Lt. Border
(LA enlarge)

- Double density sign
- Carinal angle >90.
- Oblique measurement >7cm.
- Convex LT atrial appendage.

normal 62 – 73

RA enlarg زاوية أكبر من

>90°

RT atrium

- RT heart boarder enlargement.
- Enlarged shadow of IVC & SVC .

+ Cardiomegaly

Causes



- raised right ventricular pressures
  - pulmonary arterial hypertension
  - cor pulmonale

- valvular disease
  - tricuspid regurgitation
  - tricuspid stenosis
  - Ebstein's anomaly low position of tricuspid.
- atrial septal defect (ASD)
- atrial fibrillation (AF)
- dilated cardiomyopathy

Radiographic features

- enlarged, globular heart
- narrow vascular pedicle above the heart
- gross enlargement of the right atrial shadow, i.e. increased convexity in the lower half of the right cardiac border

+ SVC & IVC congested & dilated.

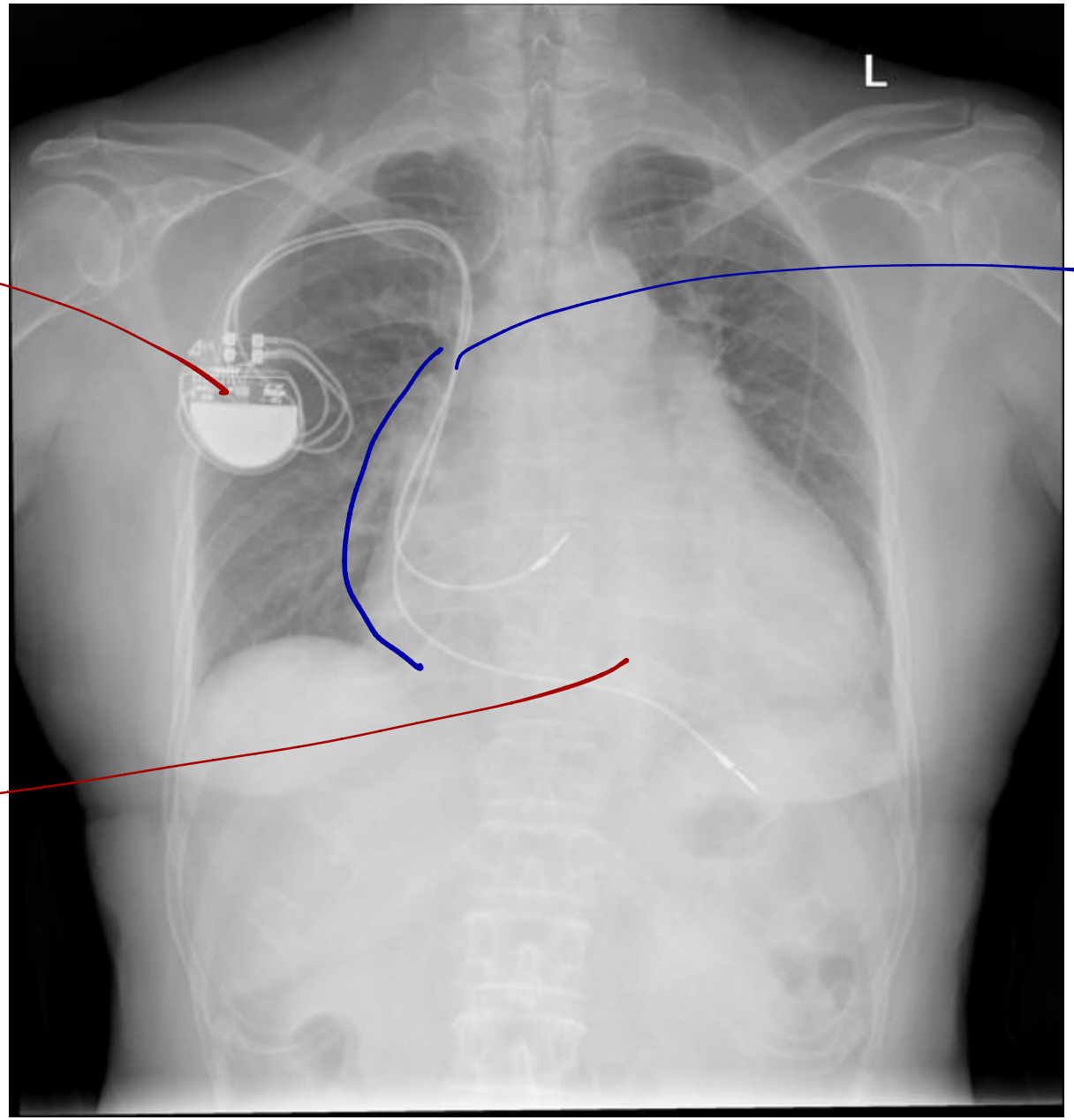

Pacemaker

Rt. Boide Convexity

(RA enlarg)

Global enlargement of the heart

global cardiomegaly

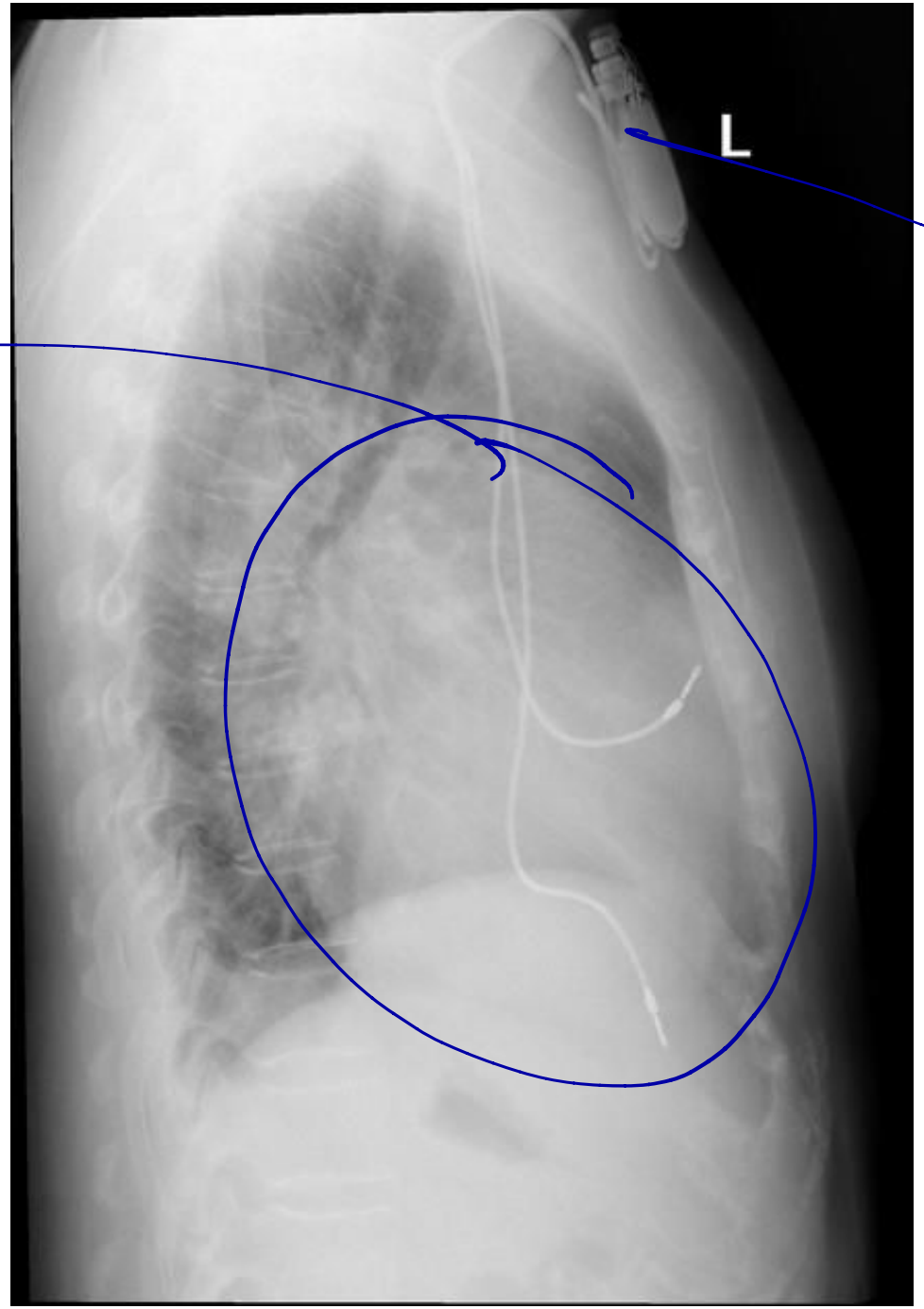

Pacemaker

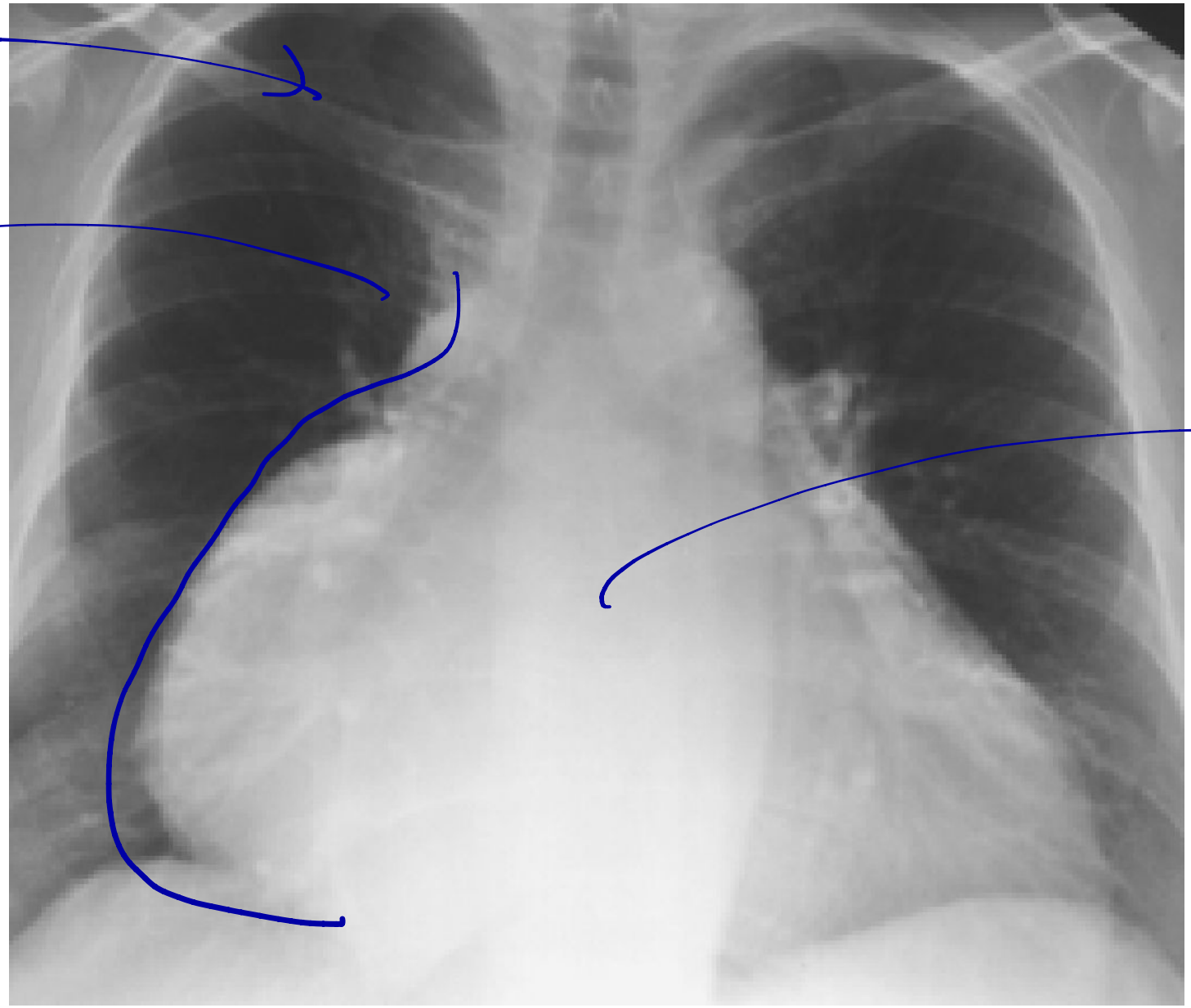

Fig. 17. Marked right atrial dilatation and right ventricular dilatation due to severe tricuspid regurgitation related to traumatic injury of the tricuspid valve

LT Ventricle Hypertrphy

elderly due to HTN

- LVH itself is not a disease, it is usually a marker for disease involving the heart.
- Disease processes that can cause LVH include any disease that increases the afterload that the heart has to contract against, and some primary diseases of the muscle of the heart.

* Global Cardiomegaly

- **Left ventricular enlargement** can be the result of a number of condition, including:

- pressure overload
  - hypertension
  - aortic stenosis
- volume overload
  - aortic regurgitation
  - mitral regurgitation
- wall abnormalities
  - left ventricular aneurysm (Common) post infarction.
  - hypertrophic cardiomyopathy



LV Enlarged

- Bulge in the LT heart boarder, down ward and lateral displacement of the cardiac apex.
- Rounded apex.
- Posterior displacement of heart in lateral x ray.
- Late signs:
  - LT atrial enlargement
  - Pulmonary congestion.
  - Prominent aortic arch.

~ retrocardiac space ~

Posterior Border is

LA

LV

= unfolded aorta

+ venous congestion.



LT VENTRICLE

retrocardiac space

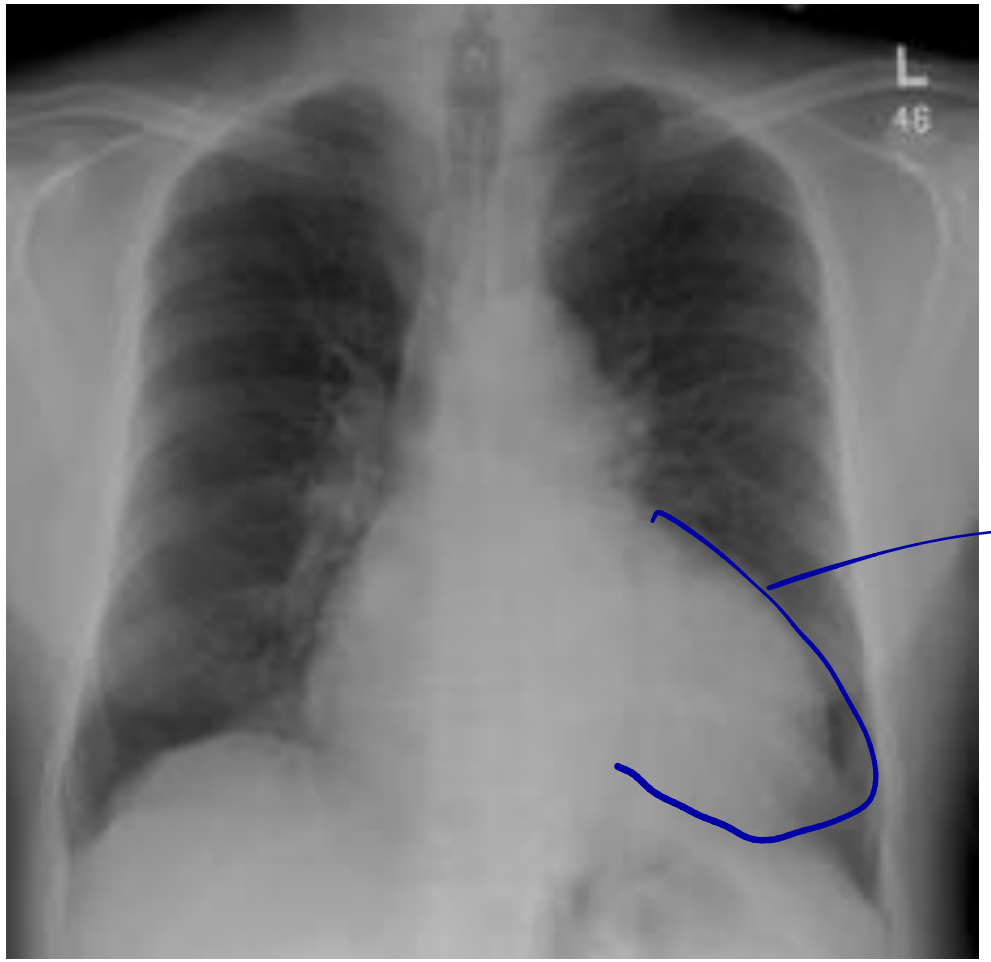

LV enlargement

+ Cardiomegaly

Convexity (Lt)
+ downward lateral apex.
+ rounded apex

Left ventricular aneurysm

Hover over image to show findings

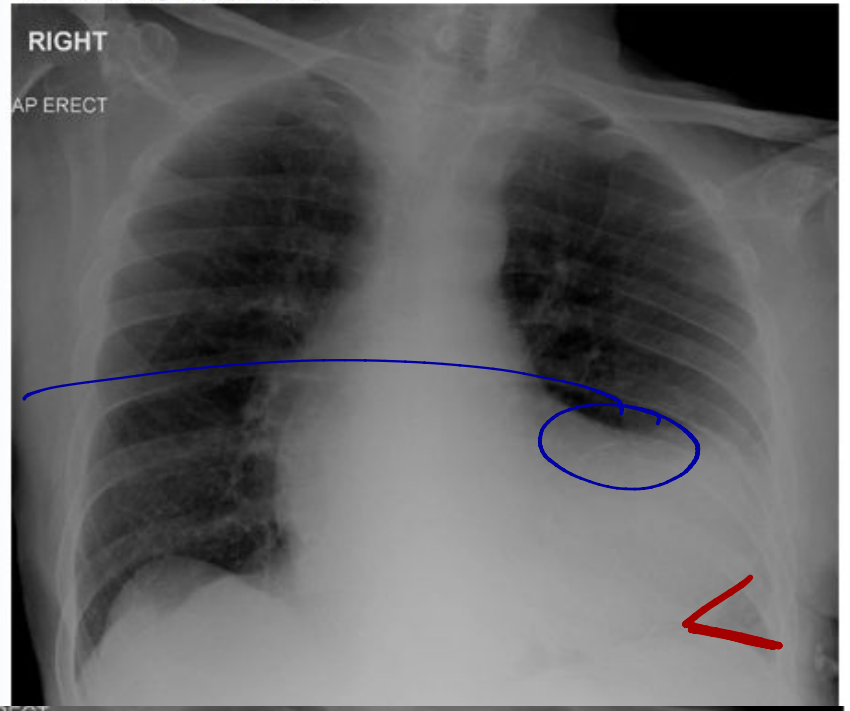

Left ventricular aneurysm

- AP erect chest x-ray
- Heart clearly enlarged despite the AP view
- Bulging left heart border
- Circular rim of calcification (arrowheads)

Clinical information

- Previous myocardial infarction

Diagnosis

- Left ventricular aneurysm - an uncommon complication of myocardial infarction

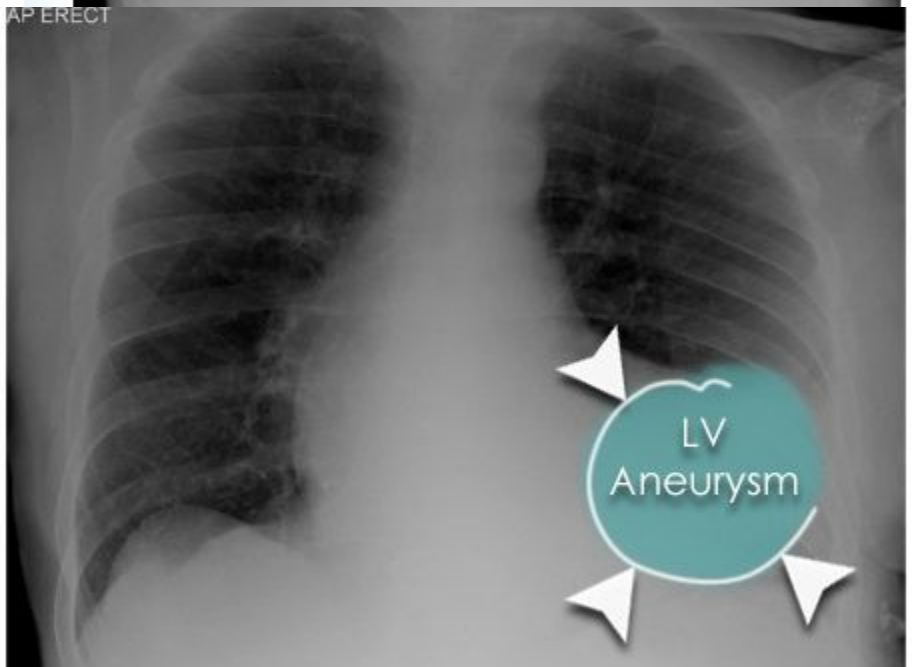

- Heart clearly enlarged despite the AP view
- Bulging left heart border
- Circular rim of calcification (arrowheads)

Clinical information

- Previous myocardial infarction

Diagnosis

- Left ventricular aneurysm - an uncommon complication of myocardial infarction

في عندي نقط
Calcification
نتيجة ال
LV aneurysm
2ry to MI
غالباً.

ليش فكرت
في
LV aneurysm
لأنه لل
apex
لنوقد
مش
LV hypertrophy

RT Ventricle Enlargement.

- AP view:
  - Up ward elevation of cardiac apex.
  - Transverse position of the heart.

- Lateral view demonstrates:
  - filling of the retrosternal space
  - rotation of the heart posteriorly

RV rest on diaphragm

enlargeul → Apex elevated

LVH

RVH



Right ventricular enlargement can be the result of a number of conditions, including :

- pulmonary valve stenosis
- pulmonary artery hypertension
- atrial septal defect
- tricuspid regurgitation (late stage)
- dilated cardiomyopathy
- ASD
- VSD
- anomalous pulmonary venous drainage
- High altitude
- Cardiac fibrosis
- Chronic obstructive pulmonary disease (COPD)
- Athletic heart syndrome



RV enlargement

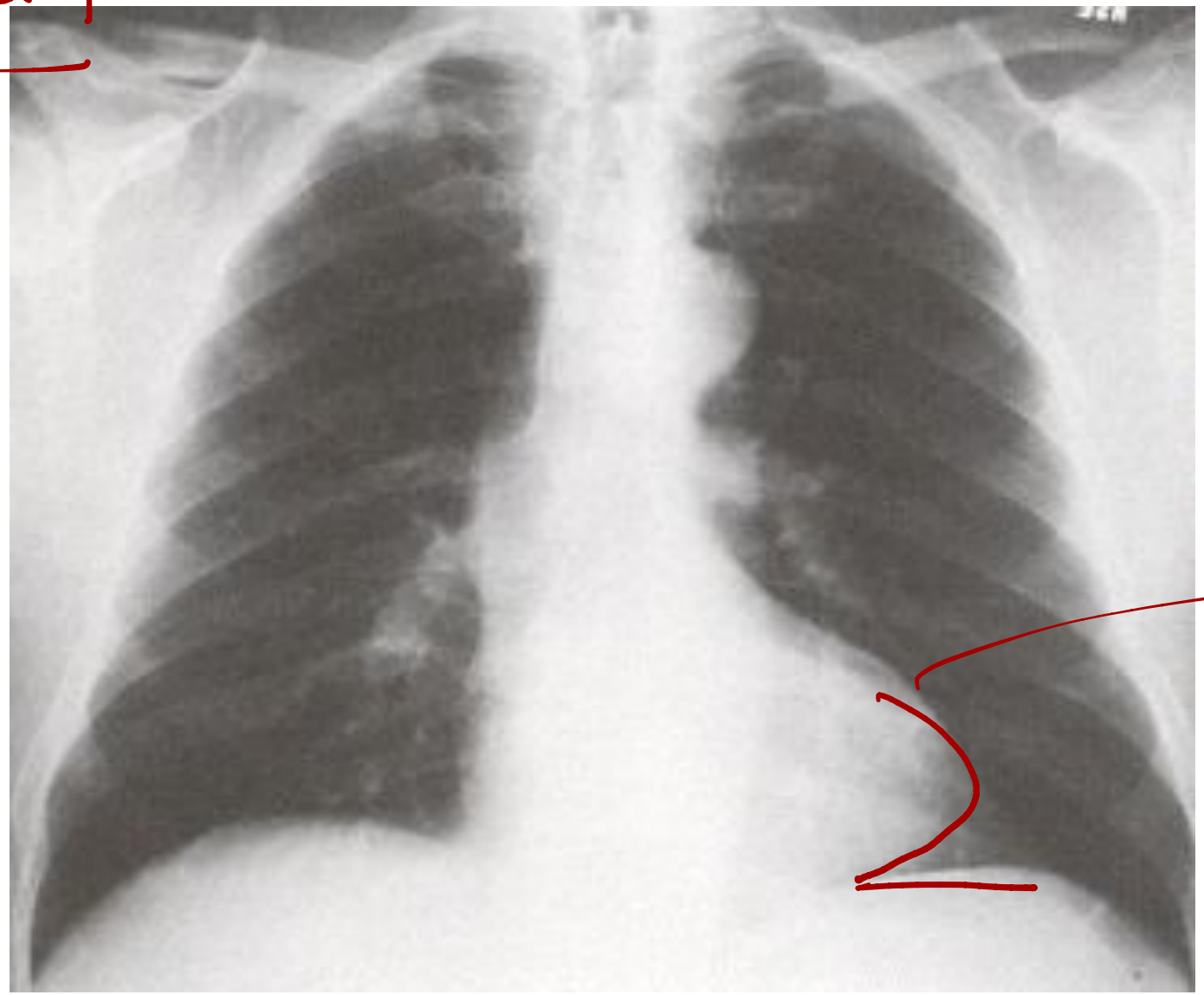

elevated apex

RT VENTRICLE (PS)

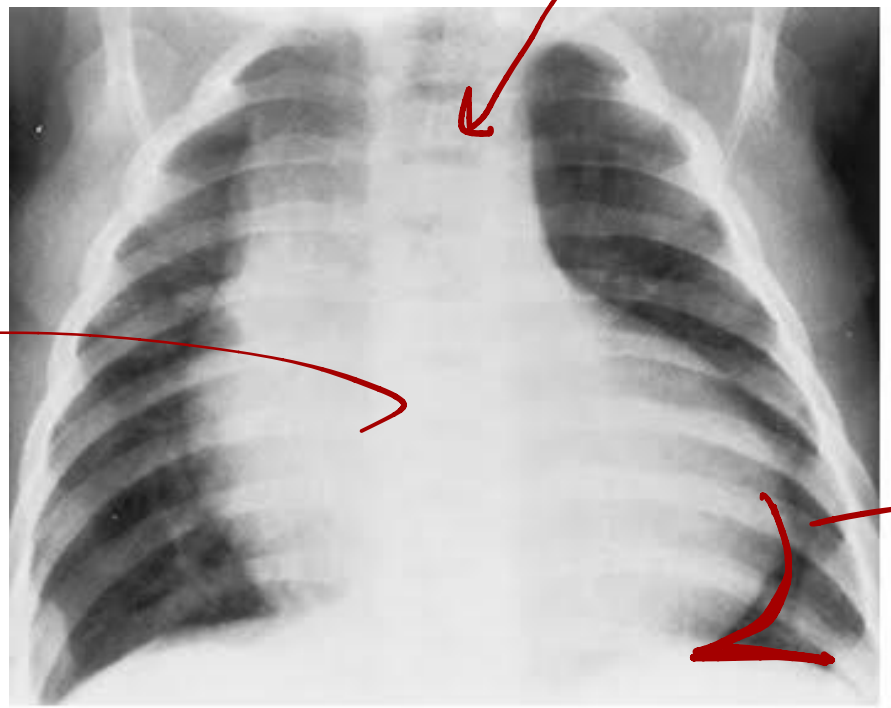

RVH

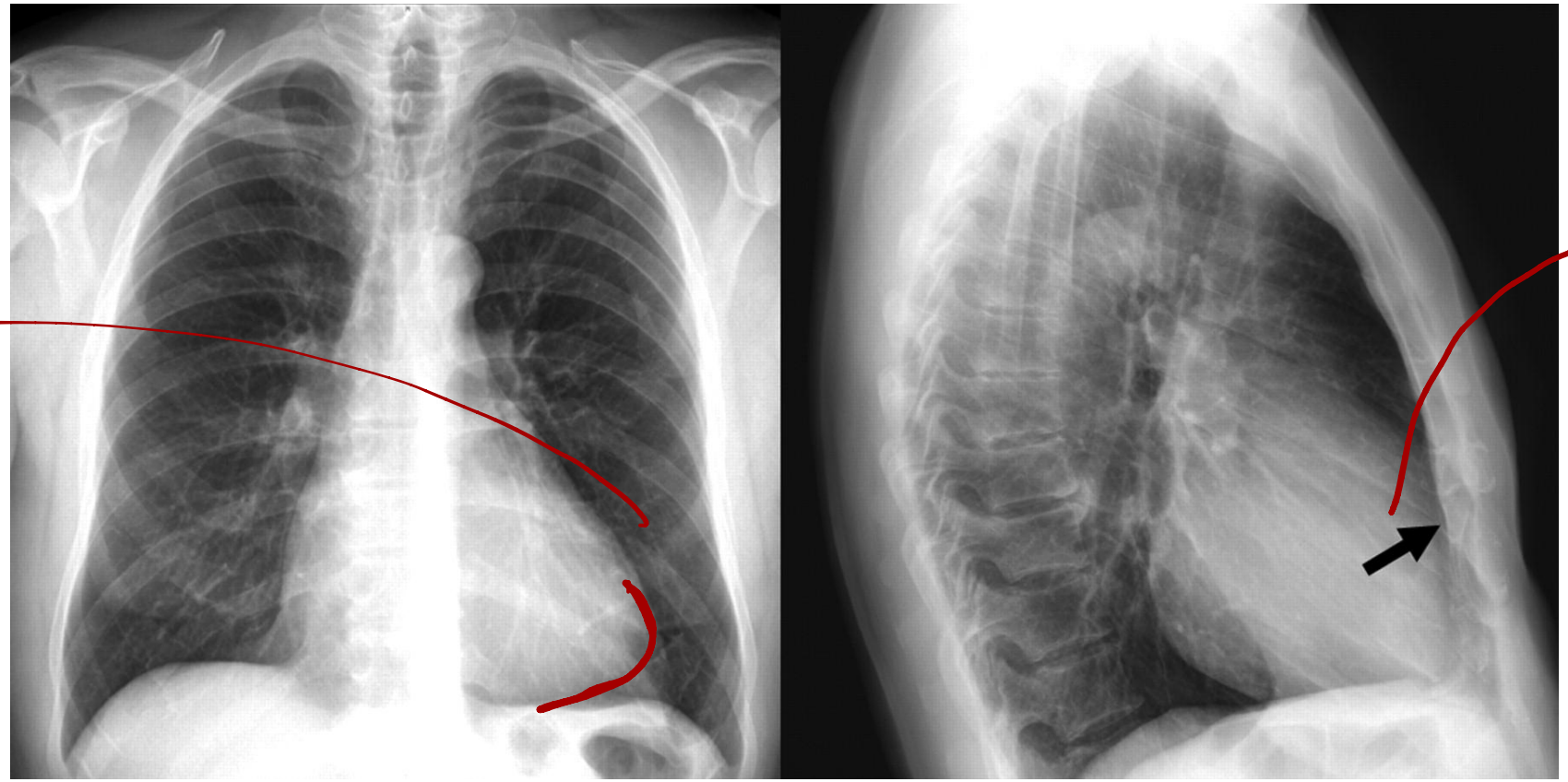

Rt. Pulmonary Ar Congested

Pulmonary trunk enlarged

& Lt. pulmonary artery enlarg.

تمدد القلب من

transvere

RVH

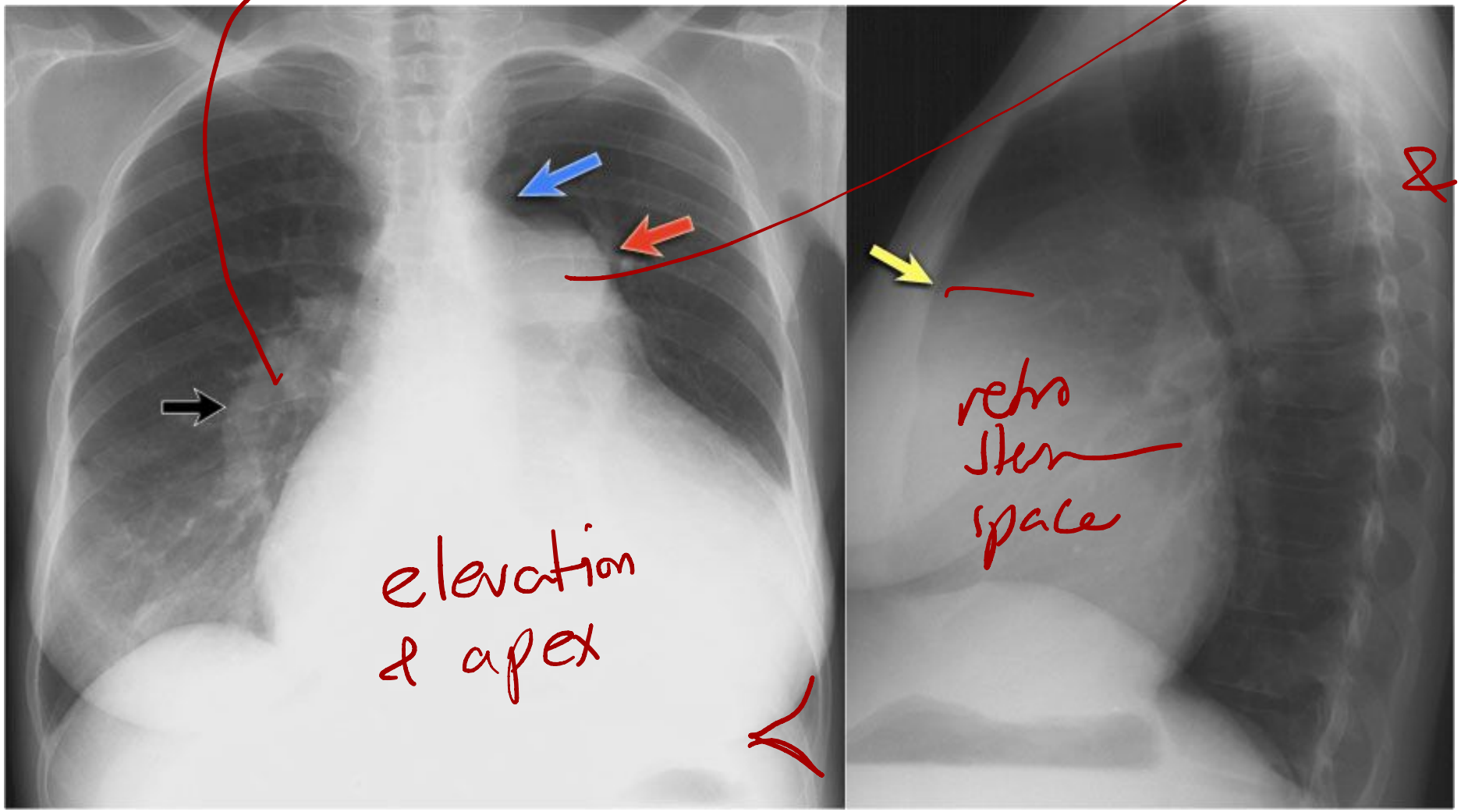

RT

RVH

Congestion & pulmary vessels.

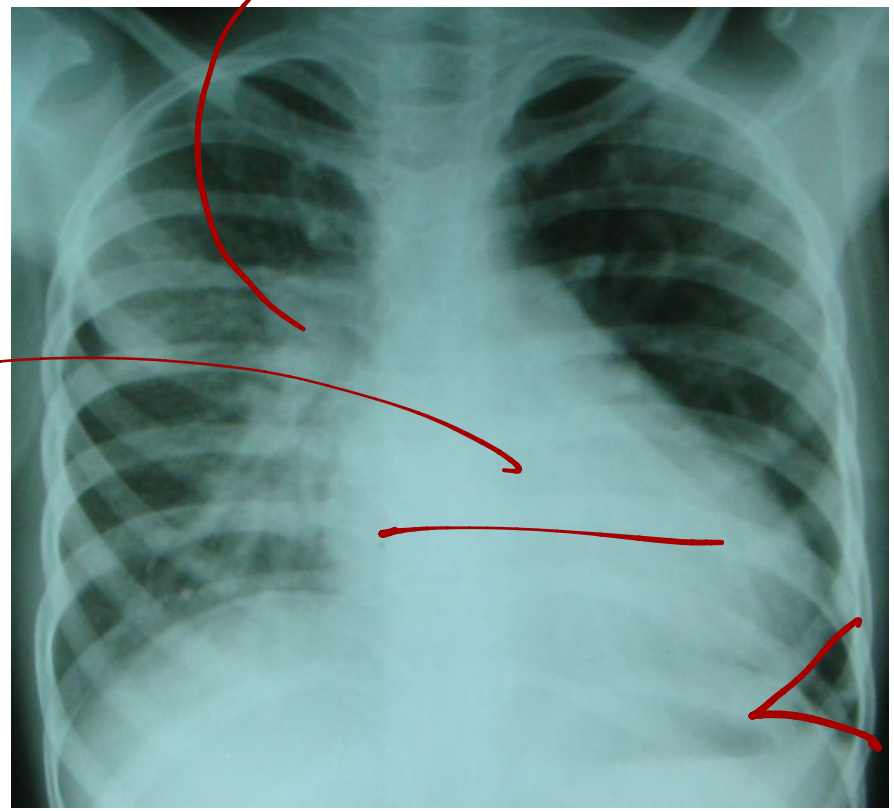

Transverse Cardiomegaly

elevated apex

Congenital abnormality , primary RT ventricle enlargement

RV enlargement

Fallot

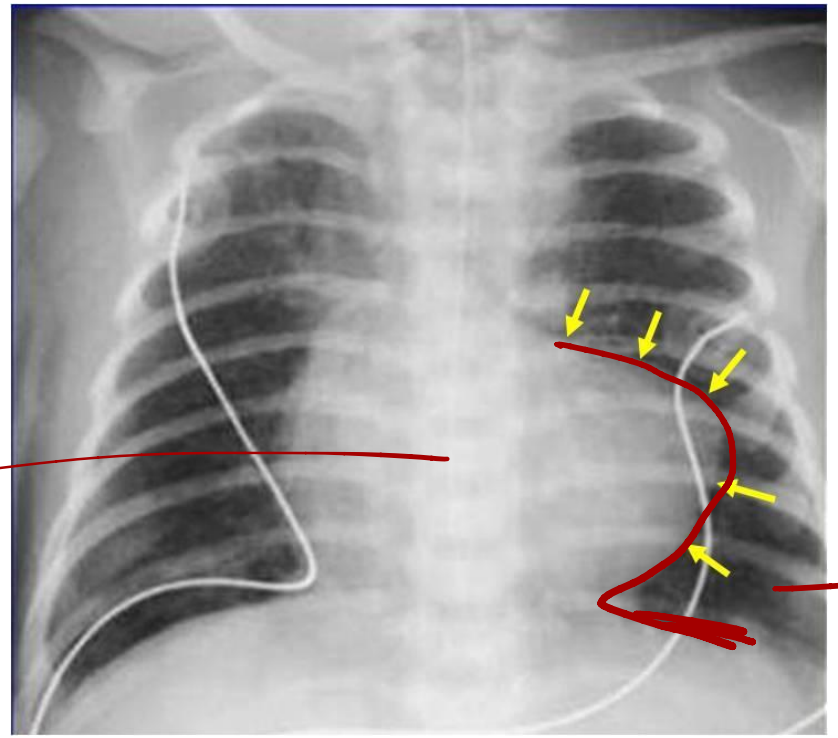

Cardiomegaly

elevation

Fallot-

Boot shape

