DEGENRATIVE BONE DISEASE

D. MOHAMAD MATAR

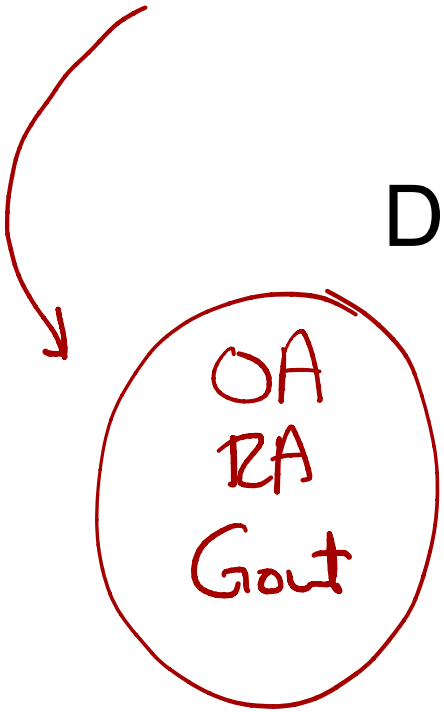

osteoarthitis

- Most commonly affecting knee.
- Narrowed joint space.
- Sub chondral sclerosis.
- Marginal osteophytes.
- Gleode/subchondral pseudo cyst formation.
- Spiking of tibial spin.

* OA

Female > 50 y. hormones

in males due to trauma

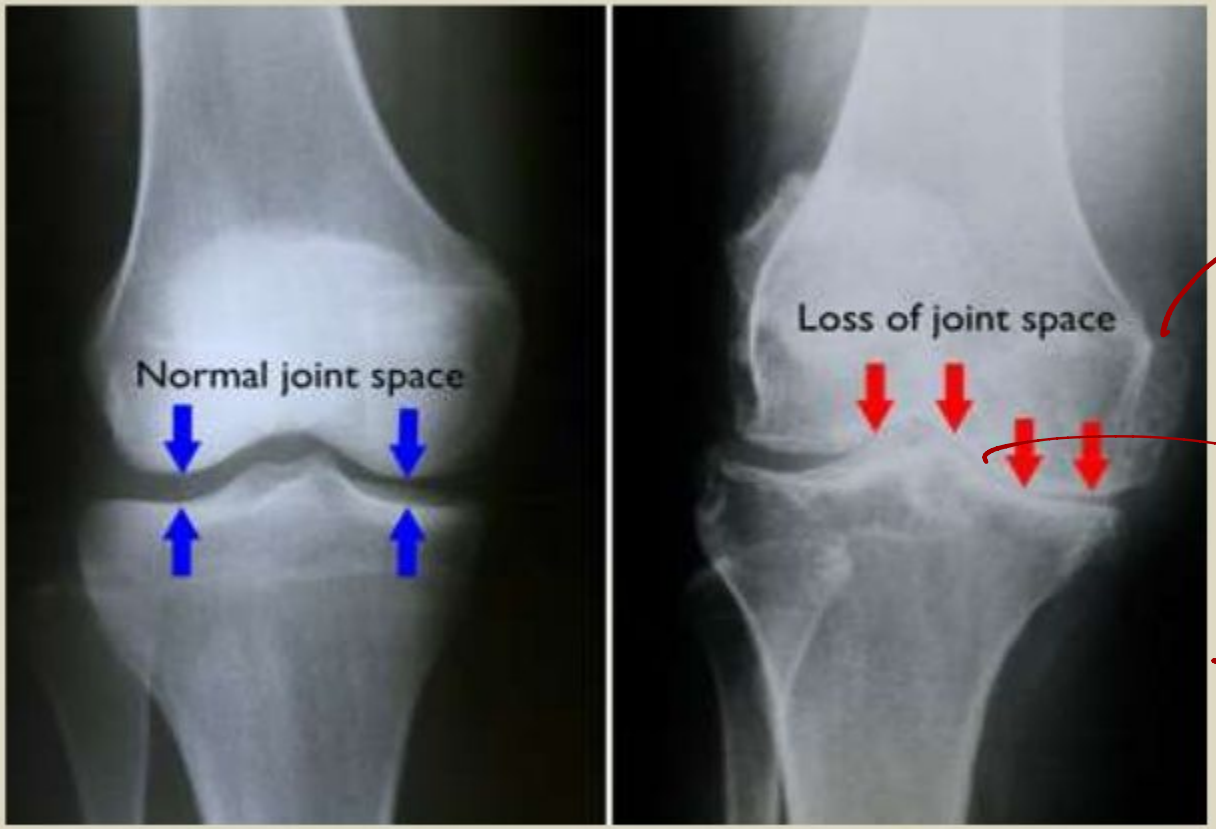

Sclerotic end plate

Osteophytes

* narrow joint space

* Subchondral sclerosis

(Left) In this x-ray of a normal knee, the space between the bones indicates healthy cartilage (arrows). (Right) This x-ray of an arthritic knee shows severe loss of joint space.

OA

↓

erosion of cartilage

↓

negative Xray

(Clinical)

↓

ve ve

+ve Xray.

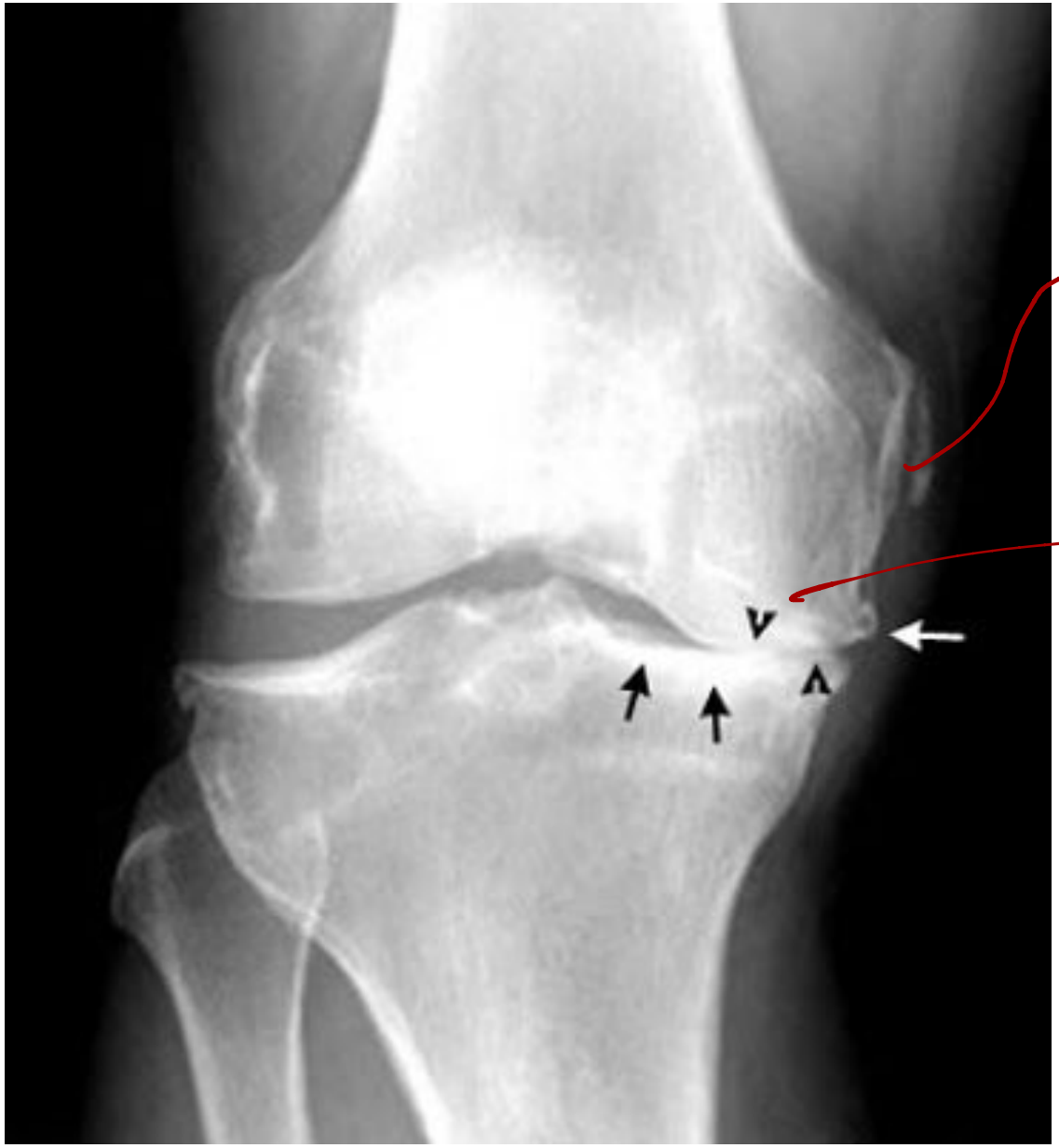

Subchondral sclerosis

Joint space narrow

medial

+ marginal osteophyte

new Bone formation



→ Valgus deformity

Kellgren-Lawrence (KL) grading scale

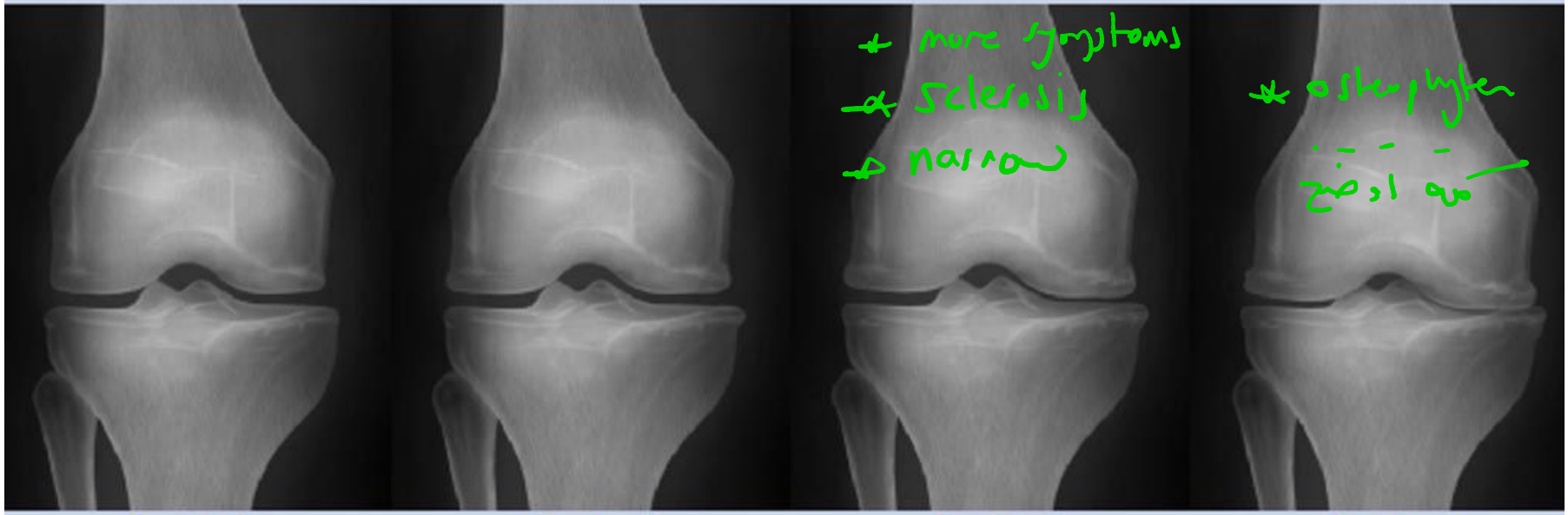

Grade 1 | Grade 2 | Grade 3 | Grade 4

CLASSIFICATION	Normal	Doubtful	Mild	Moderate	Severe
DESCRIPTION	No features of OA	Minute osteophyte: doubtful significance	Definite osteophyte: normal joint space	Moderate joint space reduction	Joint space greatly reduced: subchondral sclerosis

OA in the hip

narrow space

Cyst

osteophytes

sclerosis

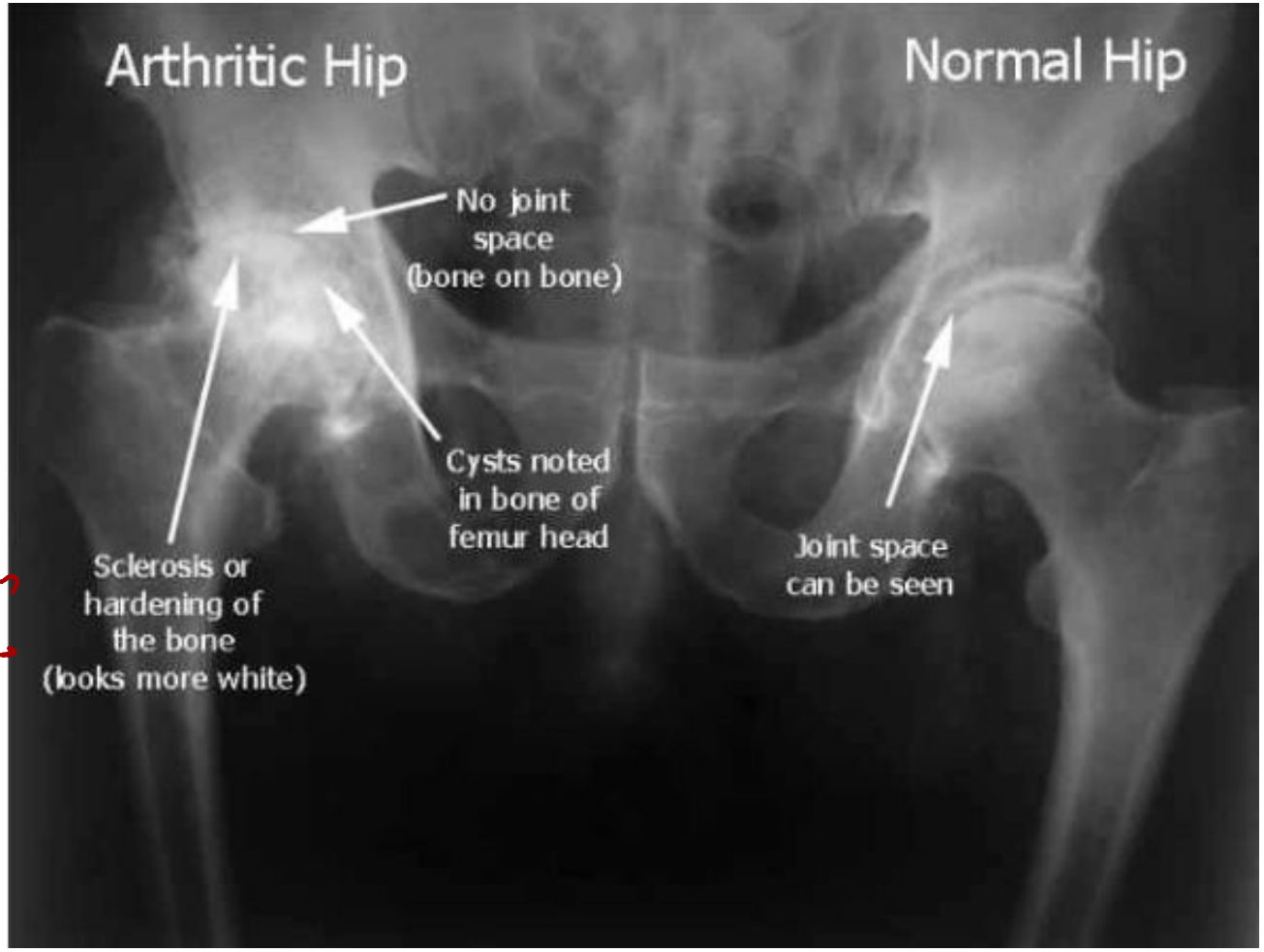

Bilateral OA more on RF



Normal



ligamel
of Fova
طبيعي هيك
ريربالك

In hand it affect more the distal .joints

RA

narrow sclerosis



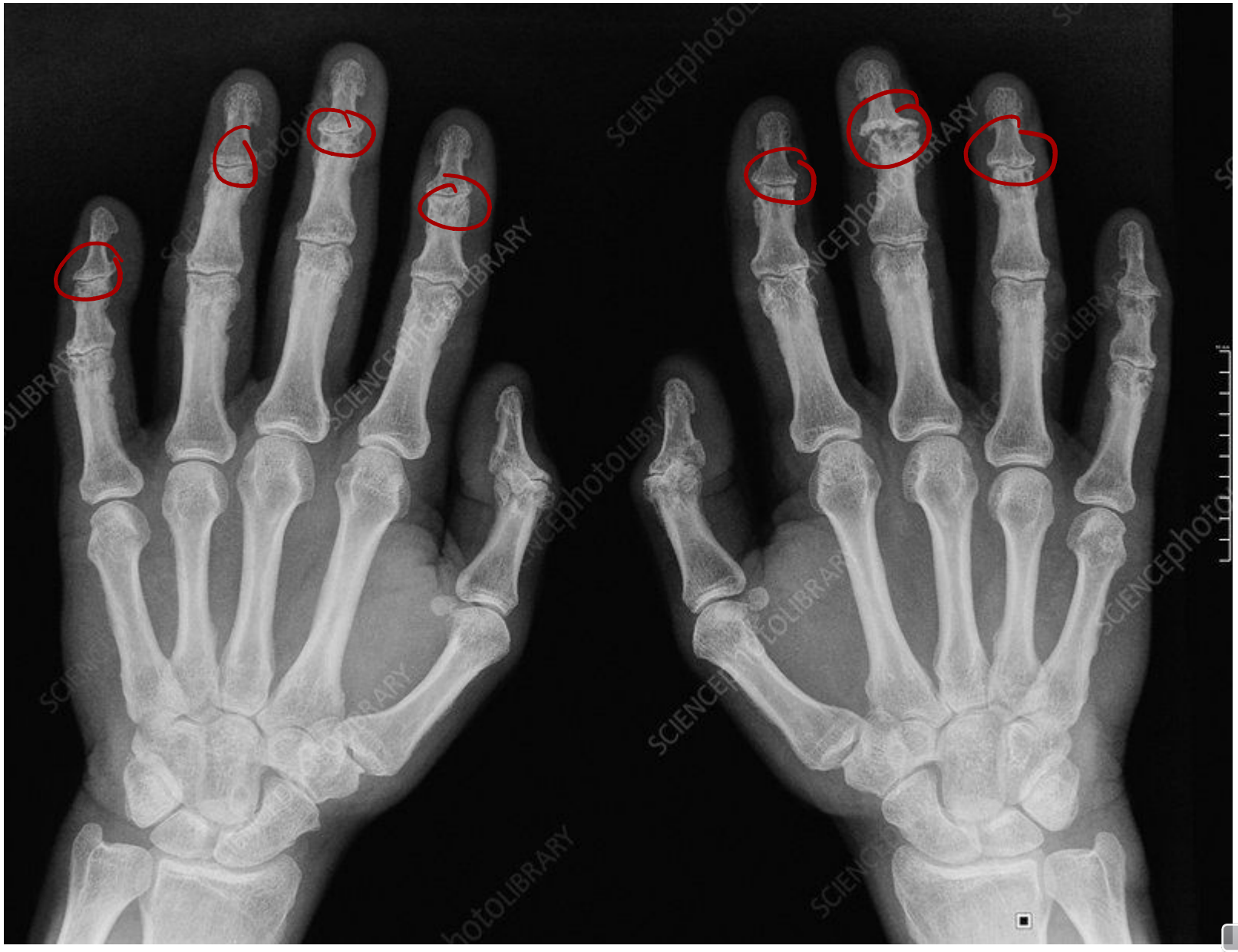



.Rheumatoid arthritis

- More affecting carpal , metacarpal and proximal joints.
- Erosion of cortical margins , articular.
- Osteopenia.
- Flexion, extension contractures.
- Deformity , dislocation, sublaxation is common in late disease.
- soft tissue swelling and loss of joint space
- No osteophytes.



Figure 1

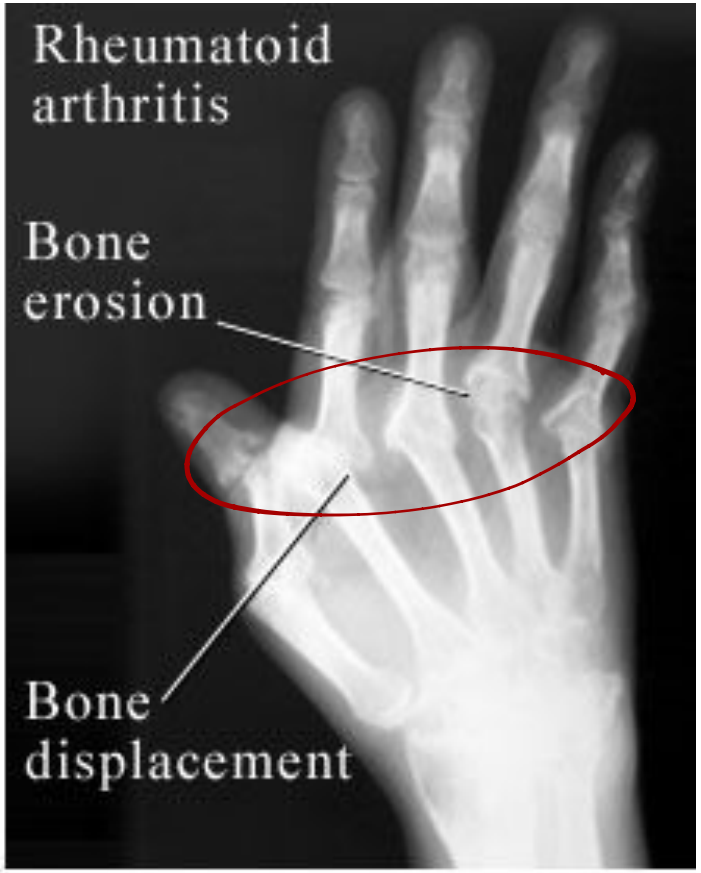

Figure 2



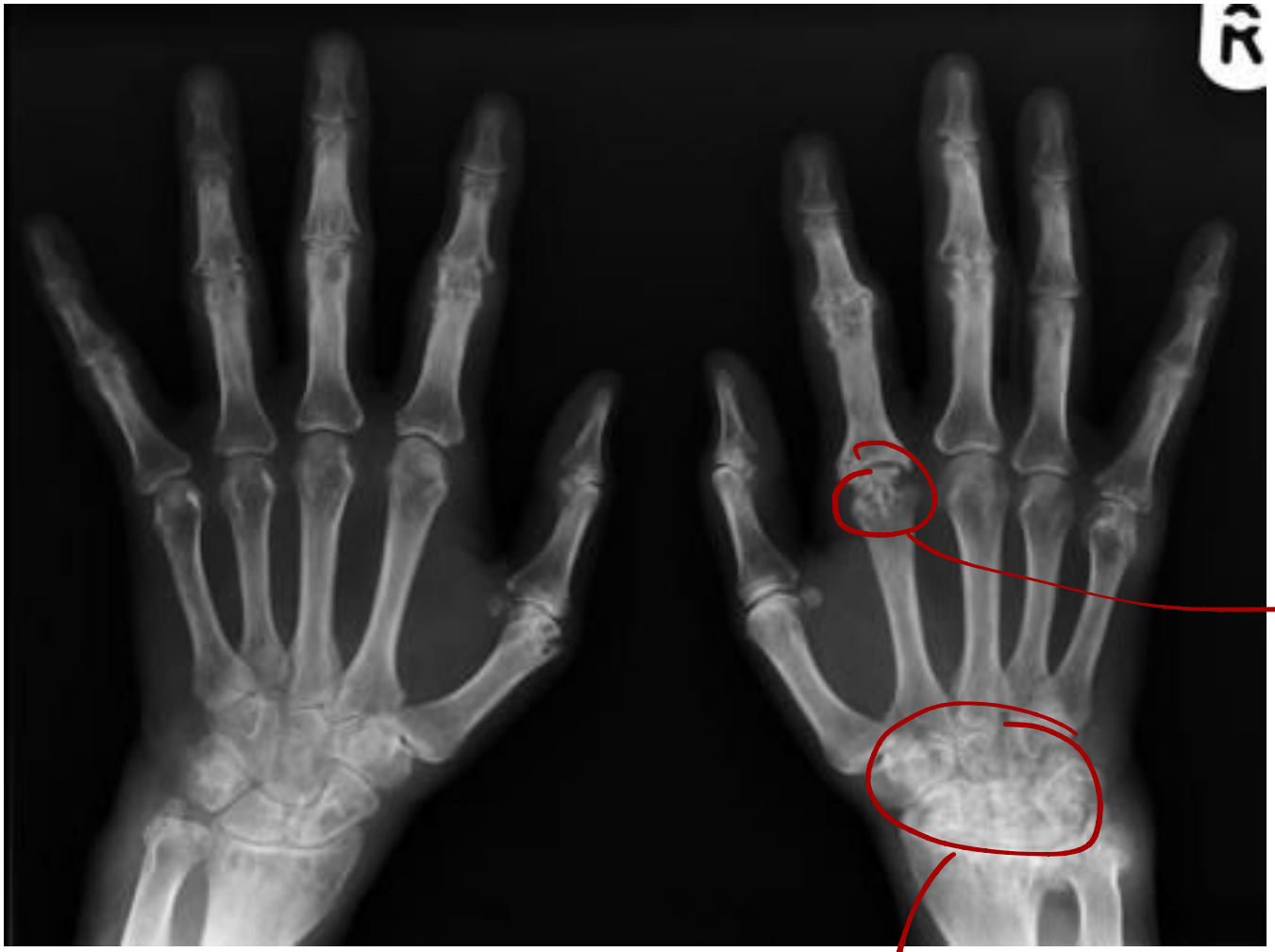
R
lytic lesion
destruction erosion


Normal
Rheumatoid Arthritis


SCIENCEPHOTOLIBRARY


Distribution OA vs RA: Hands
OA
DIPs
PIPs
Thumb base
✓ CMC
✓ STT
Spares
MCPs
Rest of the wrist
Hand PA view
Hand PA view
RA
MCPs
Entire wrist
✓ DRUJ
Spares
DIPs
PIPs

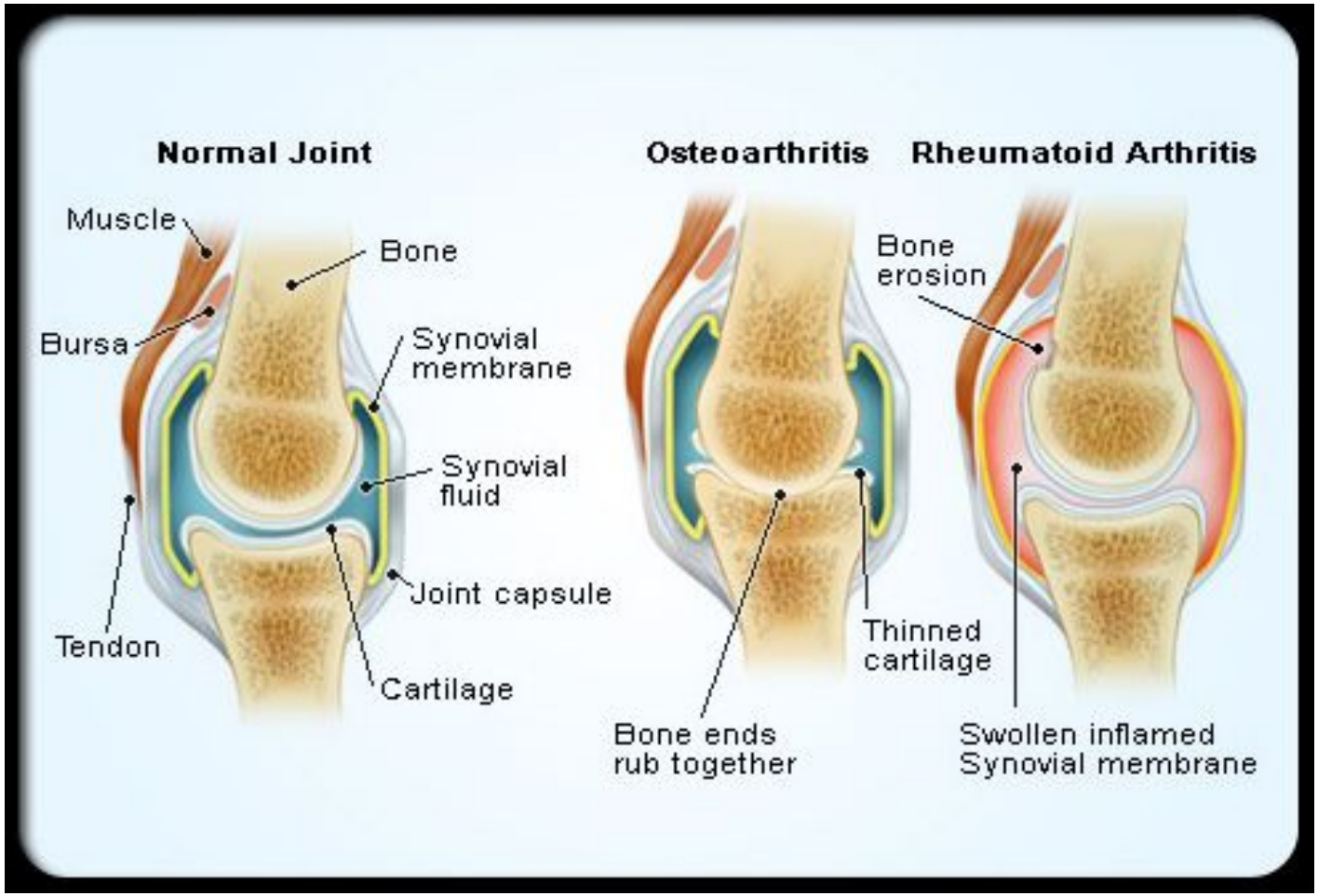
Normal Joint
Muscle
Bone
Bursa
Synovial membrane
Synovial fluid
Joint capsule
Tendon
Cartilage
Osteoarthritis
Bone ends rub together
Rheumatoid Arthritis
Bone erosion
Thinned cartilage
Swollen inflamed Synovial membrane

Gout

- Soft tissue findings
  - Calcific deposits in gouty tophi in 50% (only calcium urate crystals are opaque)
  - Eccentric juxta-articular lobulated soft-tissue masses
  - Bilateral olecranon bursitis
  - Aural calcification
- Joint findings
  - Preservation of joint space initially
  - Erosion of joint margins with sclerosis
  - Cartilage destruction late in course of disease



Gout

- Bone findings
  - "Punched-out" lytic bone lesion ± sclerosis of margin
  - "Mouse / rat bite" from erosion of long-standing soft-tissue tophus
  - "Overhanging margin" (40%)
  - Ischemic necrosis of femoral / humeral heads
  - Bone infarction

عند الجنب

Complica

Soft tissue density

Delay

Punch out

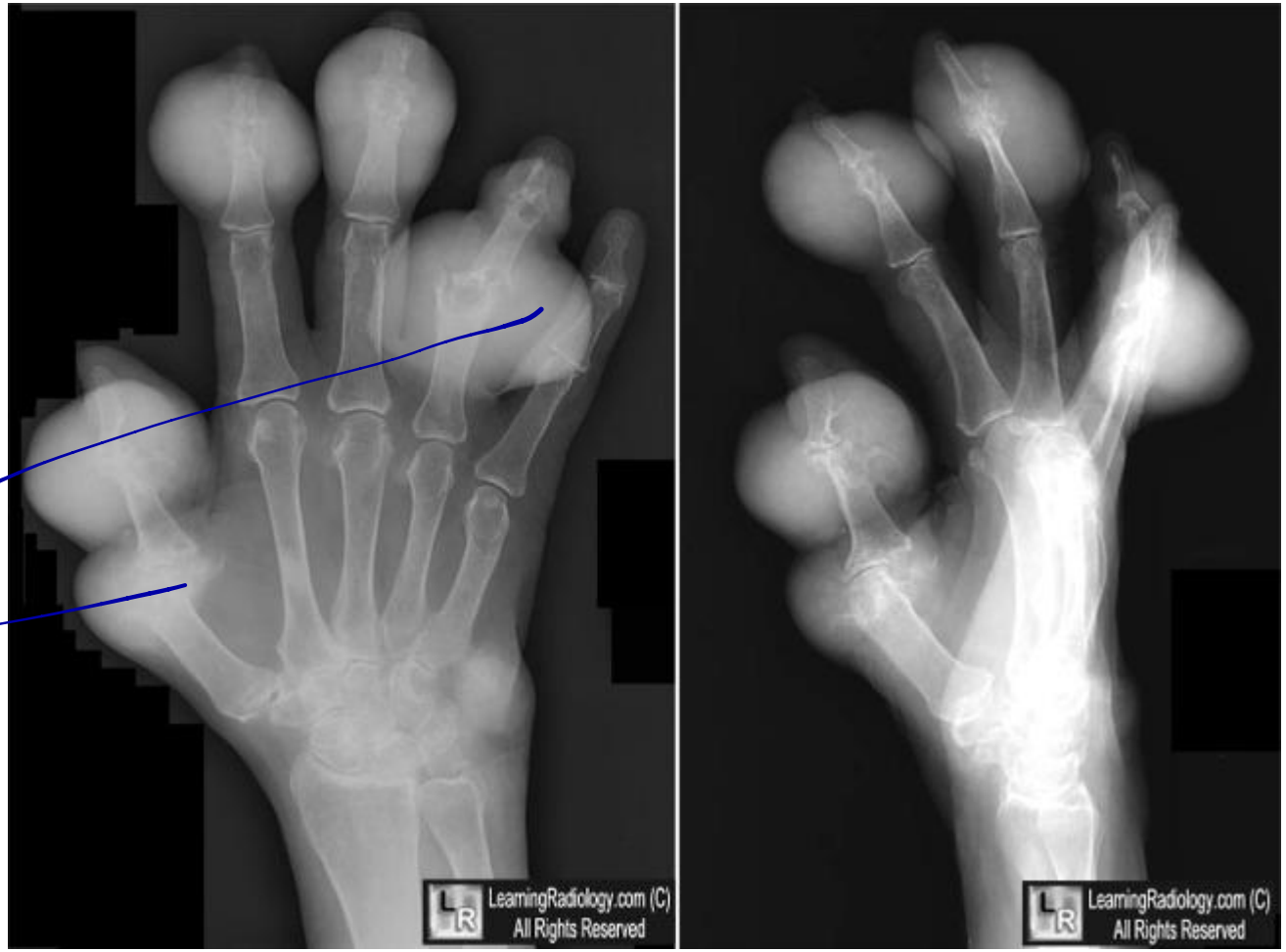



Punch out lesion
+ over hanging margins
+ sclerosis

Big toe



Figure 1



Figure 2

Punch out
(Textbook)

Mouse Bite (punch out

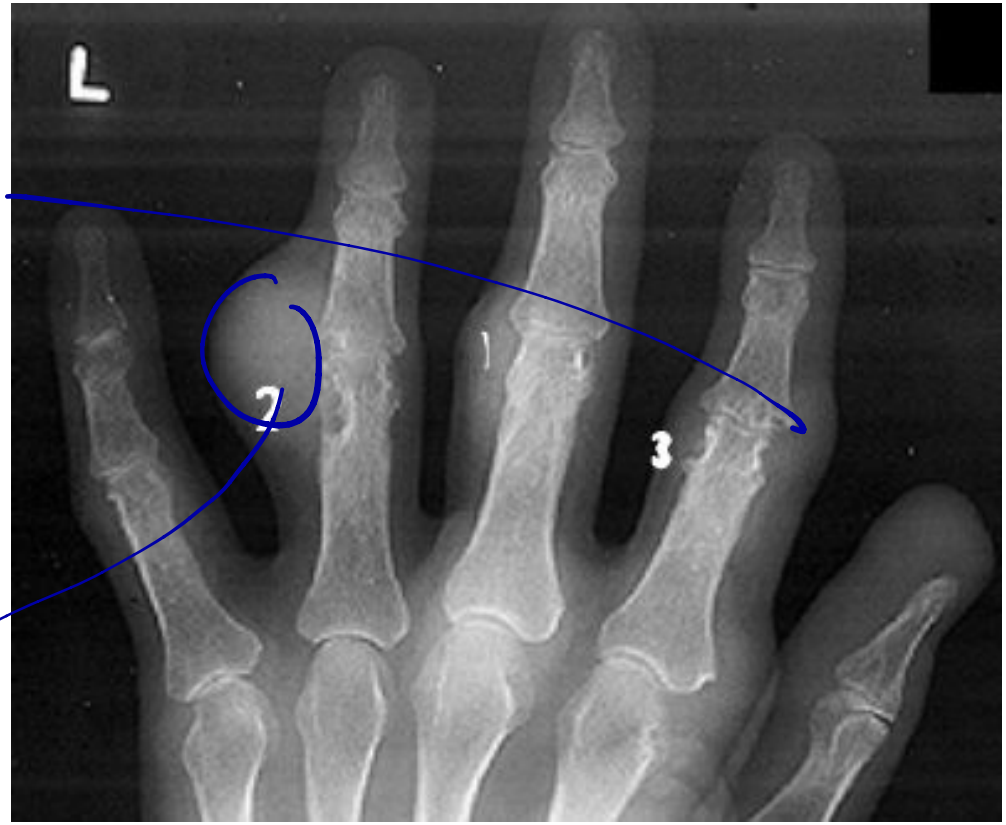

soft tissue

THAN YOU FOR LISENING

