MRI Brain

↳ In acute condition.

* Emergent cases that show by MRI, not CT :-

* if CT is normal in the presence of clinical findings. [like CVA, stroke].
  ↳ if the patient symptoms are CVA symptoms [I determine that]. ↓
  start mangement with streptokinase or Anti-tPA
  but if not CVA → Don't treat with Antithrombotic agents.
  → In CVA, patient will never get completely resolved, and if s/he is completely resolved
  ↳ It's not CVA, it's (TIA).
  [Transient Ischemic attack]

** Encephalitis. [not apear in CT]. ↳ even if it; viral, or bacterial. Autoimmune ↳ like Behcet D. or SLE....)

*Notes:-

* (-) CT does not exculde Diagnosis.
* Tumors can be seen in CT.
  [so, in any space occuping leosion → Ask for CT.

MRI Sequences

- *:T1 and T2 weighted sequences*
- *On T1: white matter appears white & grey matter appears grey & CSF is black*
- *On T2: It is the opposite. CSF is hyperintense, thalamus is darker than the corpus striatum (putamen & caudate) which are darker than cortical grey*

*Brain → White m. → inside.
→ Gray m. → outs.

Examples of T1 and T2 images

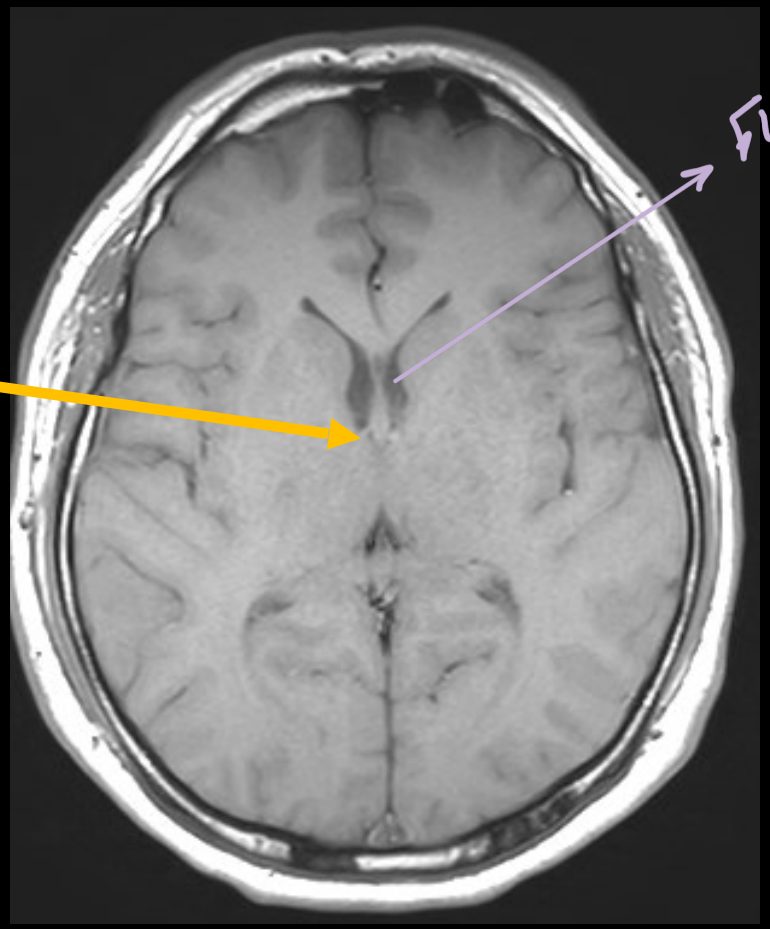

T1 weighted

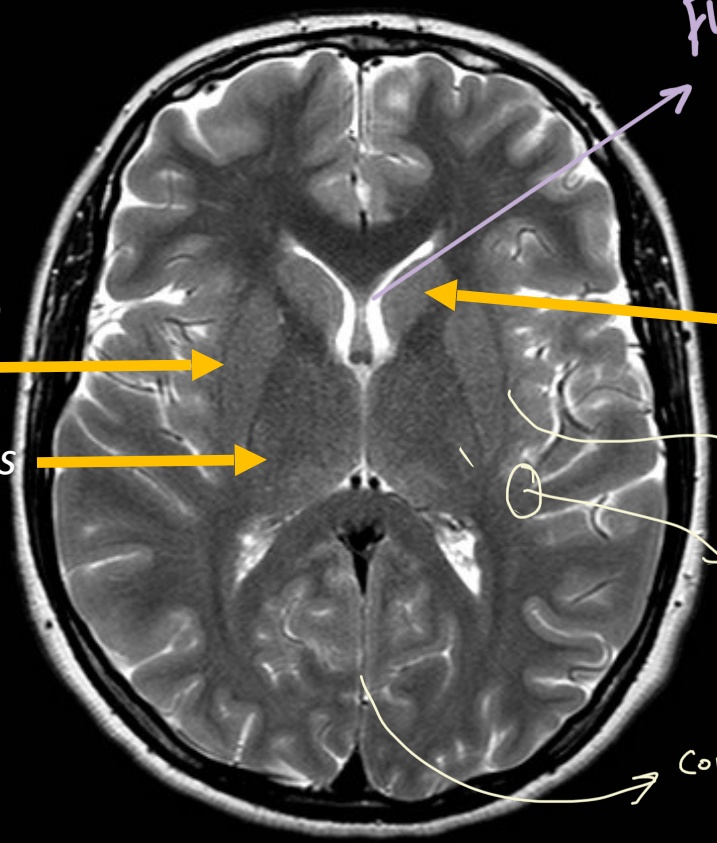

T2 weighted

T1 hyperintense (bright) lesions i.e. short T1 lesions

- *High protein: e.g. Rathke cleft cyst*
- *Mineralization*
- *Fat & cholesterol*
- *Subacute hemorrhage (Meth Hb)*
- *Subacute thrombus*
- *Manganese (e.g. in striatum in liver disease)*
- *Melanin*

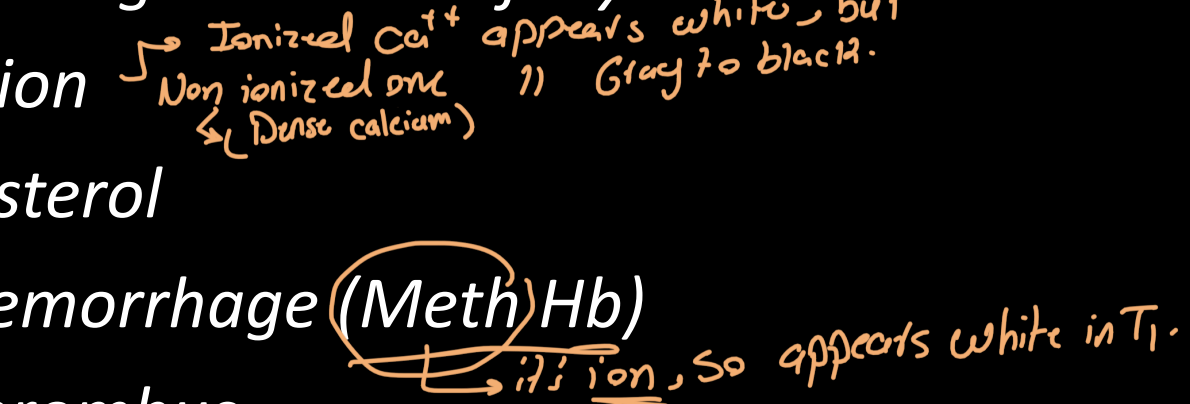

T1 hypointense (dark) lesions i.e. lesions with :T1 prolongation

- *CSF*
- *Edema*
- *Chronic hemorrhage*
- *Air* [In both T_1, T_2 → appears black [hypodense].
- *flow in blood vessels* → معظم الأحيان أسود في T_1, T_2.
- *Low protein*

"في كلام كبير خاص بتعوّن الأشعة ← ملناش فيه."

T2 hyperintense (bright) lesions i.e. long T2

- *Sensitive for many pathologies, edema or gliosis*
- *Edema*
- *Gliosis*
- *CSF*

T2 hypointense (dark) lesions i.e. short T2

- *Calcification*
- *Air*
- *Fibrous tissue*
- *Acute hemorrhage*
- *Very chronic hemorrhage (hemosiderin)*
- *High protein*
- *Calcium*
- *flow in blood vessels*
- *Metal*

FLAIR (fluid-attenuated inversion recovery)

← الجهاز بيشيل ال Fluid إلي جوّا ال cavity زي ال ventricles وفي ال Arochnoied cyst، لكن ال Fluid إلي جوّا ال cells مابيشيلها، وبكدة ببين ال Edema.

← وزي م فيه لل Fluid / فيه لل Fat / بيعمل Fat substraction ← بيمحي ال Fat الكيتو

فبشوف ال pathology بشكل أوضح ← Especially post. contrast:

لأنّ ال Fat أبيض وال contrast أبيض.

- *Sensitive but not specific*
- *.a type of T2 but CSF is black* [Fluid substraction].
- *FLAIR: Helps identify pathologies. shows areas next to CSF .(periventricular) very well. Also good for juxtacortical areas*
- *.Inferior quality to other sequences in posterior fossa and spinal cord*

FLAIR

- *Helps differentiate VR space from Lacunar infarct*
- *Causes of FLAIR hyperintensity in sulci*

SAH

High protein (meningitis, neoplastic)

High oxygen tension (intubation & ventilation)

.Artifact

FLAIR image

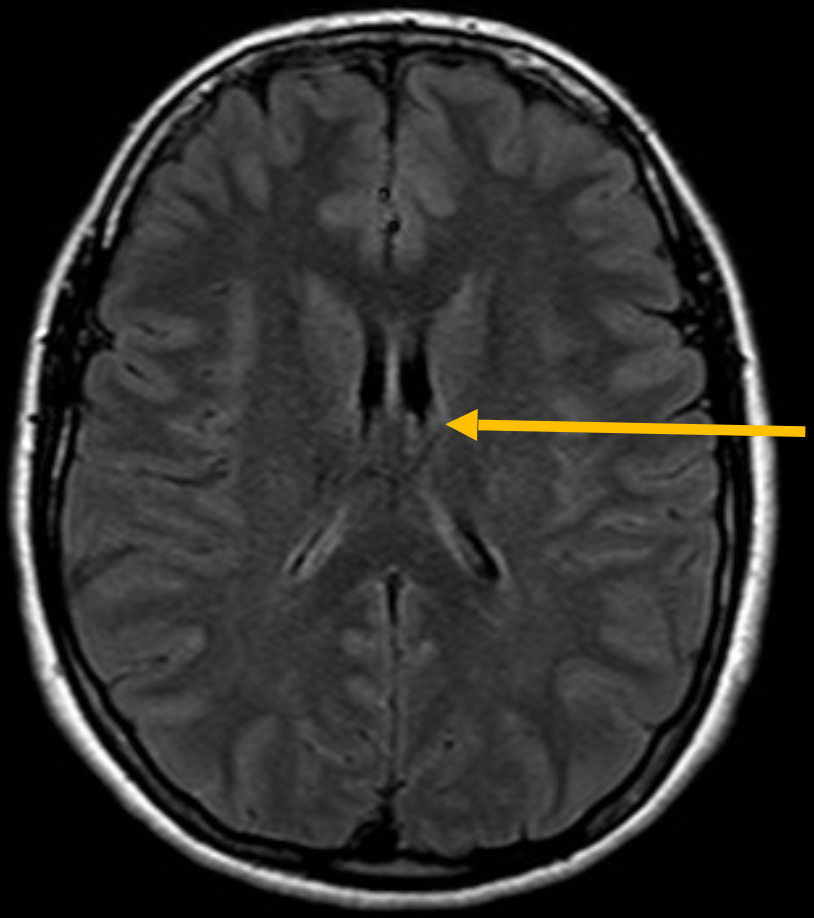

Suppression
Of normal
fluid in
Ventricles & sulci

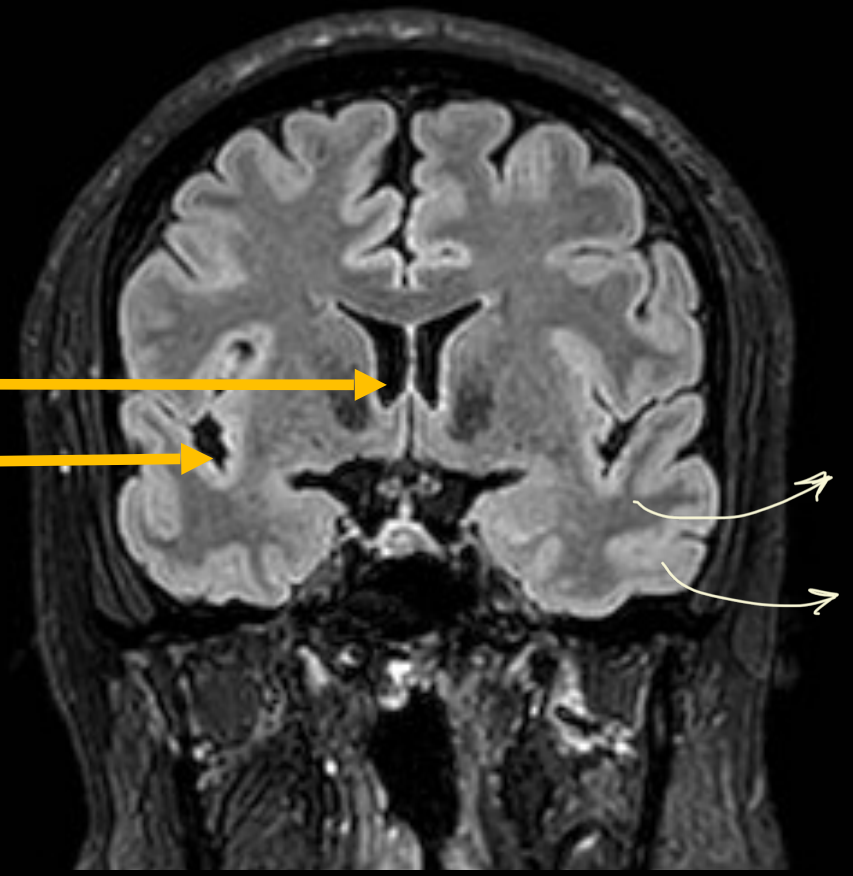

T_2

T_1

white matter is more
عرفناها (أبيض من T_2).

Diffusion weighted imaging

- *Diffusion imaging uses diffusion of water molecules. Calculates apparent diffusion coefficient ADC that can be displayed on a separate scan.*
- *Detects changes in local deoxy- and oxy-hemoglobin ratios, helps localize cognitive (including language) & other functions*
- *Apparent diffusion coefficient, ADC:*
- *Decreased in cytotoxic edema i.e. opposite to diffusion i.e. true DW restriction i.e. infarct or abscess.*
- *Increased from a T2 effect 'T2 shine-through' i.e. same as diffusion.*
- *Restricted diffusion= high signal on DWI & low signal on ADC*

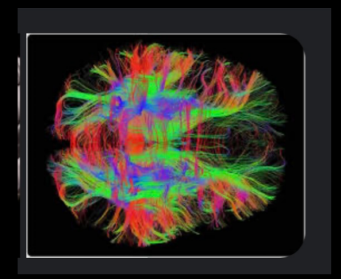

(10-15) minut الـ image الـ لعلاج DWI الـ ← Acute stroke بالمخ/بتجاسي Resolution الـ
(-) حساس/highly sensitive لـ

Images of DWI and ADC

Exclude CUA

بعض النظر عن الـ clinical picture الـ في جاي فيها المريض.
(CT لو ما بتقولك إيه/رجعها).

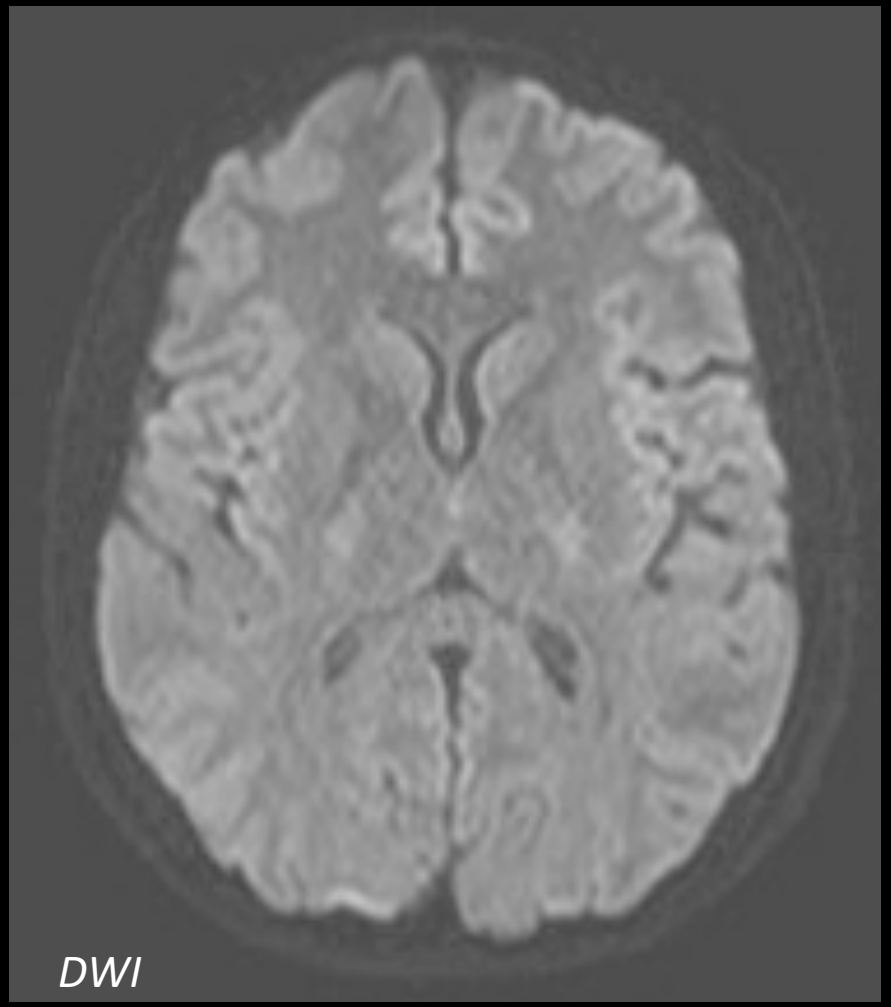

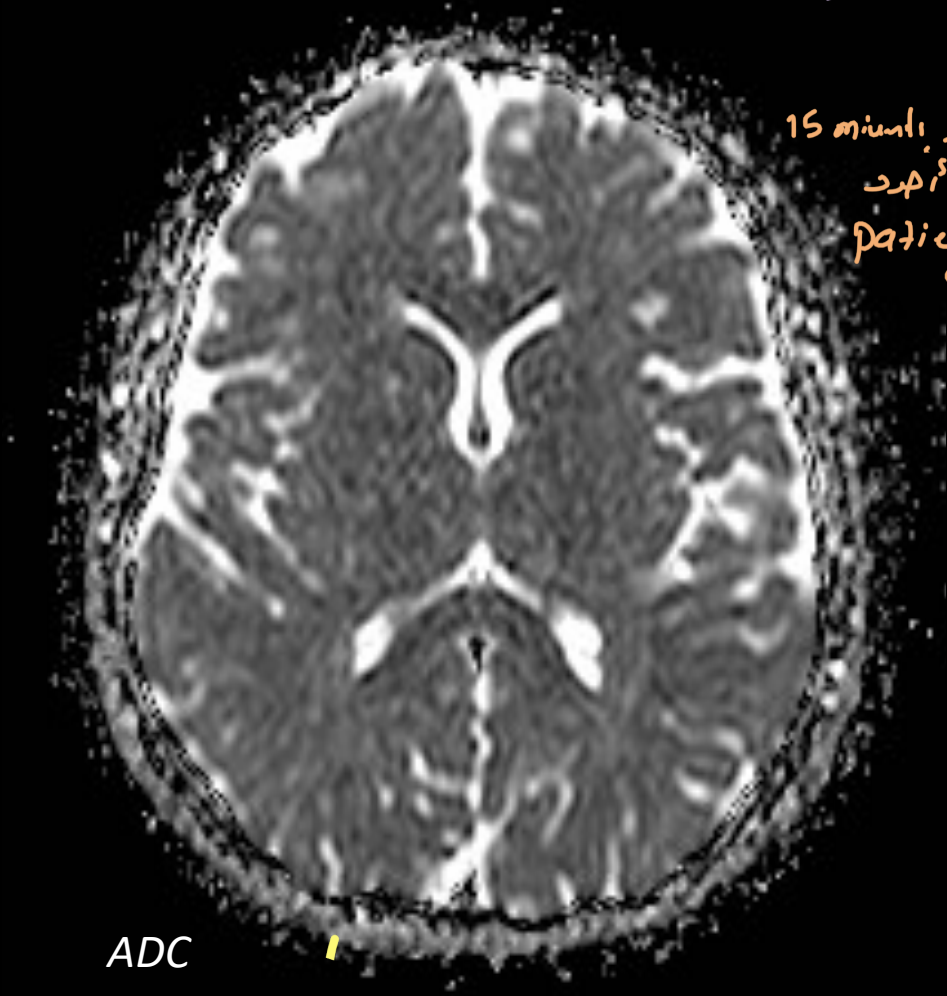

* خيب خلال الـ 15 minut الـ لازم نعرف كيف نحكم
Patient has الـ إذا
CUA or not?!

عن طريق (invitro study)
في جامعة القدس معلوم تسعة
وتسعين المئة بيشوفو تدبير الوقت
المناسب ليصير(؟)

[ملاحظة:]

Increased DWI seen in

- *acute ischemic stroke*
- *Important to evaluate for diffusion restriction also in*
- *encephalitis like herpes*
- *focal seizure*
- *Infections (like abscess, CJD)*
- *Tumors and tumor treatment response (egs like medulloblastoma, epidermoid cyst)*
- *Asses extent of diffuse axonal injury*
- *Asses active demyelination*

more sensitive to blood.

GRE & SWI sequences

لا T1 ولا T2 الكن بيشبه T2.

Detects hemorrhage (hemosiderin) well. Low intensity (called .susceptibility artifact or T2 effect)*

- *Diffuse axonal injury*
- *Hypertension and amyloidosis*
- *Multiple cavernomas*
- *.Evaluation of Venous sinus/cortical vein thrombosis*
- *Infections*

GRE and SWI

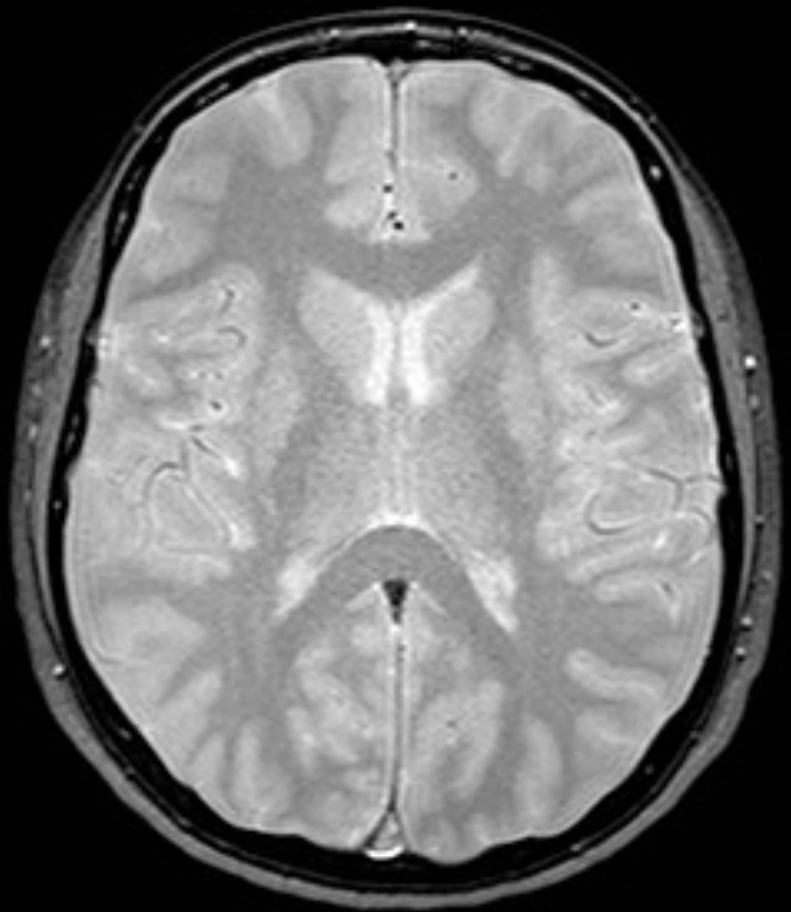

** T2*

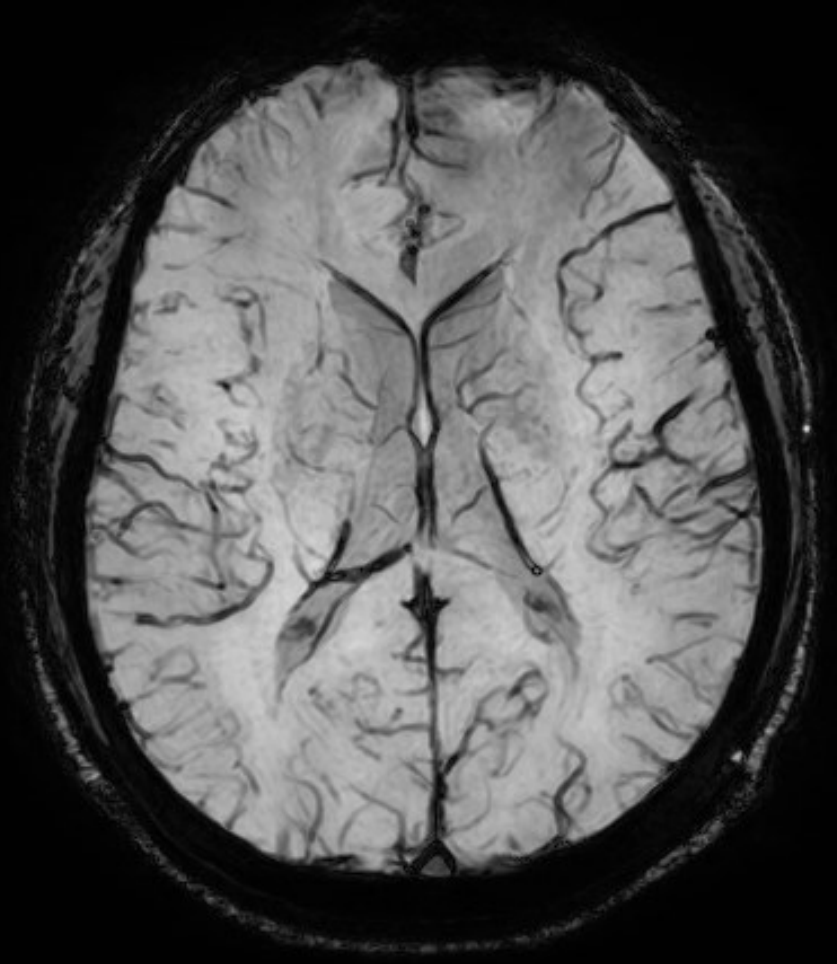

SWI

Normal structures that enhance on MRI

Gadolinium can't pass it.
(MRI contrast)
لأنه المحاضرة الأولى موجود أسماء contrast
لكل image.

Structures outside the blood-brain barrier like

- *Dura*
- *Adenohypophysis and pituitary stalk*
- *Pineal gland*
- *Choroid plexus*
- *Nasal mucosa*
- *Tuber cinereum*
- *Area postrema*

T1 +Gadolinium

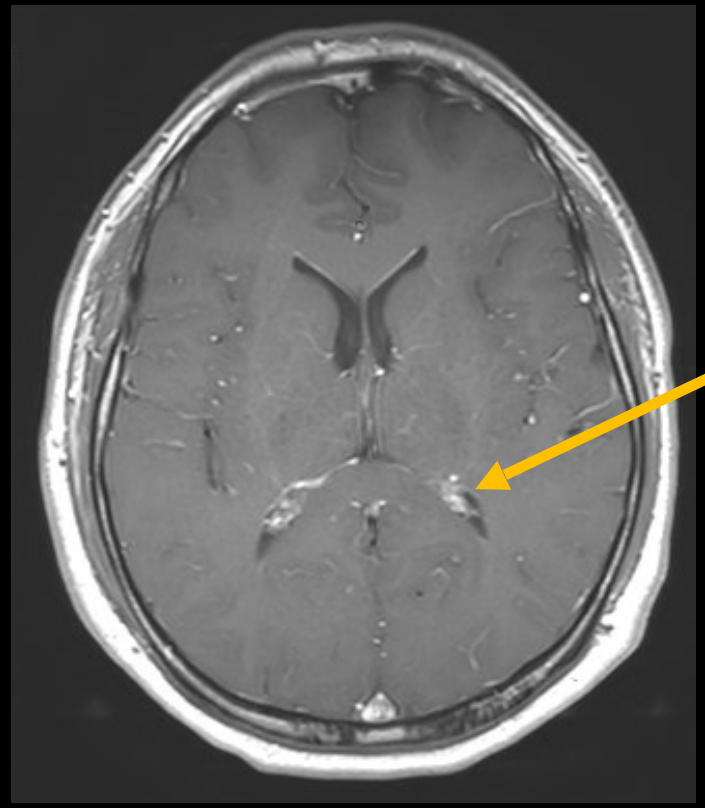

Enhancing Choroid Plexus

Enhancing Pituitary gland stalk &

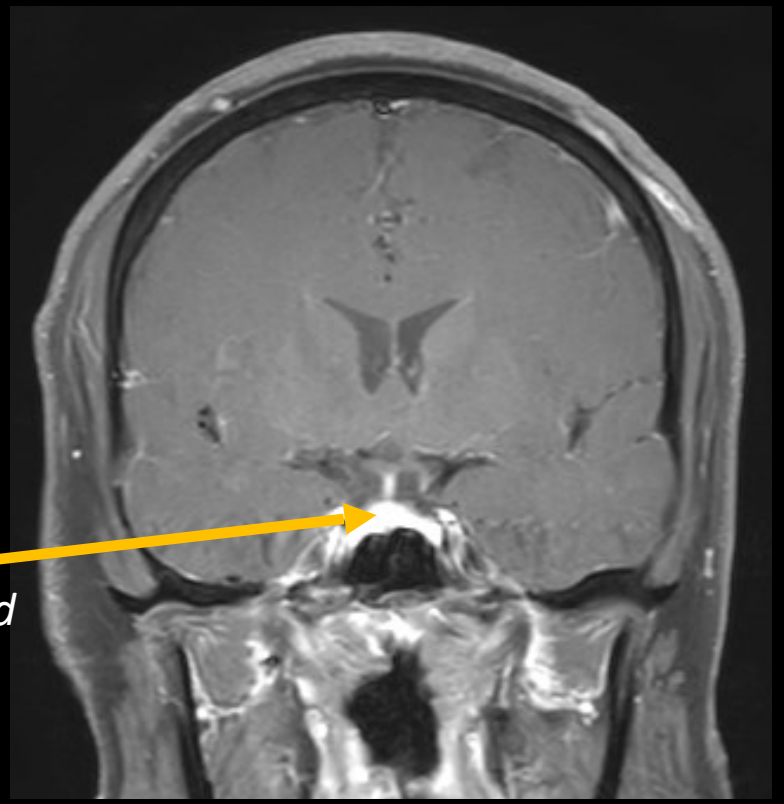

- *Disruption of normal blood brain barrier causes enhancement of different lesions on MRI.*
- *Enhancement may be seen in:*
  - *Tumors*
  - *Infections*
  - *Inflammatory conditions such as active demyelinating lesions*
  - *Subacute areas of ischemia*

Sagittal images

- *Scroll and look at midline image (in the mid-sagittal plane) from bottom to top. Then look laterally at the parasagittal planes. Observe the normal and .abnormal structures*
- *Foramen magnum & base of skull including cerebellar tonsils*
- *Clivus and nasopharynx*
- *Fourth ventricle and Cerebellar vermis*
- *Sella, pituitary & optic chiasm*
- *Corpus callosum*
- *Superior sagittal sinus*
- *Visualized cervical spine*

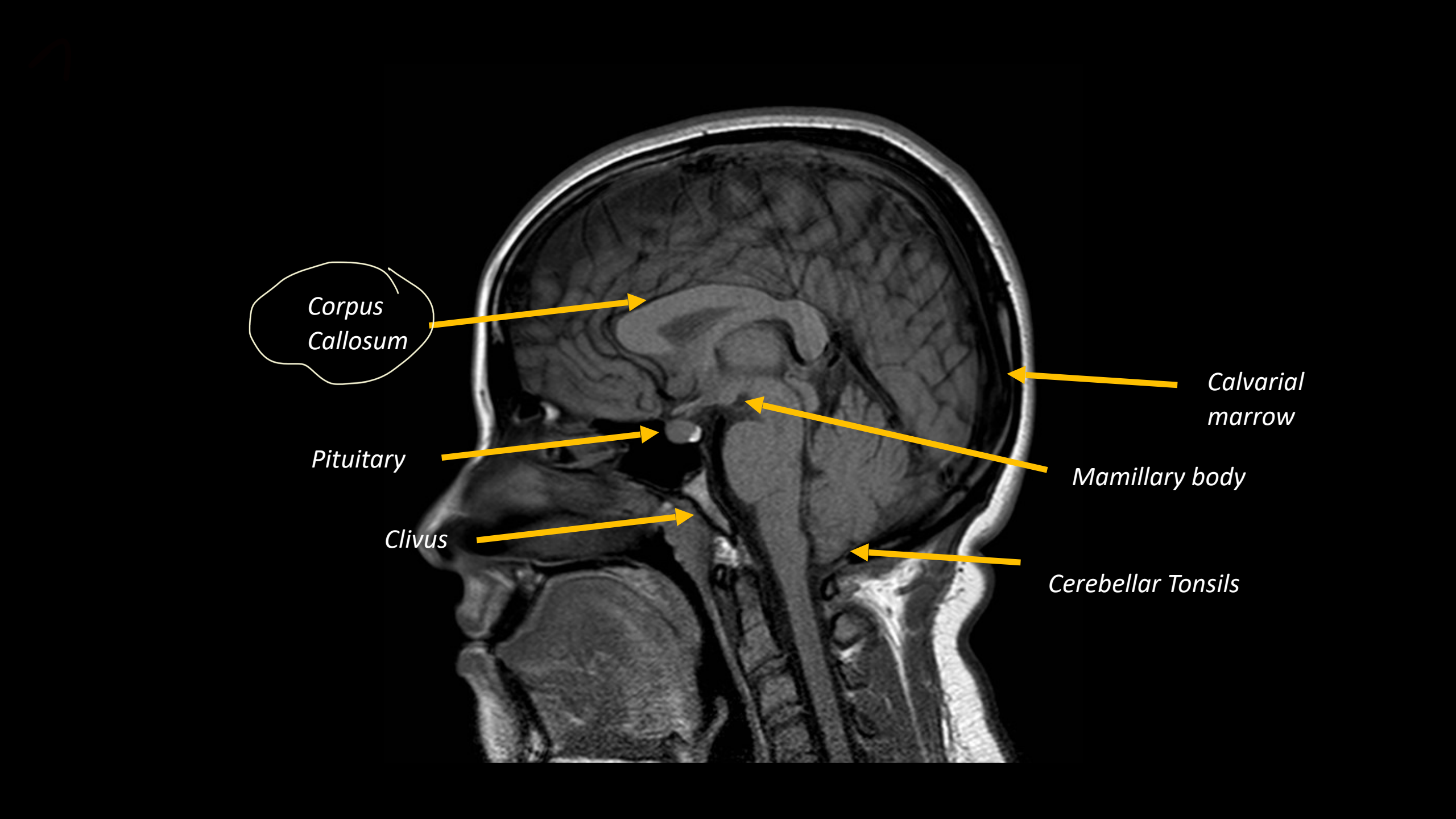
Corpus Callosum
Pituitary
Clivus
Calvarial marrow
Mamillary body
Cerebellar Tonsils

- *When interpreting the axial images follow a systematic approach. Scroll through the MRI from bottom to top interpreting each of these systems or areas at a time. The CSF system (ventricles, cisterns and sulci), the brain matter (grey matter structures and white matter structures), the vessels and venous sinuses, the meninges and skull and adjacent tissues. And finally the extended search i.e. review areas .(paranasal sinuses, orbits, nasal cavity, visualized tongue and face)*

Ventricles, cisterns & sulci

- *When ventricles, cisterns, fissures or sulci are “squashed” we use the term effaced. When they are large we just describe them as large or enlarged. The different CSF spaces should be interpreted together for example, effaced sulci tell us that the enlarged ventricles likely represent hydrocephalus. Whereas enlarged sulci and enlarged ventricles likely represent brain volume loss*

:Ventricles

- *Lateral ventricles (frontal, occipital & temporal horns), Third ventricle, fourth ventricle*

:Cisterns & fissures

- *Quadrigeminal plate cistern, interpeduncular cistern, ambient cistern, suprasellar cistern*

:Sulci

- *Appearance: effaced, obscured*
- *Ventriulo-sulcal proportionality*

Brain Grey & white matter

- *Midline shift*
- *Grey white differentiation*
- *:Structures*
- *Caudate nucleus, Internal capsule, Putamen & globus pallidus, .thalamus*
- *Other structures: centrum semiovale, midbrain, pons, medulla, cerebellum*

Vessels: arteries, veins & venous sinuses

- *Arteries: basilar, carotid arteries, vertebral artery, middle cerebral arteries*
- *Venous: Superior sagittal sinus, torcula, transverse sinus, sigmoid sinus, internal jugular vein*

Meninges

- *Dural involvement/enhancement look at (falx, tentorium, CP angle)*
- *Leptomeningeal enhancement look at (basal cisterns, cerebellar folia, sulcal perivascular spaces)*

Extra axial lesions

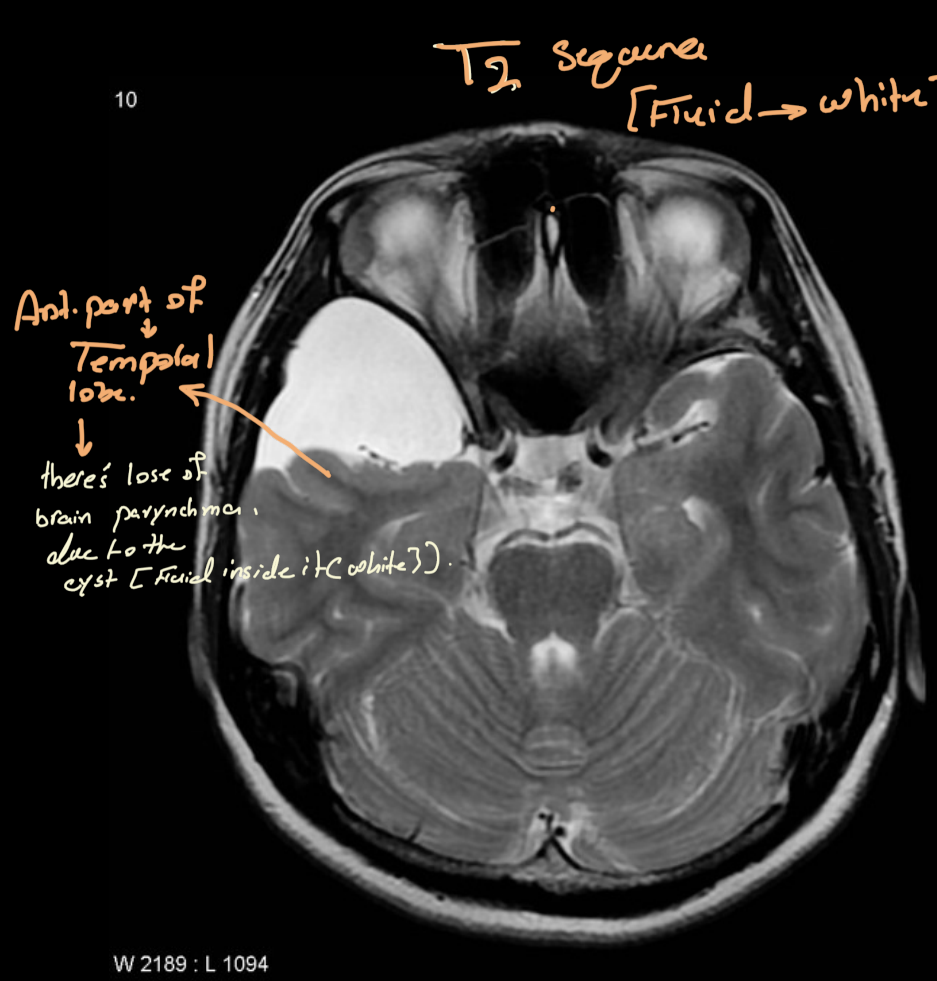

Subarachnoid cyst

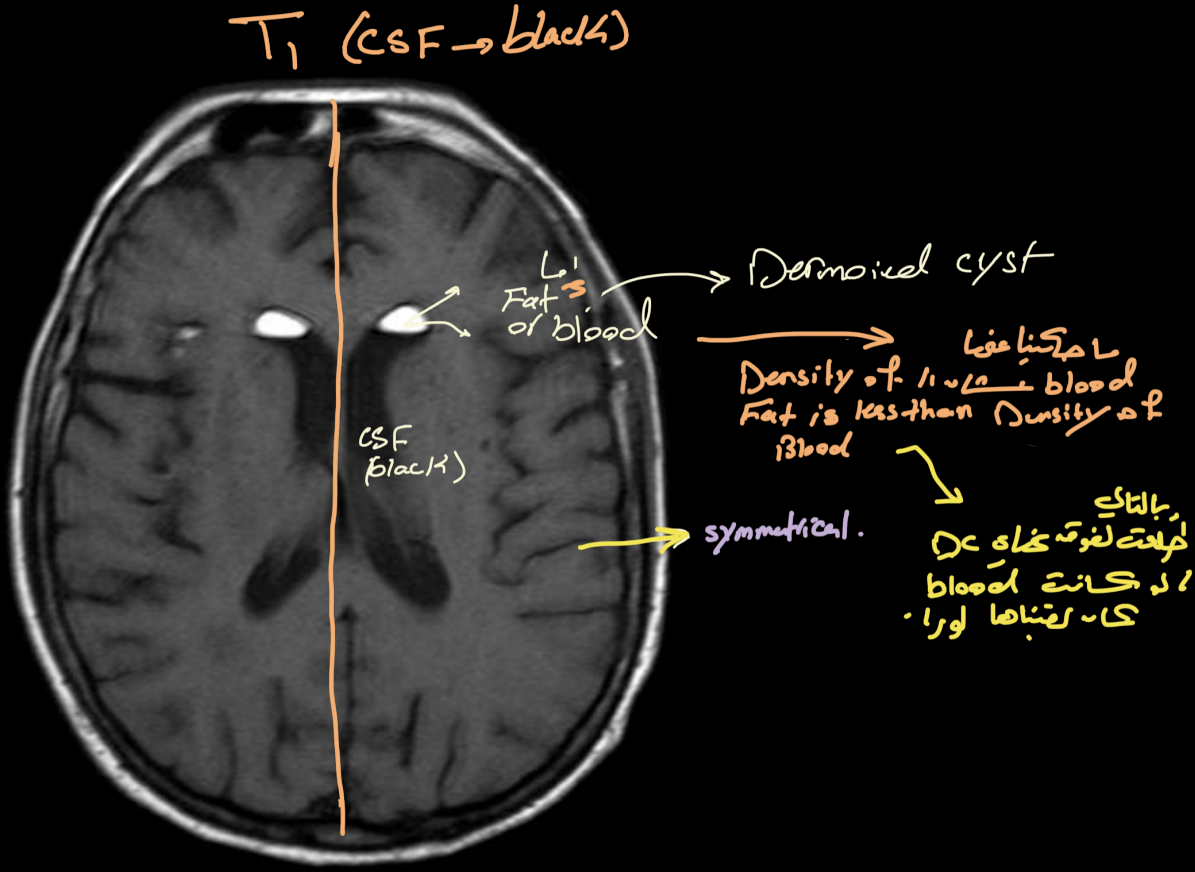

dermoid cyst

T_1 (CSF is black)

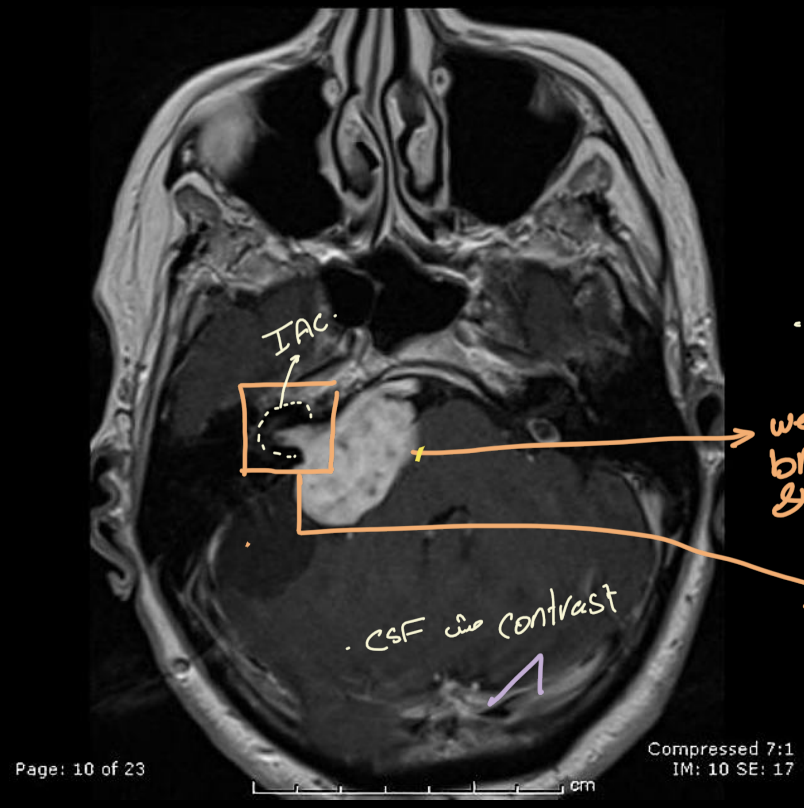

مش مبيجوا ال brain ميا وانما ضاغطة عليه.

well defined mass, compress the brain tissue especially Brain stem & Middle of cerebellum.

Extension of Mass to the internal autidary canal [Ice cream / coan appearance].

Vestibular schwannomas

↳ causing tenites / headache / vertioge -- etc.

↳ Benign tumor, it's a dangerous surgery → May 7th CN + 8th CN injured in the operation.

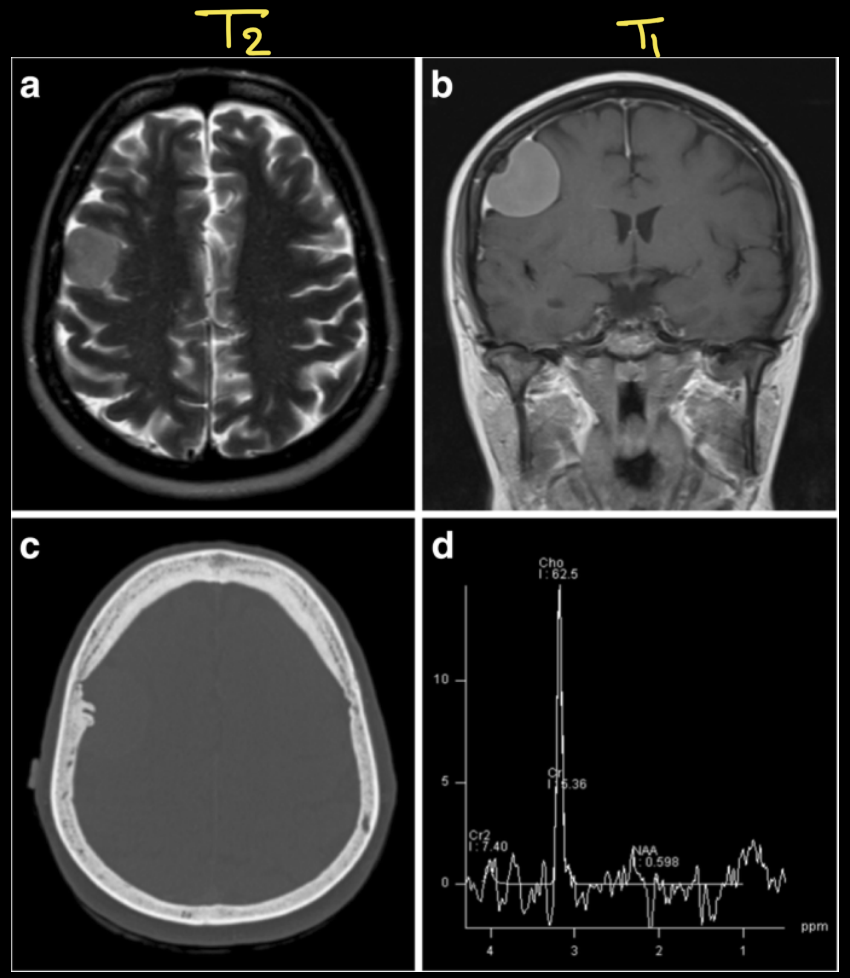

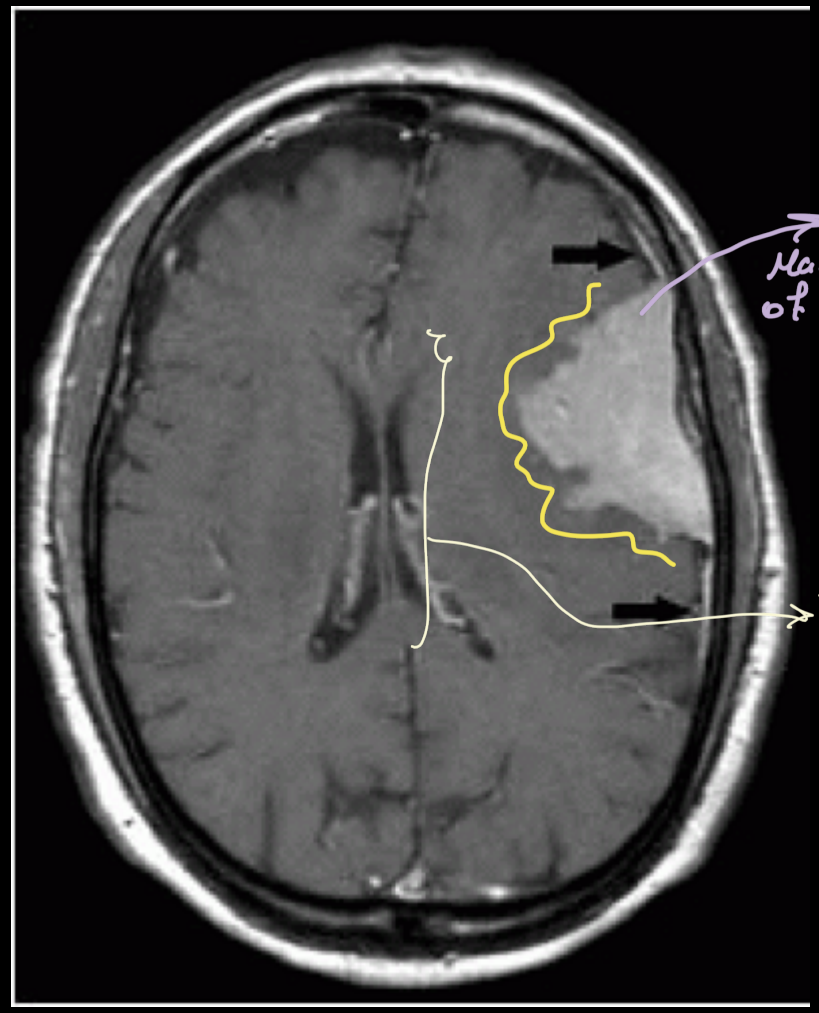

attach with Dura making dural tail + compressing of brain tissue which is Meningioma.
↳ Benign lesion.

There is a midline shift [Mass effect].



Common Intra-Axial Tumors in Pediatric

Supratentorial:

Astrocytoma
Pleomorphic xanthoastro (PXA)
PNET
DNET
Ganglioglioma

Infratentorial:

Juvenile Pilocytic Astro
PNET (Medulloblastoma)
Ependymoma
Brainstem Astrocytoma

Common Intra-Axial Tumors in Adult

Supratentorial:

Metastases ++

Gliomas (25%)

- Fibrillary Astrocytoma
- Anaplastic Astrocytoma
- Glioblastoma Multiformi
- Oligodendroglioma

Infratentorial:

Metastases ++++

Hemangioblastoma

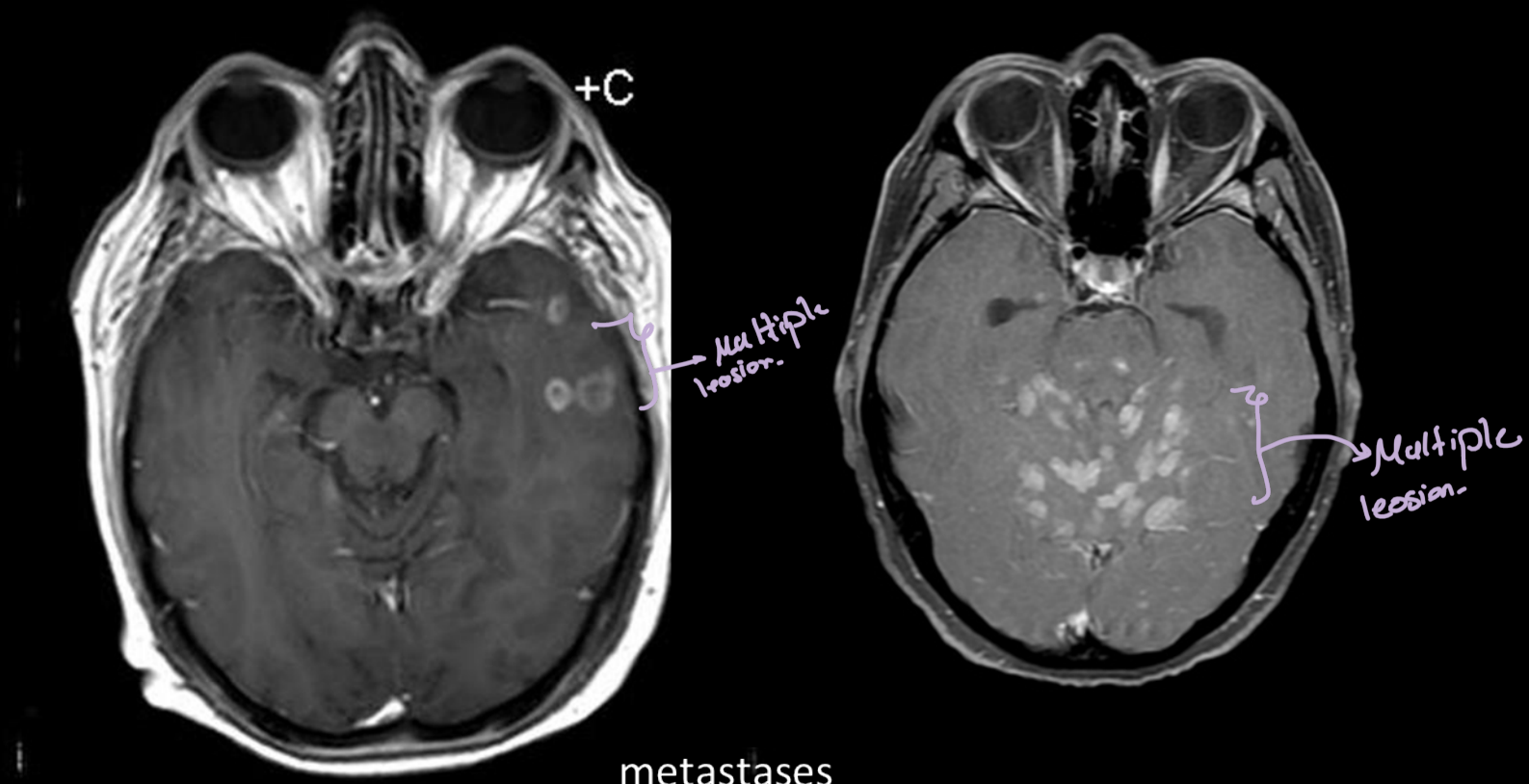

metastases

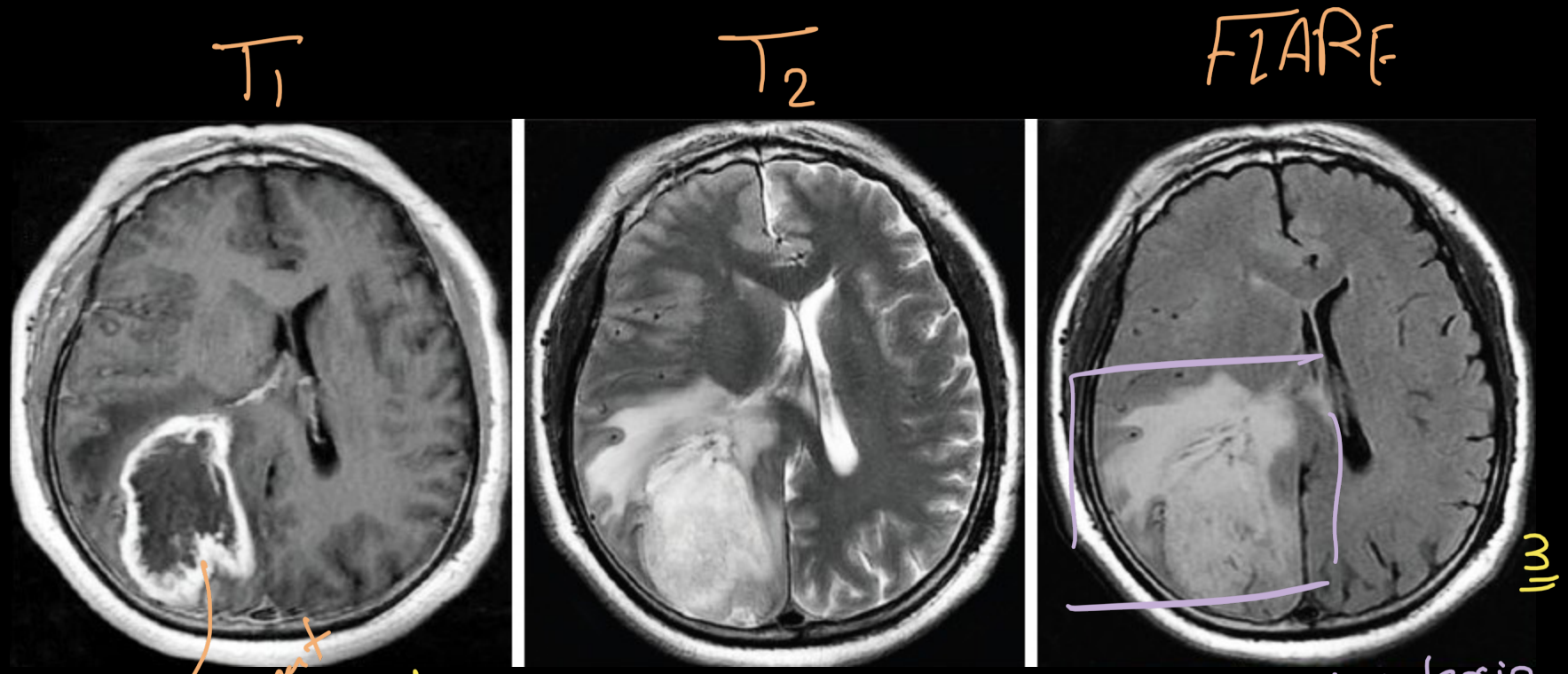

* ال leosio جوا ال brain .
+ Mass effect [Mid line shif] .

astrocytoma

في (1) فيه عنا enhancement لكن post contrast [In 2] راح ال Enhancement بسبب ال Necrosis .

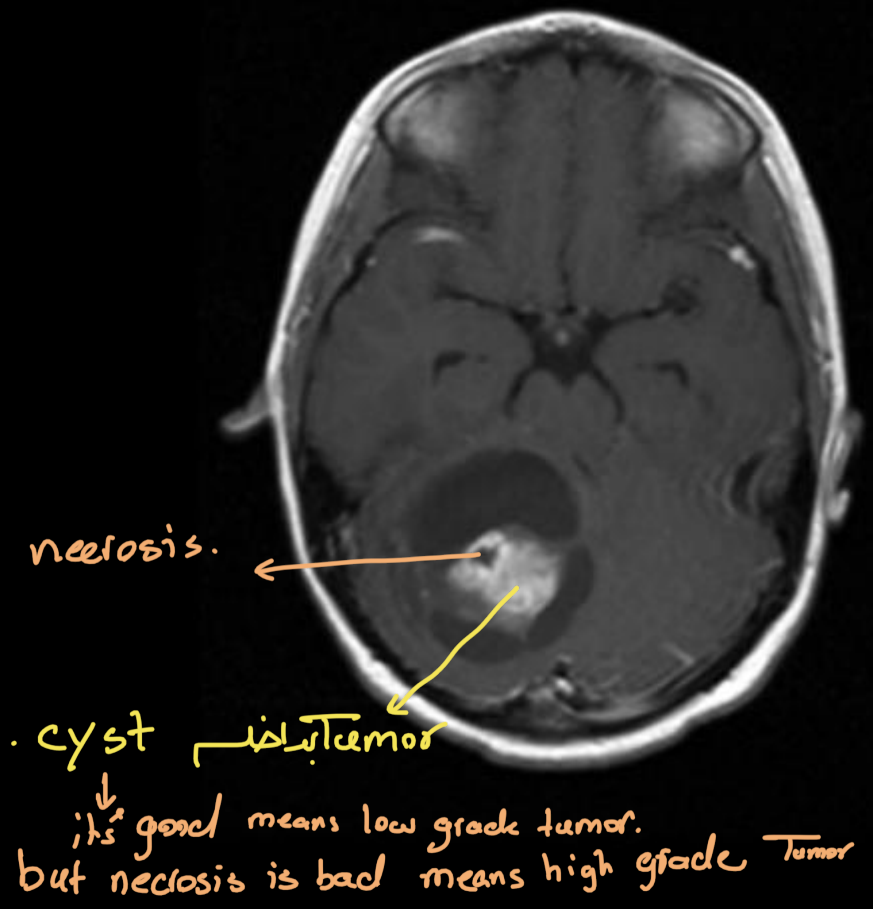

Pilocytic astrocytoma

meduloblastoma

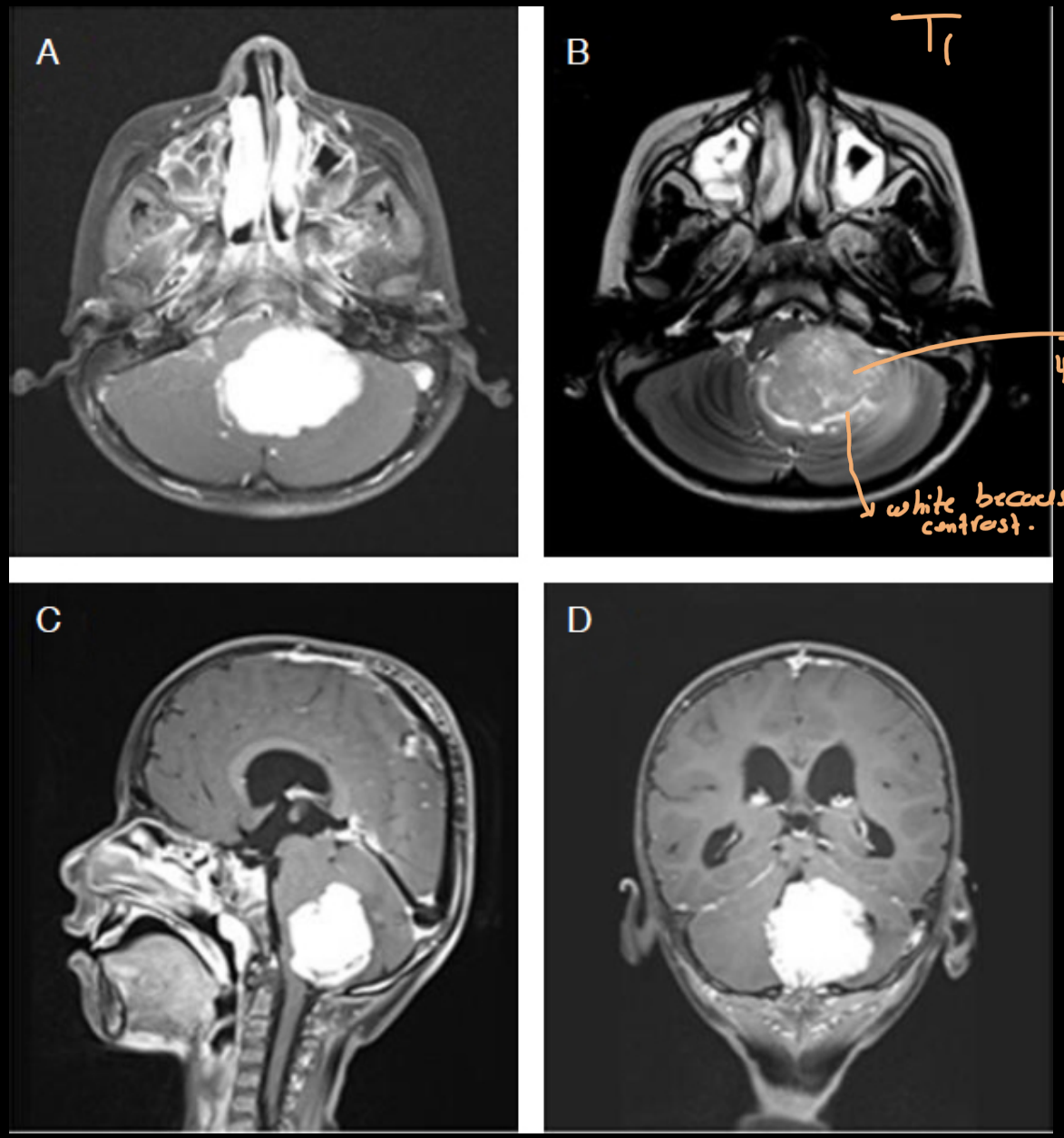

T1

Tumor of cerebellum
4th ventrick
typical
Medulloblastoma

white because of contrast.

also, ependymomas
in the skull base of pediatric
- infratentorial in the 4th ventricle.

Extended search

- *Sella, pituitary & optic chiasm*
- *Paranasal sinuses (ethmoidal, sphenoid, frontal, mastoid), temporal bone/ears*
- *Orbits*
- *Nasopharynx, Oropharynx*