Head CT

DR MOHAMAD MATAR

LEARNING OBJECTIVES

Upon completion of this course, participants :will be able to

- Understand the basics of head CT imaging
- Identify and describe basic cerebral anatomy
- Develop an approach to head CT interpretation
- Identify pathologic lesions found on head CT

CT BASICS

- CT uses x-rays [In one cut].
- Provides axial brain view
- CT scan measures density of the tissue being studied

OU Neurology

CT Brain axial view

- CT uses x-rays to make cross-sectional axial images
- Right is on left and left is on the right
- Patient lying on a stretcher with feet coming toward you and is slid through a large open ring (CT machine)

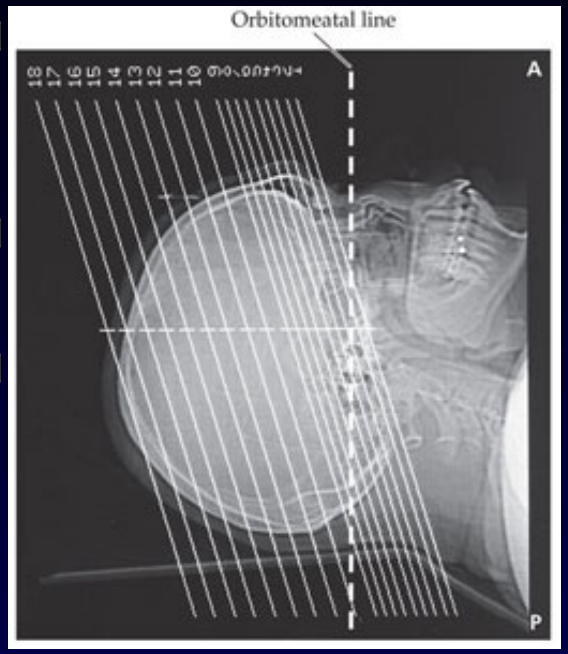

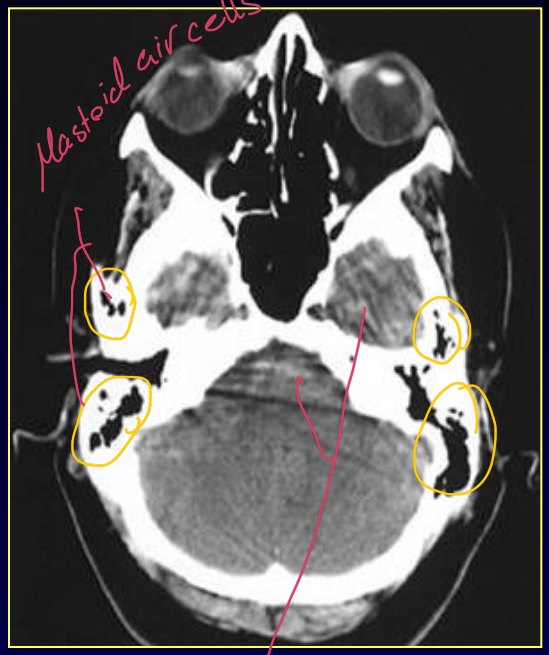

Lateral view of skull is shown with imaging planes indicated by lines. The true horizontal plane is approximated by the orbitomeatal line, while the typical CT imaging plane is angled slightly upward anteriorly

OU Neurology

CT BASICS-density

↳ It's calculated by: HU [Hounsfield unit formula]

Black



Structure/ Tissue	Hounsfield units
Air	-1000 to -600
Fat	-100 to -60
Water	0
CSF	+8 to 18
White matter	+30 to 41
Gray matter	+37 to 41
Acute blood	+50 to 100 (60-70)
Calcification	+140 to 200
Bone	+600 to 2000

White

calcification بتكون
blood
(Faint) تقريبًا مساوية

70 بتكون

حسب ↓

[1] cortical bone >1000
or
[2] cancelous bone [Medulla of the bone]

(200-600) بتكون

blood ؟! لو تكتيف بدك أعرفها مساوية
MRI بكون المريض

Hyperdense things on CT

(بيانات)

- blood
- calcification
- Foreign body.

2 ocular lens

bone

contrast (dye)

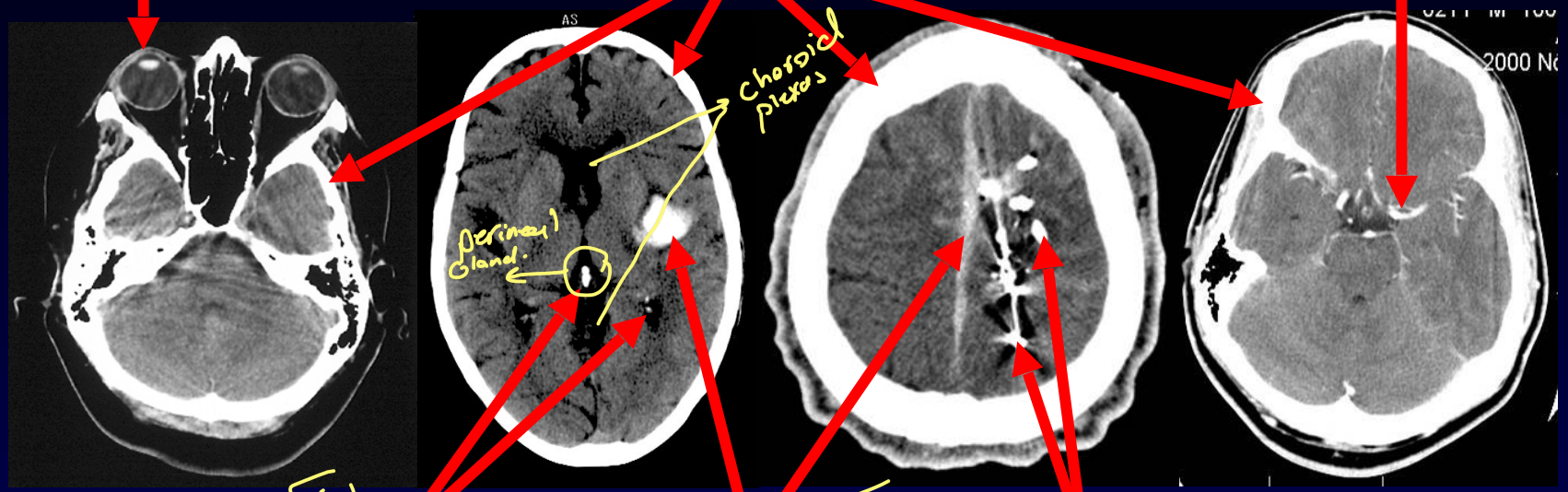

1

calcifications

- physiological calcification in:
  1. Basal ganglia. → bilateral (عادة بتكون بالجانبين)
  2. Perineal body.
  3. choroid plexus

في تقليل سبب يخلي calcif. يعتبر pathological مثل: زي hyperparathyroidism, Renal dystrophy. + others.

3

acute blood [Blood in Basal ganglia: دم بالعقد القاعدية]

/metal (bullets w (streak artifact



OU Neurology

Isodense things on CT

Basal ganglia consists of:
1. External capsule.
2. Internal capsule.
3. lenticiform nucleus.
   - Globus pallidus [Medial]
   - putamen [Lateral]

4. Head of caudate nucleus

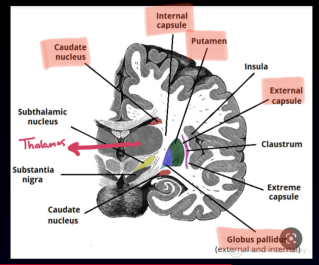

- *Note that white matter is less dense than gray matter and therefore:* ***white matter is darker than gray matter***

Gray matter (cerebral cortex)

Gray matter (basal ganglia)

White matter



Hypodense things on CT

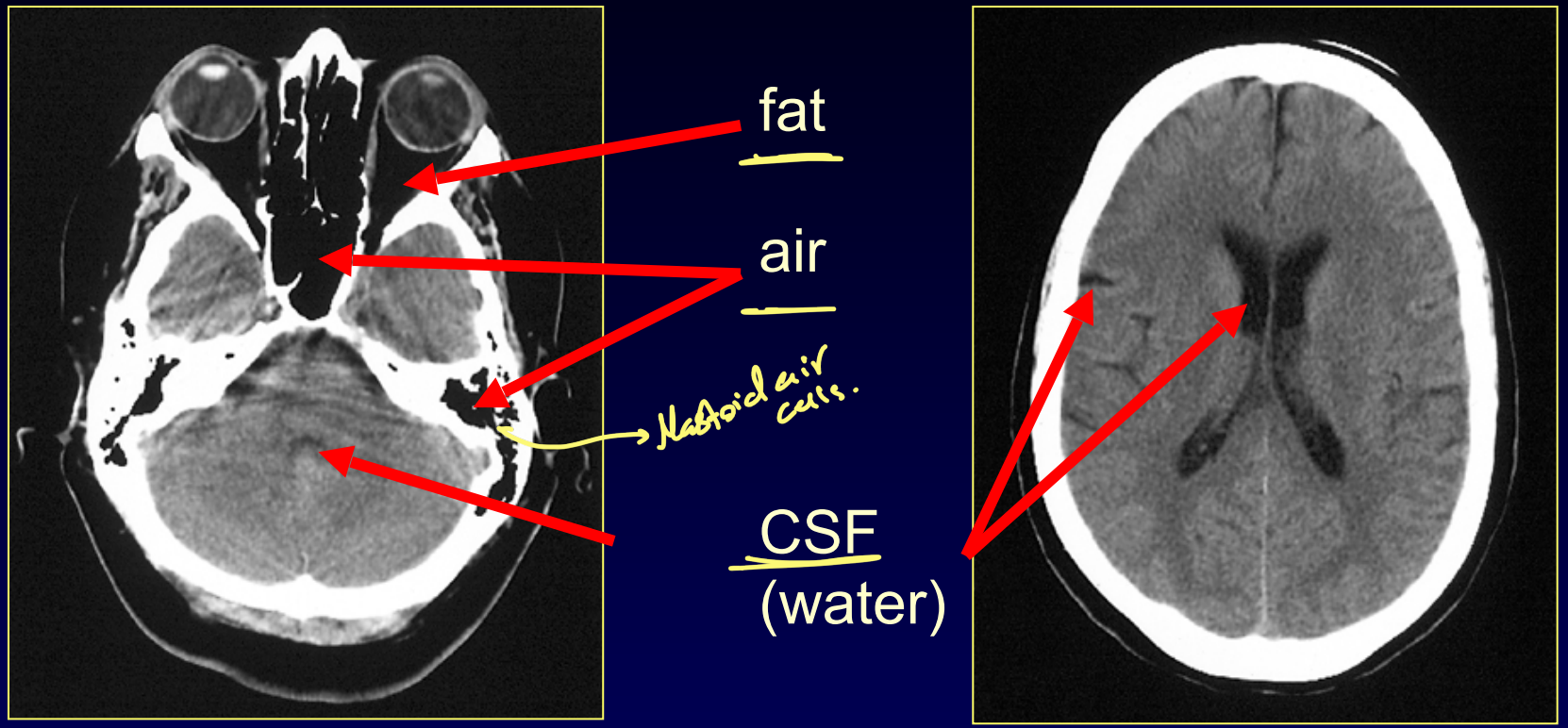

Normal Brain anatomy

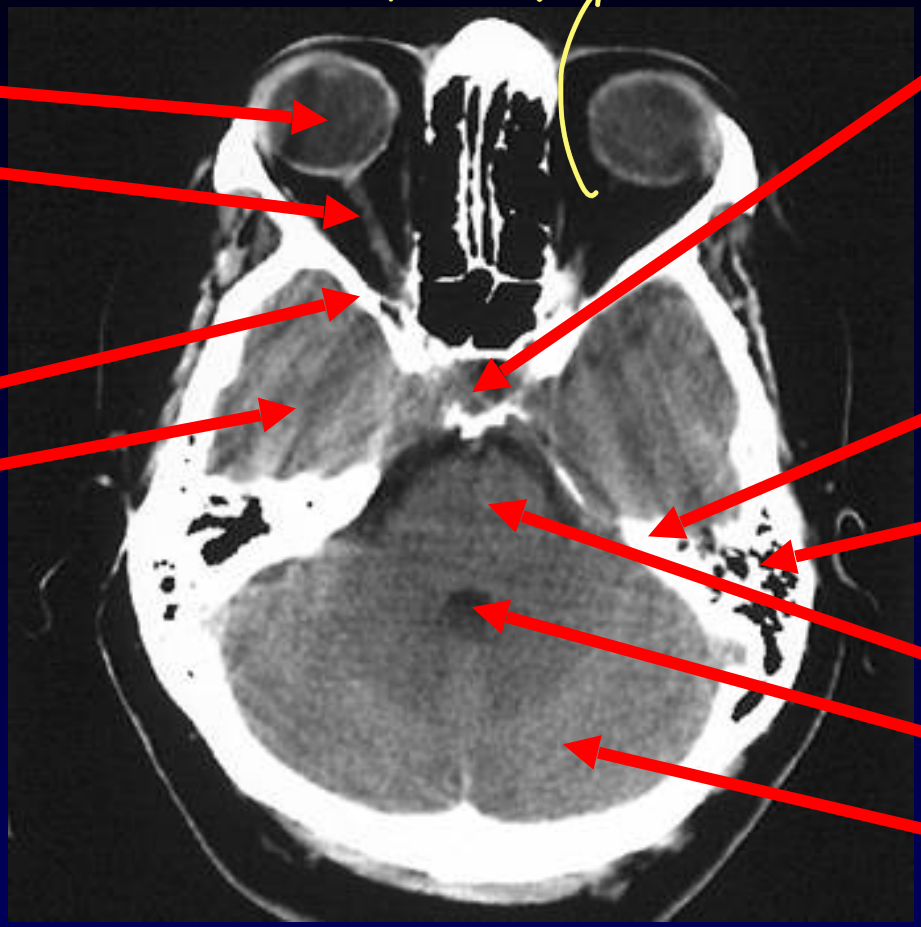

Eye

Optic nerve

Sphenoid bone

Temporal lobe

Sella turcica contains pituitary) (gland

Petrous bone

Mastoid air cells

Pons

4th ventricle

Cerebellum

Normal Brain Anatomy

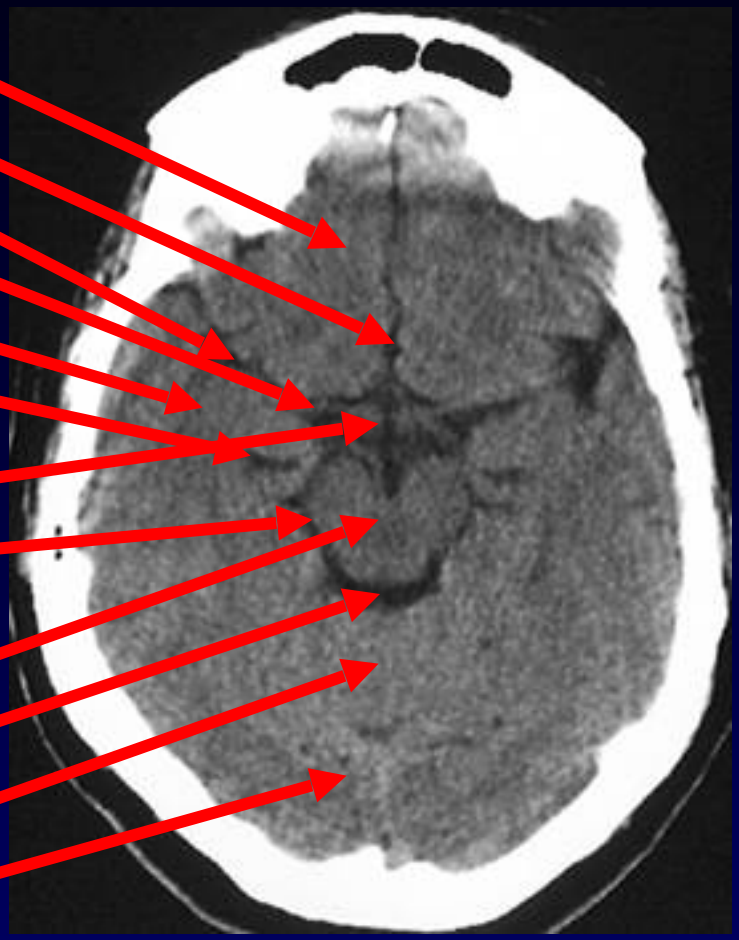

Normal Brain Anatomy

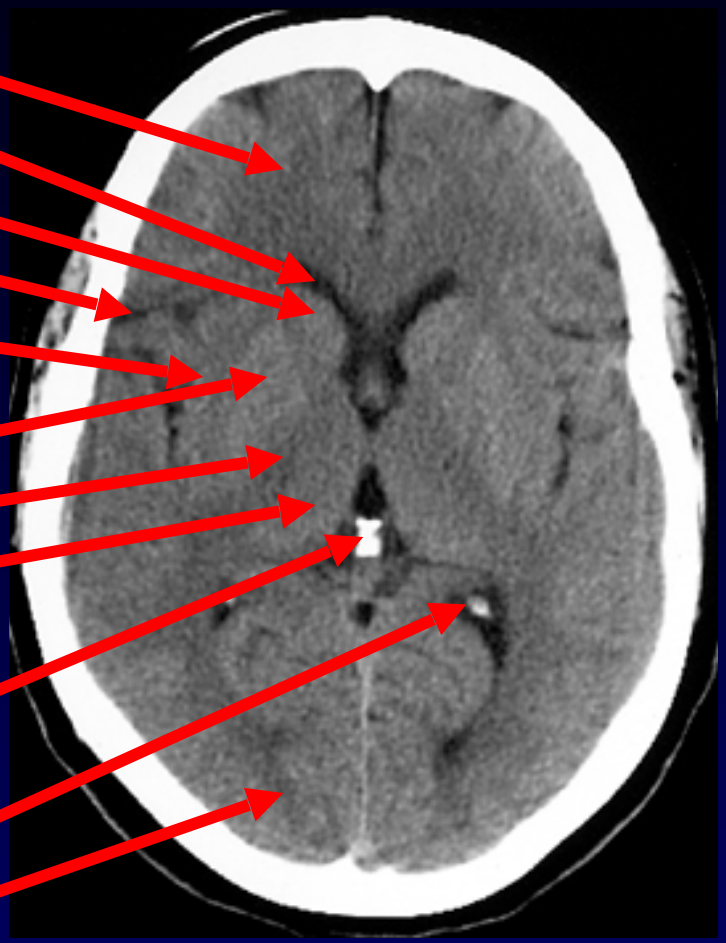

Approach to Reading a CT scan- ABBBC

- A- Air-filled structures (sinuses, mastoid air cells)
- B- Bones (fractures)
- B- Blood (subarachnoid, intracerebral, subdural, epidural hematoma)
- B- Brain tissue (infarction, edema, masses, brain shift
- C- CSF spaces (sulci, ventricles, cisterns, hydrocephalus, atrophy)

A- Air-filled Structures

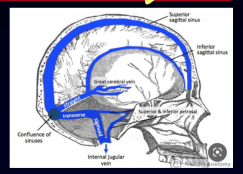

- Normal air spaces are black both on bone and brain window (frontal, maxillary, ethmoid, and sphenoid sinuses)
- Mastoids are spongy bone filled with tiny pockets of air
  When these pockets are opacified you will see a (gray or white) shade
- Air-fluid levels in the setting of trauma suggest a fracture
- Mastoid opacification without trauma indicates mastoiditis

B- Bones

* 90% of brain CT for suspecting Trauma.

* Bone window for detecting
  1. Fracture.
  2. bone mets [due to breast cancer, neuroblastomas, ewing sarcoma, HM].

- Useful when trauma is suspected
- Window your image for bone reading
- Recognize normal suture structures (usually visible on both sides)
- If fracture suspected, inspect the opposite side for similar finding
- If not present then look for abnormalities associated with the fracture (air/pneumocephalus, black spots within the hemorrhage)

* CT is not a primary method of the bone Fracture, it's x-ray.

OU Neurology

B- Blood

Location and shape of the blood

- Epidural hematoma: over brain convexity, not crossing suture line, lens shaped .(biconvex)
- Subdural hematoma: over brain convexity, interhemispheric, along the tentorium, SDH will cross suture lines & it's crescent .shaped
- Intraparenchymal/Intracerebral hemorrhage: within the brain matter, sizes/shape varies dependent on etiology can be regular or .irregular
- Interventricular hemorrhage- inside ventricles, can be isolated and or secondary .to SAH, ICH
- Subarachnoid hemorrhage- blood within the subarachnoid spaces (sulci, sylvian fissure, cisterns). Usually assumes shape of the surrounding cerebral structure

Types of Intracranial Hemorrhage

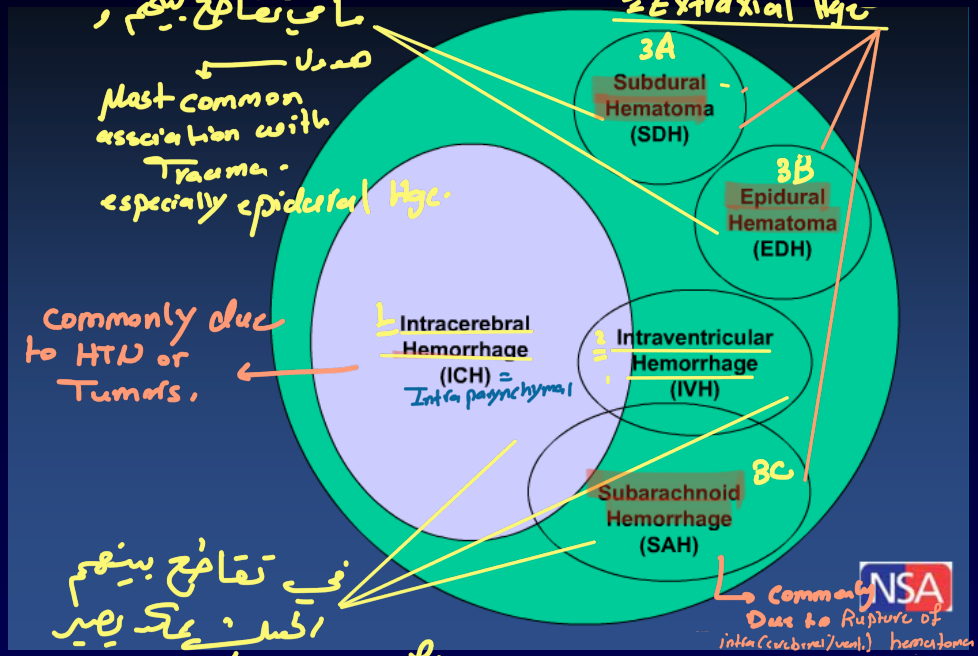

OU Neurology

Epidural Hematoma

- will have a lucid 20% period before clinical worsening
- Note the soft tissue swelling adjacent to the hematoma explaining the mechanism of the injury



Epidural Hematoma

like Middle meningeal a.

- Arterial injury following head trauma
  - Lens shaped
  - Confined between the sutures
  - Most commonly middle meningeal artery



Epidural Hematoma

- Repeat CT brain (post-op)

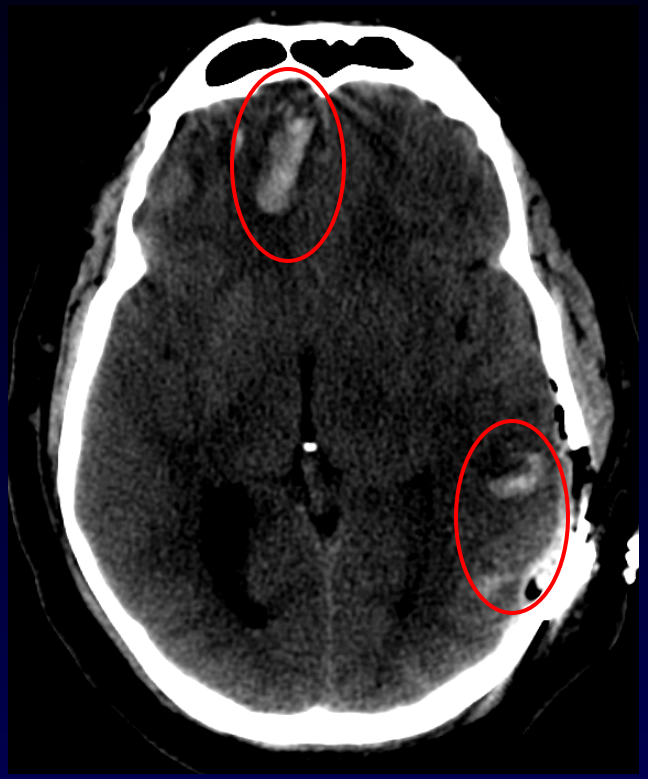

OU Neurology

Subdural Hematoma (SDH)

- Differentiate between acute, subacute, chronic, or acute on chronic
- Acute SDH
  - Bright white on CT
  - Can only be removed with a craniotomy
  - Doesn't always require surgery, depends on the patient's neurological examination and comorbidities
  - Usually related to shearing of bridging veins between the dura and brain

Acute Subdural Hematoma

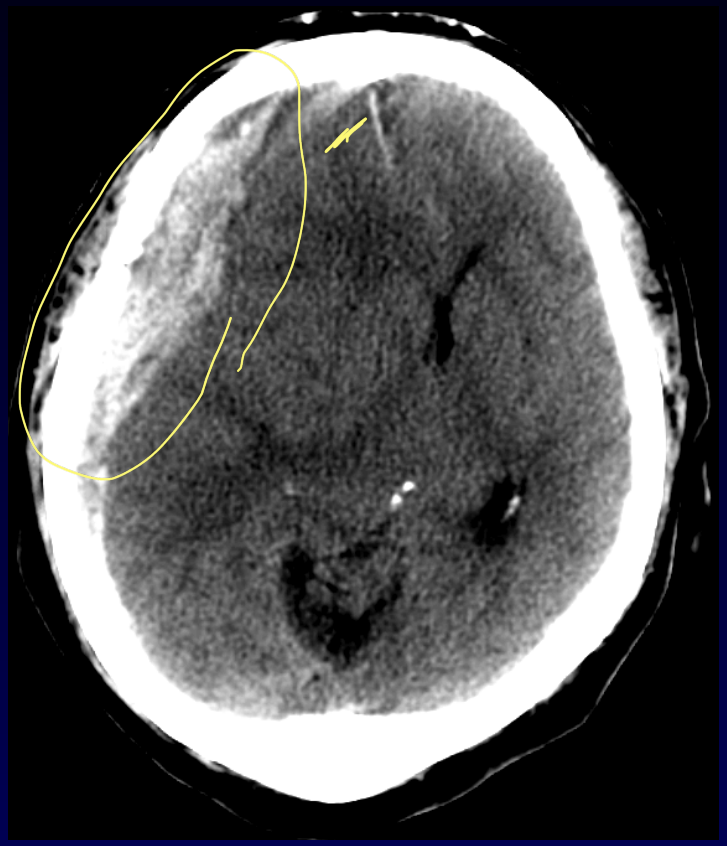





Acute and Chronic Subdural Hematoma

- Patient may be asymptomatic until the event leading to the acute component
- Chronic component can be drained using a bedside burr hole device such as the Subdural Evacuation Port System (SEPS)



http://www.hakeem-sy.com/main/files/subdural%20hematoma.jpg, accessed on 3/31/10

ICH: Sites of Spontaneous ICH



A) Lobar Subcortical Hemorrhage (~20-30%)

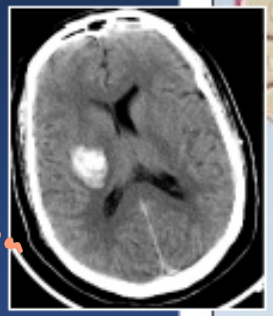

B) Putaminal Hemorrhage (~40-50%)

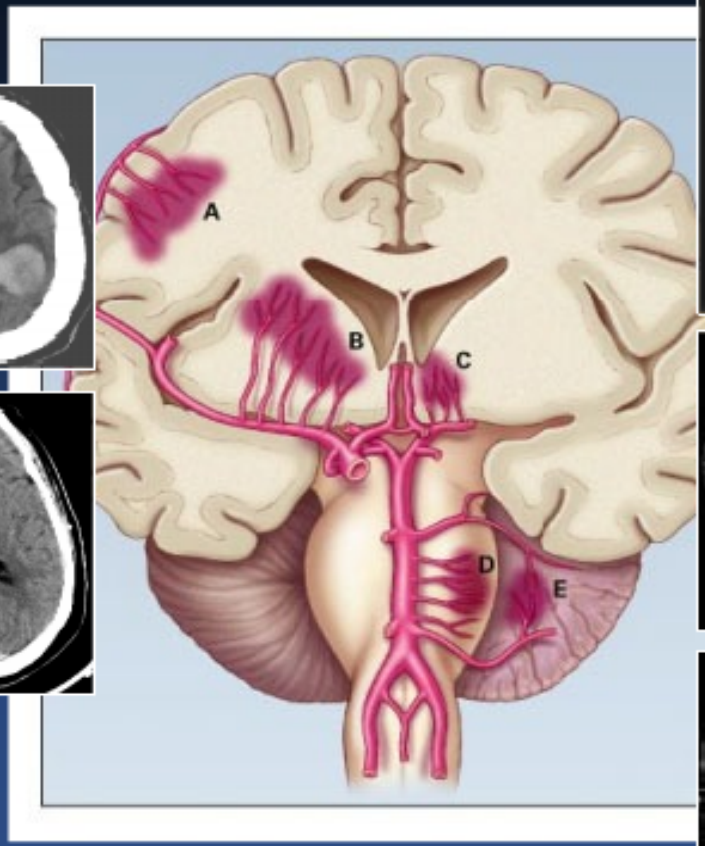



C) Thalamic Hemorrhage (~20-30%)



D) Pontine Hemorrhage (~8%)



E) Cerebellar Hemorrhage (~8%)

Mayer SA, Rincon F. *Lancet Neurol.* 2005;4:662-672.
Qureshi AI, et al. *N Engl J Med.* 2001;344:1450-1460.
Terayama Y, et al. Stroke. 1997;28:1185-1188.

NSA

CT Angiography "Spot Sign" Predicts Hematoma Expansion in Acute Intracerebral Hemorrhage

Ryan Wada, MD; Richard I. Aviv, MBChB; Allan J. Fox, MD; Demetrios J. Sahlas, MD; David J. Gladstone, MD; George Tomlinson, PhD; Sean P. Symons, MD

- source of on going bleeding ← يتكون منه ← (٢) بكبوت بشرية ← في في نقطة صغيرة

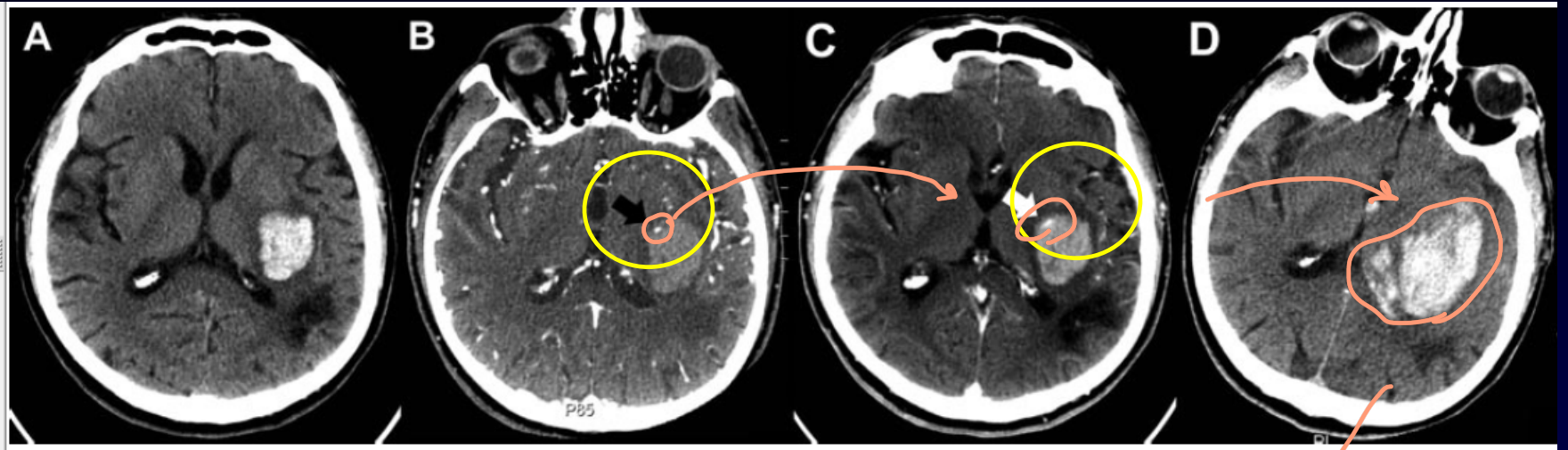

Figure 1. Patient with spot sign, demonstrating extravasation and hematoma expansion. CT slice selection has been optimized for hematoma configuration, not for head position. A, Unenhanced CT demonstrates left posterior putaminal and internal capsule hematoma with mild surrounding edema. An old parieto-occipital infarct is seen posterior to this. B, A small focus of enhancement is seen peripherally on CTA source images, consistent with the spot sign (black arrow). C, Postcontrast CT demonstrates enlargement of the spot sign, consistent with extravasation (white arrow). D, Unenhanced CT image 1 day after presentation reveals hematoma enlargement and intraventricular hemorrhage.

BP control ← Fluid ← conservative علاجه بس بنمشي

- Thrombosis لأنه ← لا نعطي ← Thrombolytic agents ← بالنسبة لـ brain infarction

(*Stroke*. 2007;38:1257-1262.)

Calculating the ICH Volume



ICH volume on CT
can be estimated by

$$\frac{A \times B \times C}{2}$$

Select CT slice with largest ICH
A = longest axis (cm)
B = longest axis perpendicular to A (cm)
C = no. of slices x slice thickness (cm)

Estimated spheroid volume
correlates well with planimetric
CT analysis

For standard :0.5 cm slices $\frac{A \times B \times C}{4}$

Kothari RU, et al. *Stroke*. 1996;27:1304-1305.

Predictor of Outcome

ICH Volume

Ping-pong ball
28.0 cm^3



Golf ball
40.8 cm^3



ICH (N=188)	→	Overall mortality 44%
0-29 cm^3 and GCS ≥9	→	Mortality 19%
30-60 cm^3	→	Mortality 46%-74%
≥60 cm^3 and GCS ≤8	→	Mortality 91%

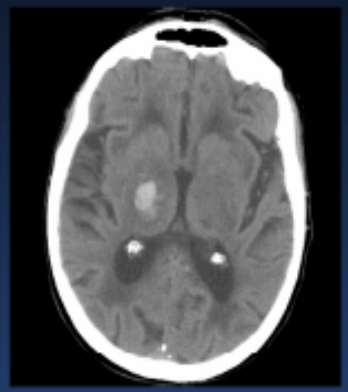



Only 1 of 71 patients with ICH volume ≥30 cm^3 functioned independently at 30 days

Broderick JP, et al. *Stroke*. 1993;24:987-993.

OU Neurology

Traumatic Intracerebral hemorrhage

- Occurs at the time of impact
- Diffuse axonal injury
- Inertial forces cause deformation of the white matter, aka shear injuries
- Most commonly leads to acute coma
- CT (not very sensitive) may reveal petechial hemorrhages in the central 1/3 of the brain (subcortical white matter, corpus collosum, basal ganglia, brainstem, cerebellum)
- MRI to evaluate extent of injury



Gennarelli, et al J. Trauma 1994

OU Neurology

Traumatic Intracerebral hemorrhage

- Focal parenchymal contusions
  - Coup, contra coup, intermediate coup
  - CT: hemorrhagic core surrounded by low density edema
  - Variable CBF in and around contusion

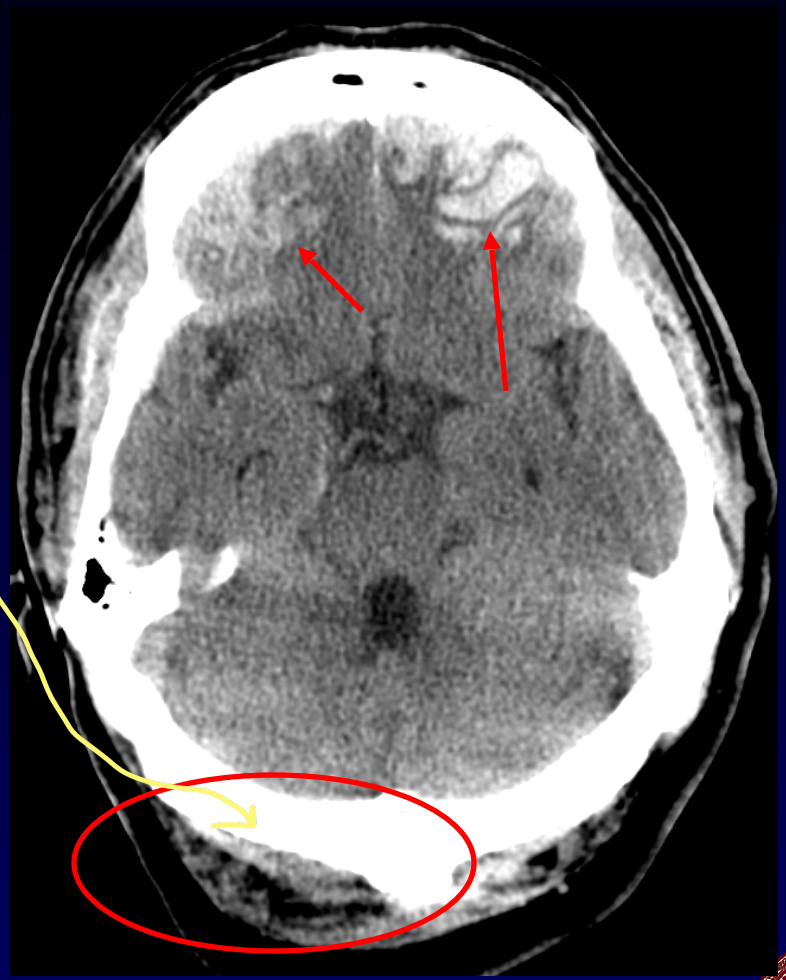

Intraventricular Hemorrhage

- Variety of etiologies
  - Anticoagulation
  - Hypertension MCC.
  - Aneurysm
  - Substance abuse
  - Trauma (less likely)
- Often will need an external ventricular drain with or without intraventricular tPA



http://www.bing.com/image, accessed 6/12/14

Subarachnoid Hemorrhage

- Always exclude an aneurysm even when head trauma is obvious
- Aneurysmal SAH has a poorer prognosis than traumatic subarachnoid hemorrhage
- Traumatic subarachnoid hemorrhage
  - Serially monitor the patient clinically
  - Rarely required surgical intervention
  - Usually has a good prognosis

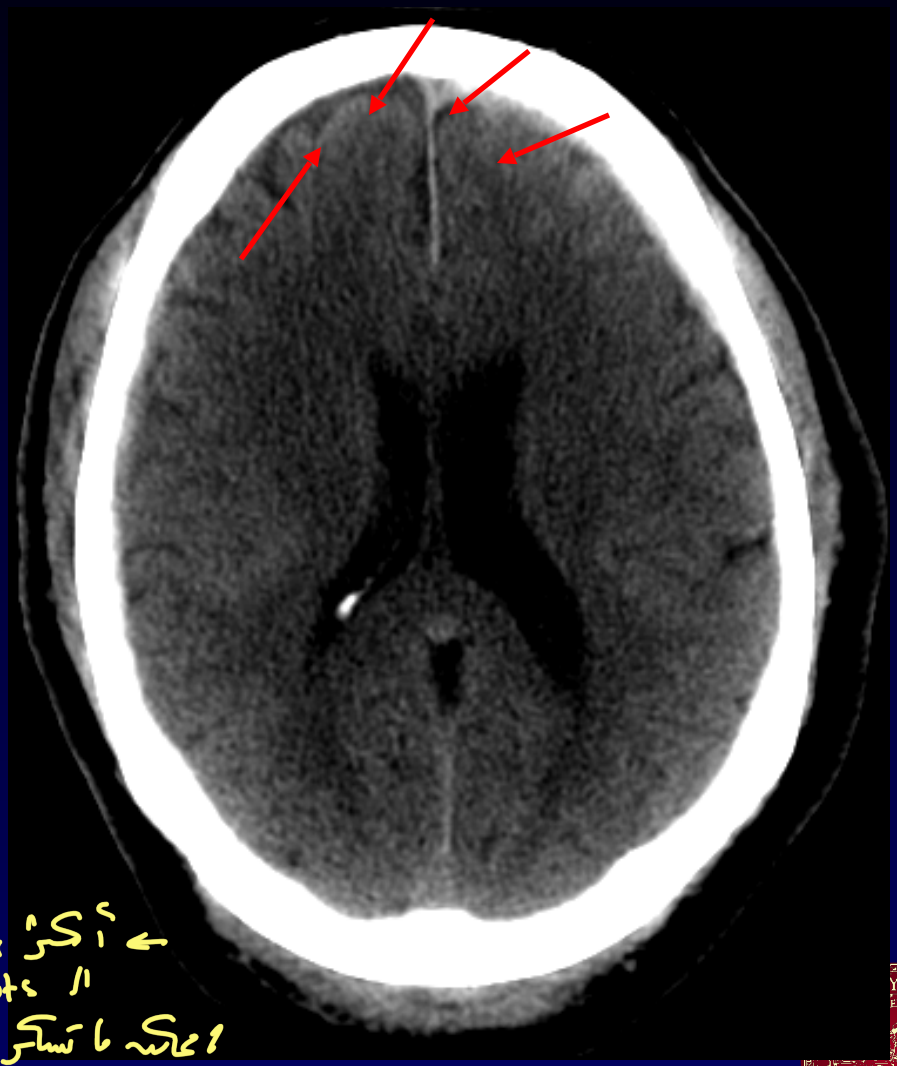

OU Neurology

Practice Reading CT scans-ABBBC
Brain tissue

In 1st few hours to day, .A CT usually normal (though may show blurring of gray-white junction & sulcal effacement as seen on next slide)

By day 2, CT shows .B dark area with mass effect (compression of surrounding structures)

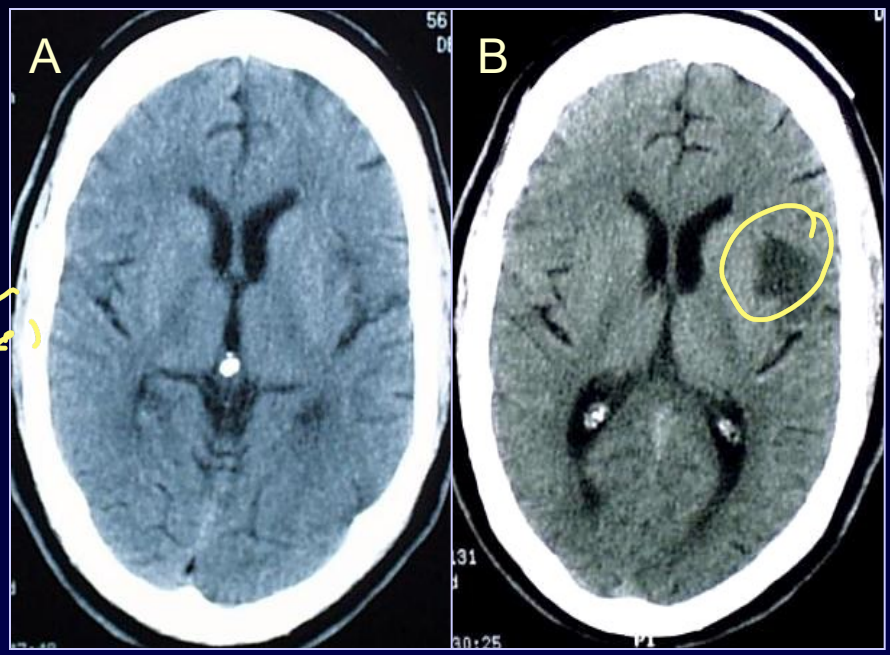

Day 1
Acute infarction

Day 3
Subacute infarction

OU Neurology

Herniation Syndromes

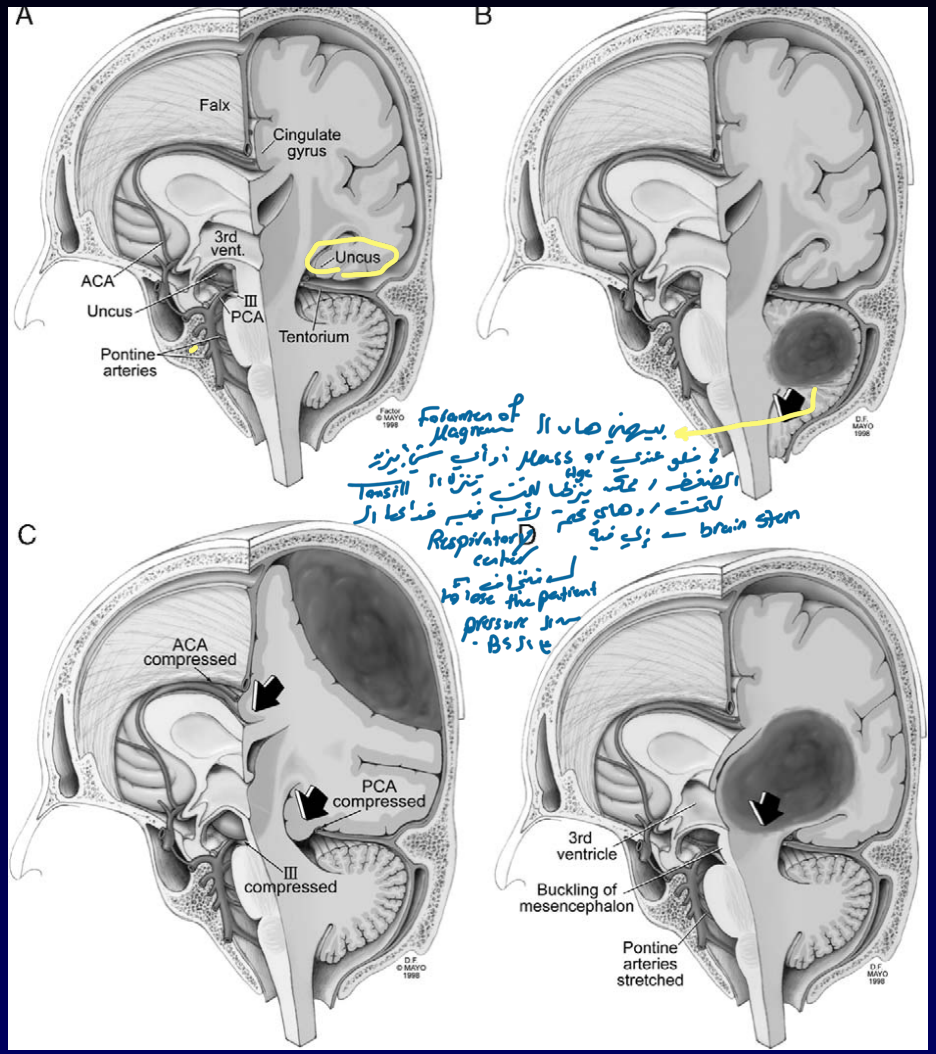

Figure 1. A, Normal anatomy; B, ;tonsillar herniation
C, uncal and subfalcine herniation; and
.D, central herniation

By permission of Mayo Foundation for Medical Education and Research. All rights reserved. Catastrophic Neurologic Disorders in the Emergency Department. 2nd ed. :New York
Oxford University Press; .2004:67–69

Practice Reading CT scans-ABBBC
Air filled structures

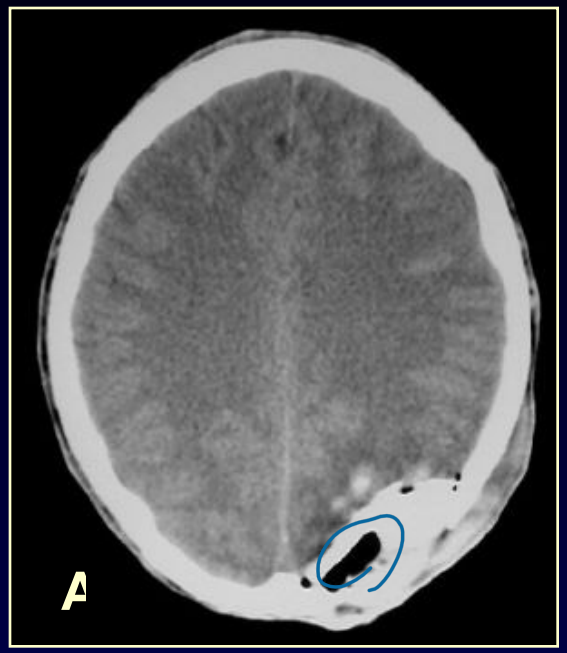

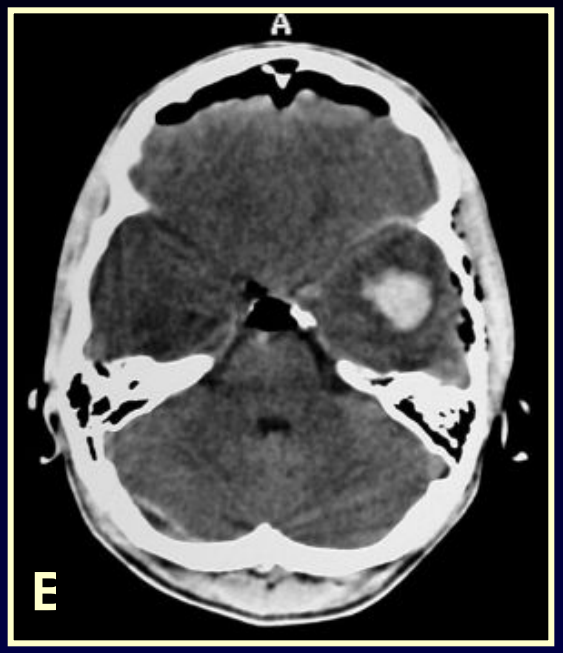

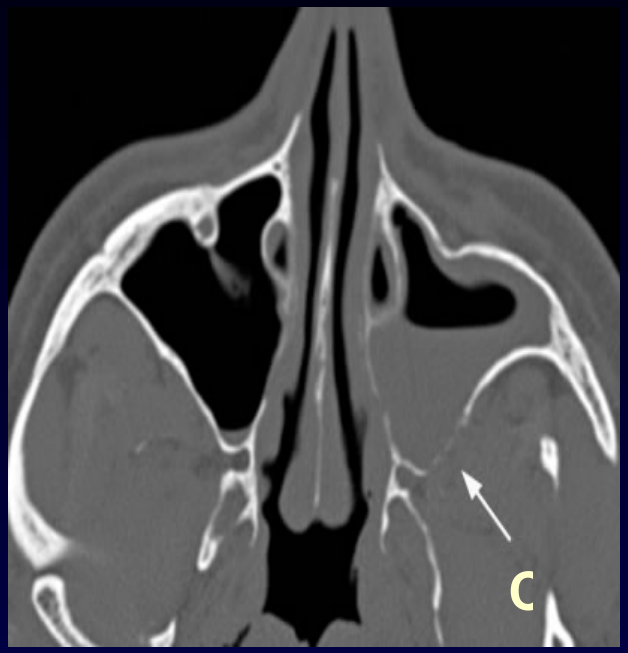

A: Left parietoocipital pneumocephalus post-op

B: Left temporal ICH

C: Left sinus air fluid level with associated sinus fracture

Thank you