- CT is the best measure in acute conditions.
MRI isn't an option for emergency → takes time in scanning & interpretation.

⇓

ضد = (claustrophobia) يعني عنده claustrophobia : unfit for MRI & emergency : ما عنده وقت

يعني ما عنده وقت يضل جوا الجهاز.

⇒ That's why CT is the first choice in emergency of (GI / chest / Abdomen / Brain / Spine).

MRI Brain

(emergency في MRI ما بنعمل)

(emergency لأنه بياخد وقت) ⇐ في حالات طارئة بنستخدم CT

⇒ MRI isn't needed for ischemia regularly → once CT is normal + Clinical findings

= CVA

→ Goal of CT is to exclude hg, not to detect ischemia / infarction.

⇒ once I saw infarction on CT, everything is finished & managment is pliable

but if CT was normal ⇒ This is the Pt I wish to select to see in my emergency (My target)

e.g. hg CI to give thrombolysis or anticoagulant in acute phase ← else if CT is infarction

I can manage the Pt if CT is normal ← target of CT

by

giving thrombolytics as tPA

OR streptokinase

50-60 mins

available OTC

→ Evaluation of stroke pt is 90% dependent on clinician → stroke مثل الجلطة، streptokinase

(normal ECG ٪٨) stroke

drug overuse - migraine

(its symptoms mimics CVA)

⇒ so if CT is negative ⇒ start management immediately if you have clinical evidence that this is CVA, with tPA loading dose or by thrombectomy of CVA.

infarction ٪٥ bleeding

start ttx

⇒ The time from presentation to time of management with streptokinase should be < 20, 45 mins

we never get PT completely resolved

if so this is not CVA, it's TIA

⇒ symptoms of CVA ⇒ weakness / paralysis / slurred speech

⇒ so stroke doesn't appear initially on CT

⇒ Encephalitis also doesn't appear on CT, appears on MRI, mimics stroke.

(negative CT doesn't exclude diagnosis) ، MRI لتأكيد ، CT بنبتشي بـ

⇒ Encephalitis = inflam of brain ID2 → bacterial
Viral
Autoimmune as (SLE / Behcet d2)

⇒ by definition, most of rheumatological diseases can involve CNS.

In ⇒ Viral / Bacterial encephalitis ⇒ بنعمل lp و بنجيب CSF
MRI

⇒ Tumors appear on CT

⇐ كل الأورام بتظهر على CT (لو كانت كبيرة وعندها تأثير) بس الأول بنبدأ بـ MRI عشان نستبعد أي space occupying lesion.
to exclude space occupying lesion.

⇒ SOL in space occupy lesion → order CT → لو موجود هيبين
↳ لو مش موجود ← SOL

⇐ There are basic sequences (T1, T2)

T1 ↓ fluid - بيبقى أسود/gray
بيبقى anatomy أكتر

T2 ↓ fluid بيبقى أبيض
بيبقى pathology أكتر
(زي edema بيبقى)
sensitive for fluid

MRI Sequences

- T1 and T2 weighted sequences:

- On T1: white matter appears white & grey matter appears grey & CSF is black
- On T2: It is the opposite. CSF is hyperintense, thalamus is darker than the corpus striatum (putamen & caudate) which are darker than cortical grey

→ White matter is composed of axons (myelin sheath = fat)

في T2 و T1 بيبقى

T1 بيبقى

T1 في W.M بيبقى

بيبقى T2 بسبب الـ fat بيبقى أقل

← في الـ abd./brain MRI الـ fluid لونه أسود: T2 و T1 في كل

fluid → if white → T2

→ Fluid is present in ventricles / CSF spaces / around S.C. / inside stomach / UB

(T2_weighted دلوقتي بيضا ازاي)
image

⇒ Anatomy in MRI is much clearer
(تشريح الأنسجة جيدة)

Examples of T1 and T2 images

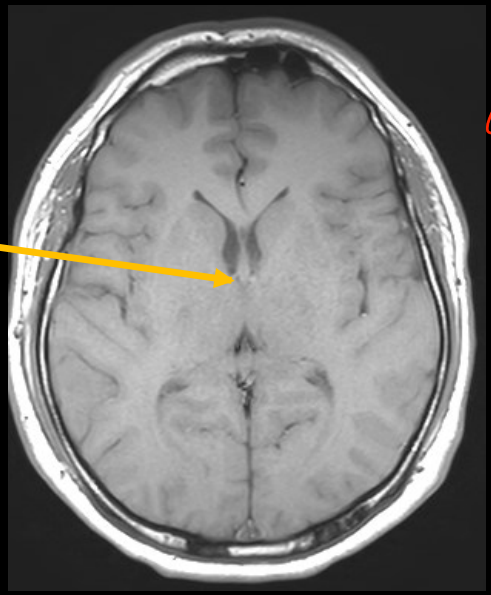

Foramen of Monro

T 1 weighted

- Fluid is grey / black

Globus Pallidus

Putamen

Lentiform Nucleus

Thalamus

- ant. & post. limbs of I.C

- amygdala

- Posterior corpus callosum.

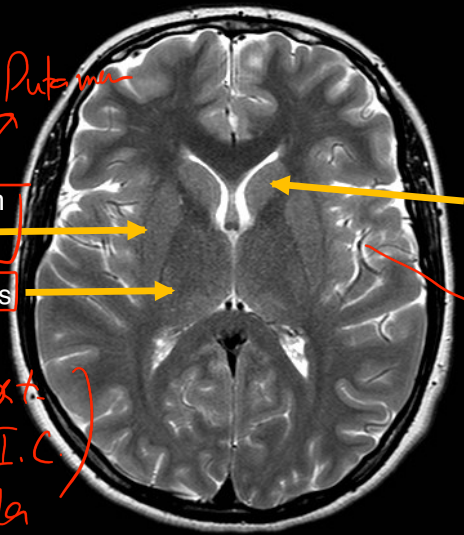

Head of Caudate Nucleus

Insula of temporal lobe.

T2 weighted

- Fluid is white

- whiter W.M (أكثر بياضاً)
- anatomy is clear

- W.M is grey /black

= High signal

T1 hyperintense (bright) lesions i.e. short T1 lesions

الأجسام اللي بتبين بيضا في T1

1. High protein: e.g. Rathke cleft cyst
2. Mineralization
3. Fat & cholesterol
4. Subacute hemorrhage (Meth Hb)
5. Subacute thrombus
6. Manganese (e.g. in striatum in liver disease)
7. Melanin

1 Calcification / Mineralization

Mineralized / ionized Ca^{+2} بيبين

dense calcification بيبين

2 Subs. by (Meth Hb)
- iron -

T1 hypointense (dark) lesions i.e. lesions with T1 prolongation:

1. CSF
2. Edema
3. Chronic hemorrhage (ferritin accumulates → low signal (dark))
4. Air → black in T1 & T2
5. flow in blood vessels → black in T1 & T2
6. Low protein

⇒ in CT, white is either → blood
→ calcification
→ bone

⇒ but in MRI → الأشياء مختلفة بتغير
عشان توضح صح وتكون
واضحة، منها الأنسجة العضلية.
fluid
بتغير حاجات تضعف اللي عملتها في CT
عالريتيه؛ لأنها 2 different modalities.

- بتغير عشان فيه حاجة بيضا جدا وحاجة التغير تبعا اتجاه الـphase أضوء، بيخلي الصورة معقدة.

so MRI is more complicated than CT.

it's not always the نفس T2 & T1 بتشبه بعض
في بعض الحالات الأشياء

care,

& there are some variables in the same study.

يعني عندك نفس الصورة تشوف فيها blood وفيها grey - وفيها pt ونفس الصورة.

هاي T1 بتبين subs. hg / fluid ← General principles بس

T2 hyperintense (bright) lesions i.e. long T2

- Sensitive for many pathologies, edema or gliosis
- Edema
- Gliosis
- CSF

low signal

T2 hypointense (dark) lesions i.e. short T2

1. Calcification (dense → black in T1 & T2) (not mineralized / ionized calcification)
2. Air
3. Fibrous tissue → (black in T1 & T2)
4. Acute hemorrhage
5. Very chronic hemorrhage (hemosiderin) → (black in T1 & T2)
6. High protein
7. Calcium
8. flow in blood vessels → (appears black as it's flowing → no magnetisation)
9. Metal

. الأكثر sensitive لعمل MRI بكون عندها أي حاجة فيها حديد ← تكون غامقة

. الجيرالي فيها حديد بتبين بيضا ~ (80%)

FLAIR (fluid-attenuated inversion recovery)

↳ (simply is T2 bomb with fluid attenuated.)

cyst / cavity هما اللي فيهم fluid بشكل طبيعي فلما اللي موجود CSF / arachnoid / ventricles spaces cyst

- Sensitive but not specific
- a type of T2 but CSF is black.
- FLAIR: Helps identify pathologies. shows areas next to CSF (periventricular) very well. Also good for juxtacortical areas.
- Inferior quality to other sequences in posterior fossa and spinal cord.

بشكل edema بشكل sequence هذا كويس جداً بشكل عام بشكل fluid بشكل physiologic fluid

→ What appears high intensity in T2 signal → appears high intensity also in FLAIR (as it's a T2 but with fluid substraction).

→ There's also a fat substraction → عايزين عنى fat زايدة سالازم، عملياً، نشوف pathology واضحة، وهنا بستخدم صورة Post contrast عشان fat أبيض، MRI contrast برضو أبيض، فأبيض أبيض بتروح الصورة، فالكود بروح يجيب ال fat، فبيبقى contrast طالع.

FLAIR

- Helps differentiate VR space from Lacunar infarct
- Causes of FLAIR hyperintensity in sulci :-
  1. SAH
  2. High protein (meningitis, neoplastic)
  3. High oxygen tension (intubation & ventilation)
  4. Artifact.

FLAIR image

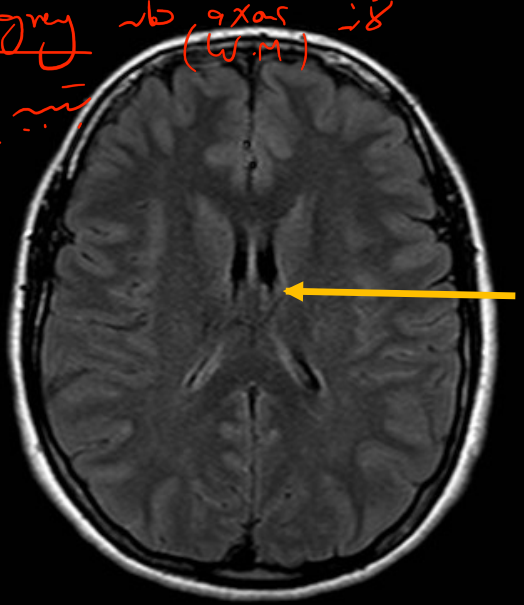

Suppression
Of normal
fluid in
Ventricles & sulci

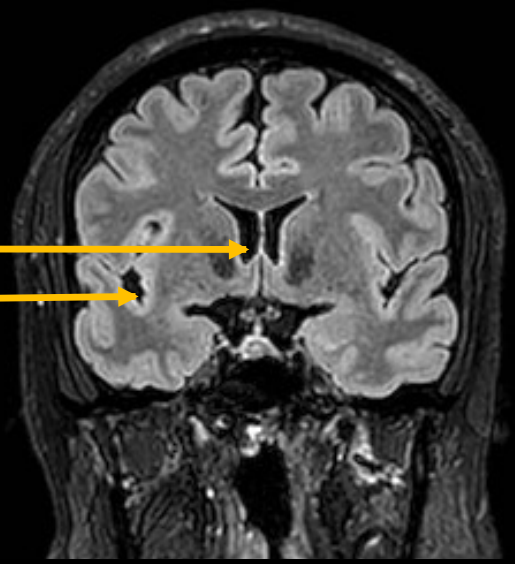

Diffusion weighted imaging

- Diffusion imaging uses diffusion of water molecules. Calculates apparent diffusion coefficient ADC that can be displayed on a separate scan.
- Detects changes in local deoxy- and oxy-hemoglobin ratios, helps localize cognitive (including language) & other functions

Apparent diffusion coefficient, ADC:

- Decreased in cytotoxic edema i.e. opposite to diffusion i.e. true DW restriction i.e. infarct or abscess.
- Increased from a T2 effect 'T2 shine-through' i.e. same as diffusion.
- Restricted diffusion= high signal on DWI & low signal on ADC

سنة diffusion حتى وجود لها (10-20 سنة)

one of the most important advances in MRI is DWI.

يعني ما تطور طبي عظيم بسببها.

molecules inside structure & water it's free or not

يعني الجهاز يعمل خلال gradient ويعمل إزاي بحيث يكشف بحيلي حركة السوائل (Pushed) between structures.

2 different cells from different tissues as (Grey & white matter)

يعني خلايا مختلفة من أنسجة مختلفة والتي هم سوائل.

communications between cells occur by pumps / diffusion

خلايا بحيث حركة السوائل الطبيعية بحيث sequence بحيث حركة السوائل الطبيعية والتانية، فلو كان في healthy normal brain tissue & tumor tissue

حاجي بحيلي حركة السوائل اللي تتكون من

tumor tissue → الخلايا حوا

benign or malignant tumor ← وبناءً عليه بيقدر يحدد الورم

& grade of malignancy (high / low malignant potential)

Advance of this sequence (how it's basic sequence) → is that it determines characterization of the lesion & diffusion tensor imaging (Tractography)

↓

(as spinothalamic tract) ← ascending & descending pathways اللي بتمشي

(كالحبل الشوكي مثلاً) (أو العكس) بتكون بالظهر

des. pat ، المريض MRI

. S.C. ك brain نازلين

new advances in وكمان medicine

كيف بيشتغل دلوقتي؟

→ brain cells communicate with each other & with S.C through axons

↓

diffusion of molecules inside axons & electrical signals have a specific direction

delineation يعني بيتحدد بالظبط

ايه الطريقة اللي؟

communicate by 2 cerebral hemispheres in corpus callosum

& from brain to S.C.

tracts

طريقة الـ diffusion

خال Tract ك compression ك tractography ك بالتأكيد learn

بجنب أو لورا ـه فايكون الخلل حاصل بطرق axis تكمن وسطيين

↓

to avoid important tracts

ويضل بعيد عنى

to avoid complications

ك بتعقيدات ويصل

Catastrophic consequences to the Pt

they never knew if tumor was سكانوا زمله يشتغلوا الأناتومي بس

affecty / displacing it or not

. tracts بين ك D.W.I ك تأكيد بدال

Images of DWI and ADC

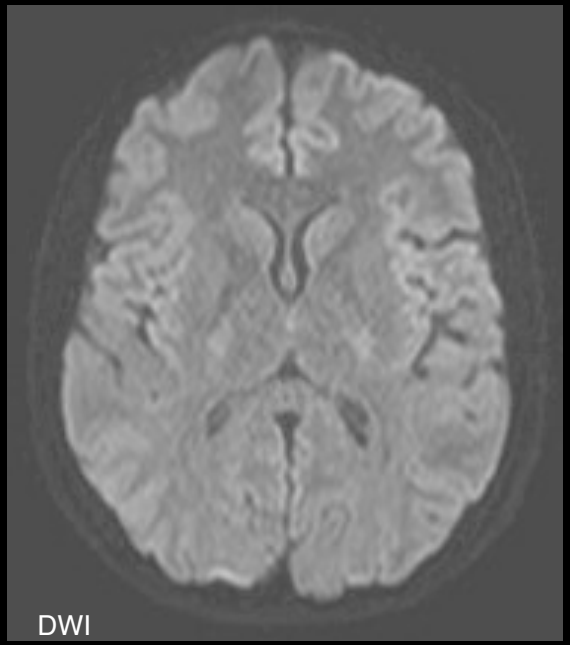

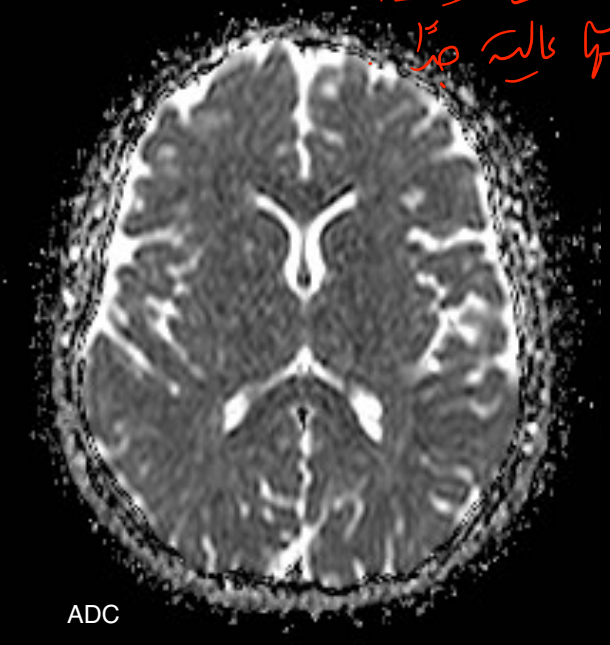

Increased DWI seen in

- acute ischemic stroke

Important to evaluate for diffusion restriction also in

- encephalitis like herpes
- focal seizure
- Infections (like abscess, CJD)
- Tumors and tumor treatment response (egs like medulloblastoma, epidermoid cyst)
- Asses extent of diffuse axonal injury
- Asses active demyelination

⇒ In acute stroke ⇒ D.W.I are positive during < 10_15 mins.

(٥ إلى ١٥ دقيقة . D.W.I تصوير acute stroke في الـ sequence الأول

⇒ if diffusion was -ve → exclude CUA despite all the clinical data.

حتى لو بالتشخيص السريري ، هنا ← حتى بالغة فلازم .

In vitro study ← كيف قدروا يتأكدوا انه سبب ١٥ دقيقة

أخذوا مخ جاي / قرد / معلبات ، وبقطعة بشروا الشريان ، وبشغلوا قدرة الوقت اللي بياخذ DWI

(في الطب أكاديمية سم تجارب in vitro studies) . true يصير

- research center يعملوها في استخبارات .

GRE & SWI sequences

Detects hemorrhage (hemosiderin) well. Low intensity (called susceptibility artifact or T2* effect).

- Diffuse axonal injury
- Hypertension and amyloidosis
- Multiple cavernomas
- Evaluation of Venous sinus/cortical vein thrombosis.
- Infections

GRE and SWI

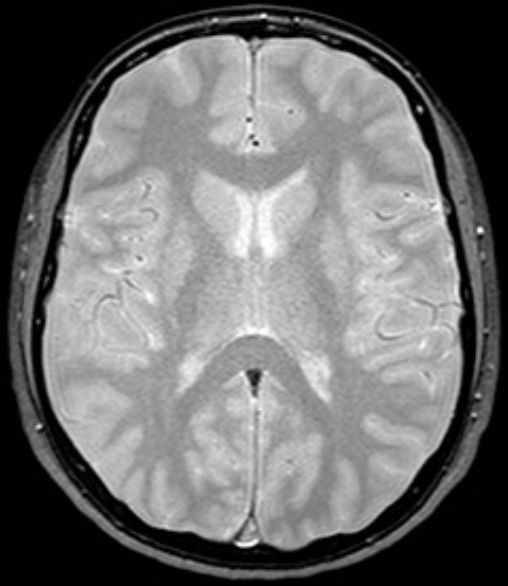

T2 *

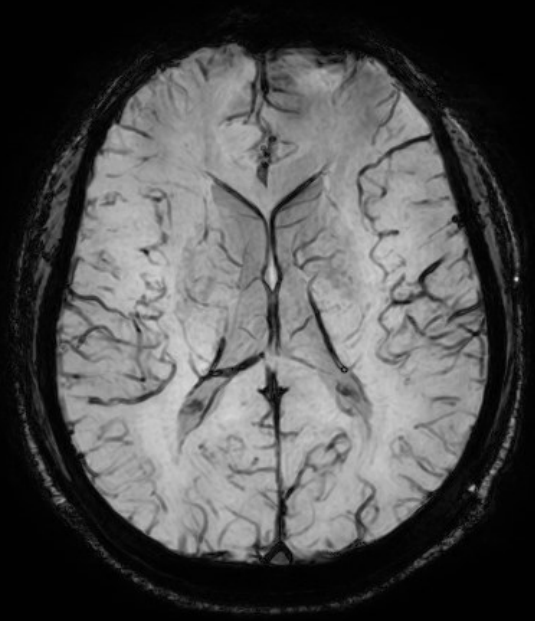

SWI

⟹ Basic sequences are T1 & T2 (أساسيات)

⟹ There are about 35 sequences in MRI

⟹ GRE (gradient sequence) → سريعة sequence → T1 أحسن
أساسيات → T2 resolution

GRE → T2 شبه
spin echo
sequence.

⟹ GRE is sensitive than not to blood products & iron & old blood

Normal structures that enhance on MRI

(physiologic enhancement in MRI) (as phys. calcification in CT)

is normally enhanced – it's not pathology –

Structures outside the blood-brain barrier like

- Dura
- Adenohypophysis and pituitary stalk
- Pineal gland
- Choroid plexus
- Nasal mucosa
- Tuber cinereum
- Area postrema

→ but some structures should never take Kontrast → once it took enhancement there's pathology.

T1 +Gadolinium

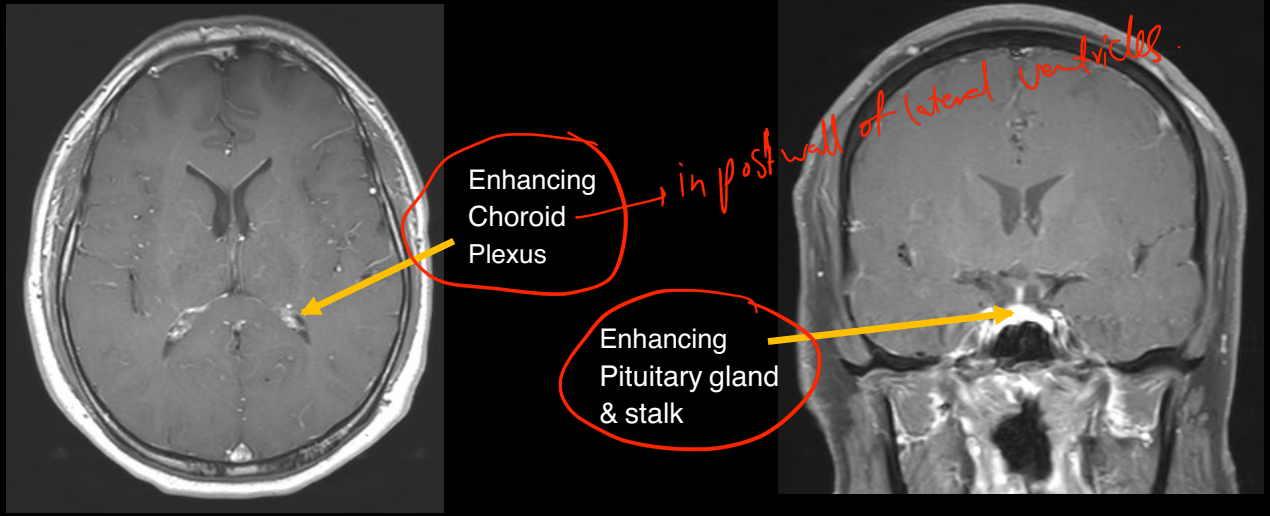

⇒ BBB, usually gadolinium doesn't pass it

⇒ Gadolinium is MRI contrast

⇒ Technicium is used in isotope scan & RAI ($I_{123/132}$)

⇒ Iodine contrast is used in CT/IVU (Iodine based - contrast as Ultravist)

- Disruption of normal blood brain barrier causes enhancement of different lesions on MRI.
- Enhancement may be seen in :
  - Tumors
  - Infections
  - Inflammatory conditions such as active demyelinating lesions
  - Subacute areas of ischemia

Sagittal images

- Scroll and look at midline image (in the mid-sagittal plane) from bottom to top. Then look laterally at the parasagittal planes. Observe the normal and abnormal structures.
- Foramen magnum & base of skull including cerebellar tonsils
- Clivus and nasopharynx
- Fourth ventricle and Cerebellar vermis
- Sella, pituitary & optic chiasm
- Corpus callosum
- Superior sagittal sinus
- Visualized cervical spine

⇒ Sagittal image
Coronal :
axial :
Oblique :

one sequence in MRI every image takes 3 mins.

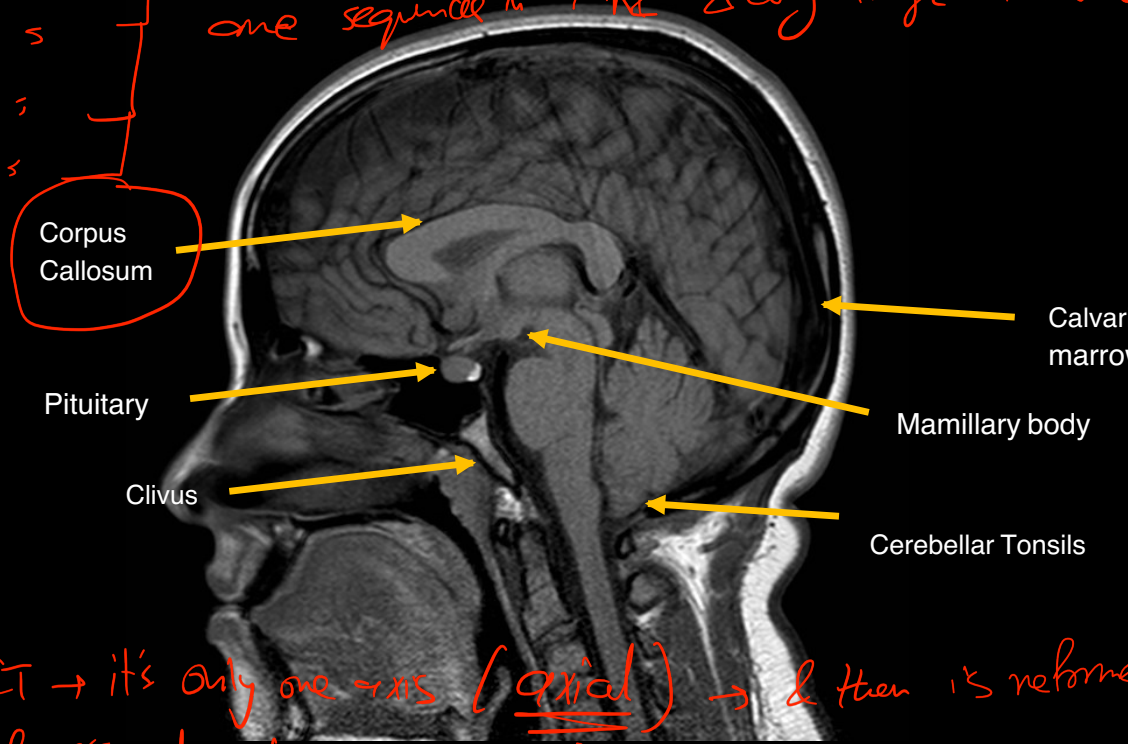

⇒ but in CT → it's only one axis (axial) → & then is reformed into sagittal & coronal (Dr. ميرفالي)

⇒ No coronal & sagittal images in CT (as in MRI).

⇒ If I want to screen elbow/ankle/wrist ⇒ oblique sequence أو reformation في oblique (من ٢٥ - ٤٥°)

- When interpreting the axial images follow a systematic approach. Scroll through the MRI from bottom to top interpreting each of these systems or areas at a time. The CSF system (ventricles, cisterns and sulci), the brain matter (grey matter structures and white matter structures), the vessels and venous sinuses, the meninges and skull and adjacent tissues. And finally the extended search i.e. review areas (paranasal sinuses, orbits, nasal cavity, visualized tongue and face).

Ventricles, cisterns & sulci

- When ventricles, cisterns, fissures or sulci are “squashed” we use the term effaced. When they are large we just describe them as large or enlarged. The different CSF spaces should be interpreted together for example, effaced sulci tell us that the enlarged ventricles likely represent hydrocephalus. Whereas enlarged sulci and enlarged ventricles likely represent brain volume loss

Ventricles:

- Lateral ventricles (frontal, occipital & temporal horns), Third ventricle, fourth ventricle

Cisterns & fissures:

- Quadrigeminal plate cistern, interpeduncular cistern, ambient cistern, suprasellar cistern

Sulci:

- Appearance: effaced, obscured
- Ventriulo-sulcal proportionality

Brain Grey & white matter

- Midline shift
- Grey white differentiation

Structures:

- Caudate nucleus, Internal capsule, Putamen & globus pallidus, thalamus.
- Other structures: centrum semiovale, midbrain, pons, medulla, cerebellum

Vessels: arteries, veins & venous sinuses

- Arteries: basilar, carotid arteries, vertebral artery, middle cerebral arteries

- Venous: Superior sagittal sinus, torcula, transverse sinus, sigmoid sinus, internal jugular vein

Meninges

- Dural involvement/enhancement look at (falx, tentorium, CP angle)
- Leptomeningeal enhancement look at (basal cisterns, cerebellar folia, sulcal perivascular spaces)

Extra axial lesions

T2 → white fluid

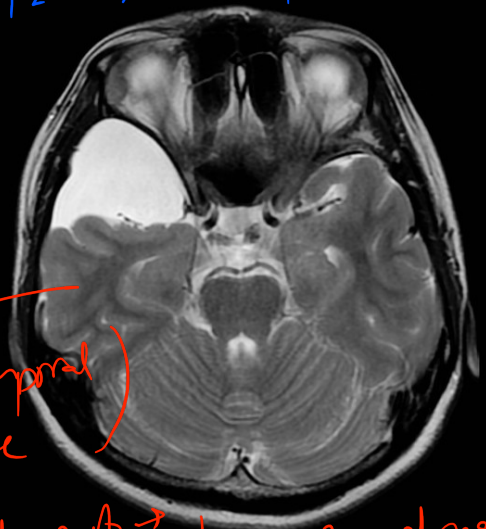

(Rt temporal lobe)

↓ CSF part → brain parenchyma is lost (replaced by subarach. cyst).

Subarachnoid cyst

(T1) → black CSF

→ white grey matter. (not FLAIR).

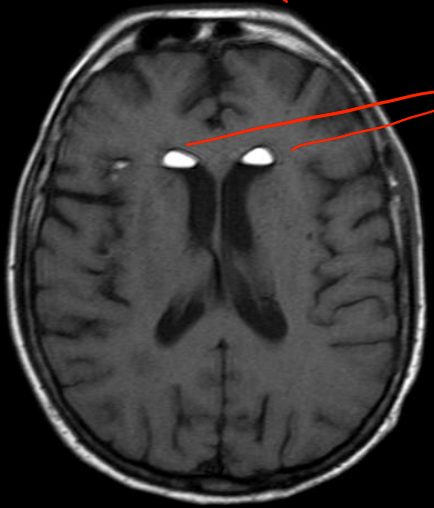

ventricles

Calcification

blood ، Fat

dermoid cyst → can rupture

→ (contains teeth / hair)

very common in ovaries / mediastinum / brain

abnormal ← في اختلاف ← كل الحيوانات، عكس الحيوانات ← brain MRI ← دايمًا في ال

⇒ Symmetrical is mandatory in many organs as → Brain
                                                → Neck
                                                → limbs

⇒ Chest / Abd. symmetricity isn't mandatory.

⇒ Cyst (by definition) is a benign pathology → ممكن (kidney / liver / brain)

- sometimes symptomatic or asymptomatic بالحالات
- mostly it's incidental finding (صدفة)

headache / epilepsy عشان هيك

not related وبعض الحالات بكون -

⇐ هنا dermoid cyst، نزلت لكت بسبب الكتافة؛ لأن dermoid cyst بطلع الدهون fat
is fat

عن fluid، بينما blood الإيزل لكت، بشوفيه فيها عبطاط البيض dermoid cyst
& not blood.

بعدما نشوف باقي sequences (تتابعاتها في) بناظر كافيزا، الـ blood بتبدأ تتحلل بترا أتحلل بتنزل
hemosiderin

كتبنا fat بطلع الدهون.
dermoid cyst

Post-contrast

T1 → black CSF

↳ بيضا عشان بسبب contrast



Vestibular schwannomas

well defined mass in the Rt side compressing the brain (obvious عشان واضح)

esp. compressing brainstem & middle cerebellar peduncle & is extending into internal auditory canal (ice cream - corn appearance).

it's a benign tumor but difficult to manage
petrous bone -

[pathognomic for acoustic / vestibular schwannoma]

cause tinnitus / headache / vertigo

it's dangerous surgery despite benign pathology.

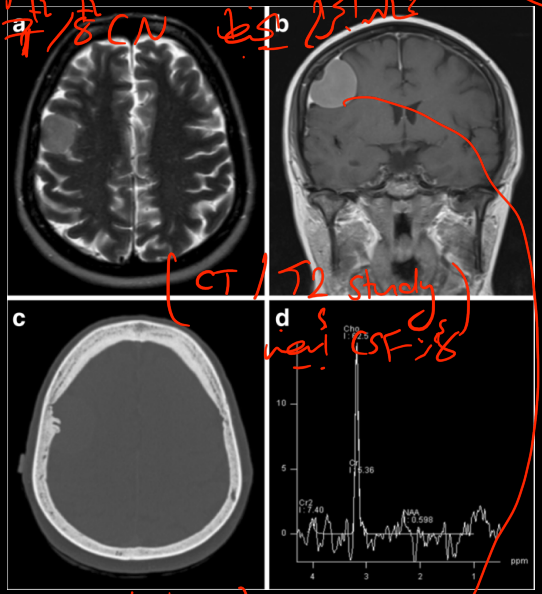

CT / T2 study

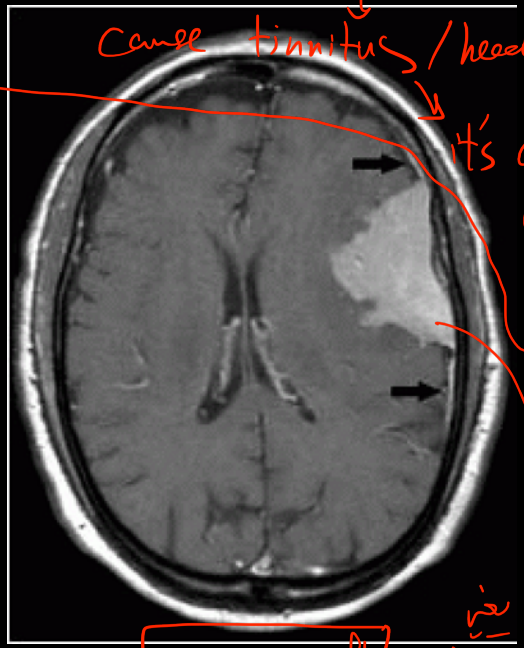

meningioma after enhancing

midline shift

midline shift

(mass effect

Rt side ventricles ضغطة عليها ، طبعا

& septum pellucidum

mass effect يعني في

brain مركز الـ ضغطة عليها

dural tail ⟹ dura في enhanced بتأخذ lesion في

= (dural lesion, attached to dura matter, compressing the brain)

by definition it's meningioma.

typical meningioma is well defined & homogenous & benign lesion.
(90%)

Common Intra-Axial Tumors in Pediatric

Supratentorial:

1. Astrocytoma
2. Pleomorphic xanthoastro (PXA)
3. PNET
4. DNET
5. Ganglioglioma

Infratentorial:

1. Juvenile Pilocytic Astrocytoma
2. PNET (Medulloblastoma)
3. Ependymoma
4. Brainstem Astrocytoma

⇒ NO mets in pediatrics, while it's the mc tumor in adults.

Common Intra-Axial Tumors in Adult

Supratentorial:

1. **Metastases ++** (mc)
2. Gliomas (25%)
   - Fibrillary Astrocytoma
   - Anaplastic Astrocytoma
   - Glioblastoma Multiformi
   - Oligodendroglioma

Infratentorial:

1. **Metastases ++++** (mc)
2. Hemangioblastoma

(mets supra – ✓✓)

very rare to see primary tumor but if so → ✓ hemangioblastoma.

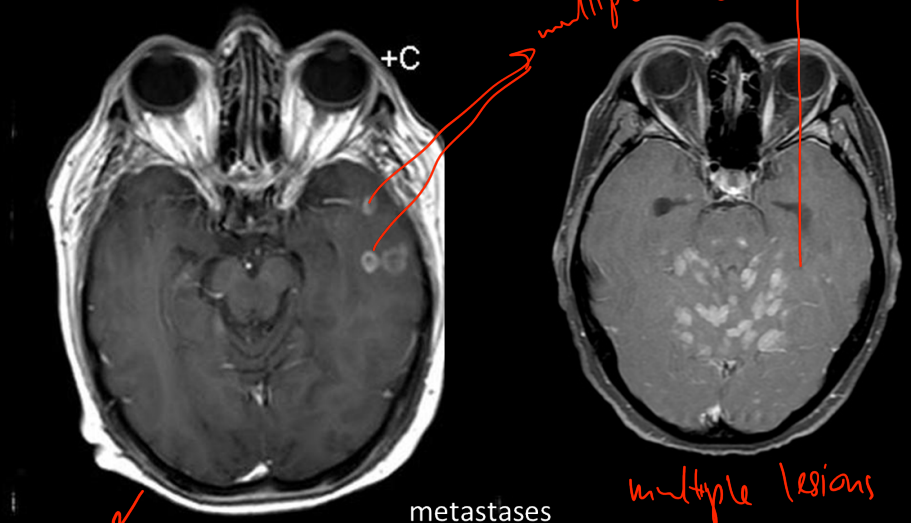

multiple ring enhancement → mets.

metastases

multiple lesions

Post contrast study

90% mets ← multiple lesions في أكثر من مكان in brain

⟹ common is common & rare manifestations of uncommon dz is impossible.

[- it's not - الحالة typical appearance ؛ يعني، uncommon بتبقى uncommon -].

(meningioma مثلاً) brain صابحه جيا

(& acoustic schwannoma)

compression & midline shift & mass effect

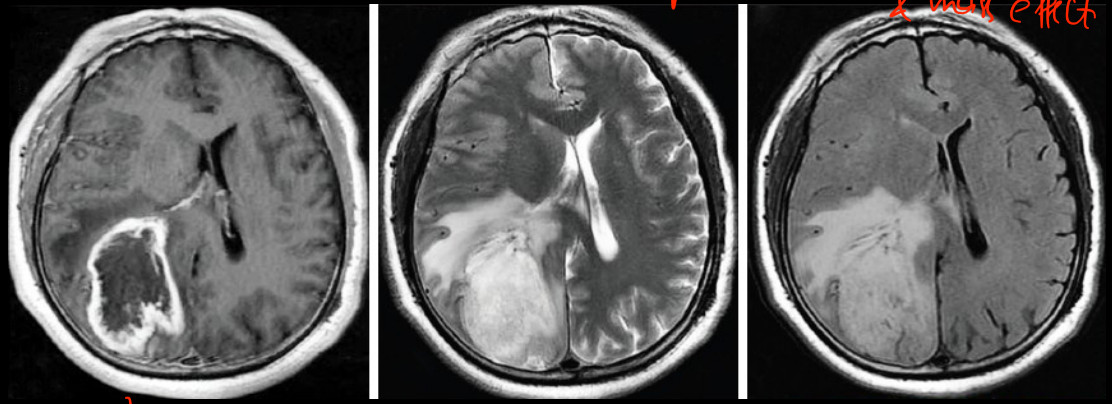

Post contrast

enhancement rim in the center due to necrosis

(bad prognostic sign)

FLAIR

astrocytoma

الكيس بيكون CSF او fluid

زائد pathology فيه cells في fluid

T2

→ cyst is good prognostic sign

→ if tumor contains cyst (as astrocytoma)

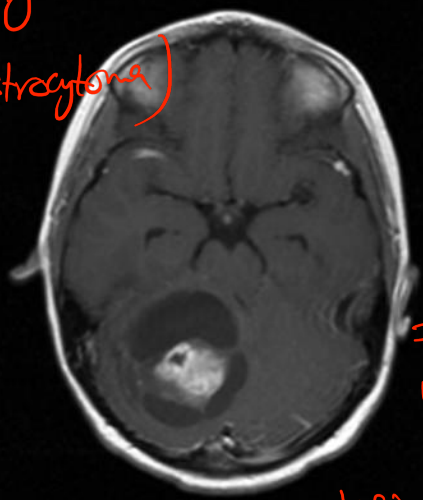

necrosis
↓
irregular
↓
bad sign
= high grade
malignancy
↓
lesion ... irregular

Cyst
↓
good sign
= low grade
brain tumor

(as Pilocytic
astrocytoma
↓
lesion ... well
defined, regular,

Pilocytic astrocytoma in Pediatric Pt

[multilobulated irregular ... tumor ... cyst]

→ this is a good prognostic sign

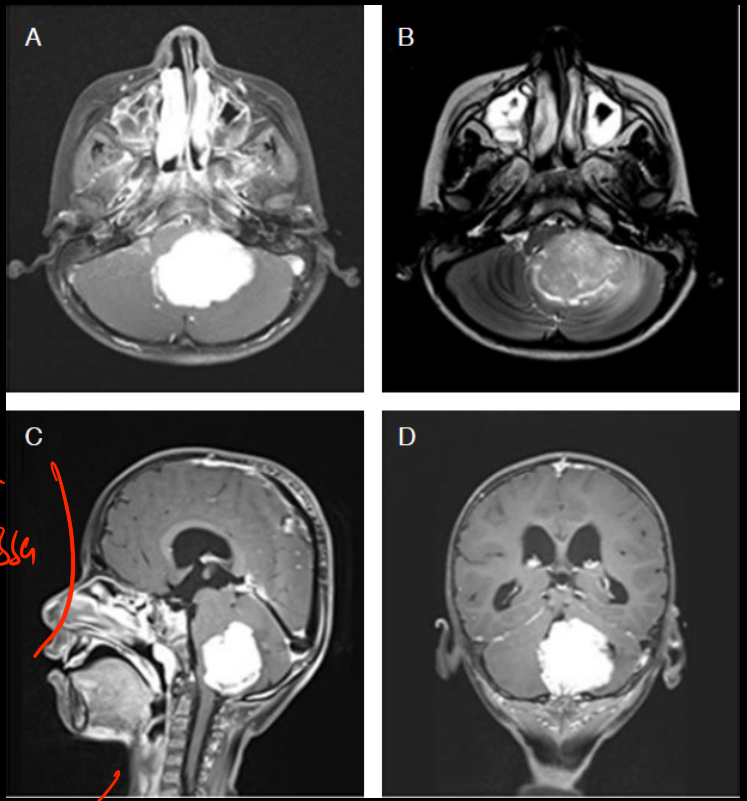

meduloblastoma

one of the common tumors in Post. Fossa in 4th ventricle.

Saggital sequence T1 as CSF is black / with contrast

T1 بعطي
بيضة
ال
فتصبح
white contrast.

Extended search

Lesion inside 4th ventricle + typical of Medulloblastoma.

- Sella, pituitary & optic chiasm
- Paranasal sinuses (ethmoidal, sphenoid, frontal, mastoid), temporal bone/ears
- Orbits
- Nasopharynx, Oropharynx

Ependymoma & Medulloblastoma is the first DDx in infratentorical tumors in Pediatrics (inside 4th Ventricle).