1. Position & Anatomy



2. Technique

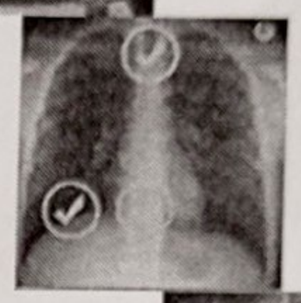

3. Reading System

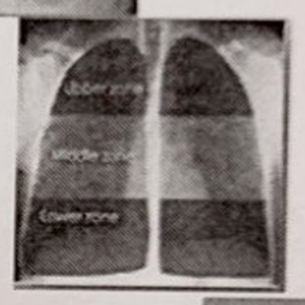

4. Hidden Areas

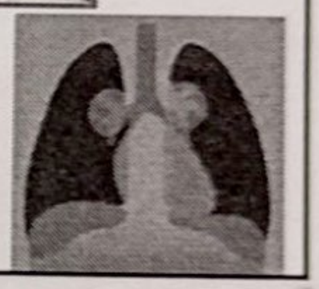

POSITION

SHOT ON POCO X3

Scanned with CamScanner

28/07/1444

1

PAview

[Most Common postural] 80%

uncooperative patient → (trauma / ICU)

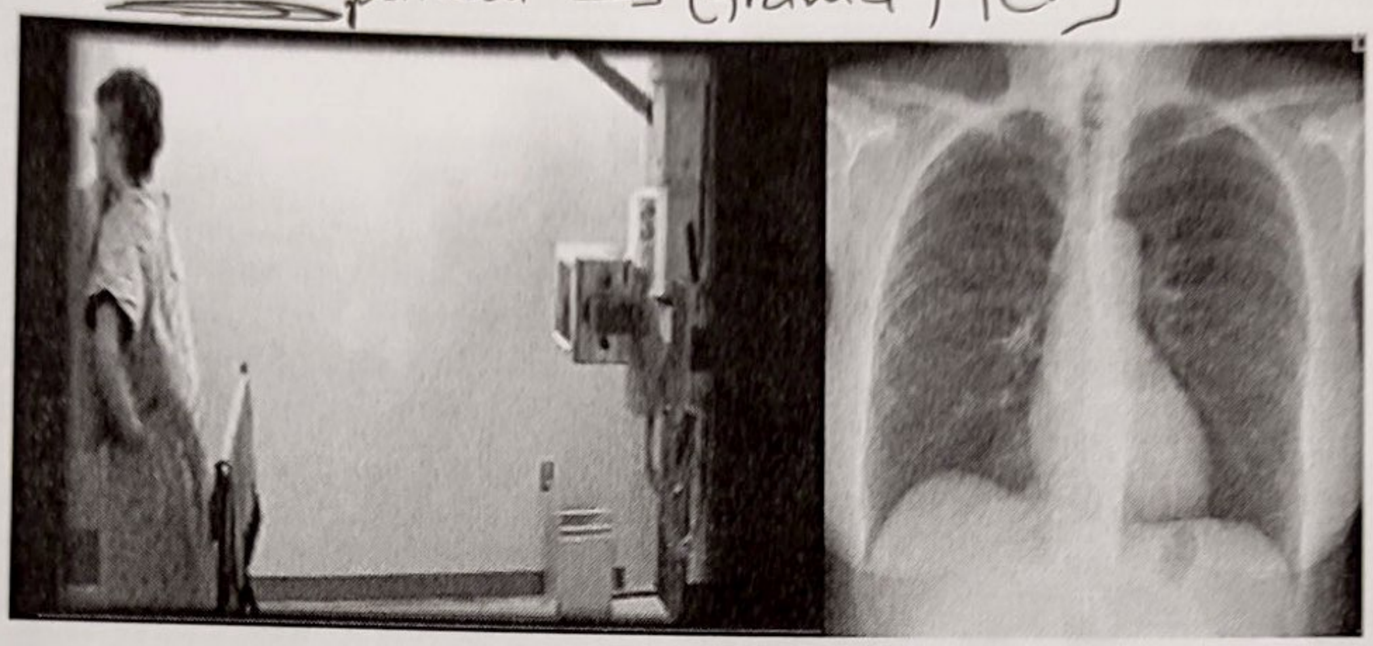

2

Lateral view

selected position.

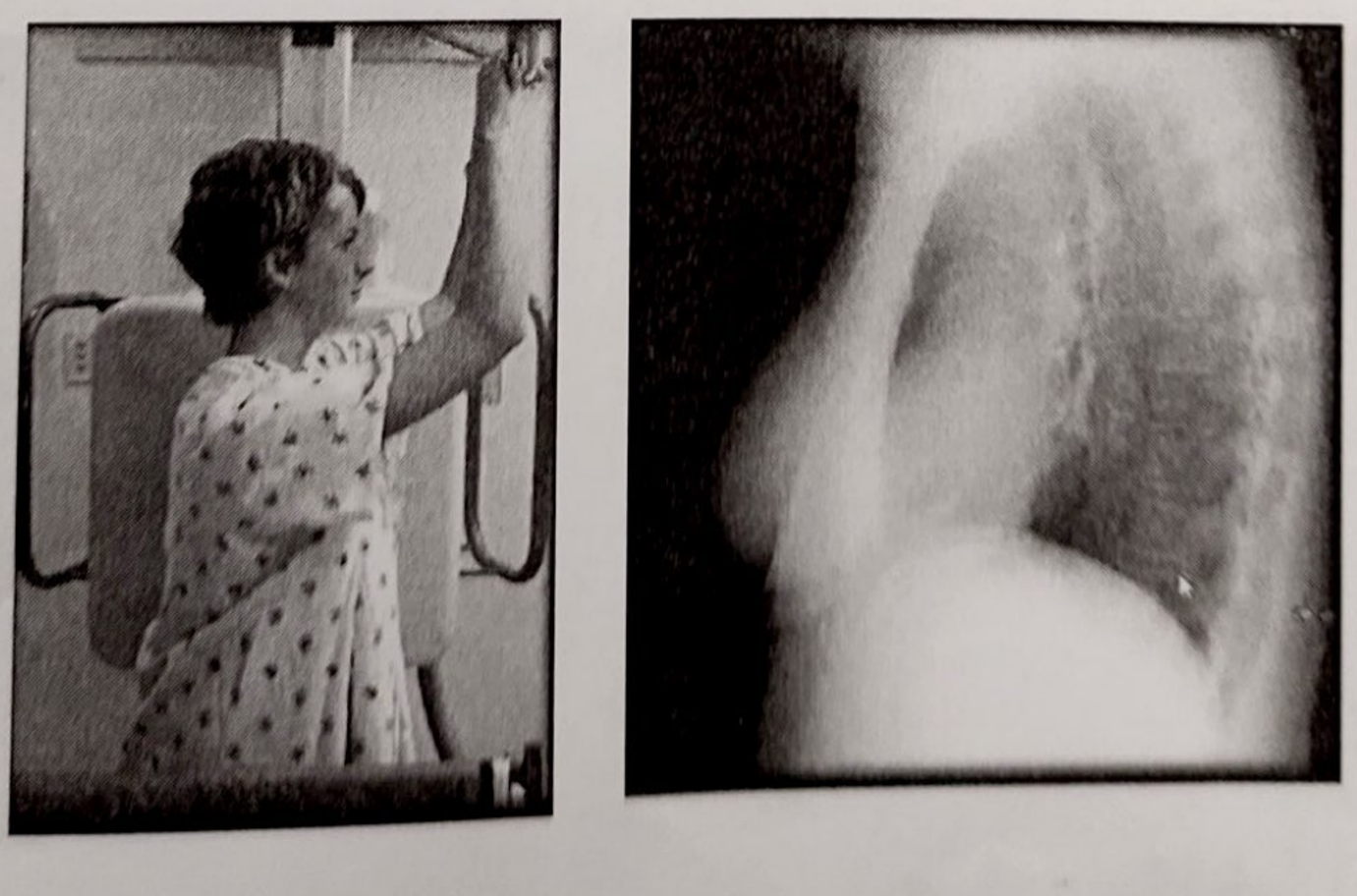

SHOT ON POCO X3

Scanned with CamScanner

3

AP view

- truma patient
- ICU patient
- pediatric

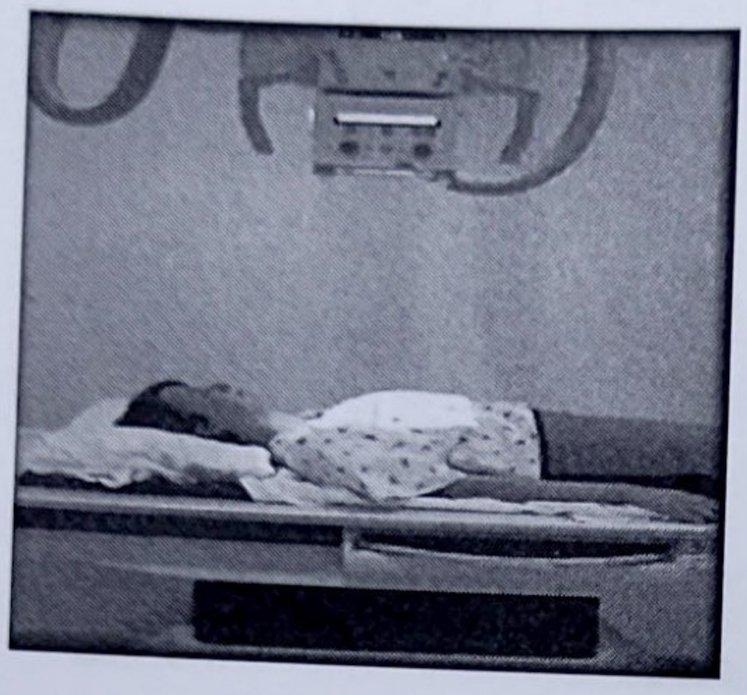



❑ Disadvantages of the bedside (portable) AP CXR:

- The heart is magnified .
- Under ventilation (supine patient is unable to take a full inspiration)
- Also , he may be rotated .

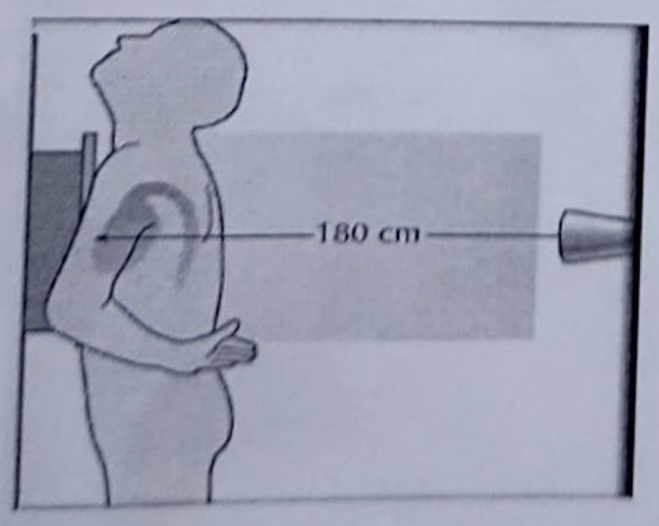

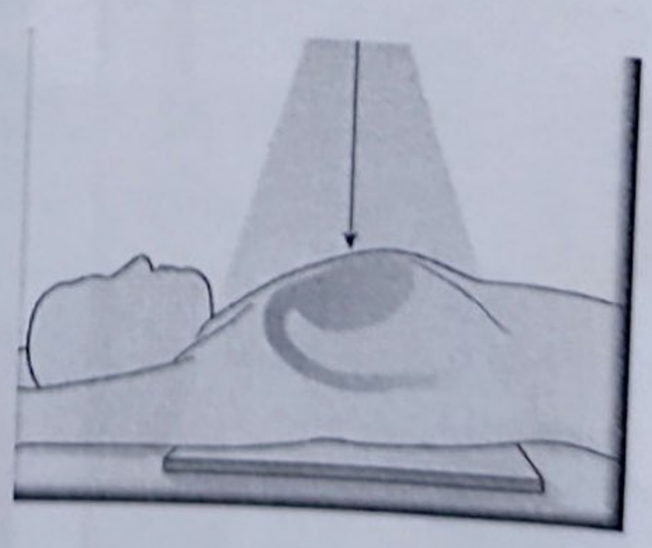

SHOT ON POCO X3

Scanned with CamScanner

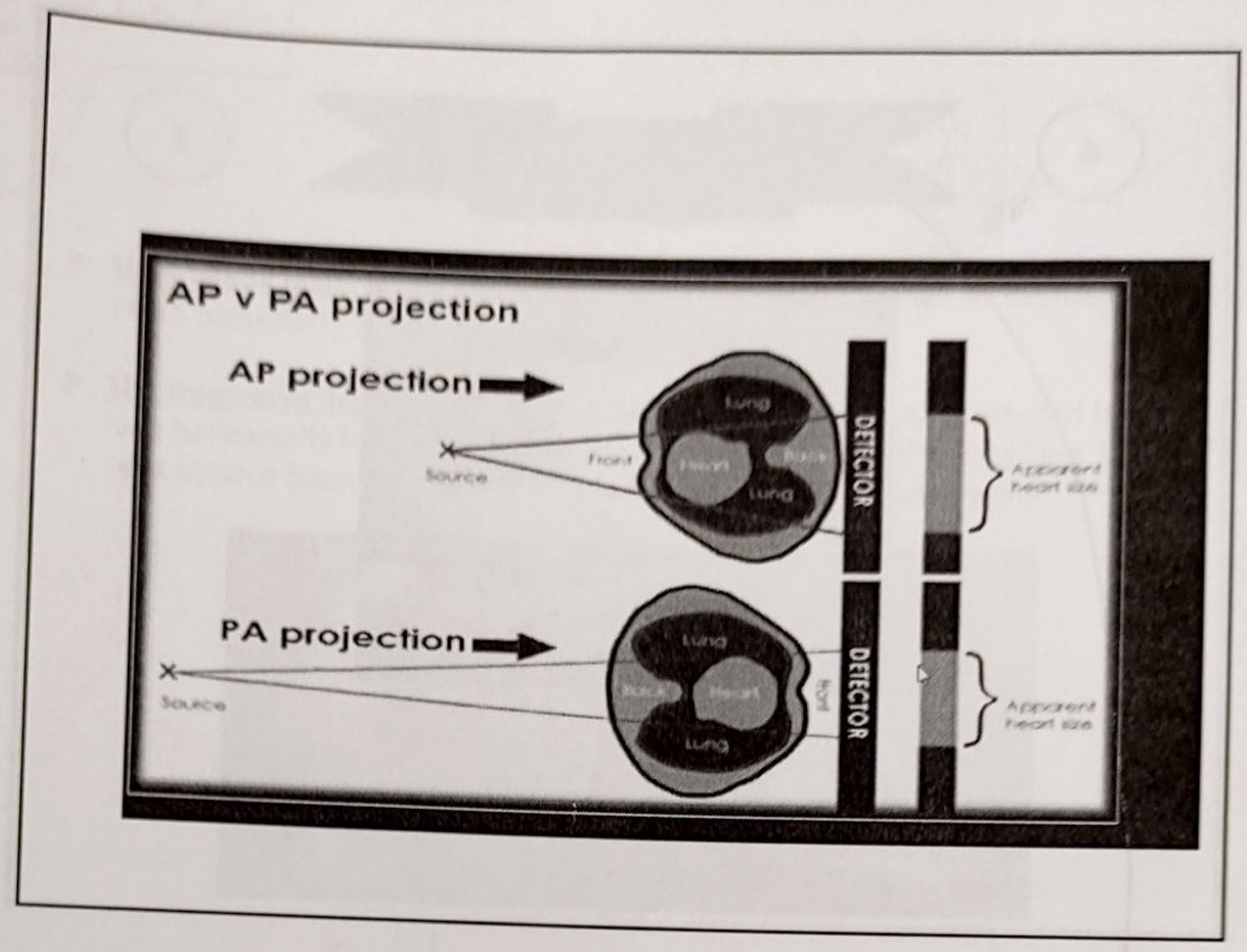

4 D

(1) In adequate ventilation in PA

PA VS AP

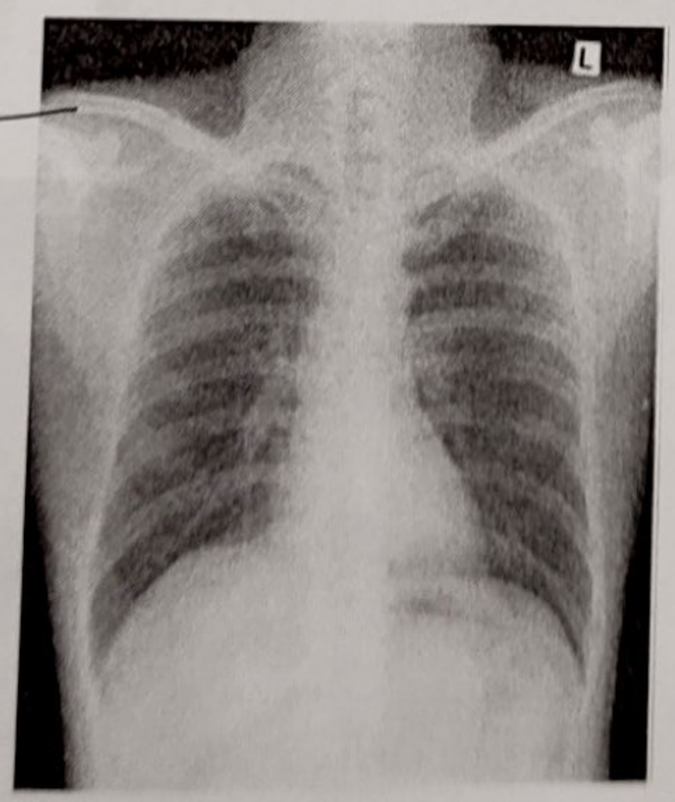

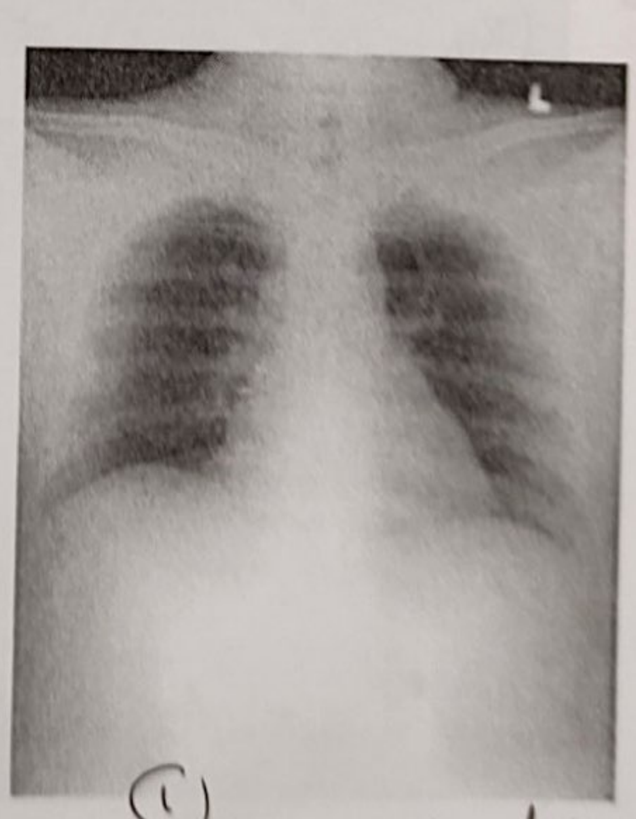

(2) oblique position clavicul

(3) ng shadow of scapula

(4) ribs

(1) under ventilated lung.

(2) More transverse position

(3) Theirs shadow of scapula.

(4) ribs More transerse.

SHOT ON POCO X3

Scanned with CamScanner

28/07/1444

28

4

Lateral Decubitus

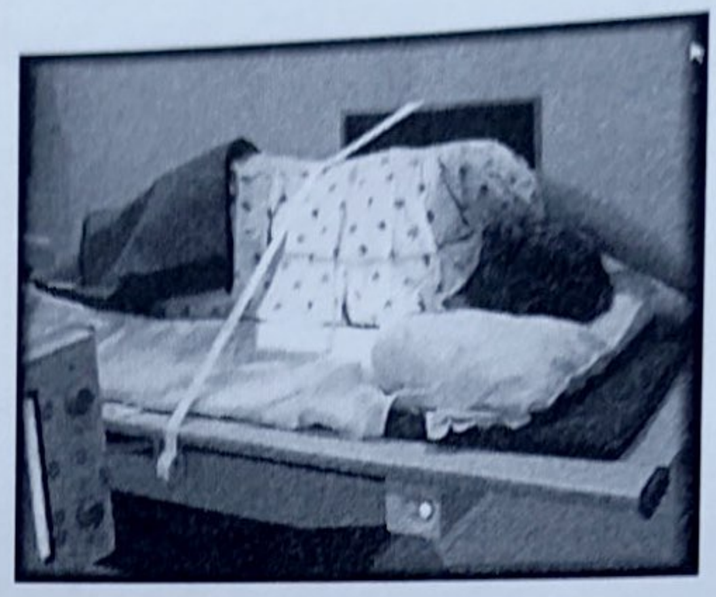

① يرقد لعتت الجاد.

يطلع لعوجه طواد

Pleural effusion = affected side down

pneumothorax = affected side up

②

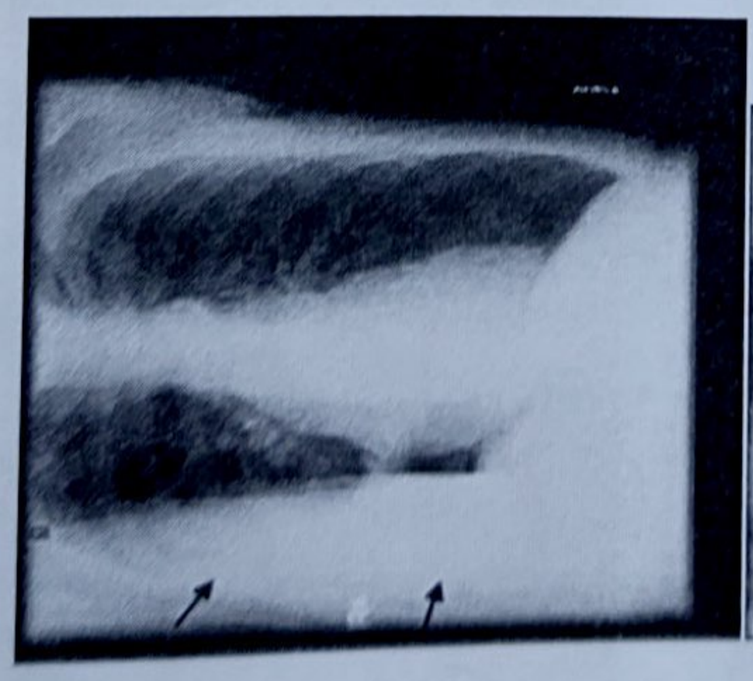

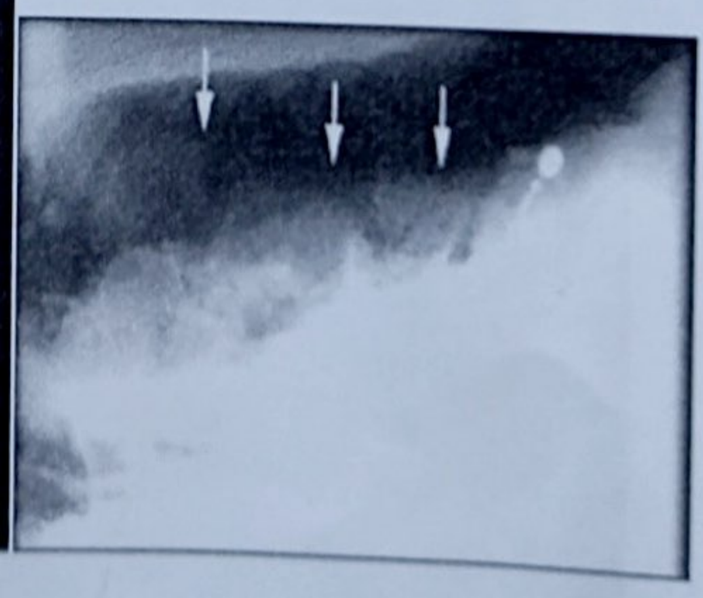

① الأبيض

① X ray

① soft tissue

② bone

③ fluid.

④ Mass

⑤ calcification / nodul / ③ vessels

① air

② cavity.

③ bronchus (tube)

6

SHOT ON POCO X3

Scanned with CamScanner

X-ray (fissure لـ حالات
if pathology

- like plera effusion

→ Cause thickning of fissure.

1

Fissures & Lobes

- **The oblique major fissure** is similar in both right and left lungs .Its extended from T4/T5 posteriorly to the diaphragm antero-inferior

- **The transverse fissure (minor)** separates the upper and middle lobes of the right lung horizontally from the hilum to the anterior surface of the right lung to the right oblique fissure at the level of the sixth rib in the mid-axillary line .

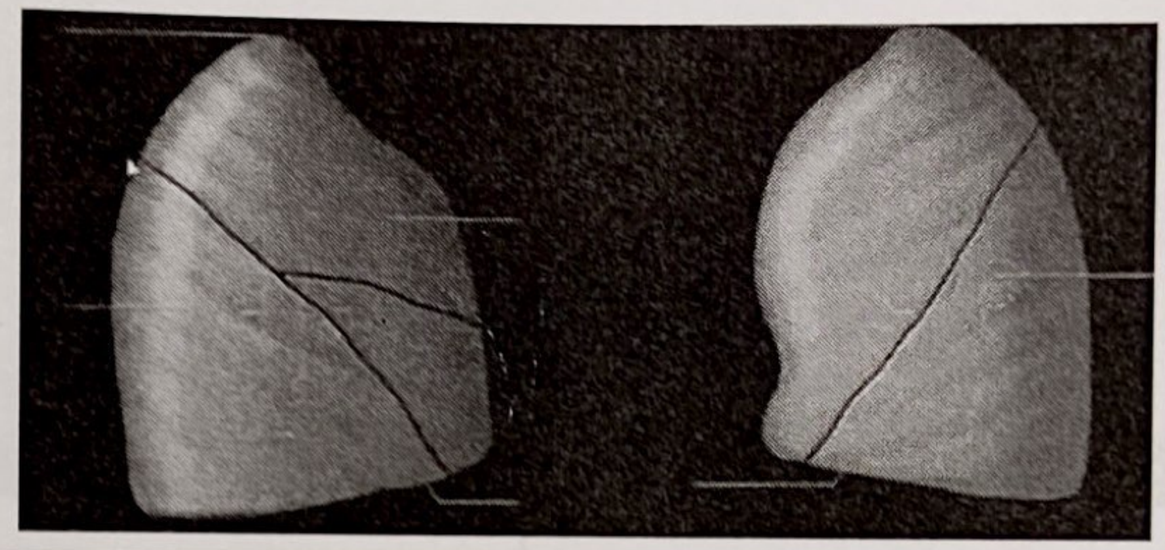

right

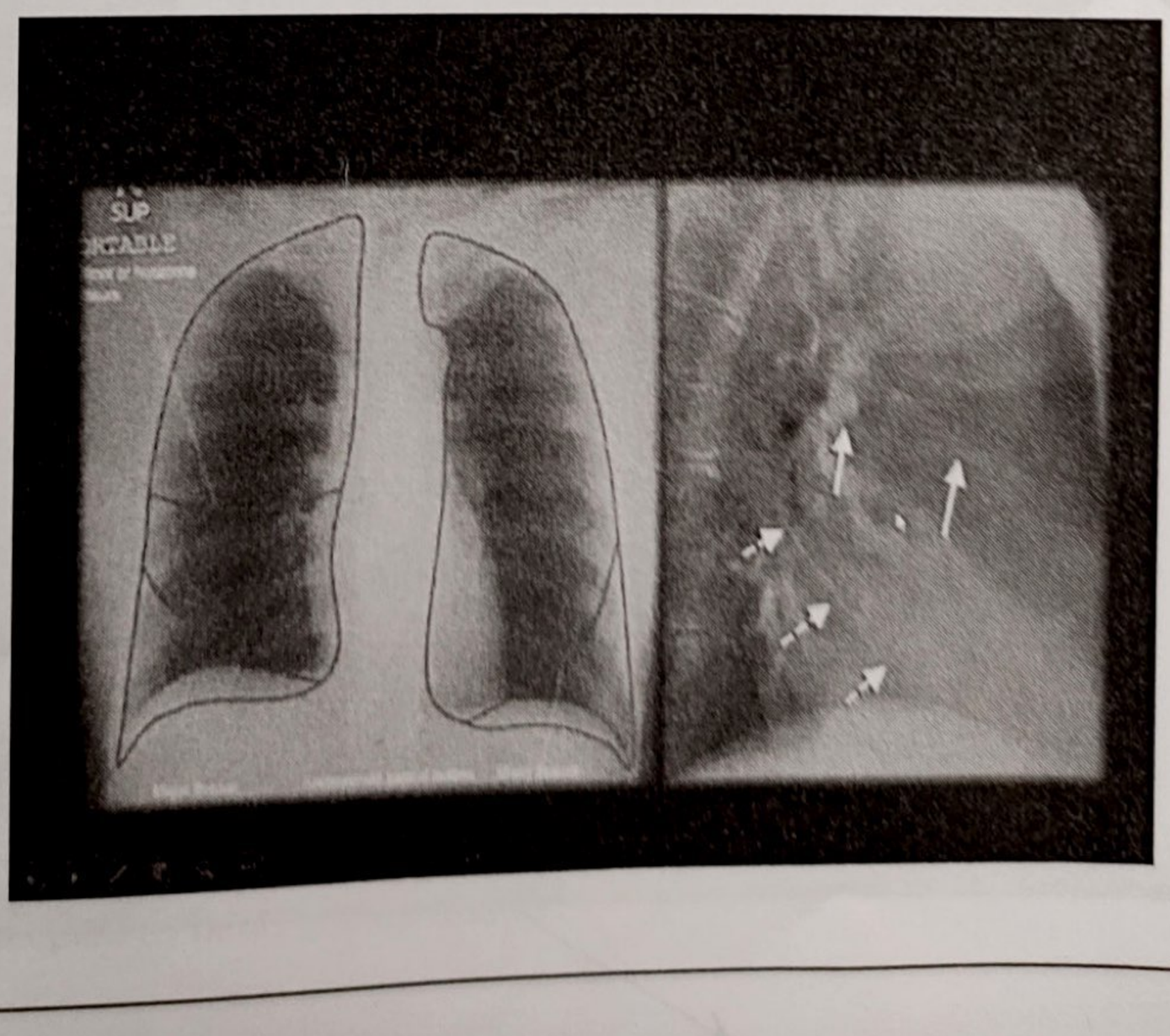

SHOT ON POCO X3

Scanned with CamScanner

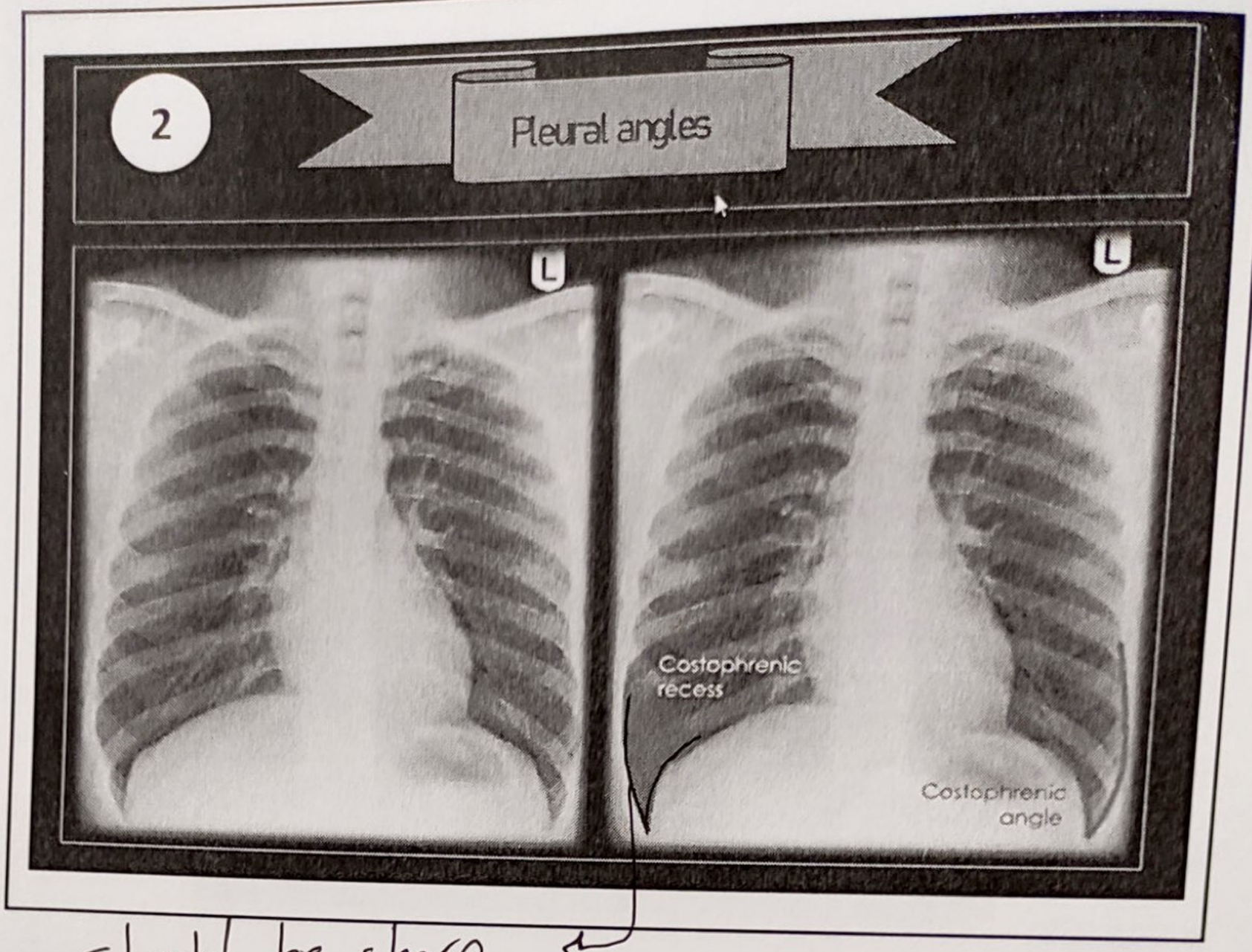

should be sharp.

لو ما كانت sharp نتحكي على انه

Pleura effusion

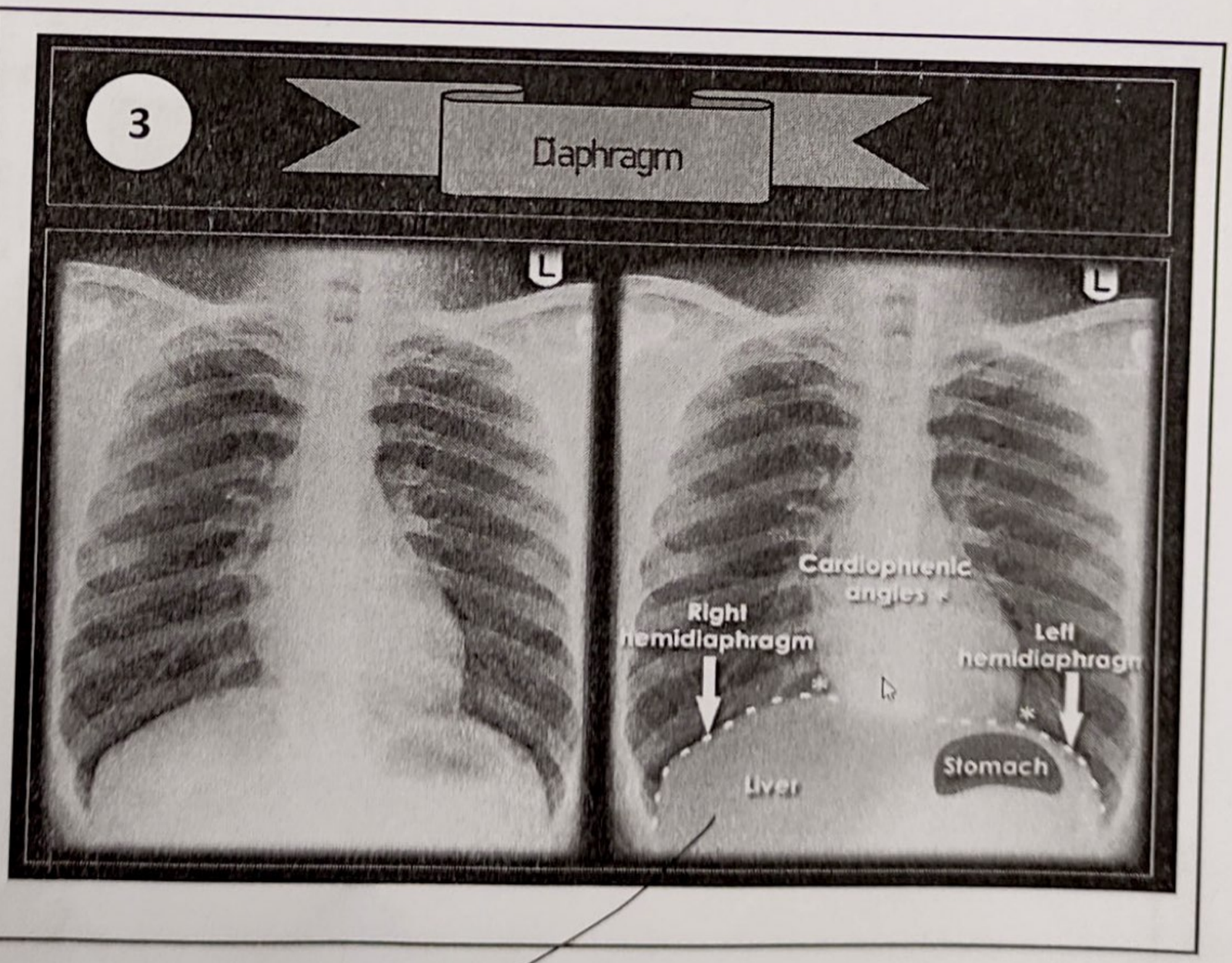

normal Convex dom shape

8 Right Move higher than left in one intercostal space.

- fibrosis
- hyperinflamed lung

pathology

3cm

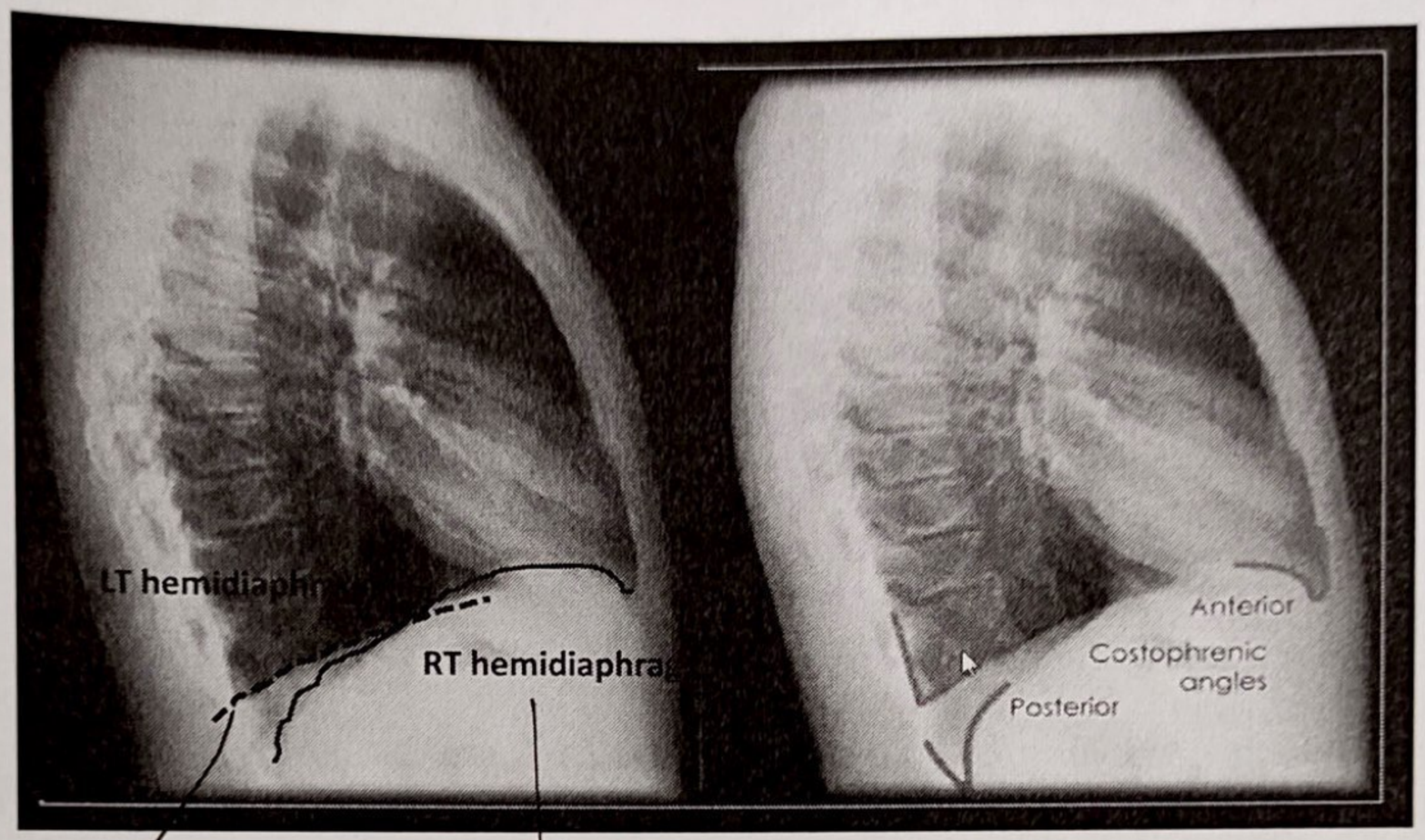

Continuation

not Continuation due to the heart.

4

Mediastinum

- The mediastinal division
- The superior is above a line drawn from the lower border of T4 to the sternal angle .
- Below this line are anterior, middle and posterior compartments .
- The anterior mediastinum is between the anterior part of the heart and the sternum .
- The middle mediastinum is occupied by heart and its vessels .

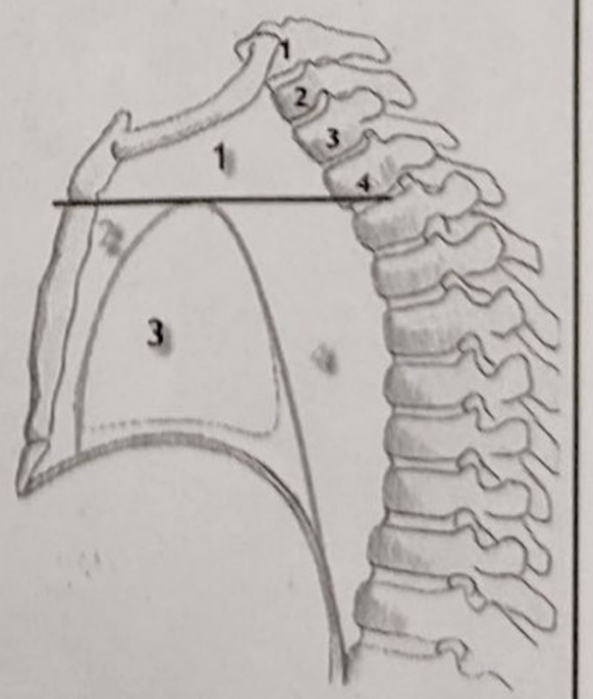

SHOT ON POCO X3

Scanned with CamScanner

26/07/1444

-abdominal CT 350 chest X-ray

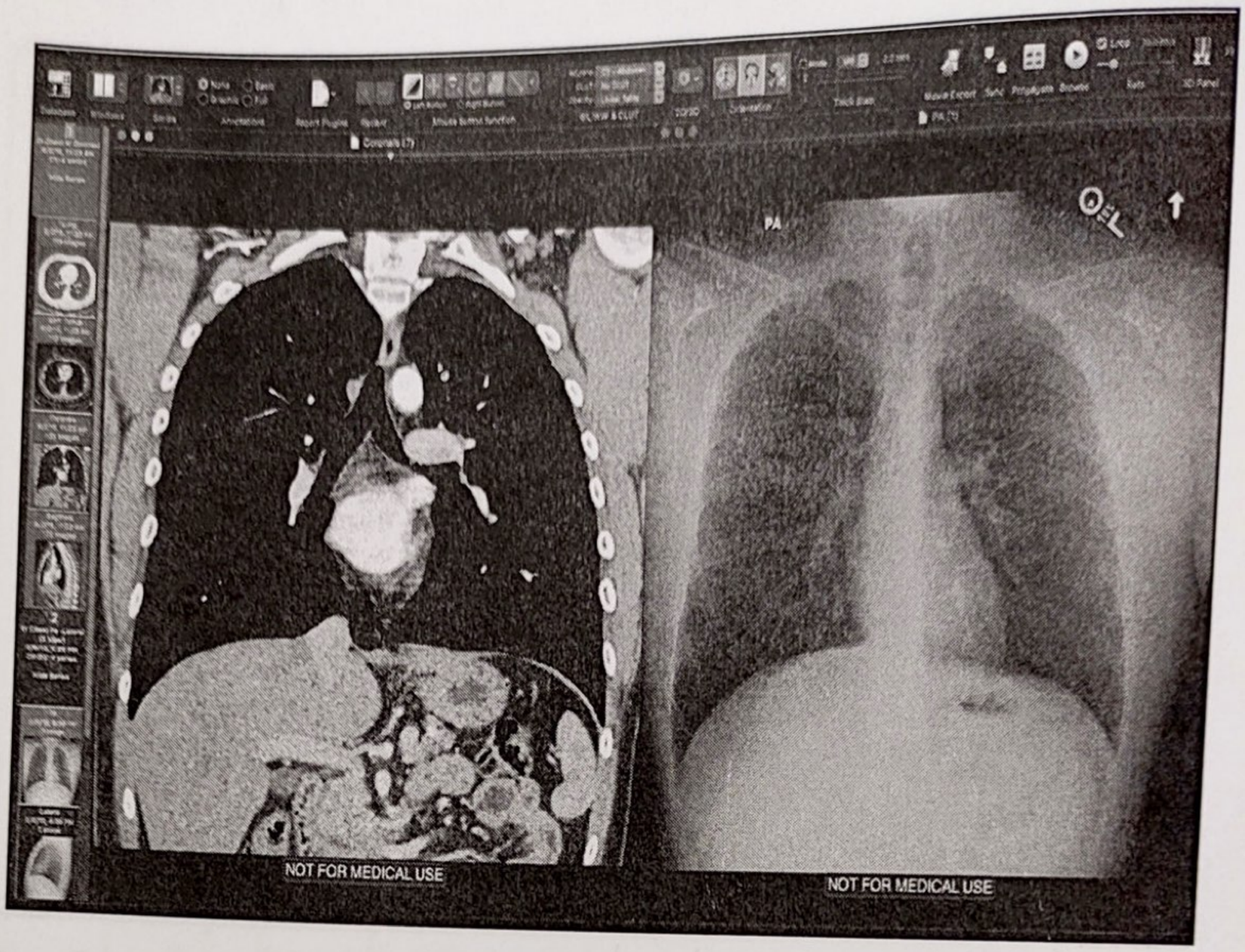

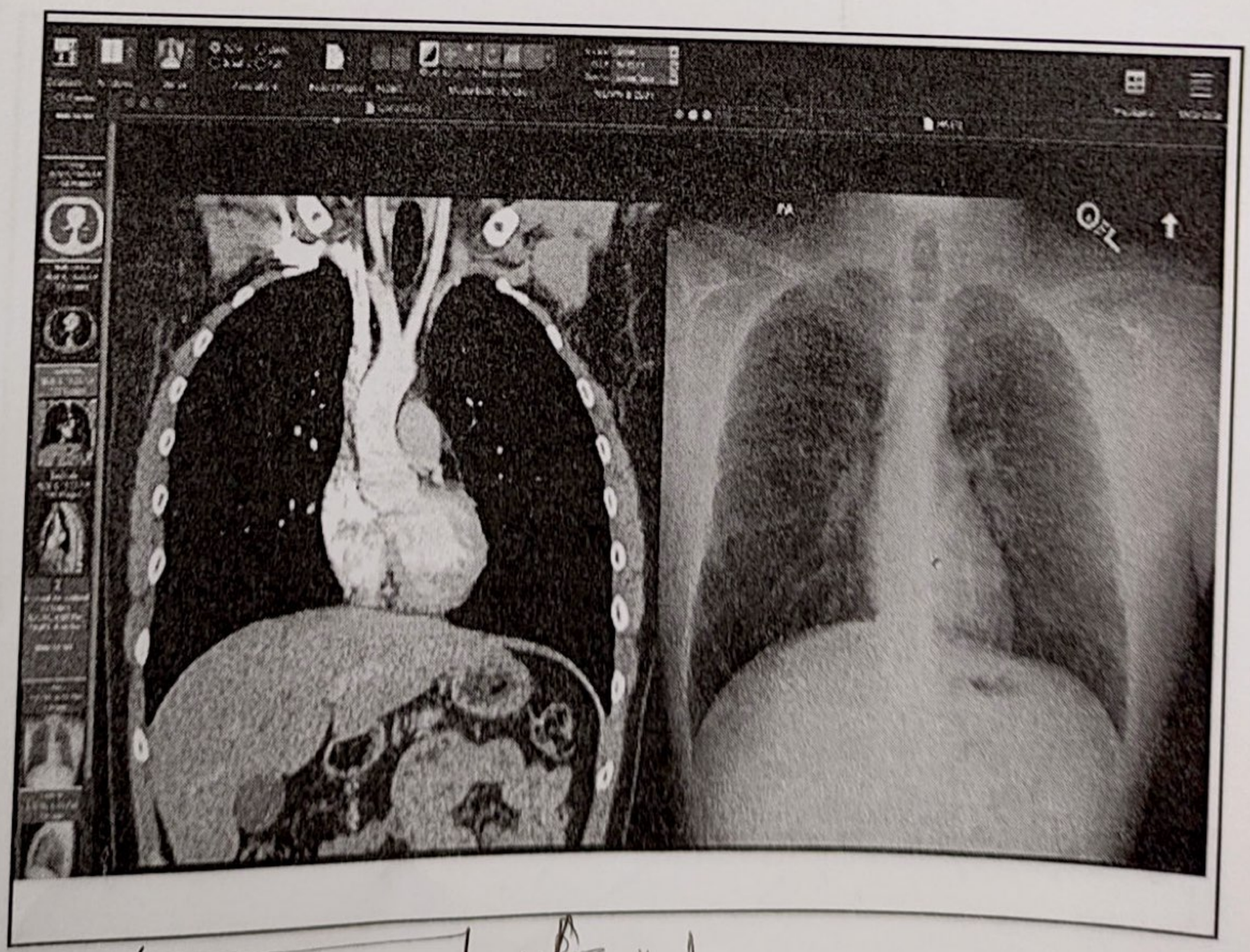

* CT/US/MRI يذب artificated

* X-ray real immage

SHOT ON POCO X3

Scanned with CamScanner

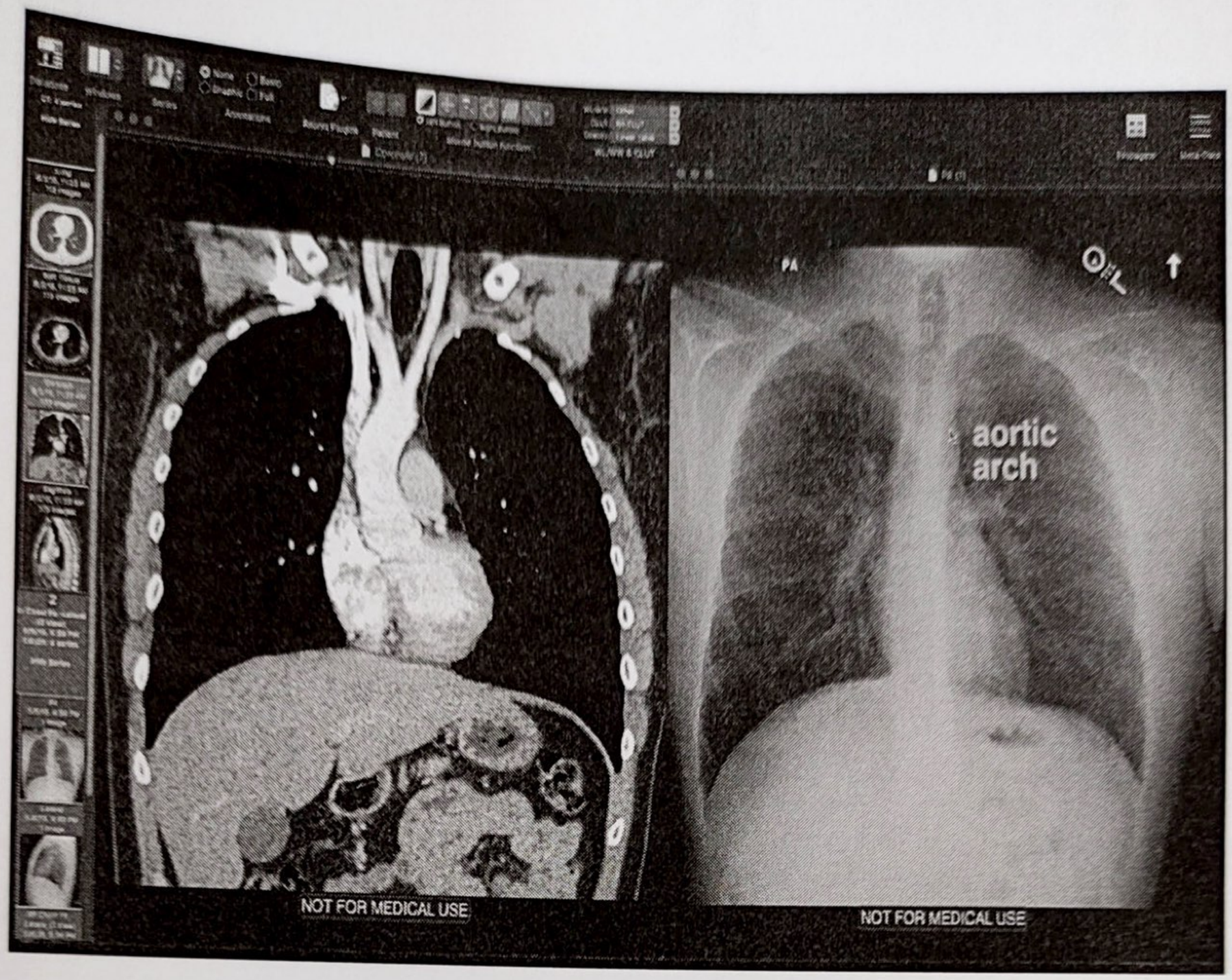

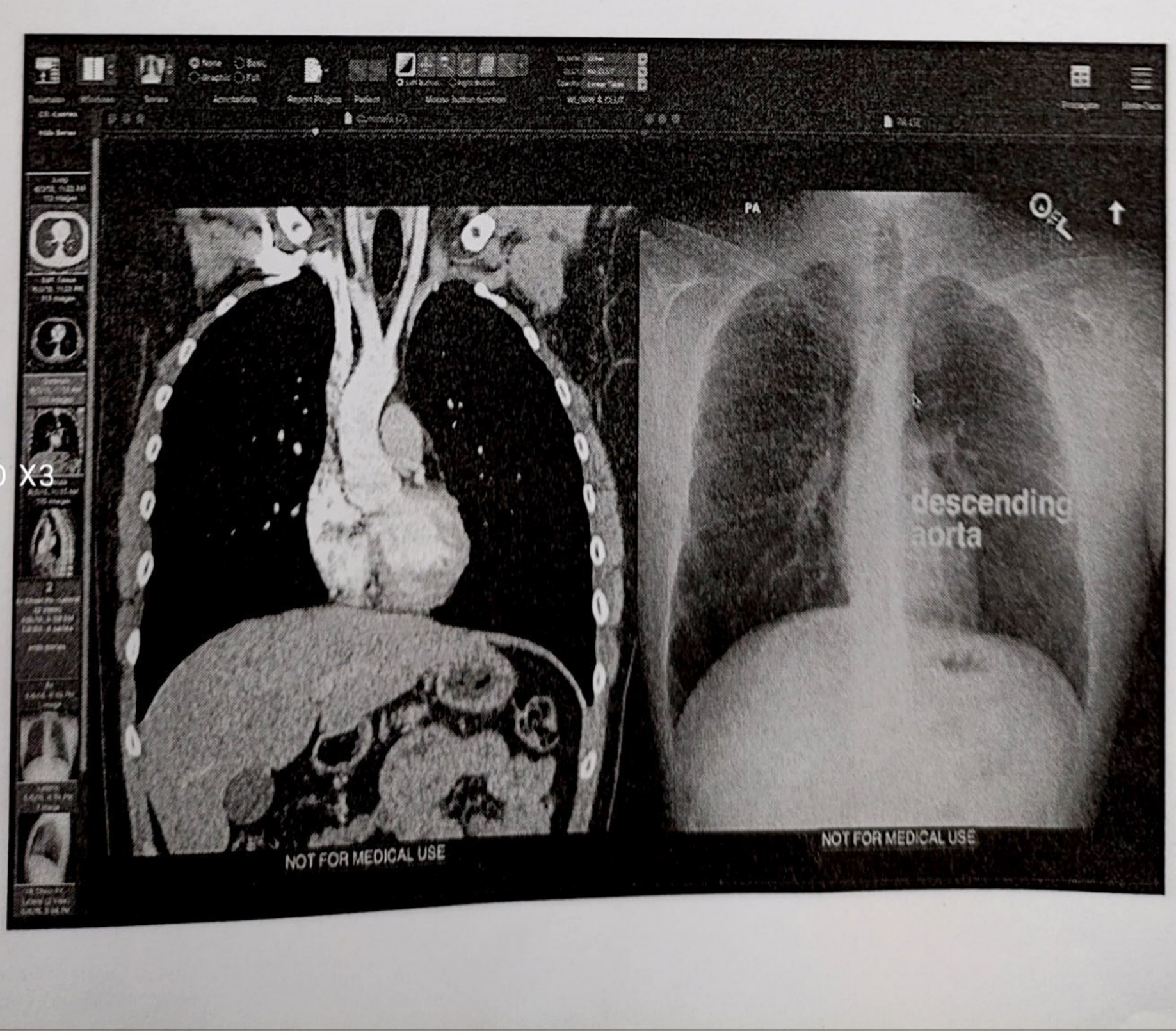

SHOT ON POCO X3

Scanned with CamScanner

28/07/1444

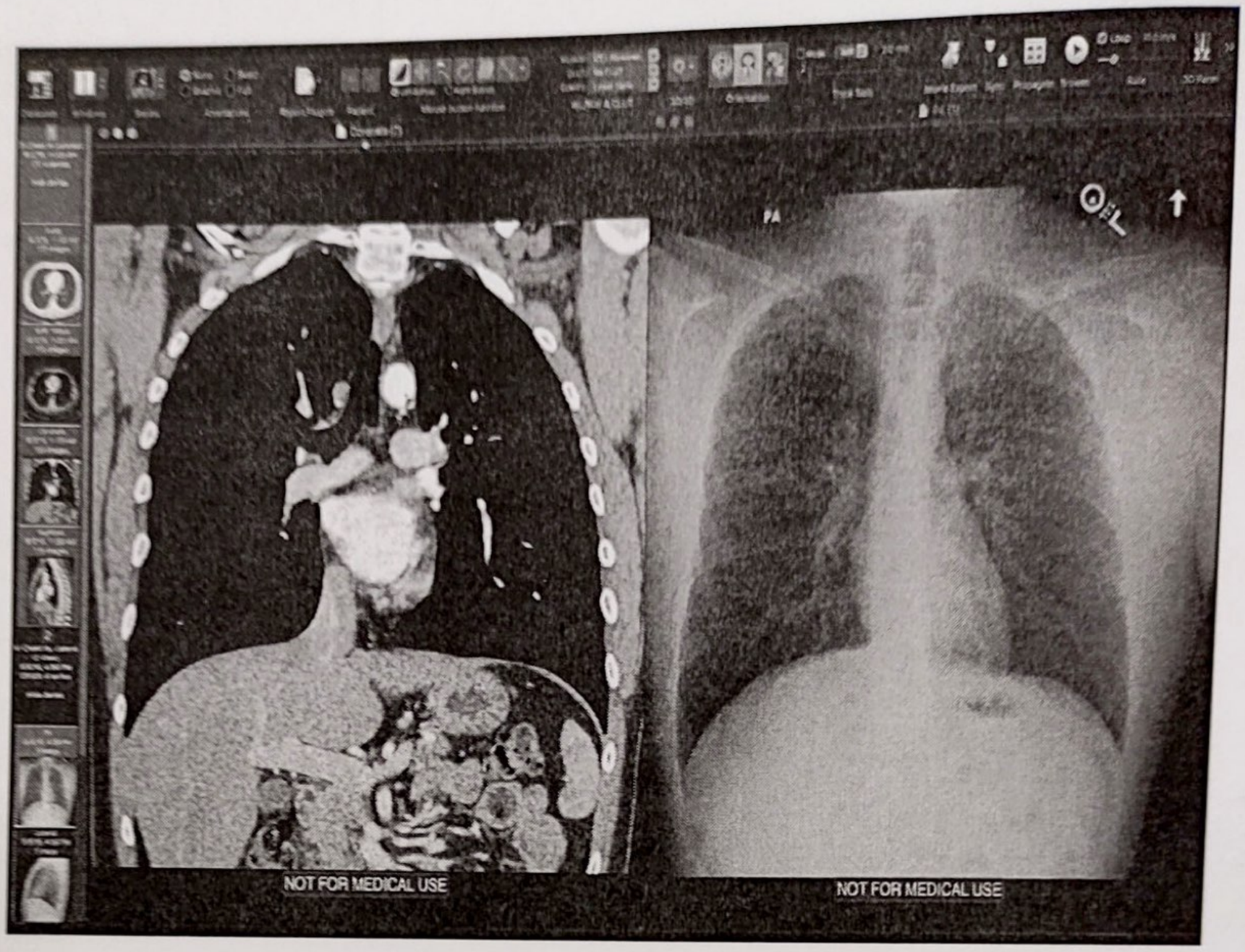

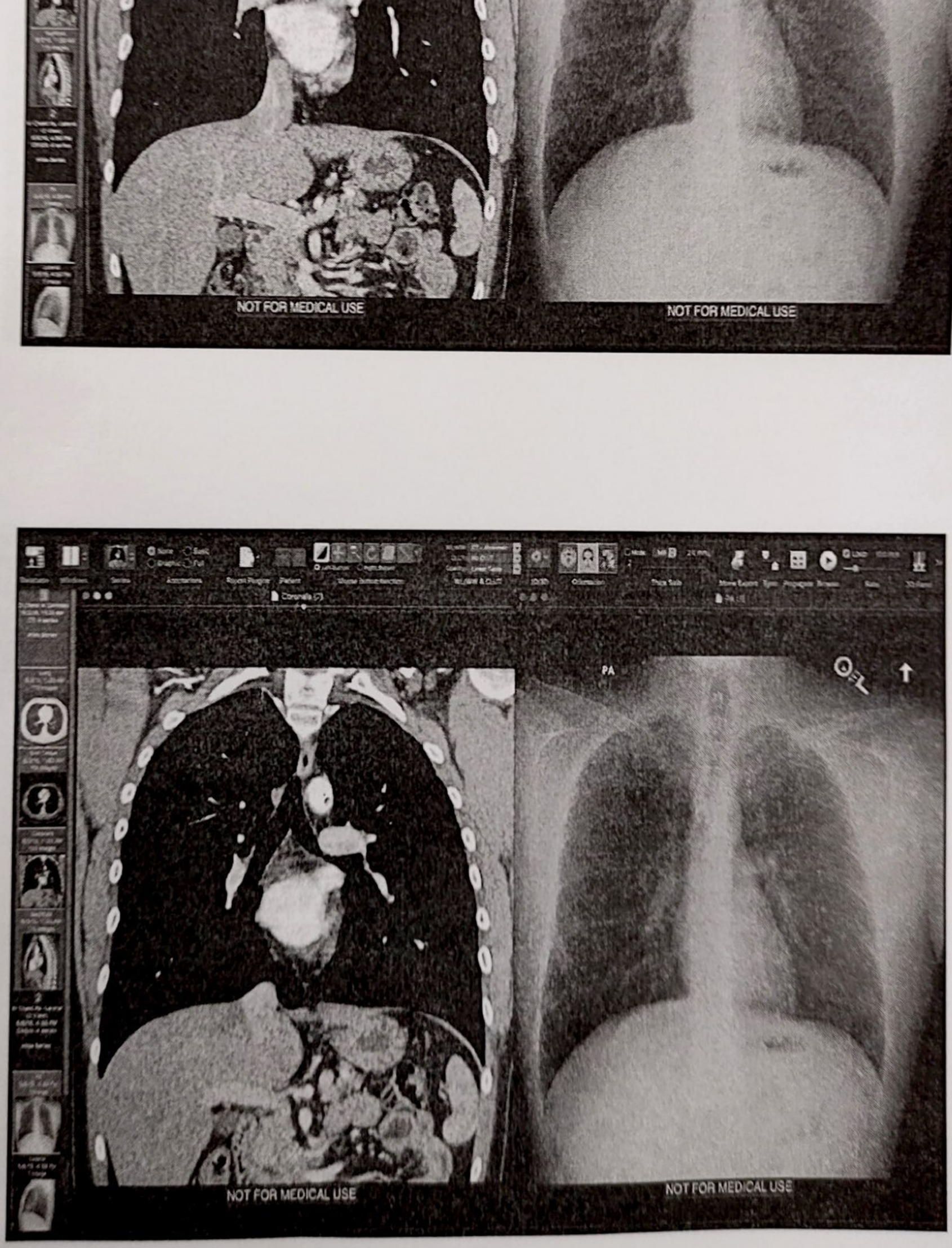

SHOT ON POCO X3

Scanned with CamScanner

23/07/1444

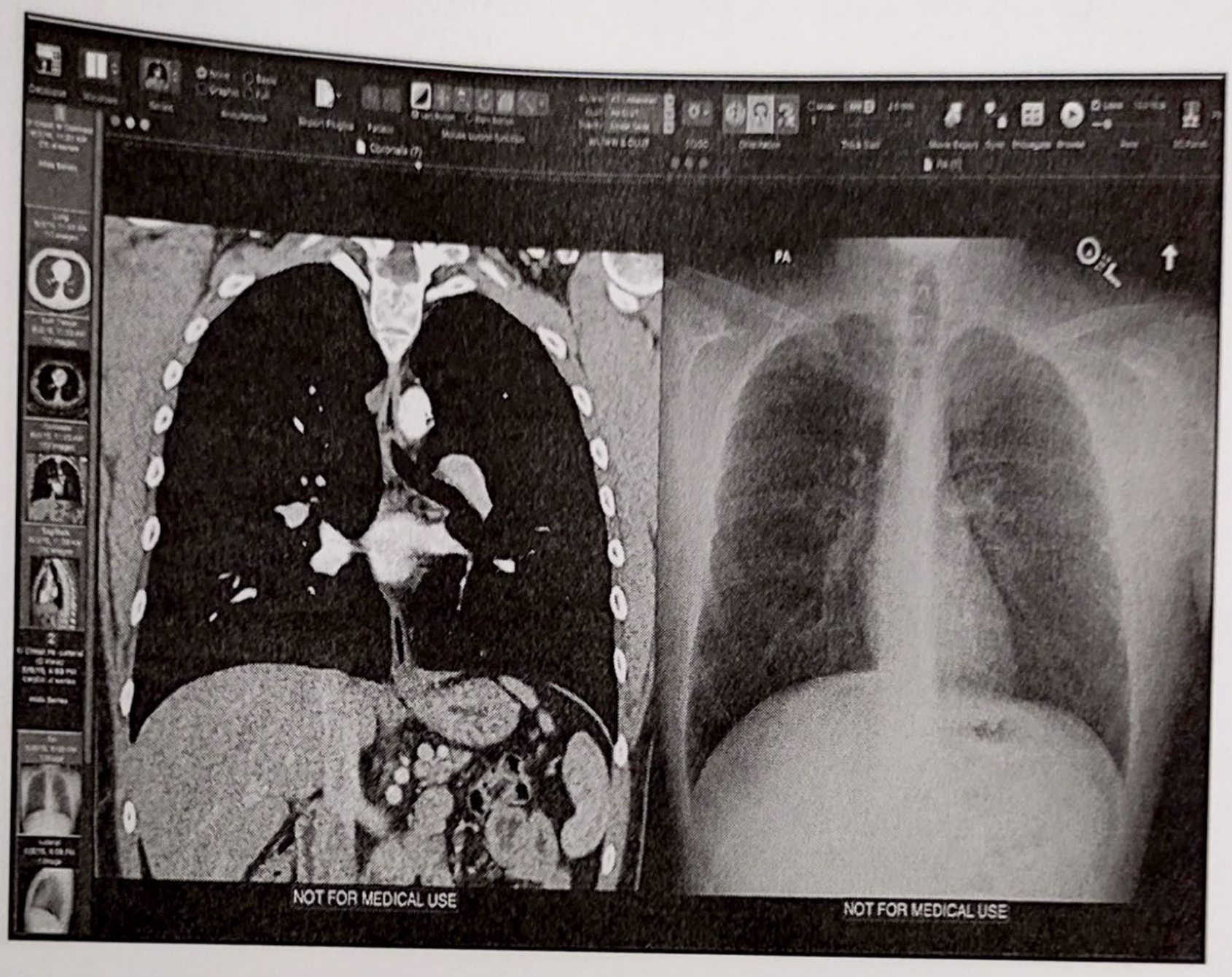

SHOT ON POCO X3

Scanned with CamScanner

28/07/1444

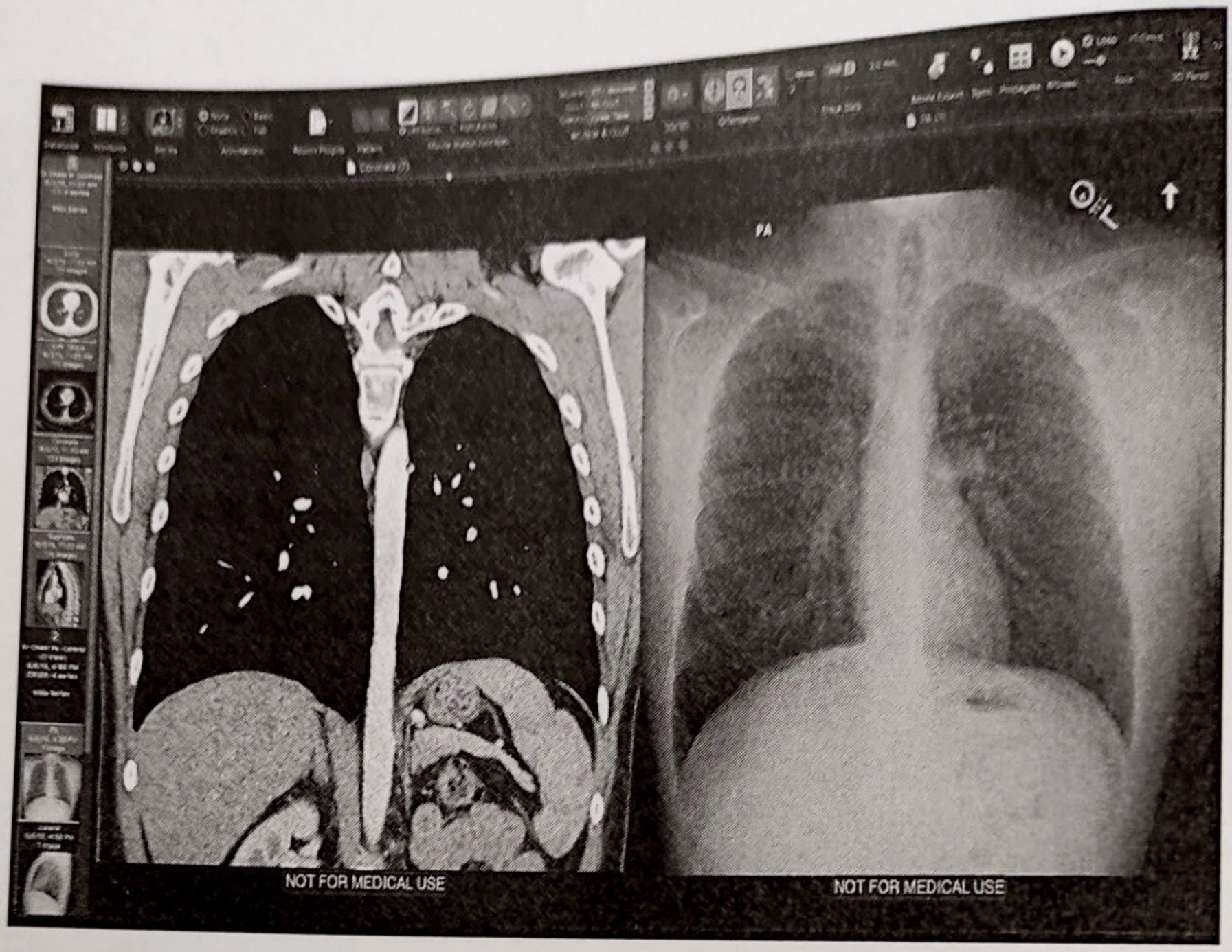

TECHNIQUE

SHOT ON POCO X3

Scanned with CamScanner

28/07/1444

1

Identification

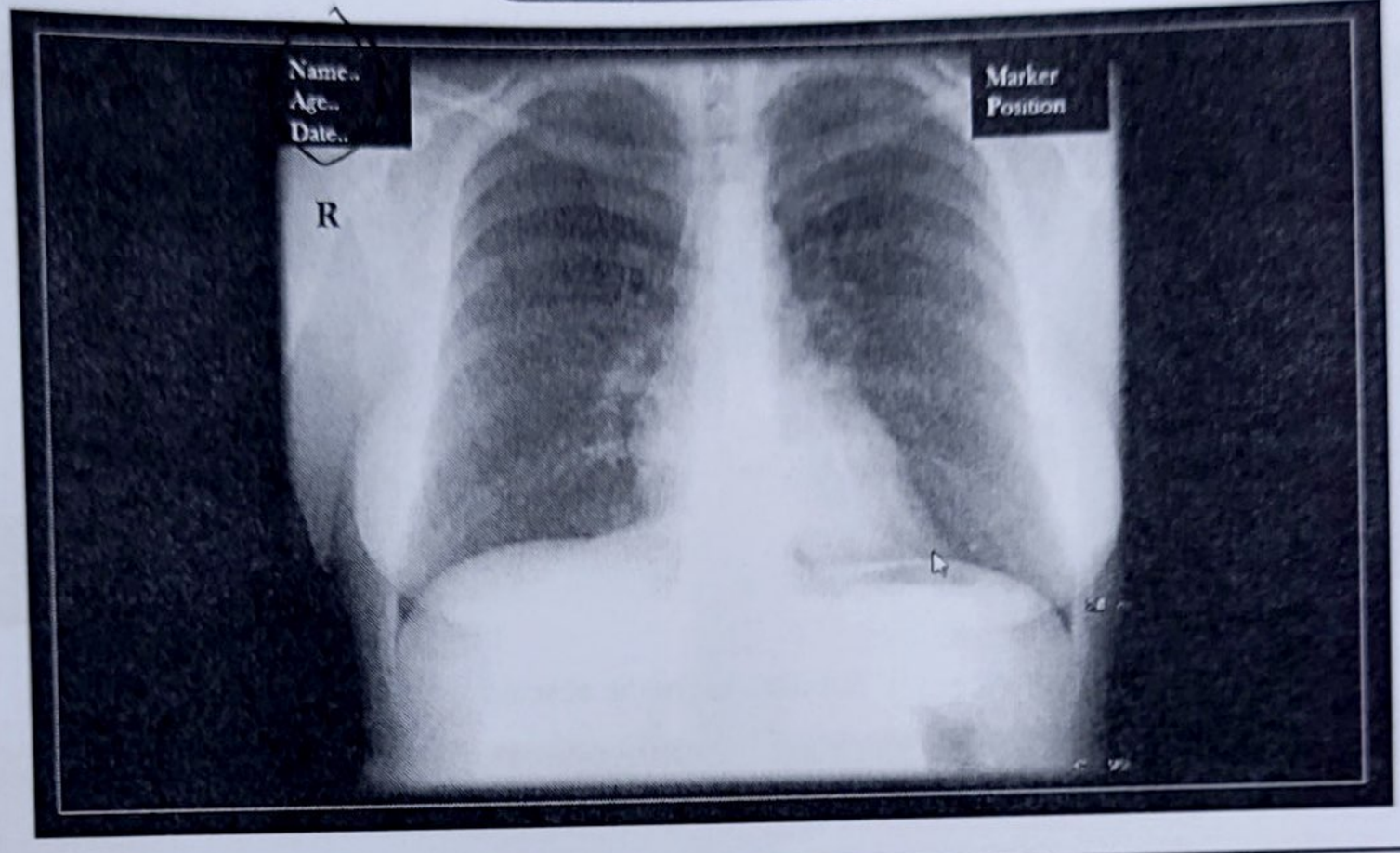

???

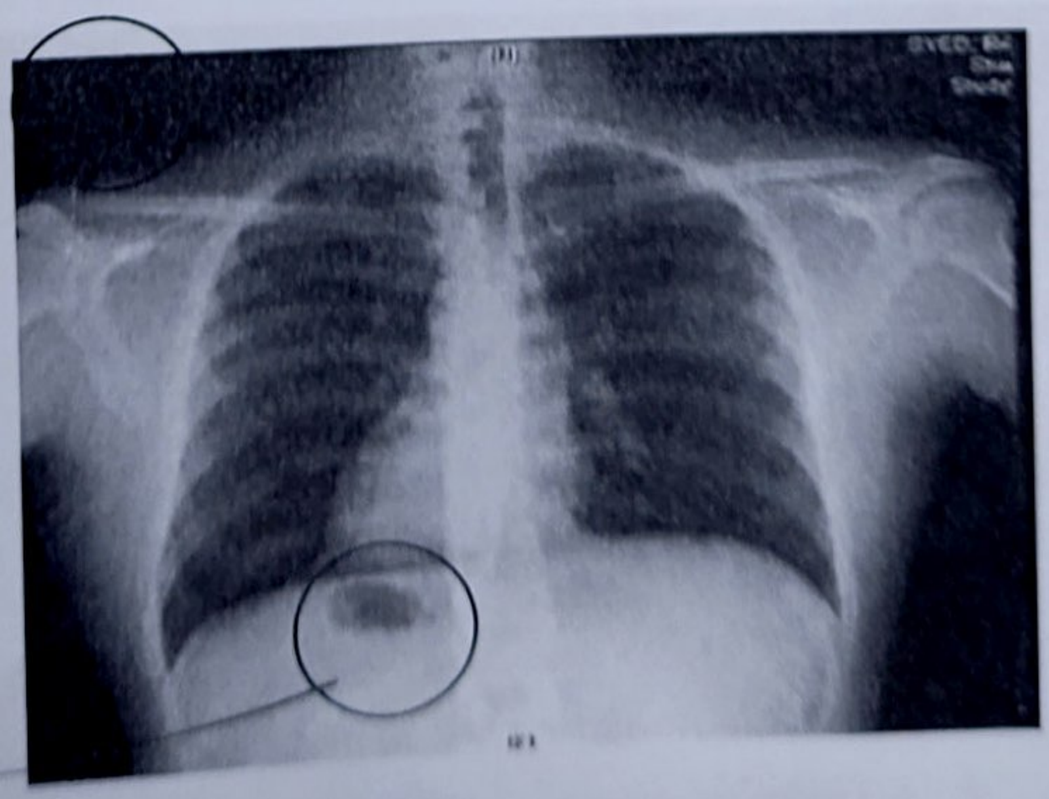

dextrocardia

Stomach

SHOT ON POCO X3

Scanned with CamScanner

???

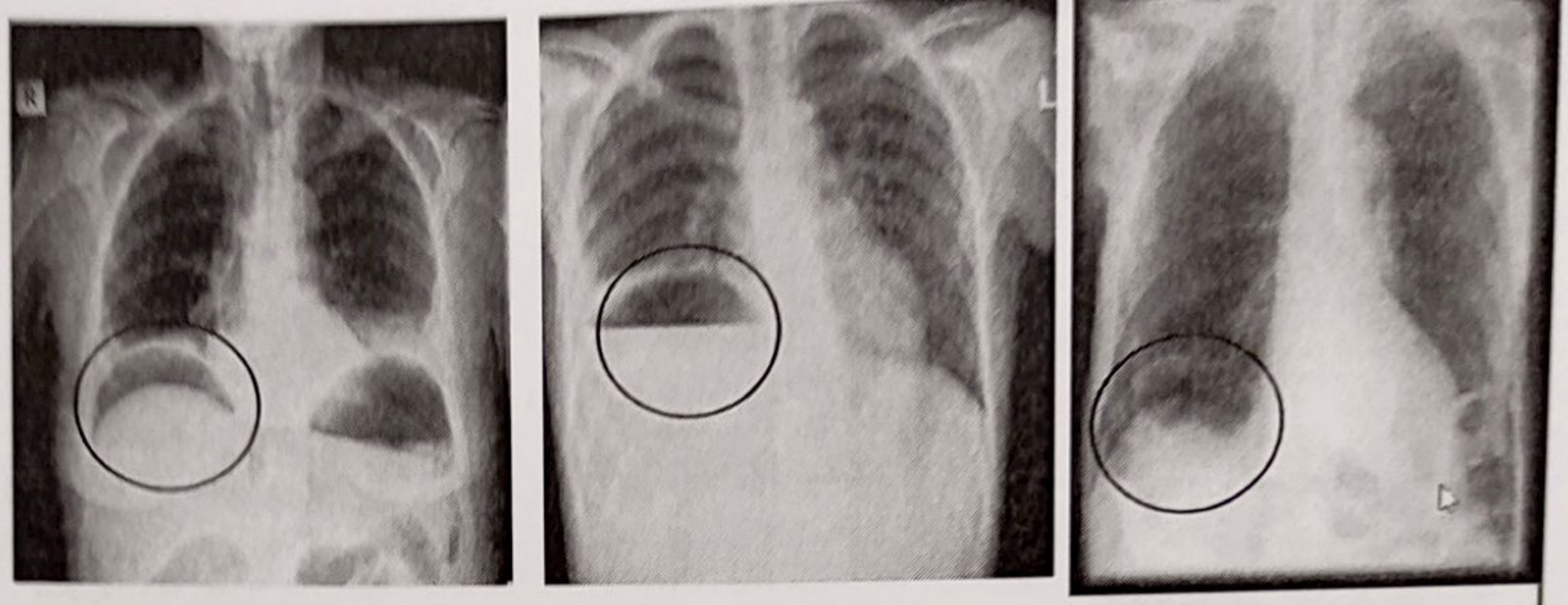

Pneurmoperitonium

Subdiaphragmatic abscess

Chilaiditi syndrome

2

Centralization

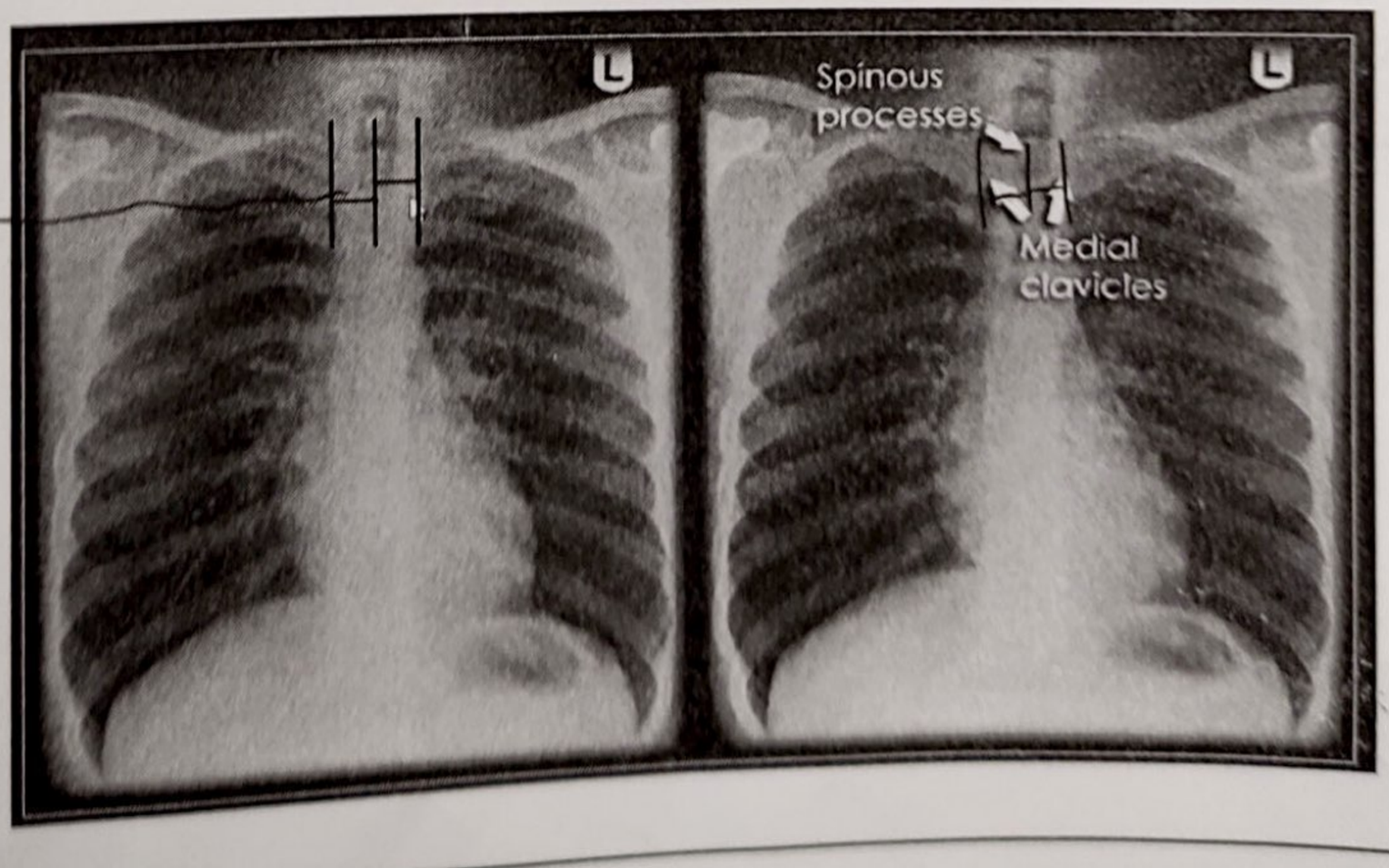

equal لازم يكون

Mal rotation.

SHOT ON POCO X3

Scanned with CamScanner

???

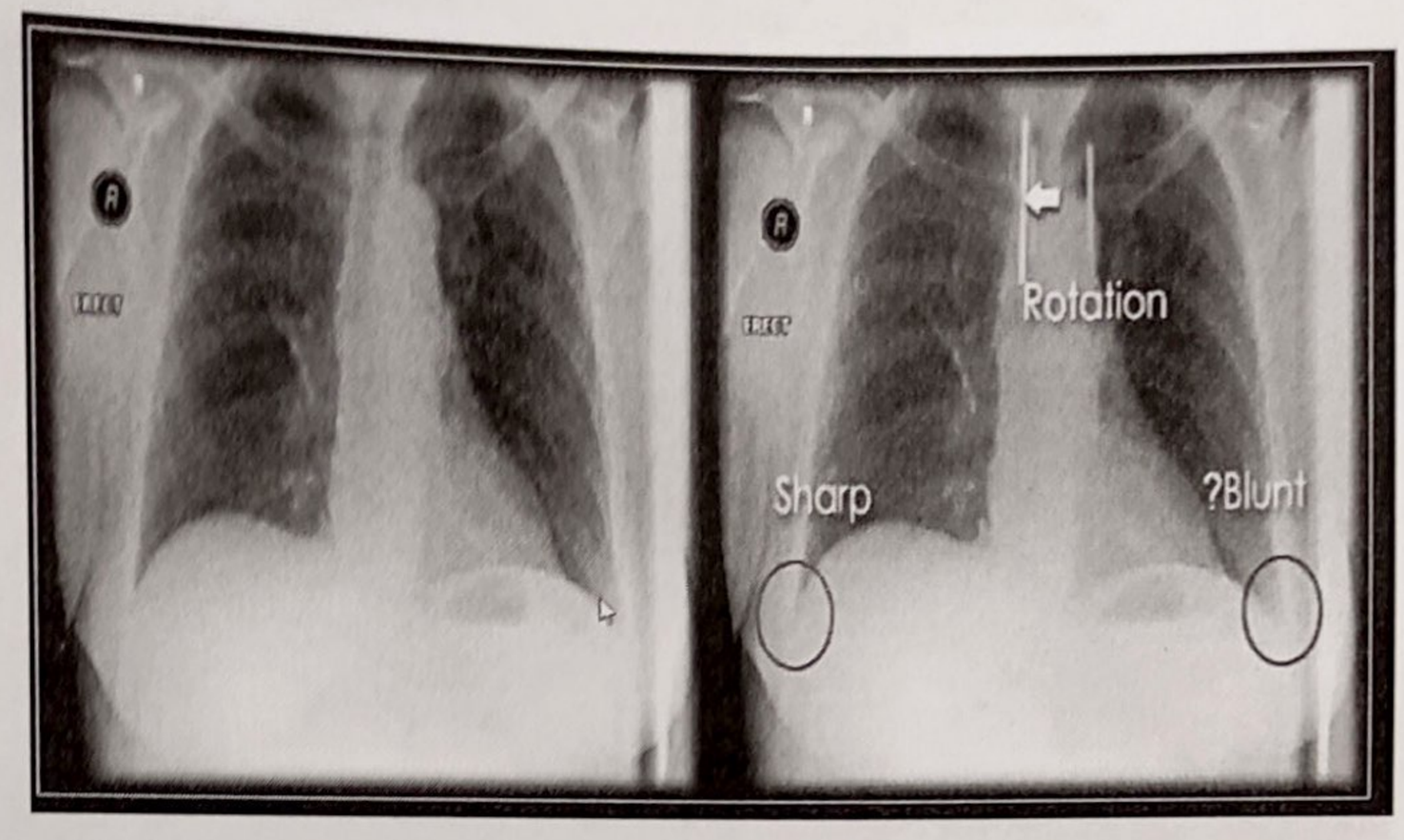

3

Ventilation

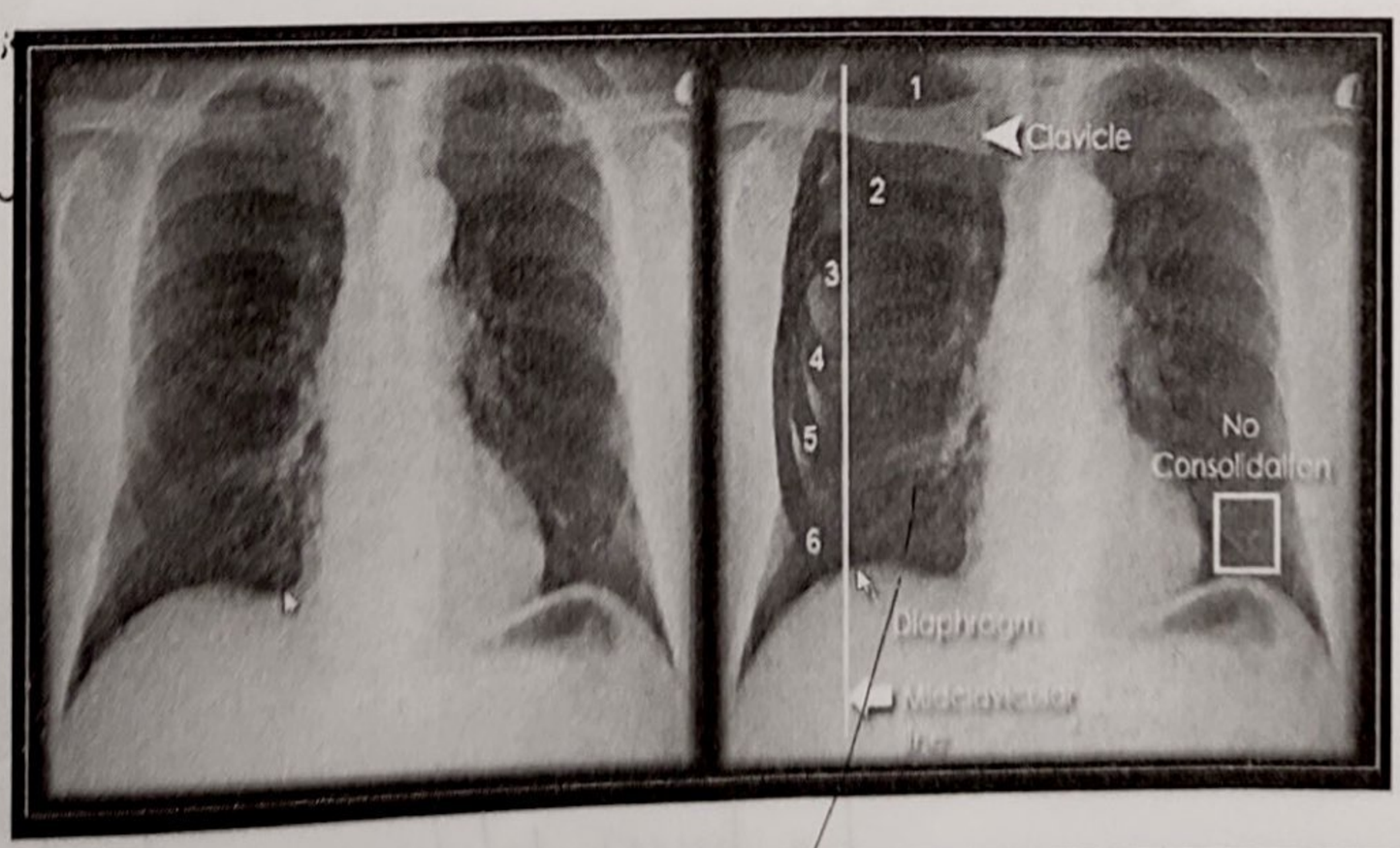

كيف أعرف أن الصورة underventelati & hyperventelate

ribs نعد ←

ribs أعلى جزء يعني posterior نصف cartilage.

adquate ventlatio

5-6 ribs → in anterior.

9-10 ribs → in posterior.

أكثر سوداء hyperinflated lung.

صغيرة cartilage ما بيشوفها

SHOT ON POCO X3

Scanned with CamScanner

???

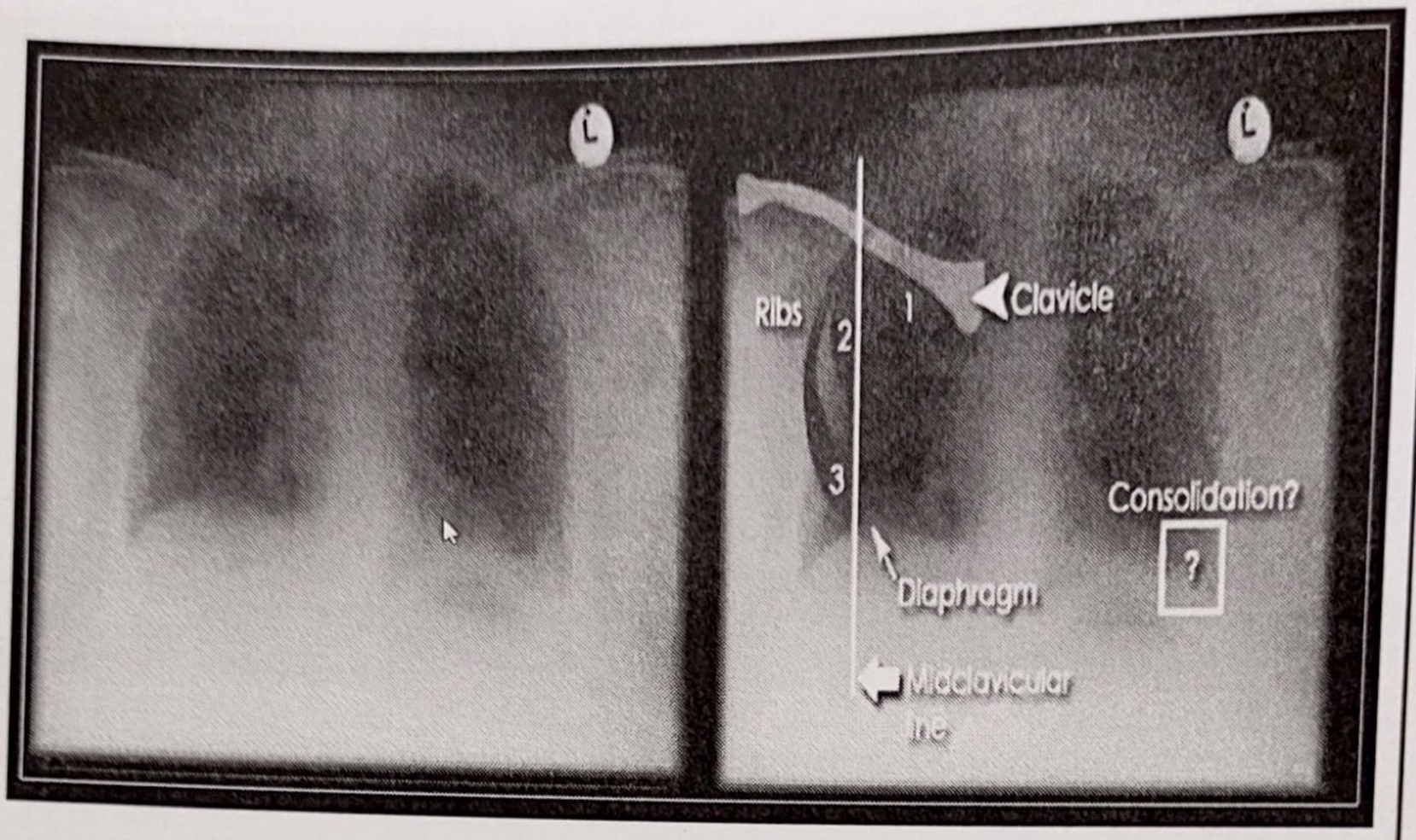

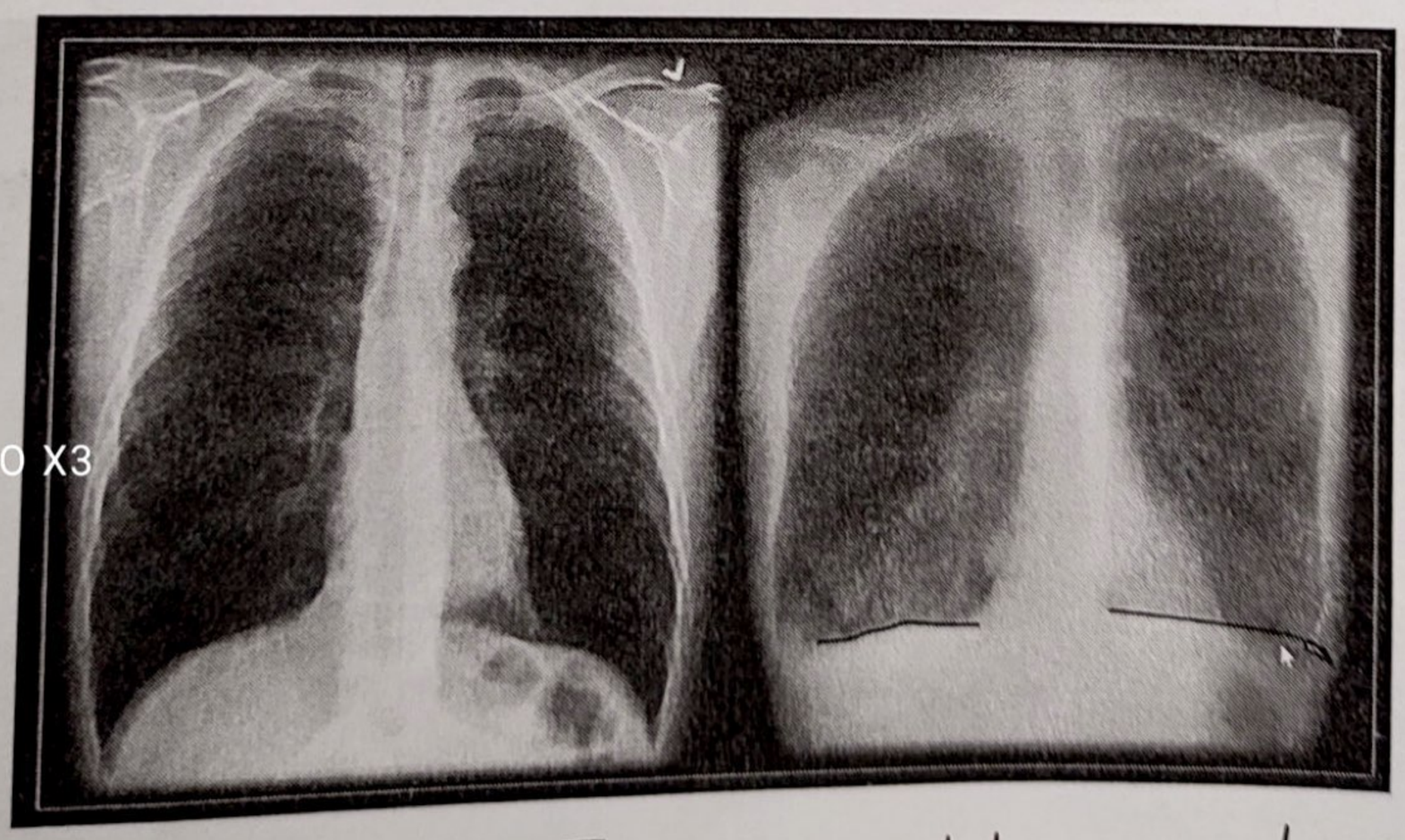

In hyperinflation → diaphram is flatted.

SHOT ON POCO X3

Scanned with CamScanner

4

Penetration

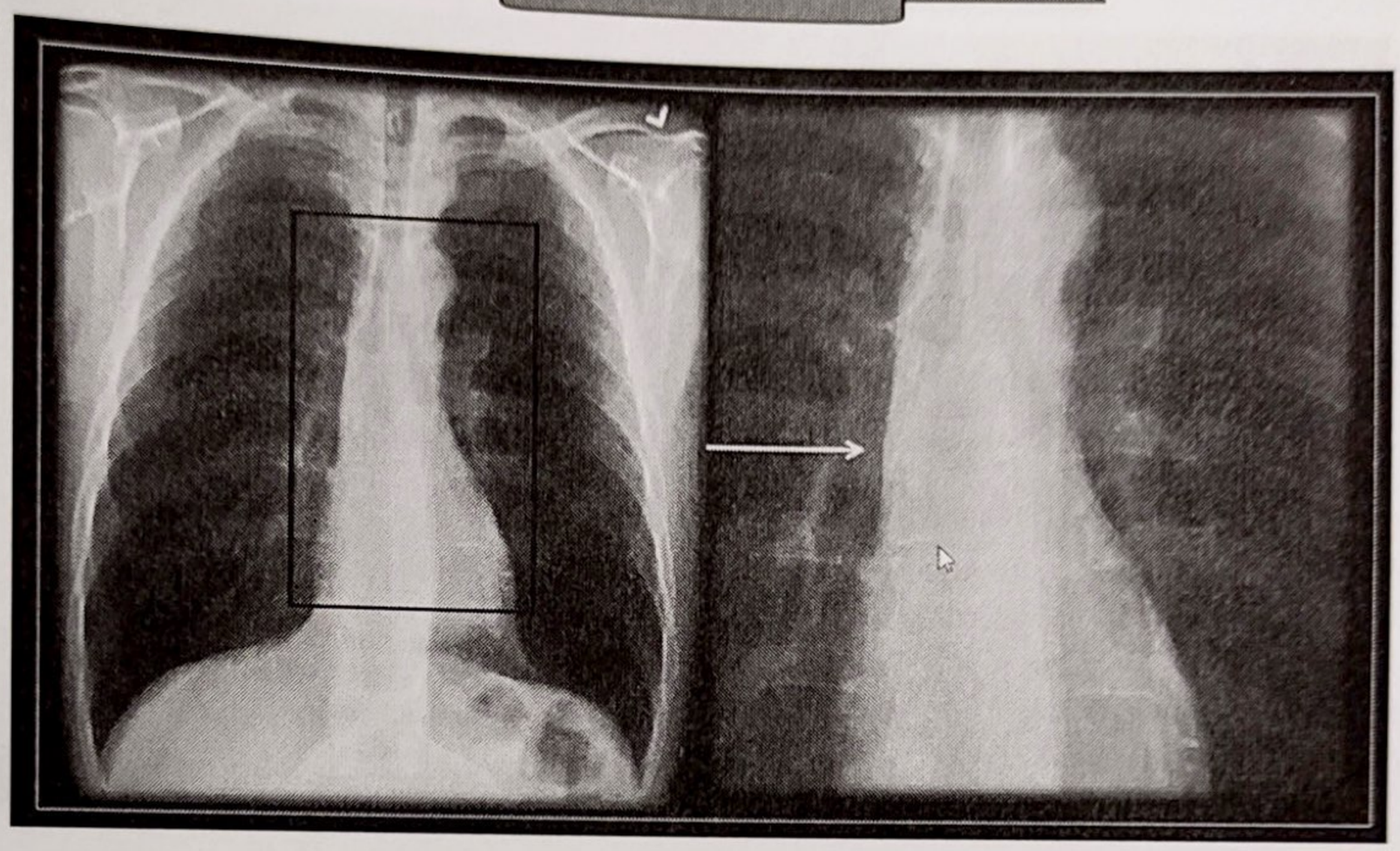

???

Soft film

Hard film

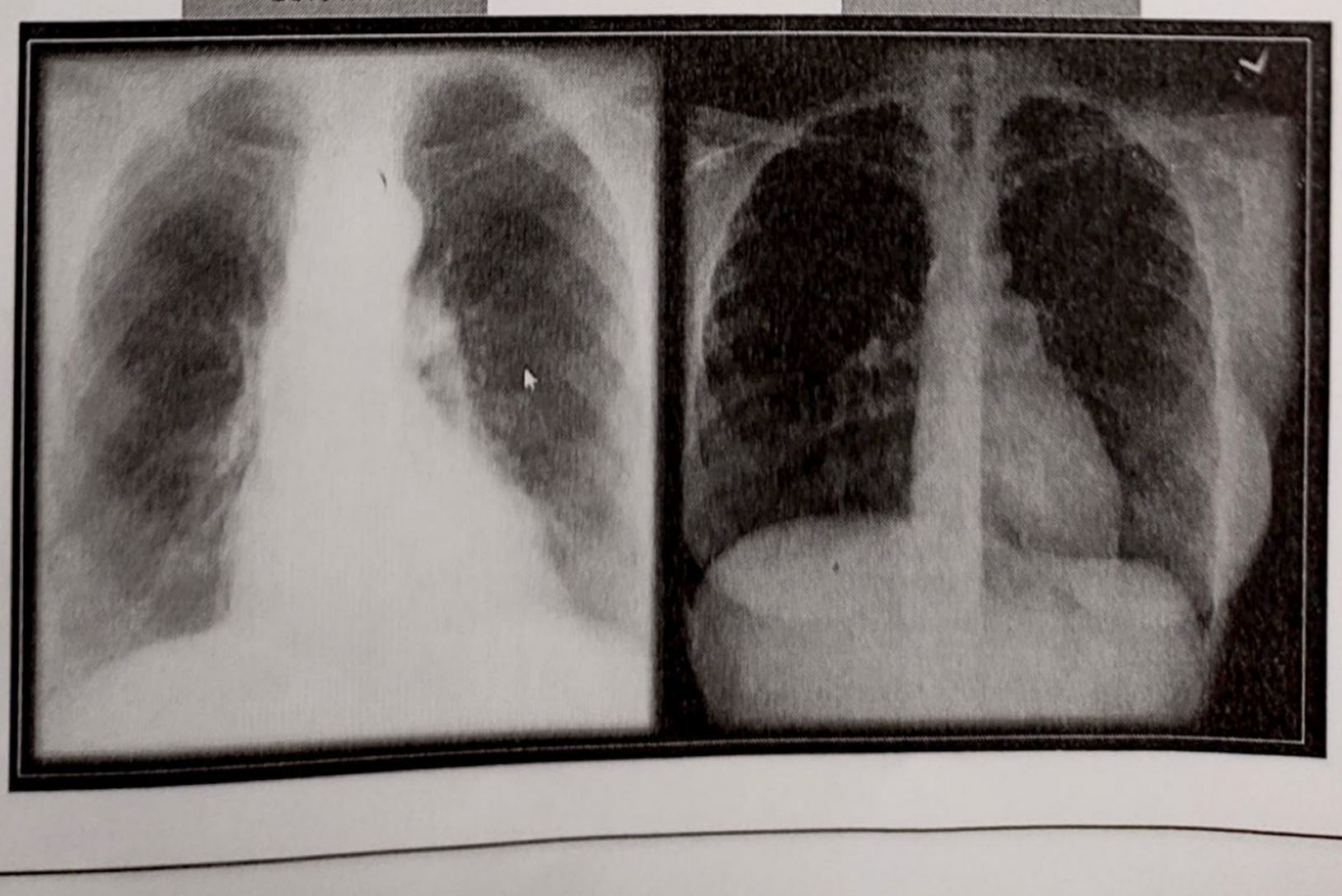

SHOT ON POCO X3

Scanned with CamScanner

READING SYSTEM

نطرح من براطوا

Rule Of 4

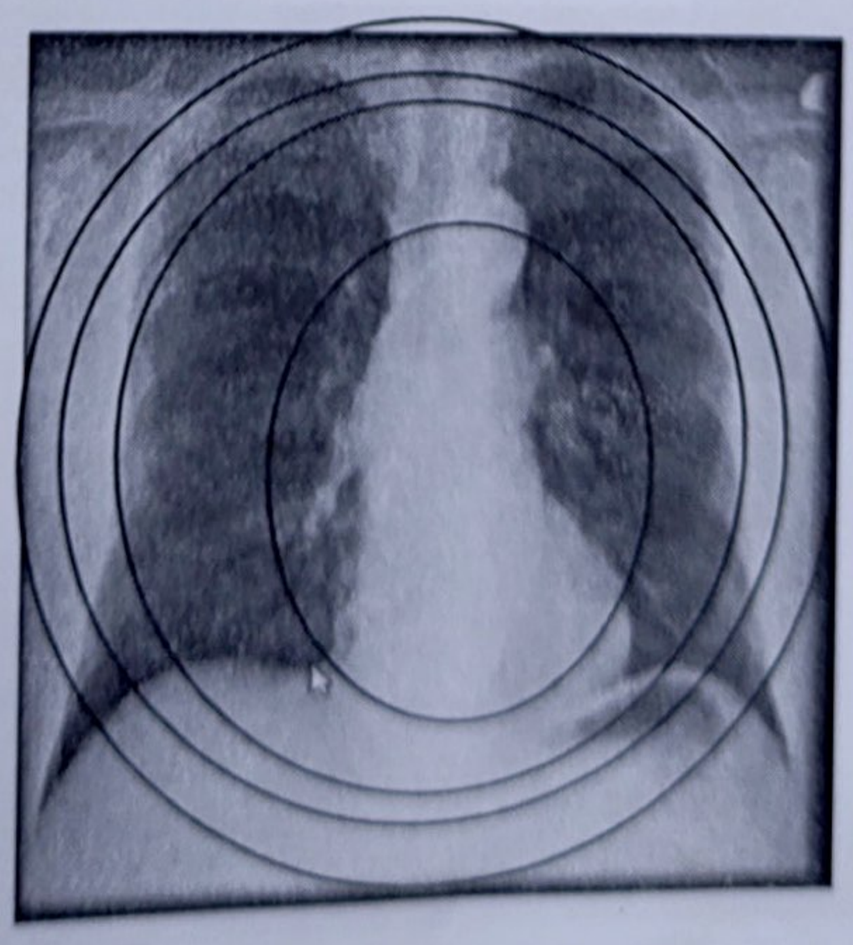

- Soft tissue
- Bony cage
- Lungs
- mediastinum

SHOT ON POCO X3

Scanned with CamScanner

هذا كت بلد

Surgical
apheresis

1

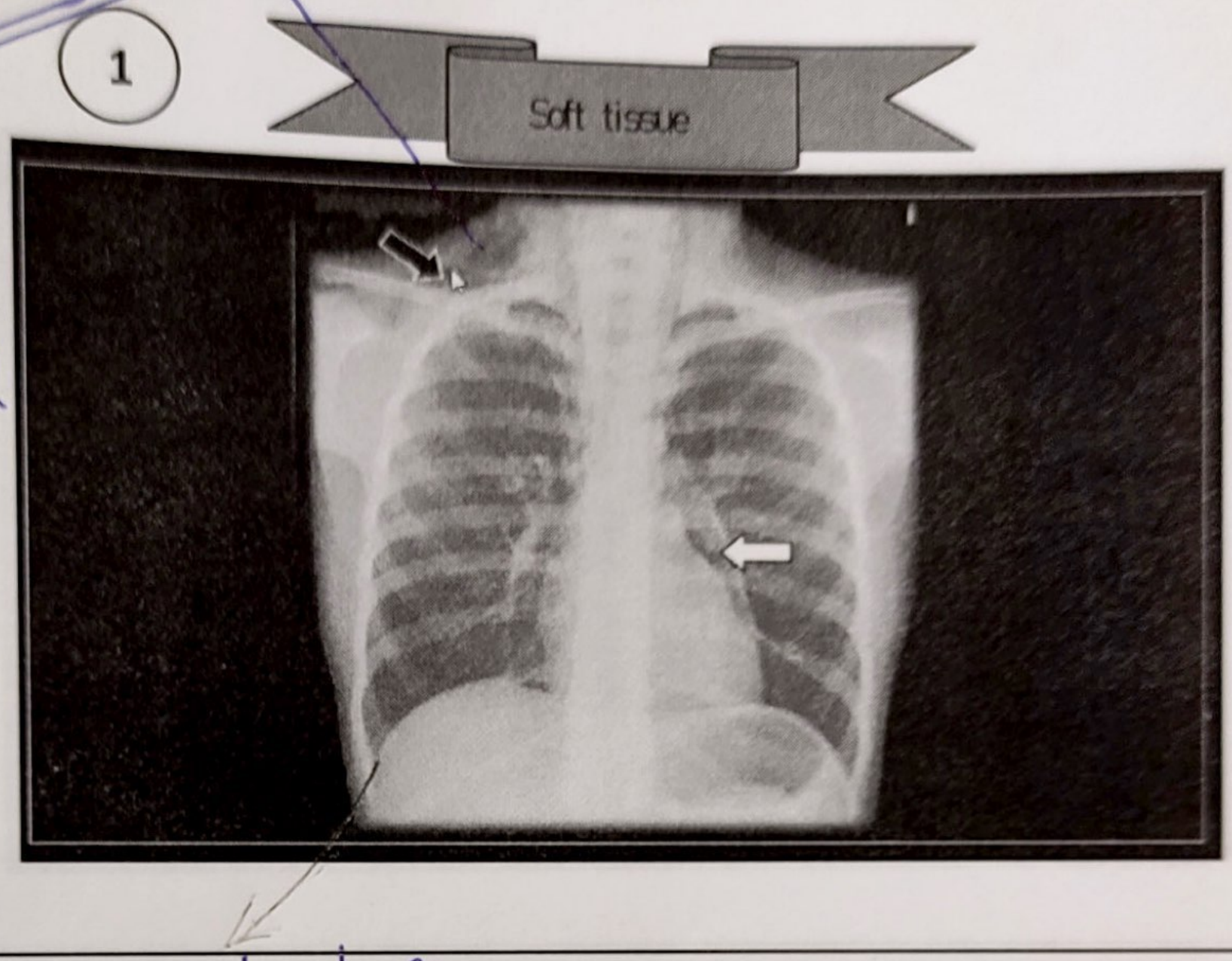

Thiers one
Side Mastectomy.

angle shape

2

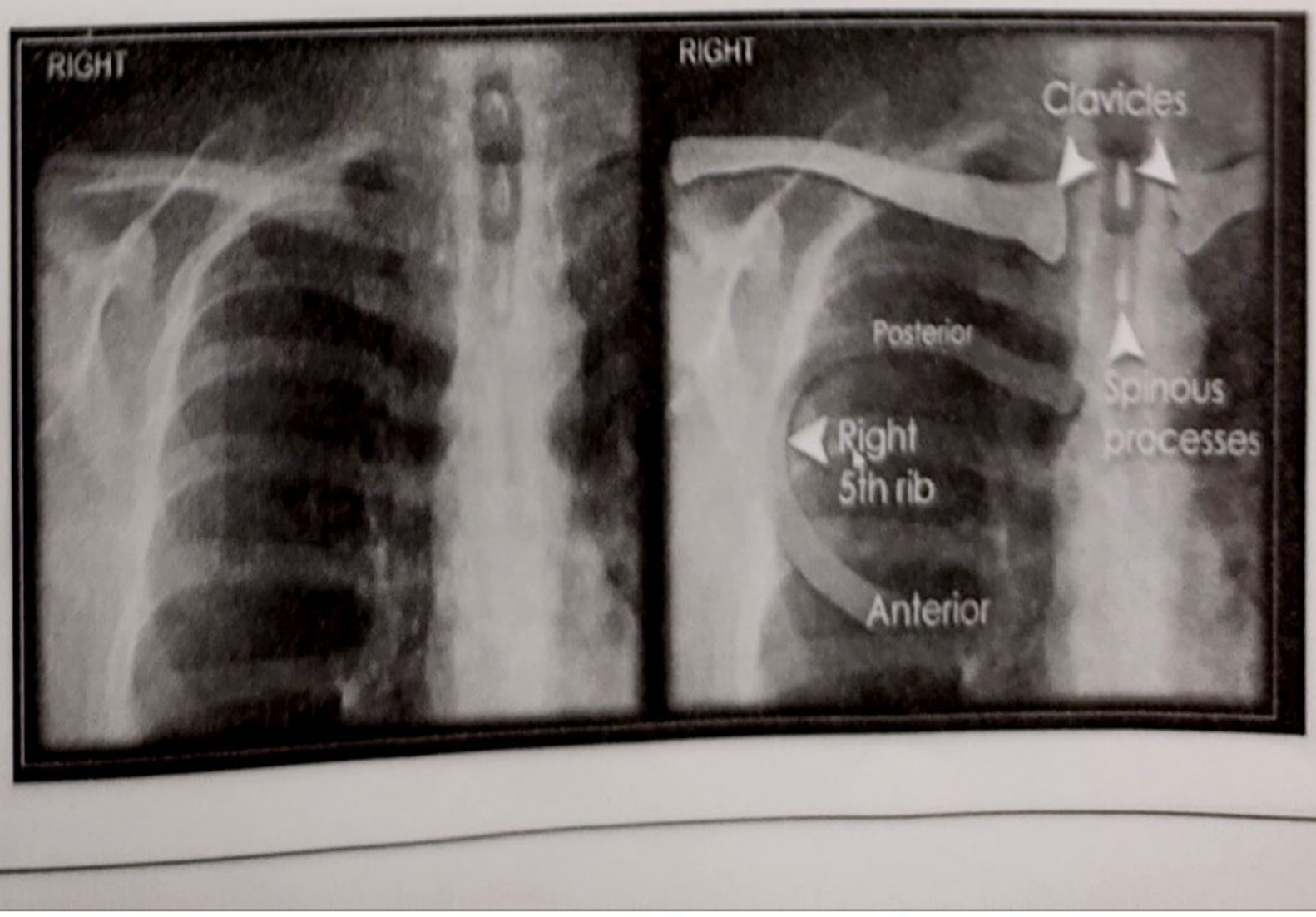

① Fracture
② pneumothorax
③ hydrothorax.

SHOT ON POCO X3

Scanned with CamScanner

28/07/1444

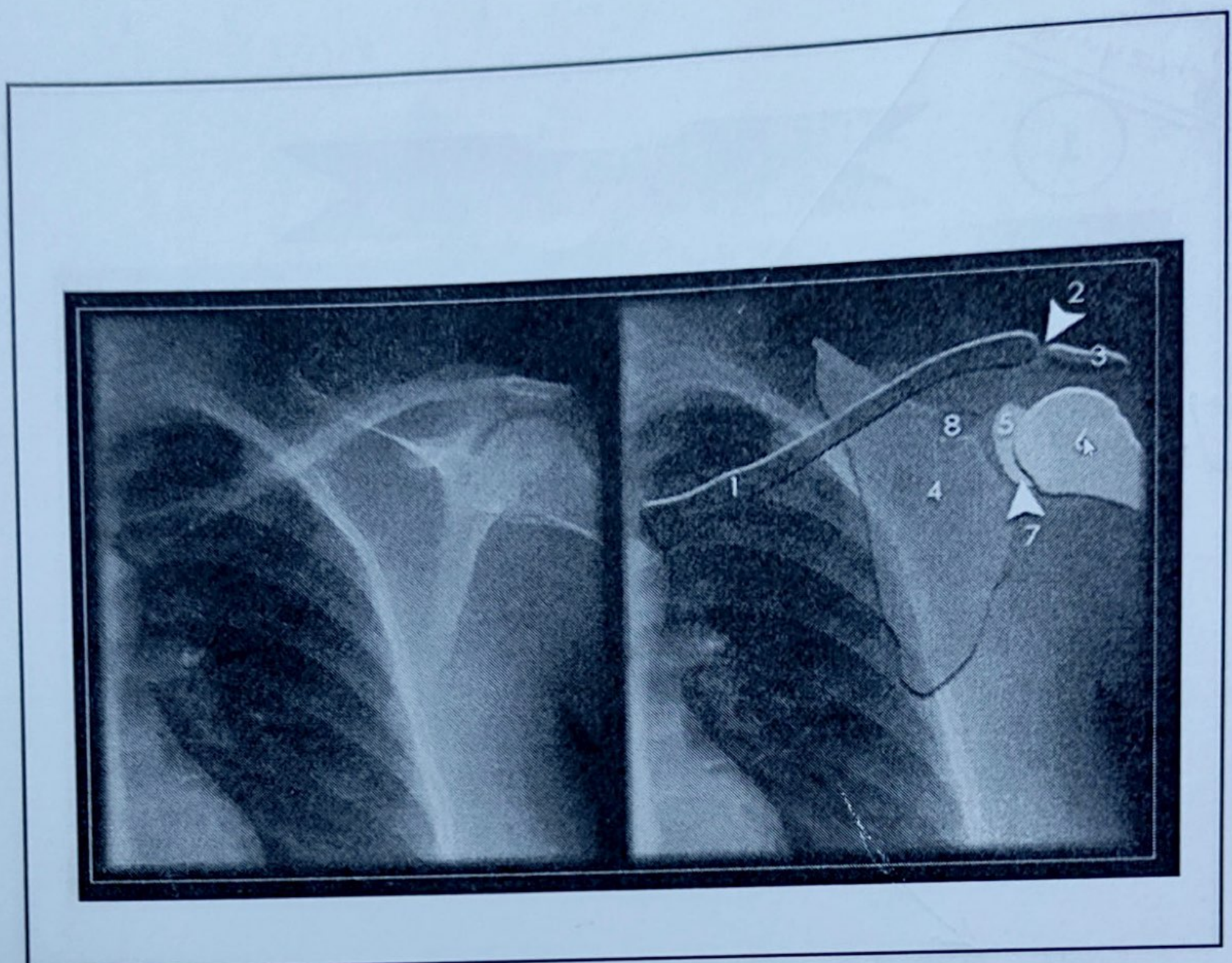

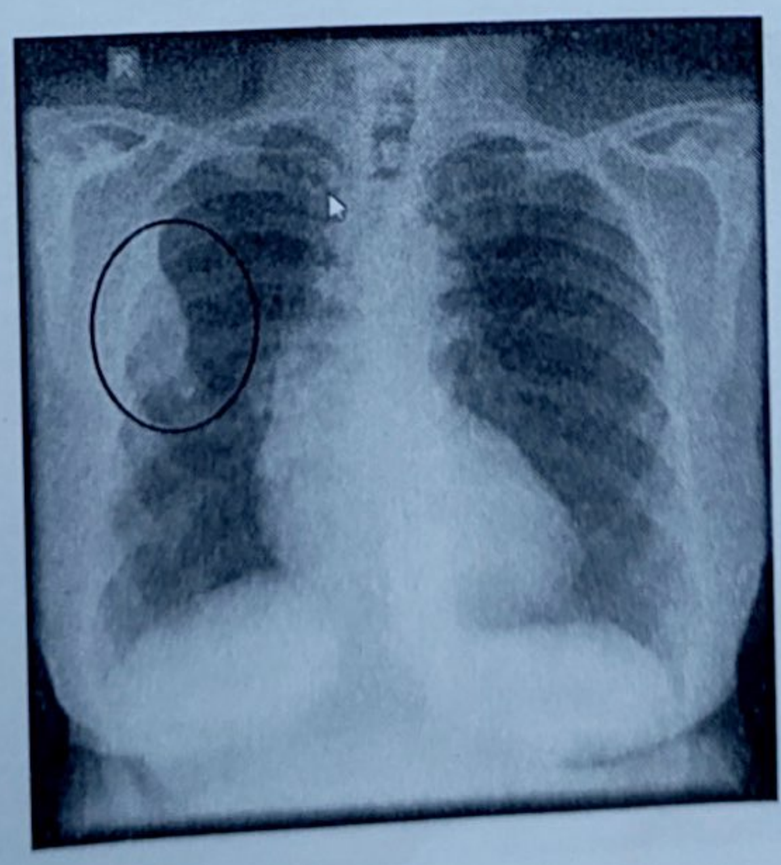

SHOT ON POCO X3

Scanned with CamScanner

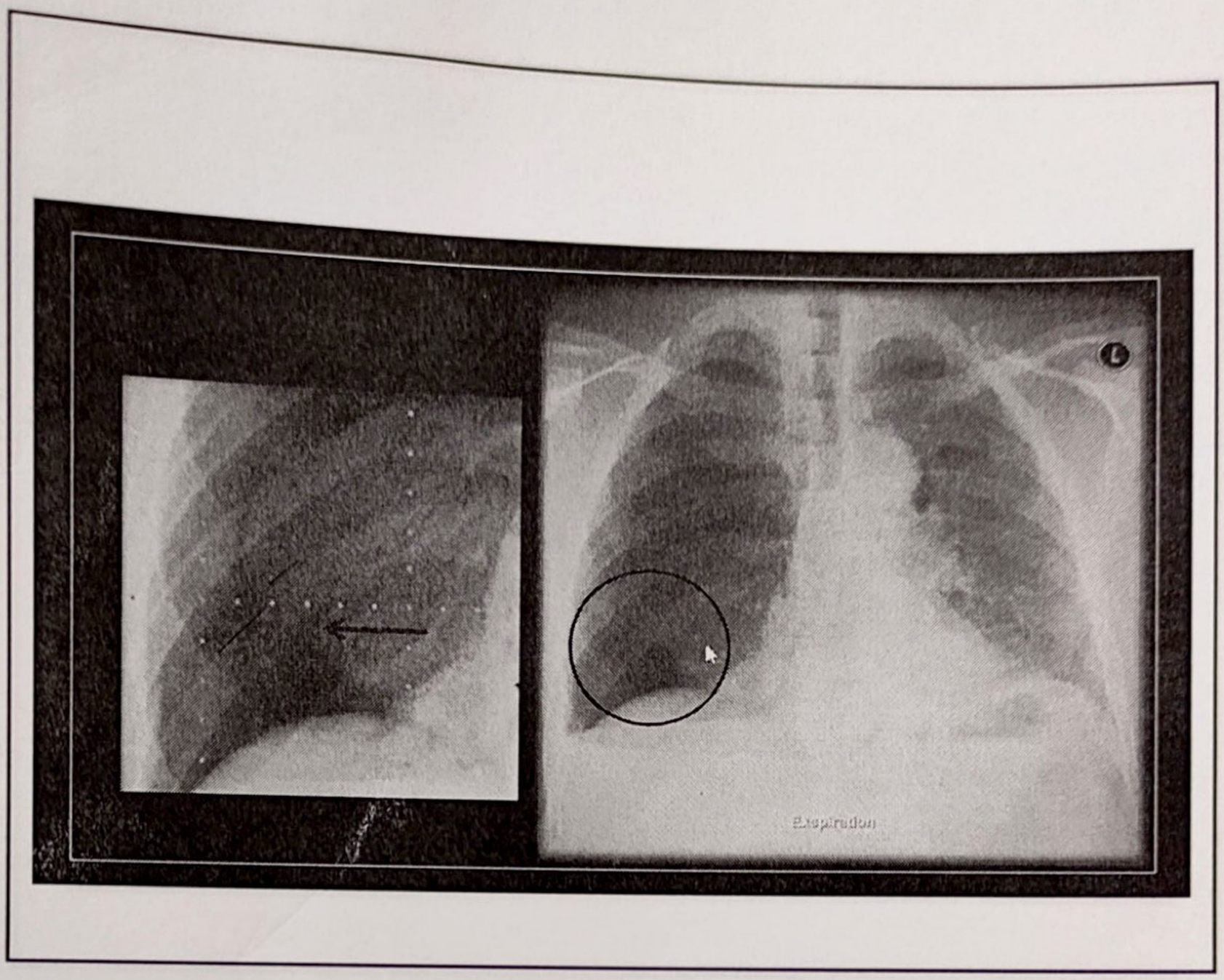

- Upper zone
- Middle zone
- lower zone.

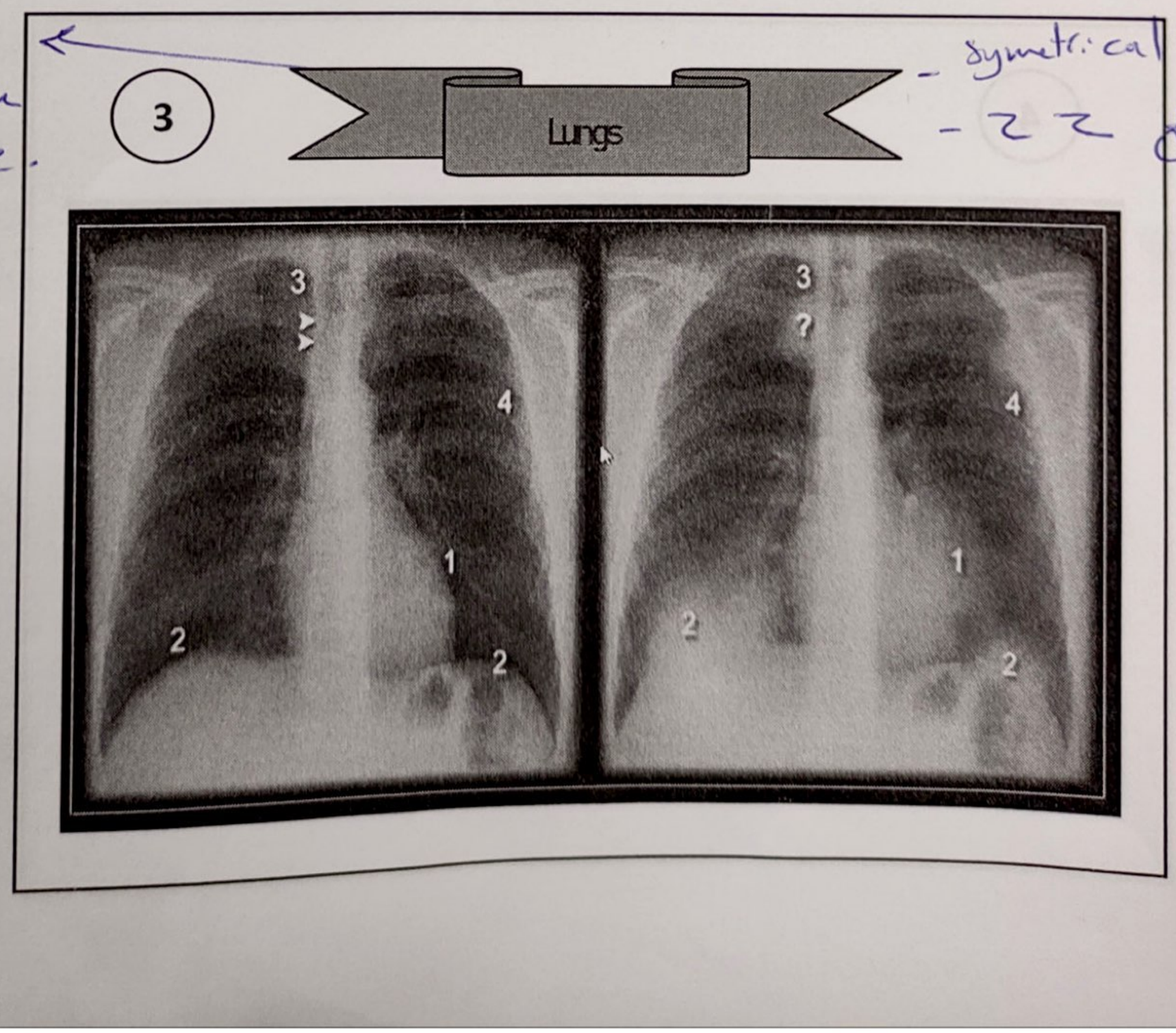

- symetrical
- ? ?

SHOT ON POCO X3

Scanned with CamScanner

28/07/1444

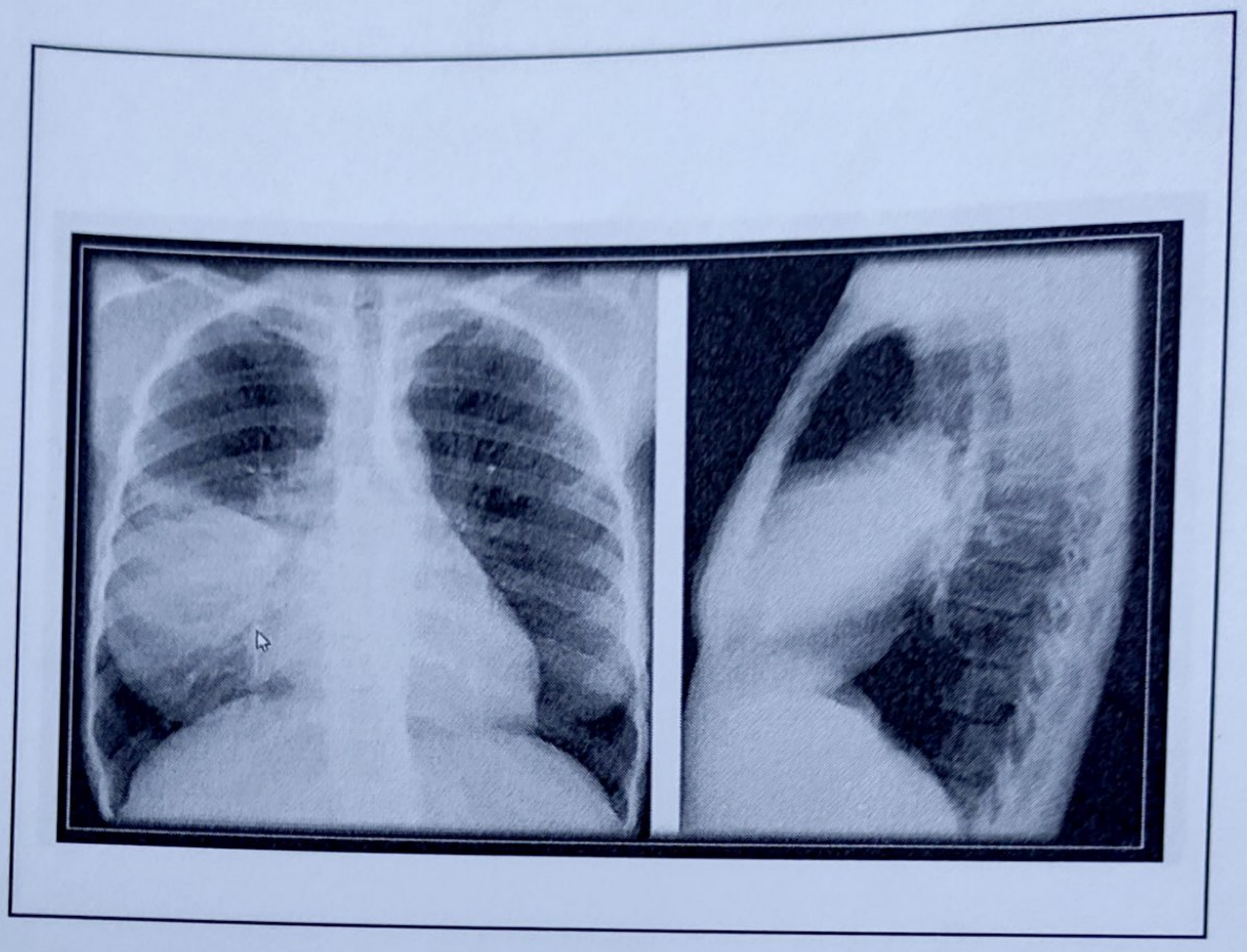

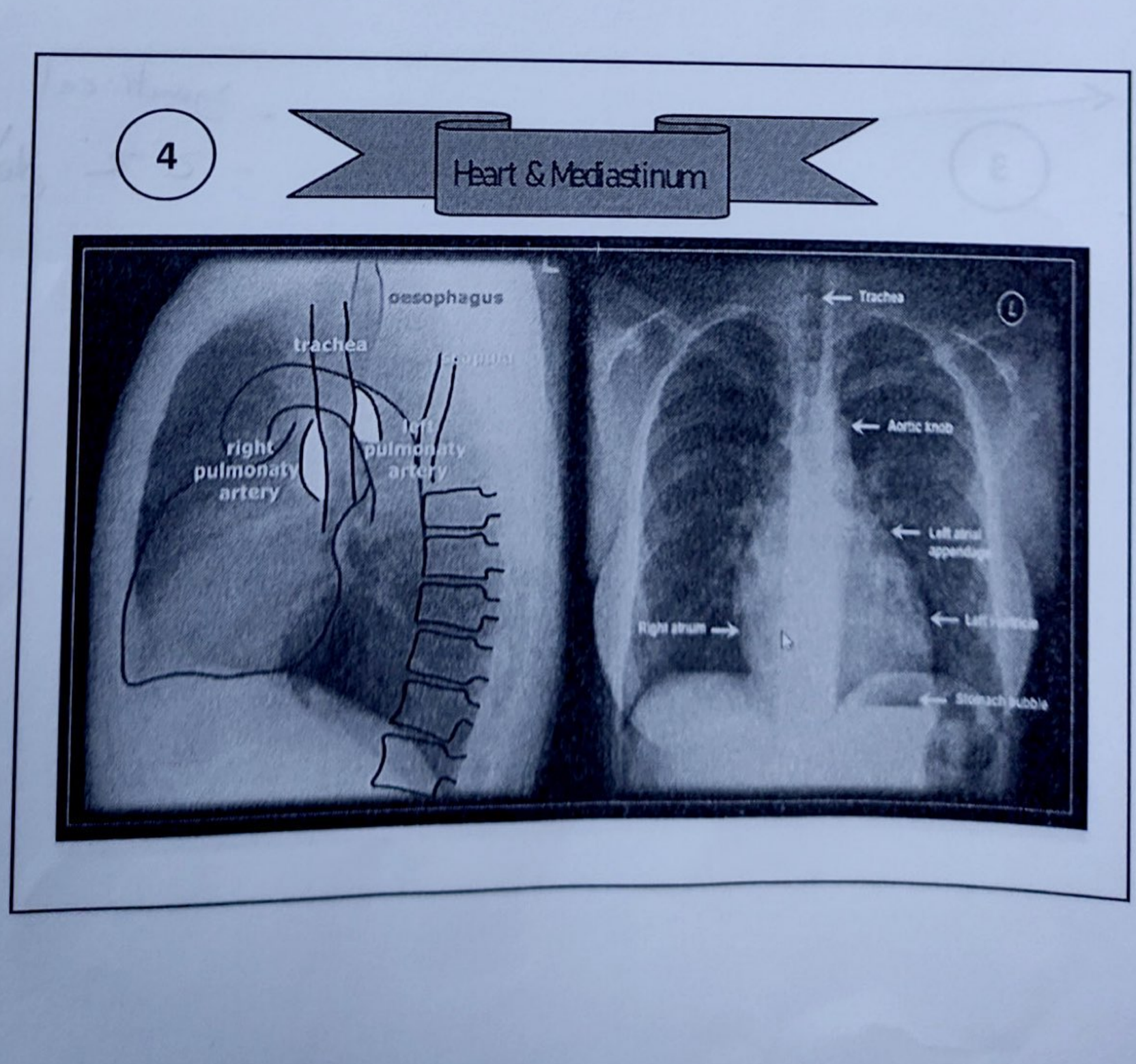

SHOT ON POCO X3

Scanned with CamScanner

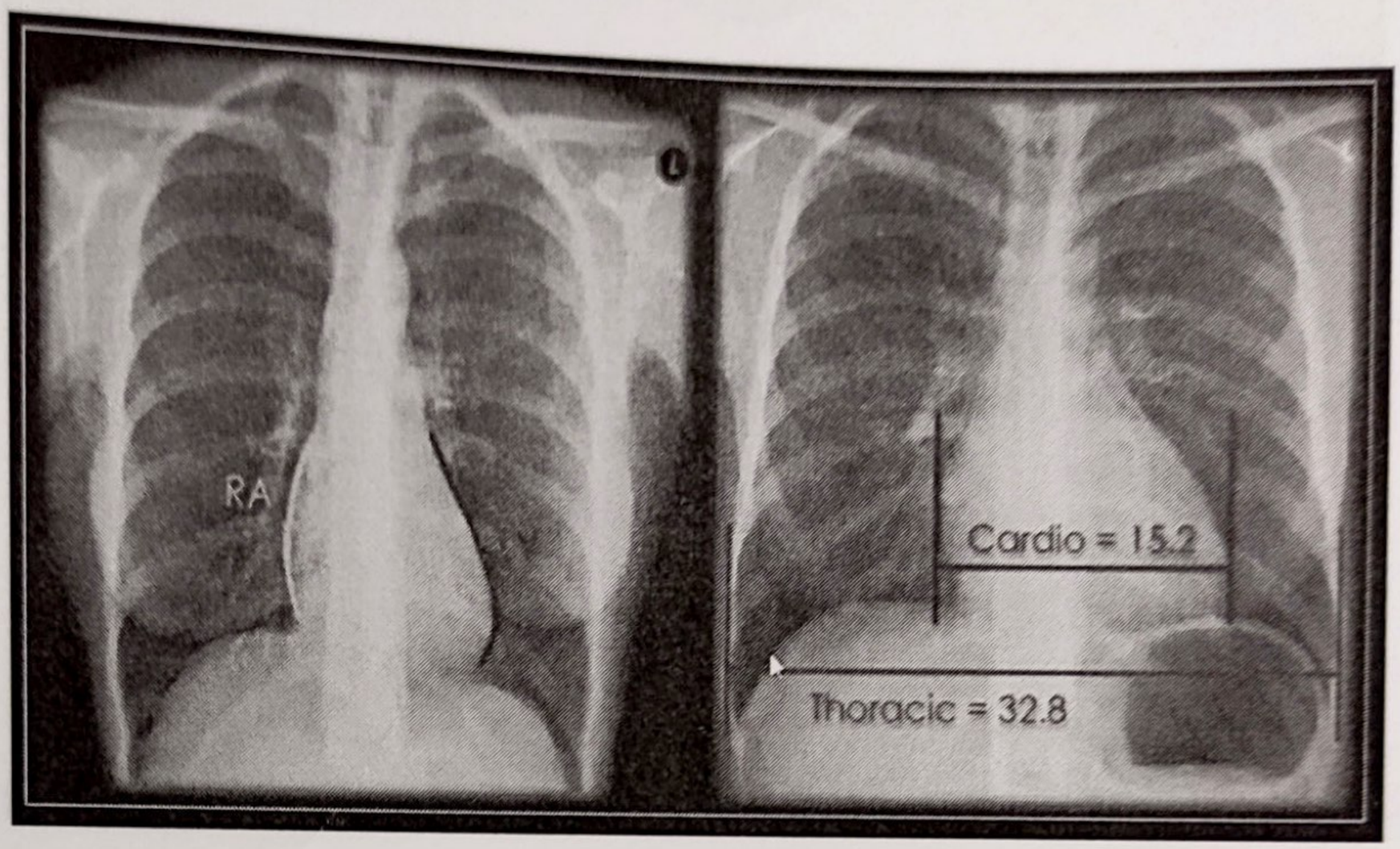

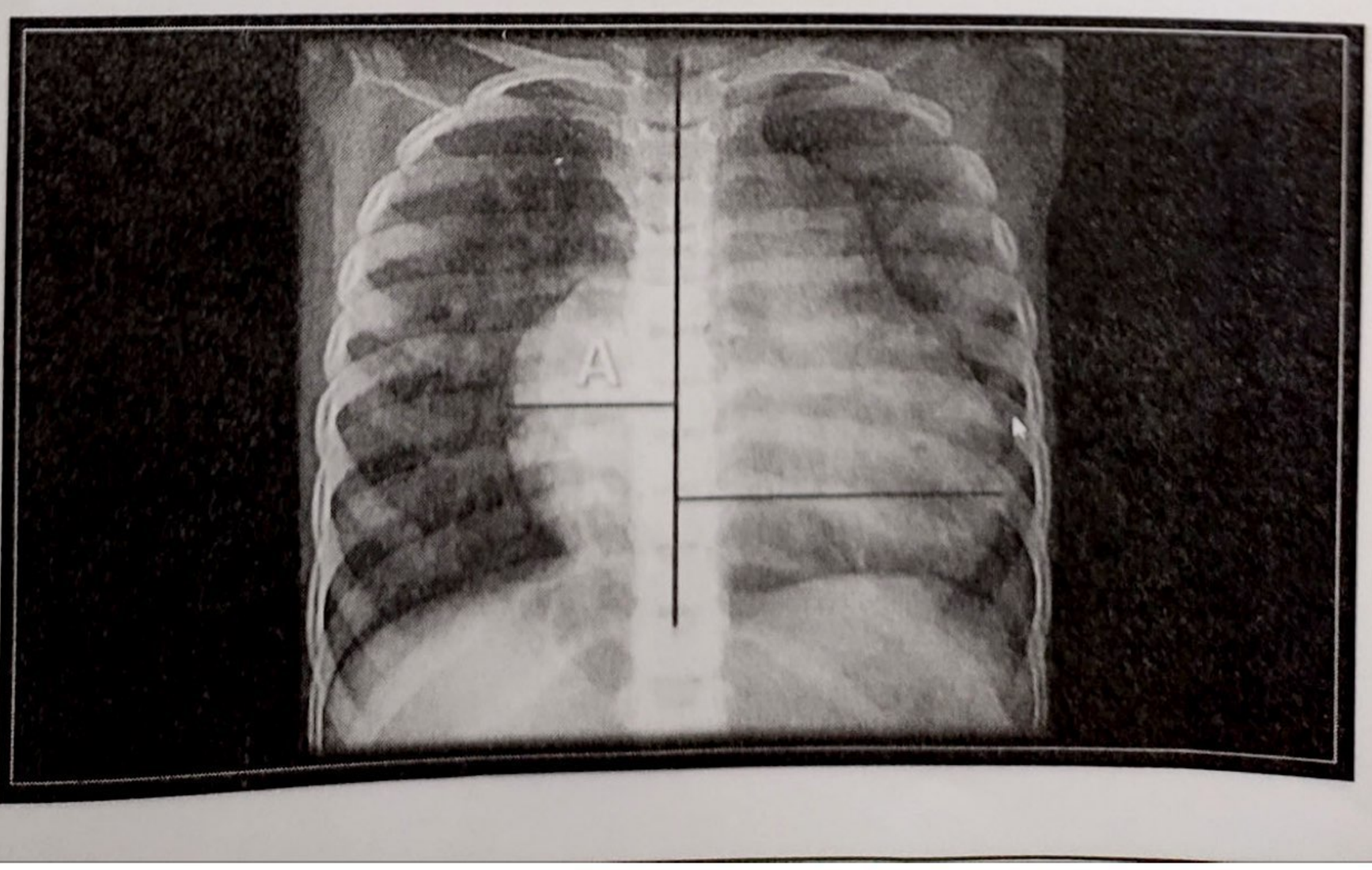

SHOT ON POCO X3

Scanned with CamScanner

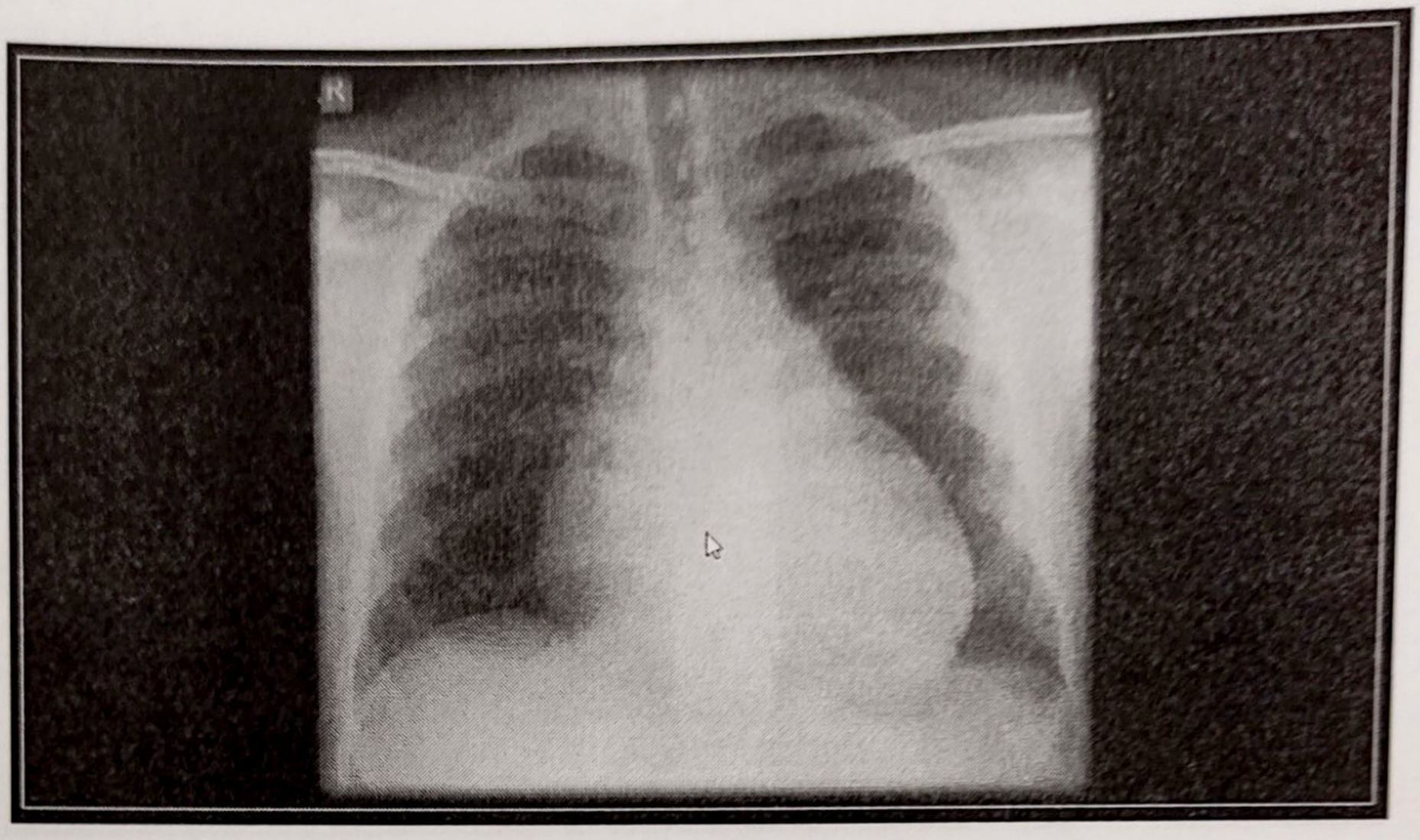

HIDDEN AREAS

SHOT ON POCO X3

Scanned with CamScanner

H.A.H.A.

- Checking the four tricky hidden areas: apices ( ), superimposed over the heart (green), around each hilum (yellow) & area below the domes of the diaphragm (blue).

- It has been shown that these are the four sites where small (and also large) lesions are most commonly overlooked.

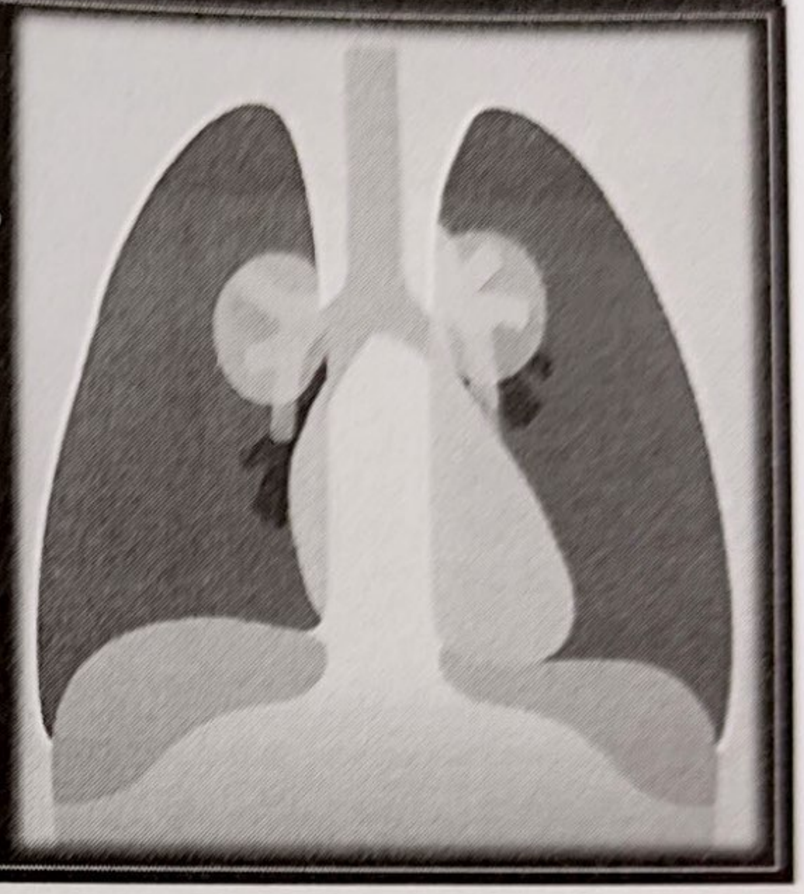

1

Hlum

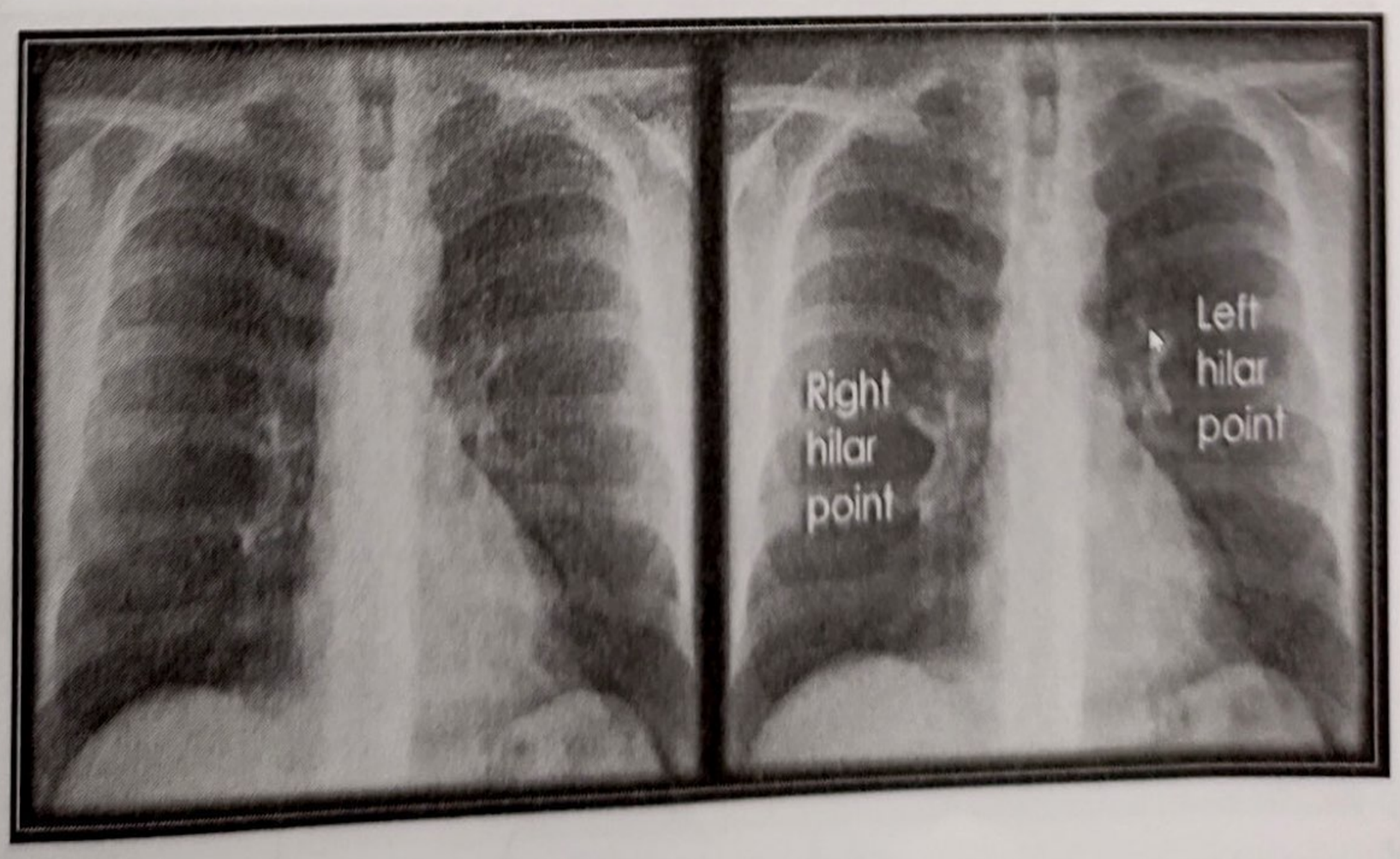

SHOT ON POCO X3

Scanned with CamScanner

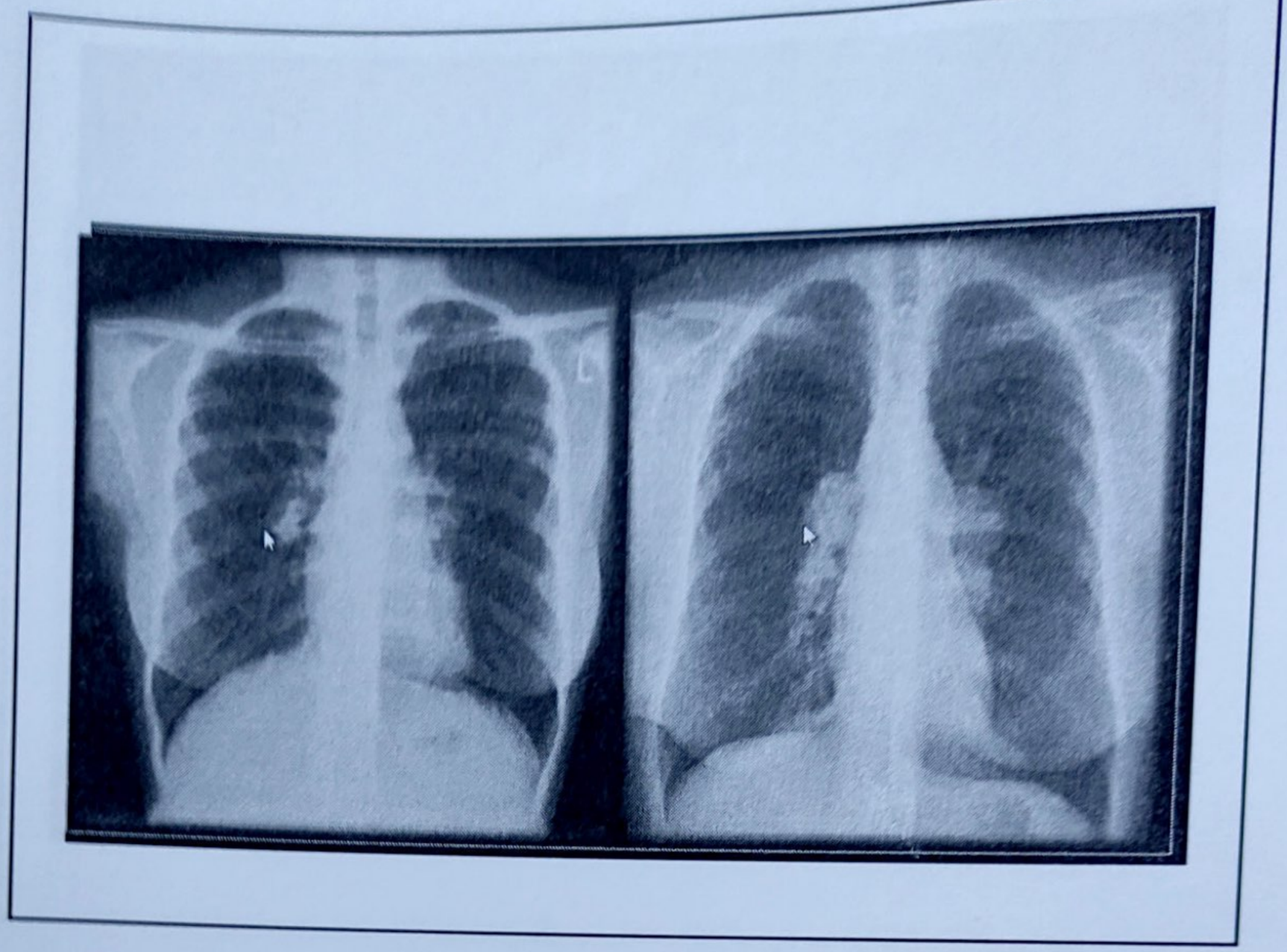

clavical موضع

جسم ان بنشط

يحل expiration.

Capiratoy

① foreign body in trachea.

لتفريغ

pneumothorax.

SHOT ON POCO X3

Scanned with CamScanner

pan cost tumor.

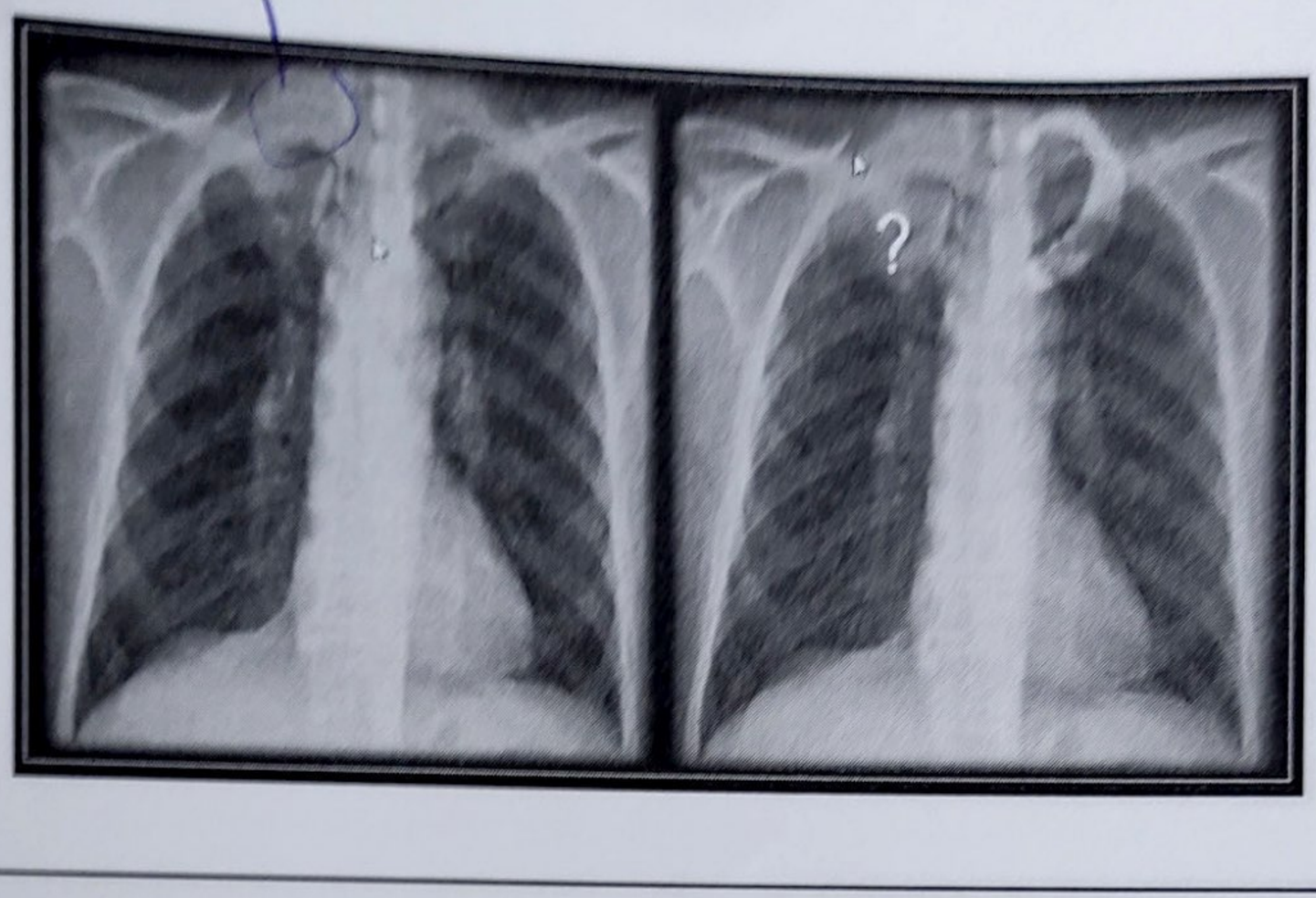

3

Heart

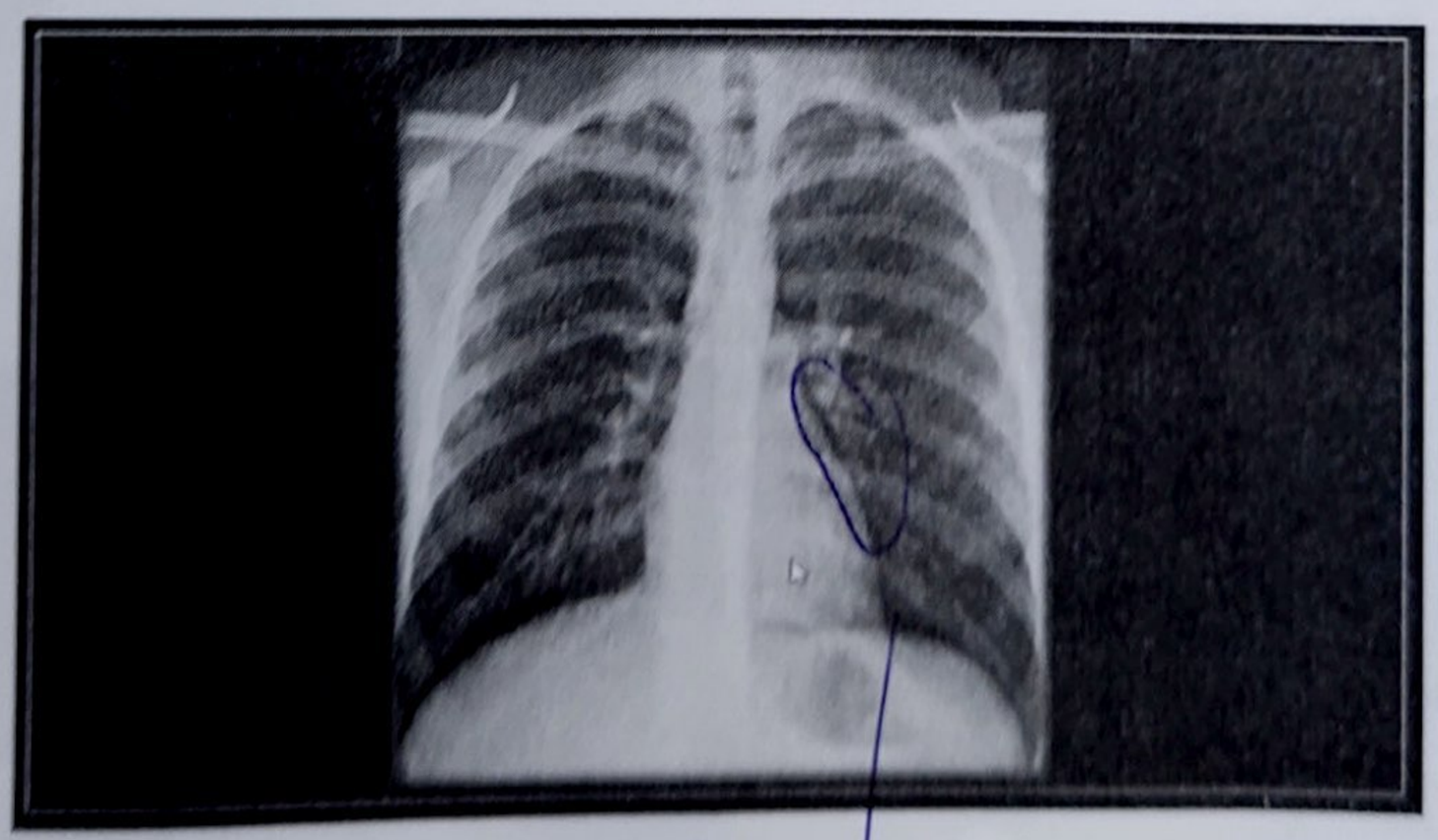

air fluid level → abscess

↓

RLG

hiatus hernia.

SHOT ON POCO X3

Scanned with CamScanner

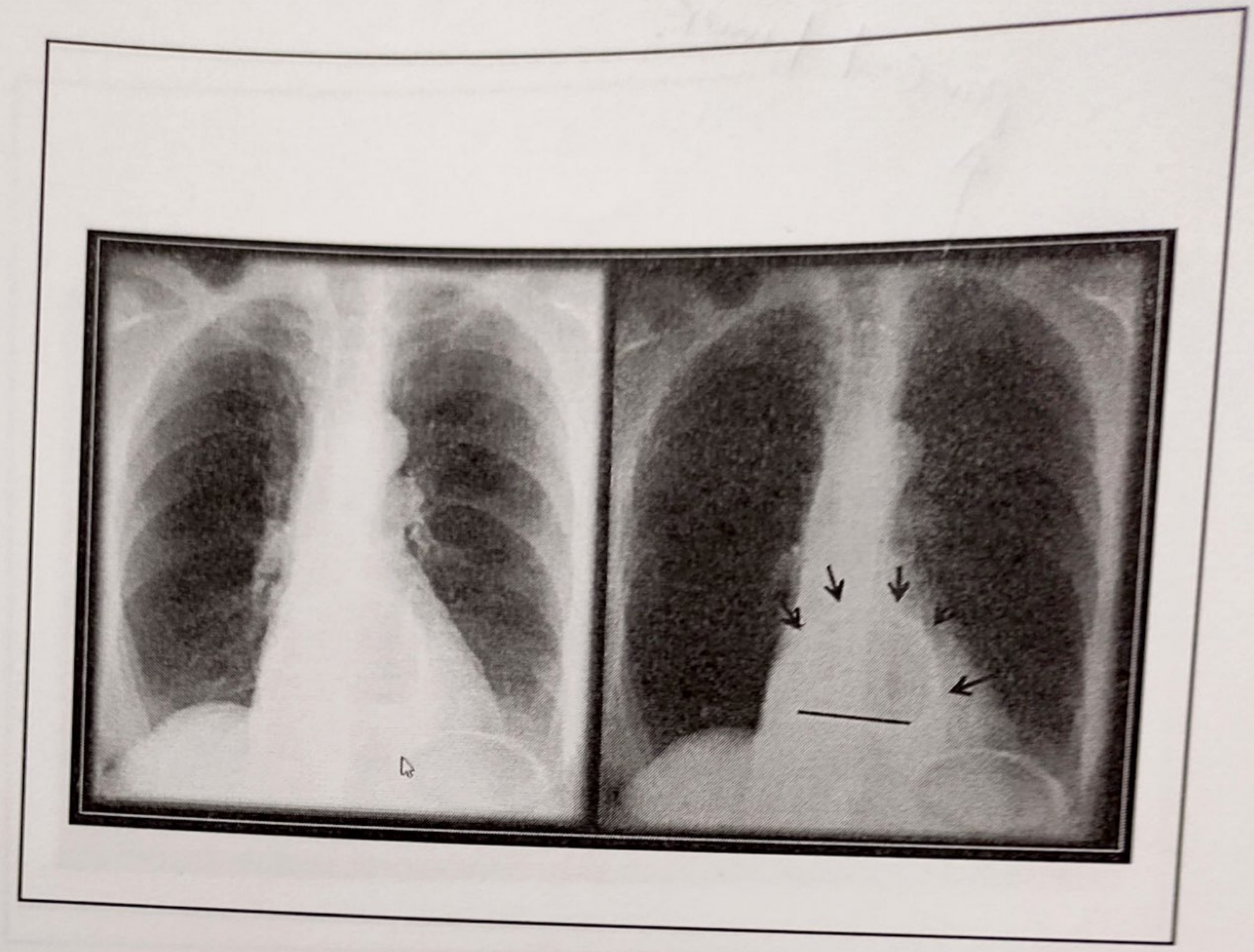

4

Area below Diaphragm

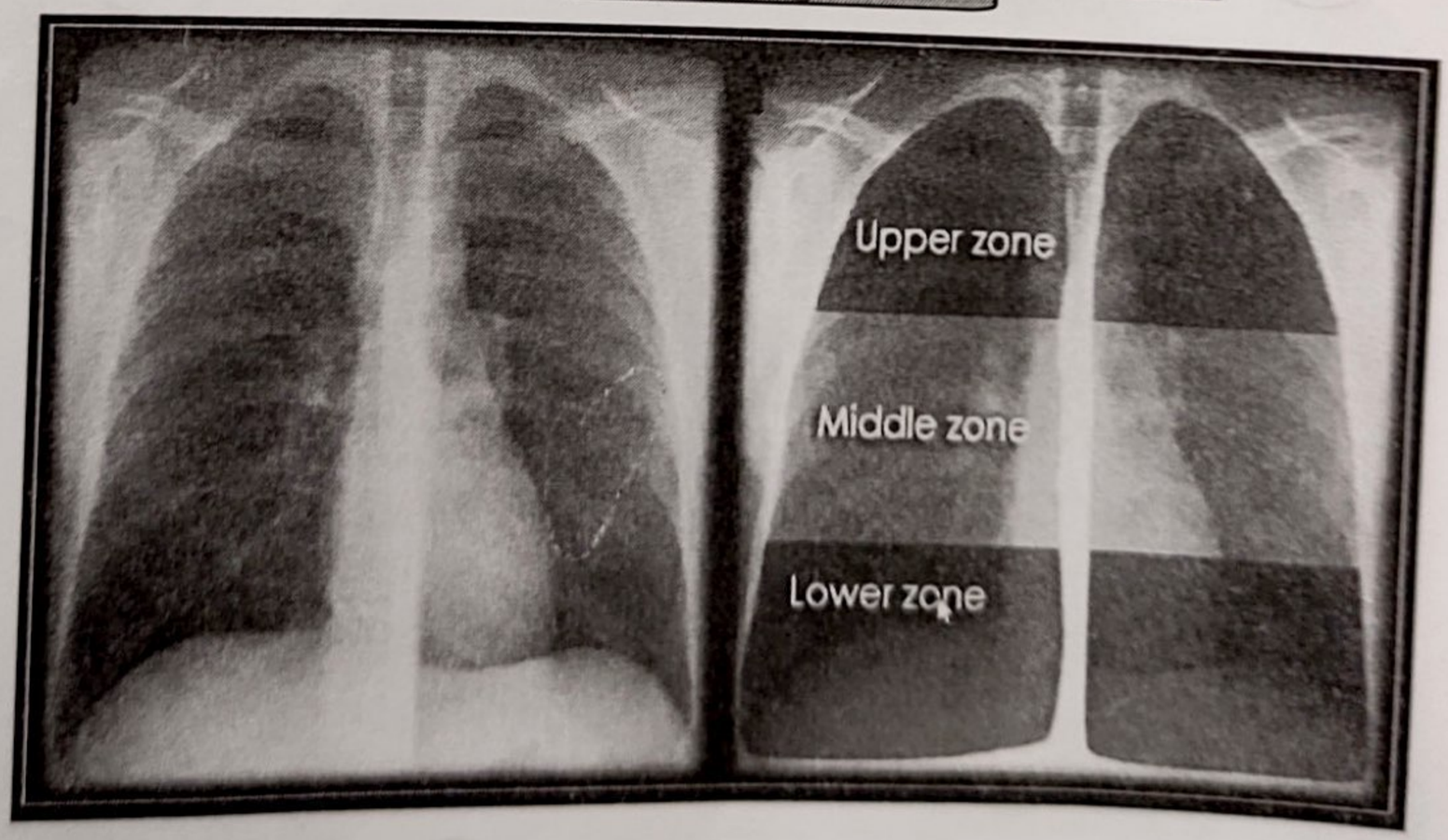

SHOT ON POCO X3

Scanned with CamScanner

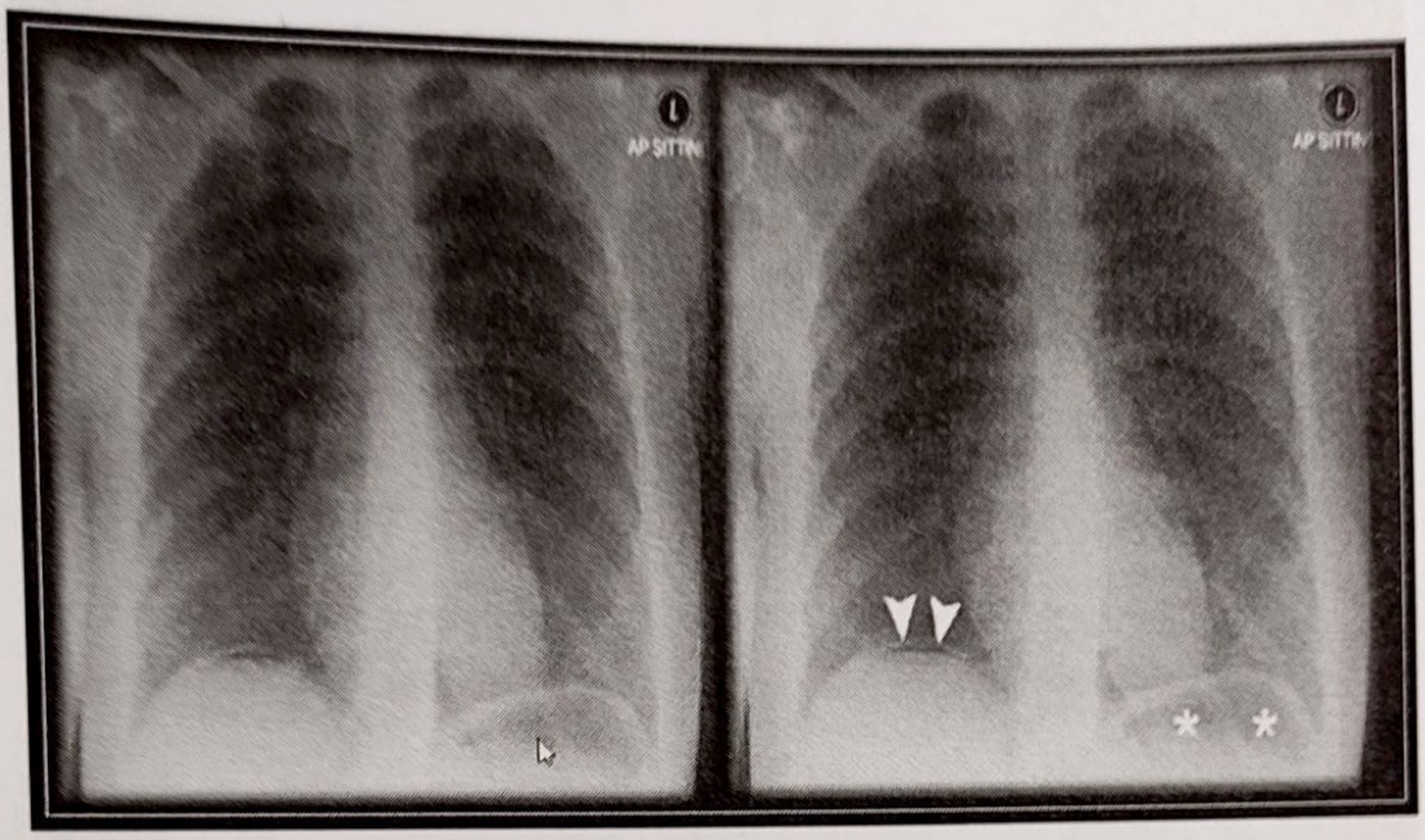

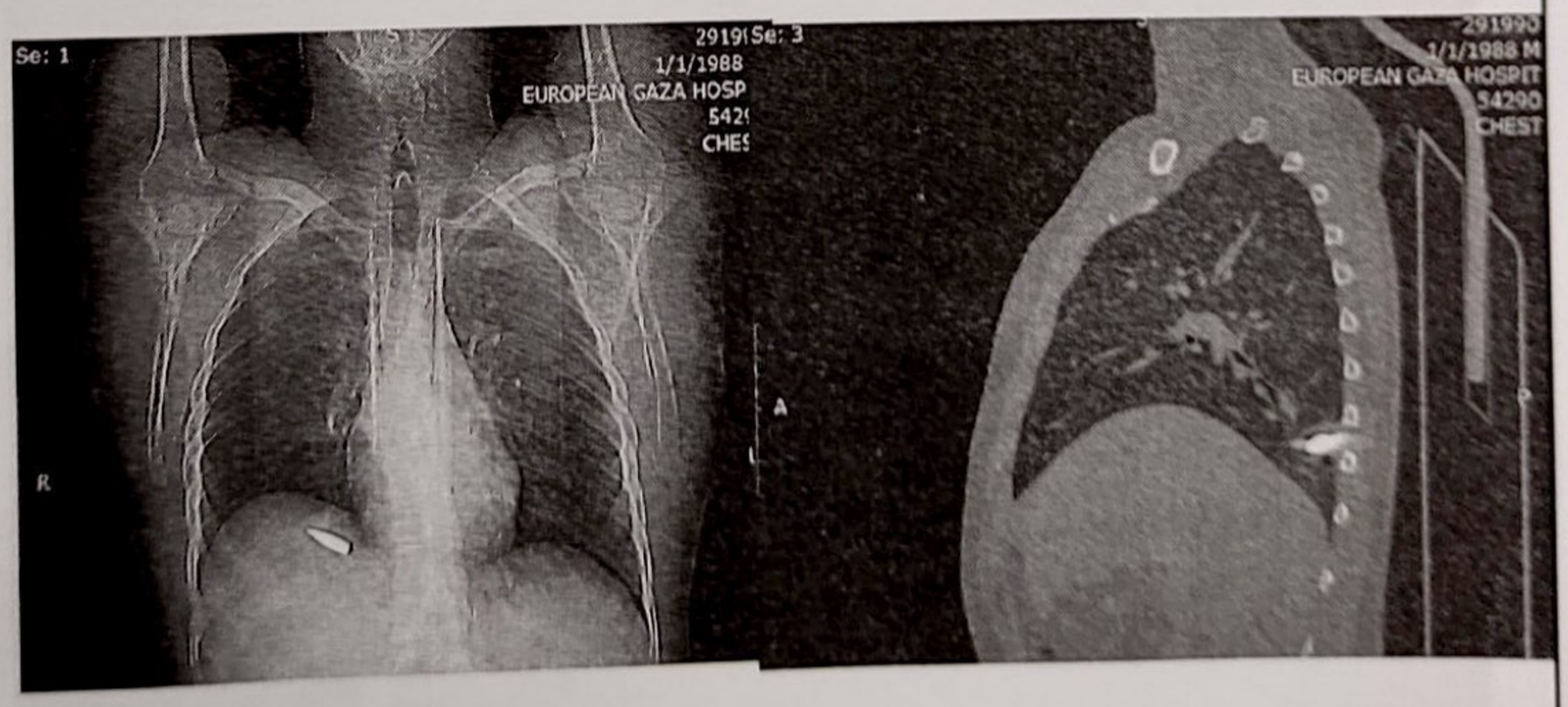

SHOT ON POCO X3

Scanned with CamScanner

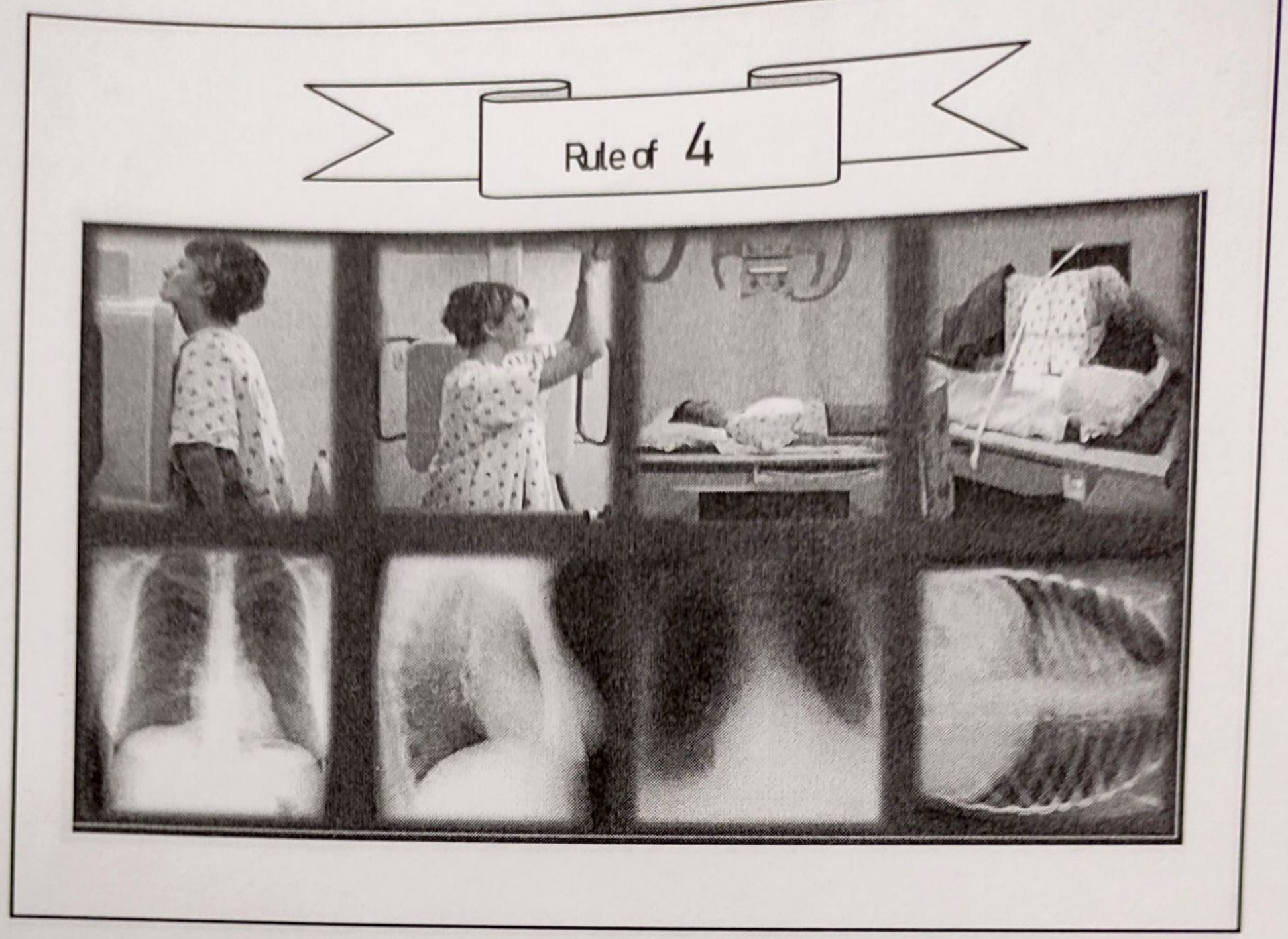

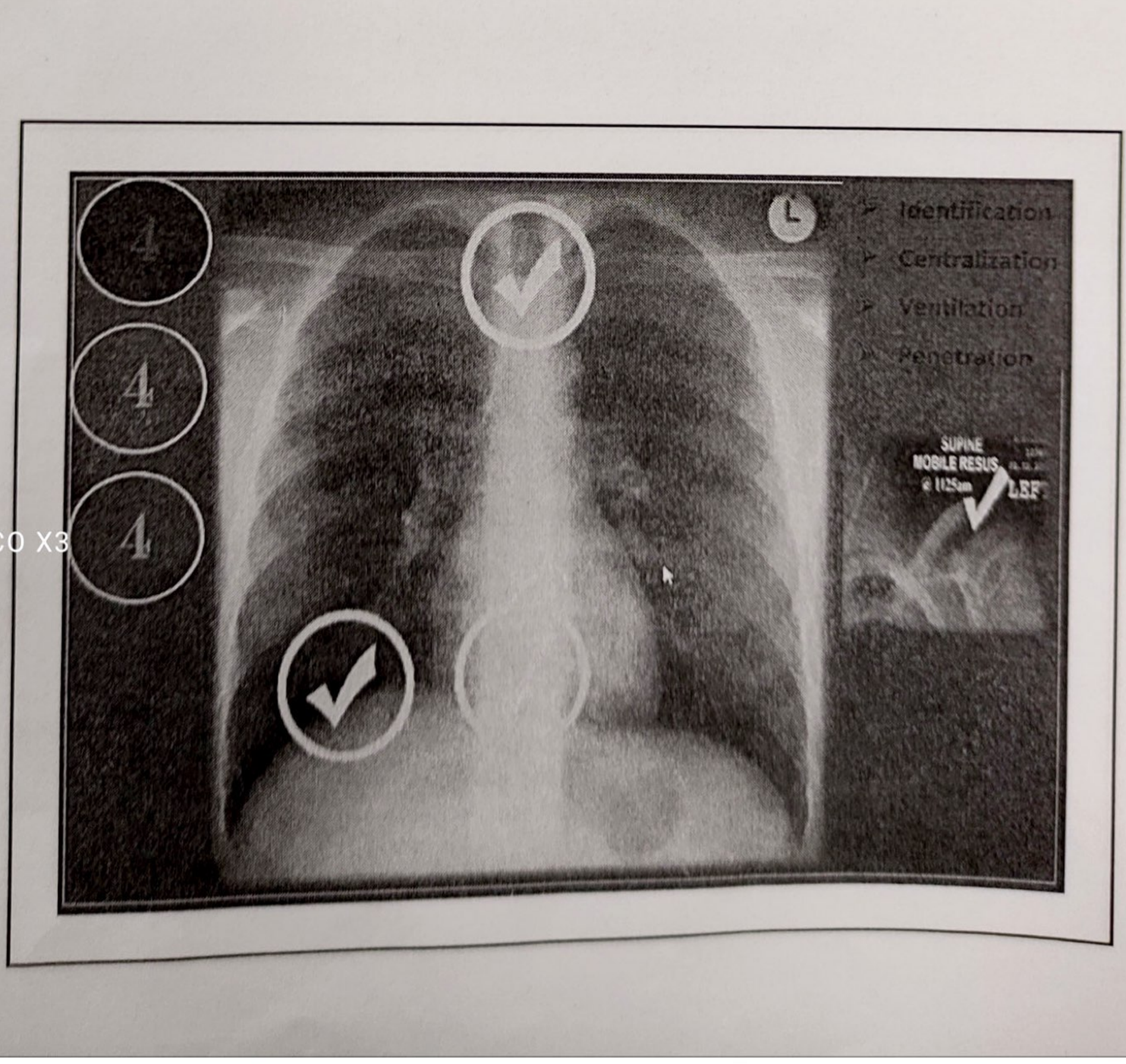

SHOT ON POCO X3

Scanned with CamScanner

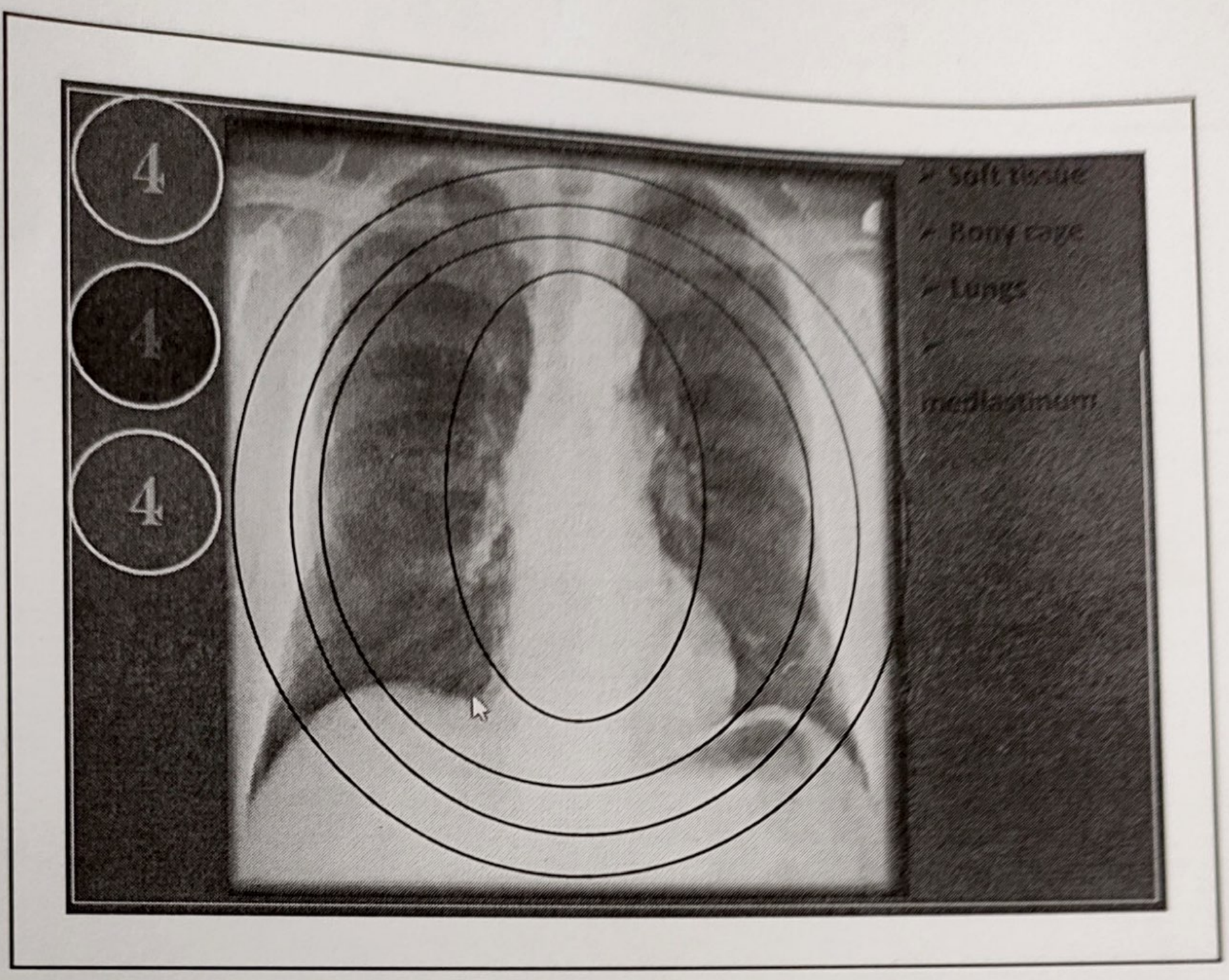

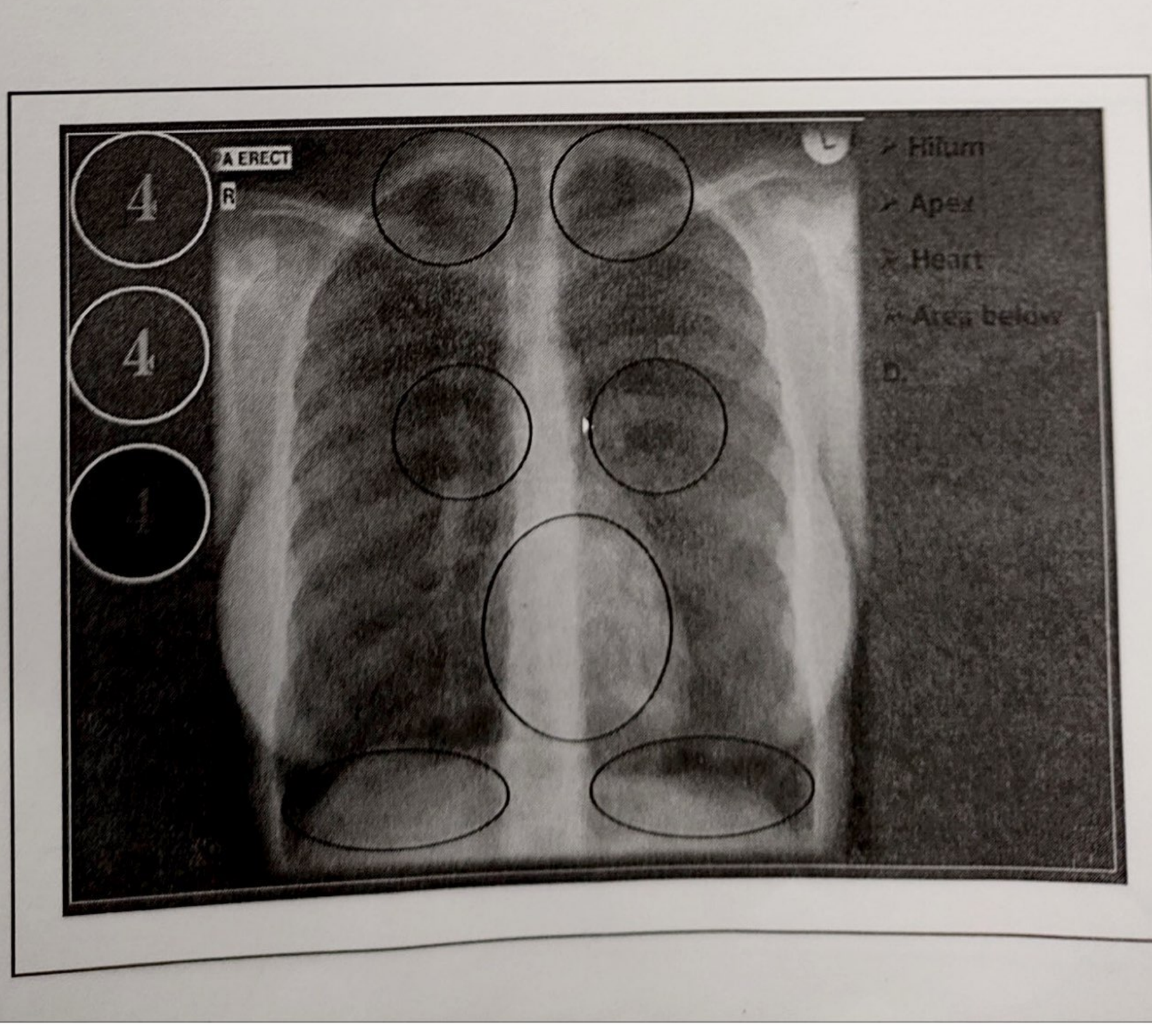

SHOT ON POCO X3

Scanned with CamScanner

HOW TO READ CHEST X-RAY



2

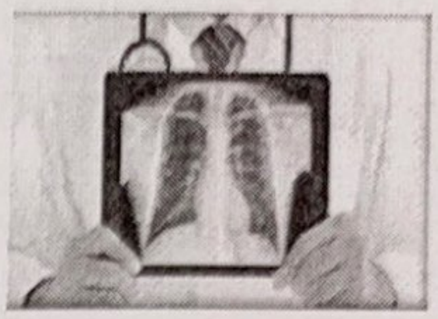

Dr Marwan Matar

Consultant Radiologist

PATTERN APPROACH

Low Attenuation

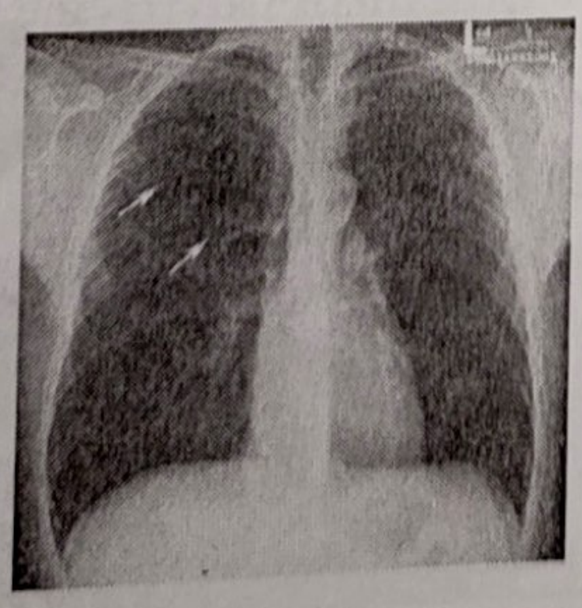

High Attenuation

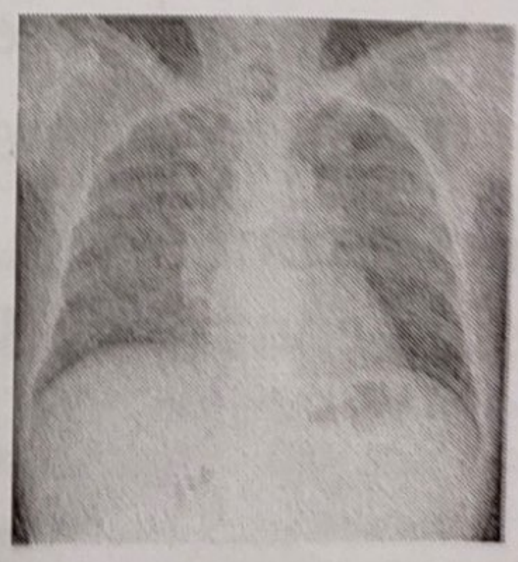

SHOT ON POCO X3

Scanned with CamScanner

HIGH ATTENUATION PATTERNS

4

1. Consolidation
2. Atelectasis
3. Interstitial
4. Nodules and masses

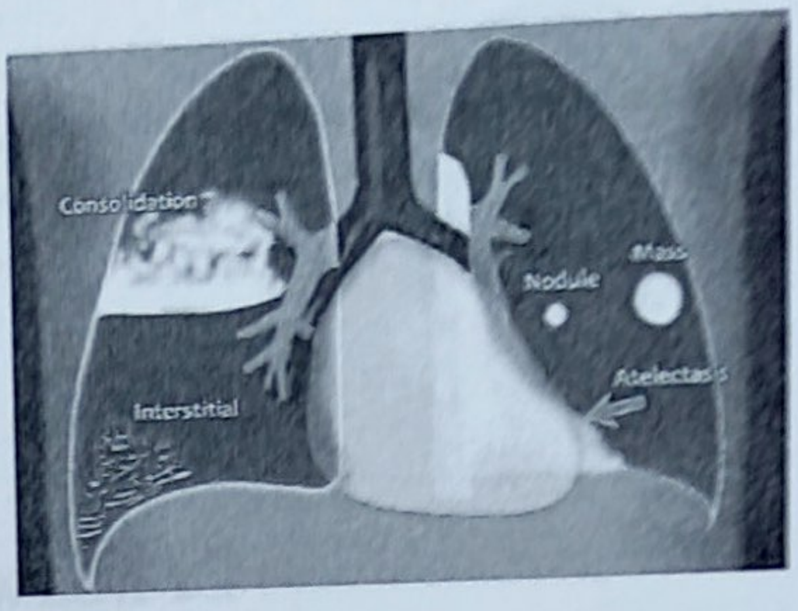

ACINI

- Structural unit of the lung distal to a terminal bronchiole
- **Contains :** Alveolar ducts & Alveoli

The largest unit in which all airways participate in gas exchange

- 6-10 mm in diameter.
- One secondary pulmonary lobule contains : 3 : 25 acini





SHOT ON POCO X3

Scanned with CamScanner

1

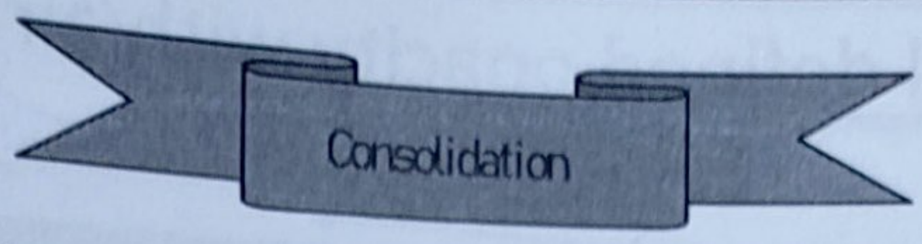

- **Definition** - any pathologic process that fills the alveoli with fluid, pus, blood, cells or other substances resulting in lobar, diffuse or multifocal ill-defined opacities

- When it reaches a fissure the spread stops there

- Pneumonia is by far the most common cause of consolidation .

The key-findings on the X-ray are:

1. ill-defined homogeneous opacity obscuring vessels
2. Silhouette sign: loss of lung/soft tissue interface
3. Air-bronchogram
4. Extention to the pleura or fissure, but not crossing it
5. No volume loss

SHOT ON POCO X3

Scanned with CamScanner

لو مدرك تكون حصلها
Mass ← nodule
nodule ←

Ill defined opacity with air bronchogram

not alleolitesis

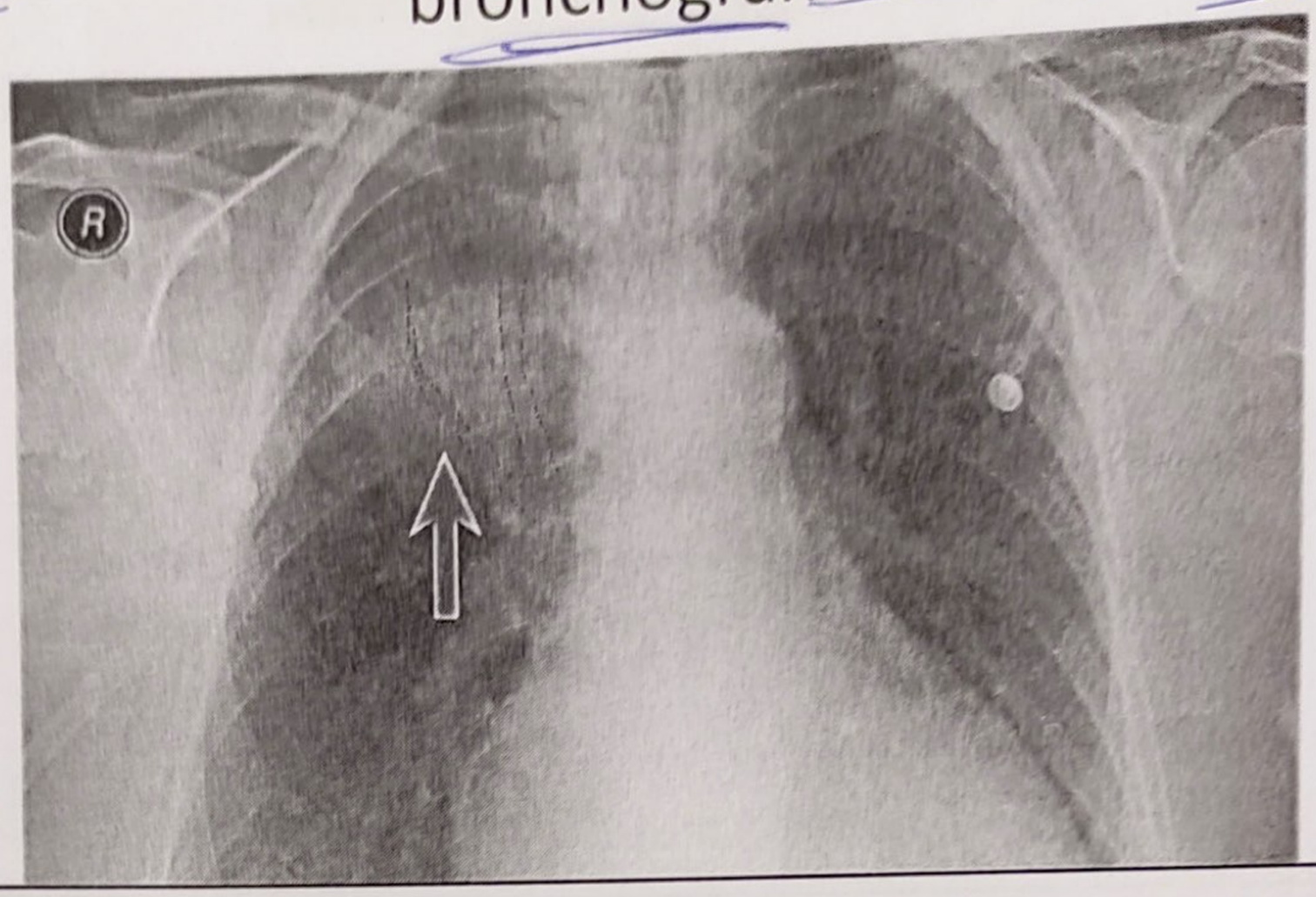

- ❑ Silhouette sign: loss of lung/soft tissue interface



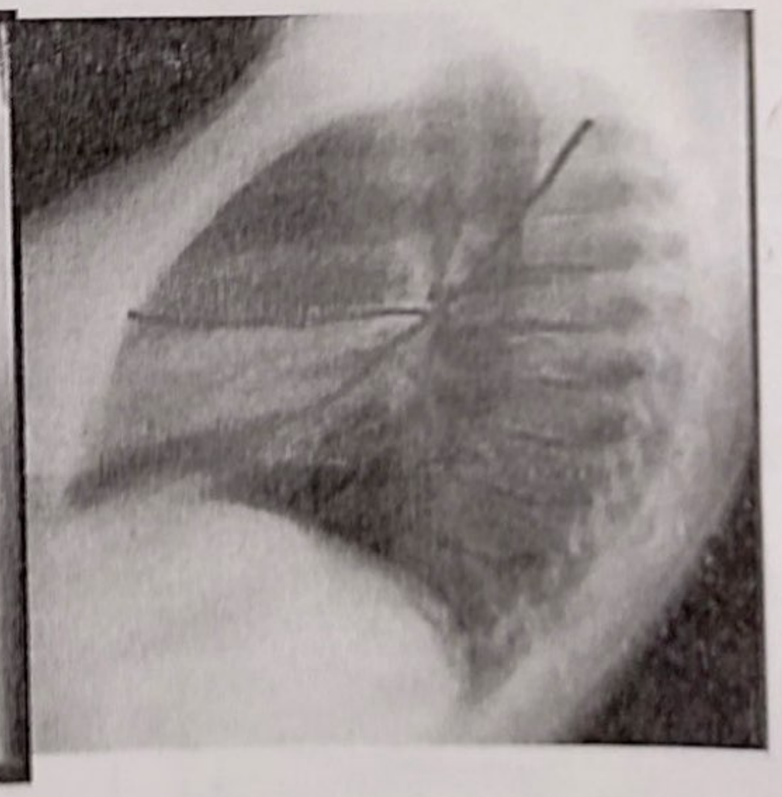

مثلاً صادر
SHOT ON POCO X3
تكون
border of heart

This lesion anterior. [left side / right]
in Middle lobe.

- Intima. [right side / left]

Scanned with CamScanner

Left lower lobe



I can identified the left border of heart

→ posterior lesion in lower zone.

Silhouette no ~~sohat~~ Sign in upper lobe.

Right upper lobe pneumonia

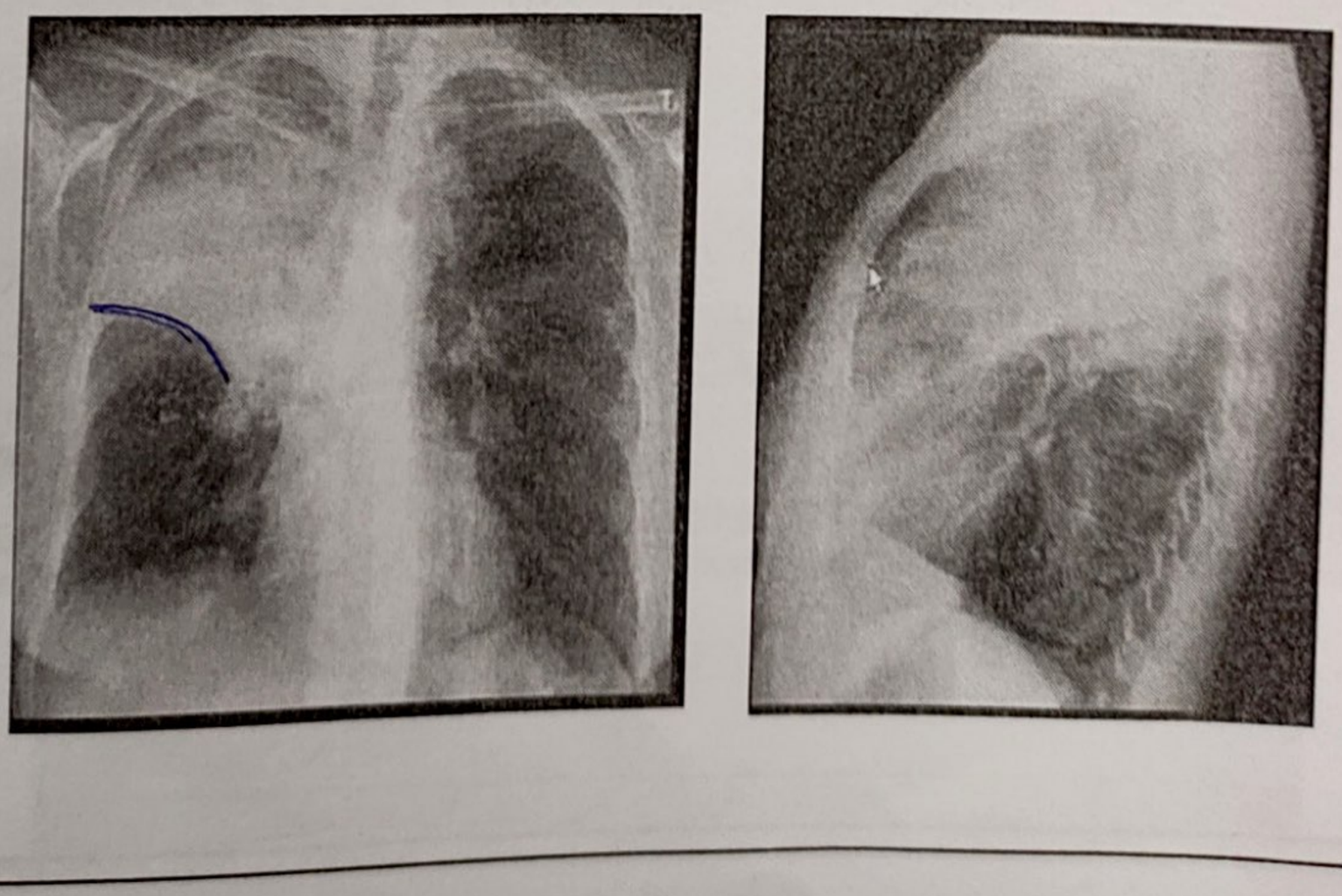

SHOT ON POCO X3

Scanned with CamScanner

Content			
Water	Pus	Blood	Cells
Heart failure ARDS Low albumin Renal failure	Pneumonia	Trauma Goodpasture Henoch Schonlein SLE	BAC Organizing pneum Chron eosin pneum Sarcoid

Pattern		
Lobar	Diffuse	Multi-focal
Lobar pneumonia - Streptocos pneum. - Klebsiella - TB - viral - fungal - Aspiration **Neoplasm** - Lungca with obstructive pneumonia - BAC - Lymphoma **Hemorrhage** - Contusion - Infarction **Others** - Organizing pneumonia - Eosinophilic pneum - Sarcoidosis - Sequestration - Mitral regurgitation with RUL edema	**Edema** - Heart failure - Volume overload - ARDS - Low albumin - Renal failure - Transfusion reaction **Bronchopneumonia** - Staph Aureus - Gram negative - PCP - Viral - fungal **Neoplasm** - BAC - Lymphoma **Hemorrhage** - SLE - Henoch-Schönlein - Wegener - Goodpasture **Others** - Organizing pneumonia - Eosinophilic pneum - Hypersensitivity pneum - Alveolar proteinosis	**Bronchopneumonia** - Staph Aureus - Legionella - Gram negative - Streptococcus pneum - Kliebsiella - Pseudomonas - Anaerobe - PCP - TB - Aspiration **Vascular** - Septic emboli - Wegener's **Neoplasm** - BAC - Lymphoma - Metastases **Others** - Organizing pneumonia - Eosinophilic pneum - Lipoid pneumonia

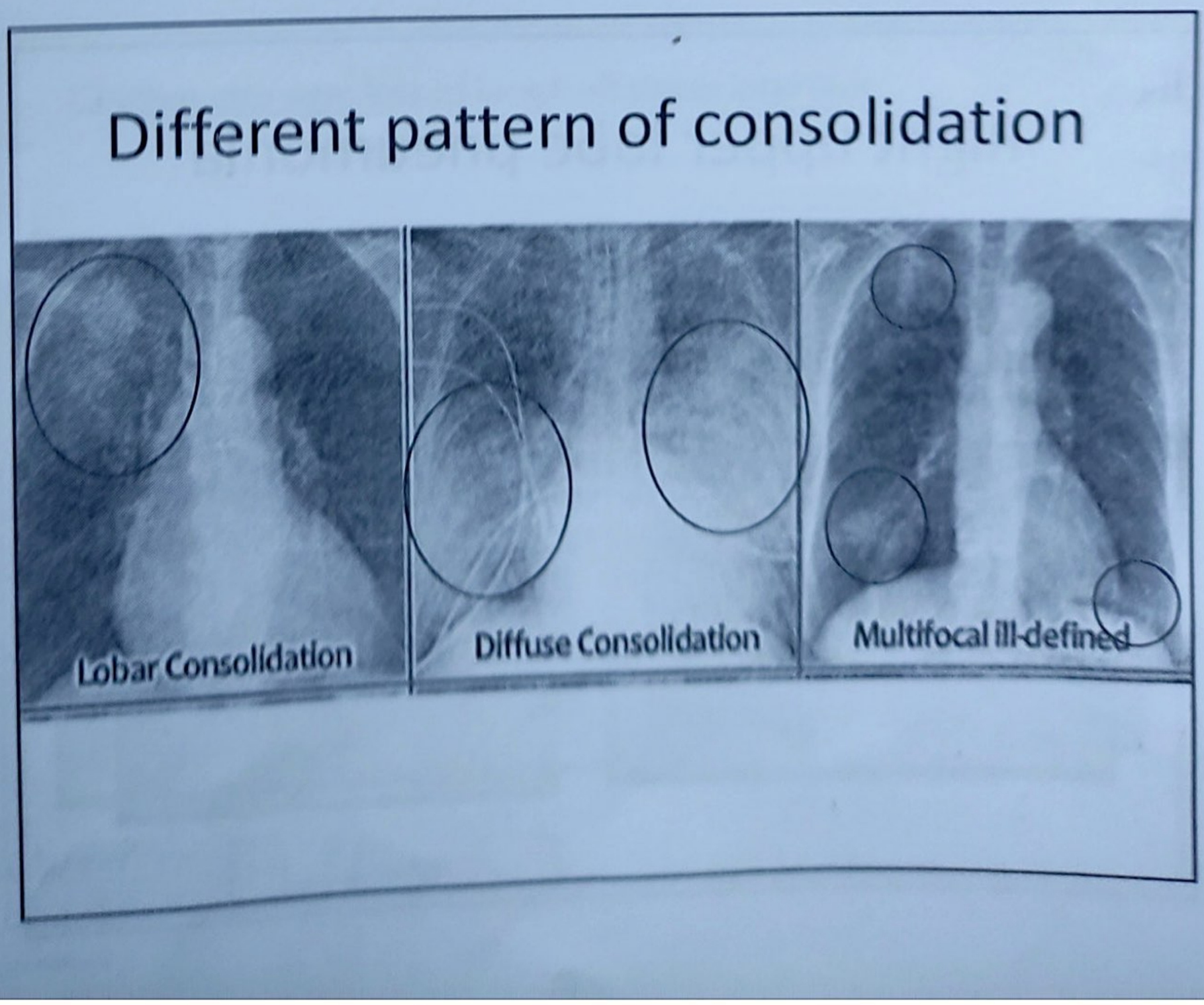

SHOT ON POCO X3

Scanned with CamScanner

the most common consolidation is lobar or segmental

Lobar consolidation

Lobar pneumonia
- Streptococ pneum.
- Klebsiella
- TB
- Aspiration

Neoplasm
- Lungca with obstructive pneumonia
- BAC
- Lymphoma

Hemorrhage
- Contusion
- Infarction

Others
- Organizing pneumonia
- Eosinophilic pneum.
- Sarcoidosis
- Sequestration
- Mitral regurgitation with RUL edema

the most common diffuse consolidation is pulmonary edema

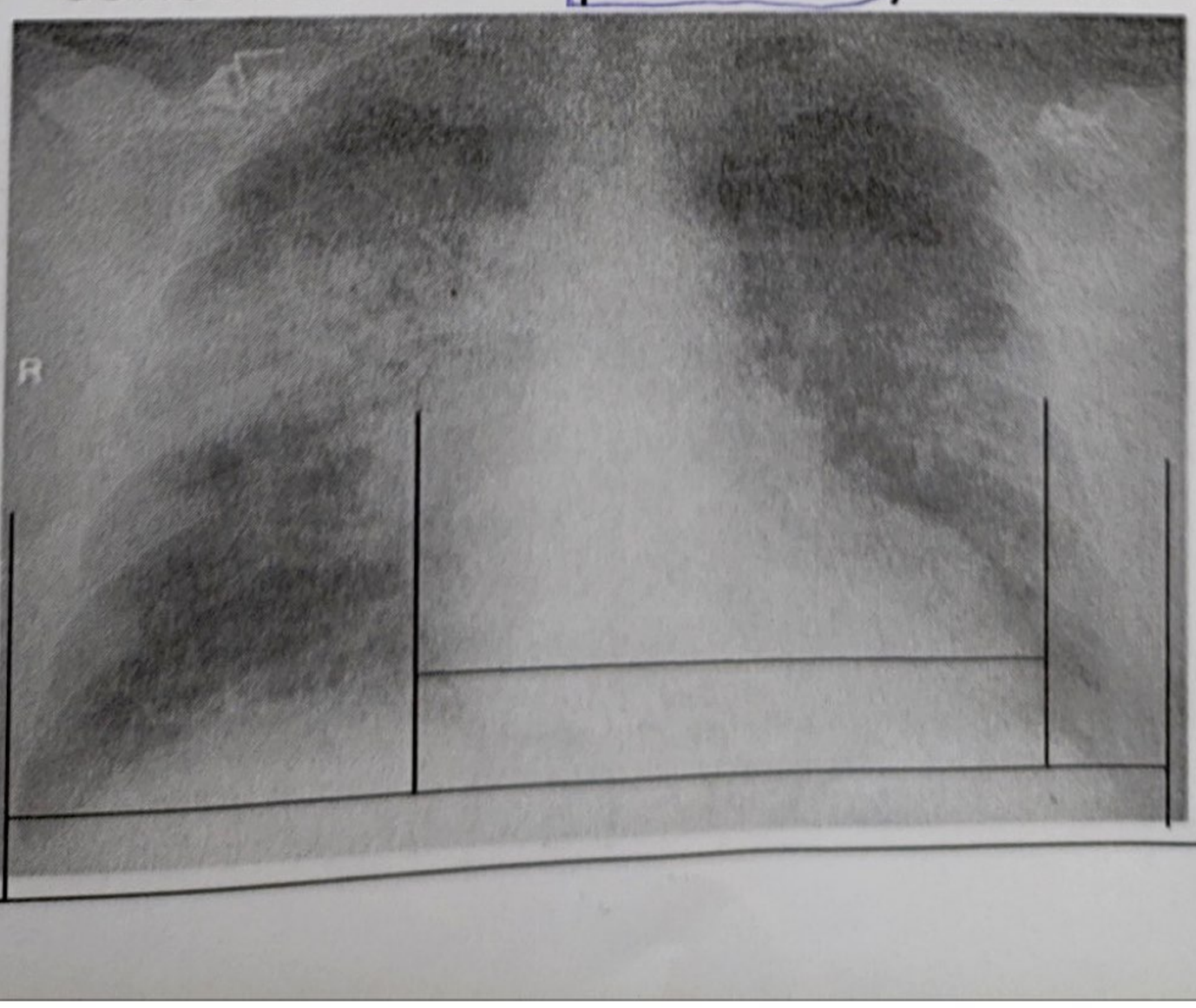

SHOT ON POCO X3

Scanned with CamScanner

12/07/1444

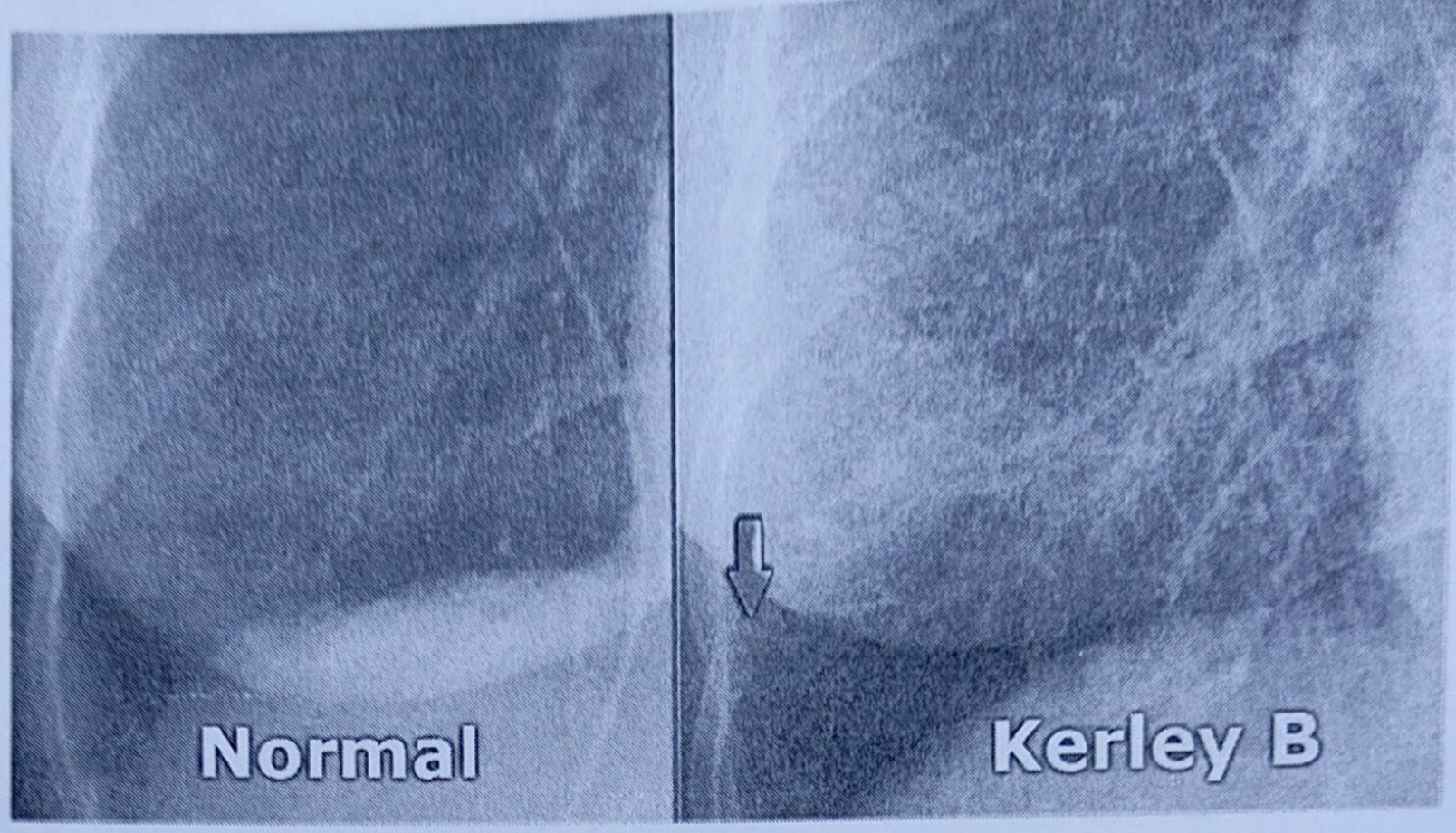

Interstitial edema in Heart failure
lymphangitis carcinomatosa

قبل الـ ct
Mastectomy

It is very important to differentiate between acute consolidation and chronic consolidation, because it will limit the differential diagnosis

Acute Consolidation	Chronic Consolidation
Pulmonary edema Pneumonia Aspiration Hemorrhage / Contusion Infarction	Neoplasm · post-obstruction · Bronch-alveolar ca · Lymphoma Sarcoidosis Organizing Pneumonia Eosinophilic pneumonia Alveolar proteinosis

SHOT ON POCO X3

Scanned with CamScanner

2/07/1444

Batwing	Reversed Batwing
Pulmonary edema	Bronchoalveolar carcinoma
Bronchopneumonia	Sarcoidosis
PCP	Organizing Pneumonia
Viral pneumonia	Eosinophilic pneumonia

Lip Common ! -typ

COVID 19

Multifocal proposal consolidation

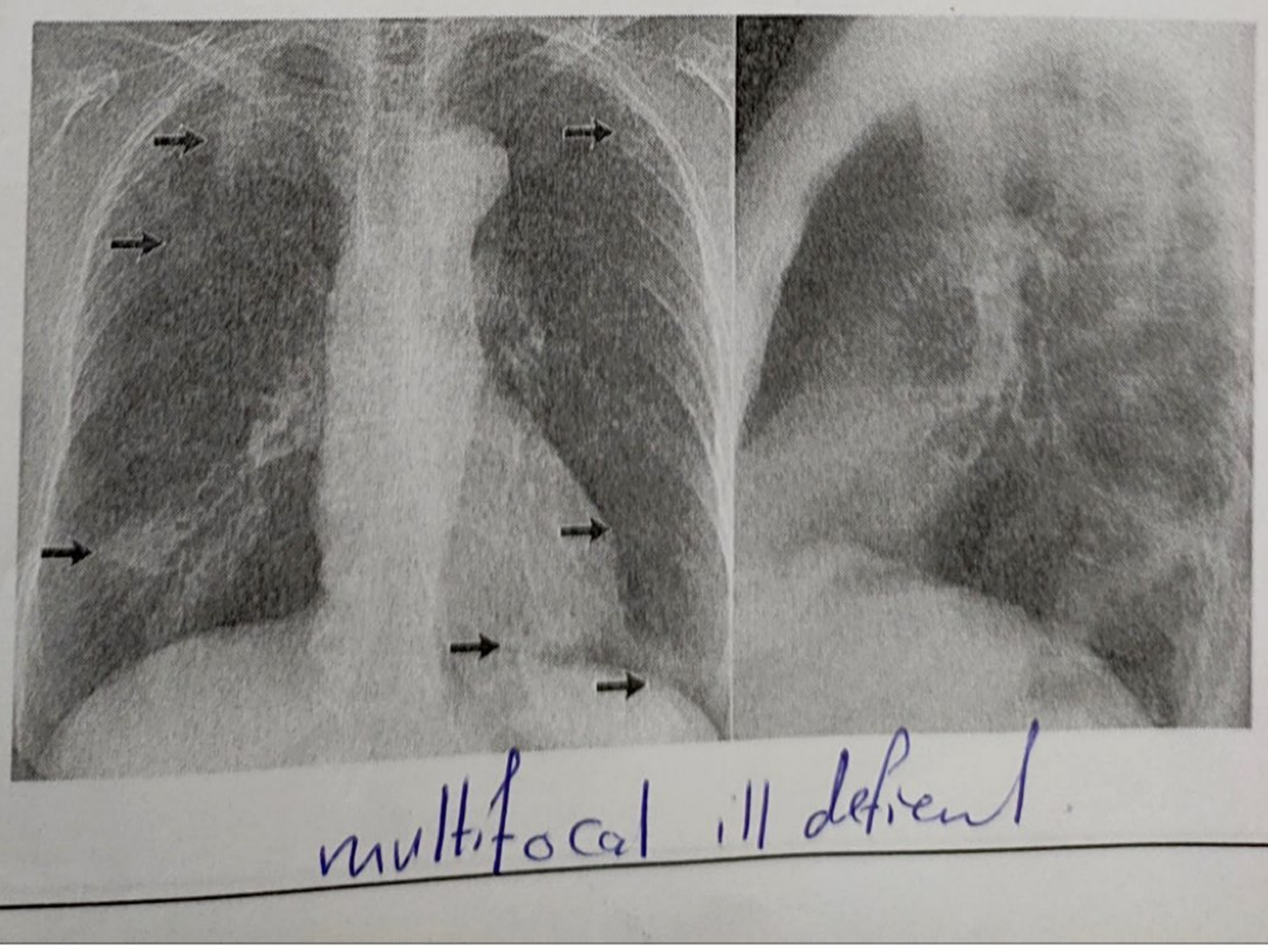

multifocal ill defined.

SHOT ON POCO X3

Scanned with CamScanner

12/07/1444

2

Atelectasis

- **Definition** - (lung collapse) is a result of loss of air in a lung with subsequent volume loss due to airway obstruction or external compression by pleural fluid or gas.

- In many cases atelectasis is the first sign of a lung cancer.

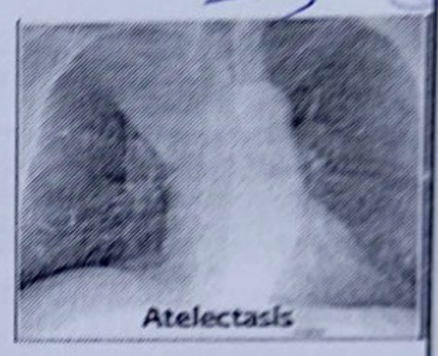

shift
- no air bronchogram
- whit lung focal
⇒ can't cross the fissure

The key-findings on the X-ray are:

- Sharply- defined opacity obscuring vessels without air bronchogram .
- Volume loss resulting in displacement of diaphragm , fissure , hili or mediastinum

SHOT ON POCO X3

Scanned with CamScanner

2/07/1444

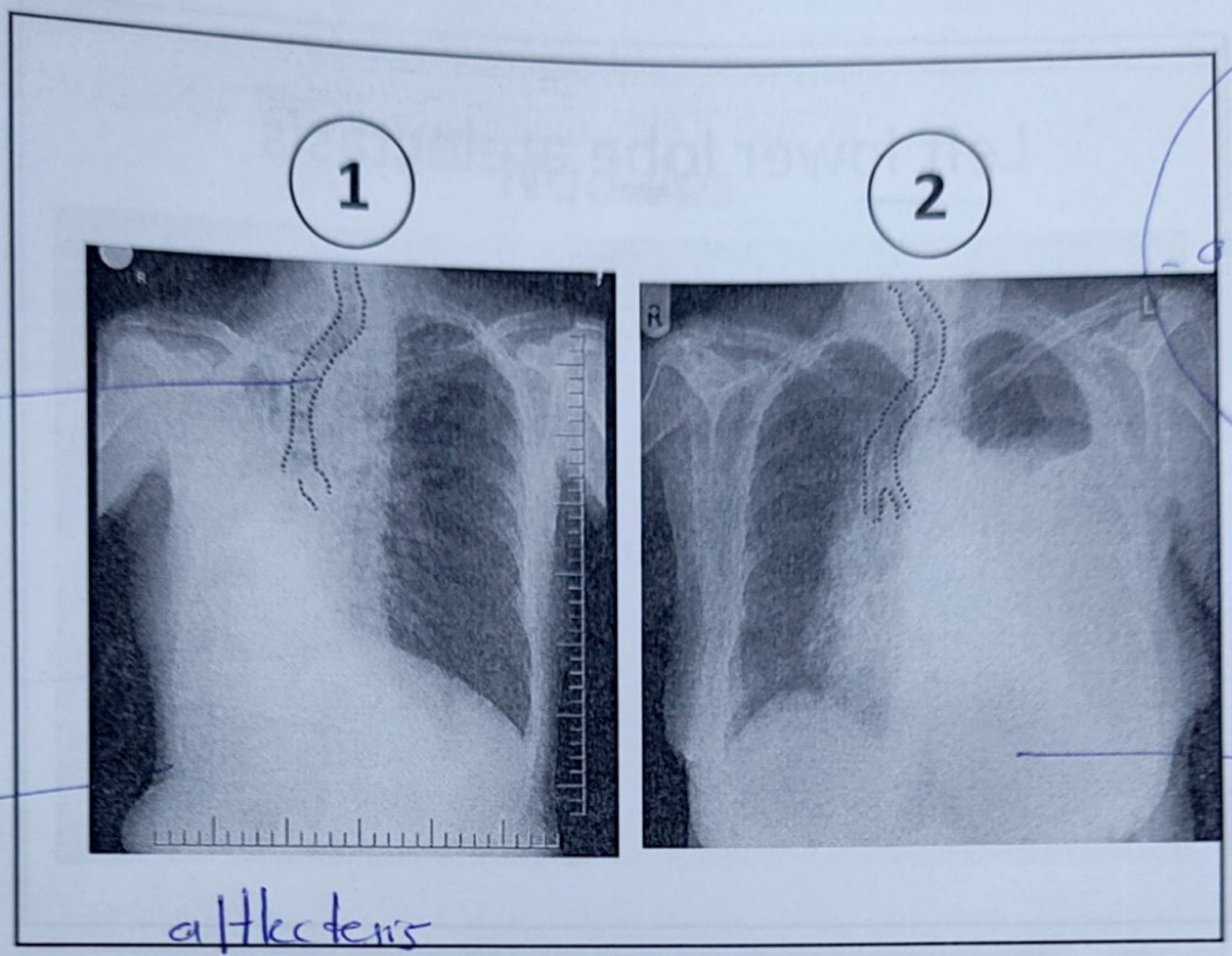

Shifted

Mediastinal shift

atelectasis

- sharply well defined
- one segment if it
- one lobe.

opposed the affected site (space occupied lesion)

lung Cancer.

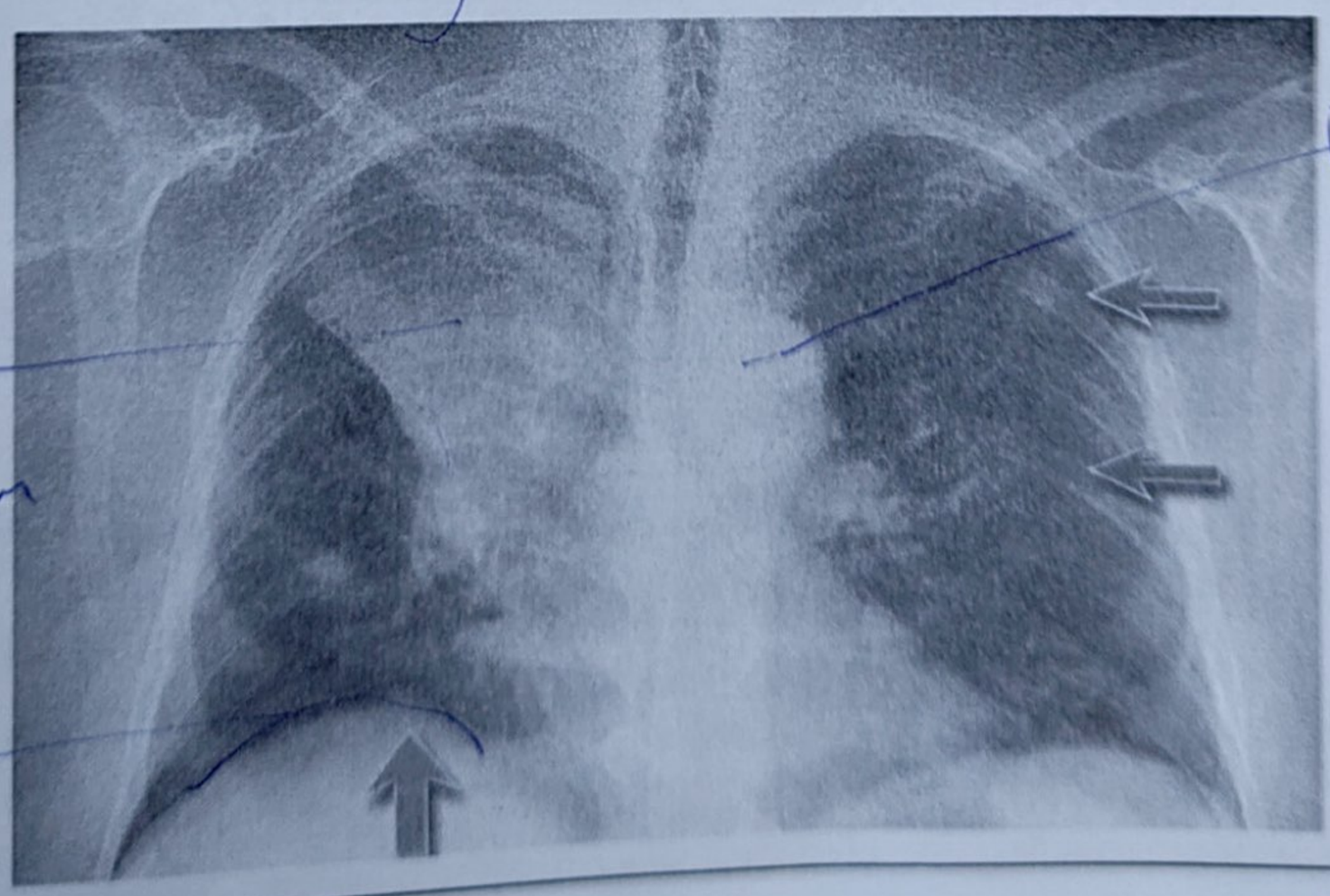

Metastatic

collapse

no air bronchogram

SHOT ON POCO X3

Scanned with CamScanner

Left lower lobe atelectasis

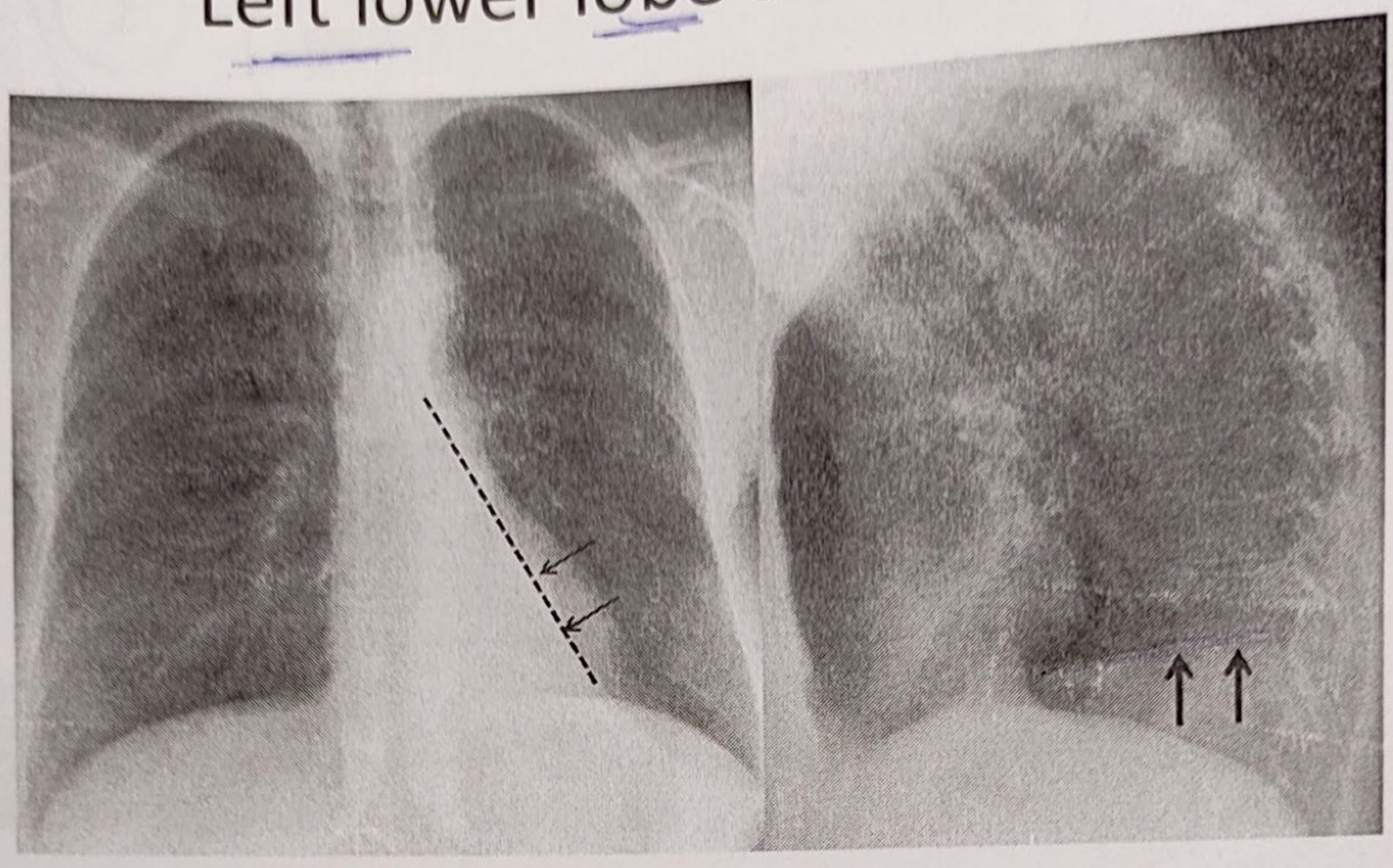

retro Cardiac space

3

Nodules and Masses

- **Definition** -

➢ Nodule : defined as well-marginated, rounded opacity less than 3cm in diameter .

1. Solitary Pulmonary Nodule (SPN)
2. Multiple Pulmonary Nodules

➢ Mass : defined as well-marginated, rounded opacity more than 3cm in diameter .

SHOT ON POCO X3

Scanned with CamScanner

Nodules

1. Tuberculoma
2. Hamartoma
3. Bronchogenic carcinoma
4. Metastasis
5. AVM
6. Hydatid cyst

low density → May Contain fat

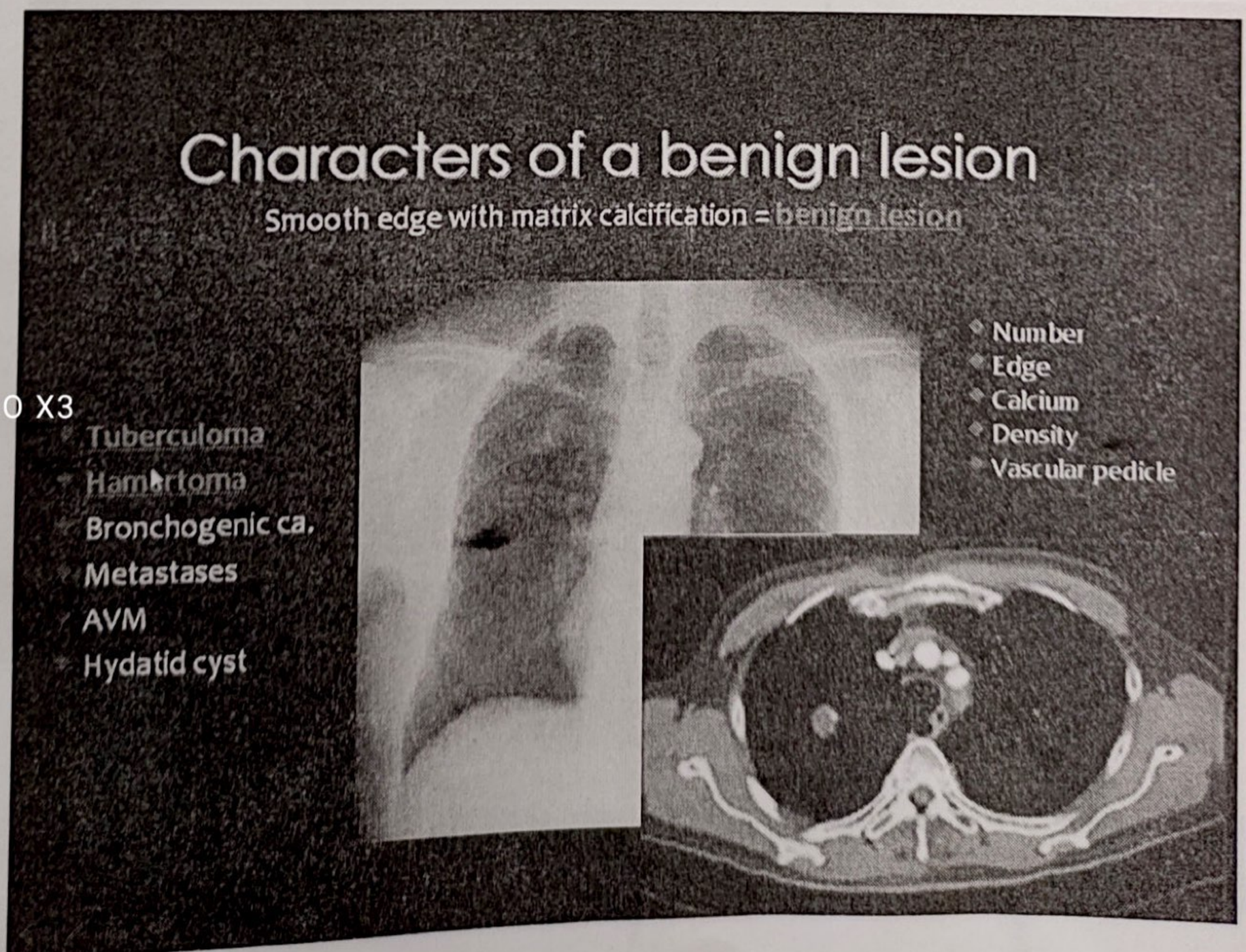

SHOT ON POCO X3

Scanned with CamScanner

12/07/1444

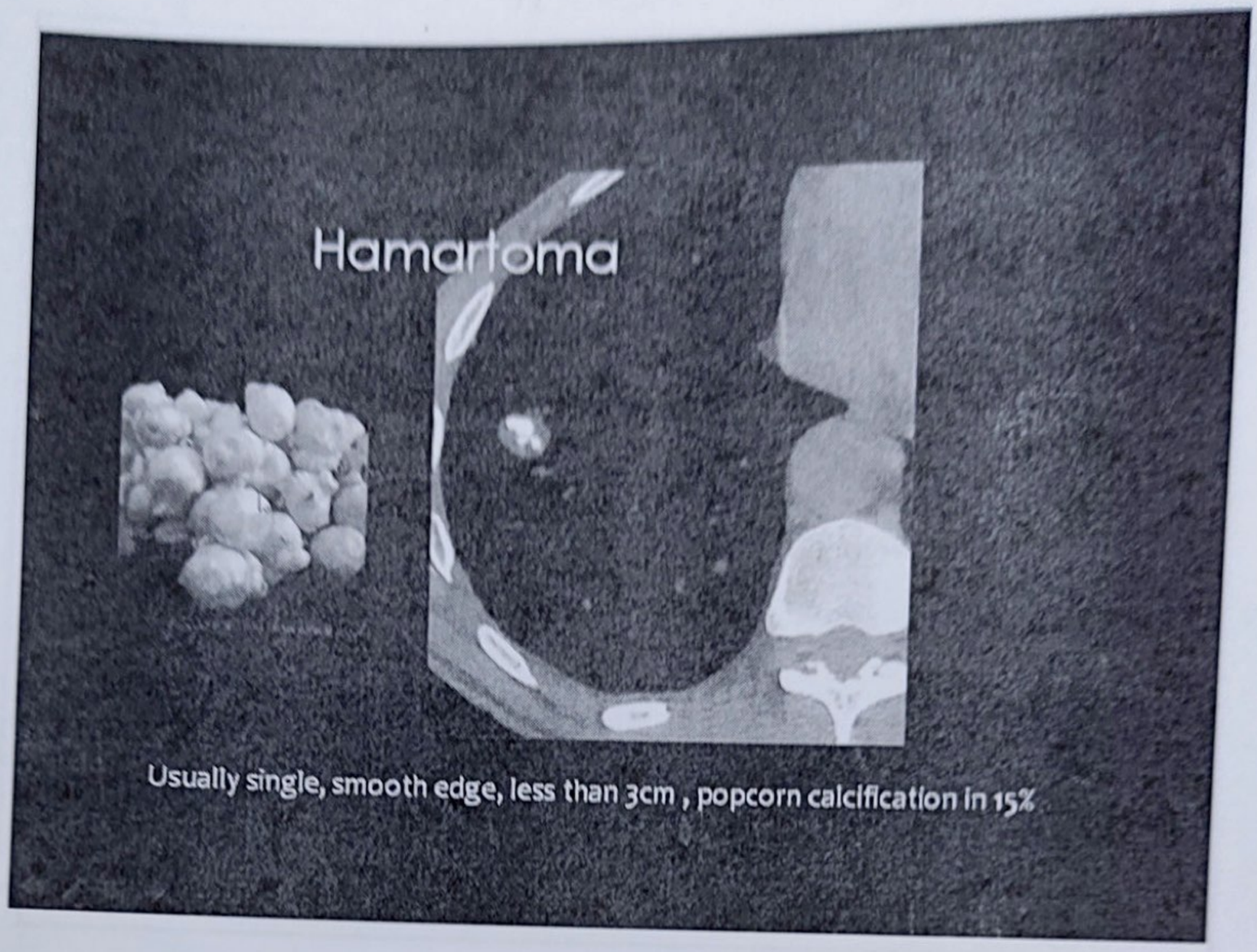

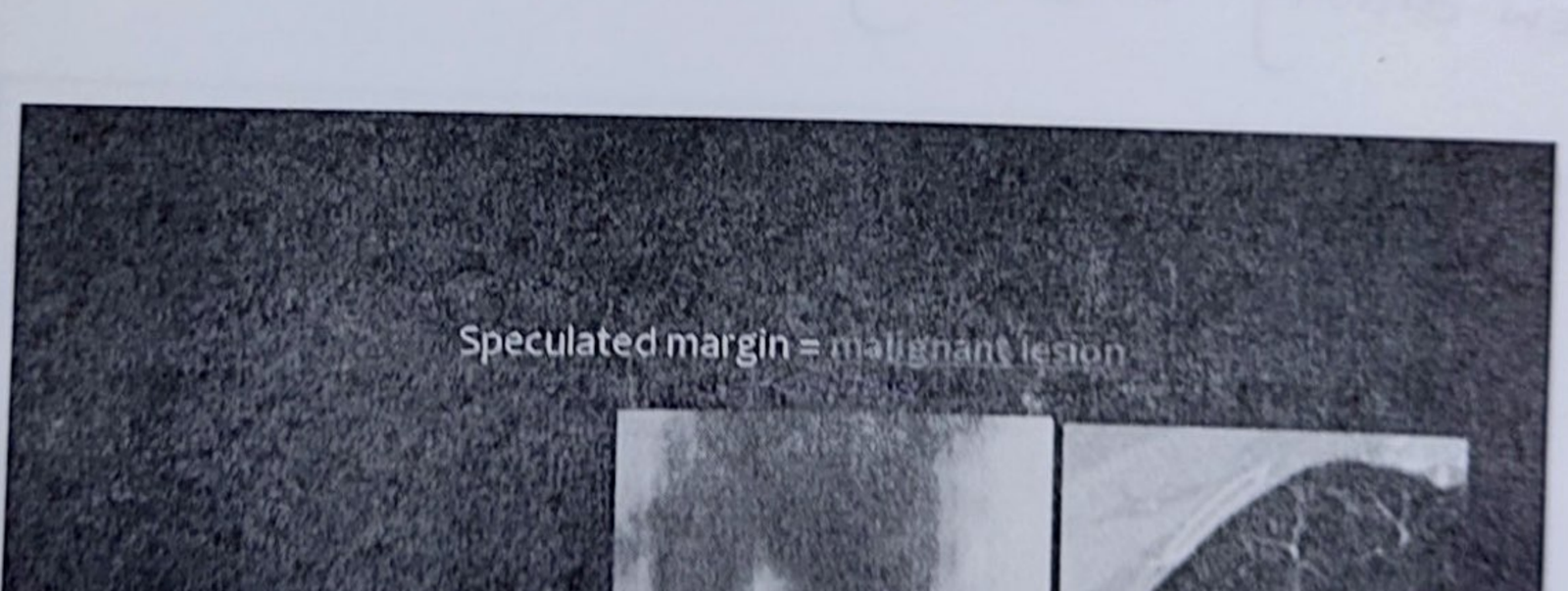

SHOT ON POCO X3

(إذا كانت multiple.

Scanned with CamScanner

Vascular pedicle

two lines connecting the lesion to the hilum = AVM

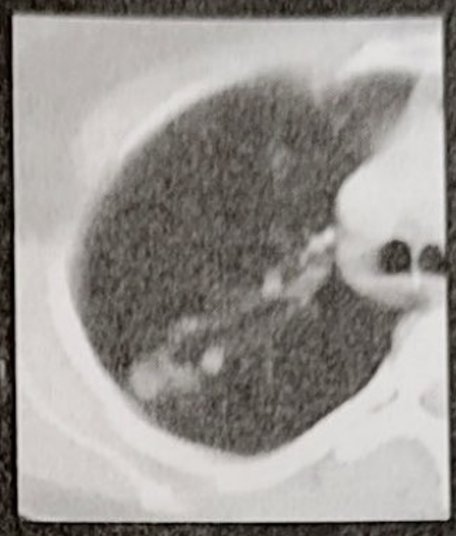

- Tuberculoma
- Hamartoma
- Bronchogenic ca.
- Metastases
- Arteriovenous malformation
- Hydatid cyst

- Number
- Edge
- Calcium
- Density
- Vascular pedicle

Contraindication to biobsy

Single or multiple Lesions with water density = hydatid cyst (s)

- Tuberculoma
- Hamartoma
- Bronchogenic ca.
- Metastases
- AVM
- Hydatid cyst

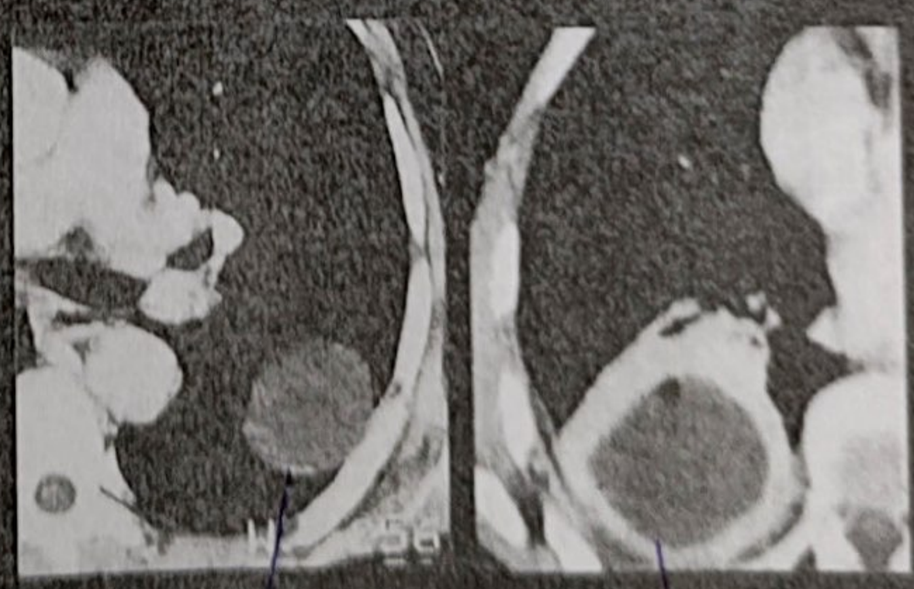

خوف ruptun يعمل prophylactic shock

يسبب paracute.

thin wall

thick wall. air pupe (abcess) صديد clear.

SHOT ON POCO X3

Scanned with CamScanner

Masses

Well defined lesion measuring more than 3cm

- Bronchogenic Carcinoma
- Hydatid cyst
- Metastatic deposit

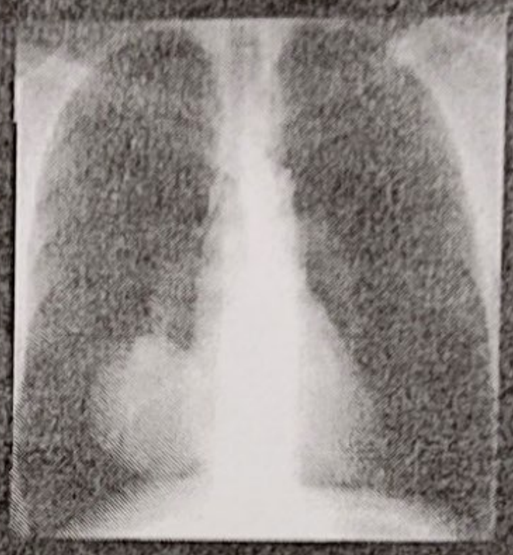

CT is needed to show if the lesion is cyslic or solid ?!!

Don't touch or aspirate.

Multifocal

Bronchogenic Carcinoma

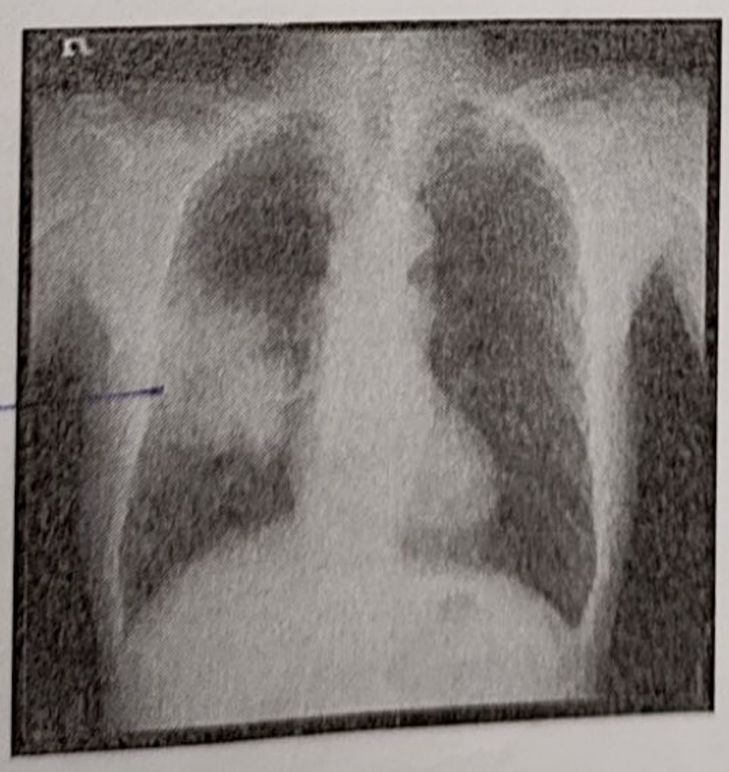

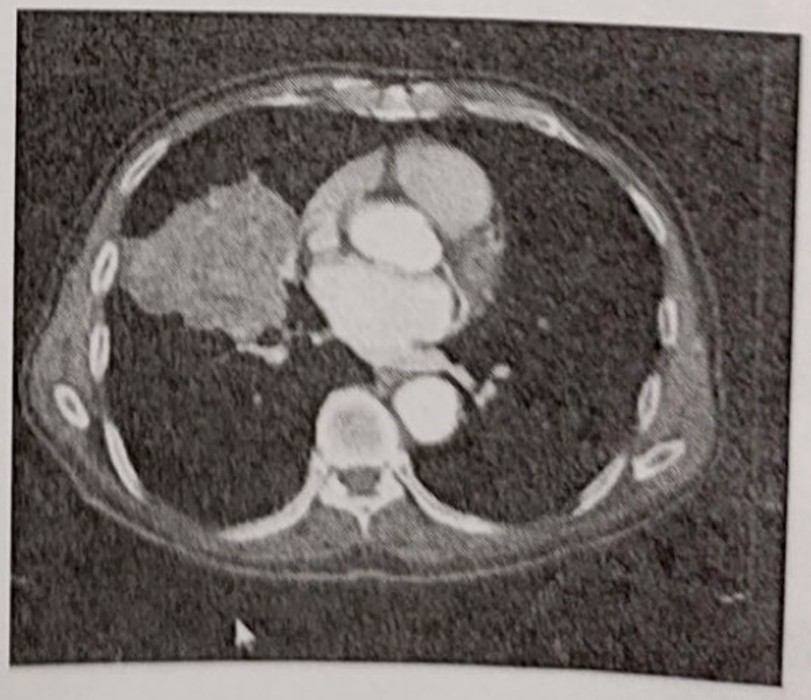

Can be crossing fissure.

SHOT ON POCO X3

Scanned with CamScanner

4

Interstitial disease

- **Definition** - involvement of the supporting tissue of the lung parenchyma resulting in fine or coarse reticular opacities or small nodules.

- X-Ray is limited (pattern ??) just reticular

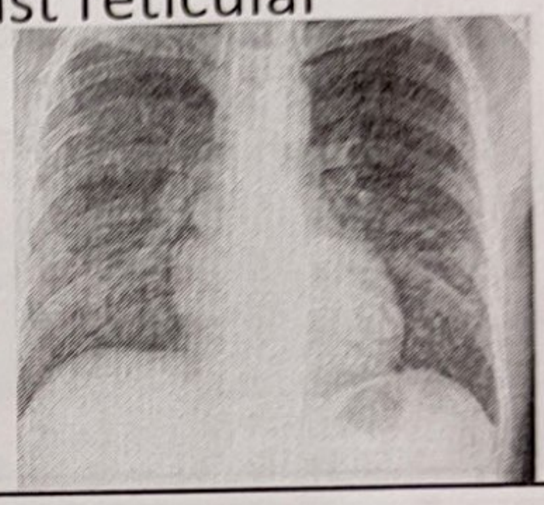

- HRCT (High Resolution CT) .

Reticular pattern	Cystic disease
- **Edema** heart failure - fluid overload - **Interstitial pneumonia** Viral - PCP - Mycoplasma - **Lymphangitis ca** - **UIP** - *honeycombing* IPF - RA - Systemic sclerosis Dermatomyositis - **Drugs** Nitrofurantoine - Methotrexate - Amiodarone Busulfan - Bleomycin - Cytoxan	- Langerhans cell histiocytosis - Lymphangioleiomyomatosis - Pneumatoceles - Lymphocytic Interstitial Pneumonia
	Fine nodular
	- Sarcoidosis - Metastases - TB

SHOT ON POCO X3

Scanned with CamScanner

12/07/1444

Cystic Versus Reticular

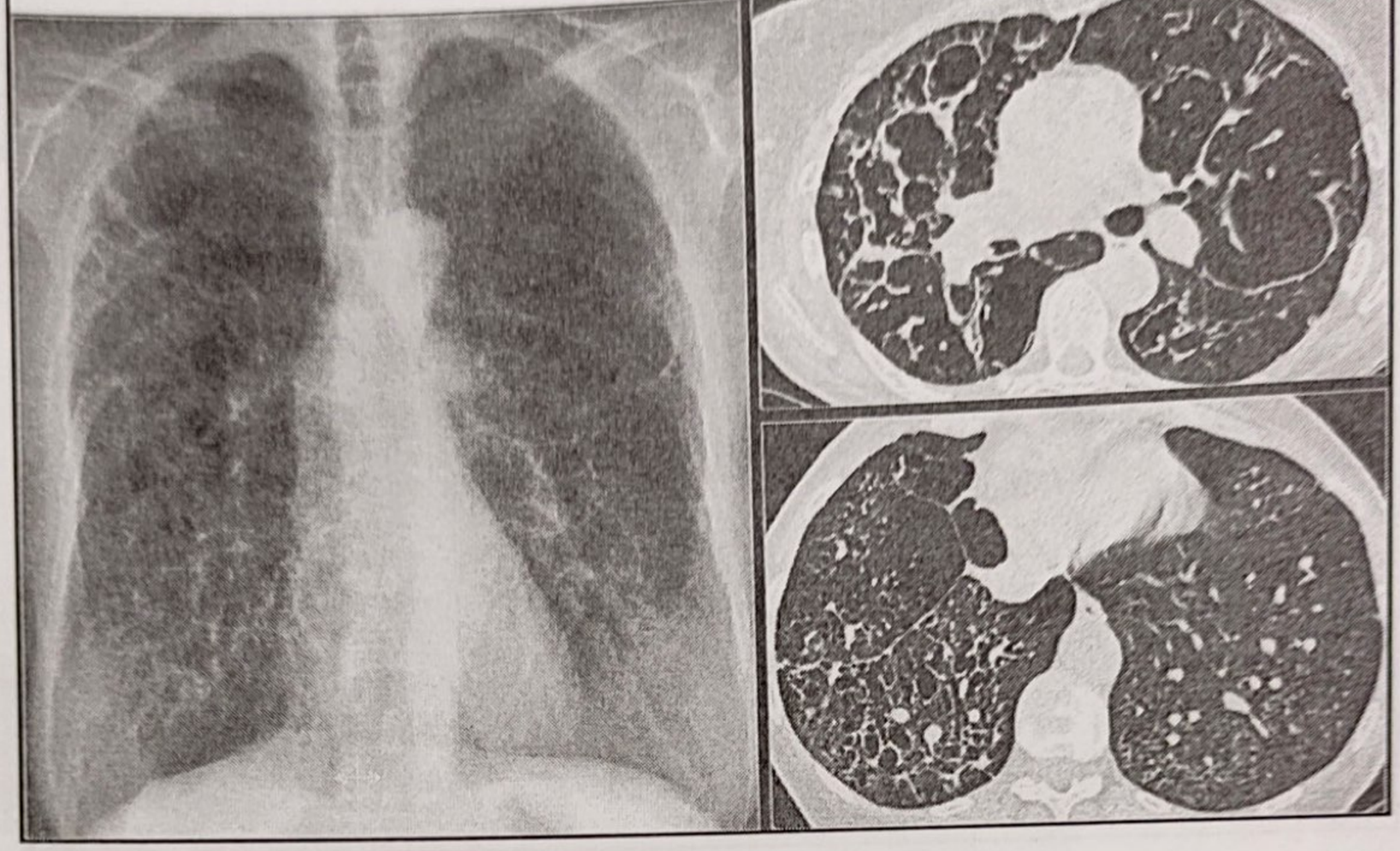

Decrease density or lucency
low attenuation

- Cavity - focal lucency with a thick wall
- Cyst – focal lucency with a thin wall
- Emphysema - lucency without a visible wall

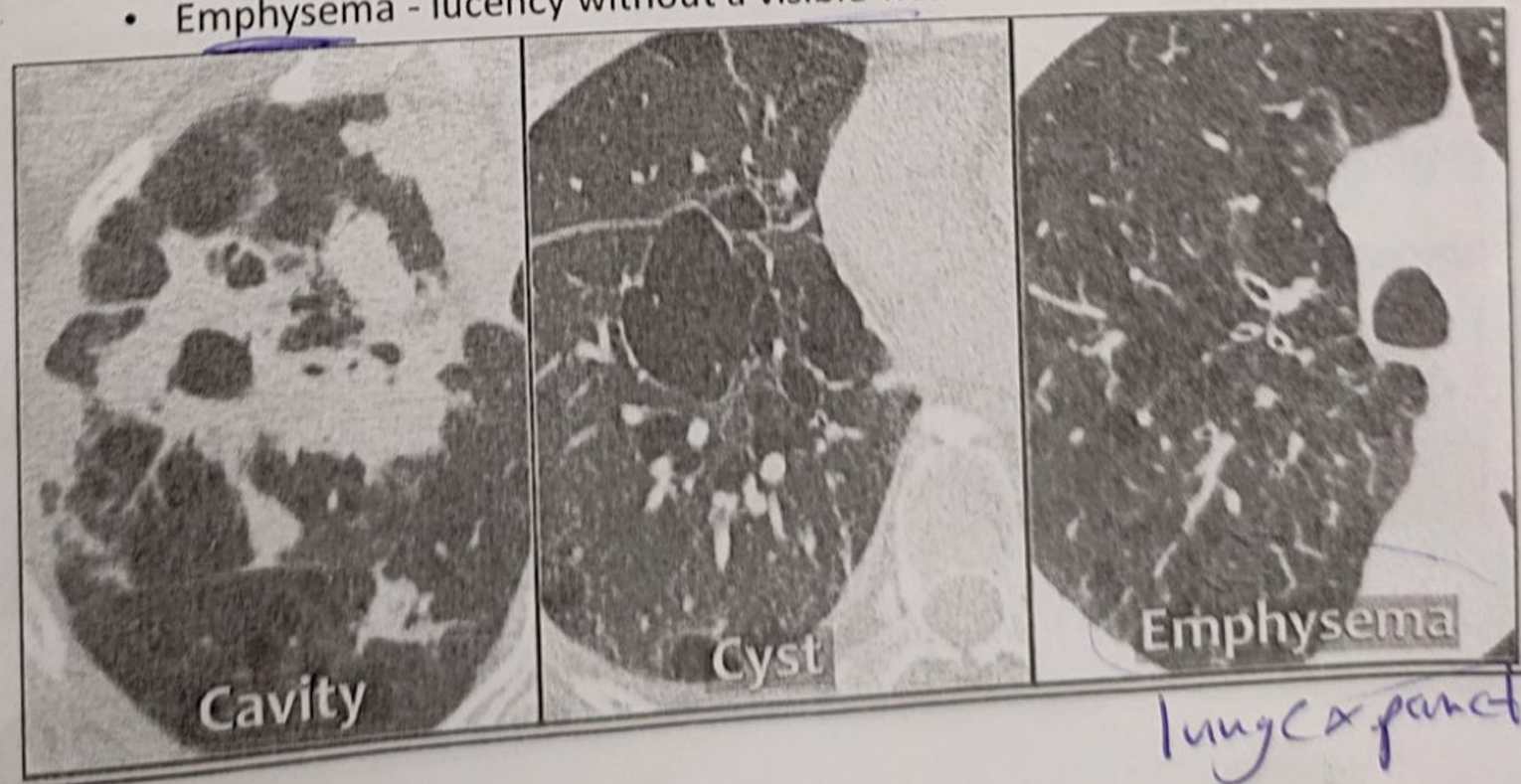

SHOT ON POCO X3

Scanned with CamScanner

2/07/1444

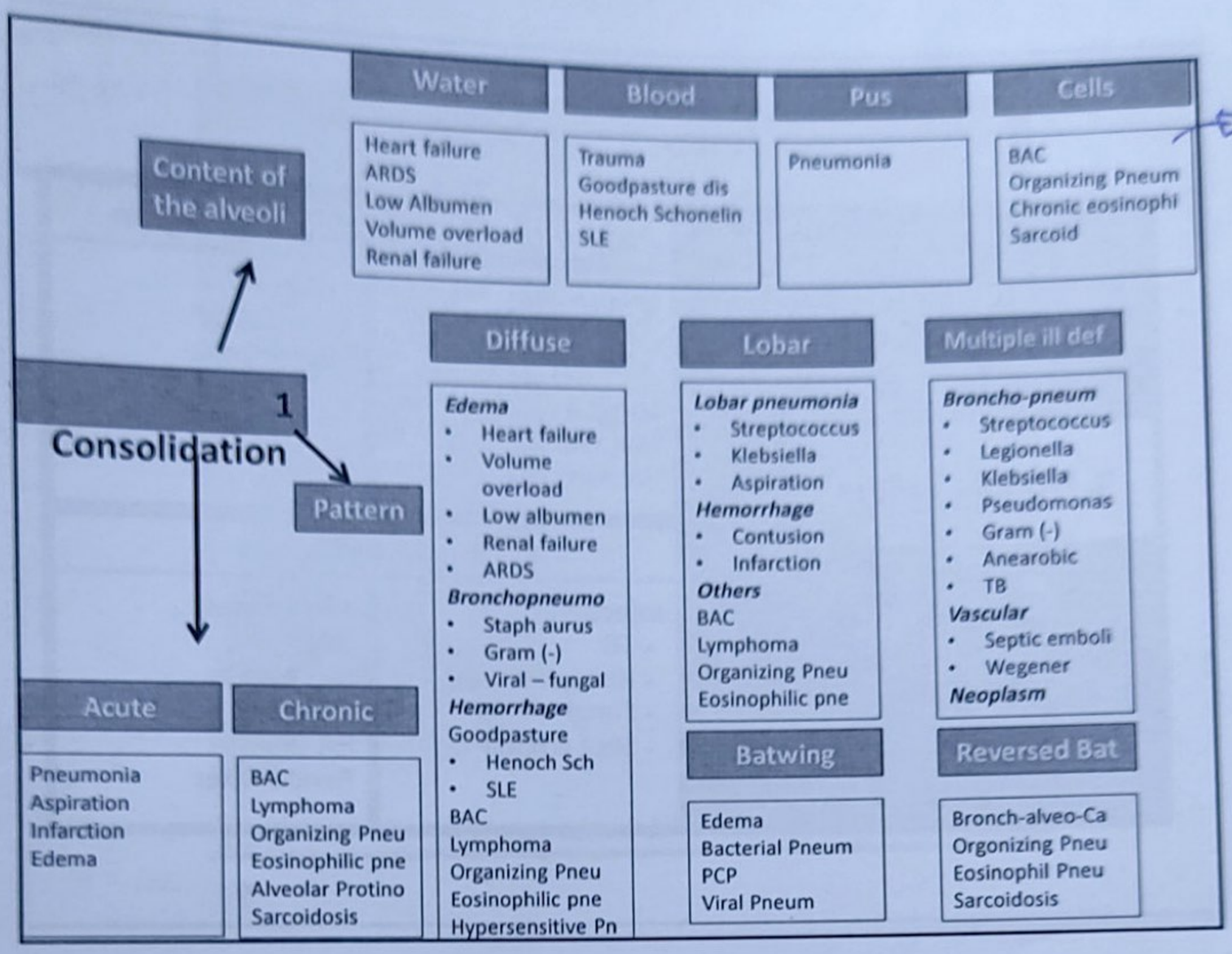

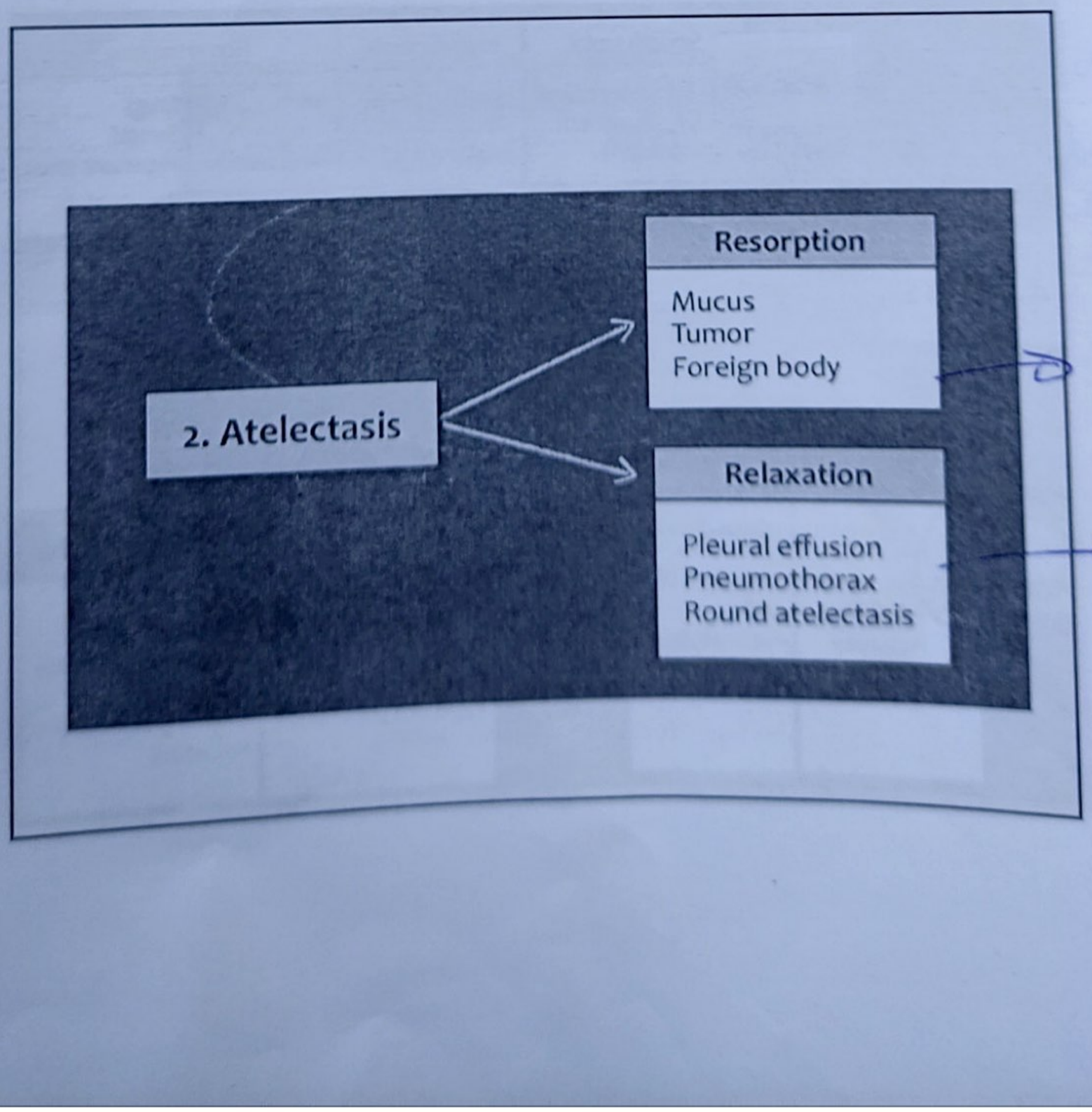

SHOT ON POCO X3

Scanned with CamScanner

12/07/1444

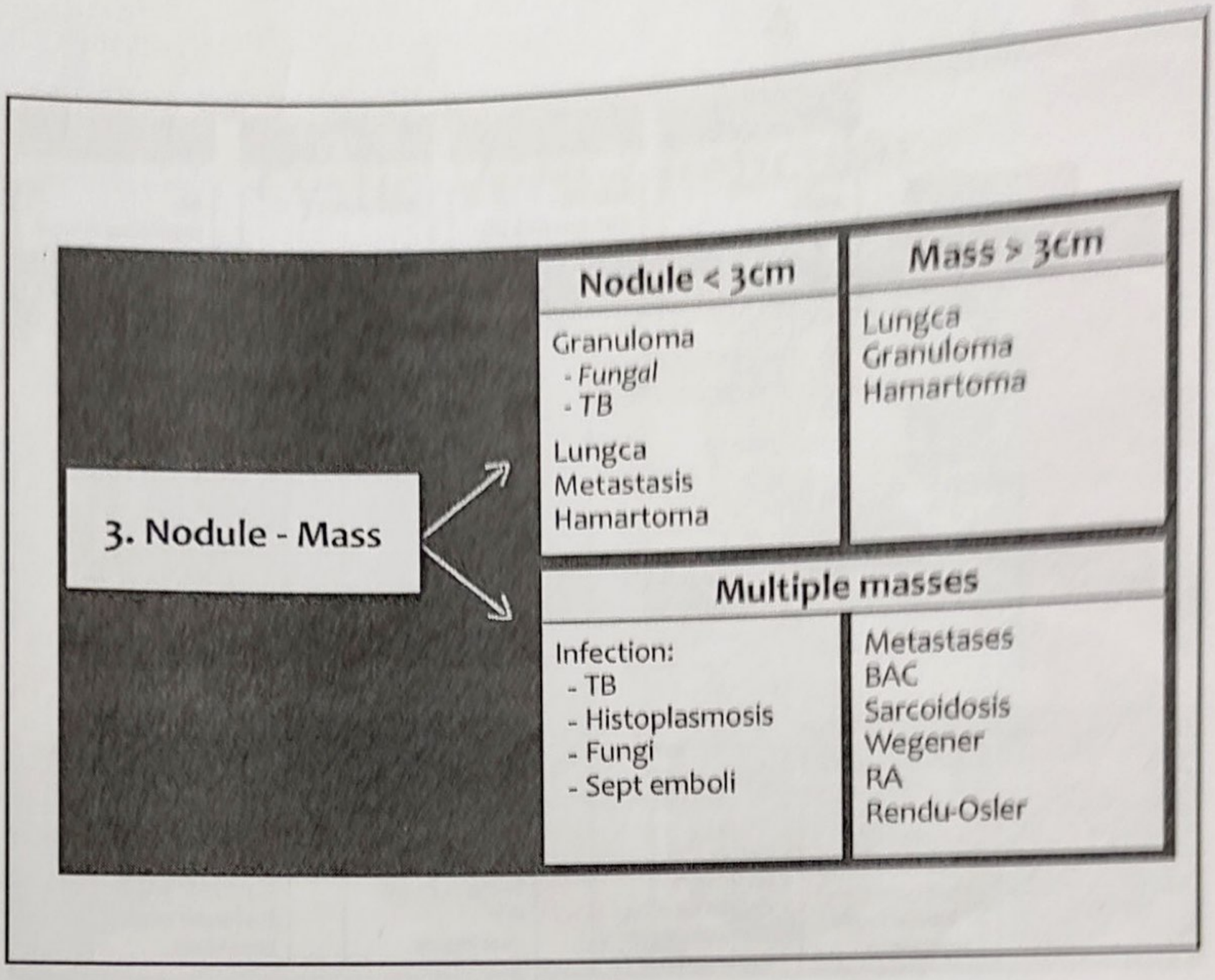

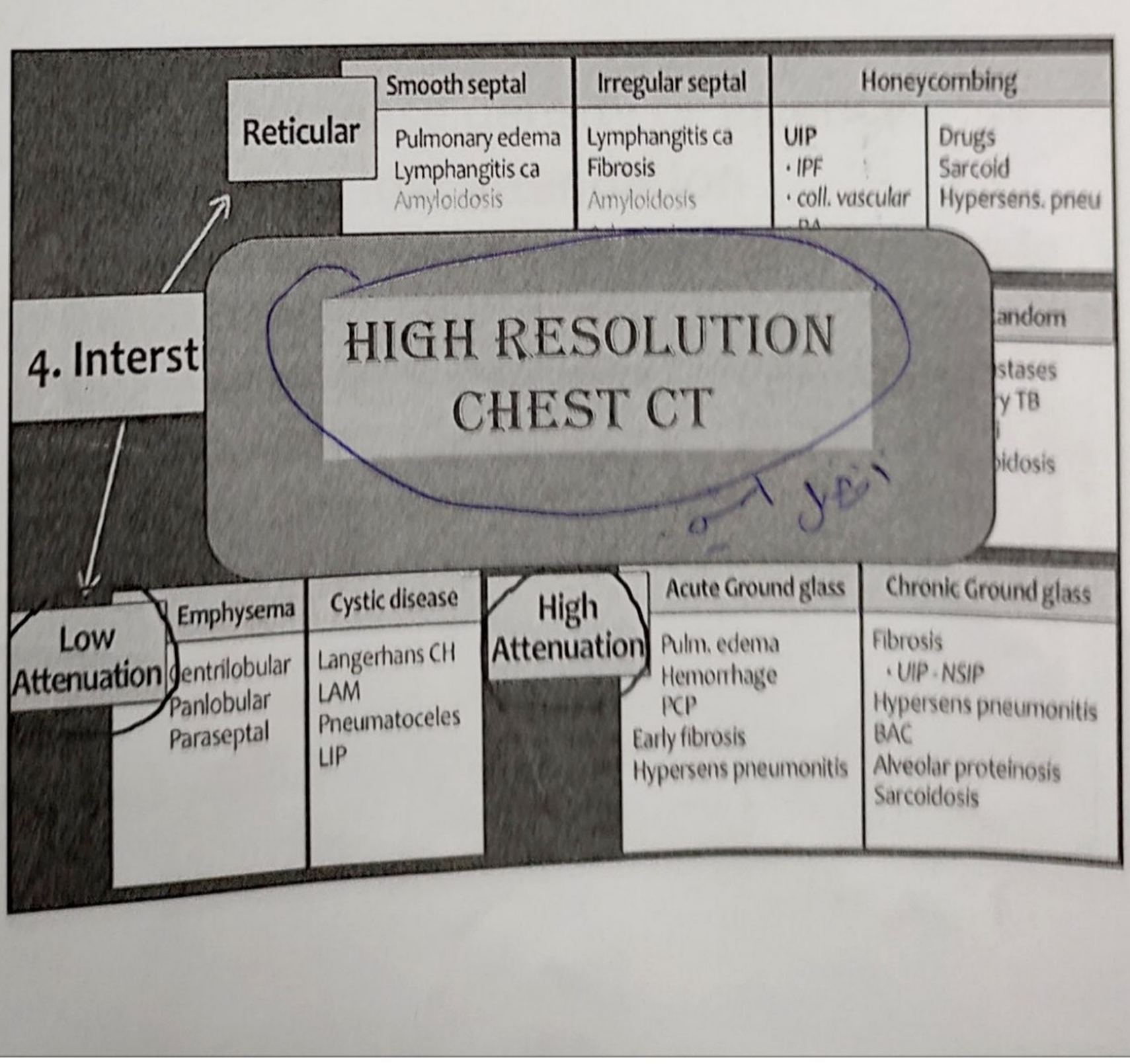

SHOT ON POCO X3

Scanned with CamScanner

multi
- focal ill defined
consolidation

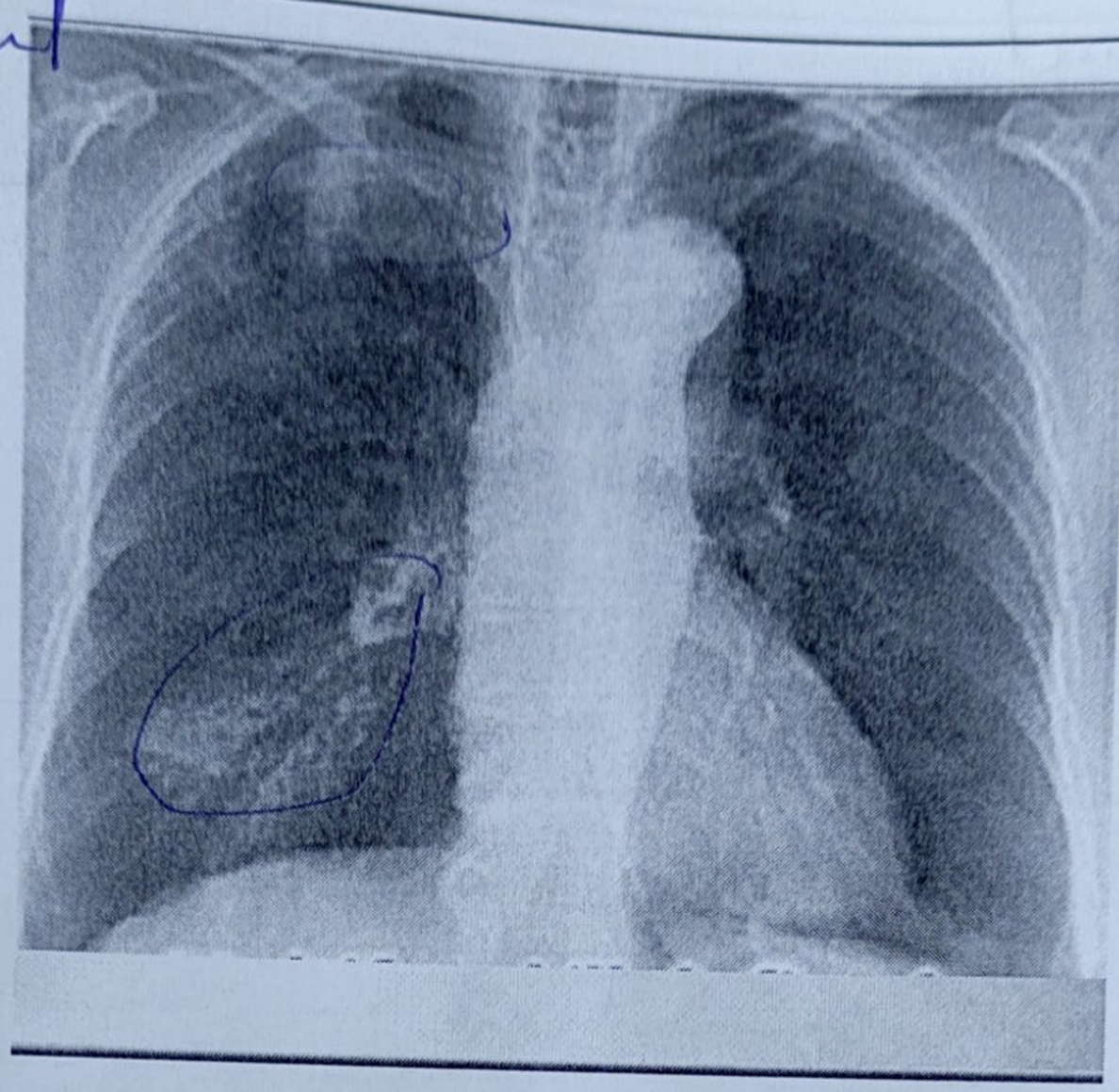

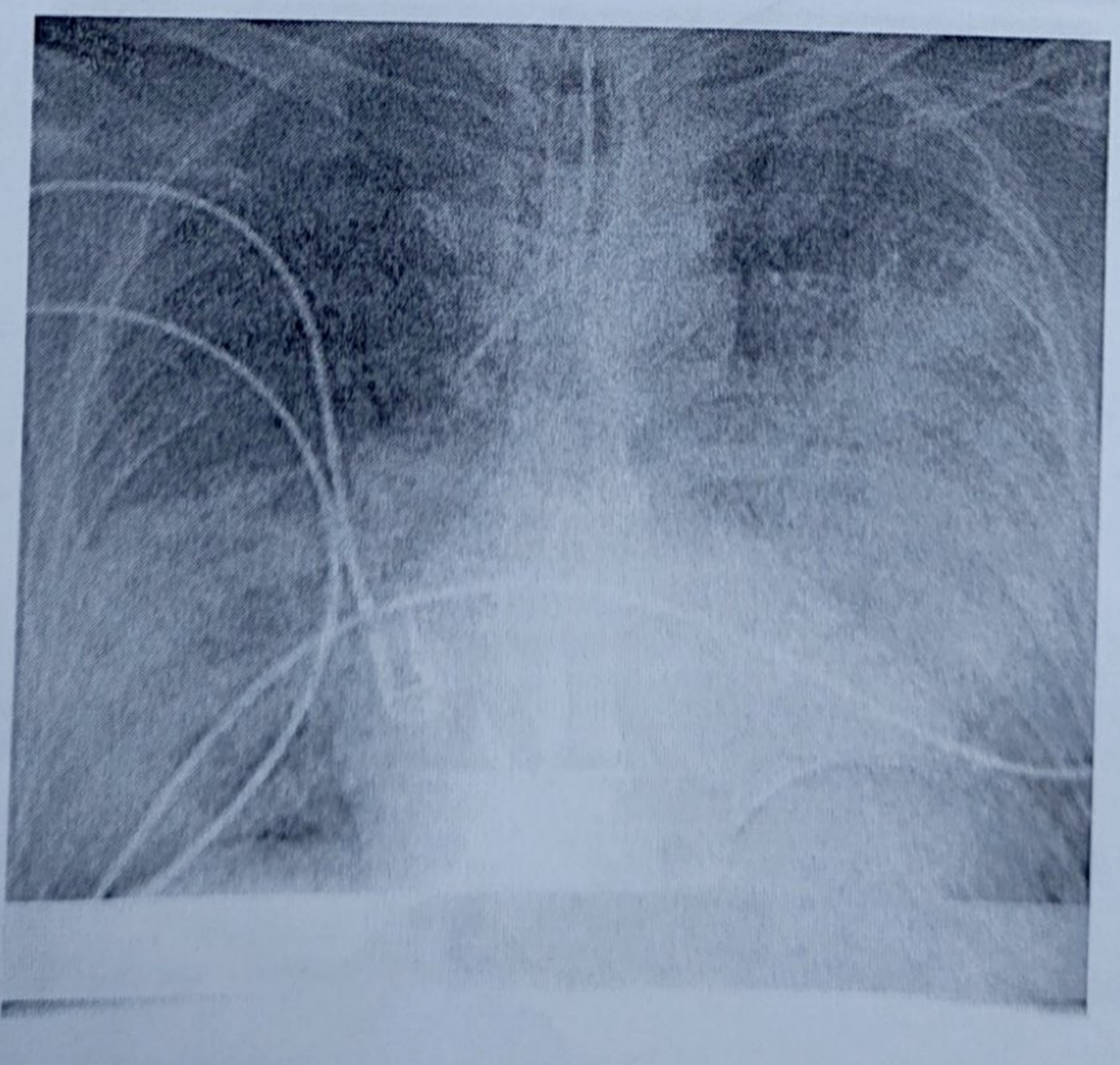

diffuse
heart enlargement
(CHF)

SHOT ON POCO X3

Scanned with CamScanner

lobar ill defined
Consolidation
(bronchogram)

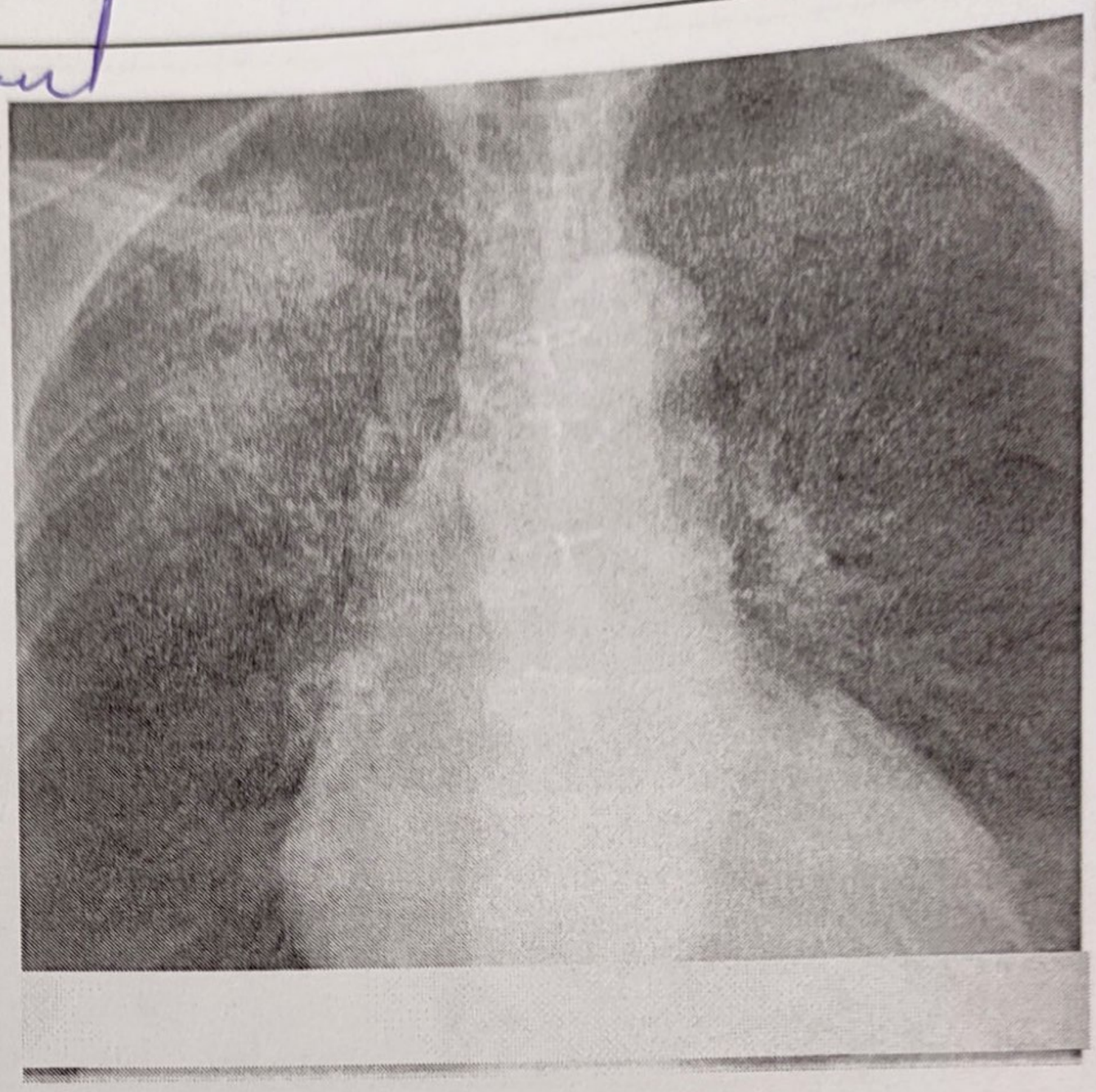

Trachea

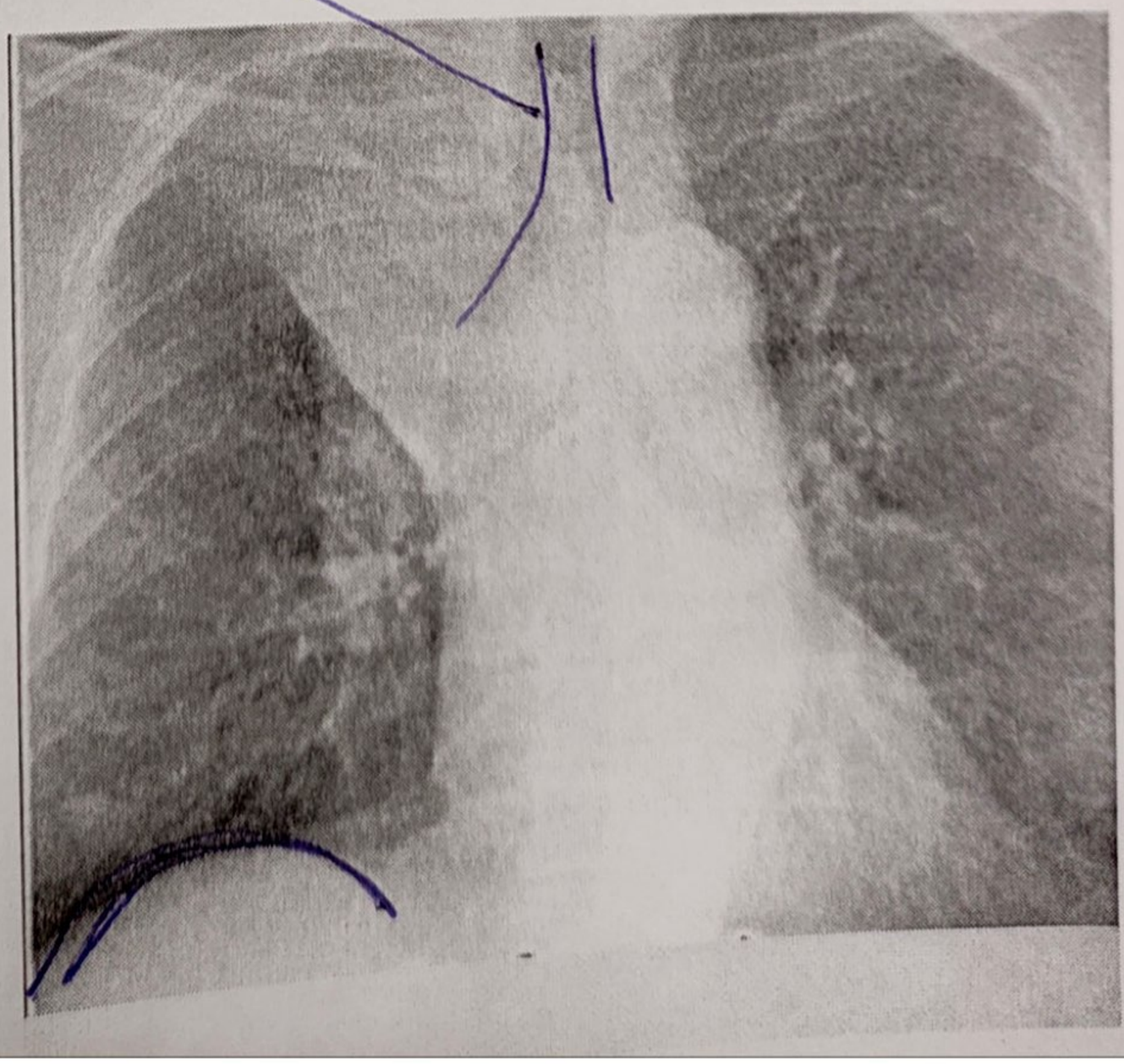

SHOT ON POCO X3

Scanned with CamScanner