

Pathology

محاضرة 2 د.سامح

Hydropic degeneration and fatty degeneration



Layan

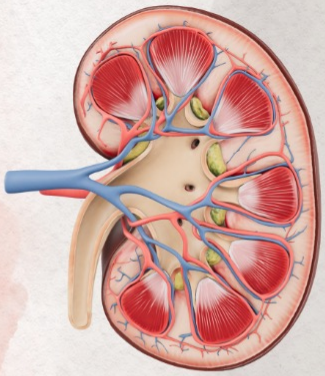

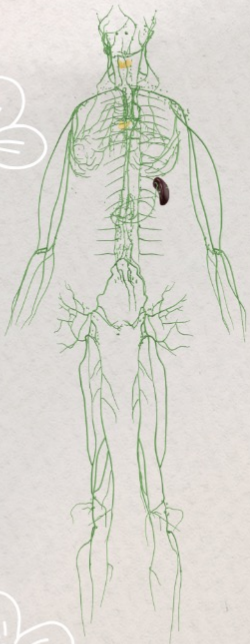

injurious agent يؤثر على mitochondria ووظيفة mitochondria هي انتاج ATP المهمة لـ Na^+-K pump وعشان نحافظ على Na^+ برا الخلية و K جوا الخلية محتاجين ATP و mitochondria لما تتأثر وتتكسر هتضعف Na-K pump وبالتالي تؤدي عكس وظيفتها Na هيدخل داخل الخلية ومعاه المياه وال mitochondria بعد تكسرها بتسيب granules جوا ال cytoplasm

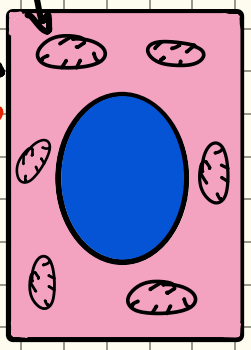

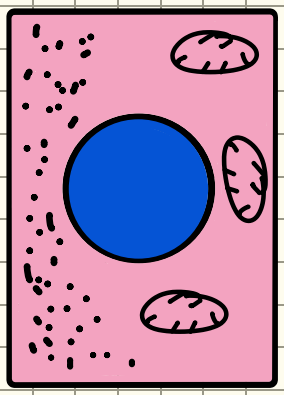

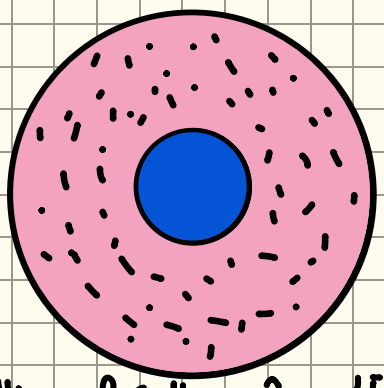

swelling of cells بالتالي حدث
+ granules in cytoplasm.

امتلأت بالمياه وانتفخت وصار فيها mitochondria متكسرة.

Cloudy swelling

Organs	Gross picture	Microscopic picture
أهم Organs - Liver - Kidney - Heart	- enlarged - pale - soft (as fat). - rounded borders. - tesnse capsule. - bulging cut surface	- swelling of cells. - granules in cytoplasm. - Nucleus is not affected affected عشان لو كانت necrosis هتصير

Fate of cloudy swelling

- reversible
- progress to hydropic degeneration.

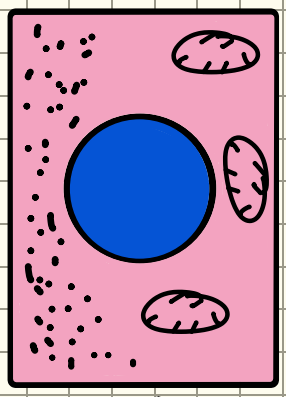



ال hydropic degeneration هو عبارة عن ال Cloudy swelling لكن في مرحلة متقدمة شوي

* Hydropic swelling: cells are swollen with a single large clear vacuole or multiple vacuoles

microscopic picture

من كثر كمية المياه الي بتدخل عملت vacules تكوّن water vacules بنسميه vacular degeneration أو hydropic degeneration

hydropic degeneration

- reversible cell injury.
- metabolic and morphologic changes.
- Caractarized by: - Swelling of cells.
  - vacules in cytoplasm

- Causes
- pathogenesis
- Gross picture

} ⇐ as cloudy swelling

- Microscopic picture: - swelling of cells.
  - water vacules in cytoplasm.
  - nucleus is not affected.



هنا هي عبارة water vacules

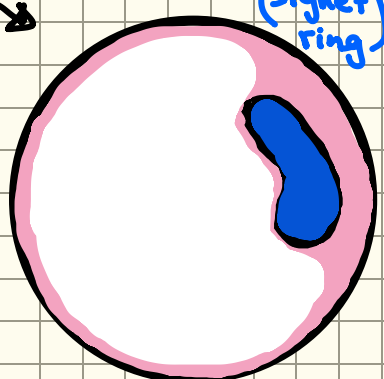

it push nucleus prepherally تظهر على شكل (signet ring)

هتزيد وتتحد مع بعضها وتعمل single large vacule

Fatty degeneration

(Steatosis)

- When the fat enters the cytoplasm.
- metabolic and morphologic cellular changes charactarized by accumalation of nuteral fat (triglysride TG) inside parenchymal cells.

الي بيحدث أنه يوجد Free fatty acids (FFA) بتروح على الـ Cell و بتتحول داخل هذه الـ Cell إلى triglycerides (وهذا يخص liver بالأكثر). وهذا TG يتحد مع Apoprotien يتحول لـ lipoprotien وهتبدأ الـ Cell تُصدِّر هذا الـ lipoprotien مثل cholesterol. (هذا في الـ normal cell).

الفكرة أنه الـ Triglyceride هذا هيزيد داخل الـ Cell و هيحدث تراكم له داخل الـ Cells.

pathogenesis of fatty degeneration:-

- increase free fatty acids.

or

- decrease the formation of Lipoprotien.

عن طريق

- inhibition of triglyceride conjugation with Apoprotien $\xrightarrow[\text{form}]{\text{to}}$ Lipoprotien.

Causes of fatty degeneration ⇒ the same causes of cell injury + in liver.

* Causes of fatty degeneration in liver = Causes of fatty liver.

1. toxins.
2. hypoxia _ ischemia. (metabolism of triglycride بيوقف)
3. infection.
4. DM.
5. Chronic alcoholism.
6. Starvation.
7. Obesity
8. deficiency of Lipotropic factors — methionine. / Choline.

هذه الـ Causes تمنع تحويل الـ triglyceride إلى Lipoprotien فهتضل محبوسة داخل الـ liver.

FATTY CHANGE (STEATOSIS)

DEFINITION: Accumulation of lipids (neutral fat) inside parenchymal cells.

It can affect the heart, kidney & other organs, but is by far most common in the liver (hepatic steatosis).

AETIOLOGY: CAUSES & PATHOGENESIS:

1- Fatty change of liver: causes (& pathogenesis) include:

a) Hypoxia or bacterial toxins metabolism enzymes suppression of mitochondrial lipid intracellular accumulation of fat

b) Hepatocellular specific causes: since the liver is the main organ responsible for fat metabolism, its cells may undergo fatty change in the following conditions:

*Excess fat carried to liver cells (more than their capacity to utilize these amounts) e.g.

- Obesity (excess dietary fat). امتصاص كميات كبيرة جداً من الدهون كمان بتعمل fatty degeneration

- Starvation & diabetes mellitus: excessive mobilization of fat from fat stores to liver.

مريض السكر بتكون الخلية عنده مش قادرة تستخدم الـ glucose فيبدأ الجسم يحرق الدهون بكميات كبيرة بالتالي free fatty acids هتروح على الـ liver بكميات كبيرة فبدأ يحدث تراكمات لـ triglycrides داخل الـ liver cells

*Deficiency of lipotropic factors as choline & methionine accumulation of neutral fat inside liver cells.

*Hepatotoxins as alcohol which fatty acid synthesis, fatty acid oxidation & peripheral lipolysis. There are many other hepatotoxins as CCI4 & some drugs.

*Some liver cell diseases as viral hepatitis C.

2- fatty change of other organs (as kidney & heart) is mainly due to hypoxic or toxic depression of mitochondrial enzymes.

fatty liver

definition: metabolic and morphologic changes in liver cells, Characterized by intracellular accumulation of neutral fat (triglecride)

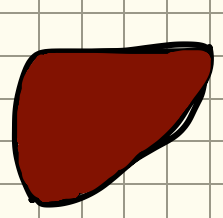

normal liver

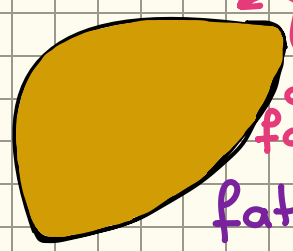

لو كان بسبب (toxaemia) diffuse بيكون fatty degenration

fatty liver

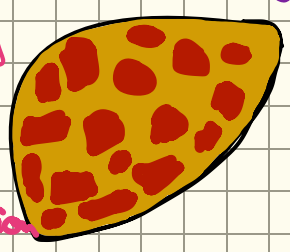

لو كان بسبب ischemea hypoxia أو (نقص O_2) بيكون patchy fatty degeneration

Gross picture

- enlarged.
- Soft.
- rounded borders
- yellowish.
- greasy appearance to touch عليه دهون/شحوم
- patchy or diffuse

Microscopic picture



PATHOLOGY:

Gross picture:

*The organ appears enlarged, with tense capsule. Consistency is soft greasy . cut surface is bulging are rounded. Color is yellow ; diffuse or patchy

*The most commonly affected organs are:

1-liver : Affection may be extensive (diffuse) in severe toxic injury or spotty (patchy) due to milder injury as hypoxia. In such cases the liver appear mottled (nutmeg appearance).

Microscopic picture :

*With ordinary stains fat appears as small clear fat vacuoles or a single large vacuoles that may flatten the nucleus and displace it eccentrically signet ring appearance .

*With special stains fat can be stained orange (sudanIII) or black (osmic acid)

Clinical significance:

Fatty change is a severer form of cell injury that may progress to cell necrosis resulting in

*In case of diffuse heart affection → it may heart failure

*In case of liver affection , it may → progress to liver cirrhosis

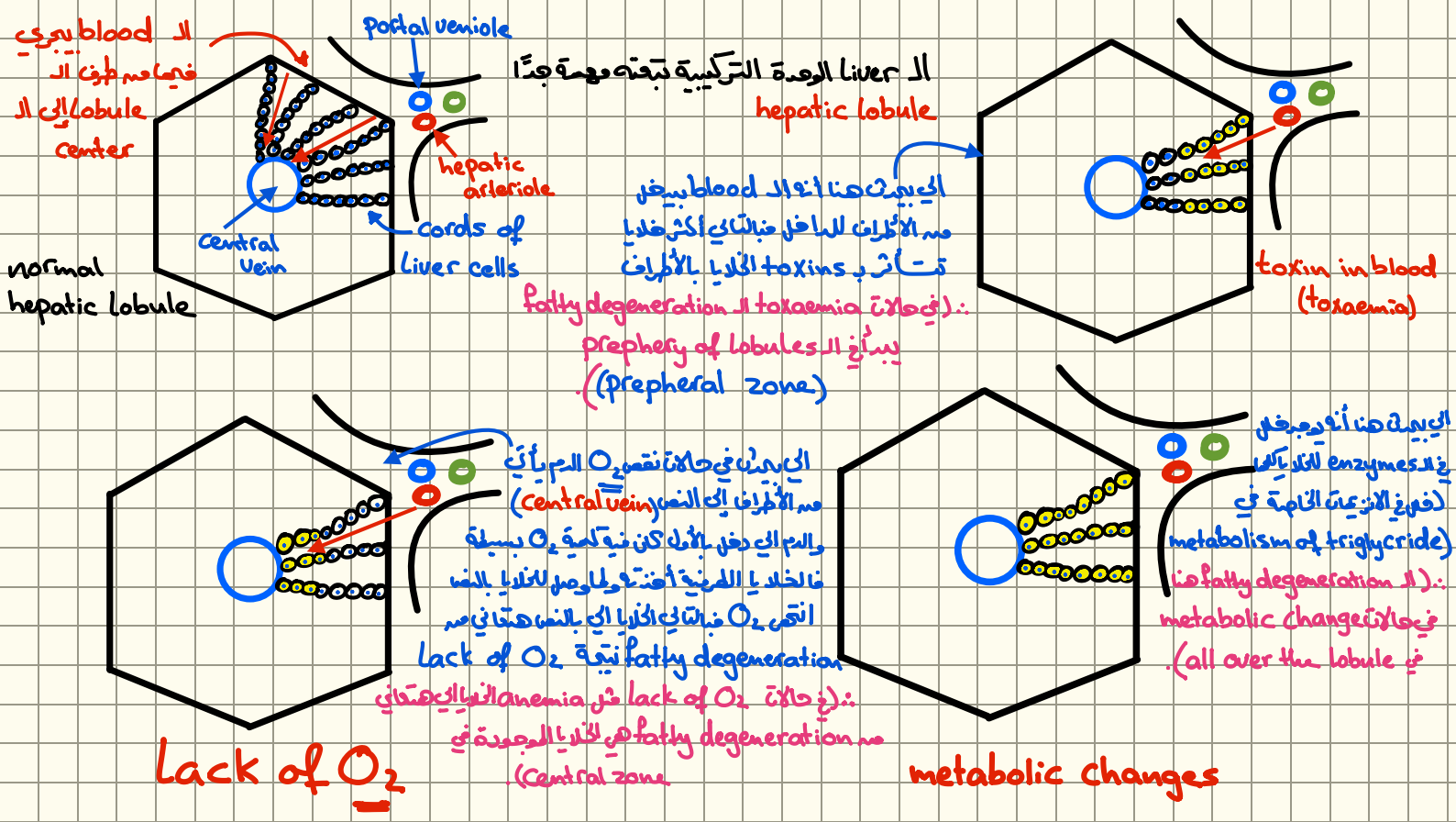

1. Hydropic change means:

A. Accumulation of water in the cell.
B. ~ ~ eosinophilic material in the cell.
C. ~ ~ myxoid ~ ~ ~ ~

2. Fatty Change means:

A. Change of protiens into fat.
B. Accumulation of fat within parenchymal cells.
C. Unmasking of the normal fat in the cells.

3. The commonest site of fatty Change in: A. Spleen B. Kidney (C) liver

* A man who is drinking alcohol for many years shows elevated liver enzymes on routine check up. Liver biopsy shows multiple cytoplasmic vacuoles in the liver cells. No other pathology in liver.
- What is the diagnosis?
Fatty degeneration in liver
- Explain pathogenesis in such condition: Alcohol increases the lipolysis & prevents the coupling of triglycride into lipoprotien.