

Pathology

محاضرة 12 د.سامح

Necrosis 2



Layan

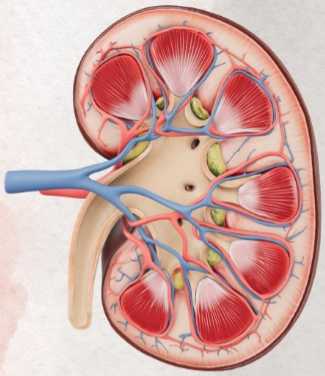

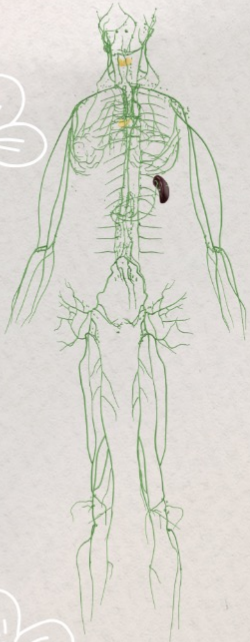

TYPES OF NECROSIS:

1-Coagulative necrosis: (ischaemic necrosis) (infarction) necrosis due to sudden cut of blood supply.

It occurs in infarcts(ischemic necrosis) of all organs except CNS.

There is denaturation of cell proteins , which lasts for at least some days ; thus the basic outline of the necrotic cell is preserved deposite loss of the nuclei.

Finally lysis occurs and necrotic tissue becomes structureless

2- liquefactive necrosis : liquifaction of necrotic tissue

Occurs in infarcts CNS (unknown reasons) and in pus. brain infarction

It is due to prevalence of cell lysis over protein denaturation as in case of pus (by proteolytic enzymes liberated from pus cells)

3- Gangrenous necrosis:

this necrosis (usually coagulative or liquefactive) followed by putrefaction by saprophytes

coagulative necrosis

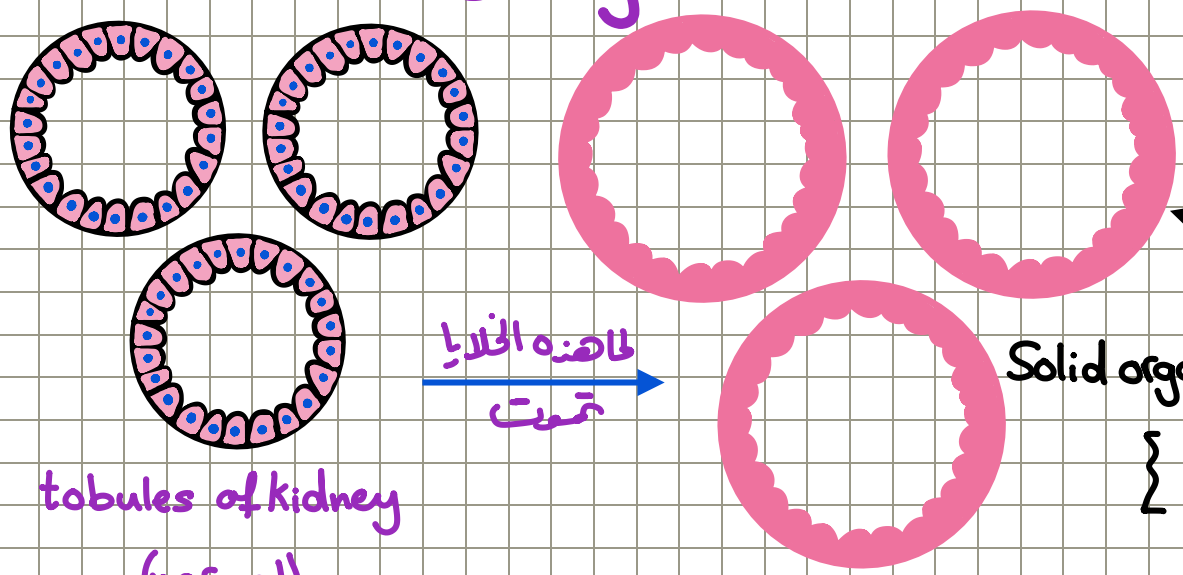

وهذا يحدث في الـ Solid organs

- kidney
- heart

liquefactive necrosis

لو حدث Sudden cut of blood supply in brain (brain ifarction) يحدث ← liquifactive necrosis ليه؟

سبب الـ liquifaction لأن الـ brain فيه كمية fat & fluids كثير (crrebrospinal fluid) CSF

لو حدث أنه bacteria دخلت للأنسجة وعملت necrosis وبدأت WBCs تهاجم هذا الـ dead tissue وWBCs هتطلع انزيمات محللة (proteolytic enzymes) فعملت liquifaction of necrotic tissue

وهذا النسيج الميت الذائب ← abscess

سبب الـ liquifaction

* لو حدث أنه أحد الطفيليات (Entameba histolytica) تدخل على أنسجة مثل liver وهذا الـ parasite هتموّت النسيج الي حواليها وتعمله liquifaction (طلّعت proteolytic enzymes وهذه الـ enzymes موّتت النسيج وعملت liquifaction).

أنواع الـ liquifactive necrosis

- Brain infarction ← high fat and fluid content of brain.
- Pus (pyogenic abscess) ← proteolytic enzymes released from WBCs.
- Amaebic Abscess (Cyst) ← proteolytic enzymes release from parasite

4- Caseous necrosis: the tissue appears as Cheesy material.

This type of necrosis is typical of tuberculosis. The necrotic tissue appears yellowish white & (cheesy) resembling casein (caseous). The caseous appearance is explained by:

-necrosis starts as ischemic coagulative necrosis due to endarteritis obliterans

-coexisting hypersensitivity (allergic inflammation) due to tuberculous antigens tuberculoprotein) release of cytotoxins and proteolytic enzymes partial liquefaction of the coagulated necrotic cells cell fragmentation .

-tubercle bacilli are rich in fats. Liberation of these fats from dead bacteria adds to the cheesy character of this type of necrosis.

*Microscopically it appears granular eosinophilic structureless material (fragmented necrotic cells).

5-Fat Necrosis : two subtypes :

Fat necrosis = necrosis in fatty area
necrosis of Adipose tissue. (in subcutaneus tissue)

a) enzymatic fat necrosis :

*Cause :it occurs in cases of acute hemorrhagic pancreatitis

*Mechanism : ruptured pancreatic ducts escape of lipase and protease enzymes digestion (necrosis) of the surrounding peritoneal fat cells .

*Grossly : the affected areas may show chalky white hard calcific patches. this is because fatty acids liberated from necrotic fat cells have a high affinity to combine with calcium forming calcium soaps.

*Microscopically: swollen necrotic fat cells , surrounded by chronic inflammatory cells (including foreign body giant cells) and fibrosis , sometimes with calcification.

b)Traumatic fat necrosis :

*Cause : it is common in the female breast and subcutaneous fat & is usually caused by trauma (which may be surgical)

*Mechanism: rupture of fat cells results in their auto -digestion and release of fatty acids , which combine with calcium. dystrophic calcification

الطباشير الأبيض

*Grossly : hard , sometimes chalky white mass. It may be clinically mistaken for a tumor as in case of fat necrosis of the breast . biopsy will diagnose the condition . (fat granuloma)

*Microscopically resembles enzymatic fat necrosis .

6-Fibrinoid necrosis :it affects muscle fibers &collagen which become fragmented finer particles resembling fibrin . it develops in autoimmune collagen disease (as rheumatic fever , reheumatoid arthritis , lupus erythematosus ...etc). .it is due to autoantibodies against collagen . it is not true necrosis since it does not affect living cells.

الـ Collagen يتكسر إلى fibrin like Structure

Fat necrosis

enzymatic fat necrosis

Acute pancreatitis عندما يحدث التهاب في البنكرياس

Acute hemarrhagic pancreatitis

الانزيمات الموجودة فيه trypsin + lipase بيطلعوا من البنكرياس بيروحوا على الـ Abdomen ← وهذا lipase بيهضم الدهون بالتالي هيهضم دهون البطن إلى glycerol + Fatty Acid

trypsin ← هيروح blood vessels ويُدمّر جدرانها فيحدث نزيف والدم الي طلع يحتوي على Ca^+ و Ca مع Fatty Acid يعمل Saponification (Calcium Soap)

traumatic fat necrosis (non-enzymatic)

الخلية حدث لها rupture هيطلع الـ fat برا الـ cell

fat cells

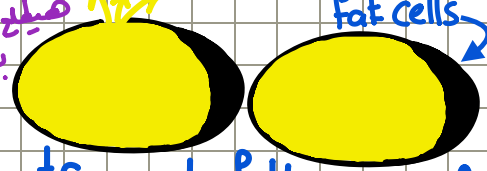

trauma to fatty area or tissue حدث بالتالي هيحدث rapture of fat cell وطلع منها الـ Fatt ← لما هذا fat طلع لبرا صار بالنسبة للجسم جسم غريب (بالنسبة للنسيج حولها) فيبدأ immune system يتفاعل مع هذا الموقف هيطلع Macrophage cells وتُهاجم هذه المنطقة وهتبدأ تلتهم هذه fats وهيصير cytoplasm foomy (في macrophage) وبالآخر تتكون كتلة في هذا المكان