



Pathology

محاضرة 4 د.سامح

Inflammation

(Types of acute inflammation)

Layan



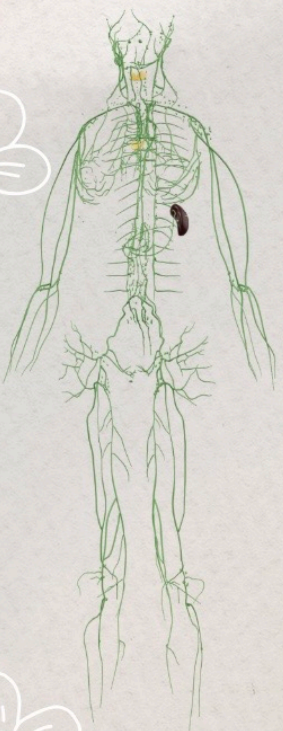

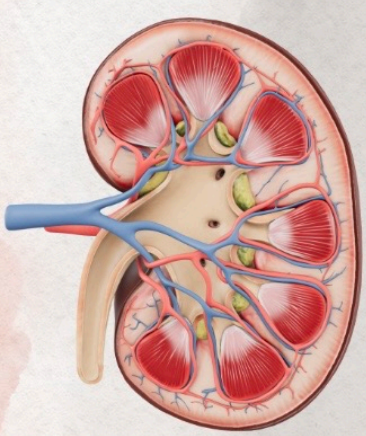

Types of acute inflammation

1-Suppurative (purulent , septic or pyogenic) inflammation : characterized by pus formation . suppurative inflammation be :

a) localized as abscess , boil and carbuncle

b) diffuse as cellulitis , suppurative appendicitis & diffuse septic peritonitis.

2-Non suppurative types:

a)serous, b)fibrinous, c)serofibrinous, d) catarrhal, e) pseudomembranous

f) hemorrhagic, g) necrotizing, h) allergic

شوية مصطلحات

- pus = liquified necrotic tissue .
- suppuration = Formation of pus تكوّن الصديد
- related to pus → pyogenic or suppurative

Acute inflammation

Note: any acute inflammation:

1. congested blood vessels.
2. inflammatory oedema (inflammatory fluid exudate)
3. Cells ⇒ PMNL.

microscopic picture

Associated with pus formation.
= (suppurative inflammation)

Localized
⇓
caused by (staphylococcus aureus)
↓
release coagulaze enzyme
↓ بتكوّن
Fibrin network
↓ بتعمل
localize the infection.

diffuse
caused by (streptococcus hemolyticus)
↓
release: - hyaluronidaze enzyme. يذوب المادة اللاصقة من الخلايا
- Fibrinolysins. يذوب الـ fibrin
↓ يؤدي إلى
spread of the infection.

Not Associated with pus.
= (non-suppurative inflammation)

- Formation of mucous ⇓ Catarrhal inflammation
- Formation of pseudomembrane ⇓ pseudomembranous inflammation
- Formation of fibrin ⇓ fibrinous inflammation
- Formation of serous Fluid ⇓ serous inflammation
- Formation of Fibrin & serous fluid ⇓ serofibrinous inflammation
- rupture of blood vessels ⇓ hemorrhagic inflammation
- excess eosinophils ⇓ Allergic inflammation

mucous membrane (GIT & respiratory tract)

هالنوعين خاصين فقط في الـ mucous membranes

مابيجي غير فيهم .

lung
اسمه ⇓
Labor pneumonia

serous sacs
هما ⇓
- pleura.
- pericardium.
- peritoneum.

Smallpox

فايروس عنيف بيكون المريض عنده الـ visscles وكلها بتكون مليانة دم من عنف هذا الفايروس بيعمل rupture هذه الـ blood vessels.

Catarrhal inflammation

هذا virus بيعمل attack لل mucous membrane وبيزود افراز ال mucous.

virus = common cold virus

Cells swallen & filled with myosin and some cells ruptured with release of mucous.

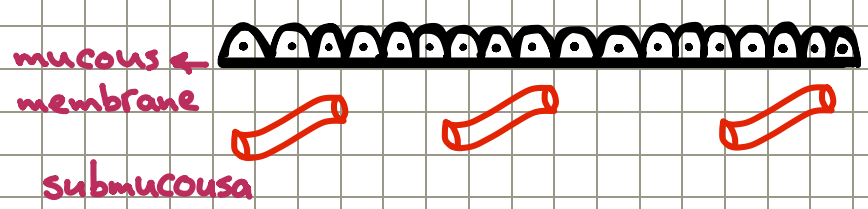

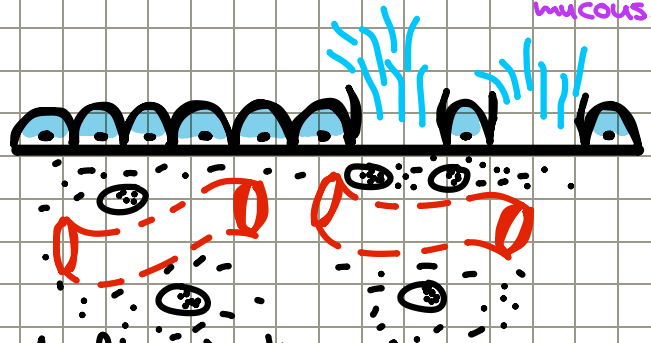

هاي الحالة اسمها catarrhal rhinitis = catarhal inflammation of nose

pseudomembranous inflammation

بعدما ال bacilli طلعت toxins تبعتها هتنتشر في mucous membrane وفي ال sub mucousa وهيعمل necrosis ال cells تبعت mucous membrane

bacilli $\xrightarrow{\text{هتطلع}}$ toxins

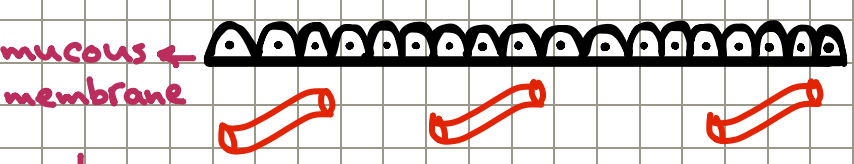

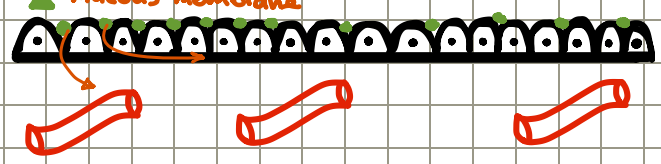

في ال pseudomembranous inflammation المُسبِّب إله نوع من أنواع bacteria اسمها

diphthria bacilli ⇒ - powerful toxic bacteria.
- aerobic (يعني مابتخل جوا الأنسجة بس بتكون برا)

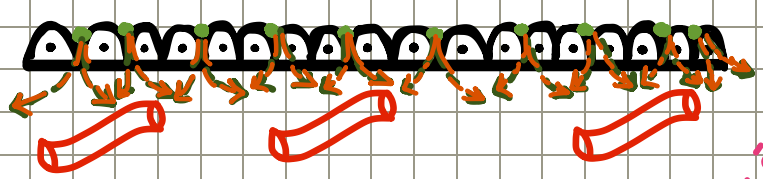

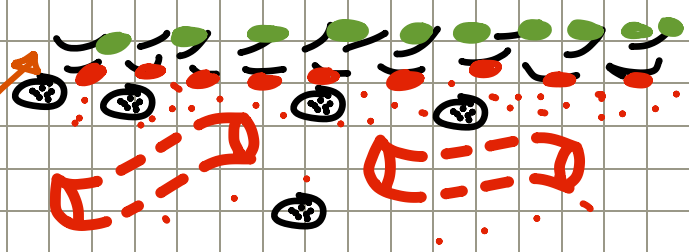

هذا عبارة عن

وشو حدث في ال submucousa؟!

1- congested blood vessels. العادي اللي هو
2- inflammatory oedema.
3- PMNL.

necrotic tissue + bacteria + fibrin + RBCs

وكل هدول بيكونوا ال pseudomembrane

Characteristics:

1. yellowish.
2. dirty.
3. adherent.
4. on removal leaves bleeding surface

I- suppurative inflammation

purulent , septic or pyogenic

Definition: acute inflammation characterized by pus formation (liquefactive necrosis).

Caused by pyogenic organisms as staphylococcus aureus ,staphylococcus hemolyticus, gonococci, pneumococci and others .

Types of suppurative inflammation:

1-localized: commonly caused by staphylococcus aureus which produce coagulase enzyme fibrin deposition localization .

the most common forms of localized suppurative inflammation are :

a) abscess. B) boil (furuncle). C)carbuncle.

2-diffuse: caused by streptococcus haemolyticus which produce hyaluronidase (spreading factor) & streptokinase (fibrinolysin) which dissolves fibrin .

the most common examples are :

a)cellulitis b)suppurative appendicitis c)diffuse septic peritonitis.

II- NON SUPPURATIVE INFLAMMATION

SEROUS INFLAMMAION

Characterized by excessive serous fluid poor in fibrin.

Examples:

- Skin blisters due to skin burns.
- Epidermal vesicles due to herpes simplex viral infection.
- Inflammation of serous membranes (pleura, pericardium and peritoneum)



FIBRINOUS INFLAMMATION

Characterized by an exudate rich in fibrin, with a little fluid component

Examples:

1)Lobar pneumonia : excess fibrin consolidation of the affected lobes.

2)Adult hyaline membrane disease.

3)Inflammation of serous membranes.

SEROFIBRINOUS INFLAMMATION OF SEROUS MEMBERANES

DEFINITION: this is inflammation of serous membranes rich in both fluid exudate fibrinogen.

the fluid component may predominate (wet or serous type).

Remark: serous membranes may be affected by other types of inflammation **e.g.** suppurative inflammation.

Gross picture:

At the beginning , the visceral and parietal layers of the serous membrane appear hyperemic and edematous. احمرار وتورّم

Then they become thickened , reticulated , opaque and grayish ,particularly in case of the dry (fibrinous) type. شبكية معتمة

The serous sac cavity contains abundant serous fluid (effusion) particularly in case of the wet (serous) type.

Microscopic features:

Serosal cells undergo degeneration and shedding

The subserosa shows dilated capillaries , fibrin and acute inflammatory cells.

In case of dry (fibrinous) inflammation the , the serosal layer becomes covered by thick network of fibrin entangling acute inflammatory cell

CATARRHAL INFLAMMATION

Characteristics: a mild form of acute inflammation of mucous membranes characterized by an exudate mixed with mucus secreted by the irritated mucous membrane.

Examples: catarrhal rhinitis (common cold) and catarrhal appendicitis.

Gross picture: swollen hyperemic mucosa; first dry then pours a discharge of serous fluid mixed with mucin.

Microscopic picture: epithelial cells of the mucosa are swollen and vaculated de to excess mucin (mucoid degeneration). The submucosa shows dilated capillaries, PMNS, macrophages and fibrin.

Pseudomembranous (membranous) INFLAMMATION

Characteristics & pathogenesis:

- A severe form of acute inflammation of mucous membranes characterized by a false membrane composed of necrotic tissue & fibrin.
- Virulent bacteria secreting exotoxins as mycobacterium diphtheria mucosal necrosis and marked submucosal inflammation false membrane composed of **necrotic mucosal patches and excessive fibrin** .

Examples: diphtheria &bacillary dysentery .

Gross picture: the original mucous membrane is replaced by another (false) membrane ,which appears yellowish gray , thick and adherent .if forcibly removed ,it leaves a bleeding surface and is reformed rabidly .

Microscopic picture: the false membrane consists of necrotic patches ,fibrin , bacteria and acute inflammatory cells . the underlying submucosa shows dilated capillaries , fibrin and acute inflammatory cells (PMNs and macrophages).

HAEMORRHAGIC INFLAMMATION



Characterized by excess RBCs within the exudate due to associated vascular damage.

Example: small pox & hemorrhagic cystitis

NECROTIZING INFLAMMATION



Characterized by: extensive necrosis in association with inflammation.

Example: cancrum oris .

التهاب فم غنغريني حاد ومدمر يصيب الأنسجة الرخوة والعظام في الفم والوجه

ALLERGIC INFLAMMATION

The Underlying cause of inflammation in hypersensitivity.

Characterized by many eosinophils.

Example: urticaria , allergic rhinitis and bronchial asthm

Mechanism (pathogenesis) of pus formation:

- Pyogenic organisms cause:

a) Remarkable necrosis.

b) Attraction of a huge number of neutrophils.

c) Death of many neutrophils due to high virulence of the bacteria.

- Dead neutrophils (pus cells) release their proteolytic enzymes liquefaction of necrotic tissue &fibrin. The liquefied material mixed with pus cells & fluid exudate form a turbid creamy fluid called pus.

mechanism of pus formation = pathogenesis of pus

bacteria responsible for pus formation ↓ pyogenic bacteria هي اللي هتعمل الصديد

staphylococcus أو streptococcus يعني

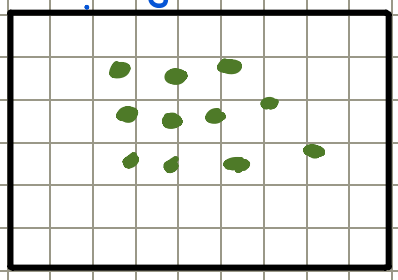

bacteria هتدخل للأنسجة

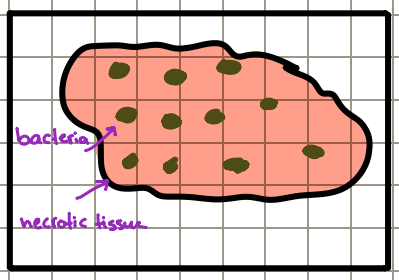

necrosis تبقى وحشة toxins طلعت من bacteria

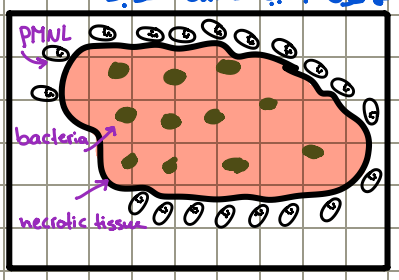

PMNL هتقاوم bacteria وتقضي عليها فتتعرض للموت بسبب toxins الموجودة.

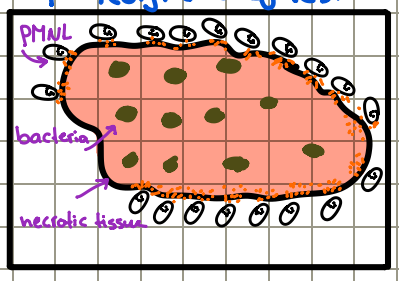

بعدها PMNL هتطلع منها proteolytic enzymes.

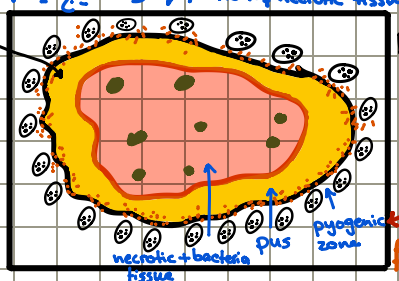

هتموت dead PMNL هذه الإنزيمات هي اللي هتسبب liquifaction of necrotic tissue وهذا النسيج هيتحول لـ زلال

الصديد عبارة عن: (pus)

liquified necrotic tissue by proteolytic enzyme released from dead PMNL.

بعدها شو بصير؟

على حسب الـ bacteria:

- staphylococcus aureus إذا كانت ← هتطلع coagulaze enzyme وتكون fibrin network حول البقعة ويصير Localization
- streptococcus hemoliticus إذا ← هتطلع lytic enzyme اللي هتحلل ← spread of the pus of infection

هذا الترتيب ← from periphery to the center

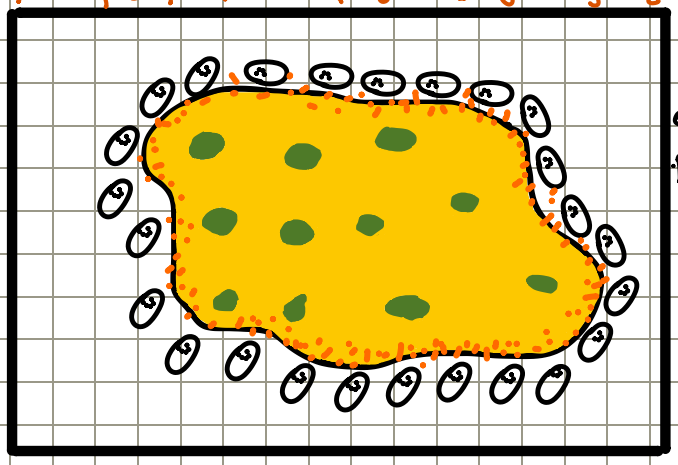

أخيراً: PMNL بتفضل تطلع وتموت عشان يتكون enzymes اللي بتطلع فتسبب تحلل النسيج الميت وبتحوله إلى pus.

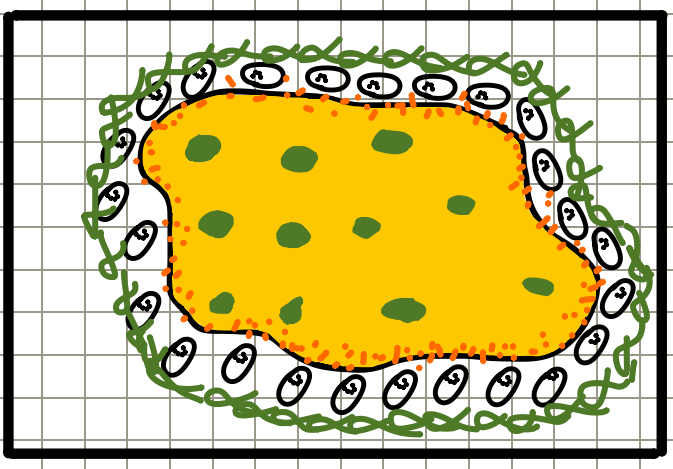

fibrin network وتكون localized حوالين staphylococcus aureus في bacteria ∴

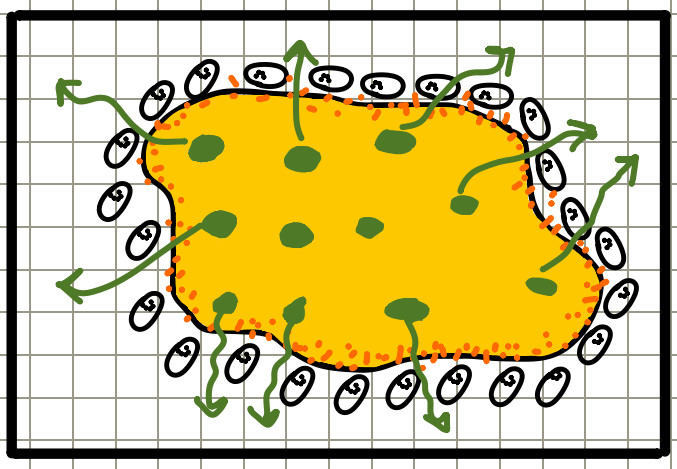

bacteria طلعت diffuse حوالين bacteria بالـ lytic enzymes اللي هتعمل spread for the infection.





supparative inflammation (diffuse)

spread for the ⇐ (حدث infection).







supparative inflammation (Localized)

(تكون fibrin network عملت Localization للـ infection).



هذا هو pus اللي بيطلع من inflammation

(liquified necrotic tissue by proteolytic enzyme released from dead PMNL.)

مكونات الـ pus Composition of pus:

- Fluid exudate without fibrin (liquefied).
- Cells: a large number of pus cells ,neutrophils , some macrophages & some RBCs
- Necrotic fragments (sloughs) and liquefied necrotic tissue.
- Bacteria and bacterial pigments which may be yellowish (as in staphylococcas infections) or greenish .

Constituents of pus:-

1. liquified necrotic tissue.
2. dead and living bacteria.
3. dead and living PMNL.
4. inflammatory exudate.
5. pus doesn't clot on standing → fibrin dissolved by proteolytic enzymes of dead PMNL.
6. Alkaline → Alkaline phosphatase.





لما بدنا نطلع هذا pus من منطقة ال inflammation ما بنعمل ← Local anathesia

بنعمله ← General anathesia

abscess بنعملها ببنج كلي (local anathesia) ← لأنه Local anathesia inactive in alkaline

pus cells (dead PMNL)

هي عبارة عن الخلايا الي لما ماتت طلع منها enzymes عملت pus. (pus ما بطلع إلا لو كانت PMNL ← dead)

pyogenic membrane

zone of dead & living PMNL around the area of pus.

هذا فقط بيكون موجود في supparative inflammation فقط (localized or diffuse)

supparative inflammation

- Localized
  - الفرق الوحيد بينهم هو site لكن كلهم
  - staphylococcus aureuos ← organism و
  - Abscess
  - boil
  - carbuncle
- diffuse
  - phlegmonous inflammation. (cellulitis)

هذا الفرق الوحيد

site

بيجي في أي مكان

hair folicles

subcotaneus tissue of the back

- subcotaneus tissue. ← (cellulitis)
- Loose tissue
  - in pelvis
  - in orbit

Abcess

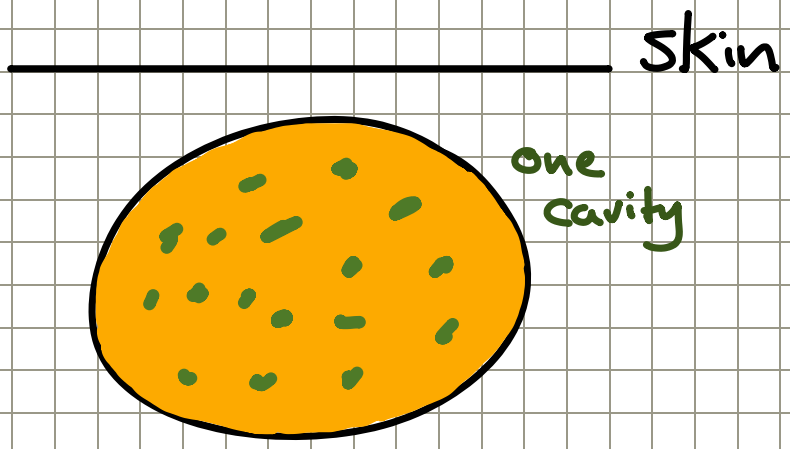

Curbuncle

بيجي للناس اللي مناعتها ضعيفة (مصابين diabetes)



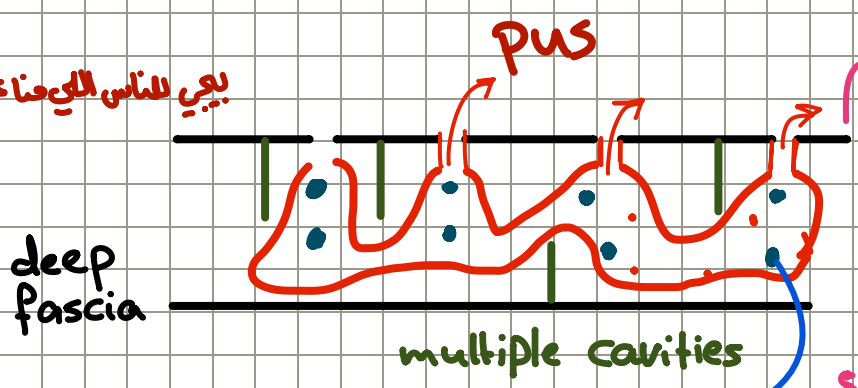

skin of the back. + diabetes.

لأنه مريض السكر مناعته ضعيفة وكمية glucose عنده في الأنسجة عالية جداً و glucose هي المادة اللي بتتغذى عليها staphylococcus aureus فمن السهل جداً تدخل على skin of the back.

بسبب fibrous set الموجودة فقط في (skin of the back) + قدرت البكتيريا تخترقه بسبب المناعة الضعيفة & glucose الكثير

- A male patient with diabetes (45 years), his back & buttocks (Curbuncle case) ← multiple sinuses discharging pus

CARBUNCLE

- A special type of localized suppurative inflammation characterized by multiple communicating deep subcutaneous abscesses, opening on skin by multiple sinuses.
- It only occurs in special sites where the skin and subcutaneous tissues are thick and tough due to dense fibrous septa that extend between the deep fascia and the dermis; thus dividing the subcutaneous fat into compartments, therefore infection reaching these multiple compartments leads to multiple suppurative foci. Sites of carbuncle include back of neck, scalp & buttocks.
- More common in diabetics (low immunity). It starts as a boil then progress carbuncle

FURUNCLE (BOIL)

Staphylococcas infection of the hair follicles (folliculitis) is common in the face of males and axilla of females. Folliculitis may regress, or progress to suppuration furuncle (boil) =small abscess related to the hair follicle. Furuncles may be multiple (furunculosis).

ABSCESS

Definition:

A type of localized suppurative inflammation characterized by a cavity containing pus.



Aetiology:

it is commonly caused by staphylococcus aureus infection.

Sites:

it is most common in the subcutaneous tissues, but can occur in any organ (lung, liver, brain, kidney, testis, ovary...etc)

Pathological features:

1- Early, two zones can be recognized:

a) A central zone of necrotic.

b) A peripheral zone of inflammation showing many neutrophils, pus cells, macrophages, dilated capillaries and fibrin.

2-later, progressive liquefaction starts at the margin of necrotic tissue three zones:

A)a center necrotic core.

b)A mid zone of pus.

c)The peripheral zone of inflammation (now called the pyogenic membrane).

3-further enlargement: the center necrotic core may disappear by further liquefaction and the abscess may enlarge if the bacteria cause further necrosis and liquefaction.