

# Pathology

## محاضرة 5 د.سامح

## Fate of abscess & chronic inflammation



Layan

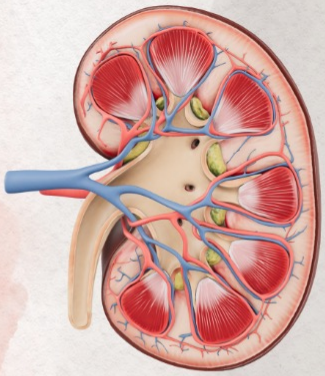

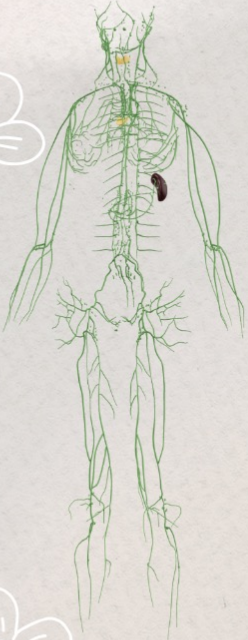

# Types of inflammation

- Acute
- subacute
- Chronic

## Acute

- supparative
  - Localized
    - Abscess — any site
    - Boil — hair folicle
    - Curbuncle
      - Skin of back.
      - DM.
  - diffuse (phlegmonus) infl.
    - Loose tissue
    - SC.
- non-supparative
  - Catarrhal.
  - pseudomembranous.
  - fibrinous.
  - Serous.
  - Serofibrinous.
  - hemorrhagic.
  - Allergic.

## Abscess

- Localized supparative inflammation.
- Localized area of suppuration.
- Cavity containing pus.

## fate of abscess:

**a)Small abscess:** pus is may be absorbed, followed by healing.

**b)Large abscess:** since absorption of pus occurs at a very slow rate, a big abscess (if not surgically incised) pointing & rupture (spontaneous evacuation) healing.

# Fate of Abscess

- Surgical Complete evacuation (good fate)
  - if mild → resolution
  - if destruction of tissue → repair
    - regeneration
    - organization

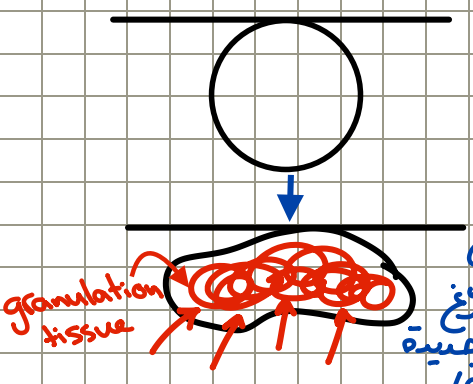


Collapse هيحدث
لهذا الصديد وهيتفرّغ
وهتمتلئ بأنسجة جديدة
(granulation tissue)

- Complications

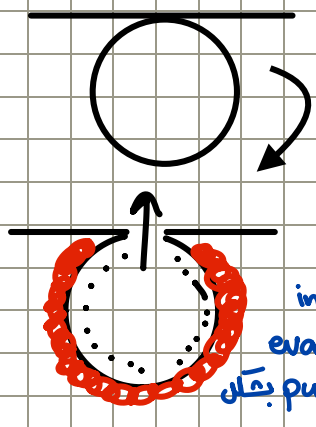

هنا حدث
incomplete
evacuation
(لم يحدث خروج pus بشكل
كامل)

# Complications

## Complications of healing




Chronic ulcer

discontinuity of surface epithelium

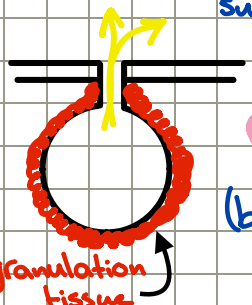


Chronic sinus

(blind ended tract)

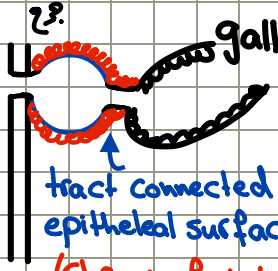


Chronic fistula

(Chronic fistula)

## Chronicity

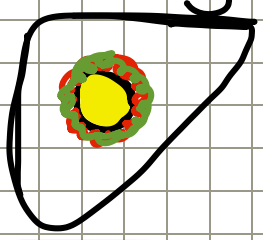

Chronic abscess

تلتئم جزئيا وتحل محلها granulation tissue و fibrous tissue

- يحدث ضغط على الأنسجة المحيطة pressure
- Secondary systemic amyloidosis.

## Spread

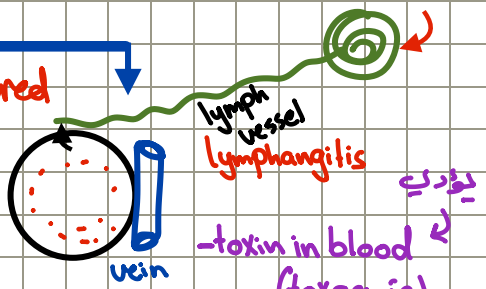


يؤدي إلى:
- toxin in blood (toxaemia).
- bacteria + toxin (septicaemia).

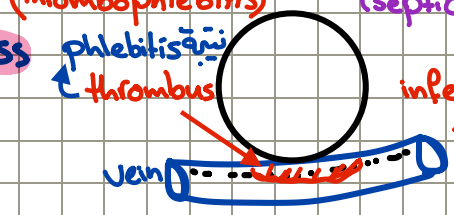


التهاب يحدث إذا كان هناك puss يحمل التهاب في vein
يحدث damage of endothelium of the vein
فتتكون thrombosis وطرف فيها بكتيريا
بالتالي الجلطة + البكتيريا بدأت تتفتت و تعشش في Circulation وتنزرع في other organs

وهذا يسمى عبارة عن pyaemia (جلطات قيحية)

# Complications of abscess:

## 1- spread of infection:

a)Direct spread leads to abscess enlargement.

b)Lymphatic spread leads to lymphangitis and lymphadenitis.

c)Blood spread may lead to:

- Toxaemia: bacterial toxins circulating in the blood.
- Septicaemia: large numbers of virulent bacteria & their toxins circulating in blood. Commonly fatal.
- Pyaemia: septic venous thrombi (septic thrombophlebitis)may develop close to the abscess. If these thrombi become fragmented circulating septic emboli multiple small abscesses in distant organs. These small abscesses are called pyemic abscesses and the whole process is called pyemia

2- Complications of evacuation and healing :

a)Ulcer: it is a local defect within a surface (skin, mucosa…). It is due to separation of inflammatory necrotic tissue. If infection persists defective healing chronic ulcer

b)Sinus: it is a blind ended tract between a deep abscess and the surface, e.g. a peritoneal abscess may cause sinuses on the abdominal wall. if infection persists it remains as a chronic sinus

c)Fistula: evacuation of a deep abscess may result in a tract communicating between two surfaces or hollow organs. This double ended tract is called fistula. Ano-rectal fistula
complicating a perianal abscess is an example. If infection persists ,it changes into a chronic fistula.

d)Keloid

e)Hemorrhage e.g. hemoptysis when a lunge abscess opens into a bronchus.

f)Rupture: e.g. brain abscess into ventricles & right hepatic lobe abscess into base of right lung

3-Chronicity: if the abscess is neither evacuated spontaneously nor surgically, it gets surrounded by fibrosis and becomes a chronic abscess. Pus dries and dystrophic calcification may occur.
Examples: a) chronic abscess: may be clinically mistaken for a tumor.
b) chronic lung abscess.

4- Other complications:

a)Putrefaction gangrene (e.g. putrefaction of a lung abscess by saprophytic bacteria)

b)Compression effects : e.g. in case of brain abscess
increased intracranial tension & liver abscess obstructive jaundice.

# Fate of Abscess

## Good

if mild → resolution (ما بتخلف أنسجة) — الحالات بسيطة جدًا

if destruction of tissue → repair (على حسب الخلايا)

- healing by regeneration: لو الخلايا ليها القدرة على التكاثر (نفس نوع الخلايا)
- repair by organisation: لو الخلايا ليس لها القدرة على التكاثر (تعوّض الأنسجة بألياف بنوع آخر من الأنسجة (fibrosis))

## Bad

- Spread
  - lymphangitis
  - lymphadenitis
  - toxamia
  - septicaemia
  - pyaemia
- Chronicity
- non supparative
  Supparative ← يصير

| | Acute inflammation | Chronic inflammation |
|---|---|---|
| Onset | Sudden onset بدأ فجأة | gradual Onset يبدأ تدريجيًا |
| duration | Short duration | Long duration |
| vessels | Congested blood vessel (dilated) | thick walled (fibrosis) |
| inflammatory exudate (oedema) | marked oedema | minimal |
| Cells | PMNL | -lymphocytes -plasma cells -macrophage. |
| fibrosis | Absent | present |
| toxaemia | marked | Less marked. |
| Fever | marked | Low grade fever |

# CHRONIC INFLAMMATION

## PATHOLOGICAL FEATURES OF CHRONIC INFLAMMATION

- Chronic inflammation lasts for a long duration .
- It may follow acute inflammation due to failure of defense mechanisms .
- It may start chronic by gradual onset (not preceded by an acute phase ) due to one or more of the following :

a) Infection with resistant organisms e.g. tuberculosis .

b) Non -living irritants as foreign bodies e.g. silicosis &asbestosis (inhalation of silica or asbestos particles into lungs )

c) Development of autoimmunity e.g. rheumatoid arthritis .

- The inflammatory response basically resembles that of acute inflammation .the main differences between acute & chronic inflammation are listed in the next table

## Chronic inflammation

- may Start Chronic.
- or on top of acute. → repeated acute attacks.
  → in adequate treatment of acute attack.

## Chronic inflammation

granulomatous

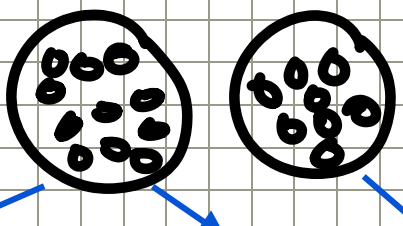

infective — non infective — unknown

- bacteria
- virus.
- parasite.
- foreign body.
- talc powder.
- sarcoidosis.

non-granulomatous (diffuse)

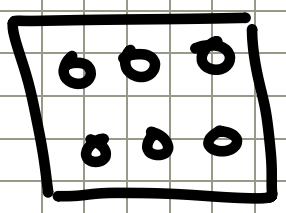

يوجد أنواع من الـ Chronic inflammation بتحصل diffuse وأنواع أخرى بتحصل granuluma

# GRANULOMAS

## DEFINITION & PATHOLOGICAL CHARACTERISTICS:

- A particular form of chronic inflammation characterized by nodular collections of macrophages with a variable mixture of lymphocytes , plasma cells , giant cells & sometimes neutrophils .
- The macrophages commonly change into large eosinophilic cells . these modified macrophages are called epithelioid cells
- Some granulomas may exhibit central necrosis .
- Granulomas often represent type IV hypersensitivity , where stimulated T lymphocytes release lymphokines that attract large numbers of macrophages

## TYPES OF GRANULOMAS:

1- infectious granulomas : most of these granulomas are necrotizing .Examples:

- Bacterial as tuberculosis , brucellosis , syphilis , leprosy and cat -scratch disease .
- Parasitic as schistosomiasis (bilharziasis)
- Fungal as coccidiomycosis , crypococcosis and histoplasmosis .

2-foreign body granulomas : mostly non-necrotizing granulomas. Examples :

- Silicosis .
- Foreign body granulomas around surgical sutures , or other foreign bodies when trapped in a tissue as pieces of glass , metal , wood... etc.

3-granulomas of unsettled aetiology : mostly non-necrotizing granulomas . Examples: Sarcoidosis & Crohn's disease