

Pathology

محاضرة 3 د.سامح

Fatty, mucoid, hyaline, and fibrinoid degeneration



Layan

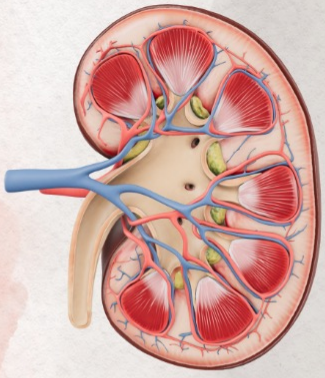

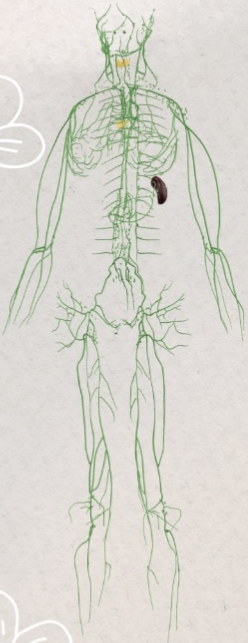

Gross picture:

تابع للمحاضرة السابقة

*The organ appears enlarged, with tense capsule. Consistency is soft greasy . cut surface is bulging are rounded. Color is yellow ; diffuse or patchy

*The most commonly affected organs are:

1-Heart: Affection may be also diffuse as in case of diphtheritis toxic myocarditis or patchy such as in hypoxia cases . patchy affection of myocardial fibers yellow streaks alternating with the non-affected brownish muscle fibers tigroid or tabby cat appearance .

2-kidney: affection is mainly cortical (where tubules exist) & is spotty or rarely diffuse.

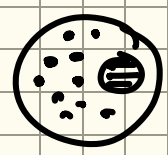



- water → Cloudy swelling / Hydropic degeneration } inside the cells.

- Fat → fatty degeneration
- mucin → entracellular & extra cellular
- abnormal protien

in the staining → basophilic (لونها أزرق) / esinophilic (لونها أحمر)

Mucin (basophilic) لونها أزرق

Mucoid degeneration
intra cellular



لو mucin زاد جوا الخلية هيعمل signet ring appearance

e.g - Catarrhal rhinitis التهاب رشحي (inflammation)
- mucoid carcinoma (mucoid cancer)

Myxomatous degeneration
extra cellular (stromal CT)

لو زاد برا الخلية هيضغط على الخلايا من برا ويعطي star shaped cells

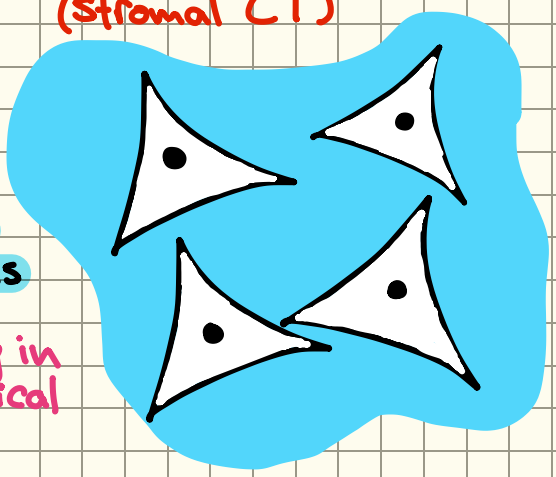

e.g normally in the umbilical cord يعني هذا مش مرض

- myxoma (tumor in the heart)
- myxoedema نقص افراز الـ Thyroid فبتراكم mucin ويعمل

INTRACELLULR ACCUMULATIONS AND EXTRACELLULAR DEPOSITIONS

1- INTRACELLULR ACCUMULATIONS

Water

See cloudy swelling & hydropic degeneration

FATS

*Change: see before.

*Atherosclerosis: see systemic pathology.

*Xanthoma: deposition of fat in skin (engulfed by dermal macrophages).

*Gaucher's disease: accumulation of glucocerebrosides inside phagocytic cells.

*Neimann picks disease: accumulation of sphingomyelins inside phagocytic & parenchymal cells .

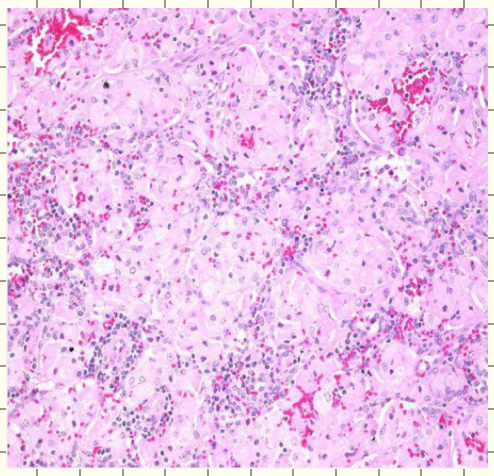

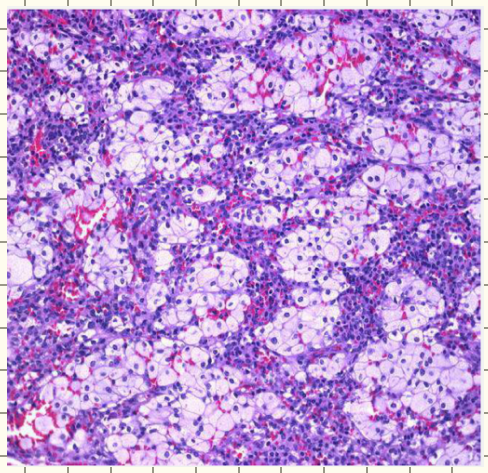

MUCIN

MUCOID DEGENERATION

*This is accumulation of mucin inside epithelial cells which swell & show vacuolated cytoplasm, may with eccentric nuclei (signet ring cells). Cells may rupture leading to extracellular pools of mucin.

*Occurs in a number of pathological conditions. Example

- In case of catarrhal inflammation (see before).
- In case of mucoid and signet ring cell carcinoma (see later).
- In case of mucinous cystadenoma of the ovary (see later).

*Remark: extracellular accumulation of mucin is called Myxomatous degeneration (see later)

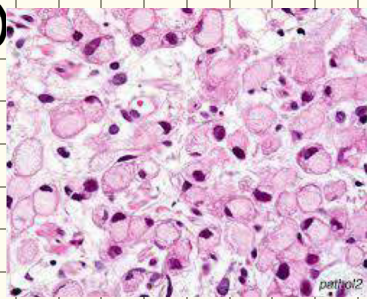

hyaline degeneration (eosinophilic).

تراكمات بشكل إما داخل أو خارج الخلايا.

مادة بروتينية تتراكم في الأنسجة ولأنها بشكل متجانس وليس لها تركيب محبب (hyaline) وتصبغ eosinophilic (homogenous)

- protienous مادة بروتينية
- structureless. ليس لها تركيب محبب
- homogenous.
- eosinophilic. لونها أحمر

intracellular

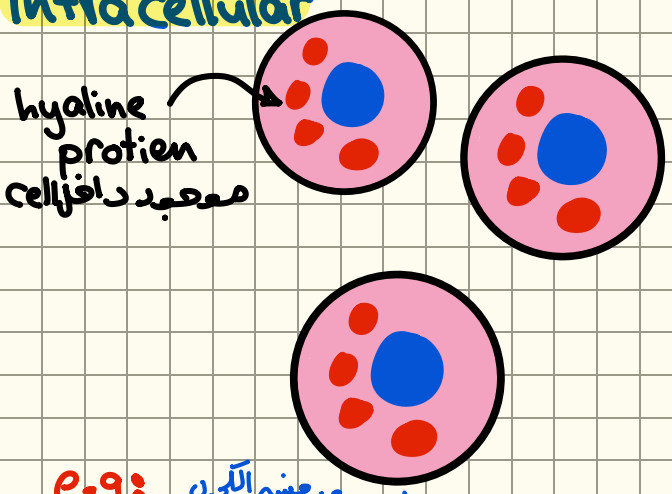

e.g: مع شرب الكحول

1. liver
   - alcohol → Mallory's bodies (اسمها) عندهم في liver وهي hyaline
   - viral hepatitis → Councilman bodies (اسمها) عندهم في liver وهي hyaline

2. kidney → renal tubular cells. → GN (ليس لها اسم)
   GN (glomerulonephritis) التهاب الكلية اسمه

3. inflammation of nose (معدية جرثومية) → Rhinoscleroma (اسمها)
   nose + thikining
   plasma Cell → Rihnoscleroma → Russel bodies (اسمها)
   عند أخذ عينة من nose موجود فيها plasma cells



4. Skeletal muscle → toxaemia → Zenker's degeneration
   الي حدث هنا انو المريض كان عنده toxins في الدم وهذا الـ toxin أثر على العضلات ← تراكم بداخلها ← هذا شو بسمى هذه العضلة واسم الي اكتشف هذا الـ Zenker ← proteins
   Zenker عشان هيك اسمها Zenker

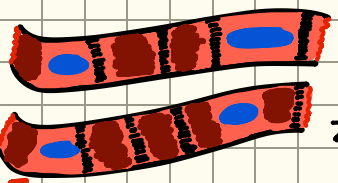

5. pituitary gland → basopholic cells → Cushing's disease
   pituitary gland تفرز ACTH ويزيد الـ Cortisol ويزيد بسبب وجود Hyaline protien بداخلها هذا الورم. (ليس له اسم)

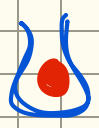

extracellular

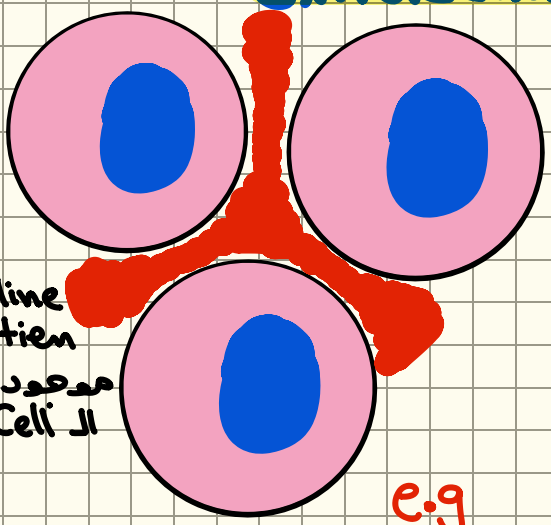

e.g



Arteriolosclerosis

Sclerosis = thikining

سبب هذا الـ Sclerosis ترسب hyaline material في جدار arteriole بنسميها hyaline arteriolosclerosis.

PROTEINS

HYALINE CHANGE (HYALINOSIS)

DEFINITION:

The term "hyaline" refers to any cellular or extracellular alteration manifested by homogenous, glassy-pink appearance in sections stained with hematoxylin & eosin. It is a microscopic change with no specific gross features. The mechanism of hyalinosis is excess protein, synthesized or deposited in the affected cell or matrix.

Examples of cellular hyalinosis:

*Russel bodies: hyaline change of plasma cells which appear as bright eosinophilic oval bodies . it is due to overproduction of immunoglobulins in some prolonged chronic inflammations as rhinoscleroma.

*Mallory alcoholic hyaline seen in liver cells in alcoholic hepatitis. عند وجود مشكلة الكحول

*Hyalinosis of islets of Langerhans in cases of diabetes mellitus.

*Corpora amylacea: laminated hyaline bodies in the lumen of prostatic acini in cases of prostatic hyperplasia. تضخم البروستاتا

Examples of extracellular (connective tissue) hyalinosis:

*Hyalinosis of old scars and keloids. الندب أو الندب الكيلويدي

*Hyalinosis of organized (fibrotic) thrombi. جلطات

*Hyalinosis of some mesenchymal tumors as leiomyoma.

*Vascular Hyalinosis : examples

- Hyalinosis of arteriolar walls in cases of hypertension diabetes mellitus & old age
- Hyalinosis of fibrosed glomeruli in cases of chronic glomerulonephritis

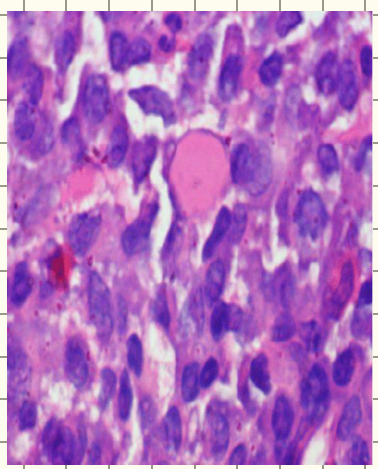

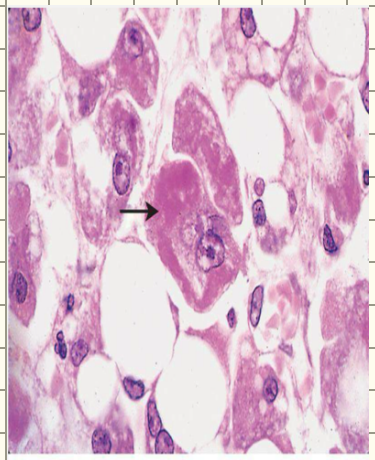

Fibrinoid degeneration



Collagen fibers موجود في الجسم
فالجسم بيعمل antibody هيكسّر هذا
الـ collagen fibers (خلل صناعي).
وهتتحول إلى fibrin like structure

Autoimmune disease هذا المرض هو



in the fibrinoid degeneration Collagen transformed into fibrin ← MCQ* لو سؤال

False

Because it transformed into fibrin like structure

GLYCOGEN

In case of glycogen storage diseases

